Digital Clubbing

Presented by: Anushka Bhandare

Notes

Introduction & Definition

Definition: Digital clubbing is a clinical sign characterised by bulbous, uniform swelling of the soft tissue of the terminal phalanx of a digit, with subsequent loss of the normal angle between the nail and the nail bed.

KEY FEATURES

- Increased nail curvature in both longitudinal and transverse axes
- Sponginess (fluctuation) of the nail bed on palpation
- Loss of the normal 160° Lovibond angle (angle becomes ≥ 180°)

Clubbing: Common Symptoms

Notes

Pathophysiology & Mechanism

The exact mechanism is not fully understood, but several theories have been proposed. The most widely accepted involves VEGF and megakaryocyte/platelet fragments.

VASCULAR ENDOTHELIAL GROWTH FACTOR (VEGF) / HYPOXIA THEORY

- Chronic hypoxia → ↑ **Vascular Endothelial Growth Factor (VEGF)** release from distal tissues
- VEGF promotes angiogenesis & vascular permeability
- Connective tissue hyperplasia in the nail bed
- Leads to soft-tissue swelling of the fingertip

MEGAKARYOCYTE / PLATELET THEORY

- Megakaryocyte fragments normally fragmented in lungs
- In lung/cardiac disease → fragments bypass the lungs
- Lodge in distal capillaries of the digits
- Release **Platelet-Derived Growth Factor (PDGF)** & **VEGF** → local tissue proliferation

Notes

Types & Causes of Clubbing

1. UNIDIGITAL CLUBBING

- Only **one finger** involved
- Suggests **local pathology**

CAUSES

- Trauma
- Infection

2. UNILATERAL CLUBBING

- **One hand** involved
- Usually due to **vascular or neurological causes**

CAUSES

- Arteriovenous fistula (AV fistula)
- Nerve injury

3. BILATERAL (GENERALISED) CLUBBING

- **Both hands** involved
- Indicates **systemic disease**

COMMON CAUSES

- **Lung diseases:** Lung cancer, Bronchiectasis, Lung abscess
- **Heart diseases:** Cyanotic congenital heart disease

4. DIFFERENTIAL CLUBBING

- Clubbing in **lower limbs only** (toes)
- Upper limbs remain **normal**

CLASSIC CAUSE

- **Patent Ductus Arteriosus (PDA)**

Notes

Grades of Clubbing

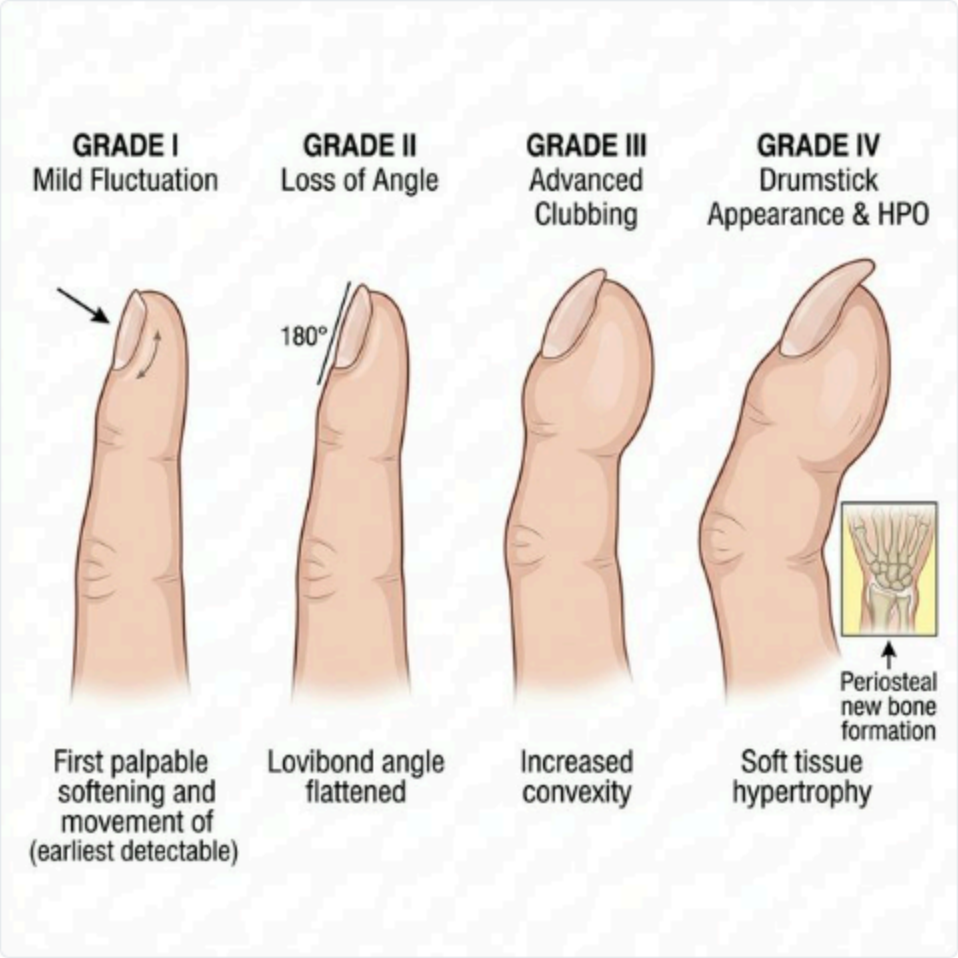

Progression from Grade 1 (fluctuation & softening) → Grade 2 (loss of Lovibond angle) → Grade 3 (increased curvature) → Grade 4 (drumstick appearance with HOA)

Notes

Clinical Assessment & Tests

1. Schamroth Window Test

Place dorsal surfaces of opposite terminal phalanges together. Normally a diamond-shaped window is visible. In clubbing, this window is obliterated.

2. Lovibond Angle / Profile Sign

The angle between the nail plate and the proximal nail fold (hyponychial angle) is measured. Normal: < 180° (approximately 160°). Clubbing: ≥ 180°.

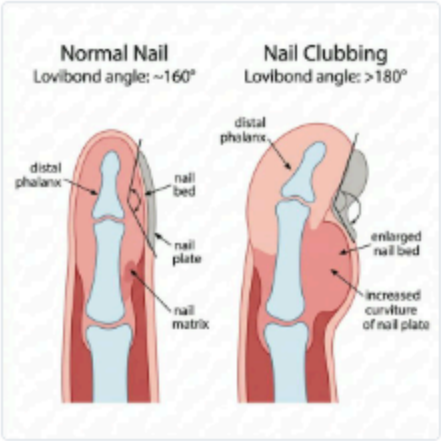

Normal digit (Lovibond angle ~160°) versus clubbed digit (angle ≥ 180°)

Notes

Schamroth Window Test — Detail

✓ NORMAL FINDING

- The test was developed by **Leo Schamroth in 1976** after he noticed the disappearance of this window during his own episode of infective endocarditis.
- When opposing terminal phalanges of the same finger are placed together (nail-to-nail), a small diamond-shaped 'window' of light is visible at the nail base.
- This window exists because the Lovibond angle is < 180°, creating a gap between the two nail-fold junctions.

✕ POSITIVE (CLUBBING)

- When opposing phalanges are placed together, the normal diamond-shaped window is **ABSENT** (obliterated).
- This occurs because: the Lovibond angle ≥ 180° → the nail-fold areas are flush against each other → no gap remains.
- **Interpretation:** Window present → No clubbing (negative). Window absent → Clubbing present (positive).

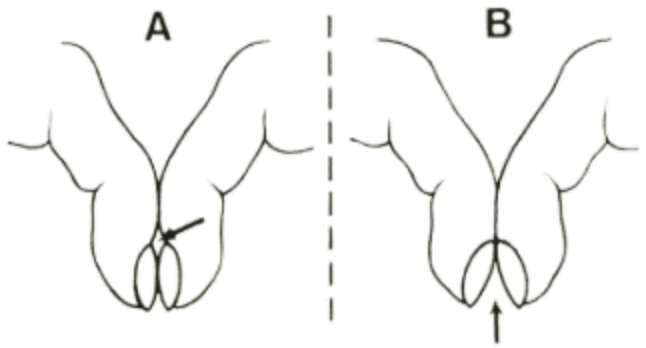

Fig. 1. Diagrams illustrating (A) normal finger contour, and (B) clubbing of the fingers.

Schamroth Window Test — Normal (negative) vs. Positive (clubbing present)

Notes

References

TEXTBOOKS

1. Hillegass, E. (2022). *Essentials of Cardiopulmonary Physical Therapy.* 5th ed. Elsevier.
2. Watchie, J. (2010). *Cardiovascular and Pulmonary Physical Therapy: Evidence to Practice.* 2nd ed. Saunders/Elsevier.
3. Pryor, J. A., & Prasad, A. S. (2008). *Physiotherapy for Respiratory and Cardiac Problems.* 4th ed. Churchill Livingstone.
4. Frownfelter, D., & Dean, E. (2012). *Cardiovascular and Pulmonary Physical Therapy: Evidence and Practice.* 5th ed. Mosby/Elsevier.

JOURNALS

5. Schamroth, L. (1976). Personal experience. *South African Medical Journal*, 50(9), 297–300.
6. Spicknall, K. E., & Zirwas, M. J. (2009). Clubbing: an update on diagnosis, differential diagnosis, pathophysiology, and clinical relevance. *Journal of the American Academy of Dermatology*, 60(6), 1073–1082.
7. Dickinson, C. J. (1993). The aetiology of clubbing and hypertrophic osteoarthropathy. *European Journal of Clinical Investigation*, 23(6), 330–338.
8. Lovibond, J. L. (1938). Diagnosis of clubbed fingers. *The Lancet*, 231(5979), 363–364.

Notes