MUSCLE
TISSUE

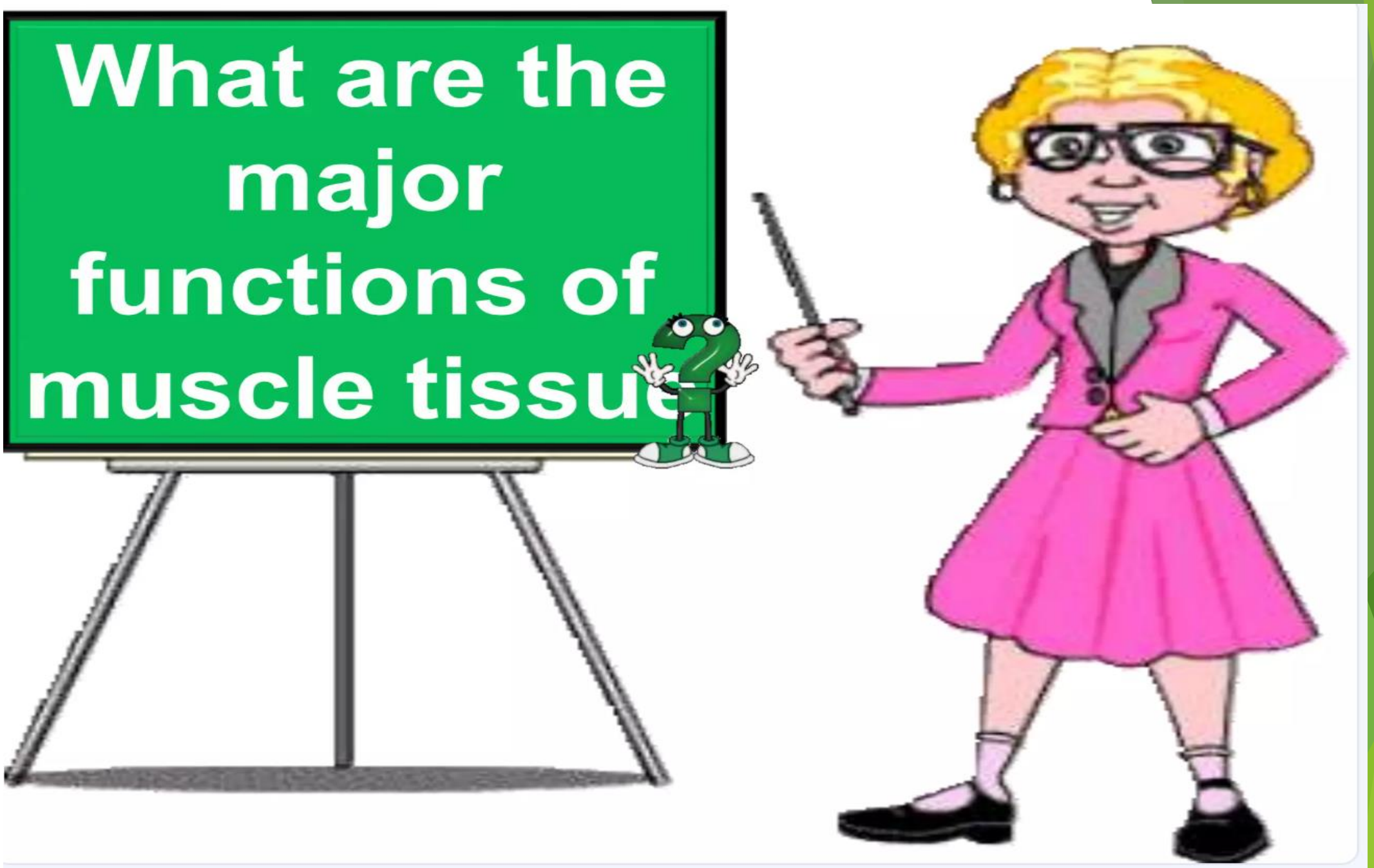
What are the major functions of muscle tissue?

There are four characteristics associated with muscle tissue:

Excitability

- Tissue can receive and respond to stimulation

Contractility

- Tissue can shorten and thicken

Extensibility

- Tissue can lengthen

Elasticity

- Tissue can return to its resting state

The characteristics of muscle tissue enable it to perform some important functions, including:

- Movement (both voluntarily and involuntarily)
- Maintaining posture
- Supporting soft tissues within body cavities
- Guarding entrance and exits of the body
- Maintaining body temperature

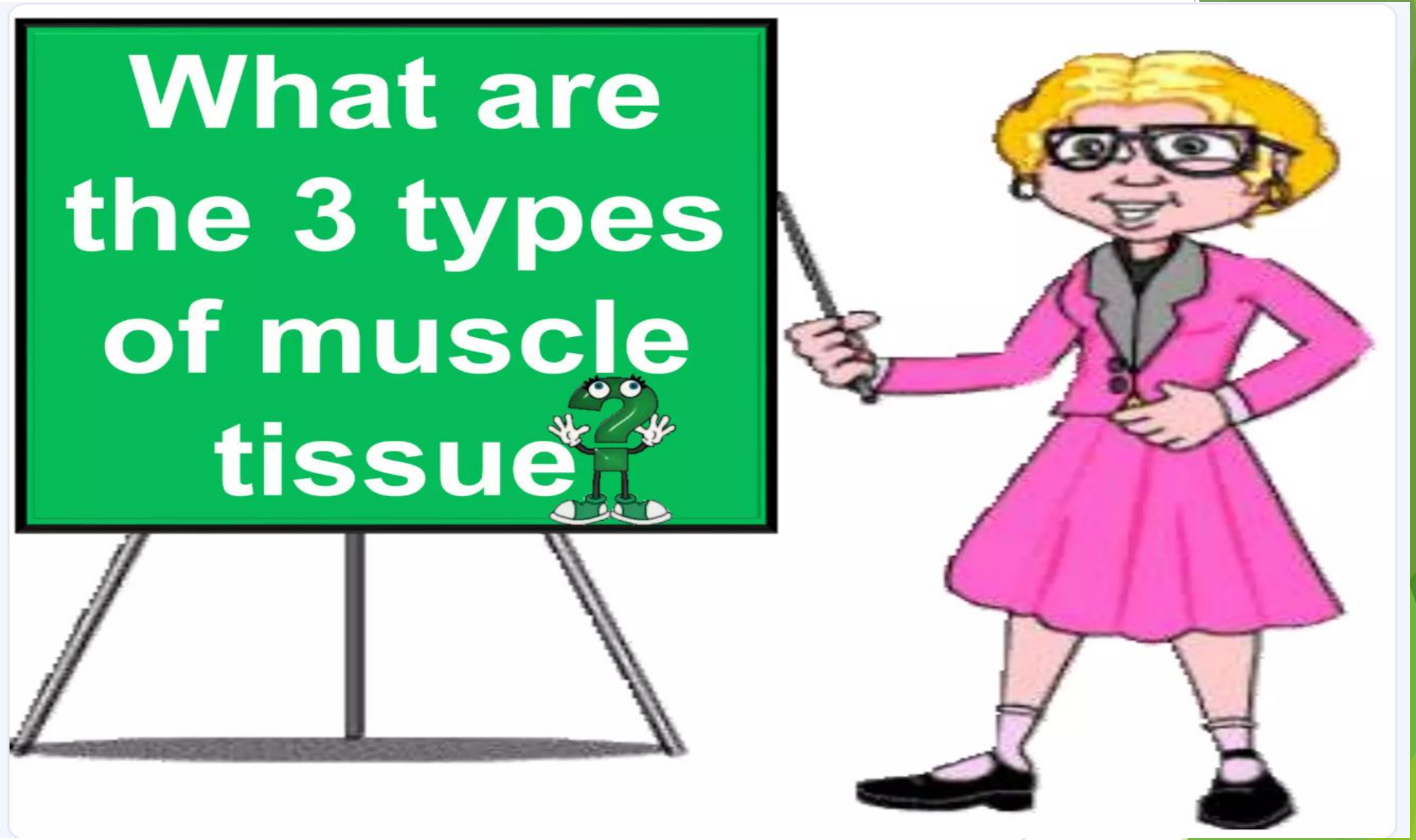
What are the 3 types of muscle tissue?

SKELETAL MUSCLE TISSUE

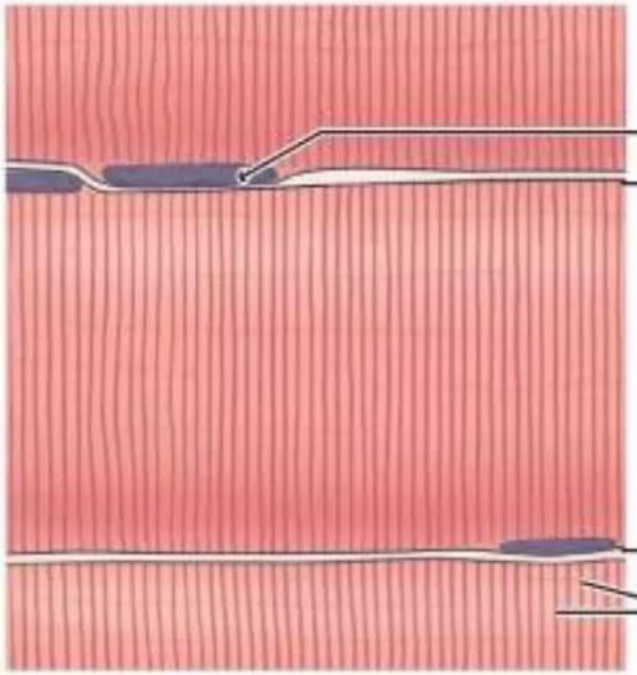



Skeletal muscles move or stabilize the position of the skeleton; guard entrances and exits to the digestive, respiratory, and urinary tracts; generate heat; and protect internal organs.

Skeletal Muscle Tissue features and characteristics:

- Fibers are **multinucleated** with peripheral nuclei
- **Actin** and **myosin** filaments form distinct cross- striation patterns
- Muscle is surrounded by connective tissue **epimysium**
- Muscle fascicles surrounded by connective tissue **perimysium**
- Each muscle fiber surrounded by connective tissue **endomysium**
- Voluntary muscle under conscious control

Sensitive stretch receptors called **neuromuscular spindles** are present within nearly all skeletal muscles

These spindles consist of a connective tissue capsule, in which are found modified muscle fibers called **intrafusal fibers** and numerous **nerve endings**

Neuromuscular spindles monitor the changes in the muscle lengths and activate complex reflexes to regulate muscle activity

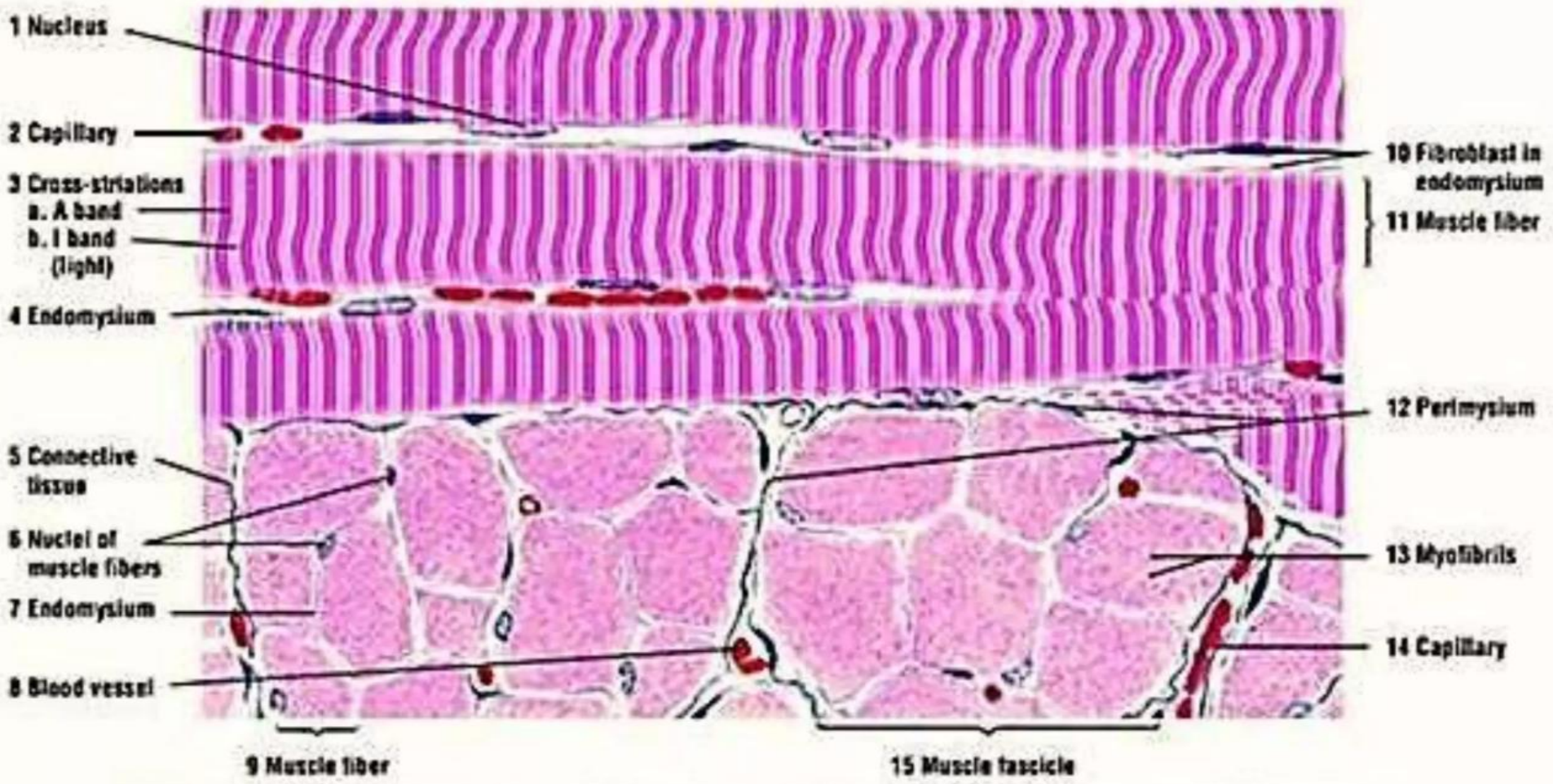

FIGURE 6.1 ■ Longitudinal and transverse sections of skeletal (striated) muscles of the tongue. Stain: hematoxylin and eosin. High magnification.

Functions of Skeletal Muscle Tissue

- Skeletal muscles function in pairs to bring about the coordinated movements of the limbs, trunk, jaws, eyeballs, etc.
- Skeletal muscles are directly involved in the breathing process.

SMOOTH MUSCLE TISSUE

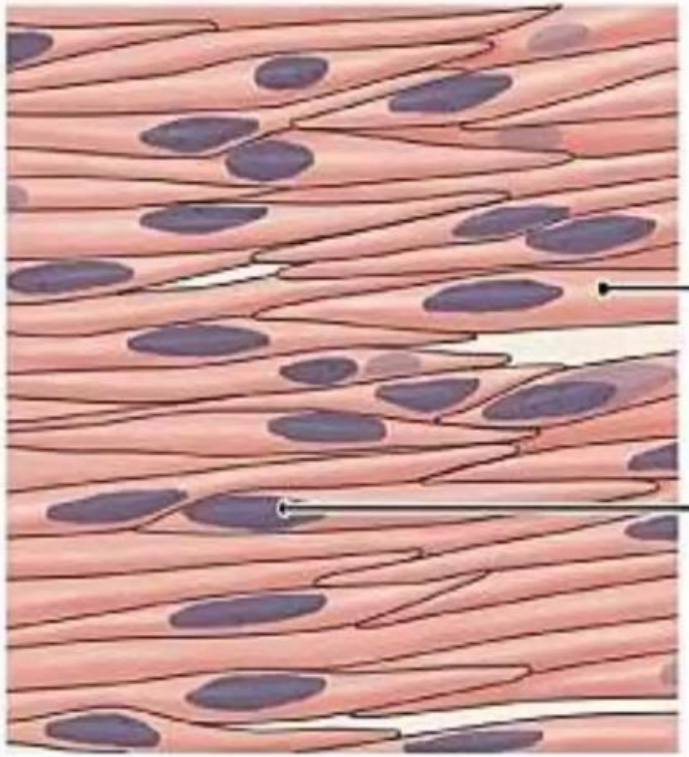

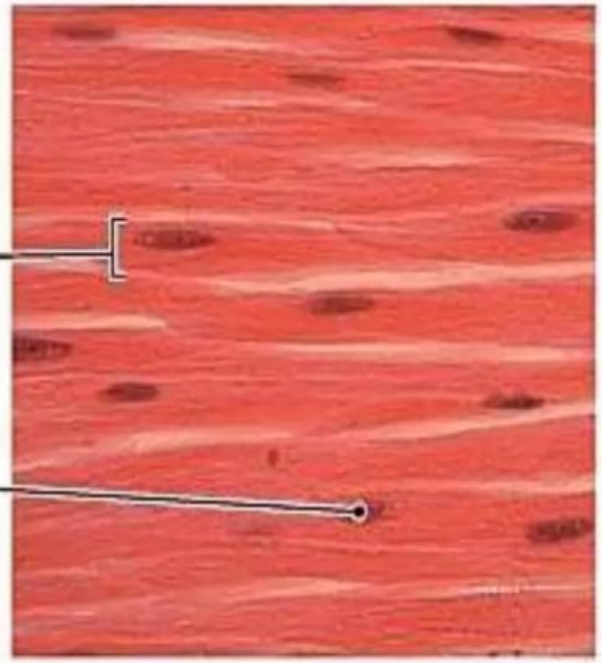

LM × 235

Smooth muscle moves food, urine, and reproductive tract secretions; controls diameter of respiratory passageways and regulates diameter of blood vessels.

© 2011 Pearson Education, Inc.

Smooth Muscle Tissue features and characteristics:

Found in **hollow organs** and **blood vessels**

Fibers are **fusiform** in shape and contain **single nuclei**

Each cell is filled with a **specialized cytoplasm**, the **sarcoplasm** and is surrounded by a thin cell membrane, the **sarcolemma**.

Contain contractile **actin** and **myosin** filaments; however, they are **not arranged** in the regular, cross-striated patterns that are visible in both the skeletal and cardiac muscle fibers

As a result, these muscle appear **smooth** or **nonstriated**

Smooth muscle fibers are also **involuntary muscles** and are, therefore, under autonomic nervous system and hormonal control

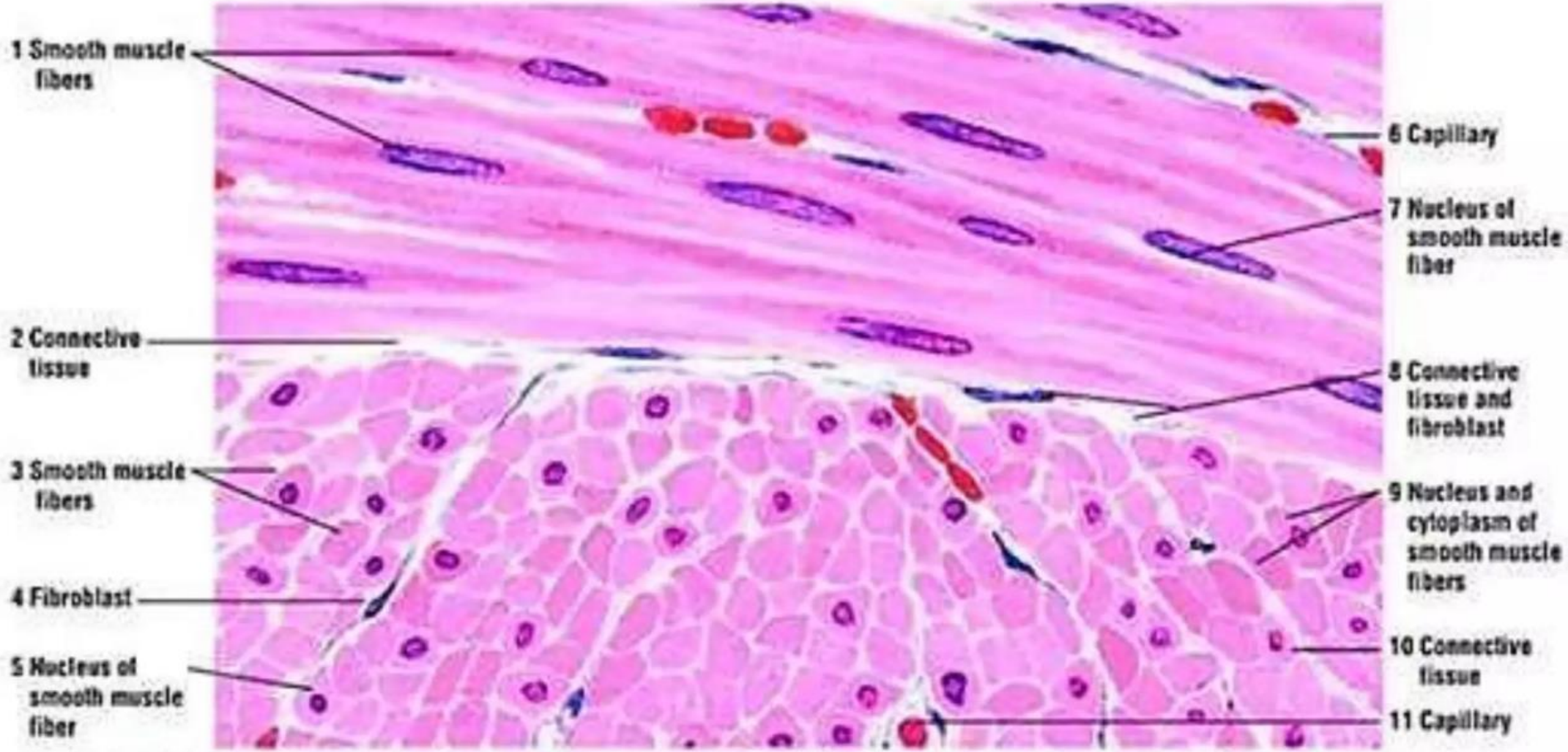

FIGURE 6.11 ■ Longitudinal and transverse sections of smooth muscle in the wall of the small intestine. Stain: hematoxylin and eosin. High magnification.

Functions of Smooth Muscle Tissue

- Smooth muscle *controls slow, involuntary movements* such as the contraction of the smooth muscle tissue in the walls of the stomach and intestines.
- The muscle of the arteries *contracts and relaxes to regulate the blood pressure and the flow of blood.*

CARDIAC MUSCLE TISSUE

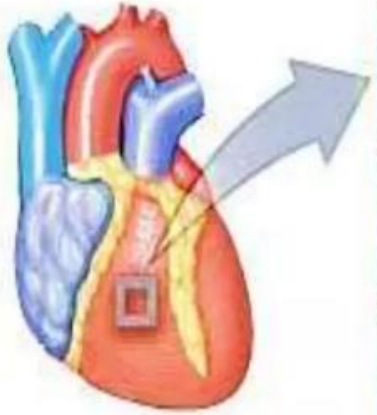

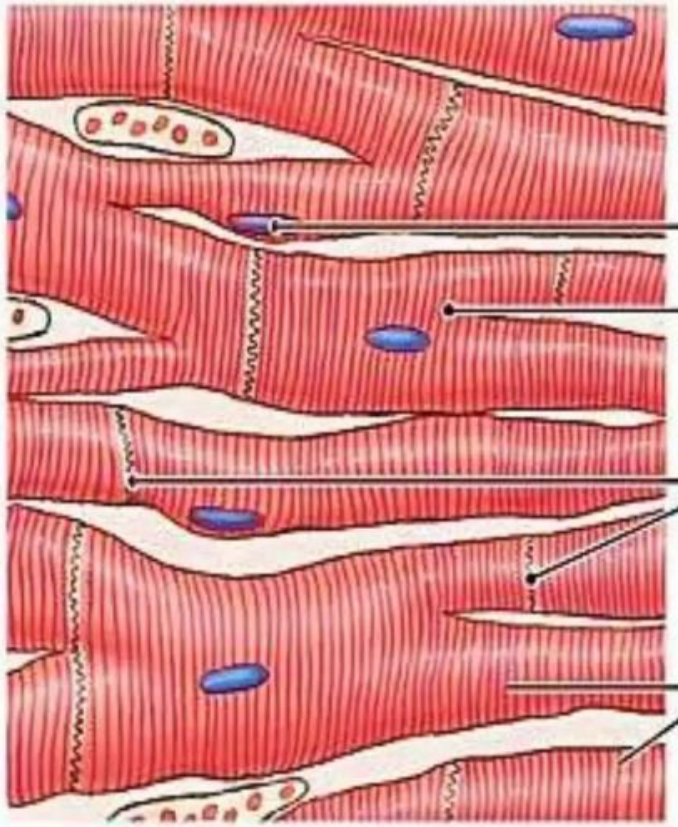

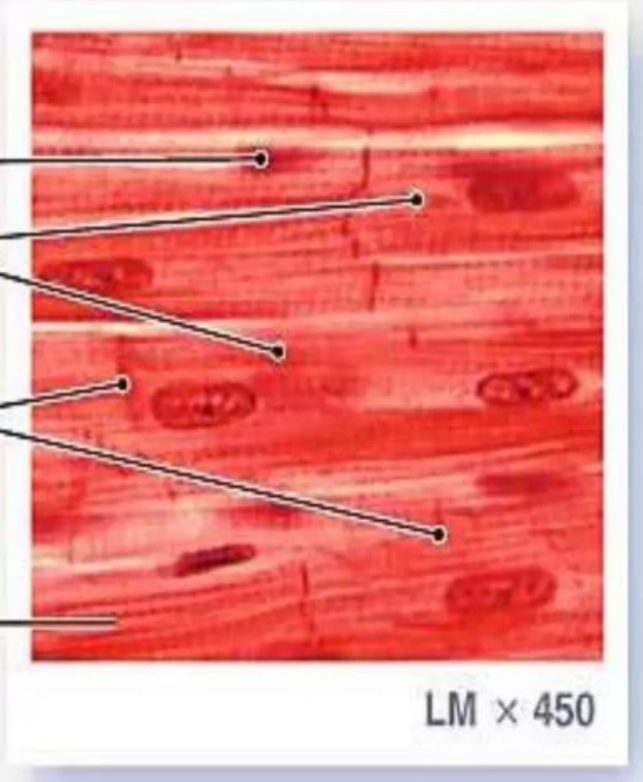

Cardiac muscle moves blood and maintains blood pressure.

Cardiac Muscle Tissue features and characteristics:

Primarily located in the walls and septa of the heart and in the walls of the large vessels attached to the **heart**(aorta and pulmonary trunk)

Similar to skeletal muscle, cardiac muscle fibers exhibit distinct **cross-striations** as a result of the arrangement of actin and myosin filaments.

Transmission electron microscopy reveals similar A bands, I bands, Z lines, and repeating sacromere units

Exhibits only one or two **central nuclei,** are shorter, and are **branched**

The terminal ends of adjacent cardiac muscle fibers show characteristic and dense-staining, end-to-end junctional complexes called **intercalated disks.**

Located in the intercalated disks are the **gap junctions** that enable ionic communication and continuity between adjacent cardiac muscle fibers.

Exhibit **autorhythmicity** and spontaneously generate stimuli

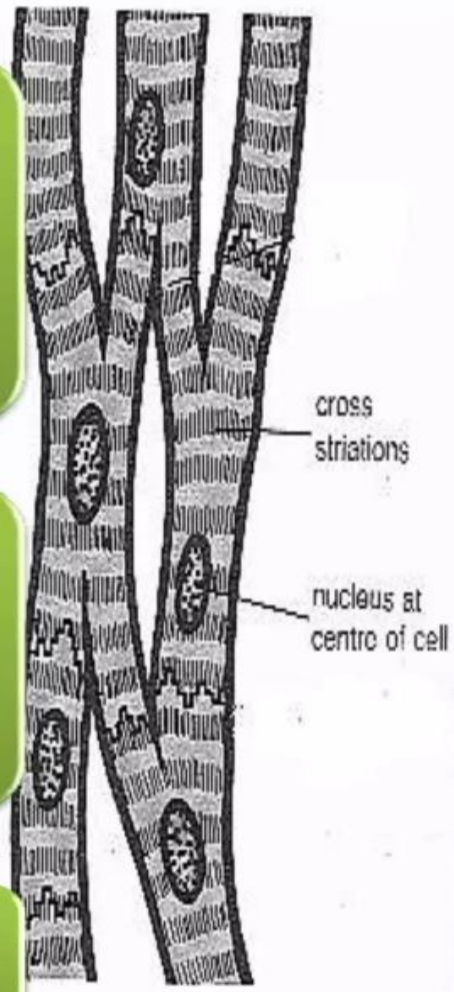

Functions of Cardiac Muscle Tissue

- Cardiac muscle tissue plays the most important role in the *contraction of the atria and ventricles of the heart.*
- It *causes the rhythmical beating of the heart*, circulating the blood and its contents throughout the body as a consequence.

Copyright © The McGraw-Hill Companies, Inc. Permission required for reproduction or display.

Smooth muscle

- has spindle-shaped, nonstriated uninucleated fibers.
- occurs in walls of internal organs.
- is involuntary.

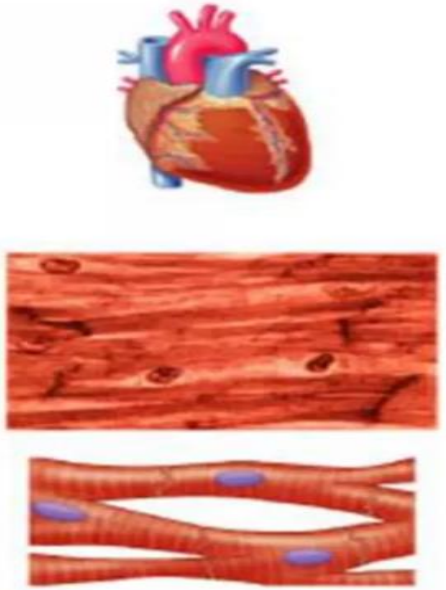

Cardiac muscle

- has striated, branched, uninucleated fibers.
- occurs in walls of heart.
- is involuntary.

Skeletal muscle

- has striated, tubular, multinucleated fibers.
- is usually attached to skeleton.
- is voluntary.