The Liver Artificial Intelligence (LAI) Consortium

Frederik Hartmann, Ruben Niemantsverdriet, Mara Veenstra, Maarten Thomeer, Stefan Klein, Martijn Starmans

Artificial Intelligence for Integrated Diagnostics (AIID), the Biomedical Imaging Group Rotterdam, Erasmus MC

Correspondance: f.hartmann@erasmusmc.nl

The Challenge - The differentiation of solid-appearing **liver lesions** on MRI is a key challenge for abdominal radiologists, as their **assessment** determines follow-up care and treatment. With the diagnosis relying heavily on the radiologist's experience, more **reproducible, quantitative** methods are strongly desired.

The Data - **Twelve hospitals** from **three continents** are retrospectively collecting routine MRI scans of pathologically confirmed solid-appearing liver lesions. With **no restrictions** on age, sex, or underlying liver conditions, the project aims to gather **anonymized** clinical and imaging data from **over 3000 patients**.

The Mission - of the LAI consortium is to fast-forward the **development, validation, and implementation** of machine learning methods that could **support MRI-based diagnosis** of liver lesions. To advance open science, the data will be shared in a **public dataset** — creating avenues for **discovery and collaboration**!

Our Members

Figure 1: *The Lai Consortium Members: Erasmus University Medical Center Rotterdam (NL), Academisch Ziekenhuis Maastricht (NL), University Medical Center Utrecht (NL), University Medical Center Groningen (NL), Stichting Amsterdam UMC (NL), Assistance Publique – Hôpitaux de Paris (FR), Università Di Pisa (IT), Università Degli Studi Di Palermo (IT), Institute Jules Bordet (BE), Medical University of Gdansk (PL), Icahn School of Medicine at Mount Sinai (USA), Austin Health (AUS), along with advisors from: the Dutch Hepatocellular & Cholangiocarcinoma Group (DHCG, NL), Dutch Benign Liver Tumor Group (DBLTG, NL), Dutch Liver Patient Organisation (NLV, NL), Collective Minds Radiology (SWE), Universitat de Barcelona (SP), University of California, San Diego (USA).*

Data

- **Data Included:**
  - Clinical (all patients): Age, sex, lesion phenotype(s) and underlying liver disease (if applicable)
  - MRI (all patients): T2-weighted and DCE sequences
  - Clinical (some patients): Alcohol abuse, Hepatitis, anonymized pathological report
- **Patients:**
  - **With Liver Lesions:**
    - Solid-appearing liver lesion (pathologically proven, except typical FNH, cysts, hemangiomas)
    - Untreated lesions, $\geq$1 cm, max 2 lesions per patient (RECIST criteria)
    - Underlying liver disease identified (if applicable)
  - **Without Lesions:**
    - Pathologically proven underlying liver disease
- **Additional Notes:**
  - Imaging has to be done within 3 months before biopsy/resection
  - Diagnosis based on latest (2019) WHO classification guidelines

We Want Your Opinion!

How do you think a tool for **differentiating liver lesions** should be used? As a second opinion? For patient filtering? Prioritization? Or do you have another brilliant idea? **We'd love to hear your thoughts!**

Imaging

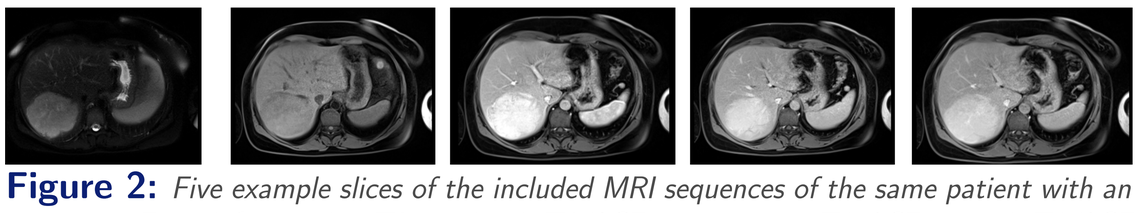

Figure 2: *Five example slices of the included MRI sequences of the same patient with an adenoma. From left to right: T2-weighted, T1 DCE pre-contrast, T1 DCE arterial, T1 DCE portal-venous, T1 DCE delayed phase.*

Reach out to us!

Are you interested in joining the consortium, want to contribute, or do you have a question? Please reach out to us! You find us in the NA building on floor 25 & 26, by mail lai.info@erasmusmc.nl, through our website www.lai-consortium.org or by scanning the QR Code.