International Journal of Advanced Medical Sciences and Technology (IJAMST)
ISSN: 2582-7596 (Online), Volume-2 Issue-2, February, 2022

Combined Techniques for Bilateral Maxillary and Nasal Reconstruction After Ablative Surgery for Adenoid Cystic Carcinoma

Jan Rustemeyer, Alexander Busch

Abstract*: Indolent tumor growth up to large tumor masses and broad infiltration of surrounding tissue are the most typical characteristics of malignant tumors of the nasal cavity and paranasal sinuses. If surgery is a therapeutic option, extended resections and complex reconstruction modalities have to be taken into account. We present a combination of different reconstruction techniques to restore midface integrity after bilateral maxillectomy, including parts of the nasal skeleton, for adenoid cystic carcinoma. After obtaining tumor-free margins, reconstruction was performed using a microvascular double-flap technique to achieve a neo-maxilla and soft tissue lining of the oral cavity, dental implantology with prosthetic restoration and the insertion of a patient-specific implant for nasal re-shaping and stability. In cases of extended maxillary resection, a combination of different techniques can achieve sufficient functional and aesthetic rehabilitation, and restore quality of life. Further studies are warranted to evaluate the long-term stability of such complex reconstructions. However, local tumor control remains the highest priority and will be essential for years.

***Keywords*: Adenoid Cystic Carcinoma, Bilateral Maxillectomy; Neo-Maxilla, Patient Specific Implant**

I. INTRODUCTION

Of all tumors of the nasal cavity and paranasal sinuses, one of the most dreaded entities is the adenoid cystic carcinoma (ACC), which bears a high risk of perineural invasion as well as early and distant spreading.

Because of these attributes, ACC can have an unpredictable clinical course, even if surgery is able to achieve tumor-free margins. In general, ACC is a rare tumor, with incidence ranging from 0.3 to 1.0 percent of all sinonasal tumors [1]-[3].

The 5-, 10- and 15-year survival rates are relatively high at 90, 80 and 60 percent, respectively, compared with patients with squamous cell carcinoma who have an overall 5-year survival rate of approximately 45 percent.

In high-risk patients with infiltration of the skull base and distant metastases at initial diagnosis, recurrences occur significantly more often. However, the 3-year survival rate despite recurrences still ranges between 70 and 80 percent [4], [5]. Radiation and/or chemotherapy have no effect on survival rates and are only indicated in cases in which inoperability has been confirmed for various reasons [6]. ACC predominantly metastasizes hematogenously into the lungs and liver, and metastasis is detected in at least 11 percent of all patients at initial diagnosis.

The mixed histological and solid subtypes especially are far more aggressive than the classical cribriform type, which has a relatively slow growth. Neck dissection does not bring any benefit with regard to survival, although micrometastases are reported to be present in the lymph nodes of the neck in 20 percent of patients [7], [8].

However, indolent tumor growth, eventually forming large masses in the paranasal sinus and nasal cavity, and broad infiltration of surrounding tissue including neural sheaths, make extended removal of soft and hard tissue necessary to achieve tumor-free margins. Therefore, tumor resection could result in major defects requiring complex reconstruction methods.

In our case report we present a successful reconstruction following bilateral maxillectomy including the nasal skeleton by the application of a combination of different techniques to restore the midface and nose, and to achieve dental rehabilitation. We aimed to encourage the use of different but combinable devices for expanded reconstructions to achieve optimum results in similar cases.

II. CASE REPORT

A 54-year-old female was admitted to our clinic with a complete obstruction of the nasal air passage that had existed for about six weeks and was accompanied by recurrent nose bleeds.

The patient's further history did not reveal any particular concomitant illnesses. She was always healthy and had never smoked. Upon anterior rhinoscopy, a tumorous solid mass filling the anterior nasal cavity was found. Computed tomography (CT) and magnetic resonance tomography (MRT) revealed a tumor with infiltration of the upper jaw, the main nasal cavity, the palate and the adjacent nasopharynx.

The histopathological work-up of multiple biopsies confirmed the diagnosis of a cribriform ACC. Further examinations for tumor staging, including positron emission tomography (PET)/CT strongly suggested metastasis to the left upper

Manuscript received on December 26, 2021.
Revised Manuscript received on January 05, 2022.
Manuscript published on February 10, 2021.
* Correspondence Author
Jan Rustemeyer*, Department of Oral and Maxillofacial Surgery, Plastic Operations, Clinical Center Bremen-Mitte, Germany. Email: jan.rustemeyer@klinikum-bremen-mitte.de
Alexander Busch, Department of Oral and Maxillofacial Surgery, Plastic Operations, Clinical Center Bremen-Mitte, Germany. Email: Alexander.Busch@fachaerztezentrum-hanse.de

© The Authors. Published by Lattice Science Publication (LSP). This is an open access article under the CC BY-NC-ND license (http://creativecommons.org/licenses/by-nc-nd/4.0/)

Fig. 1. Initial findings. (a) MRT shows broad tumor infiltration of the midface. (b) PET/CT suggests metastasis in the left upper lobe of the lung

lobe of the lung (Fig. 1). On the recommendation of the tumor board, the patient underwent resection of the ACC via midface degloving and the provisional supply of the resection cavity with tamponade, as well as functional neck dissection of the upper neck lymph node levels. Extended bony and soft tissue resections were necessary to achieve tumor-free margins. Afterwards the patient was transferred to the thoracic surgery clinic for resection of the histologically-confirmed lung metastasis. Adjuvant radiochemotherapy was recommended by the tumor board, but it was definitely refused by the patient and her relatives. The bilateral maxillary defect comprised the complete Le Fort I level, the anterior nasal skeleton, and displayed an Okay class III defect [9] (Fig. 2); hence, the "double flap" technique for reconstruction was deemed necessary.

For bony reconstruction, a microvascular iliac crest graft (deep circumflex iliac artery (DCIA) flap) was harvested together with parts of the internal oblique muscle for covering and internal lining of the maxillary sinuses and the nasal cavity. The vascular pedicle of the DCIA flap was anastomosed intraorally after dissection of the facial vessel

Fig. 2. CT scan revealed the amount of midface resection including the Le Fort I- level and the nose

in the buccal tissue. During the same operation, soft tissue reconstruction of the vestibule and palate, and intraoral coverage of the DCIA flap were achieved with a free fasciocutaneous radial forearm flap (Fig. 3). The further postoperative course was uneventful. After a total of six weeks, the patient was able to swallow and to speak clearly.

After one year of follow-up and with no evidence of local recurrence or further distant metastases, four dental implants were inserted into the neo-maxilla. During the same surgery, one lateral mini-plate was removed because of material loosening. Seven months later, prosthetic restoration comprising a removable denture was applied (Fig. 4). Subsequently, the tip of the nose drooped down to the level of the upper lip, because after the former tumor resection involving cartilaginous and bony parts, the anterior to middle soft tissue supply of the nasal skeleton was missing. As a result, the nose constantly hit any drinking vessel, making it practically impossible to drink fluids without a straw. In order to help the patient, we planned a reconstruction of the bony bridge of the nose and thus a lifting of the tip of the nose by means of a patient-specific implant (PSI) made of titanium. The virtual planning and production of the PSI by a 3D laser melting process was carried out using the computer-aided design/computer-aided manufacturing (CAD/CAM) technique in cooperation with our provider (3Di, Jena, Germany). The PSI was implanted as planned through an open lateral access and fixed with screws. It was particularly important for the success of the operation that the PSI could be completely enclosed within the existing soft tissue, especially intranasally (Fig. 5). The further course was uneventful and there was no exposure of the PSI. The patient was able to drink undisturbed again immediately after the operation. Two years after the last operation, the patient is still free of recurrence and very satisfied with the result achieved (Fig. 6).

© Copyright: All rights reserved.

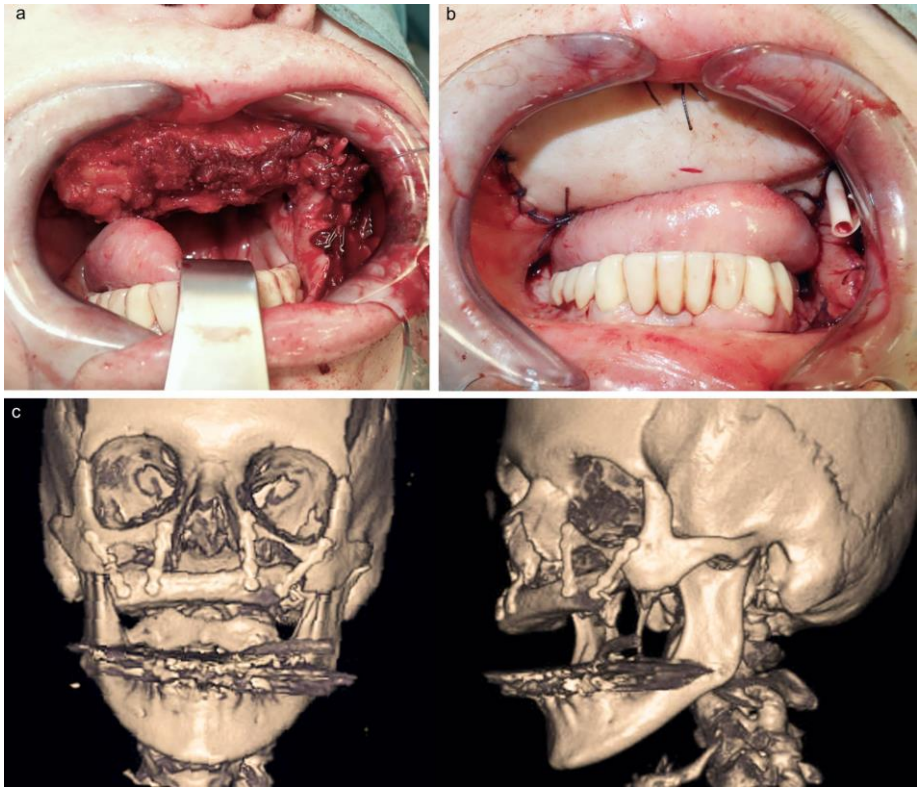

Fig. 3. (a) Insertion of a DCIA flap with an extended muscle cuff for bony reconstruction and internal lining and (b) a free fasciocutaneous radial flap for intraoral coverage. (c) 3D-CT scans of postsurgical DCIA flap position

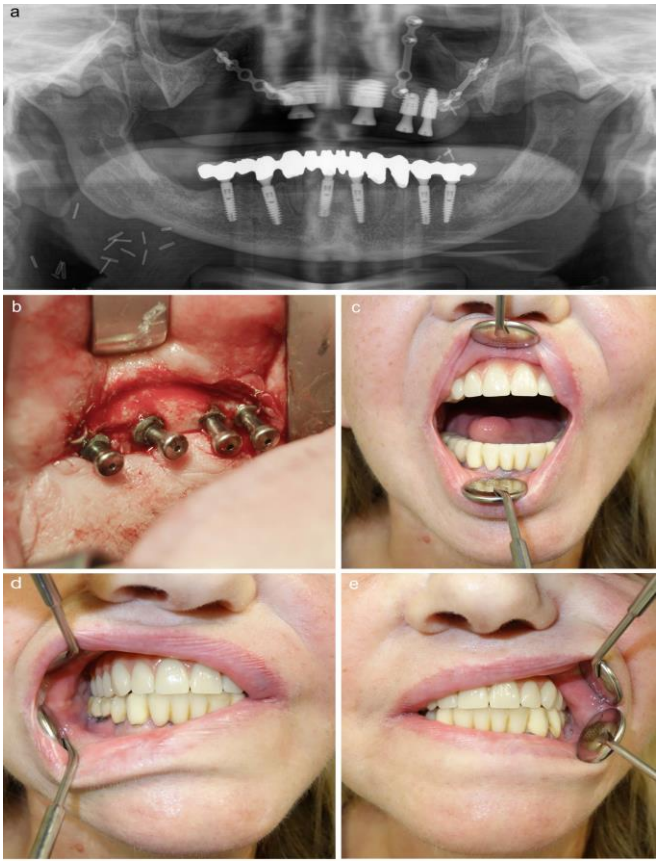

Fig. 4. (a) Orthopantomogram after implant loading. (b) Bone exposition and loading of four implants. (c–e) Mouth opening and occlusion with removable dentures

© Copyright: All rights reserved.

Fig. 5. (a) Virtual planning of PSI for nasal bridge and tip support. (b) PSI ready for implantation. (c) Lateral approach and insertion. (d) Postsurgical 3D-CT scan

Fig. 5. Profiles before (above) and after (below) implantation of the nasal PSI

© Copyright: All rights reserved.

Table -I: Literature review of reconstruction techniques for bilateral maxillary defects

Authors	Diagnosis	Reconstruction Technique	Follow-up
Joseph et al. [11]	Sarcoma (n = 3)	OCFF (n = 7)	25 months (mean)
	Carcinoma (n = 3)	RAF + rib graft (n = 1)	DFD (n = 1)
	Adenoma (n = 1)	ALT n = 1	LTF (n = 1)
	Mycosis (n = 2)	RFF n = 1	
	Trauma (n = 1)		
Rustemeyer et al. [12]	Osteonecrosis (n = 1)	OCFF	6 months, LTF
de la Parra et al. [13]	Chondroblastoma (n = 1)	Double-barreled, double skin paddle OCFF	6 months
Ettinger et. al. [14]	Avascular necrosis (n = 1)	OCFF, secondary dental implant loading	30 months
This study	Carcinoma (n = 1)	DCIAF, secondary dental implant loading, PSI	24 months

OCFF = osteocutaneous fibula flap, RAF = M. rectus abdominis flap, ALT = antero lateral thigh flap, RFF = radial forearm flap, DCIAF = deep circumflex iliac artery flap, PSI = patient-specific implant, DFD = died from disease, LTF = lost to follow-up

III. DISCUSSION

Although tumor growth of ACC in the sinonasal areas is relatively indolent, the chance of recovery depends on an early diagnosis by reacting early to suspicious symptoms. As described in our case report and in accordance with other reports, this includes nasal breathing that is obstructed on one or both sides for weeks and recurrent nasal bleeding [2], [6]. A specialist department must definitely clarify this. A further warning could be a craniomandibular dysfunction that is resistant to therapy or worsens within 3–4 weeks after the start of therapy, and even escalating to trismus. Imaging diagnostics, e.g., MRI, should be performed in such a case, even in young patients in order to rule out a space-consuming process [10]. Hence, it is all the more important to identify the cause of persistent and therapy-resistant, nonspecific symptoms and to investigate them in individual cases.

In the literature, the usages of various free flap techniques are reported following bilateral maxillary ablations mainly for malignant tumors. The spectrum ranges from soft tissue flaps for intraoral soft tissue coverage without addressing bony structures towards segmented osteocutaneous fibula flaps with optional involvement of the CAD/CAM technique and secondary implant loading. Follow-up periods with stable results are in some reports considerably long, but do not extend to 5 years (Tab. I). However, in some rare cases, more than one or two reconstruction features must be applied to obtain satisfactory results. Our case report shows the possibility of a total reconstruction of the midface and the nose through a three-way combination of different procedures, namely microvascular flap techniques to rebuild a neo-maxilla and soft tissue lining of the oral cavity, dental implantology with prosthetic restoration and the insertion of a PSI for nasal stability. Only by the combination of these was the patient functionally and aesthetically rehabilitated and her quality of life regained. The latter effect in particular is well-known and could be mostly attributed to the implant-supported removable overdentures [15]. The risk of complications from the complex surgical methods used in our case was assessed as relatively low, since no adjuvant therapies in the form of radiation or chemotherapy were carried out before or after the reconstruction. Otherwise, such a complex reconstruction would not have come into consideration in the relatively short period of time after resection. In this case, we would have resorted to an obturator as an interim or even a final solution. This well-known procedure has recently come back into focus [16], [17]. In our experience it is still inferior to surgical reconstructive procedures in terms of quality of life and comfort, especially for younger patients, but remains an option for patients, for example, who cannot undergo any extended surgical reconstruction due to their general condition and concomitant diseases. Despite successful reconstruction and rehabilitation, local tumor control is of the greatest importance even in cases in which clear and safe tumor margins were achieved. Thus, a balance must always be made between the various reconstructive procedures, adjuvant therapies and the risk of recurrence. In any case, regular tumor follow-up remains essential.

IV. CONCLUSION

Even after tumor-related bilateral maxillectomy, complex surgical reconstruction methods involving various techniques are successful and lead to an improved quality of life. Further studies are warranted to evaluate the long-term stability of such complex reconstructions. However, and independent from successful reconstruction, local tumor control is still the highest priority and remains essential.

REFERENCES

1. Rhee CS, Won TB, Lee CH, et al. Adenoid cystic carcinoma of the sinonasal tract: treatment results. Laryngoscope 116: 982-986, 2006.
2. Graça SAR, Sequeira H, Coelho G, et al. Adenoid cystic carcinoma of head and neck: apropos of a case. BMJ Case Reports. https://doi.org/10.1136/bcr-02-2012-5914, 2012.
3. He S, Li P, Zhong Q, Hou L, et al. Clinicopathologic and prognostic factors in adenoid cystic carcinoma of head and neck minor salivary glands: A clinical analysis of 130 cases. Am J Otolaryngol 38: 157-62, 2017.
4. Ellington CL, Goodman M, Kono SA, et al. Adenoid cystic carcinoma of the head and neck. Incidence and survival trends based on 1973–2007 surveillance, epidemiology, and end results data. Cancer 118: 4444-51, 2012.
5. Xu MJ, Wu TJ, van Zante A, et al. Mortality risk after clinical management of recurrent and metastatic adenoid cystic carcinoma. Journal of Otolaryngology - Head &Neck Surgery. https://doi.org/10.1186/s40463-018-0273-z, 2018.

© Copyright: All rights reserved.

6. Lahjaouj M, Berrada O, Rayhane A, et al. Advanced adenoid cystic carcinoma of maxillary sinus: Rare case report and review of literature. Int J Surg Case Rep. https://doi.org/10.1016/j.ijscr.2021.02.008, 2021.
7. Rahmani K, Zahir ST, Yazdi MB, et al. Carcinoma of Maxillary Sinus in a 43-Year-Old Male: Rare Case Report and Review of Literature. Case Rep Med. https://doi.org/10.1155/2017/2324717, 2017.
8. Cordesmeyer R, Kauffmann P, Laskawi R, et al. The incidence of occult metastasis and the status of elective neck dissection in salivary adenoid cystic carcinoma: a single center study. Oral Surg Oral Med Oral Pathol Oral Radiol. https://doi:10.1016/j.oooo.2018.01.013, 2018.
9. Okay DJ, Genden E, Buchbinder D, et al. Prosthodontic guidelines for surgical reconstruction of the maxilla: a classification system of defects. J Prosthet Dent 86: 352-63, 2001.
10. Sari-Rieger A, Hassfeld S, Junker K, et al. Adenoid cystic carcinoma of the skull base mimicking temporomandibular disorder. Oral Maxillofac Surg 18: 115-8, 2014.
11. Joseph ST, Thankappan K, Buggaveeti R, et al. Challenges in the reconstruction of bilateral maxillectomy defects. J Oral Maxillofac Surg 73: 349-56, 2015.
12. Rustemeyer J, Melenberg A, Junker K, et al. Osteonecrosis of the maxilla related to long-standing methamphetamine abuse: a possible new aspect in the etiology of osteonecrosis of the jaw. Oral Maxillofac Surg 18: 237-41, 2014.
13. de la Parra M, Sanchez G, Lopez J, et al. Total maxillary reconstruction using a double-barreled and double skin paddle fibular flap after total maxillectomy. Arch Plast Surg 40: 779-82, 2013.
14. Ettinger KS, Nathan J, Guerrero LM, et al. Microvascular Reconstruction of Total Maxillary Avascular Necrosis as a Complication of Routine Orthognathic Surgery. J Oral Maxillofac Surg 78: 1846-58, 2020.
15. Kumar VV, Jacob PC, Ebenezer S, et al. Implant supported dental rehabilitation following segmental mandibular reconstruction- quality of life outcomes of a prospective randomized trial. J Craniomaxillofac Surg 44: 800-10, 2016.
16. Bahrami M, Falahchai SM. Full Mouth Reconstruction of a Skeletal Class II Division 1 Patient with Adenoid Cystic Carcinoma Using an Interim Immediate Obturator and a Definitive Obturator. Case Rep Dent. https:// doi.org/10.1155/2017/5458617, 2017.
17. Gueutier A, Kün-Darbois JD, Laccourreye L, et al. Anatomical and functional rehabilitation after total bilateral maxillectomy using a custom-made bone-anchored titanium prosthesis. Int J Oral Maxillofac Surg 49: 392-6, 2020.

AUTHORS PROFILE

Rustemeyer, Jan. Professor, MD, DMD. is the Head of the Department of Oral and Maxillofacial Surgery and Plastic Operations, and the Head of the certified Head and Neck Cancer Unit at the Clinical Center Bremen-Mitte, Germany. He is board member of the German association of Oral Maxillofacial Surgery and of the European Association of Cranio-Maxillo-Facial Surgery. His special areas are among others the plastic and reconstructive surgery of the head and neck, orthognathic surgery, temporomandibular joint- surgery, and aesthetic surgery**.**

Busch, Alexander, DMD. is Chief Consultant and Vice Head of the Outpatient Sector of the Department of Oral and Maxillofacial Surgery and Plastic Operations at the Clinical Center Bremen-Mitte, Germany. He is Master of Implantology and board member of the German association of Implantology. His special areas are among others the preprosthodontic surgery, bone augmentation, implantology, dentoalveolar surgery and trauma surgery.

© Copyright: All rights reserved.