International Journal of Advanced Medical Sciences and Technology (IJAMST)
ISSN: 2582-7596 (Online), Volume-1 Issue-5, December, 2021

Secondary Treatment of Facial Asymmetry in Hemifacial Microsomia

Jan Rustemeyer, Susanne Sehhati Chafai Leuwer

Abstract*: Hemifacial microsomia is most often diagnosed at birth and comprises varying degrees of malformations of one side of the face. Depending on the malformations involved, multiple procedures are required as primary treatment approaches, often embedded in an interdisciplinary concept from birth to adolescence. However, with regard to the symmetry of the face, soft tissue and bony discrepancies between the normal and the affected side often remain recognizable or even persist after surgery, resulting in lasting disturbed facial harmony. Such patients may have a high burden of disease. In our case report, we present the clinical course of a 39-year-old female with hemifacial microsomia, who was suffering persistent facial asymmetry after primary treatment comprising surgery on the mandible and soft tissue augmentation with the use of a free muscle flap. By means of virtual planning tools and patient-specific implants for genioplasty and bony augmentation in a first step followed by soft tissue augmentation with autologous fat cells in a second step, a very satisfactory result was achieved for both patient and medical staff. Hence, for secondary treatment of facial asymmetry in adulthood, a combined and step-by-step therapy addressing both soft and hard tissue seems to be the key to success.

Keywords: Asymmetry, CAD/CAM, Genioplasty, Lipofilling, Patient Specific Implant.

I. INTRODUCTION

Patients with skeletal facial asymmetries are not uncommon in everyday practice. In the majority of cases, patients are admitted to surgical units for orthognathic surgery or surgery of the temporo-mandibular joint as primary treatment options to correct their laterognathism [1]-[3]. However, it is sometimes difficult to recommend a suitable therapy beyond the above-mentioned options, especially when routine procedures are neither indicated at all or any more, or have not shown the desired success previously. These conditions leave the patients with a high level of suffering from their asymmetric and disharmonic face. In such cases, which often consist of complex malformations, patients should be helped by combining different procedures and techniques in the scope of a secondary treatment. This case report aimed to give an idea of one possible option for a treatment algorithm for these cases.

Manuscript received on November 15, 2021.
Revised Manuscript received on November 27, 2021.
Manuscript published on December 10, 2021.
* Correspondence Author
Rustemeyer, Jan*, Department of Oral and Maxillofacial Surgery, Plastic Operations, Clinical Center Bremen-Mitte, Germany.
Email: jan.rustemeyer@klinikum-bremen-mitte.de
Sehhati Chafai Leuwer, Susanne, Department of Oral and Maxillofacial Surgery and Plastic Operations, Clinical Center Bremen-Mitte, Germany. Email: Susanne.SehhatiChafaiLeuwer@gesundheitnord.de

© The Authors. Published by Lattice Science Publication (LSP). This is an open access article under the CC BY-NC-ND license (http://creativecommons.org/licenses/by-nc-nd/4.0/)

II. CASE REPORT

A 39-year-old patient presented herself with the question of an aesthetic improvement on her "crooked face". Her left-sided facial underdevelopment, especially of the lower facial third, and the associated asymmetry had existed since birth. More than 20 years ago, various therapies were used elsewhere, namely orthodontics, surgery of the mandible and soft tissue augmentation using a muscle transplant. However, none of the procedures would have led to the desired success in the long term. Clinically, there was a clear atrophy of the left lower face with a deviation of the center of the face to the left. Hence, taking into account the previous history, the patient still suffered from hemifacial microsomia. There were also preauricular and submandibular scars on the left due to previous surgeries. Although the dental center of the lower jaw was also shifted to the left, the dental occlusion was well compensated. Radiologically, an orthopantomogram (Fig. 1) showed a clear narrowing of the entire left lower jaw area and a previously inserted mini osteosynthesis plate in the area of the ascending ramus. In order to meet the patient's understandable desire for aesthetic improvement, it was decided to carry out a two-stage procedure with precisely this aim.

Fig. 1. Initial orthopantomogram shows narrowing of the entire left lower jaw area and a previously-inserted mini osteosynthesis plate after primary treatment

The first step involved an osseous genioplasty with rotation and translation of the chin to the right side with an adjustment to the center of the face. In the same procedure, a basal augmentation of the left mandible was carried out using a patient-specific implant (PSI) made of poly-ether-ether-ketone (PEEK) to correct the bony deficit. Due to the complexity of the planning, the computer-aided design/computer-aided manufacturing (CAD/CAM) technique was used.

Cutting and burring guides for intraoperative marking of the osteotomy lines and an individual osteosynthesis plate to fix the chin in the new position were planned for relocation of the chin. The size and extent of the PSI for augmentation was determined by the difference revealed by projection of the right side onto the left half of the mandible (Fig. 2).

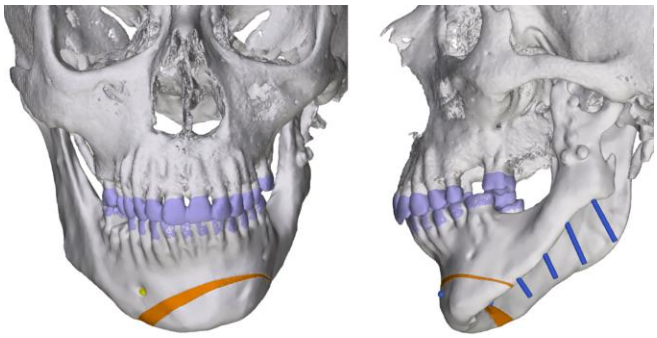

Fig. 2. Virtual planning of osteotomy lines (orange) and size of the patient-specific implant (PSI: blue bars)

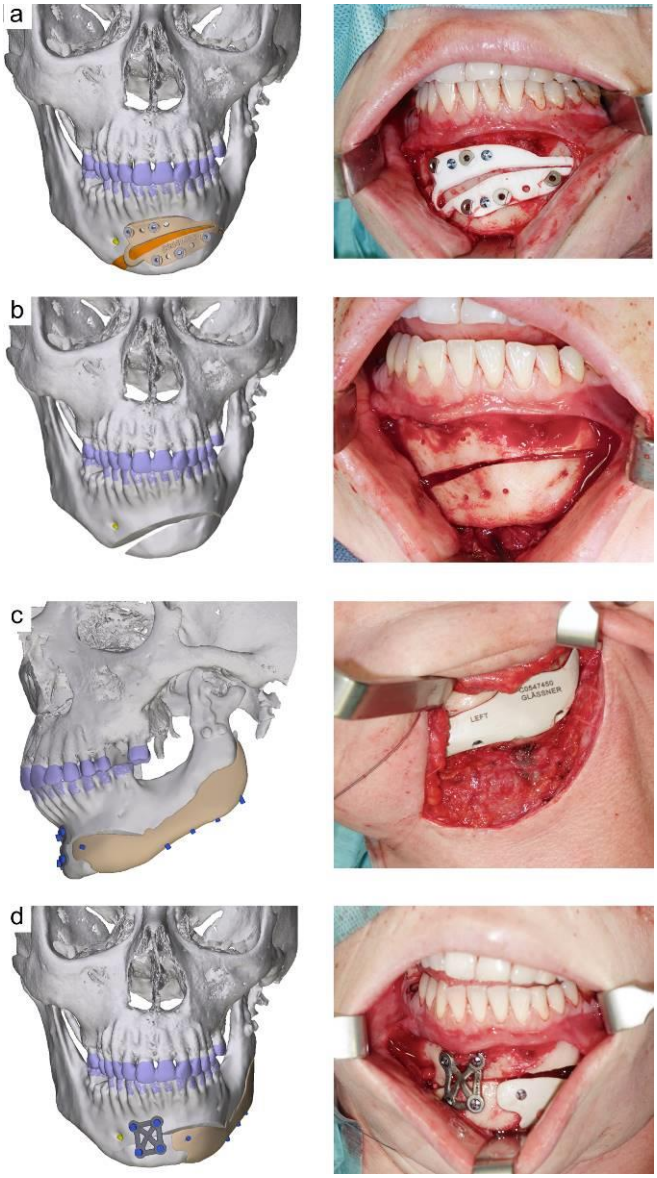

Fig. 3. Virtual planning and surgical implementation.

(a) Insertion of cutting and burring guide for the piezotome, oscillating saw and fixation screws, (b) osteotomy of the chin, (c) insertion of the PSI, (d) fixation of the chin

Additionally, the PSI provided an anterior extension to embed the left side of the repositioned chin and thus gain stability. The cutting and burring guide, osteosynthesis plate and PSI were produced using the 3D-laser melting process (KLS Martin, Tuttlingen, Germany) and inserted intraoperatively after sterilization (Fig. 3). In the second step six months after the first surgery, an autologous fat tissue transfer (lipofilling) was carried out for further augmentation and contouring of the soft tissue in the cheek area, after removing 60 mL of pure fat tissue from the abdominal and lateral thigh region (liposuction) (Fig. 4).

Fig. 4. Liposuction and lipofilling procedures

With the algorithm of first bony contour improvement and second soft tissue modelling, almost complete facial symmetry was achieved, to the patient's great satisfaction, and the result has been stable for more than one year (Fig. 5).

III. DISCUSSION

Hemifacial microsomia is the second most common congenital malformation of the face after cleft lip and palate and occurs with a frequency of one case per 5,600 to 20,000 births [4]. A duplication of a chromosome has been discussed as the cause of the phenotypically very heterogeneous clinical appearance, which can also be detected as an oncogene in medulloblastoma, the malignant, embryonic tumor of the cerebellum [5]. Oculo-auriculo-vertebral dysplasia and Goldenhar syndrome are often used as synonyms, these terms being preferred when there are additional malformations in the area of the ear and eyes. In these cases, interdisciplinary treatment concepts play an important role. A differential diagnosis can be progressive facial hemiatrophy, which is also known as Parry-Romberg syndrome. The symptoms develop almost later in the course of the first and second decades of life, especially in women, and also lead to varying degrees of facial asymmetry. The cheek region is often affected initially. The causes of this are manifold and range from infections through local circulatory disorders to autoimmune processes [6], [7]. In the case described here of a 39-year-old patient with a pretreated hemifacial microsomia, the therapy focused on the persistent underdevelopment of the lower third of the face with resulting bony and soft-tissue asymmetry. In particular, the desire for an aesthetic correction was decisive for the presentation of the patient, who is professionally in the public eye.

© Copyright: All rights reserved.

In cases of hemifacial microsomia there are often malformations of the skeleton causing conditions with deviations, especially in the vertical and transversal planes, so that appropriate orthodontic and orthognathic surgical therapies for primary skeletal treatment are necessary after

Fig. 5. Clinical course towards facial symmetry. Initial finding (above), after genioplasty and PSI augmentation (middle), one year after lipofilling (bottom)

© Copyright: All rights reserved.

growth is complete. Depending on the deficit, free microvascular flaps can also be used for soft tissue augmentation [8], [9]. Nevertheless, as in our case, it is not always possible to completely correct facial asymmetries. Consequently, further corrective interventions on the soft facial tissues and on the bony facial skull will be necessary at a later date. While the CAD/CAM technique is already being used successfully by many maxillofacial surgery clinics for genioplasty or bone reconstructions [10], [11], a combination of both surgical techniques with autologous fat tissue augmentation, as described here, is rare. In particular, the latter technique allows a soft tissue deficit to be calculated to precisely compensate for asymmetry. In addition, modeling can also be carried out in the augmented area. However, the question of the stability of the result always arises. Our experiences with liposuction/lipofilling therapy coincide with those in the literature. Fat absorption usually occurs over the first three months, after which it rarely occurs [12]. Overcorrection should also be avoided in the soft tissue area of the cheek [13]. In our patient's case, a stable result can now be seen after one year without a visible reduction in the volume of fatty tissue augmentation. Thus, a combination of genioplasty, bone augmentation using PSI and subsequent fat tissue augmentation achieved a result that was very acceptable for the patient and the medical staff.

IV. CONCLUSION

Both bony and soft tissue deficits are possible causes of facial asymmetries. Secondary corrections in adulthood often require several interventions and combinations of different techniques, depending on the severity of the deformity. However, following our algorithm, patients in everyday practice who suffer from facial asymmetry should be given hope that this can at least be significantly improved.

REFERENCES

1. Fariña R, Mebus C, Mayer C, et al. Unilateral sagittal split ramus osteotomy: an alternative for some cases of asymmetric mandibular prognathism. Int J Oral Maxillofac Surg 47: 630-637, 2018.
2. Abotaleb B, Bi R, Telha W, et al. Treatment measures of hemimandibular hyperplasia and associated facial deformities. J Craniomaxillofac Surg 49: 126-134, 2021.
3. Sembronio S, Tel A, Robiony M. Protocol for fully digital and customized management of concomitant temporomandibular joint replacement and orthognathic surgery. Int J Oral Maxillofac Surg 50: 212-219, 2021.
4. Gorlin RJ CM, Hennekam RCM. Syndromes of the head and neck. New York: Oxford University Press, 2001.
5. Zielinski D, Markus B, Sheikh M, et al. OTX2 Duplication Is Implicated in Hemifacial Microsomia. PLoS ONE 9: e96788, 2014.
6. El-Kehdy J, Abbas O, Rubeiz N. A review of Parry-Romberg syndrome. J Am Acad Dermatol 67: 769-784, 2012.
7. Indurkar A, Degwekar S, Gondivkar S. Facial hemihypertrophy and facial hemiatrophy: Report of 2 cases. J Indian Acad Oral Med Radiol 20: 57-59, 2008.
8. Abdullaev KF, Orlova EV, Yadav MK, et al. Preoperative planning for advanced modelling of anterolateral thigh flaps in the treatment of servere hemifacial atrphy in Parry-Romberg and Goldenhar syndrome. JPRAS Open 16: 36-49, 2018.
9. Kaira GDS, Gupta RK. Facial contouring with parascapular free flap: A case series of 22 cases. Indian J Plast Surg 46: 562-567, 2013.
10. Rustemeyer J, Busch A, Sari-Rieger A. Application of computer-aided designed/computer-aided manufactured techniques in reconstructing maxillofacial bony structures. Oral Maxillofac Surg 18: 471-476, 2014.
11. Rückschloß T, Ristow O, Kühle R, et al. Accuracy of laser-melted patient-specific implants in genioplasty - A three-dimensional retrospective study. J Craniomaxillofac Surg 48: 653-660.
12. Karmali RJ, Hanson SE, Nguyen AT, et al. Outcomes following Autologous Fat Grafting for Oncologic Head and Neck Reconstruction. Plast Reconstr Surg 142: 771-780, 2018.
13. Azoury SC, Shakir S, Bucky LP, et al. Modern Fat Grafting Techniques to the Face and Neck. Plast Reconstr Surg 148: 620e-633e, 2021.

AUTHOR PROFILE

Rustemeyer Jan., Professor, MD, DMD. is the Head of the Department of Oral and Maxillofacial Surgery and Plastic Operations, and the Head of the certified Head and Neck Cancer Unit at the Clinical Center Bremen-Mitte, Germany. He is board member of the German association of Oral Maxillofacial Surgery and of the European Association of Cranio-Maxillo-Facial Surgery. His special areas are among others the plastic and reconstructive surgery of the head and neck, orthognathic surgery, temporomandibular joint- surgery, and aesthetic surgery.

Sehhati Chafai Leuwer Susanne., MD, DMD- is the Vice Head of the Department of Oral and Maxillofacial Surgery and Plastic Operations and the Head of the Cleft Lip Palate and Malformations Unit at the Clinical Center Bremen-Mitte, Germany. She is board member of the German association of Oral Maxillofacial Surgery and the European association of Cranio-Maxillo-Facial Surgery. Her special areas are among others the plastic and reconstructive surgery, aesthetic surgery and other aesthetic treatments.

© Copyright: All rights reserved.