Respiratory Medicine
Series Editors: Sharon I.S. Rounds · Anne Dixon · Lynn M. Schnapp

Anastassios C. Koumbourlis
Mary A. Nevin *Editors*

Pulmonary Complications of Non-Pulmonary Pediatric Disorders

AMERICAN THORACIC SOCIETY 1905 ATS
We help the world breathe®
PULMONARY • CRITICAL CARE • SLEEP

Humana Press

Respiratory Medicine

Series Editors

Sharon I.S. Rounds
Alpert Medical School of Brown University
Providence, Rhode Island, USA

Anne Dixon
University of Vermont, College of Medicine
Burlington, Vermont, USA

Lynn M. Schnapp
Medical University of South Carolina
Charleston, South Carolina, USA

More information about this series at http://www.springer.com/series/7665

Anastassios C. Koumbourlis
Mary A. Nevin
Editors

Pulmonary Complications of Non-Pulmonary Pediatric Disorders

Humana Press

AMERICAN THORACIC SOCIETY 1905 ATS
We help the world breathe®
PULMONARY • CRITICAL CARE • SLEEP

Editors
Anastassios C. Koumbourlis
George Washington University
School of Medicine
Children's National Medical Center
Washington, DC
USA

Mary A. Nevin
Ann & Robert H. Lurie Children's Hospital
Northwestern Feinberg School of Medicine
Chicago, IL
USA

ISSN 2197-7372 ISSN 2197-7380 (electronic)
Respiratory Medicine
ISBN 978-3-319-69619-5 ISBN 978-3-319-69620-1 (eBook)
https://doi.org/10.1007/978-3-319-69620-1

Library of Congress Control Number: 2017964516

© Springer International Publishing AG 2018
This work is subject to copyright. All rights are reserved by the Publisher, whether the whole or part of the material is concerned, specifically the rights of translation, reprinting, reuse of illustrations, recitation, broadcasting, reproduction on microfilms or in any other physical way, and transmission or information storage and retrieval, electronic adaptation, computer software, or by similar or dissimilar methodology now known or hereafter developed.
The use of general descriptive names, registered names, trademarks, service marks, etc. in this publication does not imply, even in the absence of a specific statement, that such names are exempt from the relevant protective laws and regulations and therefore free for general use.
The publisher, the authors and the editors are safe to assume that the advice and information in this book are believed to be true and accurate at the date of publication. Neither the publisher nor the authors or the editors give a warranty, express or implied, with respect to the material contained herein or for any errors or omissions that may have been made. The publisher remains neutral with regard to jurisdictional claims in published maps and institutional affiliations.

Printed on acid-free paper

This Humana Press imprint is published by Springer Nature
The registered company is Springer International Publishing AG
The registered company address is: Gewerbestrasse 11, 6330 Cham, Switzerland

Contents

Pulmonary Complications of Cardiovascular Disorders 1
Anastassios C. Koumbourlis

Respiratory Complications of the Gastrointestinal System 21
Sonal Malhotra and Mary A. Nevin

Pulmonary Complications of Haematologic Disorders 31
Anne Greenough, Katie Hunt, and Elinor Charles

Pulmonary Complications of Malignancies and Blood and Marrow Transplantation 51
Geshani Jayasuriya, Beryl Lin, Steven J. Keogh, and Hiran Selvadurai

Respiratory Complications of Maxillofacial and Otolaryngologic Disorders 79
R. Paul Boesch

Pulmonary Complications of Chest Wall Disorders 107
Oscar Henry Mayer

Pulmonary Complications of Neuromuscular and Other Genetic Disorders 127
Alessandro Amaddeo, Sonia Khirani, and Brigitte Fauroux

Pulmonary Complications of Obstetric and Gynecologic Conditions 139
Amisha Jain and Iman R. Sami-Zakhari

Disorders of Central Respiratory Control 163
Eliot S. Katz

Pulmonary Complications of Mental Health Problems 177
Chelsea Manchester, Adrynne Frazier, Caitlin Condit, and Daniel Lewin

Pulmonary Complications of Rheumatologic Disorders 191
Rosemary Megalaa, Anastassios C. Koumbourlis, and Iman R. Sami-Zakhari

Pulmonary Complications of Obesity 209
Prateek J. Shukla and Anastassios C. Koumbourlis

Pulmonary Complications of Heterotaxy Syndromes 219
Thomas G. Saba and Adam J. Shapiro

Pulmonary Complications of Drug Therapy 241
Dimos K. Gidaris, Kostas N. Priftis, and Michael B. Anthracopoulos

Pulmonary Complications of Radiation Therapy 263
Donna J. Lee, Daphna Gelblum, and Nancy Lee

Pulmonary Complications of Solid Organ Transplantation 281
Sylvia Szentpetery, Daniel J. Weiner, and Geoffrey Kurland

Index 297

Contributors

Alessandro Amaddeo, M.D. Pediatric Noninvasive Ventilation and Sleep Unit, Hôpital Necker Enfants-Malades, Paris, France

Paris Descartes Faculty, Paris, France

Research Unit Inserm U 955, Team 13, Créteil, France

Michael B. Anthracopoulos, M.D. Department of Pediatrics, Pulmonary Division, Medical School of the University of Patras, Rion, Greece

Elinor Charles, L.L.B., M.B.B.S. Division of Asthma, Allergy and Lung Biology, MRC and Asthma UK Centre in Allergic Mechanisms of Asthma, King's College London, London, UK

Caitlin Condit, M.A. Department of Psychology, George Washington University School of Medicine and Health Sciences, Washington, DC, USA

Brigitte Fauroux, M.D., Ph.D. Pediatric Noninvasive Ventilation and Sleep Unit, Hôpital Necker Enfants-Malades, Paris, France

Paris Descartes Faculty, Paris, France

Research Unit Inserm U 955, Team 13, Créteil, France

Adrynne Frazier, M.A. Department of Psychology, George Washington University, School of Medicine and Health Sciences, Washington, DC, USA

Daphna Gelblum, M.D. Department of Radiation Oncology, Memorial Sloan Kettering Cancer Center, West Harrison, NY, USA

Dimos K. Gidaris, M.R.C.P.C.H., M.R.C.P.E., Ph.D. University of Nicosia Medical School, Nicosia, Cyprus

Anne Greenough, M.D.(Cantab), M.B.B.S., D.C.H., F.R.C.P., F.R.C.P.C.H. Department of Women and Children's Health, School of Life Course Sciences, Faculty of Life Sciences and Medicine, King's College London, London, UK

Katie Hunt, M.R.C.P.C.H., M.A.(Cantab), M.B.B.S. Division of Asthma, Allergy and Lung Biology, MRC and Asthma UK Centre in Allergic Mechanisms of Asthma, King's College London, London, UK

Amisha Jain, M.D. Division of Pulmonary and Sleep Medicine, Children's National Health System, George Washington University, School of Medicine and Health Sciences, Washington, DC, USA

Geshani Jayasuriya, B.M.ed., F.R.A.C.P. Department of Respiratory Medicine, The Children's Hospital, Sydney, NSW, Australia

Discipline of Child and Adolescent Health, The University of Sydney, Camperdown, NSW, Australia

Eliot S. Katz, M.D. Division of Respiratory Diseases, Department of Medicine, Children's Hospital, Harvard Medical School, Boston, MA, USA

Steven J. Keogh, M.B.B.S.Hons., F.R.A.C.P. Discipline of Child and Adolescent Health, The University of Sydney, Camperdown, NSW, Australia

Department of Oncology, The Children's Hospital, Sydney, NSW, Australia

Sonia Khirani, Ph.D. Pediatric Noninvasive Ventilation and Sleep Unit, Hôpital Necker Enfants-Malades, Paris, France

ASV Santé, Gennevilliers, France

Anastassios C. Koumbourlis, M.D., M.P.H. Division of Pulmonary and Sleep Medicine, Children's National Medical Center, George Washington University, School of Medicine and Health Sciences, Washington, DC, USA

Geoffrey Kurland, M.D. Division of Pediatric Pulmonology, Children's Hospital of Pittsburgh, Pittsburgh, PA, USA

Donna J. Lee, M.D. Section of Pediatric Pulmonology, Joseph M. Sanzari Children's Hospital, Hackensack University Medical Center, Hackensack, NJ, USA

Nancy Lee, M.D. Department of Radiation Oncology, Memorial Sloan Kettering Cancer Center, New York, NY, USA

Daniel Lewin, Ph.D. Division of Pulmonary and Sleep Medicine, Children's National Health System, George Washington University, School of Medicine and Health Sciences, Washington, DC, USA

Beryl Lin The University of New South Wales, Sydney, NSW, Australia

Sonal Malhotra, M.D. Ann and Robert H. Lurie Children's Hospital of Chicago, Northwestern University Feinberg School of Medicine, Chicago, IL, USA

Chelsea Manchester, M.A. Division of Pulmonary and Sleep Medicine, Children's National Health System, George Washington University, School of Medicine and Health Sciences, Washington, DC, USA

Oscar Henry Mayer, M.D. Division of Pulmonary Medicine, Pulmonary Function Testing Laboratory, The Children's Hospital of Philadelphia, Perelman School of Medicine at the University of Pennsylvania, Philadelphia, PA, USA

Rosemary Megalaa, D.O. Division of Pulmonary and Sleep Medicine, Children's National Health System, School of Medicine and Health Sciences, George Washington University, Washington, DC, USA

Mary A. Nevin, M.D. Ann and Robert H. Lurie Children's Hospital of Chicago, Northwestern University Feinberg School of Medicine, Chicago, IL, USA

R. Paul Boesch, D.O., M.S., F.A.A.P. Mayo Clinic Children's Center, Rochester, MN, USA

Kostas N. Priftis, M.D. Allergy-Pneumonology Department, University of Athens, School of Medicine, Athens, Greece

Thomas G. Saba, M.D. Division of Pediatric Pulmonology, University of Michigan, Ann Arbor, MI, USA

Iman R. Sami-Zakhari, M.D., M.R.C.P. Division of Pulmonary and Sleep Medicine, Children's National Health System, School of Medicine and Health Sciences, George Washington University, Washington, DC, USA

Hiran Selvadurai, M.B.B.S., F.R.A.C.P., Ph.D. Department of Respiratory Medicine, The Children's Hospital, Sydney, NSW, Australia

Discipline of Child and Adolescent Health, The University of Sydney, Camperdown, NSW, Australia

Adam J. Shapiro, M.D. Pediatric Respiratory Medicine, Montréal Children's Hospital, McGill University Health Centre Research Institute, Montréal, QC, Canada

Prateek J. Shukla, M.D. Division of Pulmonary and Sleep Medicine, Children's National Health System, School of Medicine and Health Sciences, George Washington University, Washington, DC, USA

Sylvia Szentpetery, M.D. Division of Pediatric Pulmonology, Children's Hospital of Pittsburgh, Pittsburgh, PA, USA

Daniel J. Weiner, M.D. Division of Pediatric Pulmonology, Children's Hospital of Pittsburgh, Pittsburgh, PA, USA

Pulmonary Complications of Cardiovascular Disorders

Anastassios C. Koumbourlis

Abbreviations

Ao	Aorta
CT	Computed tomography
IVC	Inferior vena cava
LA	Left atrium
LCA	Left carotid artery
LMSB	Left main stem bronchus
LSA	Left subclavian artery
LV	Left ventricle
MEFVC	Maximal expiratory flow-volume curve
MPA	Main pulmonary artery
MRI	Magnetic resonance imaging
RA	Right atrium
RCA	Right carotid artery
RMSB	Right main stem bronchus
RPA	Right pulmonary artery
RSA	Right subclavian artery
RV	Right ventricle
SVC	Superior vena cava

A.C. Koumbourlis, M.D., M.P.H.
Division of Pulmonary and Sleep Medicine, Children's National Medical Center, George Washington University, School of Medicine and Health Sciences, Washington, DC, USA
e-mail: akoumbou@childrensnational.org

© Springer International Publishing AG 2018

A.C. Koumbourlis, M.A. Nevin (eds.), *Pulmonary Complications of Non-Pulmonary Pediatric Disorders*, Respiratory Medicine,
https://doi.org/10.1007/978-3-319-69620-1_1

Introduction

The pulmonary complications of the cardiovascular disorders can be categorized into two broad categories: (a) "anatomic," which are usually the result of external compression of the airways by one or more of the large thoracic vessels or by the heart itself (although the bronchioles can also be affected), and (b) "functional" in which the complications are caused by the malfunction of the heart (e.g., congestive heart failure and pulmonary edema).

Normal Anatomic Relationships

The heart is located in the lower mediastinum directly behind the sternum and below the bifurcation of the trachea (Fig. 1). It has a conical shape, with its apex pointing downward and to the left, whereas its base is pointing upward to the right. The heart is "engulfed" by the two lungs which have special grooves to accommodate it. The heart is indirectly connected to both lungs with the right and left branches of the pulmonary artery and the pulmonary veins that enter and exit the lungs in the hilum (Fig. 2a, b). The right atrium (RA) of the heart is located anteriorly to the bronchus intermedius. The left atrium (LA) is adjacent to the left main stem bronchus (LMSB), just before and slightly below the takeoff of the left upper lobe (LUL).

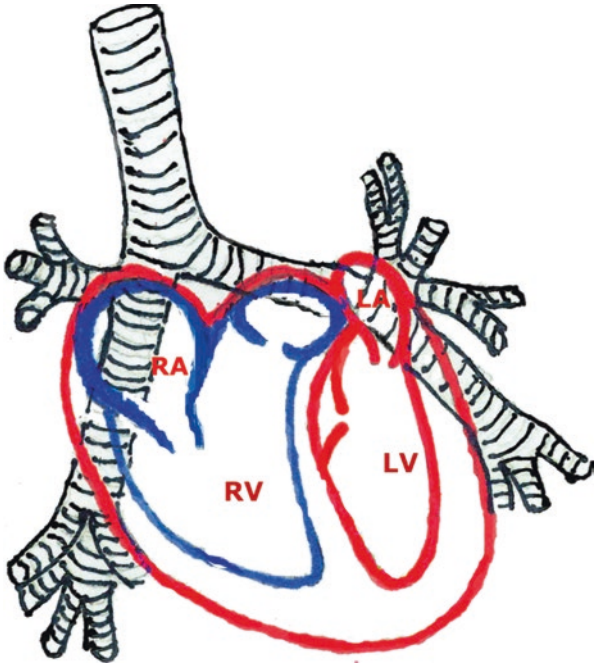

Fig. 1 Schematic representation of the location of the heart in relation to the tracheobronchial tree

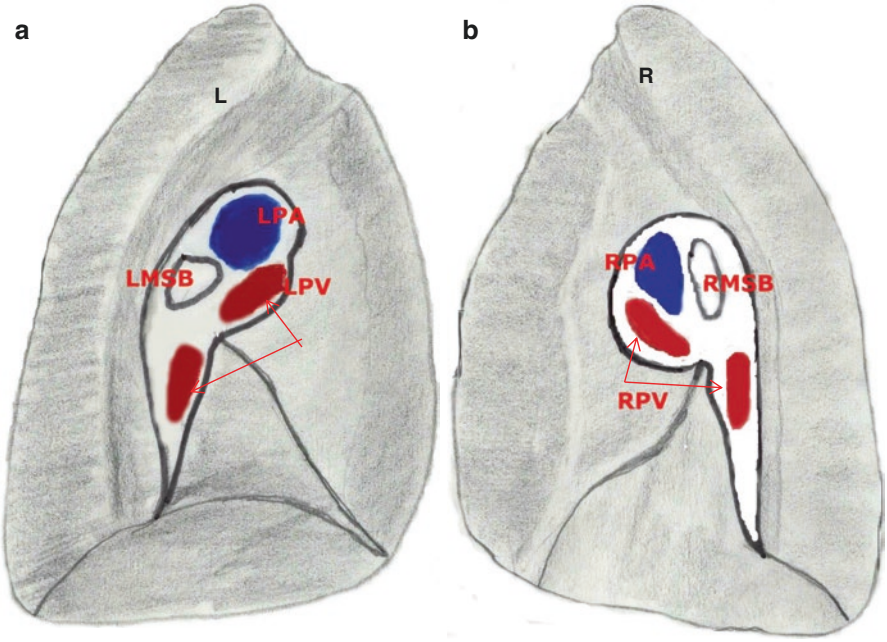

Fig. 2 Schematic representation of the left hilum (**a**) and right hilum (**b**)

Under normal circumstances there is negligible compression of the airways by the atria. In contrast with the heart, many of the big vessels are in very close proximity to the airways causing mild (not clinically significant) compression even under normal circumstances. Specifically:

– *Aorta* (Fig. 3): the *ascending aorta* originates anteriorly and to the right of the trachea. The *aortic arch* follows an oblique course toward the left anterior aspect of the lower trachea near the main carina, slightly compressing it to the right. It then rides over the LMSB and descends posteriorly (*descending aorta*) close to or in contact with the posterior wall of the LMSB. It continues to descend initially to the left and then behind the esophagus and in front of the vertebrae.
– *Brachiocephalic ("innominate") artery* (Fig. 3): it is the first vessel to arise from the aortic arch and transverses upward from left to right. It bifurcates into two branches (*right subclavian and right carotid arteries*). The right common carotid artery courses obliquely very close to the right anterior-lateral aspect of the cervical trachea at the base of the neck (mid-trachea).
– *Main pulmonary artery* (Fig. 4): it originates inferiorly in front of the carina and to the left of the ascending aorta. It branches into the right and left pulmonary arteries.
– *Left pulmonary artery* (Fig. 4): it originates beneath the aortic arch and separates it from the LMSB. It initially courses anterior to the LMSB, but before the takeoff of the LUL, it crosses over, it wraps around the LUL bronchus, and then

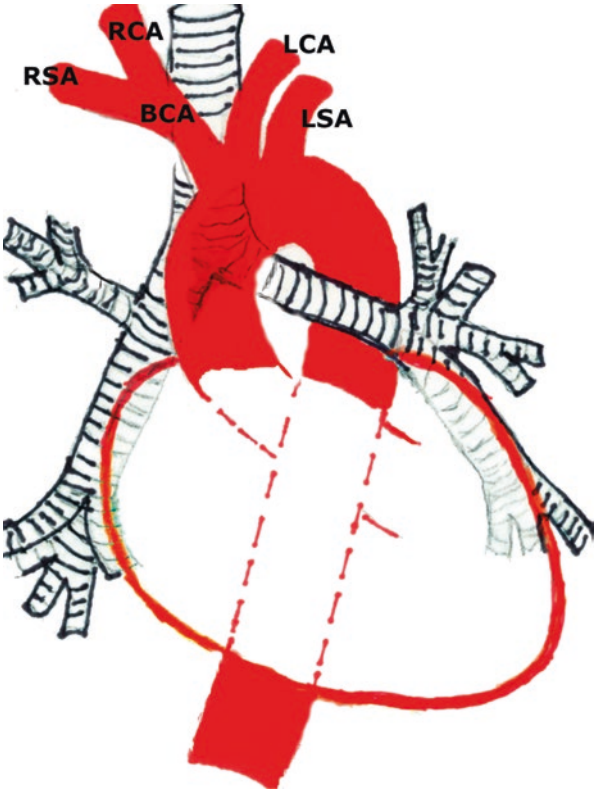

Fig. 3 Schematic representation of the course of the normal aorta and its main branches in relation to the tracheobronchial tree

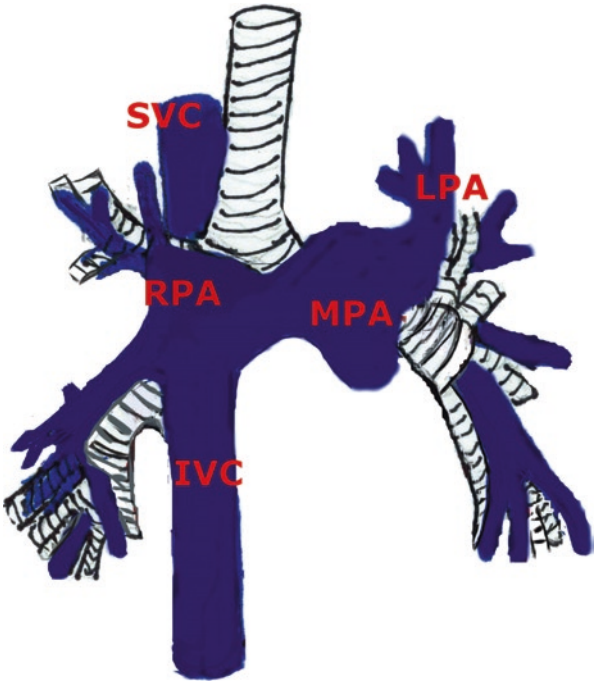

Fig. 4 Schematic representation of the course of the normal main pulmonary artery and its main branches as well as of the superior and inferior vena cava in relation to the tracheobronchial tree

it continues to run anteriorly of the LLL bronchi. In the left hilum, the left pulmonary artery is over the LMSB.

- *Right pulmonary artery* (Fig. 4): it courses almost horizontally in front of the carina, and it is in close contact with the RMSB at its takeoff from the trachea. Its branches remain in close contact with the right upper lobe as well as with the bronchus intermedius and the RML. In the right hilum, the pulmonary artery is directly anterior to the RMSB.
- *Superior vena cava and azygos vein* (Fig. 4): their juncture is in contact with the right anterior aspect of the main carina.
- *Inferior pulmonary veins*: they are located posterior to and are in close contact with the posteromedial aspect of the right and left lower bronchi.
- The *superior pulmonary veins* lie anterior to and inferior to the pulmonary arteries, and they are not in contact with the main stem bronchi.

Under normal circumstances, during bronchoscopy, pulsations and mild compression can be seen in various areas of the tracheobronchial tree, especially in the lower left anterolateral wall of the trachea, on the anterior and posterior wall of the left main stem bronchus, and on the medial segment of the right middle lobe (RML). Significant compression of the lungs causing atelectasis (usually of the left lower lobe) can occur in cases of significant cardiomegaly. Compression of various parts of the tracheobronchial tree occurs when there is enlargement of one or more of the big vessels (e.g., enlargement of the main pulmonary artery and its branches in cases of pulmonary hypertension) and/or in cases of abnormal origin or abnormal course of the vessels.

Abnormal Anatomic Relationships

Cardiomegaly

Most of the typical congenital heart diseases cause initially little or no compression of the lungs or of the airways. Their pulmonary complications tend to be gradual, related either to the development of pulmonary hypertension or of congestive heart failure with pulmonary edema. Notable exceptions are congenital cardiomegaly and Ebstein's anomaly. However, significant cardiomegaly can develop overtime as a result of a host of diverse causes (Table 1). In general, cardiomegaly can develop through one of the four mechanisms: (a) extra volume in one of the heart compartments (usually due to a left-to-right shunt and/or due to valvular malfunction) that allows the regurgitation of blood from the ventricles to the atria, (b) structural "obstruction" of the outflow (e.g., mitral, pulmonary, or aortic valve stenosis), (c) increased afterload that prevents the emptying of the ventricles (e.g., systemic or pulmonary hypertension), and (d) "weakness" of the cardiac muscle itself (e.g., cardiomyopathy) that prevents adequate emptying during systole. These mechanisms may cause enlargement of one or of all the chambers of the heart. Depending on which of the chambers enlarges, the effects will differ. Enlargement of the atria

Table 1 Conditions causing cardiomegaly

Enlargement of the entire heart	
Primary mechanism: conditions affecting the cardiac muscle	• Congenital cardiomegaly • Idiopathic cardiomyopathy • Dilated cardiomyopathy • Hypertrophic cardiomyopathy
Enlargement of the right side of the heart	
Primary mechanisms: 1. Increase in the blood volume in the right atrium and/or ventricle	• Atrial septal defect (ASD) • Ventricular septal defect (VSD) • Tricuspid regurgitation • Anomalous pulmonary venous return • Tetralogy of Fallot *Systemic noncardiac conditions* – Athletic heart – Pregnancy – Renal failure – Anemia – Scleroderma – Systemic lupus erythematosus – Rheumatoid arthritis
2. Right-sided outflow obstruction	• Tricuspid stenosis • Pulmonary valve stenosis • Cor pulmonale • Pulmonary arterial hypertension
Enlargement of the left side of the heart	
Primary mechanisms: 1. Increase in the blood volume in the left atrium and/or ventricle	• Mitral regurgitation • Aortic regurgitation
2. Left-sided outflow obstruction	• Mitral stenosis • Aortic stenosis • Hypertension

is much more likely to cause compression of the main stem bronchi. Enlargement of the left atrium may actually push the left main stem upward in a more horizontal position. In contrast, enlargement of the ventricles tends to compress the lungs causing atelectasis.

Congenital Vascular Abnormalities: "Rings, Slings, and Other Things"

Various congenital vascular abnormalities do cause direct compression of the trachea and/or of the bronchi. The vast majority of these abnormalities consist of an abnormal aortic arch, in combination with a left (or less commonly a right) ligamentum arteriosum and/or an aberrant subclavian artery, which create a "ring" formation around the trachea. The most common of the aortic arch abnormalities are the double aortic arch and the right aortic arch. The ligamentum arteriosum is the remnant of the ductus arteriosus that normally disappears during the first 2–3 weeks of

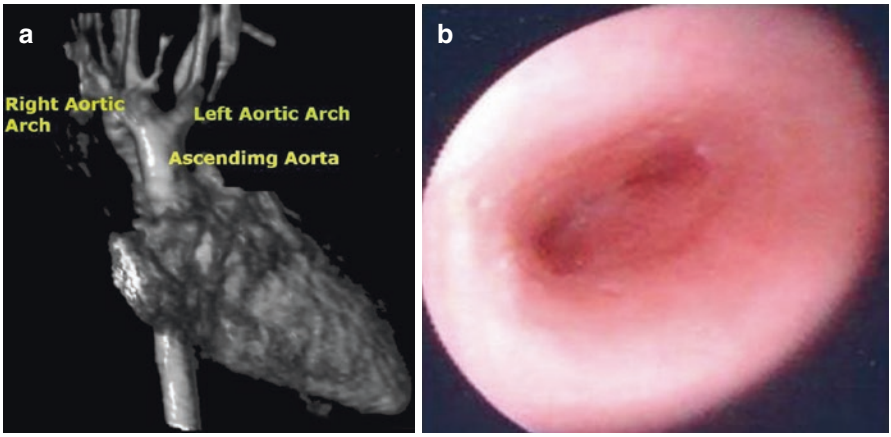

Fig. 5 3-D reconstruction from a cardiac MRI showing the double aortic arch (**a**); severe compression of the lower trachea due to a complete vascular ring (**b**)

life. When it fails to involute, it becomes a small ligament that connects the right aortic arch (or of one of its branches) to the left pulmonary artery.

Double Aortic Arch (Fig. 5)

- *Frequency*: one of the two most common vascular abnormalities.
- *Components*: it is caused by the failure of the fourth right arch to involute. As a result there are two arches (left and right) that are both connected to the descending aorta.
- *Special features*: it encircles the trachea and the esophagus; in 30% of the cases, the smaller arch is atretic; it is usually not associated with intracardiac defects.
- *Clinical features*: it usually causes symptoms (harsh inspiratory and expiratory "wheezy" sound) early in life (even at birth) that tend to become worse after the first few weeks as the infant becomes more acting. However, if it is not very tight, it can remain undiagnosed for years and may manifest itself later in life as "exercise intolerance."

Right Aortic Arch

- *Frequency*: rare in the general population but common among patients with other intracardiac anomalies (especially patients with tetralogy of Fallot).
- *Components*: a "ring" is being formed by the aortic arch that is located on the right side of the trachea, the ascending aorta anteriorly, the descending aorta posteriorly, and the ligamentum arteriosum and left pulmonary artery on the left.
- *Special features*: the ring encircled the trachea and the esophagus; it is associated with intracardiac defects in 10% of the cases.
- *Clinical features*: it causes symptoms early in life.

Right Aortic Arch with Aberrant Left Subclavian Artery and Left Ligamentum Arteriosum

- *Frequency*: rare in the general population.
- *Components*: in this formation the right arch gives off both the left and the right carotid arteries and the right and left subclavian arteries. The "ring" is formed by the right arch to the right, the left carotid artery that travels across the anterior wall of the trachea, and the left subclavian artery that courses from right to left, and it is completed by the left ligamentum arteriosum that connects the left subclavian with the left pulmonary artery.
- *Special features*: the ring encircled the trachea and the esophagus; it is associated with intracardiac defects in 10% of the cases.
- *Clinical features*: it causes symptoms early in life.

Right Aortic Arch with Mirror-Image Branching and Retroesophageal Ligamentum Arteriosum

- *Frequency*: rare in the general population.
- *Formation of the ring*: the left innominate artery is the first branch of the right arch, and it then branches into the left carotid and left subclavian arteries, both of whom are branches of the left innominate artery and course over the anterior tracheal wall. The right carotid artery is the second branch of the aortic arch followed by the right subclavian artery and finally the ligamentum arteriosum that originates from the Kommerell diverticulum that is the remnant of the left fourth arch, and it is located at the point where the right arch merges with the descending thoracic aorta. The ligamentum crosses to the left behind the esophagus and then travels anteriorly where it completes the ring when it joins the left pulmonary artery. Often the ligamentum originates from the left innominate artery of left subclavian artery, so it does not form a complete ring.
- *Special features*: this type of anomaly is associated with intracardiac defects in up to 90% of the cases.

Left Aortic Arch with Right Descending Aorta and Right Ligamentum Arteriosum

- *Frequency*: extremely rare.
- *Formation of the "ring"*: in this variant the first branch of the left aortic arch is the right common carotid artery that crosses to the right over the anterior tracheal wall. The next vessel is the left carotid, followed by the left subclavian artery. The right subclavian artery is branching off the proximal right-sided descending aorta. The ligamentum arteriosum branches off the base of the right subclavian (or from a nearby diverticulum) and connects it to the right pulmonary artery.

Left Aortic Arch, Right Descending Aorta, and Atretic Right Aortic Arch

- *Frequency*: very rare.
- *Formation of the "ring"*: the brachiocephalic vessels are branching normally of the left aortic arch. However, the arch travels behind the esophagus and joins the descending aorta that is right sided. The "ring" is completed by an atretic right arch.

Tracheal Compression by Vascular Structures but Without Formation of a Complete Ring

Anomalous Brachiocephalic (Innominate) Artery (Fig. 6)

- *Frequency*: it is the most common type of tracheal compression.
- *Anatomy*: the innominate artery originates from the brachiocephalic artery that originates in the left aortic arch and crosses normally over the anterior wall of the trachea from left to right. In certain cases it is originating more distally, and thus it crosses much closer to the tracheal wall than usual.
- *Special features*: tracheal compression by the innominate artery is very easily recognizable during bronchoscopy because it causes a characteristic compression of the right anterior-lateral tracheal wall. It is more difficult to diagnose radiographically or angiographically because the course of the artery is normal.

Retroesophageal Right Subclavian Artery with Left Aortic arch and Left Ligamentum Arteriosum

- *Frequency*: very common, occurring in approximately 0.5% of the general population.
- *Anatomical features*: in this variant the right subclavian artery originates from the descending aorta and courses posterior to the esophagus. The left ligamentum arteriosus originates from the aortic arch and connects to the left pulmonary artery.

Fig. 6 Bronchoscopic picture showing external compression of the anterior right wall of the mid-trachea by the innominate artery

- *Special features*: this variant does not usually cause respiratory or other symptoms. However, depending on the degree of compression of the esophagus, it may cause symptoms of dysphagia.

Left Pulmonary Artery Sling (Fig. 7)

- *Frequency*: It is estimated to account for approximately 10% of the non-aortic arch-related vascular compressions.
- *Anatomical features*: in this pathologic variant, the left pulmonary artery originates from the right pulmonary artery and crosses over the right main stem bronchus and circles the trachea at its bifurcation and then crosses to the left in between the trachea and the esophagus.
- *Special features*: it causes a characteristic indentation of the right lower wall just above the bifurcation that is visible both bronchoscopically and radiographically. Pulmonary artery slings are often associated with tetralogy of Fallot as well as with tracheal stenosis with complete tracheal rings. In such cases the trachea and the main stem bronchi have a characteristic appearance of an inverted capital "T" due to the virtually horizontal position of the main stem bronchi.

Scimitar Syndrome (Pulmonary Venolobar Syndrome) (Fig. 8)

- *Frequency*: rare.
- *Anatomical features*: partial anomalous pulmonary venous return from the right lung to the inferior vena cava (usually near its junction with the right atrium).
- *Special features*: the anomalous pulmonary vein has a curved appearance that resembles the curved sword known as "scimitar." The syndrome is associated with right lung hypoplasia (including a hypoplastic right pulmonary artery) that displaces the heart to the right hemithorax.

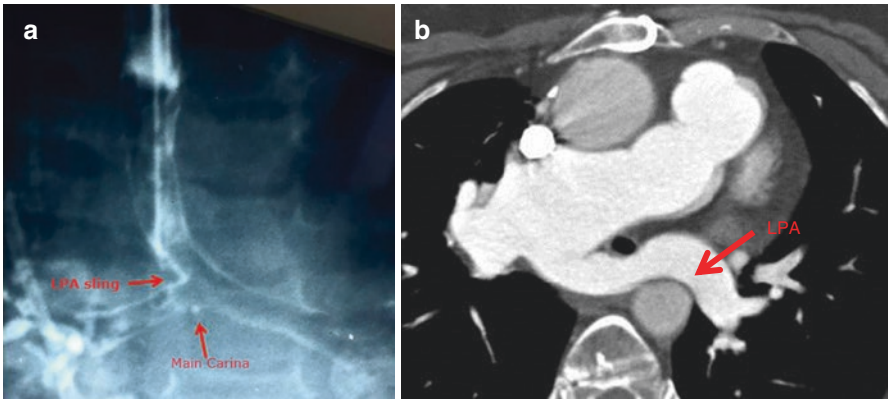

Fig. 7 (**a**) Bronchographic image showing the indentation of the right tracheal wall just above the carina caused by a left pulmonary artery sling. Note the almost horizontal position of the two main stem bronchi that give the appearance of an inverted capital T; (**b**) CT scan showing left pulmonary artery sling compressing the trachea and the esophagus

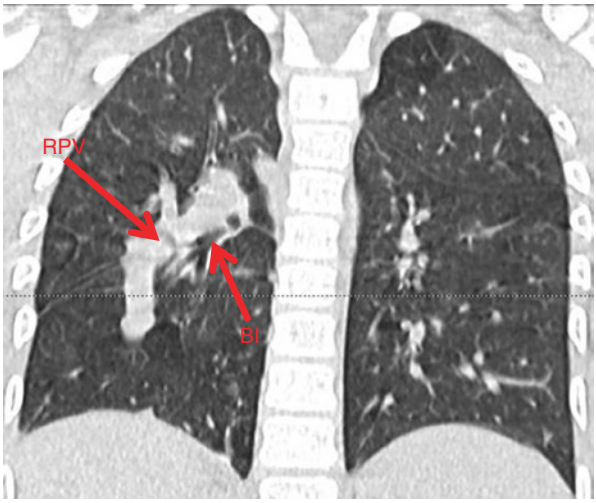

Fig. 8 Chest CT showing a curved density resembling a "scimitar" sword, formed by the abnormal course of the right pulmonary vein

Clinical Presentation of Tracheobronchial Compression by Vascular Structures

Onset of symptoms: it is variable. Severe compression will produce symptoms shortly after birth, whereas mild compression may remain asymptomatic (and undiagnosed) for years. Tracheal stenosis with complete tracheal rings (usually associated with pulmonary artery sling) tends to get progressively worse as the infant grows because the tracheal diameter does not increase despite the growth of the rest of the body. A common feature among virtually all vascular abnormalities is that they impair the clearance of secretions from the compressed airways (especially when it is associated with tracheomalacia). The retention of secretions promotes the colonization of the airways usually with bacterial organisms, and the patients often have manifestations of chronic bronchitis and/or recurrent pneumonias.

Clinical Features

Chest wall retractions: suprasternal chest wall retractions tend to be a standard feature of extrathoracic and large intrathoracic obstruction even in the absence of respiratory distress. However, they can be easily missed in young infants because their chin tends to cover the suprasternal notch. When the obstruction is significant, the patients have substernal and intercostal retractions.

Cough: because compression of the trachea usually produces a certain degree of tracheomalacia, affected patients develop a very characteristic dry cough with a "honking" quality ("goose honking"). When there are secretions, the cough is congested, hacking often described by the parents as "smokers' cough."

Breath sounds: affected patients tend to produce audible sounds that are biphasic which are often (mis)labeled as stridor or wheezing. The inspiratory sounds are not usually as high pitched as the inspiratory stridor produced by laryngomalacia, whereas the expiratory sounds are much harsher than the expiratory wheezing produced by obstruction of the small airways (e.g., bronchiolitis). The sounds can vary depending on the respiratory effort of the patient and also by the presence of secretions in the tracheobronchial tree.

Response to bronchodilators: because the airway obstruction is "mechanical" in nature due to the external compression, the patients' symptoms do not improve after administration of bronchodilator, and on occasion they can get worse, presumably due to overrelaxation of the airway smooth muscle. On the other hand, it is not unusual for infants/children to have also airway hyperreactivity.

Feeding and growth: affected infants tend to have failure to thrive that is caused by a combination of poor feeding due to increased work of breathing, dysphagia, compression of the esophagus by the abnormal vessel, and increased metabolic demands due to the increased work of breathing. The feeding pattern and the growth are further affected when the vascular anomaly is associated with an intracardiac problem (e.g., tetralogy of Fallot) that may lead to congestive heart failure.

Diagnosis

Radiographic studies: Airway compression by a vascular structure is not easy to detect on a plain radiograph. The presence of a right aortic arch always warrants further investigation. Other clues include unusual deviation of the trachea and unusual widening (or narrowing) of the transverse diameter of the trachea or of the main stem bronchi. However, because a plain radiograph is not aimed at the airways but on the lung parenchyma, such "abnormalities" should not be considered pathognomonic, because they can be the result of the way the radiograph was taken. In general the documentation of airway compression by a vascular structure requires either a CT or an MRI with contrast. However, sometimes even these detailed studies may not be conclusive. For example, in cases of tracheal compression by the innominate artery, the compression is not due to abnormal course of the vessel but due to its proximity to the tracheal wall. Considering that the tracheal lumen changes in diameter physiologically between inspiration and expiration and that the degree of compression by the vessel is different between systole and diastole, it is possible that the airway lumen may look "normal" or at least not significantly narrowed in a CT or MRI image simply because the image was taken at the moment the lumen was open. On the other hand, in the absence of other abnormalities, the detection of a single aberrant vessel (such as the left or right subclavian arteries) does not automatically imply that there is airway compression.

An esophagogram can be very useful and virtually diagnostic when the tracheal compression is accompanied by compression of the esophagus (Fig. 9). Posterior compression of the esophagus is usually caused by an aberrant subclavian artery, whereas anterior compression is caused by the left pulmonary artery that loops around the trachea and then courses in between the trachea and the esophagus.

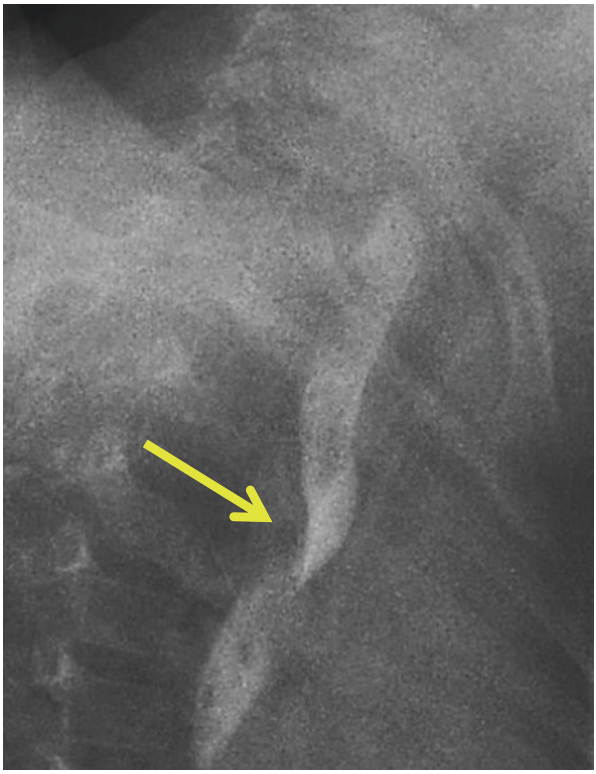

Fig. 9 Esophagogram showing posterior compression of the esophagus by an aberrant vessel

Pulmonary function testing: Spirometry and maximal flow-volume curves can be very useful in the detection of airway compression by vascular structures. Compression of the trachea is likely to produce variable intrathoracic obstruction with flattening of the proximal portion of the descending limb of the flow-volume curve (Fig. 10a). Compression of the main stem bronchus is more likely to produce flattening of the midportion of the expiratory flow-volume curve (Fig. 10b). The presence of pulmonary edema is more likely to cause a picture of a restrictive lung defect. Engorgement of the small pulmonary vessels can cause compression of the neighboring bronchioles and a picture of peripheral airway obstruction in pulmonary function testing.

Functional Cardiac Abnormalities

Heart Failure and Pulmonary Edema

Heart failure is broadly defined as the state in which the cardiac output is insufficient to meet the metabolic demands of the body. Heart failure can be the result of right or left heart failure or both. Its causes vary, especially between adults and children (in the former it is usually the result of myocardial ischemic events and/or valvular

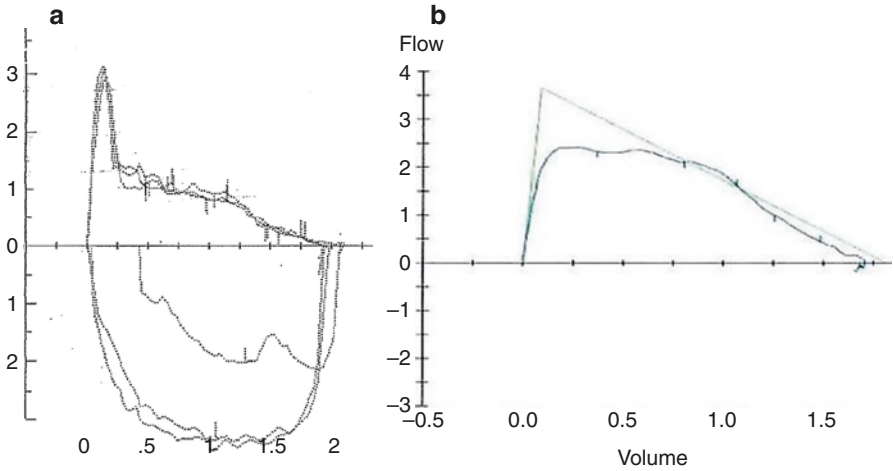

Fig. 10 (**a**) MEFVC showing proximal flattening of the descending expiratory limb due to compression of the mid-trachea; (**b**) MEFVC showing flattening of the middle section of the descending expiratory limb due to external compression of the lower trachea and left main stem bronchus

disease, whereas in infants and children, it is mostly the result of congenital cardiac abnormalities). The detailed presentation of the causes of heart failure is beyond the scope of this chapter, but they can be categorized in the following four categories: (a) conditions causing excessive preload (e.g., left-to-right shunts at the ventricular level such as ventricular septal defects), (b) excessive afterload (e.g., coarctation of the aorta), (c) conditions of decreased contractility (e.g., cardiomyopathy), and (d) cardiac dysrhythmias (e.g., atrial fibrillation).

The end point of the left heart failure is the development of pulmonary edema. The cardiogenic pulmonary edema is caused by increased capillary hydrostatic pressure secondary to elevated pulmonary venous pressure, and it is produced by accumulation of fluid with low protein content in the lung interstitium and alveoli. Increased hydrostatic pressure leading to pulmonary edema in children usually results from conditions such as aortic stenosis or coarctation of the aorta, as well as left ventricular failure due to systolic or diastolic ventricular dysfunction. It can also be caused by excessive intravascular volume. Right heart failure tends to cause peripheral edema. However, infants and children with congenital heart disease involving large left-to-right shunts are at increased risk for congestive heart failure due to increased intravascular volume in the pulmonary circulation. The presence of edema fluid reduces the lung volume (thus limiting the gas exchange surface area). The lungs become much less compliant ("stiff lung"), and the airway resistance increases, thus making the work of breathing harder.

Acute severe pulmonary edema is a true medical emergency that requires immediate attention and treatment that usually requires endotracheal intubation and positive pressure ventilation, inotropic support for the heart, and intense diuresis. The presence of mild pulmonary edema can be more challenging to diagnose because its

signs and symptoms (dyspnea especially on exertion, wheezing, and/or crackles) are identical to the symptoms of many pulmonary diseases as well.

"Cardiac asthma": the presence of dyspnea with wheezing on recumbent position and/or on exertion is a well-known feature of left-sided heart failure, and it has been termed "cardiac asthma." Its exact pathophysiology remains unclear, and several mechanisms have been proposed including the following: (a) increase in the airway resistance due to the elevation in the hydrostatic pressure, (b) increase in the airway resistance due to the decrease in lung volume that changes the geometric size of the bronchioles, and (c) compression of the bronchioles by engorged peribronchial vessels. The differentiation of cardiac asthma from the typical asthma may be difficult by auscultation alone especially since the two conditions are not mutually exclusive. One differentiating factor is their response to bronchodilator. Cardiac asthma is much less likely to respond to bronchodilators, but it may improve with diuretics.

Pulmonary hemorrhage/hemoptysis: spontaneous pulmonary hemorrhage/hemoptysis can be caused due to the presence and engorgement of major aortopulmonary collateral arteries (MAPCAs). These collateral vessels develop normally in the early embryonic life but regress when the actual pulmonary arteries develop. However, they persist and grow when there is no perfusion of the lungs by the pulmonary artery (e.g., pulmonary artery agenesis or atresia). In such cases the perfusion of the lungs is maintained by the MAPCAs that receive blood from the aorta. In rare cases MAPCAs can exist in patients without congenital heart disease. Aortopulmonary collaterals in the presence of otherwise adequate perfusion of the lungs can lead to the development of congestive heart failure and/or pulmonary hypertension due to over-circulation of blood in the lungs. Pulmonary hemorrhage due to MAPCAs has been described in patients who underwent repair for tetralogy of Fallot with pulmonary atresia, after Fontan operation, and after arterial switch for transposition of the great arteries. The bleeding can be mild or severe life-threatening, and it can present shortly after the repair (especially after arterial switch) or many years postoperatively.

Iatrogenic Complications

Cardiac surgery for the repair of congenital heart defects has the potential for a number of perioperative complications that directly or indirectly affect the lungs.

Reperfusion injury: Cardiopulmonary bypass (CPB) is necessary for all the open heart surgeries. During CPB the lungs are excluded from the circulation, and they are receiving blood only from the bronchial circulation that although it increases several fold, it can meet only part of their metabolic needs. The limited ventilation during CPB also causes significant atelectasis that may persist for hours after the CPB ends, thus causing significant hypoxemia requiring potentially harmful concentrations of oxygen and positive airway pressures. Transfusions of blood products together with the ischemia of the lungs promote the release of multiple inflammatory mediators that may cause acute lung injury and eventually acute respiratory

distress syndrome (ARDS). The latter is characterized by influx of inflammatory mediators, increased microvascular permeability, increased pulmonary vascular resistance, development of pulmonary edema, and significant hypoxemia.

Diaphragmatic paresis/paralysis: Unilateral (and less commonly bilateral) paralysis of the hemidiaphragm due to injury of the phrenic nerve is a well-known complication of cardiac surgery (both open and closed) with an incidence estimated to be as low as 0.3% to as high as 12%. The diagnosis is usually made after a patient "fails" weaning off the ventilator without any obvious reason. The condition can be easily missed when the patient is intubated and ventilated because the positive pressure from the ventilator makes the paralyzed diaphragm descend. The diagnosis can be easily made by fluoroscopy or ultrasound, but the patient has to be breathing spontaneously ideally without any positive pressure. If the phrenic nerve is not completely severed, the diaphragmatic paralysis is often reversible (paresis), but it may take up to 6–8 months for its recovery. Surgical plication can be useful especially in the short run. However, because of the possibility of spontaneous recovery, it is reserved for patients with persistent respiratory failure that is directly attributable to the paralyzed diaphragm.

Vocal cord paralysis: The recurrent laryngeal nerve is in close proximity to several vascular structures such as the aorta, the ligamentum arteriosum, and the right subclavian artery. Thus, it is prone to injury during certain surgical procedures such as the Blalock–Taussig shunt, ligation of a patent ductus arteriosum, or manipulation of the aortic arch. Vocal cord paralysis tends to be much more common on the left than on the right, and it may spontaneously recover. Its symptoms largely depend on the position of the paralyzed cord. Bilateral vocal cord paralysis at midline would require an emergency tracheostomy, whereas paralysis in abduction would probably affect the swallowing causing chronic choking and aspiration. Vocal cord paralysis should be suspected if the patient has persistent voice changes and recurrent choking or unexplained pneumonias after cardiac surgery.

Pleural effusions: Pleural effusions are very common after cardiac surgery, and most of them tend to be rather small and nonspecific. They tend to occur mostly on the left hemithorax. Their etiology is probably multifactorial involving multiple mechanisms including the following:

- Ice cooling and ice cardioplegia that injure the pericardial and pleural membranes
- Damage of mediastinal lymphatic channels
- Significant changes in the hydrostatic pressures due to fluid shifts during the perioperative period
- Pleural inflammation (based on the elevated pleural fluid protein as well as on the presence of other inflammatory mediators)
- Left heart failure (it typically causes transudates as opposed to the previous causes that tend to cause exudates)

The early effusions (within the first few postoperative days) tend to be benign, are not associated with other symptoms, and do not usually require any special care. Late development of effusions (>3 weeks postoperatively) suggests a more serious complication especially if it is accompanied by fever, increased ESR, leukocytosis, and pulmonary infiltrates. The two leading conditions that can present like this are the postpericardiotomy syndrome and pneumonia.

Chylothorax: Chylothorax is a rare complication of thoracic surgery. Its incidence has been reported to be between 0.6 and 2% among infants and children undergoing cardiac surgery, and although it could theoretically complicate any surgery, it is much more common among patients with tetralogy of Fallot and those who undergo the Fontan procedure. It is diagnosed on the basis of the milky appearance of the pleural fluid, and its analysis shows a triglyceride level of >1.2 mmol/L and a total cell count of >1000 μL with predominance of lymphocytes. Its exact causes are not known. Although it will certainly occur when there is trauma of the thoracic duct, in most cases no specific injury can be identified. It is possible that the injury is in the very small lymphatic vessels that are located around the ascending aorta, the pulmonary artery, and the superior vena cava. Another possibility is that the chylothorax is caused by obstruction (or increased pressure) in the SVC that would explain its relatively high incidence in patients undergoing Fontan procedure. Chylothorax carries higher morbidity than a pleural effusion of the same size because the chyle is very rich in proteins, lipids, and immunoglobulins.

Plastic bronchitis: Plastic bronchitis is a rare complication that occurs usually in patients undergoing the Fontan procedure. It consists of the formation of gelatinous or rubbery casts of the bronchial tree that can be often expectorated. Depending on their size and location, the casts can cause a variety of symptoms ranging from cough, wheezing, and difficulty in breathing to asphyxia and death. The diagnosis should be suspected in patients who belong to the high-risk groups and develop progressive respiratory symptoms that cannot be explained any other way. If the patient cannot expectorate the casts, bronchoscopy should be considered both for diagnostic and therapeutic purposes.

Compression of the airways: Many of the operations for the palliation and/or repair of various congenital heart defects involve the manipulation of the great arteries (e.g., transposition of the great arteries), of the aortic arch (e.g., interrupted aortic arch or coarctation of the aorta), and/or of the major veins (e.g., Fontan procedure). The repairs change the normal anatomic relations between the vessels and the tracheobronchial tree and may result in postoperative compression of the airways. Similar problems can occur after placement of vascular stents. The compression of the airways can produce symptoms that may range from mild "wheezing" to complete obstruction of the main stem bronchus and severe respiratory distress. The compression of the airway can lead to atelectasis or to hyperinflation of the left lung that can be mistaken as congenital lobar emphysema (Fig. 11).

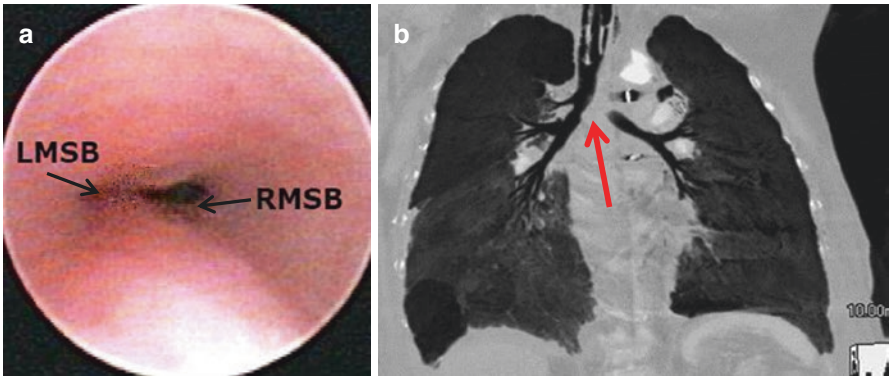

Fig. 11 Bronchoscopic picture showing the compression of the LMSB (**a**); CT scan showing compression of the left tracheal wall and complete collapse of the proximal LMSB (**b**)

Bibliography

1. Grey's Anatomy. Human body > XI. Splachnology > The lungs. http://www.theodora.com/anatomy/the_lungs.html
2. Minnich DJ, Mathisen DJ. Anatomy of the trachea, carina, and bronchi. Thorac Surg Clin. 2007;17(4):571–85.
3. Madriago E, Silberbach M. Heart failure in infants and children. Pediatr Rev. 2010;31(1):4–12.
4. Frydrychowicz A, Landgraf B, Wieben O, François CJ. Images in cardiovascular medicine. Scimitar syndrome: added value by isotropic flow-sensitive four-dimensional magnetic resonance imaging with PC-VIPR (phase-contrast vastly undersampled isotropic projection reconstruction). Circulation. 2010;121(23):e434–6.
5. Drevet G, Conti M, Deslauriers J. Surgical anatomy of the tracheobronchial tree. J Thorac Dis. 2016;8(Suppl 2):S121–9.
6. Hanneman K, Newman B, Chan F. Congenital variants and anomalies of the aortic arch. Radiographics. 2017;37(1):32–51.
7. Dakkak W, Tonelli AR. Compression of adjacent anatomical structures by pulmonary artery dilation. Postgrad Med. 2016;128(5):451–9.
8. Lai SH, Liao SL, Wong KS. Cardiovascular-associated tracheobronchial obstruction in children. Cardiol Young. 2013;23(2):233–8.
9. Backer CL, Mongé MC, Popescu AR, Eltayeb OM, Rastatter JC, Rigsby CK. Vascular rings. Semin Pediatr Surg. 2016;25(3):165–75.
10. Buckner K. Cardiac asthma. Immunol Allergy Clin N Am. 2013;33(1):35–44.
11. Maskatia SA, Feinstein JA, Newman B, Hanley FL, Roth SJ. Pulmonary reperfusion injury after the unifocalization procedure for tetralogy of Fallot, pulmonary atresia, and major aortopulmonary collateral arteries. J Thorac Cardiovasc Surg. 2012;144(1):184–9.
12. Kaneko Y, Yoda H, Tsuchiya K. Airway compression by major aortopulmonary collaterals with 22q11 deletion. Asian Cardiovasc Thorac Ann. 2007;15(1):e9–11.
13. Perri G, Albanese SB, Carotti A. Airway complications after single-stage unifocalization for pulmonary atresia, ventricular septal defect, and major aortopulmonary collateral arteries. J Card Surg. 2015;30(5):453–8.
14. Asija R, Koth AM, Velasquez N, Chan FP, Perry SB, Hanley FL, et al. Postoperative outcomes of children with tetralogy of Fallot, pulmonary atresia, and major aortopulmonary collaterals undergoing reconstruction of occluded pulmonary artery branches. Ann Thorac Surg. 2016;101(6):2329–34.

15. Sugimoto A, Ota N, Sakamoto K. Pulmonary haemorrhage due to an aortopulmonary collateral artery after arterial switch. Cardiol Young. 2016;26(3):579–8.
16. Zaidi SJ, Javois AJ, Akhter J. Hemoptysis from an aorto-pulmonary collateral vessel in a four month old resolved by embolization. Pediatr Pulmonol. 2016;51(9):E31–3.
17. Yuan SM. Postperfusion lung syndrome and related sequelae. J Thorac Dis. 2016;8(5):E340–4.
18. Biewer ES, Zürn C, Arnold R, Glöckler M, Schulte-Mönting J, Schlensak C, et al. Chylothorax after surgery on congenital heart disease in newborns and infants -risk factors and efficacy of MCT-diet. J Cardiothorac Surg. 2010;5:127.
19. ML C, Morris NR, Hulsebus ML, Olson TP, Lalande S, Johnson BD. Influence of bronchial blood flow and conductance on pulmonary function in stable systolic heart failure. Respir Physiol Neurobiol. 2011;177(3):256–64.
20. Joho-Arreola AL, Bauersfeld U, Stauffer UG, Baenziger O, Bernet V. Incidence and treatment of diaphragmatic paralysis after cardiac surgery in children. Eur J Cardiothorac Surg. 2005;27(1):53–7.
21. Milonakis M, Chatzis AC, Giannopoulos NM, Contrafouris C, Bobos D, Kirvassilis GV, et al. Etiology and management of chylothorax following pediatric heart surgery. J Card Surg. 2009;24(4):369–73.
22. Nichols BG, Jabbour J, Hehir DA, Ghanayem NS, Beste D, Martin T, et al. Recovery of vocal fold immobility following isolated patent ductus arteriosus ligation. Int J Pediatr Otorhinolaryngol. 2014;78(8):1316–9.
23. Truong MT, Messner AH, Kerschner JE, Scholes M, Wong-Dominguez J, Milczuk HA, et al. Pediatric vocal fold paralysis after cardiac surgery: rate of recovery and sequelae. Otolaryngol Head Neck Surg. 2007;137(5):780–4.
24. Avitabile CM, Goldberg DJ, Dodds K, Dori Y, Ravishankar C, Rychik J. A multifaceted approach to the management of plastic bronchitis after cavopulmonary palliation. Ann Thorac Surg. 2014;98(2):634–40.
25. Yuan SM, Jing H. Palliative procedures for congenital heart defects. Arch Cardiovasc Dis. 2009;102(6–7):549–57.

Respiratory Complications of the Gastrointestinal System

Sonal Malhotra and Mary A. Nevin

Introduction

Gastrointestinal disease may manifest as respiratory symptoms through a number and variety of pathophysiologic mechanisms. For this discussion, the physiologic basis of shared gastrointestinal and pulmonary disease manifestations will broadly be considered in three categories; these include inflammatory change, anatomic abnormalities, and vascular shunting with related hypoxemia. First, inflammatory changes may occur in the airway as a result of aspiration secondary to dysphagia or gastroesophageal reflux. Inflammatory derangements may also be implicated in parenchymal pulmonary derangements from more remote intra-abdominal processes such as pancreatitis. In the setting of pancreatitis, the inflammatory response may be diffuse and overwhelming with associated changes in vascular permeability due to cytokine release. Specific eosinophilic inflammation has been increasingly recognized for its shared pulmonary and gastrointestinal symptomatology in the setting of eosinophilic esophagitis. Second, anatomic anomalies such as tracheomalacia or vocal cord paralysis may be encountered in association with gastrointestinal anomalies such as esophageal atresia with or without tracheoesophageal fistula. Direct anatomic compression of the airway may also occur in the setting of esophageal foreign body or with achalasia cardia. Lastly, hypoxemia and related dyspnea may occur in patients with late-stage hepatic disease or in those with rare intrahepatic shunting lesions such as the Abernethy malformation.

In this chapter, the pulmonary complications and symptoms associated with primary gastrointestinal disease will be discussed, and the physiologic basis for these associations will be reviewed.

S. Malhotra, M.D. • M.A. Nevin, M.D. (✉)
Ann and Robert H. Lurie Children's Hospital of Chicago, Northwestern University Feinberg School of Medicine, Chicago, IL, USA
e-mail: MNevin@luriechildrens.org

© Springer International Publishing AG 2018

A.C. Koumbourlis, M.A. Nevin (eds.), *Pulmonary Complications of Non-Pulmonary Pediatric Disorders*, Respiratory Medicine,
https://doi.org/10.1007/978-3-319-69620-1_2

Inflammatory Changes

Dysphagia and Aspiration

Direct insult to the airway and inflammatory change may occur as a result of a dysfunctional swallow mechanism (dysphagia) with aspiration of oral secretions or a food bolus into the airway; gastric contents and secretions can also be aspirated when gastroesophageal reflux events occur to the level of the thoracic inlet [1]. Associated respiratory symptoms may include laryngospasm with stridor, apnea, and cyanosis. Additionally, in many children, the ensuing inflammation may be implicated in recurrent lower respiratory tract infections or recurrent bronchospasm with wheezing or chronic cough. Disease and symptom severity are dependent on the quantity and nature of aspirated material, the chronicity of the insult, and the ability of the host to respond appropriately. A large and acute aspiration event may be devastating, but even smaller amounts of fluid or food, when chronically aspirated, can lead to significant lung damage resulting in respiratory morbidity and mortality.

Normal swallowing includes four phases: oral preparatory, oral transit, pharyngeal, and esophageal. The pharyngeal phase is reflex mediated with many measures to protect the airway from aspiration. When stimulated, adduction of the true vocal cords and approximation of the arytenoid cartilages occur, thereby closing the laryngeal inlet and preventing foreign material to enter the airway. Evidence suggests that patients with aspiration have reduced or inhibition of laryngopharyngeal sensation with clinical correlates of intermittent wheezing, choking or gagging with feeds, chronic "wet" cough, and recurrent pneumonias [2, 3].

Children at greatest risk for aspiration are those with anatomical malformations (cleft palate, esophageal atresia, tracheoesophageal fistula, or posterior laryngeal cleft), central nervous system abnormalities, or progressive neuromuscular diseases (Table 1). Although these comorbidities should be recognized, practitioners should not exclude aspiration as a potential contributor to disease in children without known risk factors and in whom respiratory symptomatology is unexplained; 60% of these children are found to demonstrate oropharyngeal aspiration of liquids, and of these, 100% aspiration events are silent (without cough) [4].

Table 1 Common contributors to oropharyngeal dysphagia in infants and children

Neuromuscular	*Anatomical*
• Cerebral palsy (CP)	• Vocal cord paralysis
• Prematurity	• Tracheoesophageal fistula
• Arnold-Chiari malformation	• Subglottic stenosis
• Muscular dystrophy	• Cleft lip or cleft palate
• Developmental delay	• Laryngeal cleft
Physiologic	• Laryngomalacia
• Gastroesophageal reflux disease (GERD)	• Esophageal atresia
• Eosinophilic esophagitis (EOE)	• Achalasia
• Oro-naso-pharyngeal secretions	• Vascular ring
	• Craniofacial malformations

Gastroesophageal reflux (GER) is a normal physiologic phenomenon which occurs in 40% of infants. In 10–20%, these events are symptomatic and may be defined as pathologic gastroesophageal disease (GERD) [2]. Chronic reflux of caustic material decreases laryngeal sensation and reactivity during the pharyngeal phase of swallowing. This insensate larynx may contribute to or exacerbate oropharyngeal dysphagia and aspiration. It is also a risk factor for recurrent and persistent upper and lower respiratory tract conditions including sinusitis, laryngitis, laryngospasm, chronic cough, and asthma in children [5].

Early detection and management of chronic aspiration are critical in preventing poor respiratory health and progression to permanent lung disease. Late-stage complications of aspiration include bronchiectasis, hypoxemia, and respiratory insufficiency or failure. Although there is no known gold standard in investigating pulmonary aspiration, the diagnosis is made clinically with judicious use of supportive diagnostic evaluations as clinically indicated.

Plain chest radiographs (CXR) are insensitive for early disease; early findings may include hyperinflation, segmental infiltrates, and peribronchial thickening. High-resolution computed tomographic imaging (HRCT) is more sensitive than CXR in detecting early disease; characteristic but non-specific findings of chronic aspiration include bronchial thickening, air trapping, centrilobular opacities, and bronchiectasis [1].

A videofluoroscopic swallow study (VSS), or modified barium swallow, evaluates for dysfunction during the oral, pharyngeal, and esophageal phases of swallowing. Laryngeal penetration and true aspiration are able to be visualized through this approach. The VSS lacks sensitivity in the diagnosis of retrograde aspiration (related to gastroesophageal reflux) and salivary aspiration. The study involves ionizing radiation, and cumulative exposure should be considered in children who are studied on more than one occasion. Alternatively, the swallowing mechanism may be directly visualized with a fiber-optic endoscopic evaluation of swallowing (FEES) study. In this evaluation, the otolaryngologist and speech and language pathologist (SLP) generally collaborate in the endoscopic visualization of oral and pharyngeal phases of swallowing while assessing the airway protective reflexes. Unlike the VSS, children are not exposed to radiation and sedation during this procedure.

In the setting of suspected salivary or retrograde aspiration, the diagnostic approach involves a detailed patient history with additional testing as clinically indicated. Testing considerations include esophageal pH and/or impedance monitoring, gastroesophageal scintigraphy, and upper endoscopy with esophageal biopsy. Esophageal pH monitoring detects only acid reflux and lacks the ability to detect alkaline reflux events. Impedance monitoring is not available at all sites but allows detection of bidirectional flow and both acid and alkali reflux events. In the setting of confirmed reflux, the relationship between these events and pulmonary symptomatology may remain undefined. Other available testing modalities include gastroesophageal scintigraphy (e.g., milk scan), upper endoscopy with biopsy, bronchoscopy with bronchoalveolar lavage for lipid-laden macrophage index (LLMI), and nuclear salivary studies. All of these studies are limited by their sensitivity and specificity for clinically significant pulmonary aspiration, and a collaborative approach to the

diagnosis and management of suspected pulmonary aspiration, which includes the otolaryngologist, gastroenterologist, speech and language pathologist, pulmonologist, and primary care provider, is recommended.

Eosinophilic Esophagitis

Eosinophilic esophagitis (EOE) represents an alternate inflammatory etiology for shared gastrointestinal and pulmonary symptomatology. EOE is a chronic and allergic-mediated disease defined histologically by an eosinophil-predominant inflammation [6]. Histologic confirmation is achieved by demonstrating the presence of ≥15 eosinophils on esophageal biopsy (per HPF).

Disease prevalence is currently approximated at 0.5–1 per 1000 but has increased markedly in recent decades with a trend which mimics that of other allergic diseases such as food allergy, asthma, and allergic rhinitis [7]. EOE affects males at a rate three times greater than females, and more than half of affected individuals have a history of atopic disease. Recently investigations have established that mutations in thymic stromal lymphopoietin (TSLP) and filaggrin (FLG) genes are found in association with both EOE and other atopic diseases, providing further support for a primary atopic disease pathogenesis [8]. The majority of patients with EOE demonstrate food sensitivity to milk, egg, soy, wheat, seafood, or peanuts, and avoidance of these food allergens has been associated with amelioration of disease in a significant number of patients.

Symptoms of EOE may vary significantly across age groups; infants and young children are most likely to demonstrate symptoms which overlap and mimic those of dysphagia, aspiration, and gastroesophageal reflux disease with wheezing, cough, and recurrent respiratory infections as predominate concerns. As a result, many affected infants and children may undergo extensive testing and be treated symptomatically prior to the consideration or confirmation of primary eosinophilic disease. In later childhood, vomiting, abdominal discomfort, and food impaction may become more recognizable symptoms of esophageal disease. Suggestive endoscopic findings of progressive fibrosis include mucosal linear furrowing and stricture formation.

Although the pathophysiologic basis for pulmonary symptomatology in EOE has historically been lacking, recent data suggests that eosinophils and eosinophil-derived cellular components may contribute to the Th2 inflammatory response [8], which is commonly implicated as an immunologic factor in asthmatic disease. The inflammatory change in the esophagus and nearly universal comorbidity with gastroesophageal reflux are additionally thought to contribute to lack of laryngeal sensitivity and increased risk for aspiration.

Although the etiology remains unclear, eosinophilic esophagitis (EOE) is commonly associated with oropharyngeal dysphagia, reflux-like symptoms, and allergic diseases such as atopic dermatitis, allergic rhinitis, and bronchial asthma in children.

While patients present with a variety of symptoms including feeding difficulties, vomiting, and retrosternal pain, all patients have GERD and food allergies, both of which contribute to inflammation and reduced sensitivity to the larynx and increased risk for aspiration [2].

The diagnosis of EOE must be suspected clinically and confirmed histologically. A therapeutic trial of a proton-pump inhibitor is indicated to exclude alternate etiologies of eosinophilic inflammation in the esophageal mucosa such as proton-pump inhibitor-responsive esophageal eosinophilia (PPI-REE). Once the diagnosis is confirmed, additional recommended management includes food allergen elimination and topical steroid therapy. In severe cases, systemic steroids and esophageal dilation procedures may be required.

Anatomic Abnormalities

Achalasia and Airway Obstruction

Pulmonary symptoms may be encountered when there is mechanical obstruction of the airway from an adjacent disease process. When esophageal disease is implicated as the source of airway obstruction, the site of impingement is often in the upper airway, at or near the thoracic inlet. Tracheal obstruction may be seen in the setting of esophageal foreign body aspiration. A high index of suspicion for this potential cause of shared gastrointestinal and respiratory symptoms is especially indicated in young children as a swallowing of nonorganic material (e.g., coins) or a choking event is frequently unwitnessed; furthermore, radiographic imaging may be normal in the setting of non-radiopaque foreign bodies.

Mechanical impingement of the upper airway may also occur with marked esophageal dilatation due to achalasia cardia. Achalasia is the most common primary motility disorder of the esophagus and is characterized by failure of the lower esophageal sphincter (LES) to relax on swallowing with absence of esophageal body peristalsis due to a loss of inhibitory myenteric neurons.

Progressive esophageal dilation and food impaction are common disease sequelae, and common presenting symptoms include dysphagia, regurgitation, aspiration, chest discomfort, weight loss, and anorexia. Pulmonary symptomatology may predominate with cough, hoarseness, stridor, and dyspnea. Although symptoms may be attributable to laryngeal and tracheal inflammation in the setting of micro-aspiration, direct compression of the airway from a dilated esophagus is an alternate explanation for respiratory symptomatology (Fig. 1a, b). Due to the frequently non-specific nature of symptoms, patients may be treated for more common pulmonary disorders with poor response to medical therapies. Several case reports have highlighted the potential for attributing the symptoms of achalasia to anorexia nervosa or an alternate psychiatric disorder [9]. Therefore, the diagnosis may be significantly delayed and a high index of suspicion is required.

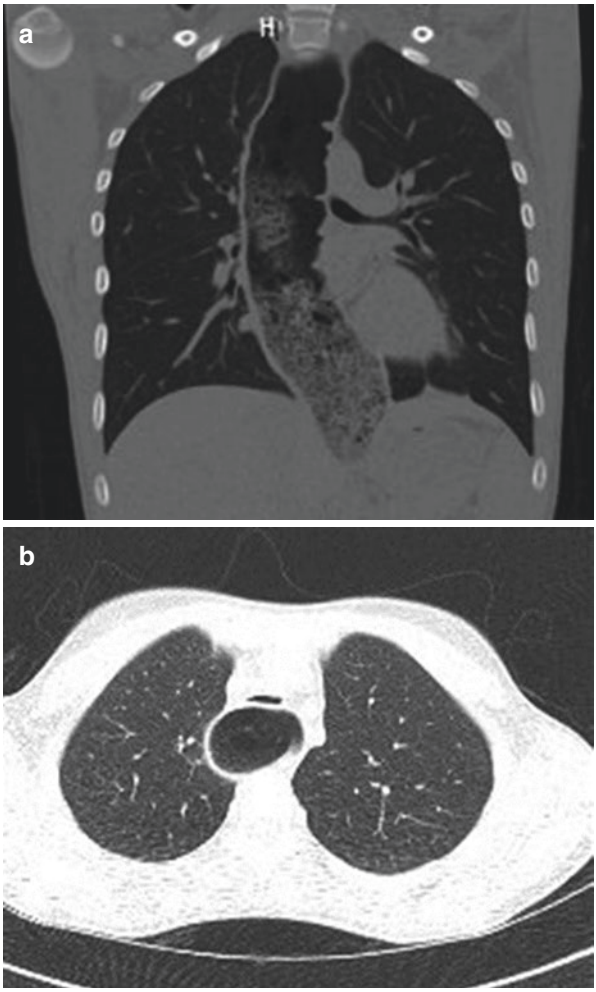

Fig. 1 (**a**) Markedly dilated esophagus with retained ingested material in achalasia. (**b**) Markedly dilated esophagus exerting pressure and causing decreased diameter of tracheal lumen

In suspected cases of achalasia, endoscopy is indicated to exclude alternate diagnoses, particularly pseudoachalasia which is commonly caused by malignancy in the gastroesophageal junction. Both endoscopy and radiographic imaging (barium swallow) are poorly sensitive for the diagnosis of achalasia, especially in early stages of disease. A barium esophagram may be indicated to determine the diameter and axis of the esophagus prior to surgical management. The classic radiographic finding, including the appearance of a "bird's beak" at the area of the gastroesophageal junction and a dilated esophageal body, may not be visualized until late in the disease course. There is no cure for achalasia; management relies on dilation of the LES or disruption of the dysfunctional muscular sphincter through Heller myotomy or peroral endoscopic myotomy (POEM). A majority of affected patients will require repeat treatment for recurrent disease. End-stage esophageal dysfunction is rarely encountered [10].

Esophageal Atresia and Associated Airway Anomalies

Structural abnormalities in the lower airway may also occur in association with gastrointestinal anomalies and are frequently encountered after surgical correction of an esophageal atresia (EA), with or without associated tracheoesophageal fistula (TEF).

Congenital atresia of the esophagus either with or without an associated tracheoesophageal fistula (EA ± TEF) is not uncommonly encountered in the pediatric population. This congenital anomaly may be suspected when oral secretions are not swallowed normally, when attempts at feeding result in choking or emesis, or when passage of an esophageal catheter is unsuccessful. Surgical repair is generally performed early in postnatal life; however, abnormalities in the structure and function of the esophagus and trachea can be expected to persist and contribute to gastrointestinal and pulmonary disease.

Dysphagia is a commonly encountered comorbidity due to a deficiency in the myenteric plexus of the esophagus and reduced esophageal peristaltic motion [11]. Gastroesophageal reflux is also commonly seen. As with other etiologies of dysphagia and aspiration, timely recognition and proactive management are indicated to prevent late-stage pulmonary complications and loss of pulmonary function.

After surgical repair of EA ± TEF, the membranous posterior wall of the trachea remains abnormally compliant, and cartilaginous tracheal rings may be shorter than normal; these structural abnormalities result in anteroposterior bowing of the tracheal wall or tracheomalacia with variable degrees of airway obstruction. Clinically significant tracheomalacia may be present in and complicate the respiratory status of up to 78% of patients with esophageal atresia with or without TEF [12]. These affected individuals may present with recurrent lower respiratory tract infections and pneumonia due to the narrowing of the intraluminal diameter of the airway and related poor cough clearance. Additional symptoms may include a brassy cough, recurrent wheezing, and submaximal exercise performance.

Vascular Shunt

Hepatopulmonary Syndrome

Dyspnea and arterial hypoxemia are associated with hepatopulmonary syndrome (HPS) in the setting of liver disease. In HPS, deoxygenation of arterial blood occurs as a result of intrapulmonary vascular dilatations (IPVD) which allow mixed venous blood to pass directly into the pulmonary veins.

HPS affects 5–32% of adult patients being assessed for liver transplantation. In children, the reported prevalence of HPS is less but still significant at 3–19%. The most common hepatic disorder leading to HPS is liver cirrhosis; although the etiology of cirrhotic change does not appear to alter risk, portal hypertension is commonly

associated. Clinical symptoms include dyspnea, platypnea (an increase in dyspnea with a change from supine to upright positioning), and orthodeoxia (a decrease of ≥5% in the partial pressure of arterial oxygen with a change from supine to upright positioning). Digital clubbing and cyanosis may be present. Arterial hypercarbia is not an expected finding in children with hepatopulmonary syndrome; in fact, hypocarbia and alkalemia may be found in patients with increasing levels of dyspnea.

As a result of the non-specific nature of symptoms in HPS, suggestive findings may be attributed to primary disease or other comorbidities; in these areas as in others, a high index of suspicion is warranted. In addition to precedent liver disease, the diagnostic criteria for HPS [13] include an alveolar-arterial oxygen gradient ≥15 mmHg and a positive contrast-enhanced echocardiogram (CEE) where the delayed (>3 cardiac cycles) visualization of small bubbles in the left atrium strongly suggests an intrapulmonary vascular shunt and the presence of intrapulmonary vascular dilatations.

An additional and more specific approach to the diagnosis of HPS is found in whole body 99mTcMAA (technetium-99m-labeled macroaggregated albumin) scanning. In this nuclear medicine study, injected, radiolabeled macroaggregates of albumin (>20 μm in diameter), which would normally be retained in the pulmonary vascular bed, may be visualized in extrapulmonary sites such as the brain, kidneys, spleen, or liver thereby indicating the presence of IPVD.

Subclinical IPVD may occur in the presence of normal oxygen saturations. As such, pulse oximetry is poorly sensitive for the early diagnosis of HPS.

In patients with HPS, median survival is recorded as 2 years, but lesser survival has been demonstrated when partial pressures of oxygen in arterial blood fall below 50 mmHg [14]. Liver transplantation remains the only effective therapeutic option for late-stage HPS. Survival in liver transplantation has not been found to be associated with the severity of hypoxemia at the time of diagnosis [15].

Summary

In summary, a number of primary gastrointestinal diseases may be clinically associated with respiratory symptomatology or pulmonary radiographic abnormalities; these manifestations tend to be non-specific, and related concerns may be referred first to a pulmonologist or primary care provider. A high index of suspicion and timely but careful investigations will help to alleviate symptomatology and moderate disease-associated risk.

References

1. Boesch RP, Daines C, Willging JP, Kaul A, Cohen AP, Wood RE, et al. Advances in the diagnosis and management of chronic pulmonary aspiration in children. Eur Respir J. 2006;28(4):847–61.
2. Durvasula VS, O'Neill AC, Liacouras CA, Furuta GT, Hirano I, Atkins D, et al. Eosinophilic esophagitis: updated consensus recommendations for children and adults. J Allergy Clin Immunol. 2011;128:3–20.

3. Richter GT. Oropharyngeal dysphagia in children: mechanism, source, and management. Otolaryngol Clin N Am. 2014;47(5):691–720.
4. Lefton-Greif MA, Carroll JL, Loughlin GM. Long-term follow-up of oropharyngeal dysphagia in children without apparent risk factors. Pediatr Pulmonol. 2006;41(11):1040–8.
5. Onal Z, Cullu-Cokugras F, Isildak H, Kaytaz A, Kutlu T, Erkan T, et al. Evaluation of the likelihood of reflux developing in patients with recurrent upper respiratory infections, recurrent sinusitis or recurrent otitis seen in ear-nose-throat outpatient clinics. Turk J Pediatr. 2015;57(3):258–65.
6. Liacouras CA, Furuta GT, Hirano I, Atkins D, Attwood SE, Bonis PA, et al. Eosinophilic esophagitis: updated consensus recommendations for children and adults. J Allergy Clin Immunol. 2011;128:3–20.
7. Liacouras CA, Spergel J, Gober LM. Eosinophilic esophagitis: clinical presentation in children. Gastroenterol Clin N Am. 2014;43:219–29.
8. Oyoshi MK. Recent research advances in eosinophilic esophagitis. Curr Opin Pediatr. 2015;27:741–7.
9. Dabritz J, Domagk D, Monninger M, Foell D. Achalasia mistaken as eating disorders: report of two children and review of the literature. Eur J Gastroenterol Hepatol. 2010;22:775–8.
10. Moonen A, Boeckxstaens G. Current diagnosis and management of achalasia. J Clin Gastroenterol. 2014;48(6):484.
11. Kovesi T. Long-term respiratory complications of congenital esophageal atresia with or without tracheoesophageal fistula: an update. Dis Esophagus. 2013;26:413–6.
12. Malmstrom K, Lohi J, Lindahl H, Pelkonen A, Kajosaari M, Sarna S, et al. Longitudinal follow up of bronchial inflammation, respiratory symptoms and pulmonary function in adolescents after repair of esophageal atresia with tracheoesophageal fistula. J Pediatr. 2008;153:396–401.
13. Goldberg DS, Fallon MB. Hepatopulmonary syndrome. In: Complications of cirrhosis. Berlin: Springer; 2015. p. 169–76.
14. Hoerning A, Raub S, Neudorf U, Müntjes C, Kathemann S, Lainka E, et al. Pulse oximetry is insufficient for timely diagnosis of hepatopulmonary syndrome in children with liver cirrhosis. J Pediatr. 2014;164:546–52.
15. Iyer VN, Swanson KL, Cartin-Ceba R, Dierkhising RA, Rosen CB, Heimbach JK, et al. Hepatopulmonary syndrome: favorable outcomes in the MELD exception era. Hepatology. 2013;57:2427–35.

Pulmonary Complications of Haematologic Disorders

Anne Greenough, Katie Hunt, and Elinor Charles

Abbreviations

2,3-DPG	2,3-diphosphoglyceric acid
ACS	Acute chest syndrome
AHR	Airway hyperresponsiveness
All	Acute lymphoblastic leukaemia
AML	Acute myeloid leukaemia
COHb	Carboxyhaemoglobin
CT	Computerised tomography
CTEPH	Chronic thromboembolic pulmonary hypertension
DAH	Diffuse alveolar haemorrhage
DLCO	Diffusing capacity of the lung
FEF_{75}	Forced expiratory flow at 75% of vital capacity
FEV_1	Forced expiratory volume at one minute
FOE	Fractional oxygen extraction
FVC	Forced vital capacity
GHVD	Graft-versus-host disease
HbF	Foetal haemoglobin

A. Greenough, M.D.(Cantab), M.B.B.S., D.C.H., F.R.C.P., F.R.C.P.C.H. (✉)
Department of Women and Children's Health, School of Life Course Sciences, Faculty of Life Sciences and Medicine, King's College London, London, UK
e-mail: anne.greenough@kcl.ac.uk

K. Hunt, M.R.C.P.C.H., M.A.(Cantab), M.B.B.S. • E. Charles, L.L.B., M.B.B.S.
Division of Asthma, Allergy and Lung Biology, MRC and Asthma UK Centre in Allergic Mechanisms of Asthma, King's College London, London, UK
e-mail: katie.a.hunt@kcl.ac.uk; elinor.charles@kcl.ac.uk

© Springer International Publishing AG 2018

A.C. Koumbourlis, M.A. Nevin (eds.), *Pulmonary Complications of Non-Pulmonary Pediatric Disorders*, Respiratory Medicine,
https://doi.org/10.1007/978-3-319-69620-1_3

HbSC	Haemoglobin sickle cell disease
HbSS	Sickle cell anaemia
HbSβthal	Sickle β^0- and β^+-thalassaemia
HO-1	Heme oxygenase-1
HSCT	Haematopoietic stem cell transplantation
IPH	Idiopathic pulmonary haemosiderosis
NO	Nitric oxide
OSAS	Obstructive sleep apnoea syndrome
PE	Pulmonary embolism
PEF	Peak expiratory flow
SCD	Sickle cell disease
SDB	Sleep-disordered breathing
SPLA2	Pulmonary secretory phospholipase A2
TLC	Total lung capacity
TRV	Tricuspid regurgitant jet velocity
VCAM-1	Vascular cell adhesion molecule
VOC	Vaso-occlusive crisis
VTE	Venous thromboembolism

Sickle Cell Disease

Introduction

Sickle cell disease (SCD), a haemolytic anaemia, is the most common inherited disorder affecting African and Caribbean populations. Approximately 250,000 children are born each year with SCD. Homozygous inheritance of the gene for HbS results in sickle cell anaemia (HbSS), the most severe form of SCD. Patients with SCD can suffer pulmonary complications, particularly acute chest syndrome (ACS) episodes and sickle chronic lung disease (SCLD).

Acute Chest Syndrome

ACS episodes are characterised by chest pain, productive cough and dyspnea. Affected individuals are febrile and tachypnoeic, and on auscultation there are crackles and wheeze. The incidence of ACS is 10.5 per 100 patient years [1], but ACS episodes occur more commonly in children than adults. Fifty percent of SCD children will have an ACS episode prior to the age of 10 years [2]. The incidence of ACS is inversely proportional to the level of foetal haemoglobin HbF [3] and directly proportional to the steady state white blood count. High HbF levels inhibit HbS polymerisation which protects against ACS, whereas a high white cell count increases the risk as leucocytes release free radicals, elastase, pro-inflammatory mediators and cytokines. Infection is implicated in at least 30% of ACS episodes. In approximately 10% of patients, an ACS is precipitated by a pulmonary fat

embolism. Asthma is more common in those who have had an ACS episode and particularly in those with recurrent ACS episodes [4]. Wheezing, without a diagnosis of asthma, however, is also associated with an increase in SCD complications [5–7].

Sickle Chronic Lung Disease (SCLD)

SCLD is a progressive disease characterised by hypoxaemia, restrictive lung disease, cor pulmonale and radiographic evidence of diffuse interstitial fibrosis. Recurrent ACS episodes are the most important risk factor for the development of SCLD [8] as they cause damage to the lung parenchyma resulting in restrictive lung disease. Affected patients may have pulmonary hypertension which significantly reduces their survival.

Lung Function Abnormalities

Obstructive, restrictive and mixed lung function abnormalities have been reported in SCD patients. In young children obstructive lung function abnormalities are common, but restrictive lung function abnormalities become more prominent with increasing age [9–11].

Both cross-sectional [9] and longitudinal [10, 12] studies have shown that lung function deteriorates with increasing age. There is no consensus as to whether bronchial hyperreactivity is part of the pathophysiology of SCD because its reported prevalence varies widely with positive responses to bronchial challenges ranging from 0 [13] to 78% [14].

Factors Affecting Lung Function

The rate of decline in lung function is related to age, being commoner in younger children in whom ACS episodes are more common [10]. Young adults with SCD have worse lung function than ethnically matched controls, particularly if they had suffered recurrent ACS episodes [8].

Mechanisms Underlying the Lung Function Abnormalities

Sickling

Deoxygenated changes in the membrane stiffen the red blood cell, making them less deformable and subject to haemolysis. The rigid cells can obstruct small blood vessels. Over time, cells which have sickled repeatedly become irreversibly sickled. Deoxygenation is maximal in the venous circulation, and the sickled cells can cause

extensive and progressive damage to the pulmonary vascular bed. The sickle cells occlude vessels particularly to organs with sluggish circulation, for example, atelectatic areas of the lung.

Asthma

Certain SCD children with obstructive lung function abnormalities do have asthma, but not all of them. Exhaled nitric oxide (NO) is elevated in asthma, yet, in a prospective study, exhaled NO levels were similar in SCD children and controls, but the SCD children had airways obstruction [15]. Furthermore, in another study no significant correlation was found between exhaled NO and respiratory system resistance, a measure of airways obstruction [16].

Anaemia

SCD children suffer chronic anaemia resulting in a raised cardiac output and a hyperdynamic pulmonary circulation. The resultant increased pulmonary capillary blood volume has been shown to correlate with the degree of airways obstruction [17]. Furthermore, blood transfusion in SCD children acutely increased both their airways obstruction and pulmonary capillary blood volume with a significant correlation between them [18].

Clinical Impact

The most rapid deterioration in lung function occurs in very young children [10]; thus, annual respiratory monitoring should begin early. Young children have limited ability to perform lung function tests, but impulse oscillometry can be used as it is non-volitional. In older children, spirometry gives additional information. Children with SCD frequently wheeze; this may be due to asthma, but there are other causes. It is, therefore, recommended that they are formally assessed to determine if they do have bronchial hyperreactivity, but a methacholine challenge should not be used as it can precipitate an ACS. An alternative strategy would be a trial of inhaled steroids, but with diary card and lung function analysis to determine if the inhaled steroids have been efficacious. It is important to determine the underlying mechanism resulting in the lung function abnormalities in an individual as this will determine their most appropriate treatment.

Iron Overload

Iron overload, due to a variety of conditions, can cause damage to the lungs resulting in lung function abnormalities and respiratory morbidity. In this section, thalassaemia is used as an example of such a condition.

Thalassaemia

Introduction

The thalassaemias are a group of inherited blood disorders resulting from defects in globin genes. The β-thalassaemias are characterised by a reduction in the production of the β-globin chains of HbA. The abnormal haemoglobin synthesis results in decreased oxygen delivery to the tissues. To improve the oxygen-carrying capacity of the blood, patients receive regular transfusions, but this can result in iron overload.

Lung Function Abnormalities

Between 45 and 70% of children with β-thalassaemia have abnormal lung function results. The most common abnormality is a restrictive pattern [19, 20], but an obstructive pattern has been reported in up to 20% of patients. Patients with β-thalassaemia major also have evidence of small airways obstruction as evidenced by a reduced forced expiratory volume in 0.75 s (FEF_{75}) results [21] and gas trapping on computerised tomography (CT), with a negative correlation between the gas trapping and $FEF_{25–75\%}$ results [22]. They also have a reduced diffusional capacity [19, 23, 24]. A caveat in interpreting the lung function test results is their relationship to blood transfusion administration (see below).

Factors Affecting Pulmonary Function

Age has been reported to have an inverse correlation with forced vital capacity (FVC), forced expiratory volume at one minute (FEV_1) and peak expiratory flow (PEF) [25], with worse lung function in postpubertal compared to prepubertal patients [19].

The relationship of serum ferritin to lung function is inconsistent. Some report no correlation [23, 26], whilst others show an inverse correlation between serum ferritin and FVC, TLC and DLCO [19, 27]. In addition, a lower FVC has been reported in children with high compared to low serum ferritin [28]. Furthermore, higher serum ferritin levels have been reported in children with restrictive compared to those without restrictive lung disease [29]. It should be noted, however, that all of the studies were of relatively small sample size (each less than 50 participants).

Mechanisms Underlying the Lung Function Abnormalities

The association between serum ferritin and lung function abnormalities may be due to iron deposition. In one study, [24] the diffusing capacity of the alveolar-capillary membrane was substantially decreased and negatively correlated with age and the serum ferritin level, the fall being primarily attributed to increased membrane

thickness. Those findings suggest that lung fibrosis and/or interstitial oedema related to iron overload and are causes of pulmonary dysfunction in thalassaemic patients. Serum ferritin, however, is an acute phase reactant and not a direct marker of pulmonary iron stores. Nevertheless, iron deposition in the lung, as evidenced by iron-laden macrophages on bronchoalveolar lavage, was reported in 14 of 15 thalassaemic patients with abnormal spirometry or DLCO results [25]. Furthermore, ferritin was found to be a strong predictor for forced vital capacity (FVC) and total lung capacity [25]. Iron deposition may lead to airway narrowing and hence explain the airway obstruction seen in some patients. Haemosiderosis and subsequent free radical-induced oxidative tissue injury could lead to lung damage and fibrosis.

The hypercoagulable status of the thalassaemic patients results in microembolisation of the pulmonary arteries which may interfere with alveolar growth [20]. Pulmonary function was reported to be higher when blood transfusions were given with a leucocyte filter compared to without, suggesting that leucocytes may play a role in impairing lung function, but no mechanism was reported.

Clinical Impact

Although lung function abnormalities are common in children with β-thalassaemia major and chest radiograph abnormalities demonstrate an increase in interstitial markings [26, 27], the children are usually asymptomatic. It is likely, however, as the lung function abnormalities progress, the children will become symptomatic. It is, therefore, essential that children with β-thalassaemia major have routine respiratory function monitoring to detect at an early stage those developing lung function abnormalities and hence appropriate interventions can be given. Cardiac complications of β-thalassaemia are the most important factors in determining survival and hence should also be monitored.

Abnormalities of White Blood Cells

Leukaemia

Introduction

Leukaemia is the most common cancer in children, representing 25% of childhood malignancies [30]. The most common subtypes in children are acute lymphoblastic leukaemia (ALL) and acute myeloid leukaemia (AML). Advances in treatment have led to dramatic improvements in survival rates for ALL; remission rates in childhood are 99% with a 10-year survival rate of 63% [31]. AML, which is less common, carries a poorer prognosis with survival rates of 40% at 5 years [30]. Treatment consists of intensive chemotherapy with induction, intensification and maintenance

regimes with or without central nervous system prophylaxis [31]. Unfortunately, several of the chemotherapy agents have a high risk of pulmonary toxicity [32].

Lung Function Post Childhood Leukaemia

Approximately 40% of survivors of childhood leukaemia have some degree of abnormality on pulmonary function testing [33–35], but only 10–25% of children are symptomatic reporting cough or mild dyspnea [33, 35]. Abnormalities are more common in those surviving ALL (50%) than AML (20%) [35]. The pulmonary dysfunction is predominantly restrictive [36, 37] although this is not a consistent finding [38]. Survivors of both leukaemia and lymphoma have higher rates of pulmonary dysfunction (up to 84% [39]), which may be explained by use of bleomycin and thoracic radiotherapy, both of which are known to cause pulmonary damage. Twenty percent of survivors have been reported to have pulmonary interstitial or alveolar infiltrates on CT, which were associated with abnormal pulmonary function results, but 35% of children with normal CT findings had abnormal pulmonary function results.

Effects of Chemotherapy

Currently, induction chemotherapy consists of vincristine, corticosteroid and L-asparaginase, with or without an anthracycline (doxorubicin or daunorubicin) [30]. Intensification regimens involve cumulative dosing of methotrexate or anthracyclines, and maintenance therapy is usually daily methotrexate or 6-mercaptopurine dosing [30].

During the maintenance phase of chemotherapy, children have similar spirometry results to matched healthy controls but with a moderate decrease in inspiratory muscle strength. Those results suggest that the immediate effects of chemotherapy are minimal and that physiotherapy may be of use in preserving muscle strength [39]. The incidence of pulmonary function abnormalities, however, is significantly higher in those treated with intermediate or high-risk chemotherapy protocols [33]. High doses of chemotherapy agents such as cyclophosphamide and anthracyclines have been shown to lead pulmonary toxicity in the long term [37, 40]. Pulmonary pathology and treatment-related side effects may lead to a ninefold increase in pulmonary fibrosis [41].

Cyclophosphamide causes diffuse alveolar damage [32, 35], on average 3.5 years following exposure and is thought to be independent of dose or duration of therapy [32, 37]. Less commonly, it can cause nonspecific interstitial pneumonia and bronchiolitis obliterans organising pneumonia [32, 35]. In survivors of childhood leukaemia, it has been associated with increased incidence of chronic cough, dyspnea and reduced exercise tolerance [40].

Methotrexate also causes pulmonary toxicity, occurring in 5–10% of patients, most commonly as nonspecific interstitial pneumonia [32]. Methotrexate therapy

has been reported to be a significant predictor of pulmonary dysfunction [35] irrespective of cumulative dose. It has been suggested that genetic variation in methylene tetrahydrofolate reductase may be responsible for increased susceptibility to methotrexate toxicity [35].

Doxorubicin is associated with reduced total lung capacity (TLC) [33] and independently associated with chronic cough and dyspnea [40]. Exposure to cytosine arabinoside, dexamethasone and 6-thioguanine has been associated with an increased risk of recurrent pneumonia [40]. The multidrug treatment protocols, however, make it difficult to identify causative single agents.

Children who have received cranial radiation have been shown to have reduced TLC [35]. It has been suggested that, because of their size, their lungs are still relatively close to the site of radiation and hence affected [35]. Use of cranial irradiation, however, is strongly correlated with higher cumulative doses of chemotherapy. It, therefore, seems likely that the abnormalities seen in these patients could be attributable to the high-dose chemotherapy regimens and/or the radiation [33].

Effects of Allogenic Haematopoietic Stem Cell Transplantation (HSCT)

Introduction

HSCT is used to refer to bone marrow transplantation, peripheral blood stem cell transplantation and umbilical cord blood cell transplantation. HSCT is used in children with leukaemia, lymphoma, solid tumours as well as haemoglobinopathies, immunodeficiencies and metabolic diseases.

Lung Function Abnormalities

Up to 75% of children have some abnormality on pulmonary function testing post-HSCT [34, 42]. A reduction in diffusional capacity is the most common abnormality, occurring in between 64 and 77% [34, 42]. Fifteen percent of patients may experience respiratory problems within 1 year of transplantation, most commonly pneumonia, and approximately 8% have chronic symptoms persisting a year beyond HSCT [34]. Although the lung dysfunction improves 1–2 years post-HSCT [34, 36, 42], the results remain lower than pre-transplantation [34, 36, 40], and longitudinal studies show a pattern of progressive decline [35]. The results, however, were not associated with clinical symptoms or radiographic changes [43].

Mechanisms Underlying the Lung Function Abnormalities

The possible mechanisms of injury following HSCT include use of chemotherapy drugs and total body irradiation prior to transplant. Obstructive lung function abnormalities have been linked to graft-versus-host disease (GHVD) [42]. Chronic GHVD can present as bronchiolitis obliterans seen in 4–9% of paediatric patients post-HSCT and is associated with high morbidity and mortality [42]. Pulmonary dysfunction is associated with older age at transplantation; in one series, patients who underwent transplantation during adolescence did not recover any pulmonary function [34]. Conversely, patients undergoing transplantation at less than 6 years of age experienced a decline in function until adolescence, and then their lung function began to recover.

A proportion of children (12–44%) have abnormal pulmonary function pre-HSCT [34]. This may be due to damage from prior treatment [42], and such children appear to have a higher risk of pulmonary dysfunction post-HSCT [34, 42]. Such patients may benefit from reduced-intensity conditioning, lung shielding and pulmonary infection prophylaxis [34]. Females are more likely to have reduced lung volumes and males more likely to have obstructive abnormalities [34].

Clinical Impact

Radiation-induced lung injury can manifest as acute pneumonitis, seen within the first 2 years, and pulmonary fibrosis [40, 42]. Radiation may also affect chest wall growth [42]; this, along with fibrosis, could explain the restrictive pattern seen in some patients. Immunosuppressive treatment regimens required pre- and post-transplant render individuals susceptible to infections, which can lead to pulmonary damage [42]. Patients are also at risk of idiopathic pneumonia syndrome, bronchiolitis obliterans organising pneumonia and cryptogenic organising pneumonia all of which can present as new onset or worsening lung disease and may require treatment with corticosteroids and/or immunosuppression [42]. The patients have exercise intolerance due to pulmonary limitation, skeletal muscle weakness and cardiac dysfunction. It is recommended that patients are screened periodically to detect changes in lung function, the onset of subtle pulmonary symptoms and/or changes in cardiac function [42].

Anaemia

Introduction

Children who are anaemic have a reduction in the amount of haemoglobin in the blood which reduces their oxygen-carrying capacity. Iron deficiency may also reduce the deformability of red blood cells, compromising passage through capillary beds and therefore reducing oxygen delivery [43, 44].

Physiological Response to Anaemia

As a response to anaemia, blood flow to the brain and heart is increased in an attempt to maintain oxygen delivery to these tissues. Experiments in anaemic newborn lambs demonstrated that, whilst whole body oxygen consumption decreased at low haematocrits, oxygen delivery to the brain and cardiac tissue remained stable with a marked reduction of oxygen delivery to other organs [45]. In chronic anaemia, increased levels of 2,3-diphosphoglyceric acid (2,3-DPG) cause a shift in the oxygen-haemoglobin dissociation curve to the right, promoting oxygen release to tissues at higher partial pressures of oxygen and thus compensating for the reduced oxygen-carrying capacity of the blood.

In premature infants, the fractional oxygen extraction (FOE) increases in babies with symptomatic anaemia, with a subsequent reduction following transfusion, but in asymptomatic infants the FOE is not increased and does not change with transfusion [46, 47]. Cardiac output falls following transfusion in prematurely born infants, suggesting that a low haematocrit resulted in an increase in cardiac output in an attempt to maintain oxygen delivery to tissues [48, 49]. Those compensatory mechanisms appear to be inadequate to mitigate the effects of anaemia beyond a certain threshold. A study of 33 preterm infants showed that when the haemoglobin level dropped below 97 g/L, despite an increase in the fractional oxygen extraction (FOE), the cerebral tissue oxygenation, measured by near infrared spectroscopy, was reduced. Blood transfusion rapidly improved the cerebral oxygenation [50].

Clinical Impact

Reduced tissue oxygenation in anaemic children at high altitude resulted in poorer outcomes from severe pneumonia [51]. Anaemia in cystic fibrosis patients is associated with worse lung function with lower FVC and FEV_1 results, but this was only significant in patients older than 16 years [52]. In a study in India, anaemia may be a risk factor for both the development and severity of asthma in children [53]; the lowest Hb was 5.3 g/dL. Amongst young American women, higher iron stores were associated with a lower prevalence of asthma [54]. Those results, however, should be interpreted with caution, as anaemia can be a marker for broader nutritional deficiencies.

Retrospective analysis of prematurely born infants given blood transfusions for anaemia demonstrated that transfusion improved oxygenation, as evidenced by a reduction in the oxygenation index and improvement in the arterial-alveolar gradient posttransfusion [55]. Posttransfusion improvement in tissue oxygenation may be in part due to the increased proportion of HbA in the blood, which has a lower affinity for oxygen than HbF [56]. Transfusion has been shown to reduce periodic breathing in anaemic preterm infants and to reduce the severity of desaturations, but not apnoea [57–59]. It has been postulated that the irregular breathing pattern in anaemic prematurely born infants is due to mild hypoxic respiratory centre depression [58].

Bleeding Disorders

Introduction

Inherited bleeding disorders, such as haemophilia and von Willebrand's disease, rarely cause alveolar haemorrhage, but patients may experience bleeding into the pleural cavity or mediastinum with consequent respiratory distress and hypoxaemia [60, 61]. Diffuse alveolar haemorrhage (DAH) is seen in premature infants and children with haematological malignancies, vasculitides, pulmonary infections, Henoch-Schonlein Purpura, Goodpasture's syndrome, coagulopathies and some cardiac conditions [62]. The alveolar haemorrhage may be focal or diffuse. DAH without an identifiable cause is known as idiopathic pulmonary haemosiderosis (IPH); it is commoner in children and has a high mortality [63]. Pulmonary capillaritis, a small vessel vasculitis, is an immune-mediated form of DAH. It more commonly occurs in adults but has now been reported in children [64].

Lung Function Abnormalities

Patients with IPH have a restrictive lung function picture, with normal or increased FEV_1/FVC and both FVC and FEV_1 are lower than predicted. A reduced total lung capacity has also been reported. In IPH and other conditions where there may be recurrent alveolar haemorrhage, DLCO is often ultimately reduced due to progressive lung fibrosis and iron deposition [65]. In some cases of IPH treated with immunosuppressive therapy, pulmonary function tests improved at follow-up [66, 67].

There are few reported data on the lung function of children with inherited bleeding disorders. Children with haemophilia have been reported to perform less well than their healthy peers on tests of aerobic fitness, for example, the 6-min walk test, but this not a consistent finding [68]. The reduced performance may reflect decreased physical activity due to joint problems and/or concerns regarding injury [69, 70].

Clinical Impact

Alveolar haemorrhage may present acutely with haemoptysis, hypoxia and impending respiratory failure [71–73] or, more insidiously, with chronic cough, wheeze, recurrent infections or signs of chronic lung disease, such as clubbing [64]. On chest radiographic examination, there is nonspecific bilateral patchy infiltrates [74]. It is a life-threatening pulmonary complication in patients with haematological malignancies or autoimmune disorders [62]. Treatment options that include corticosteroids, transfusions, extracorporeal membrane oxygenation and immunosuppressants are of limited benefit. Recombinant activated factor VII either systemically or via a

bronchoscope has been successfully administered in adults, but there are few reports of its use in children [62]. Children with IPH have repetitive episodes of DAH and develop iron deficiency anaemia secondary to deposition of haemosiderin iron in the alveoli [63]. Corticosteroids alone or in combination with other immunosuppressive agents can be efficacious for either exacerbations or as maintenance therapy [63]. Children with pulmonary capillaritis present with cough and hypoxia, have alveolar infiltrates on their chest radiograph and are anaemic. High-dose corticosteroids can be life-saving [71].

Hyperviscosity

Introduction

Hyperviscosity may result from a relative increase in the number of platelets, excess of plasma protein, extreme leucocytosis or an increased proportion of red blood cells. Thrombocytosis and paraproteinaemias rarely occur in children. Hyperleucocytosis may result in pulmonary leucostasis, most commonly seen in leukaemia, which may be acute or chronic.

Lung Function Abnormalities

Neonates with polycythaemia may present with respiratory distress [75]. Case reports suggest that an increased viscosity of the blood, due to a raised haematocrit, was responsible for the respiratory symptoms. Increased pulmonary vascular resistance in polycythaemic neonates is normalised by partial exchange transfusion [76].

Mechanisms Underlying the Lung Function Abnormalities

In isolated rat lungs, changes in the perfusing haematocrit and hence blood viscosity did not affect the airway mechanics of the lung preparations, but the viscous and elastic properties of the lungs were altered. As the haematocrit decreased, the viscous parameter of the lung parenchyma, which related to the total pulmonary resistance, decreased, and the dynamic lung compliance increased. Leukaemic cells have the ability to generate conditions that promote their adhesion to vascular endothelium; leukaemic myeloblasts secrete cytokines which cause endothelial cell activation [77]. The interaction of leukaemic cells with the vascular endothelium results in adhesion, and the reduced deformability of blast cells leads to aggregation of leucocytes and obstruction of the pulmonary microcirculation [77, 78].

Clinical Impact

A raised white cell count contributes to hyperviscosity, but this is often offset by the concurrent fall in erythrocyte count, and hence patients with leukaemia have little change in their blood viscosity [79, 80]. Leucophoresis or exchange transfusion, and hence reduction in white cell count, has been shown to relieve respiratory distress [81, 82], improve oxygenation and gas exchange [83], improve arterial to alveolar oxygen tension ratio [83] and reduce the need for respiratory support in children with pulmonary leucostasis.

Thromboembolism

Pulmonary embolism (PE) is a rare event in children, with an incidence of less than 1 in 100,000 [84], although rates of PE detected at autopsy suggest that PE is underrecognised in the paediatric population [85]. Risk factors include congenital cardiac disease, presence of an indwelling central venous catheter and systemic infection. Oral contraceptive use is increasingly recognised as an important risk factor in adolescent girls [86, 87]. Hypercoagulable states, such as inherited thrombophilias or acquired thrombophilic states, for example, in nephrotic syndrome or systemic lupus erythematosus, also contribute to increased risk of venous thromboembolism (VTE) and PE [88].

Lung Function Abnormalities

There is little published information regarding the effect of an acute PE on lung function. Case reports or retrospective analyses have reported children with central venous catheter-associated VTE require longer mechanical ventilation [89] and those with a massive PE have a high mortality [90].

Clinical Impact

Children with pulmonary embolism may be asymptomatic or present with sudden cardiovascular collapse. They may also present with cough and dyspnoea and are often tachypnoeic and hypoxaemic due to ventilation-perfusion mismatch [91–93]. Up to 13% of children who have a PE go on to develop recurrent PE, particularly those with underlying or persistent risk factors such as malignancy or antiphospholipid syndrome [94]. Children with acute or recurrent PE are at risk of developing chronic thromboembolic pulmonary hypertension (CTEPH) which results from the

incomplete resolution of the PE, with endothelised, organised and fibrin-rich clot in the pulmonary arteries causing obstruction, increasing pulmonary vascular resistance and therefore resulting in pulmonary hypertension [95]. CTEPH is rare in children.

References

1. Castro O, Brambilla DJ, Thorington B, Reindorf CA, Scott RB, Gillete P, et al. The acute chest syndrome in sickle cell disease: incidence and risk factors. The Cooperative Study of Sickle Cell Disease. Blood. 1994;84:643–9.
2. Paul RN, Castro OL, Aggarwal A, Oneal PA. Acute chest syndrome: sickle cell disease. Eur J Haematol. 2011;87:191–207.
3. Paul R, Minniti CP, Nouraie M, Luchtman-Jones L, Campbell A, Rana S, et al. Clinical correlates of acute pulmonary events in children and adolescents with sickle cell disease. Eur J Haematol. 2013;91:62–8.
4. Knight-Madden JM, Forrester TS, Lewis NA, Greenough A. Asthma in children with sickle cell disease and its association with acute chest syndrome. Thorax. 2005;60:206–10.
5. Glassberg JA, Chow A, Wisnivesky J, Hoffman R, Debaun MR, Richardson LD. Wheezing and asthma are independent risk factors for increased sickle cell disease morbidity. Br J Haematol. 2012;159:472–9.
6. Cohen RT, Madadi A, Blinder MA, Debaun MR, Strunk RC, Field JJ. Recurrent, severe wheezing is associated with morbidity and mortality in adults with sickle cell disease. Am J Hematol. 2011;86:756–61.
7. DeBaun MR, Rodeghier M, Cohen R, Kirkham FJ, Rosen CL, Roberts I, et al. Factors predicting future ACS episodes in children with sickle cell anemia. Am J Hematol. 2014;89:E212–7.
8. Knight-Madden JM, Forrester TS, Lewis NA, Greenough A. The impact of recurrent acute chest syndrome on the lung function of young adults with sickle cell disease. Lung. 2010;188:499–504.
9. Sylvester KP, Patey RA, Milligan P, Dick M, Rafferty GF, Rees D, et al. Pulmonary function abnormalities in children with sickle cell disease. Thorax. 2004;59:67–70.
10. Lunt A, McGhee E, Sylvester K, Rafferty GF, Dick M, Rees D, et al. Longitudinal assessment of lung function in children with sickle cell disease. Pediatr Pulmonol. 2016;51:717–23.
11. Koumbourlis A, Lee DJ, Lee A. Longitudinal changes in lung function and somatic growth in children with sickle cell disease. Pediatr Pulmonol. 2007;42:483–8.
12. MacLean JE, Atenafu E, Kirby-Allen M, MacLusky IB, Stephens D, Grasemann H, et al. Longitudinal decline in lung volume in a population of children with sickle cell disease. Am J Respir Crit Care Med. 2008;178:1055–9.
13. Field JF, Stocks J, Kirkham FJ, Rosen CL, Dietzen DJ, Semon T, et al. Airway hyperresponsiveness in children with sickle cell anemia. Chest. 2011;139:563–8.
14. Ozbek OY, Malbora B, Sen AC, Yazici AC, Ozyurek E, Ozbek N. Airway hyperreactivity detected by methacholine challenge in children with sickle cell disease. Pediatr Pulmonol. 2007;42:1187–92.
15. Chaudry RA, Rosenthal M, Bush A, Crowley S. Reduced forced expiratory flow but not increased exhaled nitric oxide or airway responsiveness to methacholine characterises paediatric sickle cell airway disease. Thorax. 2014;69:580–5.
16. Lunt A, Ahmed N, Rafferty GF, Dick M, Rees D, Height S, et al. Airway and alveolar nitric oxide production, lung function, and pulmonary blood flow in sickle cell disease. Pediatr Res. 2016;79:313–7.
17. Wedderburn CJ, Rees D, Height S, Dick M, Rafferty GF, Lunt A, et al. Airways obstruction and pulmonary capillary blood volume in children with sickle cell disease. Pediatr Pulmonol. 2014;49:716–22.

18. Lunt A, McGhee E, Robinson P, Rees D, Height S, Greenough A. Lung function, transfusion, pulmonary capillary blood volume and sickle cell disease. Respir Physiol Neurobiol. 2016;222:6–10.
19. Filosa A, Esposito V, Meoli I, Stefanelli F, Cassandro R. Evidence of a restrictive spirometric pattern in older thalassemic patients. Respiration. 2001;68:273–8.
20. Bourli E, Dimitriadou M, Economou M, Vlachaki E, Christoforidis A, Maratou E, et al. Restrictive pulmonary dysfunction and its predictors in young patients with β-thalassaemia major. Pediatr Pulmonol. 2012;47:801–7.
21. Sohn EY, Noetzli LJ, Gera A, Kato R, Coates TD, Harmatz P, et al. Pulmonary function in thalassaemia major and its correlation with body iron stores. Br J Haematol. 2011;155:102–5.
22. Khong P-L, Chan GCF, Lee S-L, Au WY, Fong DY, Tsang KW, et al. β-Thalassemia major: thin-section ct features and correlation with pulmonary function and iron overload. Radiology. 2003;229:507–12.
23. Li AM, Chan D, Li CK, Wong E, Chan YL, Fok TF. Respiratory function in patients with thalassaemia major: relation with iron overload. Arch Dis Child. 2002;87:328–30.
24. Carnelli V, D'Angelo E, Pecchiari M, Ligorio M, D'Angelo E. Pulmonary dysfunction in transfusion-dependent patients with thalassemia major. Am J Respir Crit Care Med. 2003;168:160–4.
25. Parakh A, Dubey AP, Chowdhury V, Sethi GR, Jain S, Hira HS. Study of pulmonary function tests in thalassemic children. J Pediatr Hematol Oncol. 2007;29:151–5.
26. Hamed AES, Ragab IA, Kamel TB, Abd-El-Gawad AOA. Effect of using bedside leukocyte filter on pulmonary functions in patients with thalassemia major. Pediatr Hematol Oncol. 2013;30:761–7.
27. Abu-Ekteish FM, Al-Rimawi HS, Al-Ali MK, Shehabi IM. Pulmonary function tests in children with beta-thalassemia major. Chron Respir Dis. 2007;4:19–22.
28. Ozyoruk D, Misirlioglu ED. Pulmonary functions in children with thalassemia major. J Pediatr Hematol Oncol. 2015;37:605–10.
29. Boddu A, Kumble A, Mahalingam S, Baliga B, Achappa B. Pulmonary dysfunction in children with beta thalassemia major in relation with iron overload—a cross sectional hospital based study. Asian J Med Sci. 2015;6:47–50.
30. PDQ Pediatric Treatment Editorial Board. Childhood acute lymphoblastic leukemia treatment (PDQ®): health professional version. 2002. http://www.ncbi.nlm.nih.gov/pubmed/26389206. Accessed 30 July 2016.
31. Redaelli A, Laskin BL, Stephens JM, Botteman MF, Pashos CL. A systematic literature review of the clinical and epidemiological burden of acute lymphoblastic leukaemia (ALL). Eur J Cancer Care (Engl). 2005;14:53–62.
32. Rossi SE, Erasmus JJ, McAdams HP, Sporn TA, Goodman PC. Pulmonary drug toxicity: radiologic and pathologic manifestations. Radiographics. 2000;20:1245–9.
33. Nysom K, Holm K, Olsen JH, Hertz H, Hesse B. Pulmonary function after treatment for acute lymphoblastic leukaemia in childhood. Br J Cancer. 1998;78:21–7.
34. Inaba H, Yang J, Pan J, Stokes DC, Krasin MJ, Srinivasan A, et al. Pulmonary dysfunction in survivors of childhood hematologic malignancies after allogeneic hematopoietic stem cell transplantation. Cancer. 2010;116:2020–30.
35. Tantawy AAG, Elbarbary N, Ahmed A, Mohamed NA, Ezz-Elarab S. Pulmonary complications in survivors of childhood hematological malignancies: single-center experience. Pediatr Hematol Oncol. 2011;28:403–17.
36. Nysom K, Holm K, Hesse B, Ulrik CS, Jacobsen N, Bisgaard H, et al. Lung function after allogeneic bone marrow transplantation for leukaemia or lymphoma. Arch Dis Child. 1996;74:432–6.
37. Jenney ME, Faragher EB, Jones PH, Woodcock A. Lung function and exercise capacity in survivors of childhood leukaemia. Med Pediatr Oncol. 1995;24:222–30.
38. Abdel Gawad Tantawy A, Elbarbary N, Ahmed A, Abdraoaf Mohamed N, Ezz-Elarab S. Pulmonary complications in survivors of childhood hematological malignancies: single-center experience. Pediatr Hematol Oncol. 2011;28:403–17.

39. de Macêdo TMF, Campos TF, Mendes RE de F, França DC, Chaves GS da S, de Mendonça KMPP. Pulmonary function of children with acute leukemia in maintenance phase of chemotherapy. Rev Paul Pediatr. 2014;32:320–5.
40. Mertens AC, Yasui Y, Liu Y, Stovall M, Hutchinson R, Ginsberg J, et al. Pulmonary complications in survivors of childhood and adolescent cancer. Cancer. 2002;95:2431–41.
41. Landau D-A, Azaria B, Fineman R, Barenboim E, Goldstein L. Long-term survivors of childhood malignancies—aeromedical dilemmas and implications. Aviat Space Environ Med. 2006;77:1266–70.
42. Gower WA, Collaco JM, Mogayzel PJ. Lung function and late pulmonary complications among survivors of hematopoietic stem cell transplantation during childhood. Paediatr Respir Rev. 2010;11:115–22.
43. Halis H, Bor-Kucukatay M, Akın M, Kucukatay V, Bozbay İ, Polat A. Hemorheological parameters in children with iron-deficiency anemia and the alterations in these parameters in response to iron replacement. Pediatr Hematol Oncol. 2009;26:108–18.
44. Cabrales P. Effects of erythrocyte flexibility on microvascular perfusion and oxygenation during acute anemia. Am J Physiol Heart Circ Physiol. 2007;293:H1206–15.
45. Holzman IR, Tabata B, Edelstone DI. Blood flow and oxygen delivery to the organs of the neonatal lamb as a function of hematocrit. Pediatr Res. 1986;20:1274–9.
46. Wardle SP, Yoxall CW, Crawley E, Weindling AM. Peripheral oxygenation and anemia in preterm babies. Pediatr Res. 1998;44:125–31.
47. Wardle SP, Weindling AM. Peripheral fractional oxygen extraction and other measures of tissue oxygenation to guide blood transfusions in preterm infants. Semin Perinatol. 2001;25:60–4.
48. Fredrickson LK, Bell EF, Cress GA, Johnson KJ, Zimmerman MB, Mahoney LT, et al. Acute physiological effects of packed red blood cell transfusion in preterm infants with different degrees of anaemia. Arch Dis Child Fetal Neonatal Ed. 2011;96:F249–53.
49. Lachance C, Chessex P, Fouron J-C, Widness JA, Bard H. Myocardial, erythropoitic, and metabolic adaptations to anemia of prematurity. J Pediatr. 1994;125:278–82.
50. van Hoften JCR, Verhagen EA, Keating P, ter Horst HJ, Bos AF. Cerebral tissue oxygen saturation and extraction in preterm infants before and after blood transfusion. Arch Dis Child Fetal Neonatal Ed. 2010;95:F352–8.
51. Moschovis PP, Banajeh S, MacLeod WB, Saha S, Hayden D, Christiani DC, et al. Childhood anemia at high altitude: risk factors for poor outcomes in severe pneumonia. Pediatrics. 2013;132:e1156–62.
52. von Drygalski A, Biller J. Anemia in cystic fibrosis: incidence, mechanisms, and association with pulmonary function and vitamin deficiency. Nutr Clin Pract. 2008;23:557–63.
53. Ramakrishnan K, Borade A. Anemia as a risk factor for childhood asthma. Lung India. 2010;27:51–3.
54. Brigham EP, McCormack MC, Takemoto CM, Matsui EC. Iron status is associated with asthma and lung function in us women. PLoS One. 2015;10:e0117545.
55. James L, Greenough A, Naik S. The effect of blood transfusion on oxygenation in premature ventilated neonates. Eur J Pediatr. 1997;156:139–41.
56. De Halleux V, Truttmann A, Gagnon C, Bard H. The effect of blood transfusion on the hemoglobin oxygen dissociation curve of very early preterm infants during the first week of life. Semin Perinatol. 2002;26:411–5.
57. Bifano EM, Smith F, Borer J. Relationship between determinants of oxygen delivery and respiratory abnormalities in preterm infants with anemia. J Pediatr. 1992;120:292–6.
58. Joshi A, Gerhardt T, Shandloff P, Bancalari E. Blood transfusion effect on the respiratory pattern of preterm infants. Pediatrics. 1987;80:79–84.
59. Poets CF, Pauls U, Bohnhorst B. Effect of blood transfusion on apnoea, bradycardia and hypoxaemia in preterm infants. Eur J Pediatr. 1997;156:311–6.
60. Obitko-Pludowska A, Laguna P, Adamowicz-Salach A, Brzewski M, Del Campo KS. Haemothorax in children with congenital coagulopathy. Haemophilia. 2010;16:688–91.

61. Gidaris D, Economou M, Valeri R, Gombakis N, Athanasiou-Metaxa M. Successful treatment of a spontaneous haemothorax with recombinant factor VIIa in a haemophilic child with inhibitors. Hippokratia. 2010;14:289–90.
62. Park JA. Diffuse alveolar hemorrhage and recombinant factor VIIa treatment in pediatric patients. Korean J Pediatr. 2016;59:105–13.
63. Ioachimescu OC, Sieber S, Kotch A. Idiopathic pulmonary haemosiderosis revisited. Eur Respir J. 2004;24:162–70.
64. Susarla SC, Fan LL. Diffuse alveolar hemorrhage syndromes in children. Curr Opin Pediatr. 2007;19:314–20.
65. Repetto G, Lisboa C, Emparanza E, Ferretti R, Neira M, Etchart M, et al. Clinical, radiological, and respiratory function studies. Pediatrics. 1967;40:24–32.
66. Le Clainche L, Le Bourgeois M, Fauroux B, Forenza N, Dommergues JP, Desbois JC, et al. Long-term outcome of idiopathic pulmonary hemosiderosis in children. Medicine (Baltimore). 2000;79:318–26.
67. Taytard J, Nathan N, de Blic J, Fayon M, Epaud R, Deschildre A, et al. New insights into pediatric idiopathic pulmonary hemosiderosis: the French RespiRare(®) cohort. Orphanet J Rare Dis. 2013;8:161.
68. Van der net J, Voa RC, Engelbert RHH, Van den berg MH, Helders PJM, Takken T. Physical fitness, functional ability and quality of life in children with severe haemophilia: a pilot study. Haemophilia. 2006;12:494–9.
69. Hassan J, van der Net J, Helders PJM, Prakken BJ, Takken T. Six-minute walk test in children with chronic conditions. Br J Sports Med. 2010;44(4):270.
70. Engelbert RH, Plantinga M, Van der Net J, Van Genderen FR, Van den Berg MH, Helders PJ, et al. Aerobic capacity in children with hemophilia. J Pediatr. 2008;152:833–8.
71. Fullmer JJ, Langston C, Dishop MK, Fan LL. Pulmonary capillaritis in children: a review of eight cases with comparison to other alveolar hemorrhage syndromes. J Pediatr. 2005;146:376–81.
72. Paller AS, Kelly K, Sethi R. Pulmonary hemorrhage: an often fatal complication of henoch-schonlein purpura. Pediatr Dermatol. 1997;14:299–302.
73. Abu-Kishk I, Klin B, Eshel G. Hemoptysis in children. Pediatr Emerg Care. 2012;28:1206–10.
74. Lichtenberger JP, Digumarthy SR, Abbott GF, Shepard J-AO, Sharma A. Diffuse pulmonary hemorrhage: clues to the diagnosis. Curr Probl Diagn Radiol. 2014;43:128–39.
75. Black VD. Neonatal hyperviscosity syndromes. Curr Probl Pediatr. 1987;17:78–130.
76. Murphy DJ, Reller MD, Meyer RA, Kaplan S. Effects of neonatal polycythemia and partial exchange transfusion on cardiac function: an echocardiographic study. Pediatrics. 1985;76:909–13.
77. Stucki A, Rivier AS, Gikic M, Monai N, Schapira M, Spertini O. Endothelial cell activation by myeloblasts: molecular mechanisms of leukostasis and leukemic cell dissemination. Blood. 2001;97:2121–9.
78. McKee LC, Collins R. Intravascular leukocyte thrombi and aggregates as a cause of morbidity and mortality in leukaemia. Medicine (Baltimore). 1974;53:463–77.
79. Lightman MA, Gregory A, Kearney E. Rheology of leukocytes, leukocyte suspensions, and blood in leukemia, possible relationship to clinical manifestations. J Clin Invest. 1973;52:350–8.
80. Steinberg MH, Charm SE. Effect of high concentrations of leukocytes on whole blood viscosity. Blood. 1971;38:299–301.
81. Moxey-Mims MM, Luban NLC, Bock GH, Ruley EJ, Preston KM. Relief of respiratory distress with leukapheresis in a child with chronic myelocytic leukemia. J Clin Apher. 1988;4:47–9.
82. Abla O, Khanani MF, Hitzler JK, Sung L, Geary D, Abdelhameen M, et al. Complications of hyperleukocytosis and leukapheresis in pediatric acute leukemias. Blood. 2004;104:1963.
83. Sykes JA, Kalyanaraman M, Kamalakar P, Sharma N. Acute lymphoblastic leukemia with hyperleukocytosis, sinus pauses, and hypoxemic respiratory failure in an infant. Pediatr Emerg Care. 2011;27:212–4.

84. Stein PD, Kayali F, Olson RE. Incidence of venous thromboembolism in infants and children: data from the national hospital discharge survey. J Pediatr. 2004;145:563–5.
85. Buck JR, Connors RH, Coon WW, Weintraub WH, Wesley JR, Coran AG. Pulmonary embolism in children. J Pediatr Surg. 1981;16:385–91.
86. Dijk FN, Curtin J, Lord D, Fitzgerald DA. Pulmonary embolism in children. Paediatr Respir Rev. 2012;13:112–22.
87. Branchford BR, Mourani P, Bajaj L, Manco-Johnson M, Wang M, Goldenberg NA. Risk factors for in-hospital venous thromboembolism in children: a case-control study employing diagnostic validation. Haematologica. 2012;97:509–15.
88. Babyn PS, Gahunia HK, Massicotte P. Pulmonary thromboembolism in children. Pediatr Radiol. 2005;35:258–74.
89. Faustino EVS, Lawson KA, Northrup V, Higgerson RA. Mortality-adjusted duration of mechanical ventilation in critically ill children with symptomatic central venous line-related deep venous thrombosis. Crit Care Med. 2011;39:1151–6.
90. Derish MT, Smith DW, Frankel LR. Venous catheter thrombus formation and pulmonary embolism in children. Pediatr Pulmonol. 1995;20:349–54.
91. Baird JS, Killinger JS, Kalkbrenner KJ, Bye MR, Schleien CL. Massive pulmonary embolism in children. J Pediatr. 2010;156:148–51.
92. Patocka C, Nemeth J. Pulmonary embolism in pediatrics. J Emerg Med. 2012;42:105–16.
93. van Ommen CH, Heyboer H, Groothoff J, Teeuw R, Aronson D, Peters M. Persistent tachypnea in children: keep pulmonary embolism in mind. J Pediatr Hematol Oncol. 1998;20:570–3.
94. Biss TT, Brandão LR, Kahr WH, Chan AK, Williams S. Clinical features and outcome of pulmonary embolism in children. Br J Haematol. 2008;142:808–18.
95. McNeil K, Dunning J. Chronic thromboembolic pulmonary hypertension (CTEPH). Heart. 2007;93:1152–8.

Key Articles

Lunt A, McGhee E, Sylvester K, Rafferty GF, Dick M, Rees D, et al. Longitudinal assessment of lung function in children with sickle cell disease. Pediatr Pulmonol. 2016;51:717–23.

Koumbourlis A, Lee DJ, Lee A. Longitudinal changes in lung function and somatic growth in children with sickle cell disease. Pediatr Pulmonol. 2007;42:483–8.

Knight-Madden JM, Forrester TS, Lewis NA, Greenough A. Asthma in children with sickle cell disease and its association with acute chest syndrome. Thorax. 2005;60:206–10.

Chaudry RA, Rosenthal M, Bush A, Crowley S. Reduced forced expiratory flow but not increased exhaled nitric oxide or airway responsiveness to methacholine characterises paediatric sickle cell airway disease. Thorax. 2014;69:580–5.

Lunt A, McGhee E, Robinson P, Rees D, Height S, Greenough A. Lung function, transfusion, pulmonary capillary blood volume and sickle cell disease. Respir Physiol Neurobiol. 2016;222:6–10.

Li AM, Chan D, Li CK, Wong E, Chan YL, Fok TF. Respiratory function in patients with thalassaemia major: relation with iron overload. Arch Dis Child. 2002;87:328–30.

Hamed AES, Ragab IA, Kamel TB, Abd-El-Gawad AOA. Effect of using bedside leukocyte filter on pulmonary functions in patients with thalassemia major. Pediatr Hematol Oncol. 2013;30:761–7.

Sohn EY, Noetzli LJ, Gera A, Kato R, Coates TD, Harmatz P, et al. Pulmonary function in thalassaemia major and its correlation with body iron stores. Br J Haematol. 2011;155:102–5.

Redaelli A, Laskin BL, Stephens JM, Botteman MF, Pashos CL. A systematic literature review of the clinical and epidemiological burden of acute lymphoblastic leukaemia (ALL). Eur J Cancer Care (Engl). 2005;14:53–62.

Rossi SE, Erasmus JJ, McAdams HP, Sporn TA, Goodman PC. Pulmonary drug toxicity: radiologic and pathologic manifestations. Radiographics. 2000;20:1245–59.

Fredrickson LK, Bell EF, Cress GA, Johnson KJ, Zimmerman MB, Mahoney LT, et al. Acute physiological effects of packed red blood cell transfusion in preterm infants with different degrees of anaemia. Arch Dis Child Fetal Neonatal Ed. 2011;96:F249–53.

Moschovis PP, Banajeh S, MacLeod WB, Saha S, Hayden D, Christiani DC, et al. Childhood anemia at high altitude: risk factors for poor outcomes in severe pneumonia. Pediatrics. 2013;132:e1156–62.

von Drygalski A, Biller J. Anemia in cystic fibrosis: incidence, mechanisms and association with pulmonary function and vitamin deficiency. Nutr Clin Pract. 2008;23:557–63.

Brigham EP, McCormack MC, Takemoto CM, Matsui EC. Iron status is associated with asthma and lung function in us women. PLoS One. 2015;10:e0117545.

Lichtenberger JP, Digumarthy SR, Abbott GF, Shepard J-AO, Sharma A. Diffuse pulmonary hemorrhage: clues to the diagnosis. Curr Probl Diagn Radiol. 2014;43:128–39.

Taytard J, Nathan N, de Blic J, Fayon M, Epaud R, Deschildre A, et al. New insights into pediatric idiopathic pulmonary hemosiderosis: the French RespiRare(®) cohort. Orphanet J Rare Dis. 2013;8:161.

Engelbert RH, Plantinga M, Van der Net J, Van Genderen FR, Van den Berg MH, Helders PJ, et al. Aerobic capacity in children with hemophilia. J Pediatr. 2008;152:833–8.

Douma-van riet DCM, Engelbert RHH, Van Genderen FR, Ter horst-de ronde MTM, De goede-bolder A, Hartman A. Physical fitness in children with haemophilia and the effect of overweight. Haemophilia. 2009;15:519–27.

Abla O, Khanani MF, Hitzler JK, Sung L, Geary D, Abdelhameen M, et al. Complications of hyperleukocytosis and leukapheresis in pediatric acute leukemias. Blood. 2004;104:1963.

Dijk FN, Curtin J, Lord D, Fitzgerald DA. Pulmonary embolism in children. Paediatr Respir Rev. 2012;13:112–22.

Baird JS, Killinger JS, Kalkbrenner KJ, Bye MR, Schleien CL. Massive pulmonary embolism in children. J Pediatr. 2010;156:148–51.

Pulmonary Complications of Malignancies and Blood and Marrow Transplantation

Geshani Jayasuriya, Beryl Lin, Steven J. Keogh, and Hiran Selvadurai

Abbreviations

AIP	Acute interstitial pneumonitis
ALL	Acute lymphoblastic anaemia
AML	Acute myeloid leukaemia
APL	Acute promyelocytic leukaemia
ARDS	Acute respiratory distress syndrome
BMT	Bone marrow transplantation
BOOP	Bronchiolitis obliterans with organising pneumonia
BOS	Bronchiolitis obliterans syndrome
CBO	Constrictive bronchiolitis obliterans
cGVHD	Chronic graft-versus-host disease

G. Jayasuriya, B.Med., F.R.A.C.P. • H. Selvadurai, M.B.B.S., F.R.A.C.P., Ph.D. (✉)
Department of Respiratory Medicine, The Children's Hospital, Sydney, NSW, Australia

Discipline of Child and Adolescent Health, The University of Sydney, Camperdown, NSW, Australia
e-mail: geshani.jayasuriya@health.nsw.gov.au; hiran.selvadurai@health.nsw.gov.au

B. Lin
The University of New South Wales, Sydney, NSW, Australia

S.J. Keogh, M.B.B.S.Hons., F.R.A.C.P.
Discipline of Child and Adolescent Health, The University of Sydney, Camperdown, NSW, Australia

Department of Oncology, The Children's Hospital, Sydney, NSW, Australia
e-mail: steven.keogh@health.nsw.gov.au

© Springer International Publishing AG 2018

A.C. Koumbourlis, M.A. Nevin (eds.), *Pulmonary Complications of Non-Pulmonary Pediatric Disorders*, Respiratory Medicine,
https://doi.org/10.1007/978-3-319-69620-1_4

CMV	Cytomegalovirus
COP	Cryptogenic organising pneumonia
DAH	Diffuse alveolar haemorrhage
DL_{CO}	Diffusing capacity for carbon monoxide
EBV	Epstein-Barr virus
GVHD	Graft-versus-host disease
HL	Hodgkin lymphoma
IPS	Idiopathic pneumonia syndrome
LCH	Langerhans cell histiocytosis
MPS	Mucopolysaccharidosis
NCPE	Non-cardiogenic pulmonary oedema
PAH	Pulmonary arterial hypertension
PAWP	Pulmonary artery wedge pressure
PERDS	Peri-engraftment respiratory distress syndrome
PH	Pulmonary hypertension
PTLD	Post-transplant lymphoproliferative disease
PVOD	Pulmonary veno-occlusive disease
SVC	Superior vena cava

Introduction

Despite improvements in survival among cancer patients and BMT recipients there is still substantial morbidity and mortality) associated with pulmonary complications [1–9]. Pulmonary injury can be complex and multifactorial and thus will be examined in relation to underlying malignancy, infectious and non-infectious etiologies as summarised in Table 1. Toxicity resulting from radiation therapy is described in chapter "Pulmonary Complications of Radiation Therapy".

Table 1 Classification of common complications of childhood cancer affecting the chest [1–3]

Malignancy	Infections	Non-infectious and immune
Primary and metastatic tumours Pulmonary infiltrate from systemic disease Leukemic and lymphomatous involvement – Hyperleukocytosis and pulmonary leukostasis – Acute lysis pneumopathy Superior vena cava and superior mediastinal syndrome	Impaired immune function Bacterial Viral Fungal	Drug or radiation toxicity – Acute hypersensitivity reactions – Interstitial pneumonitis – Pulmonary fibrosis – Acute respiratory distress syndrome Pulmonary embolism Pulmonary oedema Alveolar haemorrhage Acute capillary leak syndrome Graft-versus-host disease Impaired growth and development

Pulmonary Malignancies and Complications of Treatment

Complications Directly Resulting from Malignancy

Primary and Metastatic Lung Tumours

Primary lung tumours are extremely rare, representing only 0.2% of all childhood cancers [4, 5]. The vast majority of pulmonary malignancies are in fact metastases, characteristically located in peripheral lower lung segments as well-circumscribed nodules and most commonly associated with Wilm's tumour and osteosarcoma [4–6]. While parenchymal lesions exhibit a more insidious and non-specific presentation, endotracheal and endobronchial lesions often present with unilateral wheeze due to obstruction and can be easily misdiagnosed as asthma [7]. Despite the rarity and non-specific clinical presentation of most lung tumours, malignant disease should be considered in children with constitutional symptoms and persistent wheeze, haemoptysis, atelectasis or pneumonia who fail to respond to therapy [5].

Pulmonary Infiltrates from Systemic Disease

Hyperleukocytosis and Pulmonary Leukostasis

Hyperleukocytosis, defined by a leukocyte count greater than 100×10^9/L, occurs in up to 20% of initial presentations of acute lymphoblastic leukaemia (ALL) and 15% of acute myeloid leukaemia (AML) [1, 8]. Excess leukaemic aggregates can lead to pulmonary leukostasis, a life-threatening complication where cellular occlusion of the pulmonary vasculature leads to hypoxia and acute respiratory distress [9, 10]. While this condition only occurs in up to 6% of children with acute hyperleukocytic leukaemias, associated respiratory failure is one of the most common causes of early mortality in this setting [11, 12].

The pathophysiological basis of hyperleukocytosis-induced pulmonary leukostasis is related to the stasis of hyperviscous blood from elevated leukocrit [1]. Aggregates of rigid blasts cause plugging of the microvasculature and associated oxygen defects, potentiating pulmonary endothelial injury, haemorrhage and tissue hypoxia [8, 13, 14]. As such, the risk of respiratory complications increases with the degree of leukocytosis [15]. However, not all children with high leukocyte counts, such as those with chronic leukaemias, develop this complication due to the morphology and maturity of the leukocytes. Children with AML are at greatest risk of pulmonary leukostasis and tend to develop respiratory distress at lower leukocyte counts than those with ALL [9, 12]. This is because myeloblasts are larger and release pro-inflammatory cytokines with specific adhesion molecules that facilitate aggressive invasion of pulmonary endothelium [12, 16].

Pulmonary leukostasis is empirically diagnosed when children with leukaemia present clinically with hyperleukocytosis and respiratory distress. Though often

non-specific, it can manifest in dyspnoea, pleuritic chest pain and hypoxaemia and lead to right ventricular failure [17]. Chest X-rays may be normal or may show alveolar consolidation and diffuse reticulonodular infiltrates that may resemble pneumonia or interstitial oedema [18]. Computed tomography (CT) radiography may demonstrate thickening of the bronchovascular bundles, prominence of peripheral pulmonary arteries and ground-glass opacities due to leukaemic cell infiltration [1, 17, 18]. Definitive management remains controversial; however, hyperhydration, urate oxidase, low-dose chemotherapy and consideration of leukopheresis may be beneficial in children with extremely high leukocyte counts [12, 15, 19].

Acute Lysis Pneumopathy

Upon initiation of chemotherapy, children with severely worsening hypoxaemia may be symptomatic of 'acute lysis pneumopathy'. This is a rare complication of myelomonocytic and monocytic leukaemias, where lysis of leukaemic cells trapped in the lungs causes diffuse alveolar damage [3, 20, 21]. Management considerations include temporary discontinuation of chemotherapy, steroids and transfusions [22, 23].

Pulmonary Infiltrate in Leukaemia and Lymphoma

Outside the context of hyperleukocytosis, post-mortem evidence has also found diffuse and focal leukaemic infiltration of lung parenchyma, pleura, alveoli, bronchi, and pulmonary vessels in patients with leukaemia and lymphoma [24, 25]. However, symptomatic pulmonary disease due to isolated leukaemic cell infiltrates is uncommon [3, 26].

Langerhans Cell Histiocytosis (LCH)

Pulmonary involvement in LCH occurs in up to 50% of children with multisystem disease and very rarely as primary pulmonary LCH [2, 27–29]. Pathologic accumulation of Langerhans cells admixed with eosinophils, macrophages, and T lymphocytes typically exhibits a bronchocentric infiltration pattern [5, 30]. This is best assessed on high-resolution CT, typically showing reticulonodular opacities in the mid to upper zones with sparing of the costophrenic angles [29, 31]. With progressive destruction of the bronchioles, lesions develop more a diffuse, cystic and fibrotic 'honeycombing' appearance [2, 31].

Extra-Pulmonary Tumours

Mediastinal tumours can compress the tracheobronchial tree and pulmonary vessels causing respiratory insufficiency, superior vena cava (SVC) syndrome and/or superior

mediastinal syndrome [1, 6]. The low intraluminal pressure and delicate wall of the SVC in children with smaller thoracic capacity renders it particularly vulnerable, especially to rapidly enlarging masses of haematological malignancies such as Hodgkin lymphoma, T-cell leukaemia and germ cell tumours [1]. Respiratory manifestations include cough, stridor, chest pain, dyspnoea, orthopnoea, and aversion to the prone position [11]. In these children at risk of cardiorespiratory collapse, urgent assessment of haemodynamic compromise and airway patency such as with a prone CT is essential.

Extra-thoracic space-occupying tumours such as Ewing's sarcoma can also impair normal diaphragmatic excursion and mechanically compromise the respiratory system [1]. Rarely, intracranial tumours can lead to central hypoventilation syndromes or sleep apnoea [1, 2].

Infectious Complications and Their Relationship to Immune Function

Malignancy and cytotoxic therapies cause multifactorial immune defects (Fig. 1) including severe myelosuppression, multi-organ dysfunction and compromise of the mucosal integrity of the respiratory system [35]. Thus, children with cancer undergoing chemotherapy are at high risk of infections from typical and opportunistic viral, bacterial and fungal pathogens (Table 2) [39, 40]. Respiratory infections carry significant morbidity and mortality, particularly during severe neutropenia and intensive induction therapy [41]. Infection-related acute respiratory failure has been reported as a common cause of ICU admission and mortality in paediatric oncology [1, 42].

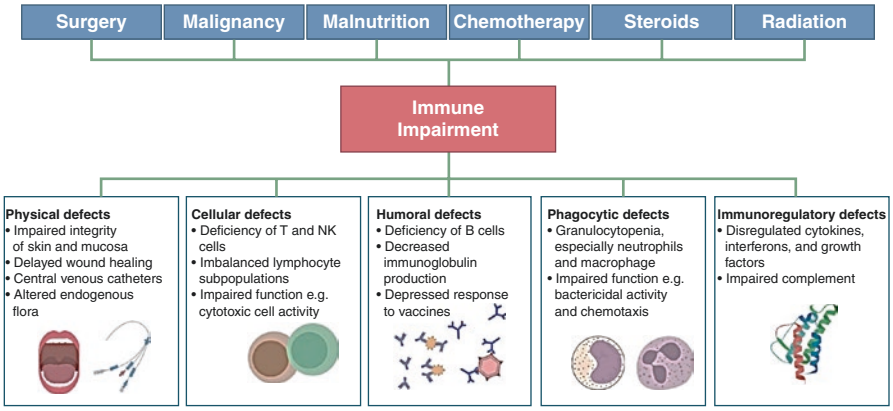

Fig. 1 Immune defects due to malignancy and cytotoxic therapy [32–34]

Table 2 Common respiratory pathogens in childhood malignancy [1, 24, 36–38]

	Common organisms	Risk factors
Protozoa	*Toxoplasma gondii*	Lymphopenia
Fungi	*Aspergillus species* *Candida* *Zygomcetes* *Pneumocystis jiroveci*	Chronic immunosuppression Severe neutropenia <100/μL Prolonged neutropenia >7 days High-dose corticosteroids
Viruses	Respiratory syncytial virus, rhinovirus, influenza, parainfluenza, human metapneumovirus, adenovirus, cytomegalovirus, varicella zoster, herpes simplex	Lymphopenia Young age < 2 years old
Bacteria	*Pseudomonas, Mycoplasma, Legionella, Chlamydia, Mycobacteria, Haemophilus influenzae* *Streptococcus, Staphylococcus*	Neutropenia, 7–12 days post-chemotherapy Skin infections

Table 3 Differentials for pulmonary infiltrates found in childhood malignancy

Pulmonary infiltrate	Differentials/causes
Local	Infection—bacterial (early) or fungal (late) Tumour Pulmonary embolus
Diffuse	Systemic disease infiltrate (Langerhan cell histiocytosis, leukaemia, lymphoma) Pulmonary haemorrhage Cardiogenic and non-cardiogenic pulmonary oedema Pulmonary leukostasis Diffuse alveolar damage Viral pneumonia Drug or radiation toxicity
Late	Immune reconstitution resulting in fibrosis Pneumocystosis

In a neutropenic child, pulmonary infections can be subclinical due to immune failure to mount an inflammatory exudative response [39, 43, 44]. Chest radiography can also be normal, with studies suggesting it is only useful for evaluating a symptomatic child or monitoring treatment response [43, 45]. While bronchoalveolar lavage is a valuable diagnostic tool, it may be of less value if patients have already commenced empirical broad-spectrum antimicrobials [46]. CT-guided fine-needle biopsy can also play a role; however, the gold standard remains thoracoscopic or open lung biopsy [47]. This is usually reserved for diagnostically challenging cases that are non-responsive to therapy. Of note, a wide range of differentials of pulmonary infiltrates can also mimic infections (Table 3) [48].

While respiratory infections are a common cause of fevers in children with cancer, their long-term pulmonary sequelae remains unclear. In childhood leukaemia survivors, reduced lung volumes and impaired exercise capacity have been correlated with recurrent chest infections [49]. Impaired cellular and humoral immune function have also been found to persist >1 year post-therapy depending on treatment intensity [44, 50].

Non-Infectious Complications

Chemotherapy

The respiratory system is particularly susceptible to drug toxicity during childhood due to ongoing physiological development, its rich vascularity and large contact surface area. As summarised in Table 4, the presentation and pathogenesis of injury varies with specific drugs but is generally hypothesised to arise from several key mechanisms: (1) oxidative injury to endothelium and pneumocytes, (2) cytokine induction and inflammation, (3) proteinolytic destruction, (4) immune dysregulation and/or (5) idiosyncrasy [35, 55–57].

Pulmonary-toxic chemotherapies can cause acute pulmonary and pleural reactions such as hypersensitivity pneumonitis, pleural effusions and lung infiltrates. Hypersensitivity reactions are most frequently reported with bleomycin and methotrexate and usually manifest as reversible eosinophilic or desquamative interstitial

Table 4 Common chemotherapeutic agents associated with pulmonary complications [2, 51–54]

Drug class	Key agents	Main uses	Pulmonary complication
Antibiotics	Bleomycin Doxorubicin	HD, lymphomas Germ cell tumours	Hypersensitivity pneumonitis, interstitial pneumonitis Pulmonary fibrosis, ARDS
Alkylating agent	Busulfan Melphalan Cyclophosphamide Ifosfamide	BMT BMT Widely used	Late-onset pulmonary fibrosis Early- or late-onset pneumonitis, bronchospasm, diffuse pulmonary haemorrhage
Nitrosoureas	BCNU (carmustine) CCNU (lomustine)	BMT, CNS tumours	Pulmonary fibrosis
Antimetabolite	Methotrexate Mercaptopurine Cytarabine Gemcitabine	ALL, non-HL ALL AML, non-HL HD	Hypersensitivity pneumonitis, interstitial and alveolar infiltrate, pleural effusion Capillary leak syndrome, NCPE NCPE, capillary leakage, diffuse alveolar damage and haemorrhage, ARDS
Plant alkaloids	Vinblastine Vincristine	ALL, lymphoma Low-grade glioma	Bronchospasm Neurotoxicity-related vocal cord paralysis and airway compromise
Newer agents	Rituximab	Lymphoma, post-transplant lymphoproliferative disease	Acute interstitial pneumonia, lung fibrosis
	Transretinoic acid	APL	Retinoic acid syndrome, diffuse pulmonary infiltrate
	Taxanes	Experimental	Interstitial pneumonitis, diffuse alveolar damage Pleural effusion

pneumonitis [48, 55, 58]. However, the most pertinent and concerning pulmonary complications of chemotherapy are interstitial pneumonitis and permanent fibrosis. These have been found to cause premature mortality, impaired diffusion, and limited exercise capacity in adult life [2, 58]. While children may be asymptomatic during treatment, persistent subclinical abnormalities indicate potential for decompensation with ageing [59].

In the absence of pathognomonic findings, drug-induced lung toxicity is a diagnosis of exclusion [1]. Typical features include:

- Clinical signs and symptoms of hypoxaemia, dry cough, crackles, and exertional dyspnoea
- Restrictive pattern on pulmonary function testing and impaired diffusion capacity [56]
- Diffuse alveolar or interstitial infiltrates on CT imaging
- Interstitial thickening, chronic inflammatory cell infiltrate (including eosinophils in hypersensitivity reactions), and type 2 pneumocyte hyperplasia on pathology [2, 35, 51]

Hyperinflation and obstructive defects secondary to airway inflammation and oedema may also be observed [1].

Specific offending agents are difficult to isolate in polytherapeutic regimes. Synergistic toxicity has been observed when specific chemotherapies are combined with radiation therapy (e.g., bleomycin, busulfan) or oxygen (bleomycin). Furthermore, certain drug combinations, particularly nitrosoureas and cyclophosphamides, can potentiate toxicity at lower doses [60].

Management is primarily reactive with cessation of the offending chemotherapy agent and supportive care with bronchodilators, antibiotics, airway clearance and/or supplemental oxygen [2, 61]. Limited evidence suggests corticosteroids may relieve hypersensitivity reactions, though steroid withdrawal must be gradual to avoid reactivation [55, 61]. Early drug-induced pneumonitis is largely reversible, emphasising the importance of lung function monitoring and prompt diagnosis [55, 62]. However, pulmonary function and radiographic abnormalities often persist into adulthood and are associated with premature lung disease and mortality [2, 58, 59, 62].

Bleomycin is a cytotoxic antibiotic used for paediatric lymphomas and germ cell tumours. It is the most widely recognised cause of drug-related lung injury, affecting up to 72% of children treated with bleomycin with a 1–2% mortality [58, 61–66]. Bleomycin has been reported to cause both acute hypersensitivity reactions and late interstitial pneumonitis and fibrosis within 1 year of treatment [55, 67, 68]. Vascular toxicities involving intimal fibrosis and pulmonary hypertension have also been observed [73].

The pathogenesis of bleomycin lung toxicity primarily involves oxidative damage to cell DNA by free radicals from bleomycin-Fe complexes [69–71]. In the absence of its detoxifying enzyme, bleomycin hydrolase [72, 73], bleomycin can accumulate in the lungs to cause proteolysis of lung parenchyma and direct endothelial injury. Subsequent vascular permeability results in interstitial oedema and the formation of hyaline membranes as plasma proteins and fluid enters alveoli [2]. Cytokines (primarily TNF-α, IL-1B and TGF-B) further potentiate endothelial damage and type 1 pneumocyte apoptosis [61, 74, 75]. Finally, inflammatory cell influx

and immune processes lead to fibrosis of the lung parenchyma and bronchi [2]. Tissue pathology has revealed type 2 pneumocyte hyperplasia, haemorrhage and oedema consistent with diffuse alveolar damage [55].

Important iatrogenic risk factors for bleomycin-induced pulmonary toxicity include cumulative doses greater than 400 IU/m^2, concomitant radiotherapy, high-dose oxygen therapy and certain chemotherapies (cyclophosphamide, vincristine, doxorubicin, cisplatin, methotrexate) [62]. Younger children and patients with impaired renal function limiting drug excretion are at greater risk and need to be monitored with higher caution [35, 58, 71, 76].

Patients with acute toxicity typically present with exertional dyspnoea and a dry cough. Reduced DL_{CO} is considered the most sensitive marker of bleomycin-induced fibrosis, where therapy cessation is indicated if <60% of baseline [2, 62]. However, it is important to note that DL_{CO} abnormalities may only become apparent 6 months post-therapy. CT radiography can be a useful adjunct for monitoring disease progression and typically demonstrates fine nodular infiltrates with a bibasilar reticular pattern [55]. While bleomycin injury is generally associated with restrictive defects and impaired diffusion, a recent study in children treated with contemporary, lower-dose bleomycin regimens found hyperinflation and obstructive lung disease to be most common up to 12 years post-diagnosis [2, 65, 66]. It has been hypothesised that these abnormalities could be due to airway inflammation from bleomycin-induced pro-inflammatory cytokines or a bridging process of early fibrosis.

Alkylating agents are a broad class of chemotherapies known to cause chronic lung injury. In children undergoing pre-BMT conditioning, busulfan can cause acute pneumonitis and alveolar haemorrhage but is most recognised for insidious pulmonary fibrosis up to 10 years post-therapy [71, 77–79]. Typical pathological findings include type 2 pneumocyte hyperplasia and lymphocyte and plasma cell infiltrate. Busulfan-induced fibrosis is typically associated with higher mortality as compared to other chemotherapies, though it does not appear to be dose related [80].

Nitrosoureas are alkylating and carbamylating agents with established dose-dependent pulmonary toxicity. Injury occurs in 50% of those with cumulative doses greater than 1500 mg/m^2 and can manifest as early as 1 month into therapy. Late-onset fibrosis has also been reported in 20–30% of BCNU-treated patients [76] and is associated with significant premature mortality [58].

Cyclophosphamide injury occurs through lipid peroxidation of phospholipid membranes and free radical formation like bleomycin [71]. Toxicity predominantly presents as early-onset pneumonitis within 6 months of exposure and is reversible with drug cessation and steroid therapy [2, 58]. Less than 1% of patients exhibit late-onset pneumonitis that progresses to fibrosis [35].

Surgery

Surgical interventions for lung tumours include pneumectomy, lobectomy, pulmonary metastasectomy and wedge resection [81–83]. Few studies to date have examined post-surgical pulmonary dysfunction in the context of paediatric malignancies. However, virtually all paediatric case series demonstrate good

long-term outcomes even with aggressive surgery in early childhood [84–86]. It is hypothesised that preserved lung function and capacity post-resection are due to hyperplastic compensatory mechanisms and hyperinflation of remaining tissue [87–89].

Complications of thoracic surgery, however, may include irreversible airway obstruction due to dysanapsis [84, 90], diaphragmatic hernia or phrenic nerve injury [91] and post-pneumonectomy syndrome due to herniation of flexible mediastinal structures into a vacant pleural cavity [88]. Progressive hyperinflation can lead to bronchomalacia and predispose to pulmonary infections [92, 93]. Damage to the chest wall and musculoskeletal deformities, particularly scoliosis, can also restrict thoracic excursion and pulmonary growth and function [94]. Thus, both functional lung testing and imaging are essential in follow-up and management.

Thromboembolic Complications

Pulmonary embolism (PE) is a rare but life-threatening complication that has been reported in 1.9–4.5% of paediatric oncology patients [95–97]. While the etiopathogenesis is difficult to determine, thromboembolic events may be associated with increased thrombin generation with malignancy, tumour emboli from cell lysis, altered haemostasis due to L-asparaginase use, acquired thrombophilia in the early post-transplant period, thrombogenic intravenous hyperalimentation and/or endothelial injury with central line use [98–100]. In children with acute respiratory failure associated with PE, studies suggest prompt thrombolytic therapy is effective for reducing early morbidity [95]. However, asymptomatic and undetected PEs do not appear to adversely affect patient outcomes [97].

Growth and Development

Children undergoing cancer treatment inevitably suffer significant disruption to normal lung growth and development due to surgery, cytotoxic therapy, chronic immunosuppression, prolonged steroid use and nutritional stress [101]. Children are at risk of impaired alveoli development, which can lead to respiratory insufficiency [102, 103]. Abnormal growth of musculoskeletal structures can also decrease chest wall compliance and further restrict pulmonary function [58]. Other respiratory morbidities can be associated with cardiopulmonary compromise, limited exercise tolerance and infections due to delayed immune reconstitution. Notably, studies have found the cumulative incidence of pulmonary morbidities increases with time since diagnosis [59]. This suggests that early childhood injury may cause late-onset respiratory complications and potentially accelerate physiological lung function decline.

Pulmonary Complications of Blood and Bone Marrow Transplantation

Since the first reported successful application of blood and bone marrow transplantation (BMT) to treat leukaemia in 1959 [104], BMT has been increasingly utilised across a range of conditions with high mortality rates [105]. Despite advances in BMT over recent decades [106], pulmonary complications continue to be a significant cause of ongoing morbidity and mortality [101]. Pulmonary complications are estimated to occur in 25% of paediatric post-BMT patients and are associated with a close to 50% increase in risk of mortality [101, 107]. Long-term follow-up studies of BMT survivors have documented the occurrence of both obstructive and restrictive lung disease following transplantation [108–110].

Multiple mechanisms are responsible for post-BMT pulmonary injury. Damage resulting from chemotherapy (including conditioning agents busulfan and cyclophosphamide) [59] has been discussed previously in this chapter, and lung injury resulting from irradiation is described in chapter "Pulmonary Complications of Mental Health Problems". Additional mechanisms through which lung injury occurs include immune-mediated events (e.g., graft-versus-host disease) as well as effects of ongoing immunosuppression [101]. A tri-phasic model of injury for chronic lung injury post-BMT has been proposed, and steps include:

1. Alloantigen recognition occurs and inflammatory cells proliferate.
2. Persistence of the inflammatory phase causes lymphocyte migration into the mucosa of the airways and result in epithelial cell damage.
3. Proliferation of lung fibroblasts then increases production and deposition of collagen [111].

Post-BMT pulmonary complications can be categorised into infectious and non-infectious complications and further separated into early (in the first 100 days post-BMT) and late (after 100 days post-BMT) as shown in Table 5 and Fig. 2. Infectious

Table 5 Infectious and non-infectious pulmonary complications post-BMT according to timing post-transplantation [112, 113]

	Infectious complications	Non-infectious complications
0–100, days, early-, post-BMT	Bacterial infections Fungal infections Pneumocystis jirovecii New community viral infections Viral reactivation—cytomegalovirus (CMV), Epstein-Barr virus (EBV)	Acute graft-versus-host disease Mucositis Pulmonary oedema Idiopathic pneumonia syndrome Pulmonary veno-occlusive disease
Late >100 days post-BMT	Late viral infections—adenovirus, HHV-6, human metapneumovirus (HMPV) Mycobacterial disease Atypical pneumonia—Legionella	Graft-versus-host disease (GVHD) Interstitial lung disease Post-transplant lymphoproliferative disease (PTLD) Bronchiolitis obliterans syndrome (BOS)

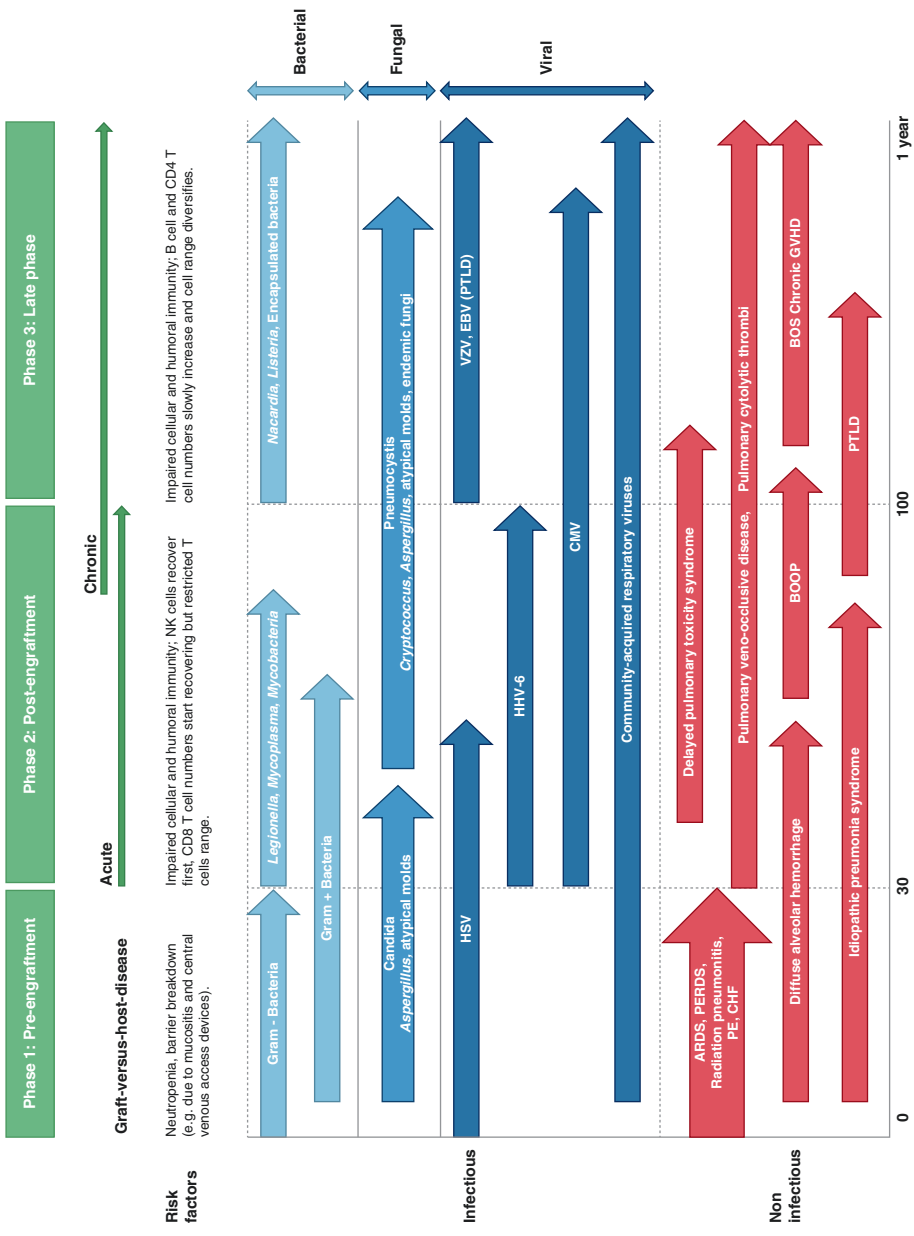

Fig. 2 Pulmonary complications post-BMT categorised to site of injury [109, 114]

complications play an important role in the first months following transplantation, and non-infectious aetiologies play a more prominent role in the months and years after BMT [101]. Another classification system is based on the site of lung injury: lung parenchyma, airway epithelium and vascular endothelium as shown in Fig. 3 [101].

Infectious Complications and Their Relationship to Immune Function

Infectious complications are common post-BMT and can occur in allogeneic and autologous recipients. However, they are more common in allogeneic transplant recipients, and this is believed to be secondary to GVHD and immunosuppressive medication use [115]. Additional known risk factors for infection post-BMT include allogeneic transplant, HLA mismatch, more advanced disease prior to BMT, unrelated donors, immunosuppression, high-dose chemotherapy/radiotherapy for conditioning and delayed engraftment [106].

The infectious complications occurring in post-transplant can be classified by time post-transplant according to the following three phases:

1. Phase 1—The pre-engraftment stage (up to 30 days post-BMT) includes the time in which the neutrophil count recovers.
2. Phase 2—Post-engraftment phase (30–100 days post-BMT).
3. Phase 3—The late phase (>100 days post-BMT) [106, 112, 115].

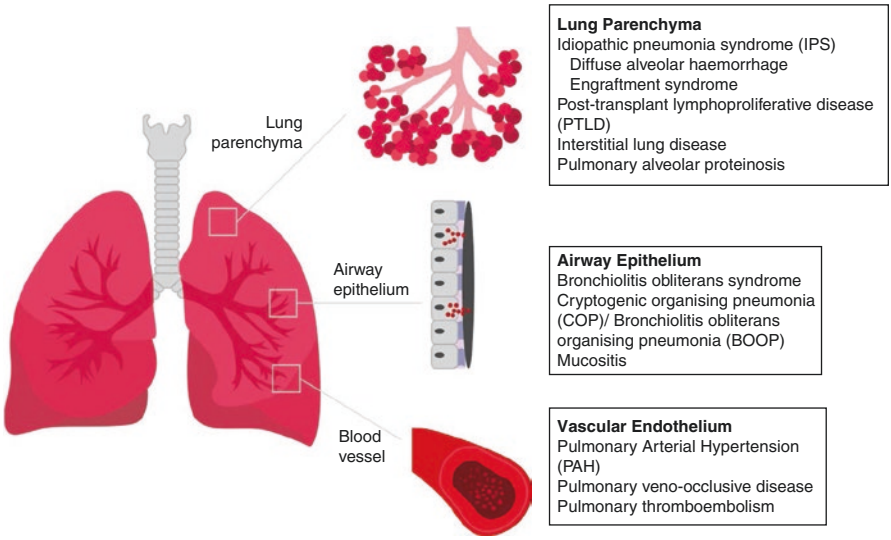

Fig. 3 Timeline of infectious and non-infectious complications post-BMT. Figure adapted from [106, 115, 116]

During the pre-engraftment phase, neutropenia and interruption of the mucocutanous barrier place patients at risk of bacteraemia as well as fungal infections (mould and yeast species) [112, 115]. *Pseudomonas aeruginosa* and *Klebsiella pneumoniae* are important gram-negative organisms, which causes bacteraemia in the pre-engraftment stage. *Staphylococcus aureus*, *Streptococcus viridans* and *Enterococcus* spp. are the common gram-positive organisms seen in this phase [115, 117].

Infections during the post-engraftment phase are predominately related to deficiencies in cell-mediated immunity. Additional risk factors are graft-versus-host disease and immunosuppressive therapy. The major pathogens during this phase are the herpes viruses (especially CMV and EBV), *Pneumocystis jirovecii* and *Aspergillus* species.

The late phase involves gradual immune system rebuilding as well as the tapering of immunosuppressive agents [112]. During this time the primary pathogens are CMV, EBV, adenovirus and encapsulated bacteria (e.g., *Streptococcus pneumoniae*). GVHD severity is again a risk factor for infection in this phase [106]. Though opportunistic infections rarely occur late post-BMT, cases are reported which suggests that transplantation itself (in the absence of GVHD or immunosuppression) can cause long-term immune dysfunction [115]. One of the factors influencing this is that for restoration of humoral immune function, post-BMT rebuilding of stores of naïve B cells and memory B cells is necessary. Hence all BMT patients are at risk of opportunistic infections from encapsulated bacteria and viruses for up to 1 year post-BMT [115].

Non-Infectious Complications

Mucositis

Oral mucositis is a well-known and common early complication affecting the majority of patients undergoing BMT [112]. Mechanisms resulting in development of mucositis include intensive chemotherapy, irradiation, bacterial colonisation, increased inflammatory cytokine and oxidative stress [118]. Compromised mucociliary clearance then leads to the development of respiratory pathology such as sinusitis, oropharyngeal haemorrhage and aspiration pneumonia. In more severe cases, it can result in upper airway obstruction due to laryngeal or epiglottic oedema [112].

Pulmonary Oedema

Pulmonary oedema is a common post-BMT complication and typically occurs in the second or third week post-transplantation [113]. Possible mechanisms for development include increased hydrostatic pressure (from intravenous rehydration or parenteral nutrition), cardiac dysfunction (anthracyclines), nephrotoxicity (cyclosporin), increased pulmonary capillary permeability (sepsis) or pulmonary toxicity

(chemotherapy or irradiation) [112]. Clinical findings are typical of those seen in pulmonary oedema affecting non-BMT patients dyspnoea, tachypnoea and hypoxia. Radiography may show bilateral infiltrates, Kerley B lines and pleural effusions. Diuresis remains the mainstay of treatment [113].

Immune-Mediated Phenomena

Idiopathic pneumonia syndrome (IPS) typically occurs in the peri-engraftment period, weeks to months after BMT [114]. The definition of IPS has recently been updated in an American Thoracic Society (ATS) Research Statement [114]. The ATS now defines IPS as "an idiopathic syndrome of pneumopathy after BMT, with evidence of widespread alveolar injury and in which infectious aetiologies and cardiac dysfunction, acute renal failure or iatrogenic fluid overload have been excluded" [114]. The clinical presentation of IPS is with dry cough, hypoxia and increasing dyspnoea. The incidence in paediatric BMT is estimated at 5–10%, and the reported mortality approaches 75% [119, 120]. The pathophysiology of IPS is still not well understood; however, the most likely factors at play are cytotoxic and immune-mediated insults to the lungs [114]. Biopsy is often not possible due to the clinical instability of patients as well as the high mortality risk of the procedure in early transplant [113, 114]. Current treatment includes supportive care and systemic corticosteroid therapy [101, 114].

Clinical entities included in the IPS definition are acute interstitial pneumonitis (AIP), diffuse alveolar haemorrhage (DAH) and peri-engraftment respiratory distress syndrome (PERDS) [101, 114]. DAH begins in the pre-engraftment period (most commonly in the second or third week) [113], and a higher rate of DAH is seen in patients with mucopolysaccharidosis (MPS) [118]. Typical clinical features are increasing dyspnoea, dry cough, and hypoxaemia [113]. Fevers may or may not occur. Bronchoalveolar lavage (BAL) reveals increasingly blood-stained fluid; however, haemoptysis is not typically seen [114]. PERDS develops in the first 5 days post-engraftment during neutrophil recovery [114] [121]. Classically patients present with fever, rash and hypoxaemia and dyspnoea due to non-cardiac pulmonary oedema [121]. PERDS has been observed in non-myeloablative regimens that avoid conditioning-associated toxicities. This would suggest that white cell recovery itself and the associated release of soluble factors are implicated in the aetiology of PERDS [121].

Graft-versus-host disease (GVHD), an immune-mediated disease, plays an important role in complications in multiple organ systems in BMT recipients [122]. Lung biopsy is not often performed in BMT patients, and therefore the extent of GVHD and level of pulmonary tissue damage are not as clearly understood as that of other organ systems [122]. Historically the lungs were not believed to be a typical target for acute GVHD; however, data now reveals that this is the case for a subgroup of patients [122]. Recent National Institute of Health (NIH) working groups have sought to better define lung chronic GVHD [123, 124]. Previously, the only diagnostic pulmonary manifestation of cGVHD was biopsy-proven constric-

tive bronchiolitis obliterans (CBO); however, bronchiolitis obliterans syndrome (BOS), a clinical entity, is now included in the NIH diagnostic criteria for lung cGVHD [123].

BOS is the most common late pulmonary complication and the most common obstructive lung disease in BMT patients [109, 110, 112]. BOS occurs in 4–9% of the paediatric post-BMT population [109] with mortality reported to range from 11% to 67% [109, 125]. Symptoms of BOS typically present months after BMT and include cough, wheeze and exertional dyspnoea [109, 125]. The diagnosis of BOS is largely based on high-resolution computed tomography (HRCT) findings (air trapping and mosaic attenuation) and an obstructive pattern on pulmonary function testing (PFTs). Confirmatory lung biopsy is not commonly required [101, 112]. The proposed NIH criteria for lung GVHD are:

1. FEV1/FVC < lower limit of normal
2. FEV 1 < lower limit of normal with ≥10% decline over less than 2 years
3. Absence of respiratory infection
4. Evidence of gas trapping on PFTs or air trapping, small airway thickening or bronchiectasis on HRCT

In the presence of distinctive GVHD of another organ system, the fourth criteria does not need to be met. If BOS is the only manifestation of cGVHD and no other organ system is involved, then a lung biopsy is necessary for diagnosis [123].

CBO is a pathological diagnosis and is otherwise known as bronchiolitis obliterans or obliterate bronchiolitis by clinicians [126]. It is caused by fibrosis and subsequent obliteration of the peripheral airway lumen due to insults such as viral infections, immune reactions from transplanted immune cells and drug toxicity [101]. Risk factors for development in post-BMT populations include chronic graft-versus-host disease (cGVHD), pre-transplant conditioning (e.g., busulfan), early viral infections and advanced age of recipient [112]. Treatment involves immunosuppression using oral and inhaled corticosteroids. Other medications which may have a role include azithromycin used for its anti-inflammatory properties and monoclonal antibodies such as rituximab [112]. A wide range of non-steroidal immunosuppressive agents have also been used including azathioprine, mycophenolate mofetil, calcineurin inhibitors, imatinib, and etanercept [127]. In treatment-resistant disease, lung transplantation has been used [109].

In CBO the fibrotic obliteration of the bronchiolar airways begins externally to the airway lumen resulting in concentric constriction and finally obliteration of the airway lumen [126]. Hence CBO is a peri-bronchiolar fibrotic process, and it can be a patchy disease making biopsy difficult [126]. While the clinical BOS classification includes CBO, BOS also encompasses other pathological entities such as lymphocytic bronchiolitis (LB) [124, 128]. In LB, lymphocytic inflammation occurs around and infiltrates the peripheral airways; however, there is no sub-epithelial fibrosis. It has been proposed that LB may be an earlier stage in the development of CBO from several differing underlying disorders including infection [129]. CBO and LB patients present with similar clinical symptoms and have similar pulmonary function; however, those with LB respond better to treatment [128]. Bronchiolitis

obliterans with organising pneumonia (BOOP), now also called cryptogenic organising pneumonia (COP), is a separate clinical and histological entity and is described later in this chapter [124].

Post-transplant lymphoproliferative disorder (PTLD) is a potentially fatal complication of both BMT and solid organ tumours. The risk of PTLD in BMT is lower than that in solid organ transplant, and the incidence is reported to be 0.5–1% [122, 130]. It is most commonly reported in allogeneic transplant recipients, and risk factors are HLA mismatch, T-cell-depleted grafts and EBV-seronegative recipients matched with EBV-seropositive donors [131]. Conditioning protocols that result in T-cell depletion and in turn cause uninhibited EBV-driven B-cell production are implicated in PTLD. PTLD can be classified into four pathogenic categories:

1. Early lesions including reactive plasmacytic hyperplasia (PH) and infectious mononucleosis (IM)-like PTLD
2. Polymorphic lesions which show disruption of nodal architecture or a destructive extra-nodal mass
3. Monomorphic PTLD which can be divided into B-cell or T-cell neoplasms
4. Hodgkin lymphoma (HL) which is an unusual form of PTLD with histology similar to classic HL [132]

The clinical presentation is typical in the first year of BMT, and monitoring of EBV viral load is important in BMT patient surveillance. Imaging often shows nodular lesions on chest X-ray or CT scan [112]. The first-line mainstay of PTLD treatment is the reduction in immunosuppression. Additional therapeutic measures typically used are anti-B-cell immunotherapy (rituximab), chemotherapy, radiotherapy and intravenous immunoglobulin [132].

Endothelial Injury

Chemotherapy agents and radiation therapy used in conditioning pre-transplantation can cause vascular inflammation and endothelial activation [133]. Endothelial activation can in turn contribute to the downregulation of anticoagulant (e.g., antithrombin, protein C and S) and anti-inflammatory molecules resulting in thrombosis and fibrogenesis [134]. Endothelial damage causes a reduction in the production of endogenous vasodilators (e.g., nitric oxide and prostaglandin I_2) and hence results in vasoconstriction [135].

Pulmonary hypertension (PH) post-BMT was first described in 1984 and has been subsequently described in a number of case series and is believed to be rare; however, the incidence in current BMT recipients is unknown [136]. The two entities of PH commonly described are pulmonary arterial hypertension (PAH) and pulmonary veno-occlusive disease (PVOD) [137]. PH in the setting of BMT may also occur secondary to left-sided heart disease, interstitial lung disease, thromboembolism, and hypoxia [138]. It is most described in allogeneic transplant for malignant infantile osteopetrosis [139].

Pulmonary arterial hypertension (PAH) is more commonly reported and involves the pulmonary arterioles. Clinically patients may be asymptomatic early in disease or may report non-specific symptoms such as fatigue or exertional dyspnoea. Pulmonary vasoconstriction plays an important early role, and a progressive increase of pulmonary arterial vascular resistance causes right ventricular failure [136, 138]. On histopathology, vascular proliferation and remodelling is seen in all three layers of the arterial wall [136, 140]. PAH develops in the setting of pulmonary arteriole intimal damage, which in turn leads to smooth muscle hypertrophy and fibroblast activation.

Veno-occlusive disease is one of most significant complications arising post-BMT. Pulmonary veno-occlusive disease (PVOD) is rare in comparison to hepatic veno-occlusive disease (VOD) and is often only diagnosed post-mortem [134]. In hepatic VOD in its severest form, there is often concomitant PVOD. The pathophysiology of PVOD involves post-capillary pulmonary venular obstruction resulting in pulmonary vascular congestion and right ventricular failure. PVOD symptoms typically occur weeks to months post-BMT with progressive dyspnoea being a common early symptom. Symptoms of right heart failure develop as pulmonary hypertension worsens. Cytotoxic chemotherapy and irradiation are considered the most significant risk factors for the endothelial injury that develops in PVOD [134].

Radiographic findings on chest X-ray include pulmonary vascular congestion, Kerley B lines and pleural effusions. Bilateral infiltrates may also occur [141]. C.T chest findings include interlobular septal thickening, dilated central pulmonary arteries, and ground-glass opacification [145].

The classically described features of PVOD are a normal or low pulmonary artery wedge pressure (PAWP) on right heart catheterisation [134]. Severe pulmonary artery hypertension, pulmonary oedema on chest X-ray and normal PAWP are characteristics of PVOD [142, 143]. However, not all patients fulfil the criteria, and lung biopsy is the gold standard for diagnosis [144]. Current therapy is limited; treatment options include vasodilators, defibrotide, and corticosteroids [134]. In severe PVOD, lung transplantation is considered definitive treatment; however, recurrence has been reported, and this would suggest a multifactorial aetiology with environmental factors, genetics, and perhaps systemic endothelial dysfunction plays a role in the development of PVOD [145].

Restrictive Lung Disease/Interstitial Lung Disease

Numerous studies have demonstrated the development of restrictive lung disease in post-BMT patients. The restrictive pattern on pulmonary function testing is either an isolated finding or occurs in the presence of a reduced DL_{CO} [108, 146–150]. These findings are typically seen soon after bone marrow transplantation, then improve and stabilise over 12–24 months; however, lung function does not return to pre-transplant results [108, 147, 149, 151]. In the majority of cases, respiratory symptoms and imaging findings are not associated with the pulmonary function

abnormalities [147, 149, 150, 152]. The proposed mechanisms of injury involve interstitial inflammation and fibrosis resulting from irradiation, chemotherapy, immunological impairment and recurrent respiratory infections with remodelling post-injury leading to partial resolution [109].

In the setting of restrictive lung disease with clinical symptoms post-BMT, it is often difficult to determine aetiology and interstitial lung disease; infectious pneumonitis and cryptogenic organising pneumonia (COP) all need to be considered. Alkylating agents, cyclophosphamide, methotrexate and busulfan are all known to be risk factors for developing pulmonary fibrosis. Treatment with steroid may affect an improvement in clinical symptoms; however, a thorough diagnostic workup, including excluding infectious pathology, is advised [112].

In COP (previously known as BOOP) histology reveals patchy areas of consolidation and plugs of granulation tissue in the respiratory bronchioles and alveolar ducts causing chronic interstitial inflammation [124]. COP is associated with both acute and chronic GVHD. Chest radiography typically shows patchy infiltrates, and pulmonary function testing is consistent with a restrictive pattern [153]. COP often improves with corticosteroid therapy; however, the exclusion of infectious pathology is important and may necessitate bronchoscopy and alveolar lavage and in some cases lung biopsy [112].

Long-Term Pulmonary Follow-Up Recommendations

Long-term follow-up protocols are an essential component of survivorship care as a greater proportion of childhood cancer patients progress through adult life and physiological pulmonary decline.

The Children's Oncology Group long-term follow-up guidelines (2013) recommend pulmonary function testing (including spirometry and DL_{CO}) at least once and 2 years post-therapy, in children treated with bleomycin, nitrosoureas, thoracic surgery, and chest radiation.

For paediatric BMT survivors, ongoing follow-up with routine pulmonary function testing (spirometry, plethysmography, and DL_{CO}) is recommended. National Cancer Institute recommendations include pulmonary function testing post-paediatric allogeneic BMT, six monthly for the first 2 years post-transplant then yearly [154]. The role of newer respiratory function tests such as multiple-breath washout and forced oscillation technique is also being evaluated in both paediatric and adult post-BMT populations [155, 156].

While the long-term outcomes of subclinical abnormalities in pulmonary function testing are not yet known, this will be an important clinical issue for patients into adulthood. Long-term sequelae of other known pulmonary insults such as respiratory infections and potential prophylactic and therapeutic interventions remain critical areas for future research.

References

1. Meyer S, Reinhard H, Gottschling S, Nunold H, Graf N. Pulmonary dysfunction in pediatric oncology patients. Pediatr Hematol Oncol. 2004;21(2):175–95. PubMed PMID: 15160517. Epub 2004/05/27. eng.
2. Turcios NL, Fink RJ. Pulmonary manifestations of pediatric diseases. Philadelphia: Elsevier Health Sciences; 2009.
3. Hildebrand F, Rosenow EC III, Habermann TM, Tazelaar HD. Pulmonary complications of leukemia. Chest. 1990;98(5):1233–9.
4. McCahon E. Lung tumours in children. Paediatr Respir Rev. 2006;7(3):191–6. PubMed PMID: 16938641. Epub 2006/08/30. eng.
5. Dishop MK, Kuruvilla S. Primary and metastatic lung tumors in the pediatric population: a review and 25-year experience at a large children's hospital. Arch Pathol Lab Med. 2008;132(7):1079–103. PubMed PMID: 18605764.
6. McCarville MB. Malignant pulmonary and mediastinal tumors in children: differential diagnoses. Cancer Imaging. 2010;10(1A):S35–41. PubMed PMID: PMC2967153.
7. Al-Qahtani AR, Di Lorenzo M, Yazbeck S. Endobronchial tumors in children: Institutional experience and literature review. J Pediatr Surg. 2003;38(5):733–6.
8. Lichtman MA, Rowe JM. Hyperleukocytic leukemias: rheological, clinical, and therapeutic considerations. Blood. 1982;60(2):279–83. PubMed PMID: 7046844. Epub 1982/08/01. eng.
9. Bunin NJ, Pui C-H. Differing complications of hyperleukocytosis in children with acute lymphoblastic or acute nonlymphoblastic leukemia. J Clin Oncol. 1985;3(12):1590–5.
10. Vernant JP, Brun B, Mannoni P, Dreyfus B. Respiratory distress of hyperleukocytic granulocytic leukemias. Cancer. 1979;44(1):264–8. PubMed PMID: 287551. Epub 1979/07/01. eng.
11. Carroll WL, Finlay JL. Cancer in children and adolescents. London: Jones & Bartlett Learning; 2010.
12. Porcu P, Cripe LD, Ng EW, Bhatia S, Danielson CM, Orazi A, et al. Hyperleukocytic leukemias and leukostasis: a review of pathophysiology, clinical presentation and management. Leuk Lymphoma. 2000;39(1–2):1–18.
13. Cuttner J, Conjalka MS, Reilly M, Goldberg J, Reisman A, Meyer RJ, et al. Association of monocytic leukemia in patients with extreme leukocytosis. Am J Med. 1980;69(4):555–8. PubMed PMID: 6932815. Epub 1980/10/01. eng.
14. Lichtman MA, Weed RI. Peripheral cytoplasmic characteristics of leukocytes in monocytic leukemia: relationship to clinical manifestations. Blood. 1972;40(1):52–61. PubMed PMID: 4504250. Epub 1972/07/01. eng.
15. Lowe EJ, Pui C-H, Hancock ML, Geiger TL, Khan RB, Sandlund JT. Early complications in children with acute lymphoblastic leukemia presenting with hyperleukocytosis. Pediatr Blood Cancer. 2005;45(1):10–5.
16. Lester TJ, Johnson JW, Cuttner J. Pulmonary leukostasis as the single worst prognostic factor in patients with acute myelocytic leukemia and hyperleukocytosis. Am J Med. 1985;79(1):43–8. PubMed PMID: 3860006. Epub 1985/07/01. eng.
17. Tanaka N, Matsumoto T, Miura G, Emoto T, Matsunaga N, Satoh Y, et al. CT findings of leukemic pulmonary infiltration with pathologic correlation. Eur Radiol. 2002;12(1):166–74.
18. Van Buchem M, Wondergem J, Kool L, Te Velde J, Kluin P, Bode P, et al. Pulmonary leukostasis: radiologic-pathologic study. Radiology. 1987;165(3):739–41.
19. Aswanetmanee P, Edriss H, Limsuwat C. Pulmonary leukostasis as a complication of leukemia. Southwest Respir Crit Care Chronicles. 2015;3(10):17–22.
20. Hijiya N, Metzger ML, Pounds S, Schmidt JE, Razzouk BI, Rubnitz JE, et al. Severe cardiopulmonary complications consistent with systemic inflammatory response syndrome caused by leukemia cell lysis in childhood acute myelomonocytic or monocytic leukemia. Pediatr Blood Cancer. 2005;44(1):63–9.
21. Azoulay É, Fieux F, Moreau D, Thiery G, Rousselot P, Parrot A, et al. Acute monocytic leukemia presenting as acute respiratory failure. Am J Respir Crit Care Med. 2003;167(10):1329–33.

22. Azoulay E, Canet E, Raffoux E, Lengline E, Lemiale V, Vincent F, et al. Dexamethasone in patients with acute lung injury from acute monocytic leukaemia. Eur Respir J. 2012;39(3):648–53. PubMed PMID: 21828031. Epub 2011/08/11. eng.
23. Tryka AF, Godleski JJ, Fanta CH. Leukemic cell lysis pneumonopathy. A complication of treated myeloblastic leukemia. Cancer. 1982;50(12):2763–70. PubMed PMID: 6958352. Epub 1982/12/15. eng.
24. Stover DE, Kaner RJ. Pulmonary complications in cancer patients. CA Cancer J Clin. 1996;46(5):303–20.
25. Soares FA, Landell GAM, Cardoso MCM. Pulmonary leukostasis without hyperleukocytosis: a clinicopathologic study of 16 cases. Am J Hematol. 1992;40(1):28–32.
26. Kovalski R, Hansen-Flaschen J, Lodato RF, Pietra GG. Localized leukemic pulmonary infiltrates. Diagnosis by bronchoscopy and resolution with therapy. Chest. 1990;97(3):674–8.
27. Braier J, Latella A, Balancini B, Castaños C, Rosso D, Chantada G, et al. Outcome in children with pulmonary Langerhans cell histiocytosis. Pediatr Blood Cancer. 2004;43(7): 765–9.
28. Ha SY, Helms P, Fletcher M, Broadbent V, Pritchard J. Lung involvement in Langerhans' cell histiocytosis: prevalence, clinical features, and outcome. Pediatrics. 1992;89(3):466–9.
29. Kilborn TN, Teh J, Goodman TR. Paediatric manifestations of Langerhans cell histiocytosis: a review of the clinical and radiological findings. Clin Radiol. 2003;58(4):269–78.
30. Smets A, Mortelé K, Praeter DG, François O, Benoit Y, Kunnen M. Pulmonary and mediastinal lesions in children with Langerhans cell histiocytosis. Pediatr Radiol. 1997;27(11):873–6.
31. Picarsic J, Jaffe R. Nosology and pathology of Langerhans cell histiocytosis. Hematol Oncol Clin North Am. 2015;29(5):799–823.
32. Lehrnbecher T, Foster C, Vazquez N, Mackall CL, Chanock SJ. Therapy-induced alterations in host defense in children receiving therapy for cancer. J Pediatr Hematol Oncol. 1997;19(5):399–417. PubMed PMID: 9329461. Epub 1997/11/05. eng.
33. Wiegering V, Schlegel PG, Winkler B. Immune function in newly diagnosed children with malignancy. J Pediatr Hematol Oncol. 2012;34(7):559–64. PubMed PMID: 22735887. Epub 2012/06/28. eng.
34. Martin Ibanez I, Arce Casas A, Cruz Martinez O, Estella Aguado J, Martin Mateos MA. Humoral immunity in pediatric patients with acute lymphoblastic leukaemia. Allergol Immunopathol. 2003;31(6):303–10. PubMed PMID: 14670284. Epub 2003/12/13. eng.
35. Jenney M. Malignant disease and the lung. Paediatr Respir Rev. 2000;1(3):279–86.
36. Lehrnbecher T, Phillips R, Alexander S, Alvaro F, Carlesse F, Fisher B, et al. Guideline for the management of fever and neutropenia in children with cancer and/or undergoing hematopoietic stem-cell transplantation. J Clin Oncol. 2012;30(35):4427–38.
37. El Saleeby CM, Somes GW, DeVincenzo JP, Gaur AH. Risk factors for severe respiratory syncytial virus disease in children with cancer: the importance of lymphopenia and young age. Pediatrics. 2008;121(2):235–43. PubMed PMID: 18245413. Epub 2008/02/05. eng.
38. Hakim H, Dallas R, Zhou Y, Pei D, Cheng C, Flynn PM, et al. Acute respiratory infections in children and adolescents with acute lymphoblastic leukemia. Cancer. 2016;122(5):798–805. PubMed PMID: 26700662. Pubmed Central PMCID: PMC4764417. Epub 2015/12/25. eng.
39. Furuya MEY, González-Martínez F, Vargas MH, Miranda-Novales MG, Bernáldez-Ríos R, Zúñiga-Vázquez G. Guidelines for diagnosing and treating pulmonary infiltrates in children with acute leukaemia: impact of timely decisions. Acta Paediatr. 2008;97(7):928–34.
40. Specchia G, Pastore D, Carluccio P, Mele G, Montagna MT, Liso A, et al. Pneumonia in acute leukemia patients during induction therapy: experience in a single institution. Leuk Lymphoma. 2003;44(1):97–101. PubMed PMID: 12691147. Epub 2003/04/15. eng.
41. Erdur B, Ylmaz S, Ören H, Demircioglu F, Çakmakç H, Irken G. Evaluating pulmonary complications in childhood acute leukemias. J Pediatr Hematol Oncol. 2008;30(7):522–6.
42. Keengwe I, Stansfield F, Eden O, Nelhans N, Dearlove O, Sharples A. Paediatric oncology and intensive care treatments: changing trends. Arch Dis Child. 1999;80(6):553–5. PubMed PMID: PMC1717963.

43. Phillips B, Wade R, Westwood M, Riley R, Sutton AJ. Systematic review and meta-analysis of the value of clinical features to exclude radiographic pneumonia in febrile neutropenic episodes in children and young people. J Paediatr Child Health. 2012;48(8):641–8. PubMed PMID: 22050289. Epub 2011/11/05. eng.
44. Mustafa MM, Buchanan GR, Winick NJ, McCracken GH, Tkaczewski I, Lipscomb M, et al. Immune recovery in children with malignancy after cessation of chemotherapy. J Pediatr Hematol Oncol. 1998;20(5):451–7.
45. Roberts SD, Wells GM, Gandhi NM, York NR, Maron G, Razzouk B, et al. Diagnostic value of routine chest radiography in febrile, neutropenic children for early detection of pneumonia and mould infections. Support Care Cancer. 2012;20(10):2589–94. PubMed PMID: 22278307. Epub 2012/01/27. eng.
46. Stokes DC, Shenep JL, Parham D, Bozeman PM, Marienchek W, Mackert PW. Role of flexible bronchoscopy in the diagnosis of pulmonary infiltrates in pediatric patients with cancer. J Pediatr. 1989;115(4):561–7.
47. Girmenia C, Martino P. Pulmonary infections complicating hematological disorders. Semin Respir Crit Care Med. 2005;26(5):445–57. PubMed PMID: 16267697. Epub 2005/11/04. eng.
48. Nucci M, Nouér SA, Anaissie E. Distinguishing the causes of pulmonary infiltrates in patients with acute leukemia. Clin Lymphoma Myeloma Leuk. 2015;15:S98–S103.
49. Jenney ME, Faragher EB, Jones PHM, Woodcock A. Lung function and exercise capacity in survivors of childhood leukaemia. Med Pediatr Oncol. 1995;24(4):222–30.
50. Ek T, Mellander L, Andersson B, Abrahamsson J. Immune reconstitution after childhood acute lymphoblastic leukemia is most severely affected in the high risk group. Pediatr Blood Cancer. 2005;44(5):461–8.
51. Charpidou AG, Gkiozos I, Tsimpoukis S, Apostolaki D, Dilana KD, Karapanagiotou EM, et al. Therapy-induced toxicity of the lungs: an overview. Anticancer Res. 2009;29(2):631–9. PubMed PMID: 19331213. Epub 2009/04/01. eng.
52. Vahid B, Marik PE. Pulmonary complications of novel antineoplastic agents for solid tumors. Chest. 2008;133(2):528–38.
53. Andre N, Meille C. Taxanes in paediatric oncology: and now? Cancer Treat Rev. 2006;32(2):65–73. PubMed PMID: 16497442. Epub 2006/02/25. eng.
54. Latiff ZA, Kamal NA, Jahendran J, Alias H, Goh BS, Zakaria SZS, et al. Vincristine-induced vocal cord palsy: case report and review of the literature. J Pediatr Hematol Oncol. 2010;32(5):407–10.
55. Dhakal S, Weiner D, Schwartz C, Constine LS. Pulmonary effects of antineoplastic therapy. In: Schwartz C, Hobbie W, Constine L, Ruccione K, editors. Survivors of childhood and adolescent cancer. Cham: Springer; 2015. p. 201–27.
56. Matsuno O. Drug-induced interstitial lung disease: mechanisms and best diagnostic approaches. Respir Res. 2012;13(1):39. PubMed PMID: PMC3426467.
57. Borzone G, Moreno R, Urrea R, Meneses M, OyarzÚN M, Lisboa C. Bleomycin-induced chronic lung damage does not resemble human idiopathic pulmonary fibrosis. Am J Respir Crit Care Med. 2001;163(7):1648–53.
58. Huang T-T, Hudson MM, Stokes DC, Krasin MJ, Spunt SL, Ness KK. Pulmonary Outcomes in Survivors of Childhood Cancer: A Systematic Review. Chest. 2011;140(4):881–901. PubMed PMID: PMC3904488.
59. Mertens AC, Yasui Y, Liu Y, Stovall M, Hutchinson R, Ginsberg J, et al. Pulmonary complications in survivors of childhood and adolescent cancer. Cancer. 2002;95(11):2431–41.
60. McDonald S, Rubin P, Phillips TL, Marks LB. Injury to the lung from cancer therapy: clinical syndromes, measurable endpoints, and potential scoring systems. Int J Radiat Oncol Biol Phys. 1995;31(5):1187–203. PubMed PMID: 7713782. Epub 1995/03/30. eng.
61. Sleijfer S. Bleomycin-induced pneumonitis. Chest. 2001;120(2):617–24.
62. Mucci GA, Torno LR. Handbook of long term care of the childhood cancer survivor. Boston: Springer; 2015.

63. Azambuja E, Fleck JF, Batista RG, Menna Barreto SS. Bleomycin lung toxicity: who are the patients with increased risk? Pulm Pharmacol Ther. 2005;18(5):363–6. PubMed PMID: 15939315. Epub 2005/06/09. eng.
64. Tantawy AAG, Elbarbary N, Ahmed A, Mohamed NA, Ezz-Elarab S. Pulmonary complications in survivors of childhood hematological malignancies: single-center experience. Pediatr Hematol Oncol. 2011;28(5):403–17.
65. De A, Guryev I, LaRiviere A, Kato R, Wee CP, Mascarenhas L, et al. Pulmonary function abnormalities in childhood cancer survivors treated with bleomycin. Pediatr Blood Cancer. 2014;61(9):1679–84.
66. Kaplan E, Sklar C, Wilmott R, Michaels S, Ghavimi F. Pulmonary function in children treated for rhabdomyosarcoma. Med Pediatr Oncol. 1996;27(2):79–84. PubMed PMID: 8649324. Epub 1996/08/01. eng.
67. White DA, Stover DE. Severe bleomycin-induced pneumonitis. Clinical features and response to corticosteroids. Chest. 1984;86(5):723–8.
68. Chen J, Stubbe J. Bleomycins: towards better therapeutics. Nat Rev Cancer. 2005;5(2):102–12. PubMed PMID: 15685195. Epub 2005/02/03. eng.
69. Hagimoto N, Kuwano K, Nomoto Y, Kunitake R, Hara N. Apoptosis and expression of Fas/Fas ligand mRNA in bleomycin-induced pulmonary fibrosis in mice. Am J Respir Cell Mol Biol. 1997;16(1):91–101.
70. Eigen H, Wyszomierski D. Bleomycin lung injury in children: Pathophysiology and guidelines for management. J Pediatr Hematol Oncol. 1985;7(1):71–8.
71. Cooper JA Jr, White DA, Matthay RA. Drug-induced pulmonary disease. Part 1: cytotoxic drugs. Am Rev Respir Dis. 1986;133(2):321–40. PubMed PMID: 3511808. Epub 1986/02/01. eng.
72. Ohnuma T, Holland JF, Masuda H, Waligunda JA, Goldberg GA. Microbiological assay of bleomycin: inactivation, tissue distribution, and clearance. Cancer. 1974;33(5):1230–8.
73. Lazo JS, Merrill WW, Pham, Lynch TJ, McCallister J, Ingbar D. Bleomycin hydrolase activity in pulmonary cells. J Pharmacol Exp Ther. 1984;231(3):583–8.
74. Sausville EA, Peisach J, Horwitz SB. Effect of chelating agents and metal ions on the degradation of DNA by bleomycin. Biochemistry. 1978;17(14):2740–6.
75. Ortiz LA, Lasky J, Hamilton RF Jr, Holian A, Hoyle GW, Banks W, et al. Expression of TNF and the necessity of TNF receptors in bleomycin-induced lung injury in mice. Exp Lung Res. 1998;24(6):721–43. PubMed PMID: 9839161. Epub 1998/12/05. eng.
76. Weiss RB, Muggia FM. Cytotoxic drug-induced pulmonary disease: update 1980. Am J Med. 1980;68(2):259–66. PubMed PMID: 6153504. Epub 1980/02/01. eng.
77. Limper AH. Chemotherapy-induced lung disease. Clin Chest Med. 2004;25(1):53–64. PubMed Epub 2004/04/06. eng.
78. Oakhill A, Green I, Knowlson G, Cameron A, Shah K, Hill F, et al. Busulphan lung in childhood. J Clin Pathol. 1981;34(5):495–500.
79. Pearl M. Busulfan lung. Am J Dis Child. 1977;131(6):650–2.
80. Abid SH, Malhotra V, Perry MC. Radiation-induced and chemotherapy-induced pulmonary injury. Curr Opin Oncol. 2001;13(4):242–8. PubMed PMID: 11429481. Epub 2001/06/29. eng.
81. Kayton ML. Pulmonary metastasectomy in pediatric patients. Thorac Surg Clin. 2006;16(2):167–83.
82. Fuchs J, Seitz G, Handgretinger R, Schäfer J, Warmann SW. Surgical treatment of lung metastases in patients with embryonal pediatric solid tumors: an update. Semin Pediatr Surg. 2012;21(1):79–87.
83. Meyers RL, Katzenstein HM, Krailo M, McGahren ED, Malogolowkin MH. Surgical resection of pulmonary metastatic lesions in children with hepatoblastoma. J Pediatr Surg. 2007;42(12):2050–6.
84. McBride JT, Wohl MEB, Strieder DJ, Jackson AC, Morton JR, Zwerdling RG, et al. Lung growth and airway function after lobectomy in infancy for congenital lobar emphysema. J Clin Investig. 1980;66(5):962.

85. Spurbeck WW, Davidoff AM, Lobe TE, Rao BN, Schropp KP, Shochat SJ. Minimally invasive surgery in pediatric cancer patients. Ann Surg Oncol. 2004;11(3):340–3. PubMed PMID: 14993031. Epub 2004/03/03. eng.
86. Harting MT, Blakely ML, Jaffe N, Cox CS Jr, Hayes-Jordan A, Benjamin RS, et al. Long-term survival after aggressive resection of pulmonary metastases among children and adolescents with osteosarcoma. J Pediatr Surg. 2006;41(1):194–9.
87. Laros C, Westermann C. Dilatation, compensatory growth, or both after pneumonectomy during childhood and adolescence. A thirty-year follow-up study. J Thorac Cardiovasc Surg. 1987;93(4):570–6.
88. Kreisel D, Krupnick AS, Huddleston CB. Outcomes and late complications after pulmonary resections in the pediatric population. Semin Thorac Cardiovasc Surg. 2004;16(3):215–9.
89. Abel RM, Brown J, Moreland B, Parikh D. Pulmonary metastasectomy for pediatric solid tumors. Pediatr Surg Int. 2004;20(8):630–2. PubMed PMID: 15258816. Epub 2004/07/20. eng.
90. Werner H, Pirie G, Nadel H, Fleisher A, LeBlanc J. Lung volumes, mechanics, and perfusion after pulmonary resection in infancy. J Thorac Cardiovasc Surg. 1993;105(4):737–42.
91. Parisi MT, Fahmy JL, Kaminsky CK, Malogolowkin MH. Complications of cancer therapy in children: a radiologist's guide. Radiographics. 1999;19(2):283–97.
92. Cournard A, Himmelstein A, et al. A follow-up study of the cardiopulmonary function in four young individuals after pneumonectomy. J Thorac Surg. 1947;16(1):30–49. PubMed PMID: 20286102. Epub 1947/02/01. eng.
93. Powell RW, Luck SR, Raffensperger JG. Pneumonectomy in infants and children: the use of a prosthesis to prevent mediastinal shift and its complications. J Pediatr Surg. 1979;14(3):231–7.
94. Westfelt JN, Nordwall A. Thoracotomy and scoliosis. Spine. 1991;16(9):1124–5.
95. Uderzo C, Marraro G, Riva A, Bonanomi E, Vaj P, Marchi P, et al. Pulmonary thromboembolism in leukaemic children undergoing bone marrow transplantation. Bone Marrow Transplant. 1993;11(3):201–3.
96. Lee EY, Kritsaneepaiboon S, Arellano CMR, Grace RF, Zurakowski D, Boiselle PM. Unsuspected pulmonary emboli in pediatric oncology patients: detection with MDCT. Am J Roentgenol. 2010;194(5):1216–22.
97. Marraro G, Uderzo C, Masera G, Marchi P, Castagnini G, Vaj PL. Acute respiratory failure and pulmonary thrombosis in leukemic children. Cancer. 1991;67(3):696–702.
98. Andrew M, David M, Adams M, Ali K, Anderson R, Barnard D, et al. Venous thromboembolic complications (VTE) in children: first analyses of the Canadian Registry of VTE. Blood. 1994;83(5):1251–7.
99. Brandao LR, Kletzel M, Boulad F, Kurtzberg J, Maloney K, Fligman I, et al. A prospective longitudinal multicenter study of coagulation in pediatric patients undergoing allogeneic stem cell transplantation. Pediatr Blood Cancer. 2008;50(6):1240–6.
100. Nowak-Göttl U, Kenet G, Mitchell LG. Thrombosis in childhood acute lymphoblastic leukaemia: epidemiology, aetiology, diagnosis, prevention and treatment. Best Pract Res Clin Haematol. 2009;22(1):103–14.
101. Versluys AB, Bresters D. Pulmonary complications of childhood cancer treatment. Paediatr Respir Rev. 2015;17:63–70.
102. Thurlbeck WM. Postnatal growth and development of the lung 1. Am Rev Respir Dis. 1975;111(6):803–44.
103. Narayanan M, Owers-Bradley J, Beardsmore CS, Mada M, Ball I, Garipov R, et al. Alveolarization continues during childhood and adolescence: new evidence from helium-3 magnetic resonance. Am J Respir Crit Care Med. 2012;185(2):186–91.
104. Thomas ED, Lochte HL Jr, Cannon JH, Sahler OD, Ferrebee JW. Supralethal whole body irradiation and isologous marrow transplantation in man. J Clin Invest. 1959;38:1709–16.
105. Australasian Bone Marrow Transplant Recipient Registry. Australasian Bone Marrow Transplant Recipient Registry: Annual Data Summary 2014. Darlinghurst: ABMTRR; 2015.
106. Tomblyn M, Chiller T, Einsele H, Gress R, Sepkowitz K, Storek J, et al. Guidelines for preventing infectious complications among hematopoietic cell transplantation recipients: a global perspective. Biol Blood Marrow Transplant. 2009;15(10):1143–238.

107. Quigg TC, Kim Y-J, Goebel WS, Haut PR. Lung function before and after pediatric allogeneic hematopoietic stem cell transplantion: a predictive role for DLCO/VA. J Pediatr Hematol Oncol. 2012;34(304–309):304.
108. Bruno B, Souillet G, Bertrand Y, Werck-Gallois MC, So Satta A, Bellon G. Effects of allogeneic bone marrow transplantation on pulmonary function in 80 children in a single paediatric centre. Bone Marrow Transplant. 2004;34(2):143–7. PubMed PMID: 15170172.
109. Gower WA, Collaco JM, Mogayzel PJ Jr. Lung function and late pulmonary complications among survivors of hematopoietic stem cell transplantation during childhood. Paediatr Respir Rev. 2011;11:115–22.
110. Inaba H, Yang J, Pan J, Stokes DC, Krasin MJ, Srinivasan A, et al. Pulmonary dysfunction in survivors of childhood hematologic malignancies after allogeneic hematopoietic stem cell transplantation. Cancer. 2010;116(8):2020–30.
111. Cooke KR, Yanik GA. Lung injury following hematopoietic cell transplantation. In: Forman SJ, Negrin RS, Antin JH, Appelbaum FR, editors. Thomas' hematopoietic cell transplantation. Chichester: Wiley-Blackwell; 2009. p. 1456–72.
112. Michelson PH, Goyal R, Kurland G. Pulmonary complications of haematopoietic cell transplantation in children. Paediatr Respir Rev. 2007;8:46–61.
113. Khurshid I, Anderson LC. Non-infectious pulmonary complications after bone marrow transplantation. Postgrad Med J. 2002;78:257–62.
114. Panoskaltsis-Mortari A, Griese M, Madtes DK, Belperio JA, Haddad IY, Folz RJ, et al. An official American Thoracic Society research statement: noninfectious lung injury after hematopoietic stem cell transplantation: idiopathic pneumonia syndrome. Am J Respir Crit Care Med. 2011;183(9):1262–79. PubMed PMID: 21531955.
115. Coomes SM, Hubbard LLN, Moore BB. Impaired pulmonary immunity post-bone marrow transplant. Immunol Res. 2011;50(1):78–86. PubMed PMID: PMC3310400.
116. Soubani AO, Pandya CM. The spectrum of noninfectious pulmonary complications following hematopoietic stem cell transplantation. Hematol Oncol Stem Cell Ther. 2010;3(3):143–57.
117. Collin BA, Leather HI, Wingard JR, Ramphal R. Evolution, incidence, and susceptibility of bacterial bloodstream isolates from 519 bone marrow transplant patients. Clin Infect Dis. 2001;33(7):947–53.
118. Stiff P. Mucositis associated with stem cell transplantation: current status and innovative approaches to management. Bone Marrow Transplant. 2001;27(Suppl 2):S3–11.
119. Sano H, Kobayashi R, Iguchi A, Suzuki D, Kishimoto K, Yasuda K, et al. Risk factor analysis of idiopathic pneumonia syndrome after allogeneic hematopoietic SCT in children. Bone Marrow Transplant. 2014;49(1):38–41.
120. Sakaguchi H, Takahashi Y, Watanabe N, Doisaki S, Muramatsu H, Hama A, et al. Incidence, clinical features, and risk factors of idiopathic pneumonia syndrome following hematopoietic stem cell transplantation in children. Pediatr Blood Cancer. 2012;58(5):780–4.
121. Gorak E, Geller N, Srinivasan R, Espinoza-Delgado I, Donohue T, Barrett AJ, et al. Engraftment syndrome after nonmyeloablative allogeneic hematopoietic stem cell transplantation: incidence and effects on survival. Biol Blood Marrow Transplant. 2005;11:542–50.
122. Kambham N, Higgins JP, Sundram U, Troxell ML. Hematopoietic stem cell transplantation: graft versus host disease and pathology of gastrointestinal tract, liver, and lung. Adv Anat Pathol. 2014;21(5):301–20.
123. Jagasia MH, Greinix HT, Arora M, Williams KM, Wolff D, Cowen EW, et al. National Institutes of Health Consensus Development Project on Criteria for Clinical Trials in Chronic Graft-versus-Host Disease: I. The 2014 Diagnosis and Staging Working Group Report. Biol Blood Marrow Transplant. 2015;21:389–401.
124. Shulman HM, Cardona DM, Greenson JK, Hingorani S, Horn T, Huber E, et al. NIH Consensus Development Project on Criteria for Clinical Trials in Chronic Graft-versus-Host Disease: II. The 2014 Pathology Working Group Report. Biol Blood Marrow Transplant. 2015;21:589–603.
125. Haddad IY. Stem cell transplantation and lung dysfunction. Curr Opin Pediatr. 2013;25(3):350–6.
126. Epler GR. Diagnosis and treatment of constrictive bronchiolitis. Med Rep. 2010;2:32. PubMed PMID: PMC2948389.

127. Flowers ME, Martin PJ. How we treat chronic graft-versus-host disease. Blood. 2015;125(4):606–15.
128. Holbro A, Lehmann T, Girsberger S, Stern M, Gambazzi F, Lardinois D, et al. Lung histology predicts outcome of bronchiolitis obliterans syndrome after hematopoietic stem cell transplantation. Am Soc Blood Marrow Transplant. 2013;19:973–80.
129. Barker AF, Bergeron A, Rom WN, Hertz MI. Obliterative bronchiolitis. N Engl J Med. 2014;370:1829–8.
130. Bhatia S, Ramsay NK, Steinbuch M, Dusenbery KE, Shapiro RS, Weisdorf DJ, et al. Malignant neoplasms following bone marrow transplantation. Blood. 1996;87:3633–9.
131. Curtis RE, Travis LB, Rowlings PA, Socie G, Kingma DW, Banks PM, et al. Risk of lymphoproliferative disorders after bone marrow transplantation: a multi-institutional study. Blood. 1999;94(7):2208–16.
132. Jagadeesh D, Woda BA, Draper J, Evens AM. Post transplant lymphoproliferative disorders: risk, classification, and therapeutic recommendations. Curr Treat Options Oncol. 2012;13(1):122–36. PubMed PMID: 22241590.
133. Catani L, Gugliotta L, Vianelli N, Nocentini F, Baravelli S, Bandini G, et al. Endothelium and bone marrow transplantation. Bone Marrow Transplant. 1996;17(2):277–80.
134. Bunte MC, Patnaik MM, Pritzker MR, Burns LJ. Pulmonary veno-occlusive disease following hematopoietic stem cell transplantation: a rare model of endothelial dysfunction. Bone Marrow Transplant. 2008;41(8):677–86.
135. Cines DB, Pollak ES, Buck CA, Loscalzo J, Zimmerman GA, McEver RP, et al. Endothelial cells in physiology and in the pathophysiology of vascular disorders. Blood. 1998;91(10):3527–61.
136. Dandoy CE, Hirsch R, Chima R, Davies SM, Jodele S. Pulmonary hypertension after hematopoietic stem cell transplantation. Bone Marrow Transplant. 2013;19(11):1546–56.
137. Rabinovitch M. Molecular pathogenesis of pulmonary aterial hypertension. J Clin Invest. 2012;122:4306–13.
138. Jodele S, Hirsch R, Laskin B, Davies S, Witte D, Chima R. Pulmonary arterial hypertension in pediatric patients with hematopoietic stem cell transplant-associated thrombotic microangiopathy. Am Soc Blood Marrow Transplant. 2013;19:202–7.
139. Steward CG, Pellier I, Mahajan A, Ashworth MT, Stuart AG, Fasth A, et al. Severe pulmonary hypertension: a frequent complication of stem cell transplantation for malignant infantile osteopetrosis. Br J Haematol. 2004;124(1):63–71.
140. Rosenzweig E, Barst R. Pulmonary arterial hypertension in children: A medical update. Curr Opin Pediatr. 2008;20:288–93.
141. Frazier AA, Franks TJ, Mohammed TL, Ozbudak IH, Galvin JR. From the Archives of the AFIP: pulmonary veno-occlusive disease and pulmonary capillary hemangiomatosis. Radiographics. 2007;27(3):867–82.
142. Mandel J, Mark EJ, Hales CA. Pulmonary veno-occlusive disease. Am J Respir Crit Care Med. 2000;162(5):1964–73.
143. Holcomb BW Jr, Loyd JE, Ely EW, Johnson J, Robbins IM. Pulmonary veno-occlusive disease: a case series and new observations. Chest. 2000;118(6):1671–9.
144. Almagro P, Alvarez M, Garau J. Lung biopsy in pulmonary veno-occlusive disease. Chest. 2001;120(4):1421–2.
145. Izbicki G, Shitrit D, Schechtman I, Bendayan D, Fink G, Sahar G, et al. Recurrence of pulmonary veno-occlusive disease after heart-lung transplantation. Lung biopsy in pulmonary veno-occlusive disease. J Heart Lung Transplant. 2005;24(5):635–7.
146. Serota FT, August CS, Koch PA, Fox W, D'Angio GJ. Pulmonary function in patients undergoing bone marrow transplantation. Med Pediatr Oncol. 1984;12(2):137–43. PubMed PMID: 6366504.
147. Uderzo C, Rovelli A, Meloni G, Balduzzi A, Pezzini C, Colombini A, et al. Evaluation of late side-effects after bone marrow transplantation in children with leukemia. Bone Marrow Transplant. 1991;8(Suppl 1):44–6. PubMed PMID: 1760638.

148. Kaplan EB, Wodell RA, Wilmott RW, Leifer B, Lesser ML, August CS. Late effects of bone marrow transplantation on pulmonary function in children. Bone Marrow Transplant. 1994;14(4):613–21. PubMed PMID: 7858537.
149. Cerveri I, Fulgoni P, Giorgiani G, Zoia MC, Beccaria M, Tinelli C, et al. Lung function abnormalities after bone marrow transplantation in children: has the trend recently changed? Chest. 2001;120(6):1900–6. PubMed PMID: 11742920.
150. Nenadov Beck M, Meresse V, Hartmann O, Gaultier C. Long-term pulmonary sequelae after autologous bone marrow transplantation in children without total body irradiation. Bone Marrow Transplant. 1995;16(6):771–5. PubMed PMID: 8750268.
151. Kaya Z, Weiner DJ, Yilmaz D, Rowan J, Goyal RK. Lung function, pulmonary complications, and mortality after allogeneic blood and marrow transplantation in children. [Erratum appears in Biol Blood Marrow Transplant. 2009 Sep;15(9):1141]. Biol Blood Marrow Transplant. 2009;15(7):817–26. PubMed PMID: 19539213.
152. Fulgoni P, Zoia MC, Corsico A, Beccaria M, Georgiani G, Bossi G, et al. Lung function in survivors of childhood acute lymphoblastic leukemia. Chest. 1999;116(5):1163–7. PubMed PMID: 10559071.
153. Yen KT, Lee AS, Krowka MJ, Burger CD. Pulmonary complications in bone marrow transplantation: a practical approach to diagnosis and treatment. Clin Chest Med. 2004;25(1):189–201.
154. Pulsipher MA, Skinner R, McDonald GB, Hingorani S, Armenian SH, Cooke KR, et al. National Cancer Institute, National Heart, Lung and Blood Institute/Pediatric Blood and Marrow Transplantation Consortium First International Consensus Conference on late effects after pediatric hematopoietic cell transplantation: the need for pediatric-specific long-term follow-up guidelines. Am Soc Blood Marrow Transplant. 2012;18:334–47.
155. Uhlving HH, Mathiesen S, Buchvald F, Green K, Heilmann CJ, Gustafsson PM, et al. Small airways dysfunction in long term survivors of pediatric stem cell transplantation. Pediatr Pulmonol. 2014;50(7):704–12.
156. Lahzami S, Schoefel RE, Pechey V, Greenwood M, Salome CM, Berend N, et al. Small airways function declines after allogeneic haematopoietic stem cell transplantation. Eur Respir J. 2011;38(5):1180–8.
157. Australian Institute of Health and Welfare. Cancer in Australia: an overview 2014. Cancer series no 90 Cat no CAN 88 Canberra, AIHW2014.
158. Krowka MJ, Rosenow rEC, Hoagland HC. Pulmonary complications of bone marrow transplantation. Chest. 1985;87(2):237–46.
159. Mulder RL, Thönissen NM, van der Pal HJ, Bresser P, Hanselaar W, Koning CC, et al. Pulmonary function impairment measured by pulmonary function tests in long-term survivors of childhood cancer. Thorax. 2011;66(12):1065–71.
160. Doll DC, Ringenberg QS, Yarbro J. Vascular toxicity associated with antineoplastic agents. J Clin Oncol. 1986;4(9):1405–17.

Respiratory Complications of Maxillofacial and Otolaryngologic Disorders

R. Paul Boesch

Introduction

Congenital and acquired airway disorders are common in children and often affect breathing. The main mechanism of effect is via inspiratory or expiratory airflow limitation, or impairment in lung protection from inhaled or aspirated material. Causes of obstruction above the thoracic inlet are extremely common and may be congenital or acquired, or due to primary infections. Infectious causes of upper airway obstruction are the most common. The upper aerodigestive tract is unique in that it must tightly coordinate air entry to the lung and nourishment to the esophagus via a common entry, almost simultaneously. The larynx is the gateway to the lower airways and integral to this coordination. When its function is compromised, soiling of the lower airways and lungs may result. Coordination of swallowing and breathing may become disrupted by any upper airway obstructive lesion in a susceptible child. Aspiration may also occur when laryngeal protective reflexes are impaired or when there is an abnormal connection between the esophagus and the airway. In many (if not most) circumstances, an upper airway lesion is not sufficient to cause chronic micro-aspiration outright; rather the lesion coexists with other swallowing challenges such as tachypnea, neurologic disease, poor feeding behaviors, or immaturity. In general, upper airway disorders do not have a direct effect on the lungs. However, they can alter the mechanics of breathing and increase significantly the work of breathing (e.g., severe laryngomalacia), affect the gas exchange, and cause chronic lung damage by predisposing to chronic (micro)aspiration.

R. Paul Boesch, D.O., M.S., F.A.A.P.
Mayo Clinic Children's Center, Rochester, MN, USA
e-mail: Boesch.Paul@mayo.edu

© Springer International Publishing AG 2018

A.C. Koumbourlis, M.A. Nevin (eds.), *Pulmonary Complications of Non-Pulmonary Pediatric Disorders*, Respiratory Medicine,
https://doi.org/10.1007/978-3-319-69620-1_5

Airway Obstruction

Physiology of Stridor

Airway physiology changes across the thoracic inlet, and therefore using this point as the defining border between upper and lower airway predicts different signs and symptoms associated with upper and lower airway obstruction. By this definition the upper airway would include the nasal ala through the extrathoracic trachea, and the lower airways would include all intrathoracic airways. Large airway obstruction produces an audible monophonic sound that can often be heard several feet away from the patient; the emitted sound can be inspiratory, expiratory, or biphasic and varies in pitch according to the bulk and shape of the vibrating structure. Typically, dynamic upper airway obstruction results in inspiratory stridor, dynamic lower airway obstruction results in expiratory stridor, and fixed upper or lower airway obstruction results in biphasic stridor (though usually more pronounced in inspiration for upper airway lesions and in expiration for lower respiratory lesions). On inhalation the upper airway is exposed to negative intraluminal pressures without opposing external airway distending forces, and on exhalation intraluminal pressure is positive (Fig. 1) [1]. Therefore soft upper airway structures collapse on inspiration, and if obstruction results then inspiratory stridor will be produced. On inhalation the lower airways are also exposed to negative intraluminal pressures, but pleural pressure is more negative and results in external distending pressure. On exhalation the tracheal pressure is less than the pleural pressure favoring airway collapse, which is further accentuated by more forceful exhalation. Fixed obstructive lesions change little between inspiration and expiration and therefore produce biphasic stridor. Flow-volume loops on spirometry can often identify variable and fixed intra- and extrathoracic obstruction (Fig. 2). Stridor is usually best auscultated over the anterior neck. Significant upper airway obstruction typically produces suprasternal retractions (often referred to as "tracheal tug"). Suprasternal retraction and the use of accessory muscles of respiration are a better reflection of the severity of the airway obstruction than is the intensity of the stridor. Increased airflow velocity, due either to increased respiratory effort or reduced airway diameter, will result in increased dynamic collapse as predicted by Bernoulli's principle. A patient presenting with stridor generally warrants direct visual examination of the airway, unless the cause is known to be infectious.

Upper Airway Obstruction

Compared to adults, the pediatric airway has morphologic characteristics predisposed to obstruction. In the child's airway, the tongue is larger in proportion to the mouth, the pharynx is smaller, the epiglottis is larger and softer, the larynx is more anterior and superior, and the larynx is funnel-shaped. In addition, the pediatric

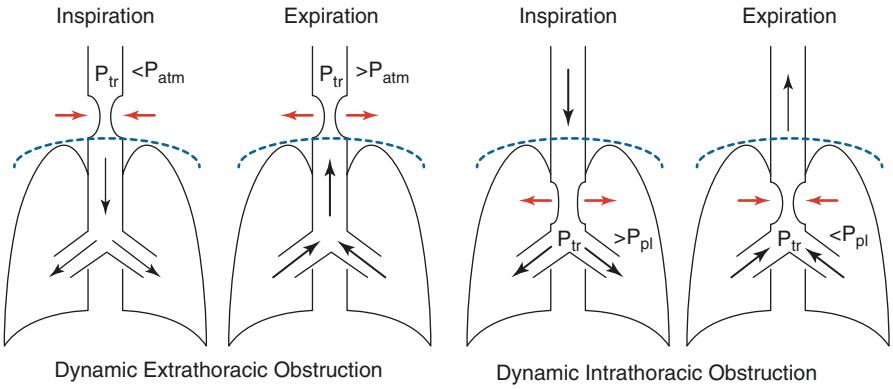

Fig. 1 Physiology of dynamic extrathoracic and intrathoracic obstruction (above vs. below the thoracic inlet). *Left*: during inspiration the intraluminal pressure of the trachea (P_{tr}) becomes negative and therefore less than atmospheric pressure (P_{atm}). This increases tendency toward airway collapse on inspiration. On expiration P_{tr} becomes positive and therefore exceeds P_{atm} and obstruction decreases. *Right*: during inspiration pleural pressure (P_{pl}) is more negative than P_{tr}, and therefore airways are pulled into a more open position. On expiration, especially more forced expiration, P_{pl} exceeds P_{tr} promoting airway collapse .Redrawn from: Kryger M, Bode F, Antic R, Anthonisen N. Diagnosis of obstruction of the upper and central airways. Am J Med. 1976;61(1):85–93

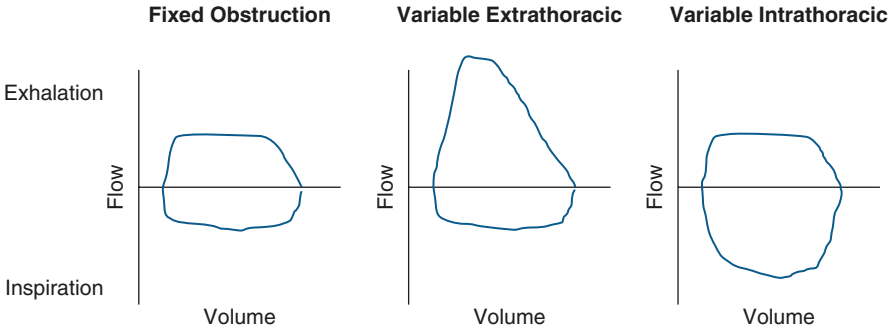

Fig. 2 Flow-volume loops in large airway obstruction. Fixed obstruction characterized by flow limitation in both the inspiratory and expiratory limbs of the flow-volume loop. Variable extrathoracic obstruction characterized by flow limitation in inspiration that normalizes in expiration. Variable intrathoracic obstruction characterized by flow limitation in expiration that normalizes in inspiration

airway is narrowest at the cricoid which makes the infant and child's airway more susceptible to injury from endotracheal intubation.

Upper airway obstruction is very common in children and may be caused by a variety of congenital or acquired factors (Tables 1 and 2). Primary infections are the most common causes followed by congenital abnormalities in healthy children and acquired causes in medically complex children. The most common cause of congenital stridor is laryngomalacia, followed in frequency by vocal cord immobility

Table 1 Congenital airway lesions presenting with inspiratory obstruction or stridor

Nasal
Pyriform aperture stenosis
Nasolacrimal duct cysts
Choanal stenosis/atresia
Pharyngeal
Micrognathia/retrognathia
Glossoptosis
Lingual thyroglossal duct cyst
Cystic hygroma
Buccopharyngeal membrane
Pharyngomalacia
Supraglottic
Laryngomalacia
Laryngeal cysts
Epiglottic petiole prolapse
Glottic
Vocal fold immobility
Glottic web
Subglottic
Subglottic stenosis
Subglottic hemangioma
Laryngotracheoesophageal cleft
Tracheal
Tracheomalacia (extrathoracic)
Congenital tracheal stenosis
Complete tracheal rings
Vascular ring

and subglottic stenosis. The impact of upper airway obstruction exists along a spectrum from dyspnea, with exertion or with concomitant upper respiratory tract infections, sleep-disordered breathing, and feeding difficulties and aspiration, to increased work of breathing at rest or overt respiratory failure.

Laryngomalacia

Laryngomalacia typically presents with inspiratory stridor that is worse with feeding, excitement, crying, or supine, with sleep-disordered breathing, or feeding and swallowing problems [2]. Laryngomalacia explains almost two-thirds of infants presenting with congenital stridor and will typically present in the first few weeks of life, and they often worsen until approximately the first 6 months. They then slowly improve and resolve by 12–18 months of age. Laryngomalacia can also present in older children, but its presentation is different compared with the neonatal onset. Children over the age of 3 years may demonstrate dysphagia,

Table 2 Acquired airway lesions presenting with inspiratory obstruction or stridor

Nasal
Nasal polyps
Nasal synechia
Pharyngeal
Tonsil hypertrophy (adenoid, palatine, lingual)
Retropharyngeal abscess
Pharyngomalacia
Supraglottic
Epiglottitis
Supraglottic stenosis
Glottic
Vocal fold immobility
Vocal cord dysfunction
Recurrent respiratory papillomatosis
Subglottic
Subglottic stenosis
Subglottic cysts
Laryngotracheitis (croup)
Tracheal
Tracheomalacia (extrathoracic)
Acute bacterial tracheitis
A-frame stenosis following tracheostomy decannulation
Acquired tracheal stenosis
Esophageal foreign body

whereas school-age children may exhibit symptoms of sleep-disordered breathing, and adolescents may complain primarily of dyspnea on exertion mimicking vocal cord dysfunction [2–5]. Awake rhinolaryngoscopy is required for diagnostic clarity. In cases of exercise-induced laryngomalacia, this must be performed during exercise, either on a treadmill or stationary bicycle. Endoscopically, laryngomalacia appears as any combination of the following: (1) anterior collapse of arytenoid mucosa or arytenoid bodies obscuring the vocal folds, (2) shortening of aryepiglottic folds and curling of the epiglottis on its long axis, and (3) posterior epiglottic prolapse.

Laryngomalacia commonly associates with other airway anomalies and with comorbidities, which may include gastroesophageal reflux, central nervous system disease, congenital anomalies, and congenital heart disease. Gastroesophageal reflux (GER) is thought to be very commonly associated with laryngomalacia and may be a contributor to swallowing dysfunction [6–9]. Children with central neurologic disease such as static encephalopathy, microcephaly, hydrocephalus, and Chiari malformation have a higher prevalence of laryngomalacia and have a higher rate of requirement for surgical intervention, though they also have a lower rate of surgical success [2, 10, 11]. Laryngomalacia is also more common in children with

congenital syndromes, such as trisomy 21, Pierre Robin sequence, and CHARGE association [12]. There is some controversy over when to perform complete bronchoscopy in children with laryngomalacia. The reported incidence of secondary airway lesions varies widely at 7.5–58%; while not all of these anomalies will be clinically significant, some may contribute to postsurgical complications [12–15]. It is reasonable to consider bronchoscopy for children in whom airway obstruction seems out of proportion to findings on awake rhinolaryngoscopy, those who have symptoms not clearly explained by laryngomalacia alone and those with severe enough disease to consider surgery. This should include evaluation for dynamic airway lesions (best achieved with flexible bronchoscopy) and fixed lesions such as subglottic stenosis (best achieved by rigid bronchoscopy).

Laryngomalacia will resolve spontaneously in 80–90% of cases; as such, the most appropriate management may be reassurance. Those with dysphagia should be evaluated for dysphagia with either a videofluoroscopic swallow study (VFSS) or fiber-optic endoscopic evaluation of swallowing (FEES). If concern for sleep-disordered breathing is present, polysomnography is appropriate. Infants with severe laryngomalacia may demonstrate continuous stridor, apnea, respiratory failure, or failure to thrive. These infants and those with moderate or atypical laryngomalacia and comorbidities may be candidates for surgical treatment. Endoscopic supraglottoplasty with or without epiglottopexy is the surgical procedure of choice. The technique typically involves division of the aryepiglottic folds to allow the larynx to obtain a more open position and trimming of redundant arytenoid mucosa (Fig. 3). Overall success rate is reported to be 53–95%, and overall complication rate is <10% [16]. Success rate is highly affected by the presence of comorbid conditions; the success rate for otherwise healthy infants (including premature infants) generally exceeds 90% but drops to 56–64% in children with static encephalopathy, congenital heart disease, or genetic syndromes [16–20].

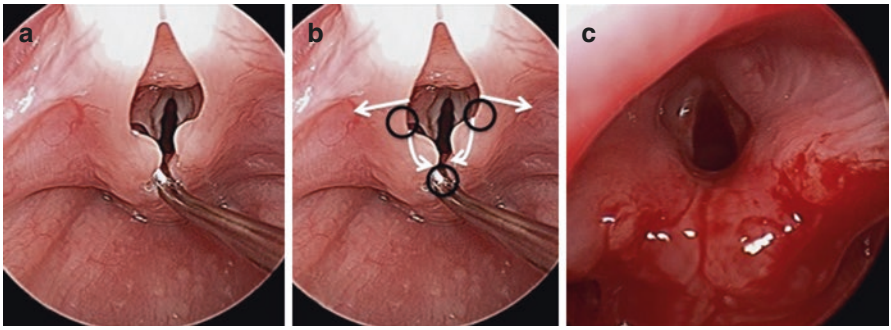

Fig. 3 Congenital laryngomalacia and supraglottoplasty. (**a**) Characteristic findings of congenital laryngomalacia including foreshortened aryepiglottic folds resulting in hooding of the true vocal folds, curling of the epiglottis on its long axis, and narrow diamond-shaped supraglottic lumen. (**b**) Cuts to be made with laser or laryngeal scissors (*white arrows*) to release aryepiglottic to the base of the epiglottis and to remove the prominent mucosa overlying the cuneiform cartilages. *Black circles* denote islands of mucosa to keep intact to prevent supraglottic stenosis. (**c**) Immediate postoperative view

Vocal Fold Immobility

Vocal fold immobility (VFI) refers to impairment in normal true vocal fold motion either by neurologic paresis or mechanical fixation. VFI can be congenital or acquired and unilateral or bilateral, each type having different etiologies, presenting characteristics, and consequences (Table 3). Both unilateral and bilateral vocal fold immobility are present with stridor; bilateral involvement is expected to be more severe with earlier presentation. With bilateral paresis the vocal folds are typically more closely approximated in a paramedian position with loss of bilateral abductor function. With unilateral immobility, preserved abductor function of the opposite cord results in improved glottic aperture. Both may present with dysphagia, but unilateral immobility is more associated with hoarseness with breathy cry and aspiration [21–23]. Congenital vocal fold paralysis is most commonly idiopathic but can also be caused by neurologic disease affecting the brainstem or perinatal difficulties such as forceps delivery or fetal hypoxemia. Acquired vocal fold immobility is much more common and tends to be unilateral and left-sided; acquired paralysis is often relatable to surgical intervention involving the neck, heart, or mediastinum.

The motor efferents of the vagus nerve originate in the medulla oblongata from the nucleus ambiguus and dorsal nuclei. The vagus exits the skull via the jugular foramen, and then the superior laryngeal nerve arises to give sensory innervation to the larynx above the true vocal folds (internal branch) and motor innervation to the cricothyroid muscle (external branch). The vagus then continues into the thorax. The right vagus passes in front of the subclavian artery, around which passes the right recurrent laryngeal nerve. The right recurrent laryngeal nerve then passes superiorly along the tracheoesophageal groove back to the larynx to provide all motor innervation to the larynx (except the cricothyroid muscle) and sensation below the true vocal folds. The left recurrent laryngeal nerve arises lower in the thorax, passing behind the aorta near the level of the ductus arteriosus. The left recurrent laryngeal nerve also courses superiorly along the tracheoesophageal groove back to the larynx to provide all motor innervation to the larynx (except the cricothyroid muscle) and sensation below the true vocal folds. The longer course of the left recurrent laryngeal nerve and its proximity to the ductus arteriosus places it at much greater risk for injury during surgery than the right.

Table 3 Causes and presenting symptoms of unilateral vs. bilateral VFI

Bilateral	Unilateral
Most idiopathic	Most iatrogenic (postsurgical)
Birth trauma	Birth trauma
Brainstem compression (e.g., Chiari)	Pulmonary artery enlargement
Increased intracranial pressure	Mediastinal tumors
Hydrocephalus	Most left-sided
Hypoxemia	
Stridor primary symptom	Dysphonia primary symptom
More likely to present with respiratory distress	More likely to have dysphagia
Aspiration more common after repair	Aspiration common

Bilateral VFI is the second most common cause for congenital stridor, representing ~10% of congenital laryngeal lesions and 25–62% of vocal fold immobility [22, 23]. Depending on the series reported, approximately half of cases of bilateral VFI are idiopathic, 14–52% neurologic, and 20% traumatic [22–25]. Congenital bilateral VFI is very likely to present with stridor within the first month of life and is more likely than unilateral paralysis to result in respiratory failure [22–26]. Spontaneous recovery of VFI is observed to occur in 32–65% of cases though the rate of recovery is affected by the cause for immobility, with a higher recovery rate for immobility related to birth trauma or idiopathic cases and lower rates for surgical injury [21–25]. More than half of children undergoing tracheostomy for bilateral VFI can expect to be decannulated, though many will require surgical procedures to achieve this. Procedures aimed at widening the glottic aperture include cordotomy, arytenoidectomy, open or endoscopic suture lateralization, variations of cricoid split, and laryngotracheoplasty with posterior graft. When vocal fold function does not return, any surgical procedure to achieve decannulation will place the glottis in a fixed more-open position; clinicians are advised to maintain awareness of the balance between airway patency and the risk of dysphonia and swallowing dysfunction. Spontaneous recovery of vocal fold function (when it occurs) usually happens within 6 months, though recovery can be delayed by several years [21, 23, 25, 26]. For this reason most recommend observing for 1–2 years prior to surgical intervention to avoid unnecessary risks.

In unilateral VFI presenting symptoms are generally those of dysphonia and feeding problems due to difficulty achieving tight glottic closure. The most common etiology of unilateral vocal cord paralysis is surgical injury. Injury to the recurrent laryngeal nerve may be encountered during ligation of patent ductus arteriosus or during cardiac surgery, specifically procedures that require manipulation of the aortic arch [23, 27, 28]. Reported risk for VFI following cardiac surgery is around 20%; much higher rates have been reported in extremely low birth weight infants undergoing PDA ligation [28–30]. Management for unilateral VFI focuses on safe feeding and dysphonia [31]. Surgical interventions for unilateral VFI seek to approximate the true vocal folds. These options include injection laryngoplasty, thyroplasty with insertion of a prosthesis into the paralyzed vocal fold, and laryngeal reinnervation procedures to improve thyroarytenoid muscle tone and bulk [27]. Success of each approach for dysphagia exceeds 80%.

Subglottic Stenosis

The subglottic region begins just below the true vocal folds and extends to the lower border of the cricoid cartilage. In infants and children, the subglottis is the narrowest portion of the airway. Subglottic stenosis (SGS) is an important cause of airway obstruction and can be either congenital or acquired. Congenital SGS results from embryologic failure of recanalization of the larynx and exists on a spectrum of SGS, glottic web, and laryngeal atresia. Congenital SGS is the third most common cause of congenital stridor representing 10–15% of causes and is frequently associated

with other genetic syndromes and malformations such as 22q11 deletion, trisomy 21, and CHARGE association [32–34]. Subglottic stenosis represents a fixed obstruction above the thoracic inlet and therefore presents with biphasic stridor that is worse in inspiration. A barky or brassy cough is a classic presenting symptom. Depending on the severity of the stenosis, stridor may be present at rest or may become apparent only during exercise or with upper respiratory tract infections. Recurrent croup is a potential presentation of milder forms of congenital SGS [35, 36].

Acquired SGS is much more common than congenital SGS and often follows airway trauma from endotracheal intubation or other injury. It does appear that neonates can tolerate longer periods of intubation without development of SGS compared to adults or older children. Overall rates of development of subglottic stenosis (with requirement of surgical intervention) following intubation in neonates are reported to be <2.5% [37–40]. A prospective study evaluating all infants and young children intubated for >24 h demonstrated an overall SGS rate of 10.3% with 50% progressing to SGS if they had interarytenoid ulceration, interarytenoid granulation, or subglottic granulation [41].

Management of SGS is driven by symptoms and severity. The Myer-Cotton system is the most widely used scale for grading SGS severity [42]. Stenosis grade (1–4) is based on measurement of subglottic diameter by endotracheal tube, relative to the age-appropriate tube size. Grade 1 is defined as <50% lumen obstruction, grade 2 is 50–70%, grade 3 is 71–99%, and grade 4 is complete obstruction. Grades 1 and 2 rarely if ever require operative intervention, whereas grades 3 and 4 typically require surgical airway expansion [34]. Congenital stenosis in general may improve with growth and time, and if not severe may be managed with observation. Care must be taken to avoid additional injury, such as from intubation. Acquired stenosis typically does not improve with time.

The mainstay of surgical management for severe SGS is open airway expansion, which includes laryngotracheoplasty with cartilage grafting or cricotracheal resection. Reported overall success rates for laryngotracheoplasty with cartilage grafting exceed 90% overall though secondary procedures are commonly required [34, 43]. Laryngotracheoplasty can be performed as a single- or double-stage procedure. Single-stage procedures have a higher success rate with the first procedure but are generally reserved for children with lesser disease comorbidities and stenosis complexity. Double-stage procedures are utilized for patients with complex multilevel stenosis, significant neurologic disease, and chronic lung disease. High-grade stenosis is also often managed by double-stage laryngotracheoplasty with grafts or by cricotracheal resection. Success with the initial operation is typically lower with double-stage procedures, but ultimate success remains high [43]. Due to long hospital stays and potential complications of open reconstruction, there has been considerable interest and development of endoscopic interventions. One such intervention includes endoscopic posterior cricoid split with costal cartilage graft. A recent study of this procedure performed for children with SGS, posterior glottic stenosis, and bilateral VFI reported an overall success rate of 80.8% though operation-specific success was only 61.5% [44]. Success rate was much higher for posterior glottic stenosis than for SGS or bilateral VFI. The median postoperative

hospitalization time was only 3 days. Endoscopic management can also mean various applications of incision, steroid injection, and dilation. These can be utilized as primary interventions or as secondary procedures after laryngotracheoplasty. Success rates for endoscopic intervention alone range from 52 to 65%, and on average ~2 treatments are required [45–47]. Morbidity is very low though success rate is consistently associated with SGS grade with improved success with grade 1 or 2 SGS vs. grade 3 or 4. Children expected to respond best to balloon dilation include those with acquired low-grade stenosis and thin, weblike or soft stenosis vs. those with congenital, high-grade or firm or thick stenosis or those with loss of cartilaginous support [34].

Micrognathia

Robin sequence (RS) is defined by the presence of micrognathia with associated glossoptosis. Associations include cleft palate, other congenital anomalies, and genetic syndromes [48–51]. Robin sequence is estimated to be associated with other genetic syndromes in 15–46% of cases; Stickler syndrome, Treacher Collins syndrome, 22q11.2 deletion, Marshall syndrome, and facial/hemifacial microsomia are associated most commonly [48, 50]. Robin sequence commonly presents in early neonatal life with upper airway obstruction and feeding difficulties; surgical intervention is commonly required. Upper airway obstruction may manifest awake or as obstructive sleep apnea and is often less severe in a prone or side-lying position as this lessens posterior displacement of the tongue. It is important to note that the severity of snoring does not correlate to severity of obstructive sleep apnea, especially in infants [48, 52]. In infants upper airway obstruction may manifest only as failure to thrive. The recommended diagnostic approach for patients with RS includes (1) flexible rhinolaryngoscopy to characterize obstructive lesions awake and sleep state, (2) evaluation for sleep-disordered breathing by polysomnogram, (3) evaluation of growth and swallowing clinically and instrumentally, and (4) evaluation by a geneticist [48, 51].

Feeding problems are very common in children with RS. This includes prolonged feeding times of >30 min per bottle, reduced oral intake, penetration and aspiration, and precipitation of respiratory distress during feeding [48, 50]. This may be due to abnormal anatomic tongue position, dyscoordination due to upper airway obstruction, and weak suck which is exacerbated by cleft palate [53]. The reported rate of need for gastrostomy tube is 33–42% [49, 54]. Aspiration is common and often occurs silently or without a cough reflex. One study evaluating swallowing in young children with glossoptosis documented abnormal oral phase in 42.1%, delayed initiation of pharyngeal swallow in 84.2%, laryngeal penetration in 52.6%, and tracheal aspiration in 31.6% [55]. Poor ability of clinical swallowing evaluation to predict or exclude penetration or aspiration on VFSS, emphasizes the need for instrumental swallowing evaluation. The majority (90%) of affected infants will eventually achieve full oral feeding [54, 56].

It is estimated that 28–40% of infants with RS will fail conservative management and will require operative intervention [43, 49]. A tracheostomy may be considered to bypass the obstructed upper airway until sufficient mandibular growth is achieved. Evidence is conflicting as to whether mandibular growth catches up and some studies show persistence of obstructive apnea over the first year in infants not treated with surgery [57]. Though effective in maintaining airway patency, tracheostomy is expected to incur both expense and changes in quality of life due to the expectation for prolonged and recurrent hospitalizations and requirements for in-home resources [48, 49, 57]. In many areas mandibular distraction osteogenesis (MDO) has become the procedure of choice for primary management of RS with severe obstruction though there are regional differences in practice, and this procedure requires a specialized center. Mandibular distraction has been found to be effective at quickly relieving airway obstruction and improves oral feeding [56, 58–60]. Several meta-analyses support that 95% of patients can avoid tracheostomy with MDO, even in children less than 2 months of age [58–60]. Mandibular distraction osteogenesis carries a high cost, and complications include facial scarring, facial nerve palsy, inferior alveolar nerve injury, malocclusion, TMJ ankylosis, unintelligible speech, and dental damage, each at a rate of 5–20% [59, 60]. An alternative procedure to improve airway obstruction from RS is tongue-lip adhesion (TLA). This procedure involves suturing the tongue to the lower lip and mandible to keep the tongue in a more forward position. This is maintained for much of the first year of life, until upper airway obstruction improves with growth, and then the tongue is released. Compared to MDO, TLA is associated with lower healthcare cost and shorter duration of hospitalization but is also associated with significantly greater postoperative dysphagia and feeding problems and need for secondary procedures for upper airway obstruction [61–63].

Lower Airway Obstruction

The cardinal clinical sign of lower airway obstruction is wheezing. Persistent wheezing is a presenting complaint that is very common to pediatric pulmonologists. A broad differential diagnosis exists for wheezing; it may be caused by inflammatory abnormalities such as asthma or aspiration, genetic disorders such as cystic fibrosis or primary ciliary dyskinesia, gastroesophageal reflux, or structural disorders such as tracheobronchomalacia or airway compression (Table 4). Physiologically, wheezing is typically expiratory as intrathoracic airway diameter decreases on expiration; when obstruction is severe, there may be an inspiratory component as well. Intrathoracic airway obstruction may also result in hyperinflation or air trapping, which may be evident on lung volume testing or, less reliably, on chest radiography. Additionally, intrathoracic obstruction may cause barky cough, prolonged expiratory phase, and impaired secretion clearance. Focal lower airway obstruction tends to produce a more monophonic (vs. polyphonic) tone. Anatomic lower airway obstruction may be fixed such as with tracheal stenosis or dynamic such as with

Table 4 Causes of wheezing

Large airway obstruction	Small airway obstruction
Tracheobronchomalacia	Asthma
Tracheobronchial stenosis • Congenital • Acquired	Bronchopulmonary dysplasia
	Bronchiolitis
Tracheal bronchus	Pneumonia
Airway foreign body	Bronchiectasis
Tracheobronchial compression • Vascular (ring or compression) • Cardiac • Scoliosis • Mediastinal mass/cyst	Chronic aspiration • Swallow dysfunction • Gastroesophageal reflux • LTEC • TEF
Tracheobronchial mass lesion • Hemangioma • Granulation • Tuberculosis • Tumor	Cystic fibrosis
	Primary ciliary dyskinesia
	Bronchiolitis obliterans
	Alveolar hemorrhage syndromes

Although asthma and infectious causes of wheezing are the most frequent, large airway causes of wheezing are many and common

tracheomalacia, and either is worsened when there is additional airway edema or mucus encumbrance. Studies evaluating the yield of flexible bronchoscopy for infants and children with persistent or atypical wheezing identify anatomic abnormalities in 48–63% [64–67]. For this reason lower airway evaluation is recommended for young children with recurrent wheezing who fail to respond to medical interventions [68, 69].

Tracheobronchomalacia

Tracheobronchomalacia refers to the excess collapsibility of the central airways and may be due to any combination of softness of the airway cartilage, distortion from extrinsic compression, hyperdynamic posterior membrane, or decrease in the normal ratio of cartilage to posterior membrane in the tracheal circumference. Tracheomalacia is common with an estimated incidence of 1:1500–2100, with higher prevalence in premature infants and almost universal presence in children with tracheoesophageal fistula. Tracheobronchomalacia may be primary or secondary to airway compression, airway distortion (such as from prolonged mechanical ventilation or tracheostomy), or following infection [70–72]. Symptoms range from coarse wheezing worse with exercise, agitation or respiratory infections, harsh brassy coughing that is prolonged following infections, and recurrent bacterial bronchitis to dysphagia, cyanotic spells, apnea, and prolonged weaning from mechanical ventilation [72, 73]. Most infants with tracheomalacia improve or resolve by 2 years of age due to increased airway lumen size and increasing rigidity of tracheal and bronchial cartilage.

Flexible bronchoscopy is the gold standard for diagnosis of tracheobronchomalacia. Flexible bronchoscopy has advantages over rigid bronchoscopy in that there is less requirement for general anesthesia, less airway stenting or distortion, and an ability to also evaluate other peripheral anatomic anomalies as well as obtain samples for bronchoalveolar lavage. It is essential that any diagnostic evaluation for tracheobronchomalacia be a dynamic assessment. Because infants can have up to 50% tracheal collapse with crying, most define tracheomalacia as collapse of >50% of the tracheal lumen [72, 74]. What is less consistent are the thresholds used for grading severity. Despite this inconsistency, inter-operator agreement for grading of tracheomalacia severity is quite good [75, 76].

Due to the tendency of young children to outgrow tracheobronchomalacia, the management approach is generally conservative, other than for severe or life-threatening disease. Management strategy includes avoidance or management of cough triggers (such as allergies, inhaled irritants, and gastroesophageal reflux) and avoidance of medications which may decrease airway tone, such as short-acting beta-agonists. Cough clearance may be improved by coughing against a resistance, and exercise tolerance may be improved by pursed-lip exhalation. Increasing airway smooth muscle tone in patients with tracheomalacia can improve airflow which can be observed during methacholine challenge or following administration of oral bethanechol [77]. Given the high frequency of protracted bacterial bronchitis in children with tracheobronchomalacia, antibiotics can be useful, especially for prolonged wet coughing following an upper respiratory infection [73].

Children with severe symptoms require surgical management. This may include aortopexy, tracheostomy with or without positive pressure support, or endobronchial stenting. Aortopexy involves mobilization of any combination of aortic arch, innominate artery, and pulmonary artery and suturing it to an anterior bony surface such as the sternum. Reported outcomes with aortopexy are favorable with overall success rate to improve or resolve respiratory symptoms in 73–80% of patients; outcomes vary as a result of malacia subtype and based on the presence or absence of comorbidities [78–80]. Tracheostomy is an additional therapeutic option for severe tracheobronchomalacia. Tracheostomy placement allows a safer interface with positive pressure modalities such as conventional or noninvasive ventilator support and also allows a conduit for secretion management. Endobronchial stenting is conceptually attractive. Success rates for airway malacia range from 43 to 85% though severe complication rates are reported in 27–33% [80–83]. Silicone stents are severely limited by the smaller ratio of internal to external diameter, lack of mucociliary clearance, and tendency to migrate. Bare metal stents carry significant risks for embedding in airway wall preventing removal, obstruction by granulation, fracture, and erosion into surrounding vessels. Covered metallic or nitinol stents have a more favorable ratio of internal to external diameter and less migration than silicone stents but also lack mucociliary clearance. Self-expanding stents cannot be further dilated to accommodate growth. All stents have risks for granulation tissue formation and therefore require repeated surveillance bronchoscopy. Bioabsorbable stents are the newest option and have the potential of obviating the need for removal when the child outgrows it [84]. Their short life span of 15 weeks

before dissolution may require repeated stenting, at great expense, until the tracheobronchomalacia improves with growth. Currently, stenting should be reserved for very specific and severe circumstances, and decision to stent should be well considered.

Tracheal Stenosis

Tracheal stenosis is generally an uncommon problem and can be either congenital or acquired and long or short segment [87]. Complete tracheal rings are the most common cause of long-segment congenital tracheal stenosis (CTS). Congenital tracheal stenosis represents a narrowing of the cartilaginous skeleton of the trachea. Acquired tracheal stenosis is most often due to trauma (especially from endotracheal tubes); alternate etiologies include thermal injury, infection, granulomatosis with polyangiitis (GPA), and neurofibroma [83]. Acquired tracheal stenosis usually represents an intraluminal narrowing within a normal cartilaginous tracheal skeleton. This distinction is important in management considerations; narrowing of the tracheal skeleton requires expansion augmentation or resection, whereas intraluminal narrowing can often be managed endoscopically. Tracheal stenosis due to complete tracheal rings which presents in the neonatal period is often associated with cardiovascular anomalies and carries a high mortality rate. Conversely, later presentations are variable in severity with symptoms including exertional dyspnea, wheezing, and recurrent infection [93, 161]. Most commonly complete tracheal rings present in an infant when activity increases or with a respiratory tract infection. These infants present with dyspnea, retractions, and biphasic stridor with a "washing machine" quality. Though 50% present with rings <2 mm in diameter, those with larger rings may be diagnosed following a difficult intubation for elective surgery [88, 89]. Overall the severity of respiratory distress has a greater correlation to the degree of narrowing than the length of the stenosis [87]. This is predicted by the Hagen-Poiseuille equation which predicts that a small change in radius results in a relatively large change in resistance.

Complete tracheal rings are best evaluated by rigid bronchoscopy. When bronchoscopy is not feasible, the length and severity of stenosis as well as identification of any airway branching abnormalities may be delineated by bronchography or reconstructed computed tomography. All children with complete tracheal rings should have echocardiography to rule out associated cardiovascular anomalies. Commonly associated defects include pulmonary artery sling, tetralogy of Fallot, patent ductus arteriosus, atrial septal defect, ventricular septal defect, double aortic arch, partial anomalous pulmonary venous return, transposition of the great vessels, and tricuspid atresia [87, 90, 91]. Of these anomalies, left pulmonary artery sling is most common and is present ~50% of the time [90, 91]. Similarly, tracheal stenosis is associated with 40–50% of pulmonary artery slings. Bronchial arborization anomalies are also common, notably lung agenesis [90, 92].

Because CTS results in narrowing of the tracheal cartilage skeleton, the treatment of choice is expansion augmentation or resection. This can be performed by

various methods. An accepted procedure for short-segment stenosis is tracheal resection with end-to-end anastomosis. This is associated with a mortality risk of <10% and carries additional risks of complications due to anastomotic tension: restenosis or dehiscence. Repair by cartilage graft or pericardial patch results in higher mortality and complication rates, notably due to leak, loss of graft, restenosis, and formation of obstructive granulation tissue [93, 94]. Slide tracheoplasty has become the treatment of choice for long-segment congenital tracheal stenosis though it can be utilized for short stenosis as well [85, 87, 89–92]. In this procedure the trachea is transected near the midpoint of the stenosis, and then one stenotic segment is split along its long axis anteriorly, and the other is split posteriorly. The two ends are then slid over each other, resulting in a long anastomosis, which resists dehiscence. The result is a reduction of the airway by half the stenotic length but with a diameter that is doubled and cross-sectional area that is quadrupled. Slide tracheoplasty has favorable mortality and complication rate and a short postoperative intubation time [85, 88–91]. Endoscopic treatment for congenital tracheal stenosis is reported but is controversial and associated with incomplete improvement in symptoms, risk for restenosis, and formation of obstructive tracheal granulation [95]. Endobronchial treatment with balloon dilation with or without incision or stenting is much more effective for treatment of acquired tracheal stenosis where there is endoluminal scar or for short-term management of restenosis following tracheal expansion procedure for congenital tracheal stenosis [81–83, 90, 91]. Up to 10% of patients with complete tracheal rings may have amelioration of symptoms with growth and will not require surgical reconstruction [96–99].

Airway Soilage

Chronic aspiration may result from swallowing dysfunction, inadequate laryngeal protection, or abnormal connection between the airway and the gastrointestinal tract. When the coordination of swallowing and breathing becomes disrupted by any upper airway obstructive lesion, soiling of the lower airways and chronic lung damage may occur. It should be noted that even lingual or palatine tonsillar hypertrophy may predispose to aspiration especially in a neurologically impaired child [100, 101]. In addition, upper airway obstruction increases the thoracoabdominal pressure gradient thus increasing the risk gastroesophageal reflux [6, 102, 103].

In many (if not most) circumstances, an upper airway lesion is not sufficient to cause chronic micro-aspiration outright; rather the lesion coexists with other swallowing challenges such as tachypnea, neurologic disease, poor feeding behaviors, or immaturity. Tracheostomy may be performed to bypass upper or lower airway obstruction, to serve as a connection for lower-airway-supporting positive pressure, or to improve secretion clearance. Tracheostomy itself alters respiratory and swallowing physiology and therefore has its own respiratory consequences.

Chronic pulmonary aspiration may result in failure to thrive, chronic cough, wheezing, stridor, and recurrent pneumonia, and progressive lung injury may occur

including bronchiectasis and respiratory failure. In general, symptoms are relatively poor predictors of aspiration with wet vocal quality and cough being the most predictive symptoms [104–106]. Large reports of children with documented aspiration on instrumental swallow studies demonstrate a history of recurrent pneumonia to be present in only 38.7–53% of patients, even when persistent enough to cause bronchiectasis [105, 106]. One study reports that 38.7% of children with aspiration will be found to have aspiration-associated airway anomalies on bronchoscopy, with a higher likelihood in those with a history of prior intubation or recurrent pneumonia and a lower likelihood in those with neurologic disease [106]. The most common finding in these patients was a laryngotracheoesophageal cleft (LTEC). Because LTEC and tracheoesophageal fistulas are not reliably identified on rhinolaryngoscopy or flexible bronchoscopy, direct laryngoscopy and bronchoscopy with rigid instruments are recommended for infants and children who have known or suspected chronic pulmonary aspiration.

There is relatively little known about swallowing function and aspiration following airway surgery, though relief of upper airway obstruction is generally beneficial to swallowing. As mentioned earlier, it is clear in children with laryngomalacia and dysphagia that aspiration improves after supraglottoplasty [2, 18, 19]. Children with Robin sequence have improved feeding after MDO but more dysphagia after TLA [58–63]. Any surgical procedure for bilateral VFI that widens the glottic aperture will increase aspiration risk. There is less data on swallowing function after laryngotracheal reconstruction. This issue is challenged by a high rate of presurgical dysphagia as well as a high rate of multiple medical comorbidities. In one study, only 1/3 of children undergoing laryngotracheoplasty were taking all oral feeds prior to surgery [107]. While 17% had feeding aversions, the remainder fed a combination of gastrostomy/oral feeds or thickened feeds. Postoperatively, most developed compensatory airway protective mechanisms with timely laryngeal closure to prevent aspiration [108].

Laryngotracheoesophageal Cleft

A laryngotracheoesophageal cleft (LTEC) is a result of an incomplete fusion of the tracheoesophageal septum occurring in the first 5–6 weeks of gestation. The most commonly used classification system is that of Benjamin and Inglis [109]. Under this scheme, a type 1 LTEC extends to but not through the level of the glottis, a type 2 extends into but through the cricoid, a type 3 extends through the cricoid but not into the thoracic inlet, and a type 4 extends into the thorax (Fig. 4). Types 3 and 4 LTEC usually present in the first few days of life with excessive airway secretions, airway obstruction, and respiratory distress. Types 1–2 LTEC present with non-specific respiratory symptoms such as cough, wheeze, and dysphagia. The diagnosis may be significantly delayed with many not diagnosed until 2–5 years of age [110]. Low-grade clefts therefore require a high index of suspicion to diagnose due to their non-specific symptoms and subtle appearance on bronchoscopy. Diagnosis is made by direct laryngoscopy and bronchoscopy with palpation of the

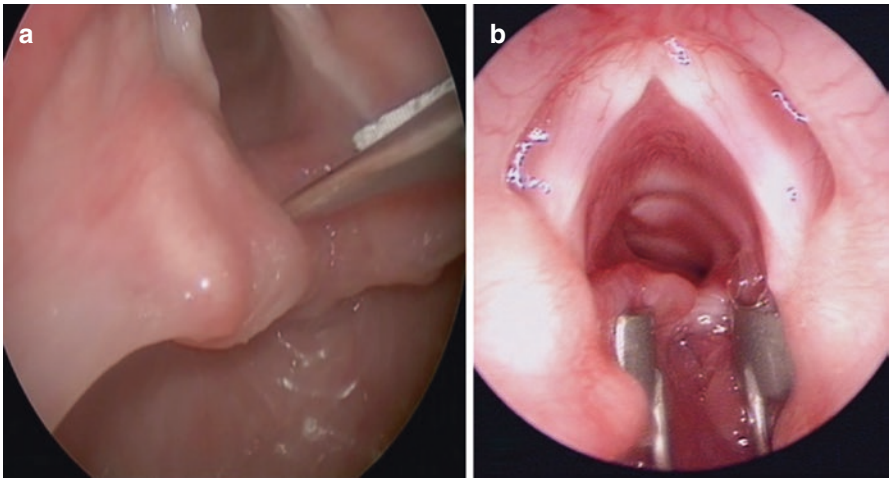

Fig. 4 Laryngotracheoesophageal clefts. (**a**) Type 1 laryngeal cleft extends into glottis but not into cricoid cartilage. (**b**) Type 3 laryngeal cleft extends through cricoid but not into thoracic inlet

interarytenoid notch. A deep interarytenoid notch is very difficult to differentiate from a type 1 LTEC; children with type 1 LTEC are likely to demonstrate some dysphagia, but not all will have evidence of penetration or aspiration. Silent aspiration has been described in 43% [111]. Treatment of a mild cleft therefore is driven primarily by evidence of aspiration or feeding problems that fail to improve with conservative treatment. Historically, the incidence of LTEC is reported as 1:10,000–1:20,000; types 1 and 2 LTEC are most common with recorded incidences of 4.4–7.1% of children undergoing direct laryngoscopy for recurrent respiratory symptoms [112–114]. Laryngeal clefts may occur in isolation or in association with other syndromes, such as with VACTERL or CHARGE association.

Types 3 and 4 laryngeal clefts require open repair with a multilayer closure. Conservative management with feeding therapy and thickened liquids is generally indicated as first-line therapy for types 1 and 2 LTEC and is effective in improving respiratory and feeding symptoms in ~50% [114, 115]. When significant respiratory or swallowing symptoms persist, there are various treatment options including injection of the interarytenoid notch. Cohen et al. reported complete resolution of penetration and aspiration in 56% and improvement in an additional 25% with treatment effect lasting a mean of 3.3 months [116]. Morbidity is low, and the injection may be used as a test of the functional significance of the shallow cleft prior to repeat injection or definitive treatment with surgical repair. Surgical closure is also commonly performed and can be done endoscopically for all types 1 and 2 clefts. Typical approach involves laryngeal suspension with denudation of the mucosa overlying the interarytenoid surfaces and suture closure. This procedure is well tolerated, and success rates to improve or resolve penetration and aspiration are reported to be >75% [110–115].

Tracheoesophageal Fistula

Tracheoesophageal fistulas (TEF) represent another abnormal connection between the gastrointestinal tract and the airway and is usually associated with esophageal atresia (EA) [117]. While the majority of TEF are associated with EA and diagnosed at birth, H-type TEF represents a bridging fistula between the trachea and esophagus without EA. Since these fistulas are small and the esophageal continuity is intact, H-type TEF are often diagnosed later as a cause of persistent nonspecific respiratory symptoms such as chronic cough, congestion, wheezing, dysphagia, and recurrent respiratory infection [118, 119]. Dysphagia and feeding problems commonly persist after a TEF is repaired, suggesting that the dysphagia is not only due to the abnormal anatomic connection [118–120]. Tracheoesophageal fistula may also be recurrent, with a rate of occurrence approaching 10% after initial repair, or secondary to injury such as endotracheal tube cuff or radiation [118, 121].

The embryologic development of a TEF usually results in U-shaped tracheal rings at the level of the fistula, which results in a wide posterior membrane. Tracheomalacia is nearly universal in patients with TEF and is a common contributor to persistent or recurrent respiratory symptoms. Additionally, there may be incorporation of esophageal mucosa within the posterior trachea, which impairs mucociliary clearance through this segment [122].

Symptoms attributable to tracheomalacia affect the majority of survivors after TEF repair and include chronic cough, recurrent lower respiratory tract infections, and wheezing. Most show significant improvement by age 10, but symptoms may persist in up to 10–40% of adults [118–120]. In addition, dysphagia and feeding difficulties are highly prevalent in children with a history of EA and may persist into adulthood [118, 120]. Owing to a lack of specific symptoms, chronic pulmonary aspiration, recurrent pulmonary infections, and chronic airway damage such as bronchiectasis may be attributed to alternate causes and/or remain unrecognized. As such, a high index of suspicion is warranted to avoid preventable morbidity and mortality [119].

Dysphagia and feeding difficulties are highly prevalent in children with a history of EA with a reported incidence of 21–84% and very commonly persisting into adulthood in almost half [118, 120]. The causes are multiple and include esophageal dysmotility, esophageal stricture, gastroesophageal reflux, severe tracheomalacia, recurrent or secondary TEF, and LTEC [118–120]. Esophageal dysmotility and gastroesophageal reflux are present to some extent in a large majority of EA patients and may be a cause for indirect aspiration. Performance of a fundoplication should be considered with caution in this population as the presence of the wrap may exacerbate the accumulation and reflux of esophageal contents or worsen food impaction. Interestingly, the rate of direct aspiration from swallowing dysfunction has been reported to be 30–37% [119, 123]. Pharyngeal aspiration may be a primary problem, a complication of repair (VFI in 3–17%), or due to a known coincidence of LTEC with TEF (27%) [124–126]. The commonness of significant long-term respiratory and gastroenterologic symptoms persisting after surgical repair warrants

regular follow-up by a multidisciplinary care team including pulmonologists, gastroenterologists, and otolaryngologists [119, 120].

Tracheostomy

Tracheostomy is a procedure commonly performed in pediatric patients, especially given increasing survivorship of children with chronic complex disease. Indications for tracheostomy include chronic respiratory failure secondary to neuromuscular or chronic lung disease. Additional indications include airway obstruction such as subglottic stenosis, vocal fold immobility, craniofacial abnormalities, and tracheomalacia [127–129]. Tracheostomy placement for prolonged mechanical ventilation is the fastest growing group [130–132]. The mortality rate for pediatric tracheostomy patients is 0.5–3.6% though this increases to 9–20% in children requiring tracheostomy for prolonged mechanical ventilation, mostly due to progression of underlying disease [133–135]. Most children requiring tracheostomy for non-neurologic reasons will eventually achieve decannulation, with or without surgical intervention [132, 136–138].

Placement of a tracheostomy tube results in several physiologic derangements [139]. Bypassing of the nose results in loss of local mucosal host defense and filtering, impaired warming and humidification of inspired gas, and diminished olfaction [140]. The presence of an open airway below the vocal folds reduces physiologic PEEP, and in infants, the loss of effective laryngeal braking may impair their ability to maintain adequate functional residual capacity [139]. Similarly, the impaired ability to increase pressure below a closed glottis during a cough will decrease the peak expiratory flow velocity moment required for an effective cough. Mucociliary clearance may be impaired due to the local effects of cool dry air on the tracheal mucosa, focal traumatic irritation and granulation tissue formation from the cannula, and an increase in airway inflammation [141–144]. These disruptions taken together place a child with a tracheostomy at increased risk for recurrent respiratory infection, mucus plugging, and difficulty ventilating [143, 144]. It can be difficult to differentiate the impact of the tracheostomy versus the underlying condition leading to the tracheostomy.

Dysphagia and aspiration are reported at a high rate in both adults and children with tracheostomy [145–147]. This may be related to their underlying condition and/or the tracheostomy tube itself. It is known that the presence of a tracheostomy tube itself affects swallowing, especially the pharyngeal phase. A tracheostomy prevents normal laryngeal elevation and which results in increased residue in the pyriform sinuses. Timeliness of pharyngeal swallow, laryngeal closure, and elevations of subglottic pressure are also expected to be impaired [139, 147, 148]. Additionally, early medical instability in infants undergoing tracheostomy often disrupts early feeding initiation and development, resulting in long-term feeding aversions and decreased parental bonding. The only study systematically evaluating swallowing dysfunction before and after tracheostomy placement is in adults and showed no

increased rate of aspiration after placement [149]. Also, in adult patients, swallowing dysfunction persists after decannulation [150]. There is conflicting evidence in adult patients that use of a one-way speaking valve may mitigate the physiologic dysfunction associated with tracheostomy and improve swallowing, but this has neither been demonstrated nor well-studied in children [151–156].

Approach

Aerodigestive Model

Overall there has been growth of a population of medically complex children who are responsible for 10–17% of hospital admissions and >50% of pediatric intensive care unit admissions [157, 158]. Many of these children have complex airway, feeding and respiratory problems which have a high degree of interaction, and overlapping, non-specific symptom presentation. Due to their complexity and need for invasive evaluation, these children are best managed within aerodigestive programs. These programs provide coordinated, interdisciplinary care by pulmonologists, otolaryngologists, gastroenterologists, speech language pathologists, and others, to provide timely diagnosis and integrated treatment plan with a single point of contact for the family. Key components of these programs include thorough pre-visit intake and obtaining of records, a prescheduled itinerary of consultations and diagnostic testing, shared clinic encounters, combined endoscopy (typically, flexible bronchoscopy with lavage, direct laryngoscopy and bronchoscopy, esophagogastroduodenoscopy) with other procedures as indicated, multidisciplinary team meeting to review results, and delivery of a unified care plan. Such programs have been developed in at least 30 states in the United States at the time of this writing. Data is emerging that demonstrates that care provided in this model reduces cost and time to accurate diagnosis. Additional expected benefits are found in less exposures to anesthesia and lowered burden of travel to families [159, 160]. Finally, there is evidence that this interdisciplinary team approach results in better operative outcomes in airway surgical patients and identifies unsuspected issues requiring management change in patients with repaired TEF [119, 161].

References

1. Kryger M, Bode F, Antic R, Anthonisen N. Diagnosis of obstruction of the upper and central airways. Am J Med. 1976;61(1):85–93.
2. Thompson DM. Laryngomalacia: factors that influence disease severity and outcomes of management. Curr Opin Otolaryngol Head Neck Surg. 2010;18:564–70.
3. Cooper T, Benoit M, Erickson B, El-Hakim H. Primary presentations of laryngomalacia. JAMA Otolaryngol Head Neck Surg. 2014;140(6):521–6.
4. Thevasagayam M, Rodger K, Cave D, Witmans M, El-Hakim H. Prevalence of laryngomalacia in children presenting with sleep-disordered breathing. Laryngoscope. 2010;120(8):1662–6.

5. Richter GT, Rutter MJ, deAlarcon A, Orvidas LJ, Thompson DM. Late-onset laryngomalacia. Arch Otolaryngol Head Neck Surg. 2008;134(1):75–80.
6. Matthews BL, Little JP, McGuirt WF, Koufman JA. Reflux in infants with laryngomalacia: results of 24-h double-probe pH monitoring. Otolaryngol Head Neck Surg. 1999;120:860–4.
7. Bibi H, Khvolis E, Shoseyov D, Ohaly M, Dor DB, London D, et al. The prevalence of gastroesophageal reflux in children with tracheomalacia and laryngomalacia. Chest. 2001;119:409–13.
8. Suskind DL, Thompson DM, Gulati M, Huddleston P, Liu DC, Baroody FM. Improved infant swallowing after gastroesophageal reflux disease treatment: a function of laryngeal sensation? Laryngoscope. 2006;116(8):1397–403.
9. Hartl TT, Chadha NK. A systematic review of laryngomalacia and acid reflux. Otolaryngol Head Neck Surg. 2012;147(4):619–26.
10. Petersson RS, Wetjen NM, Thompson DM. Neurologic variant laryngomalacia associated with Chiari malformation and cervicomedullary compression: case reports. Ann Otol Rhinol Laryngol. 2011;120(2):99–103.
11. Liu C, Ulualp SO. Type 1 Chiari malformation presenting with laryngomalacia and dysphagia. Pediatr Int. 2015;57(4):795–7.
12. Bertrand P, Navarro H, Caussade S, Holgren N, Sánchez I. Airway anomalies in children with down syndrome: endoscopic findings. Pediatr Pulmonol. 2003;36(2):137–41.
13. Krashin E, Ben-Ari J, Springer C, Derowe A, Avital A, Sivan Y. Synchronous airway lesions in laryngomalacia. Int J Pediatr Otorhinolaryngol. 2008;72(4):501–7.
14. Dickson JM, Richter GT, Meinzen-Derr J, Rutter MJ, Thompson M. Secondary airway lesions in infants with laryngomalacia. Ann Otol Rhinol Laryngol. 2009;118(1):37–43.
15. Schroeder JW Jr, Bhandarkar ND, Hollinger LD. Synchronous airway lesions and outcomes in infants with severe laryngomalacia requiring supraglottoplasty. Arch Otolaryngol Head Neck Surg. 2009;135:647–51.
16. Preciado D, Zalzal G. A systematic review of supraglottoplasty outcomes. Arch Otolaryngol Head Neck Surg. 2012;138(8):718–21.
17. Durvasula VSPB, Lawson BR, Bower CM, Richter GT. Supraglottoplasty in premature infants with laryngomalacia: does gestational age at birth influence outcomes? Otolaryngol Head Neck Surg. 2014;150(2):292–9.
18. Durvasula VSPB, Lawson BR, Bower CM, Richter GT. Supraglottoplasty in neurologically affected and syndromic children. JAMA Otolaryngol Head Neck Surg. 2014;140(8):704–11.
19. Richter GT, Wootten CT, Rutter MJ, Thompson DM. Impact of supraglottoplasty on aspiration in severe laryngomalacia. Ann Oto Rhinol Laryngol. 2009;118(4):259–66.
20. Farhood Z, Ong AA, Nguyen SA, Gillespie MB, Discolo CM, White DR. Objective outcomes of supraglottoplasty for children with laryngomalacia and obstructive sleep apnea. A meta-analysis. JAMA Otolaryngol Head Neck Surg. 2016;142(7):665–71.
21. De Gaudemar I, Roudaire M, Francois M, Narcy P. Outcome of laryngeal paralysis in neonates: a long term retrospective study of 113 cases. Int J Pediatr Otorhinolaryngol. 1996;34:101–10.
22. Chen EY, Inglis AF. Bilateral vocal cord paralysis in children. Otolaryngol Clin N Am. 2008;41:889–901.
23. Jabbour J, Martin T, Beste D, Robey T. Pediatric vocal fold immobility. Natural history and the need for long-term follow-up. JAMA Otolaryngol Head Neck Surg. 2014;140(5):428–33.
24. Rosin DF, Handler SD, Potsic WP, Wetmore RF, Tom LW. Vocal cord paralysis in children. Laryngoscope. 1990;100(11):1174–9.
25. Miyamoto RC, Parikh SR, Gellad W, Licameli GR. Bilateral congenital vocal cord paralysis: a 16-year review. Otolaryngol Head Neck Surg. 2005;133:241–5.
26. Lesnik M, Thierry B, Blanchard M, Glynn F, Denoyelle F, Couloigner V, et al. Idiopathic bilateral vocal cord paralysis in infants: case series and literature review. Laryngoscope. 2015;125:1724–8.
27. Butskiy O, Mistry B, Chadha NK. Surgical interventions for pediatric unilateral vocal cord paralysis. A systematic review. JAMA Otolaryngol Head Neck Surg. 2015;141(7):654–60.

28. Dewan K, Cephus C, Owczarzak V, Ocampo E. Incidence and implication of vocal fold paresis following neonatal cardiac surgery. Laryngoscope. 2012;122:2781–5.
29. Richter AL, Ongkasuwan J, Ocampo E. Long-term follow-up of vocal cord movement impairment and feeding after neonatal cardiac surgery. Int J Pediatr Otorhinolaryngol. 2016;83:211–4.
30. Clement WA, El-Hakim H, Phillipos EZ, Coté JJ. Unilateral vocal cord paralysis following patent ductus arteriosus ligation in extremely low-birth-weight infants. Arch Otolaryngol Head Neck Surg. 2008;134(1):28–33.
31. Connor MS, Cohen SB, Theis SM, Thibeault SL, Heatley DG, Bless DM. Attitudes of children with dysphonia. J Voice. 2008;22(2):197–209.
32. Schott SR. Down syndrome: analysis of airway size and guide for appropriate intubation. Laryngoscope. 2000;11:585–92.
33. Hamilton J, Yaneza MM, Clement WA, Kubba H. The prevalence of airway problems in children with Down's syndrome. Int J Pediatr Otorhinolaryngol. 2016;81(1–4)
34. Jefferson ND, Cohen AP, Rutter MJ. Subglottic stenosis. Semin Pediatr Surg. 2016;25(3):138–43.
35. Chun R, Preciado DA, Zalzal GH, Shah RK. Utility of bronchoscopy for recurrent croup. Ann Otol Rhinol Laryngol. 2009;118(7):495–9.
36. Hodnett BL, Simons JP, Riera KM, Mehta DK, Maguire RC. Objective findings in patients with recurrent croup: 10 year retrospective analysis. Int J Pediatr Otorhinolaryngol. 2015;79(12):2343–7.
37. Nicklaus PJ, Crysdale WS, Conley S, White AK, Sendi K, Forte V. Evaluation of neonatal subglottic stenosis: a 3-year prospective study. Laryngoscope. 1990;100(11):1185–90.
38. Grundfast KM, Camilon FS Jr, Pranksy S, Barber CS, Fink R. Prospective study of subglottic stenosis in intubated neonates. Ann Otol Rhinol Laryngol. 1990;99:390–5.
39. Choi SS, Zalzal GH. Changing trends in neonatal subglottic stenosis. Otolaryngol Head Neck Surg. 2000;122(1):61–3.
40. Walner DL, Loewen MS, Kimura RE. Neonatal subglottic stenosis- incidence and trends. Laryngoscope. 2001;111(1):48–51.
41. Schweiger C, Manica D, Kuhl G, Sekine L, Marostica PJ. Post-intubation acute laryngeal injuries in infants and children: a new classification system. Int J Pediatr Otorhinolaryngol. 2016;86:177–82.
42. Myer CM, O'Connor DM, Cotton RT. Proposed grading system for subglottic stenosis based on endotracheal tube sizes. Ann Otol Rhinol Laryngol. 1994;103:319–23.
43. Smith LP, Zur KB, Jacobs IN. Single vs double-stage laryngotracheal reconstruction. Arch Otolaryngol Head Neck Surg. 2010;136(1):60–5.
44. Dahl JP, Purcell PL, Parikh SR, Inglis AF. Endoscopic posterior cricoid split with costal cartilage graft: a fifteen-year experience. Laryngoscope. 2016; PMID: 27470697.
45. Maresh A, Preciado DA, O'Connell AP, Zalzal GH. A comparative analysis of open surgery vs endoscopic balloon dilation for pediatric subglottic stenosis. JAMA Otolaryngol Head Neck Surg. 2014;140(10):901–5.
46. Quesnel AM, Lee GS, Nuss RC, Volk MS, Jones DT, Rahbar R. Minimally invasive endoscopic management of subglottic stenosis in children. Int J Pediatr Otorhinolaryngol. 2011;75:652–6.
47. Lang ML, Brietzke SE. A systematic review and meta-analysis of endoscopic balloon dilation of pediatric subglottic stenosis. Otolaryngol Head Neck Surg. 2014;150(2):174–9.
48. Schweiger C, Manica D, Kuhl G. Glossoptosis. Semin Pediatr Surg. 2016;25:123–7.
49. Scott AR, Mader NS. Regional variations in the presentation and surgical management of Pierre Robin sequence. Laryngoscope. 2014;124:2818–25.
50. Breugem CC, Evans KN, Poets CF, Suri S, Picard A, Filip C, et al. Best practices for the diagnosis and evaluation of infants with Robin sequence. A clinical consensus report. JAMA Pediatr. 2016;170(9):894–902.
51. Baudon JJ, Renault F, Goutet JM, Flores-Guevara R, Soupr V, Gold F, et al. Motor dysfunction of the upper digestive tract in Pierre Robin sequence as assessed by sucking-swallowing electromyography and esophageal manometry. J Pediatr. 2002;140(6):719–23.

52. Anderson IC, Sedaghat AR, McGinley BM, Redett RJ, Boss EF, Ishman SL. Prevalence and severity of obstructive sleep apnea and snoring in infants with Pierre Robin sequence. Cleft Palate Craniofac J. 2011;48(5):614–8.
53. Miller CK. Feeding issues and interventions in infants and children with clefts and craniofacial syndromes. Semin Speech Lang. 2011;32(2):115–26.
54. Smith MC, Senders CW. Prognosis of airway obstruction and feeding difficulty in the Robin sequence. Int J Pediatr Otorhinolaryngol. 2006;70:319–24.
55. Gasparin M, Schweiger C, Manica D, Maciel AC, Kuhl G, Levy DS, et al. Accuracy of clinical swallowing evaluation for diagnosis of dysphagia in children with laryngomalacia or glossoptosis. Pediatr Pulmonol. 2017;52(1):41–7. https://doi.org/10.1002/ppul.23484.
56. Breik O, Umapathysivam K, Tivey D, Anderson P. Feeding and reflux in children after mandibular distraction: a systematic review. Int J Pediatr Otorhinolaryngol. 2016;85:128–35.
57. Lee JJ, Thottam PJ, Ford MD, Jabbour N. Characteristics of sleep apnea in infants with Pierre-Robin sequence: is here improvement with advancing age? Int J Pediatr Otorhinolaryngol. 2015;79:2059–67.
58. Ow AT, Cheung LK. Meta-analysis of mandibular distraction osteogenesis: clinical application and functional outcomes. Plast Reconstr Surg. 2008;121:54e–69e.
59. Breik O, Umapathysivam K, Tivey D, Anderson P. Mandibular distraction osteogenesis for the management of upper airway obstruction in children with micrognathia: a systematic review. Int J Oral Maxillofac Surg. 2016;45:769–82.
60. Scott AR, Tibesar RJ, Lander TA, Sampson DE, Sidman JD. Mandibular distraction osteogenesis in infants younger than 3 months. Arch Facial Plast Surg. 2011;13(3):173–9.
61. Denny AD, Amm CA, Schaefer RB. Outcomes of tongue-lip adhesion for neonatal respiratory distress caused by Pierre-Robin sequence. J Craniofac Surg. 2004;15:819–23.
62. Papoff P, Guelfi G, Cicchetti R, Caresta E, Cozzi DA, Moretti C, et al. Outcomes after tongue-lip adhesion or mandibular distraction osteogenesis in infants with Pierre Robin sequence and severe airway obstruction. Int J Oral Maxillofac Surg. 2013;42:1418–23.
63. Flores RL, Tholpady SS, Sati S, Fairbanks G, Socas J, Choi M, et al. The surgical correction of Pierre Robin sequence: mandibular distraction osteogenesis versus tongue-lip adhesion. Plast Reconstr Surg. 2014;133:1433–9.
64. Schellhase DE, Fawcett DD, Schutze GE, Lensing SY, Tryka AF. Clinical utility of flexible bronchoscopy and bronchoalveolar lavage in young children with recurrent wheezing. J Pediatr. 1998;132:312–8.
65. Saito J, Harris WT, Gelfond J, Noah TL, Leigh MW, Johnson R, et al. Physiologic, bronchoscopic, and bronchoalveolar lavage fluid findings in young children with recurrent wheeze and cough. Pediatr Pulmonol. 2006;41:709–19.
66. Cakir E, Ersu RH, Uyan ZS, Oktem S, Karadag B, Yapar O, et al. Flexible bronchoscopy as a valuable tool in the evaluation of persistent wheezing in children. Int J Pediatr Otorhinolaryngol. 2009;73:1666–8.
67. De Baets F, De Schutter I, Aarts C, Haerynck F, Van daele S, De Wachter E, et al. Malacia, inflammation, and bronchoalveolar lavage culture in children with persistent respiratory symptoms. Eur Respir J. 2012;39:392–5.
68. Ren CL, Esther CR, Debley JS, Sockrider M, Yilmaz O, Amin N, et al. Official American Thoracic Society clinical practice guidelines: diagnostic evaluation of infants with recurrent r persistent wheezing. Am J Respir Crit Care Med. 2016;194(3):356–73.
69. Hayden L, Boyer D, Hysinger EB, Moore PE, Faro A, Wilson KC, et al. Flexible airway endoscopy in children. Ann Am Thorac Soc. 2015;12(12):1873–5.
70. Boogaard R, Huijsmans SH, Pijnenburg MW, Tiddens HA, de Jongste JC, Merkus PJ. Tracheomalacia and bronchomalacia in children: incidence and patient characteristics. Chest. 2005;128(5):3391–7.
71. DeBoer EM, Prager JD, Ruiz AG, Jensen EL, Deterding RR, Friedlander JA, et al. Multidisciplinary care of children with repaired esophageal atresia and tracheoesophageal fistula. Pediatr Pulmonol. 2016;51(6):576–81.

72. Hysinger EB, Panitch HB. Pediatric tracheomalacia. Paediatr Respir Rev. 2016;17:9–15.
73. Kompare M, Weinberger M. Protracted bacterial bronchitis in young children: association with airway malacia. J Pediatr. 2012;160:88–92.
74. Wittenborg MH, Gyepes MT, Crocker D. Tracheal dynamics in infants with respiratory distress, stridor, and collapsing trachea. Radiology. 1967;88(4):653–62.
75. Sanchez MO, Greer MC, Masters IB, Chang AB. A comparison of fluoroscopic airway screening with flexible bronchoscopy for diagnosing tracheomalacia. Pediatr Pulmonol. 2012;47:63–7.
76. Su SC, Masters IB, Buntain H, Frawley K, Sarikwal A, Watson D, et al. A comparison of virtal bronchoscopy versus flexible bronchoscopy in the diagnosis of tracheobronchomalacia in children. Pediatr Pulmonol. 2016; .PMID: 27641078. https://doi.org/10.1002/ppul.23606.
77. Panitch HB, Keklikian EN, Motley RA, Wolfson MR, Shidlow DV. Effect of altering smooth muscle tone on maximal expiratory flows in patients with tracheomalacia. Pediatr Pulmonol. 1990;9:170–6.
78. Torre M, Calucci M, Speggiorin S, Elliott M. Aortopexy for the treatment of tracheomalacia in children: review of the literature. Ital J Pediatr. 2012;38:62–70.
79. Calkoen EE, Gabra HOS, Roebuck DJ, Kiely E, Elliott MJ. Aortopexy as a treatment for trachea-bronchomalacia in children: an 18-year single-center experience. Pediatr Crit Care Med. 2011;12:545–51.
80. de Trey LA, Dudley J, Ismail-Koch H, Durward A, Bellsham-Revell H, Blaney S, et al. Treatment of severe tracheobornchomalacia: ten-year experience. Int J Pediatr Otorhinolaryngol. 2016;83:57–62.
81. Antón-Pacheco JL, Cabezalí D, Tejedor R, López M, Luna C, Comas JV, et al. The role of airway stenting in pediatric tracheobronchial obstruction. Eur J Cardiothorac Surg. 2008;33(6):1069–75.
82. Fayon M, Donato L, de Blic J, Labbé A, Becmeur F, Mely L, et al. French experience of silicone tracheobronchial stenting in children. Pediatr Pulmonol. 2005;39(1):21–7.
83. Antón-Pacheco JL. Tracheobronchial stents in children. Semin Pediatr Surg. 2016;25:179–85.
84. Antón-Pacheco JL, Luna C, García E, López M, Moranta R, Tordable C, et al. Initial experience with a new biodegradable airway stent in children: is this the stent we were waiting for? Pediatr Pulmonol. 2016;51:607–12.
85. Grillo HC. Slide tracheoplasty for long-segment congenital tracheal stenosis. Ann Thorac Surg. 1994;58(3):613–9.
86. Grillo HC, Zannini P. Management of obstructive tracheal disease in children. J Pediatr Surg. 1984;19(4):414–6.
87. Hofferberth SC, Watters K, Rahbar R, Fynn-Thompson F. Management of congenital tracheal stenosis. Pediatrics. 2015;136(3):e660–9.
88. Fiore AC, Brown JW, Weber TR, Turrentine MW. Surgical treatment of pulmonary artery sling and tracheal stenosis. Ann Thorac Surg. 2005;79:38–46.
89. Rutter MJ, Cotton RT, Azizkhan RG, Manning PB. Slide tracheoplasty for the management of complete tracheal rings. J Pediatr Surg. 2003;38(6):928–34.
90. Butler CR, Speggiorin S, Rijnberg RDJ, Muthialu N, Hewitt RJ, et al. Outcomes of slide tracheoplasty in 101 children: a 17-year single-center experience. J Thorac Cardiovasc Surg. 2014;147:1783–90.
91. Manning PB, Rutter MJ, Border WL. Slide tracheoplasty in infants and children: risk factors for prolonged ventilator support. Ann Thorac Surg. 2008;85:1187–92.
92. DeMarcantonio MA, Hart CK, Yang CJ, Tabangin M, Rutter MJ, Bryant R, et al. Slide tracheoplasty outcomes in children with congenital pulmonary malformations. Laryngoscope. 2016;127:1283–7. https://doi.org/10.1002/lary.26404.
93. Fanous N, Husain SA, Ruzmetov M, Rodefeld MD, Turrentine MW, Brown JW. Anterior pericardial tracheoplasty for long-segment tracheal stenosis: long-term outcomes. J Thorac Cardiovasc Surg. 2010;139(1):18–23.
94. Backer CL, Mavroudis C, Gerber ME, Holiger LD. Tracheal surgery in children: an 18-year review of four techniques. Eur J Cardiothorac Surg. 2001;19(6):777–84.

95. Maeda K, Ono S, Tazuke Y, Baba K. Long-term outcomes of congenital tracheal stenosis treated by metallic airway stenting. J Pediatr Surg. 2013;48(2):293–6.
96. Rutter MJ, Willging JP, Cotton RT. Nonoperative management of complete tracheal rings. Arch Otolaryngol Head Neck Surg. 2004;130(4):450–2.
97. Antón-Pacheco JL, Cano I, García A, Martínez A, Cuadros J, Berchi FJ. Patterns of management of congenital tracheal stenosis. J Pediatr Surg. 2003;38(10):1452–8.
98. Manson D, Filler R, Gordon R. Tracheal growth in congenital tracheal stenosis. Periatr Radiol. 1996;26:427–30.
99. Sunwoo WS, Cha W, Song CM, Sung MW, Kim KH, Kwon TK. Tracheal growth after airway stenosis surgery: serial radiographic comparative study. Acta Otolaryngol. 2012;132:S124–9.
100. Conley SF, Beecher RB, Delaney AL, Norins NA, Simpson PM, Li SH. Outcomes of tonsillectomy in neurologically impaired children. Laryngoscope. 2009;119:2231–41.
101. Bock JM, Trask DK. Coblation-assisted lingual tonsillectomy for dysphagia secondary to tongue base hypertrophy. Ann Otol Rhinol Laryngol. 2008;117:506–9.
102. Zanation AM, Senior BA. The relationship between extraesophageal reflux (EER) and obstructive sleep apnea (OSA). Sleep Med Rev. 2005;9(6):453–8.
103. Boesch RP, Shah P, Vaynblat M, Marcus M, Narwal S, Kazachkov M. Relationship between upper airway obstruction and gastroesophageal reflux in a Dog model. J Investig Surg. 2005;18(5):241–5.
104. Weir K, McMahon S, Barry L, Masters IB, Chang AB. Clinical signs and symptoms of oropharyngeal aspiration and dysphagia in children. Eur Respir J. 2009;33:604–11.
105. Piccione JC, McPhail GL, Fenchel MC, Brody AS, Boesch RP. Bronchiectasis in chronic pulmonary aspiration: risk factors and clinical implications. Pediatr Pulmonol. 2012;47:447–52.
106. Adil E, Gergin KK, Rahbar R, Watters K. Usefulness of upper airway endoscopy in the evaluation of pediatric pulmonary aspiration. JAMA Otolaryngol Head Neck Surg. 2016;142(4):339–43.
107. Miller CK, Linck J, Willging JP. Duration and extent of dysphagia following pediatric airway reconstruction. Int J Pedaitr Otorhinolaryngol. 2009;73:573–9.
108. Miller CK, Kelchner LN, de Alarcon A, Willging JP. Compensatory laryngeal function and airway protection in children following airway reconstruction. Ann Otol Rhinol Laryngol. 2014;123(5):305–13.
109. Benjamin B, Inglis A. Minor congenital laryngeal clefts: diagnosis and classification. Ann Otol Rhinol Laryngol. 1989;98(6):417–20.
110. Johnston DR, Watters K, Ferrari LR, Rahbar R. Laryngeal cleft: evaluation and management. Int J Pediatr Otorhinolaryngol. 2014;78:905–11.
111. Strychowshy JE, Dodrill P, Moritz E, Perez J, Rahbar R. Swallowing dysfunction among patients with laryngeal cleft: more than just aspiration? Int J Pediatr Otorhinolaryngol. 2016;82:38–42.
112. Parson DS, Stivers FE, Giovanetto DR, Phillips SE. Type 1 posterior laryngeal clefts. Laryngoscope. 1998;108:403–10.
113. Watters K, Russel J. Diagnosis and management of type 1 laryngeal cleft. Int J Pediatr Otorhinolaryngol. 2003;67:591–6.
114. Ojha S, Ashland JE, Hersh C, Ramakrishna J, Maurer R, Hartnick CJ. Type 1 laryngeal cleft. A multidimensional management algorithm. JAMA Otolaryngol Head Neck Surg. 2014;140(1):34–40.
115. Rahbar R, Chen JL, Rosen RL, Lowry KC, Simon DM, Perez JA, et al. Endoscopic repair of laryngeal cleft type 1 and type 2: when and why? Laryngoscope. 2009;119:1797–802.
116. Cohen MS, Zhuang L, Simons JP, Chi DH, Maguire RC, Mehta DK. Injection laryngoplasty for type 1 laryngeal cleft in children. Otolaryngol Head Neck Surg. 2011;144(5):789–93.
117. Shaw-Smith C. Oesophageal atresia, trachea-oesophageal fistula, and the VACTERL association: review of genetics and epidemiology. J Med Genet. 2006;43:545–54.
118. Kovesi T, Rubin S. Long-term complications of congenital esophageal atresia and/or tracheoesophageal fistula. Chest. 2004;126:915–25.

119. DeBoer EM, Prager JD, Ruiz AG, Jensen EL, Deterding RR, Friedlander JA, et al. Multidisciplinary care of children with repaired esophageal atresia and tracheoesophageal fistula. Pediatr Pulmonol. 2015;51:576–81.
120. Krishnan U, Mousa H, Dall'Oglio L, Homaira N, Rosen R, Faure C, et al. ESPGHAN-NASPGHAN guidelines for the evaluation and treatment of gastrointestinal and nutritional complications in children with esophageal atresia-tracheoesophageal fistula. J Pediatr Gastroenterol Nutr. 2016;63:550–70.
121. Provenzano MJ, Rutter MJ, von Allmen D, Manning PB, Boesch RP, Putnam PE, et al. Slide tracheoplasty for the treatment of tracheoesophageal fistulas. J Pediatr Surg. 2014;49(6):910–4.
122. Emery JL, Haddadin AJ. Squamous epithelium in respiratory tract of children with tracheaoesophageal fistula. Arch Dis Child. 1971;46:236–42.
123. Hörmann M, Pokieser P, Scharitzer M, Pumberger W, Memarsadeghi M, Partik B, Ekberg O. Videofluroscopy of deglutition in children after repair of esophageal atresia. Acta Radiol. 2002;43(5):507–10.
124. Fraga JC, Adil EA, Kacprowwicz A, Skinner ML, Jennings R, Lellehei C, et al. The association between laryngeal cleft and tracheoesophageal fistula: myth or reality? Laryngoscope. 2015;125:469–74.
125. Morini F, Iacobelli BD, Crocoli A, Bottero S, Trozzi M, Conforti A, et al. Symptomatic vocal cord paresis/paralysis in infants operated on for esophageal atresia and/or tracheo-esophageal fistula. J Pediatr. 2011;158(6):973–6.
126. Mortellaro VE, Pettiford JN, St Peter SD, Fraser JD, Ho B, Wei J. Incidence, diagnosis, and outcomes of vocal fold immobility after esophageal atresia (EA) and/or tracheoesophageal fistula (TEF) repair. Eur J Pediatr Surg. 2011;21(6):386–8.
127. Knollman PD, Baroody FM. Pediatric tracheotomy decannulation: a protocol for success. Curr Opin Otolaryngol Head Neck Surg. 2015;23(6):485–90.
128. Prickett KK, Sobol SE. Inpatient observation for elective decannulation of pediatric patioents with tracheostomy. JAMA Otolaryngol Head Neck Surg. 2015;141(2):120–5.
129. Wiritz N, Tibesar RJ, Lander T, Sidman J. A pediatric decennulation protocol: outcomes of a 10-year experience. Otolaryngol Head Neck Surg. 2016;154(4):731–4.
130. Gowans M, Keenan HT, Bratton SL. The population prevalence of children receiving invasive home ventilation in Utah. Pediatr Pulmonol. 2007;42(3):231–6.
131. Graham RJ, Fleegler EW, Robinson WM. Chronic ventilagtor need in the community: a 2005 pediatric census of Massachusetts. Pediatrics. 2007;199(6):e1280–7.
132. Cristea AI, Carroll AE, Davis SD, Swigonski NL, Ackerman VL. Outcomes of children with severe bronchopulmonary dysplasia who were ventilator dependent at home. Pediatrics. 132(3):e727–34.
133. Edwards JD, Kun SS, Keens TG. Outcomes and causes of death in children on home mechanical ventilation via tracheostomy: an institutional and literature review. J Pediatr. 2010;157(6):955–9.
134. Com G, Kuo DZ, Bauer ML, Lenker CV, Melguizo-Castro MM, Nick TG, et al. Outcomes of children trated with tracheostomy and positive-pressure ventilation at home. Clini Pediatr. 2013;51(1):54–61.
135. Henningfeld JK, Maletta K, Ren B, Richards KL, Wegner C, D'Andrea LA. Liberation from home mechanical ventilation and decannulation in children. Pediatr Pulmonol. 2016;51(8):838–49.
136. Mahadevan M, Barber C, Salkeld L, Mills DG. Pediatric tracheostomy: 17-year review. Int J Pediatri Otorhinolaryngol. 2007;71(12):1829–35.
137. Sidman JD, Jaguan A, Couser RJ. Tracheostomy and decannulation rates in a level 3 neonatal intensive care unit: a 12-year study. Laryngoscope. 2006;116(1):136–9.
138. Overman AE, Liu M, Kurachek SC, Shreve MR, Maynard RC, Mammel MC, et al. Pediatrics. 2013;131(5):e1491–6.
139. Buckwalter JA, Sasaki CT. Effect of tracheotomy on laryngeal function. Otolaryngol Clin N Am. 1984;17(1):41–8.
140. Kennedy WP, Lewis CP, Stow J, Sobol SE. A critical period in post-nasal neuroplasticity of olfaction. A pediatric tracheostomy model. JAMA Otolaryngol Head Neck Surg. 2016;142(2):127–31.

141. Yadav SPS, Janab KS, Singh J, Ranga RK. Nasal mucociliary clearance in patients with tracheostomy. Indian J Otolaryngol Head Neck Surg. 2003;55(2):73–5.
142. McNamara DG, Asher MI, Rubin BK, Stewart A, Byrnes CA. Heated humidification improves clinical outcomes, compared to a heat and moisture exchanger in children with tracheostomy. Respir Care. 2014;59(1):46–53.
143. Griese M, Felber J, Reiter K, Strong P, Reid K, Belohradsky BH, et al. Airway inflammation in children with tracheostomy. Pediatr Pulmonol. 2004;37(4):356–61.
144. Al-Samri M, Mitchell I, Drummond DS, Bjornson C. Tracheostomy in children: a population-based experience over 17 years. Pediatr Pulmonol. 2010;45:487–93.
145. Norman V, Louw B, Kritzunger A. Incidence and description of dysphagia in infants and toddlers with tracheostomies: a retrospective review. Int J Pediatr Otorhinolaryngol. 2007;71:1087–92.
146. Leder SB, Baker KE, Goodman TR. Dysphagia testing and aspiration status in medically stable infants requiring mechanical ventilation via tracheotomy. Pediatr Crit Care Med. 2010;11(4):484–7.
147. Abraham S, Wolf EL. Swallowing physiology of toddlers with long-term tracheostomies: a preliminary study. Dysphagia. 2000;15:206–12.
148. Eibling DE, Gross RD. Subglottic air pressure: a key component of swallowing efficiency. Ann Otol Rhinol Laryngol. 1996;105:253–8.
149. Leder SB, Ross DA. Investigation of the causal relationship between tracheostomy and aspiration in the acute care setting. Laryngoscope. 2000;110:641–4.
150. DeVita MA, Spierer-Rundback L. Swallowing disorders in patients with prolonged orotracheal intubation or tracheostomy tubes. Crit Care Med. 1990;18:1328–30.
151. Stachler RJ, Hamlet SL, Choi J, Flemming S. Scintigraphic quantification aspiration reduction with the Passy-Muir valve. Laryngoscope. 1996;106:231–4.
152. Elpern EH, Borkgren Okonek M, Bacon M, Gerstung C, Skrzynski M. Effect of the Passy-Muir tracheostomy speaking valve on pulmonary aspiration in adults. Heart Lung. 2000;29:287–93.
153. Gross RD, Mahlmann J, Grayhack JP. Physiologic effects of open and closed tracheostomy tubes on the pharyngeal swallow. Ann Otol Rhinol Laryngol. 2003;112(2):143–52.
154. Srinet P, Van Daele DJ, Adam SI, Burrell MI, Aronberg R, Leder SB. A biomechanical study of hyoid bone and laryngeal movements during swallowing comparing the Blom low profile voice inner cannula and Passy-Muir one way tracheostomy tube speaking valves. Dysphagia. 2015;30(6):723–9.
155. Hull EM, Dumas HM, Crowley RA, Kharasch VS. Tracheostomy speaking valves for children: tolerance and clinical benefits. Pediatr Rehabil. 2005;8(3):214–9.
156. Ongkasuwan J, Turk CL, Rapazzo CA, Lavergne KA, O'Brian Smith E, Friedman EM. The effect of a speaking valve on laryngeal aspiration and penetration in children with tracheostomies. Laryngoscope. 2014;124:1469–74.
157. Burns KH, Casey PH, Lyle RE, Bird TM, Fussell JJ, Robbins JM. Increasing prevalence of medically complex children in US hospitals. Pediatrics. 2010;126(4):638–46.
158. Chan T, Rodean J, Richardson T, Farris RW, Bratton SL, Di Gennaro JL, et al. Pediatric critical care resource use by children with medical complexity. J Pediatr. 2016;177:197–203.
159. Collaco JM, Aherrera AD, Au Yeung KJ, Lefton-Greif MA, Hoch J, Skinner ML. Interdisciplinary pediatric aerodigestive care and reduction in health care costs and burden. JAMA Otolaryngol Head Neck Surg. 2015;141(2):101–5.
160. Skinner ML, Lee SK, Collaco JM, Lefton-Greif MA, Hoch J, Au Yeung KJ. Financial and health impacts of multidisciplinary aerodigestive care. Otolaryngol Head Neck Surg. 2016;154(6):1064–7.
161. Kocyildirim E, Kanani M, Roebuck D, Wallis C, McLAren C, Noctor C, et al. Long-segment tracheal stenosis: slide tracheoplasty and a multidisciplinary approach improve outcomes and reduce costs. J Thorac Cardiovasc Surg. 2004;128(6):876–82.

Pulmonary Complications of Chest Wall Disorders

Oscar Henry Mayer

Introduction

The chest wall and spine are integrated together and are interdependent and critical in maintaining an upright posture, and facilitating optimal pulmonary mechanics and function. The integrity of the thoracospinal unit can be impacted substantially by dysfunction in either the chest wall or spine. Understanding how they are related is important and can help determine the proper way to treat the dysfunction.

This chapter will include a discussion on the interplay between the chest wall and spine, the concepts and causes of chest wall and spine dysfunction, the types of disorders, and a finish with an analysis of five disparate disorders and the treatment options that are often used.

The Thoracospinal Unit

Mechanically, the thoracospinal unit is composed of four major parts. At its core is the spinal column from which there are 12 pairs of ribs that provide the rigid component of the posterior, lateral, and a portion of the anterior chest wall. The connection between the ribs and spine is through a series of joints between the body and lateral processes of the vertebra and each rib. The superior most ten ribs are then connected to the sternum via a series of cartilage segments to form the anterior portion of the chest wall and with the anterior end of the ribs provide the major

O.H. Mayer, M.D.
Division of Pulmonary Medicine, Pulmonary Function Testing Laboratory, The Children's Hospital of Philadelphia, Perelman School of Medicine at the University of Pennsylvania, Philadelphia, PA, USA
e-mail: MAYERO@email.chop.edu

© Springer International Publishing AG 2018

A.C. Koumbourlis, M.A. Nevin (eds.), *Pulmonary Complications of Non-Pulmonary Pediatric Disorders*, Respiratory Medicine,
https://doi.org/10.1007/978-3-319-69620-1_6

component of chest wall growth. Finally, there are multiple ligaments maintaining the positioning of the costovertebral and intervertebral joints and a complex array of muscles that help to maintain proper posture, an optimal mechanical position for the thorax and spine, and then to move the thorax during breathing.

During inspiration, the thorax increases in cross-sectional area as the external intercostal muscles contract and elevate the ribs anteriorly ("pump-handle effect") and laterally ("bucket-handle effect"), while the diaphragm contracts caudally and in pressing downward on the abdominal contents moves the lower edge of the rib cage outward ("fulcrum effect").

The thoracospinal unit can be impacted both by defective bony structure and inadequate support. If the spine is considered a "tower of blocks," then if one of the vertebra is not perfectly rectangular or is misshapen or not the normal size, then the spine becomes unstable and will tilt to the side of the deformity. If there is a problem of spinal segmentation and the vertebra are fused unilaterally or bilaterally, there will be scoliosis or a short spine, respectively. If the tension in the ligaments or muscles is higher on one side of the spine than the other, then spine will gradually curve to the hypertonic side (Fig. 1).

If there is inadequate separation of the ribs or rib fusion, this will become a tethering point around which the chest wall and spine will grow and gradually produce curve concave to the side with the fusion (Fig. 2). Similarly, if there is absence of ribs and lateral chest wall support, even without spinal dysplasia, a scoliosis will develop concave to the side of the absent ribs (Fig. 3).

The thoracospinal disorders that come from deficiencies listed above can be placed into one of five categories: (1) Inadequate chest wall and spine formation produces early onset scoliosis, which is more complex and severe than adolescent idiopathic scoliosis in which there typically are no underlying structural defects. (2) Chest wall

Fig. 1 Anterioposterior chest radiograph from a 23-year-old man with Leigh disease, contractures, and hypertonic scoliosis. (Permission to use this figure is granted by Oscar Henry Mayer, MD. All rights retained by the author.)

Fig. 2 Scoliosis with left-sided bar vertebra in a 3-year-old girl. (Permission to use this figure is granted by Oscar Henry Mayer, MD. All rights retained by the author.)

Fig. 3 Scoliosis with left rib and spine hypoplasia in an 8-month-old boy. (Permission to use this figure is granted by Oscar Henry Mayer, MD. All rights retained by the author.)

hypotonia in neuromuscular disease, such as spinal muscular atrophy, with intercostal muscle weakness and caudal rib rotation, and Duchenne muscular dystrophy, with a weak diaphragm and progressive loss of axial muscle support of the chest wall and spine. (3) Chest wall hypertonia, as seen in static encephalopathy, can cause asymmetric forces on the spine and chest wall creating an imbalance of forces and produce scoliosis. (4) Chest wall or spine hypoplasia can restrict growth both laterally, as in Jeune syndrome and Ellis van Creveld syndrome, and vertically as in Jarcho-Levin syndrome. (5) The most common chest wall defects are the conditions of chest wall hyperplasia due to abnormal cartilage growth with an invaginating deformity, as seen in pectus excavatum, or a protruding deformity in pectus carinatum.

Early Onset Scoliosis

As the name would imply, early onset scoliosis (EOS) occurs early in life and usually as a result of a substantial deficiency in the ribs, spine, or both. While the deformity is by definition present at birth, unless the deformity is severe, as with flail chest due to absent ribs, it is often not clinically evident or significant until later in infancy when the child assumes a more upright, sitting position. At this point, due to the effect of gravity on the deformity, the patient will develop scoliosis or kyphoscoliosis.

For many years, the standard approach had been delaying spine fusion to the point where the scoliosis was becoming rigid and then surgically straightening the spine and fusing it in place using one of a variety of different approaches. Ultimately, the problem with early and long-segment fusion is that the length of the fusion, the level in the spine where the fusion starts, and ultimately the thoracic height have a significant negative effect on forced vital capacity (FVC) [1].

As a temporizing procedure and to increase the potential for a good correction, halo gravity traction can be used to place a traction force on the spine to slowly straighten it or external bracing to force the spine to move closer to midline. Alternately, bracing and serial casting are used by some to treat scoliosis without substantial chest or spine dysmorphology but in EOS are not viable options beyond being a temporizing procedure to partially improve a curve to make a definitive surgery less complex and risky to the patient.

Over the last 25 years, growth sparing approaches to support the chest wall and spine such as the vertical expandable prosthetic titanium rib (VEPTR) (Fig. 4a, b) or spinal growing rods (Fig. 5a, b) and magnetic expansion rods (MAGEC rods) (Fig. 6a, b) have been developed and utilized to treat a variety of different deformities. In a mixed infant and early childhood cohort in whom the VEPTR was used to treat early onset scoliosis, there was consistent increase in FVC that kept up with growth with a stable FVC as a percent of predicted [2]. However, in an older cohort in whom the VEPTR was inserted much later in progression of their chest wall and spine disease within 2 years of the initial insertion, the FVC also increased over time but as a percent of predicted decreased over time (Table 1) [3]. These reports suggest that the earlier the correction with the VEPTR, the better the pulmonary function outcome, though this certainly requires further study.

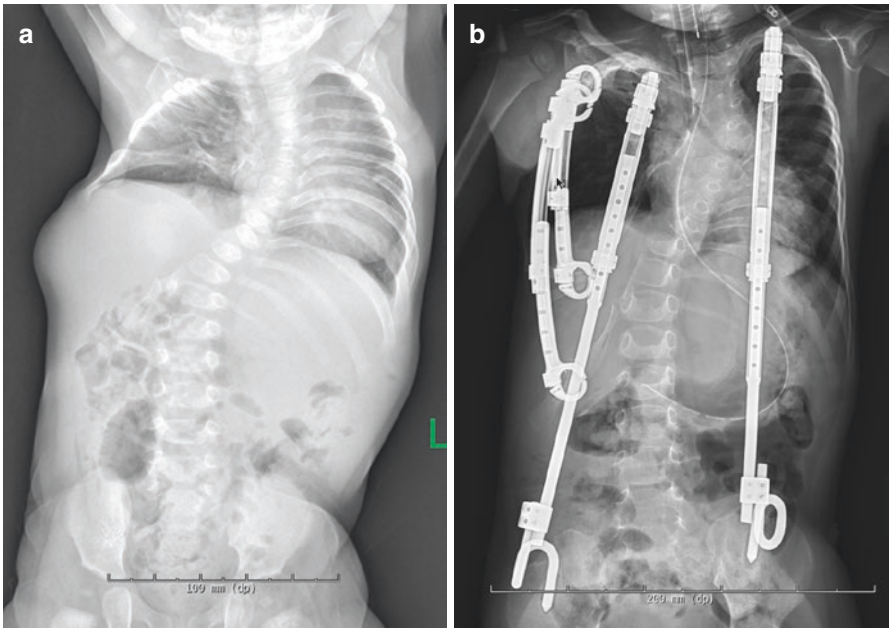

Fig. 4 (**a**) Rib fusion and spine deformity in 7-month-old male and (**b**) bilateral iliac crest to rib and right rib to rib VEPTR insertion with prior expansion in a 4-year-old male with early onset scoliosis. (Permission to use this figure is granted by Oscar Henry Mayer, MD. All rights retained by the author.)

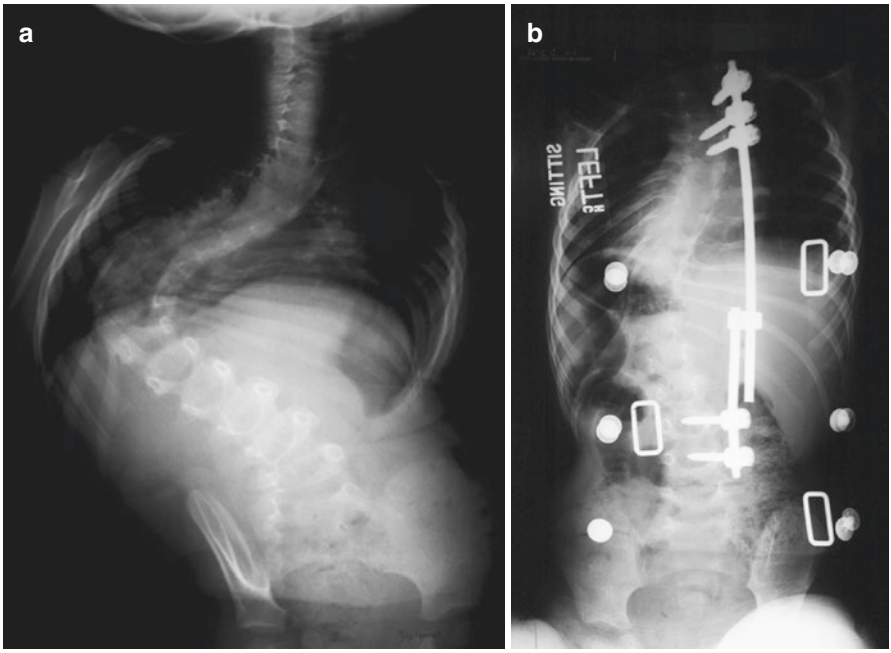

Fig. 5 (**a**) A 4-year old with congenial scoliosis and (**b**) after growing rod insertion. (Permission to use this figure is granted by Patrick Cahill, MD. All rights retained by Dr. Cahill.)

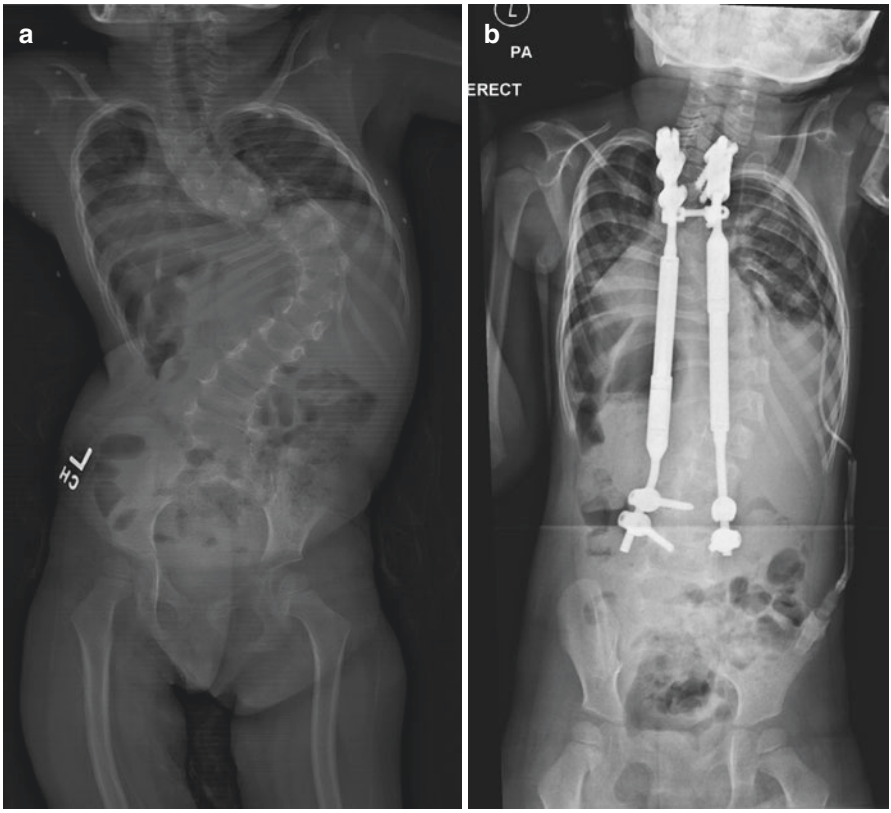

Fig. 6 (**a**) A 4-year-old male with Prader-Willi syndrome and severe scoliosis and (**b**) post-MAGEC rod insertion. (Permission to use this figure is granted by Patrick Cahill, MD. All rights retained by Dr. Cahill.)

Table 1 Change in pulmonary function and scoliosis after VEPTR insertion

	Number	Pre-VEPTR	Post-VEPTR	*P*-value
FVC	53	0.94 ± 0.07	0.97 ± 0.06	0.107
FVC%	53	61.5 ± 3.6	54.3 ± 2.5	<0.001
FEV_1	53	0.83 ± 0.05	0.87 ± 0.06	0.189
FEV_1%	53	58.9 ± 3.7	52.1 ± 2.4	0.003
FEV_1/FVC	53	89.1 ± 1.2	89.5 ± 1.1	1.000
TLC	9	1.92 ± 0.16	2.10 ± 0.15	0.111
TLC%	9	66.2 ± 4.8	65.6 ± 3.7	0.809
RV	10	0.52 ± 0.09	0.68 ± 0.10	0.029
RV%	10	79.8 ± 13.3	101.1 ± 16.6	0.083
RV/TLC	10	35.2 ± 2.5	41.5 ± 3.8	0.012
Cobb angle	40	57.9 ± 4.5	46.5 ± 3.6	<0.001

Pre- and post-VEPTR insertion data for forced vital capacity (FVC), forced expiratory volume in 1 s (FEV_1), total lung capacity (TLC), and residual volume (RV), as volume and as percent predicted, and for FEV_1/FVC, RV/TLC, and Cobb angle (Mean ± SEM)

Hypotonic Scoliosis

Hypotonic scoliosis is caused by weakness in a combination of the axial, abdominal muscles, or in the diaphragm that causes instability in the spine and chest wall and leads to eventual scoliosis. While in the early course of a hypotonic condition, the chest wall compliance may be high or normal, as the disease progresses, the scoliosis worsens, and the muscles of the chest wall may atrophy and become fibrotic. Coincident with this loss of motion is progressive loss of joint mobility (costovertebral joints) and ankylosis. While this general pattern is shared by both Duchenne muscular dystrophy (DMD) and spinal muscular atrophy (SMA), there are some differences in the type of scoliosis that is produced.

In DMD scoliosis typically does not occur until after the patient has lost the ability to ambulate, which is typically between 11 and 13 years of age. The scoliosis is typically a single long curve with the apex in low-thoracic and mid-lumbar region. There can be a great impact in the lumbar region, with progression of the scoliosis often producing substantial pelvic obliquity. However, interestingly there is minimal chest wall distortion or caudal rotation of the ribs (Fig. 7a–c).

Because in SMA, the weakness starts very early in life, the scoliosis presents early also, typically within the first decade of life. In SMA the chest wall musculature is relatively weak compared to that in DMD, and the scoliosis in SMA is typically focused in the mid-thoracic to high-lumbar region. In addition the scoliosis is usually associated with asymmetric collapse of the rib cage with caudal rotation of the ribs on the convex side of the chest creating substantial chest wall distortion (Fig. 8a–c). In severe forms the chest wall distortion can progress to the point where the ribs rotate substantially from horizontal until they are virtually parallel with the spine (Fig. 8d). This distortion also produces vertebral rotation, typically in the mid-thorax, and occasional pelvic obliquity, but not typically with the same severity as that in DMD.

Treatment options are variable and dependent both on the features of the condition and to a smaller extent on the age of the patient. Because scoliosis in SMA-2 occurs at a younger age than in DMD, temporizing procedures such as bracing have been used. However, standard chest bracing encircling the chest and applying lateral pressure on the chest to correct scoliosis is felt to worsen the caudal rib roation and chest wall distortion. For that reason, it has fallen out of favor in many centers, and when used it is used with the minimum amount of chest wall contact and pressure possible.

Spine fusion remains the standard approach to treating scoliosis in patients with DMD and has been shown to effectively stabilize the spine and decrease the rate of decline of FVC [4]. In patients with SMA, the spine can be effectively stabilized with spinal fusion [5], but without lateral thoracic support there can be substantial caudal displacement of the ribs [6].

Unlike in EOS, there is little if any discussion on the impact of spinal fusion on thoracic and lung growth in DMD and SMA and the potential for the respiratory system to not meet the metabolic needs of the body. However, since the underlying disease progression is not impacted and in being non-ambulatory, patients with

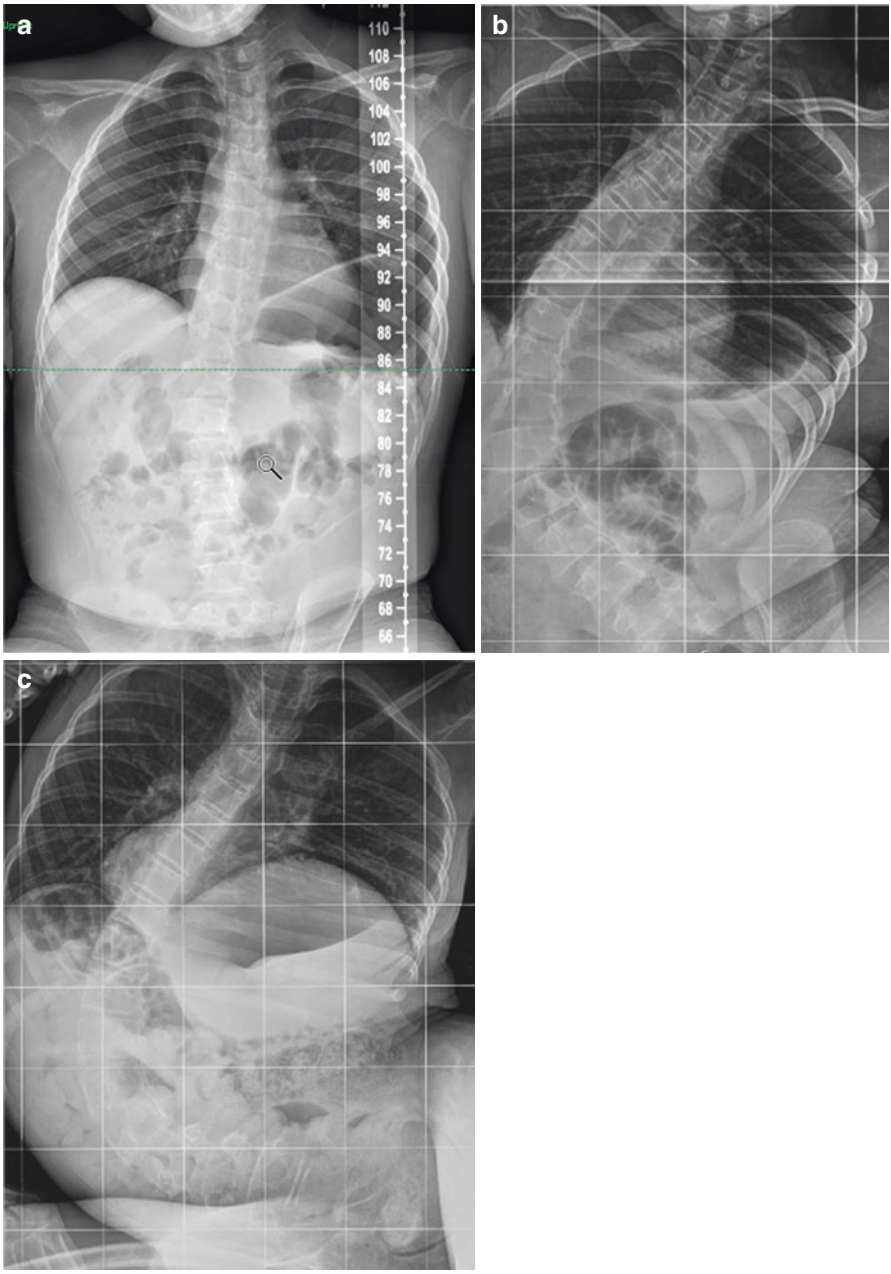

Fig. 7 (**a**) An 11-year-old patient with Duchenne muscular dystrophy and a mild thoracolumbar scoliosis with worsening of the curve with pelvic obliquity at (**b**) 12 years and (**c**) 12.5 years of age. (Permission to use this figure is granted by Oscar Henry Mayer, MD. All rights retained by the author.)

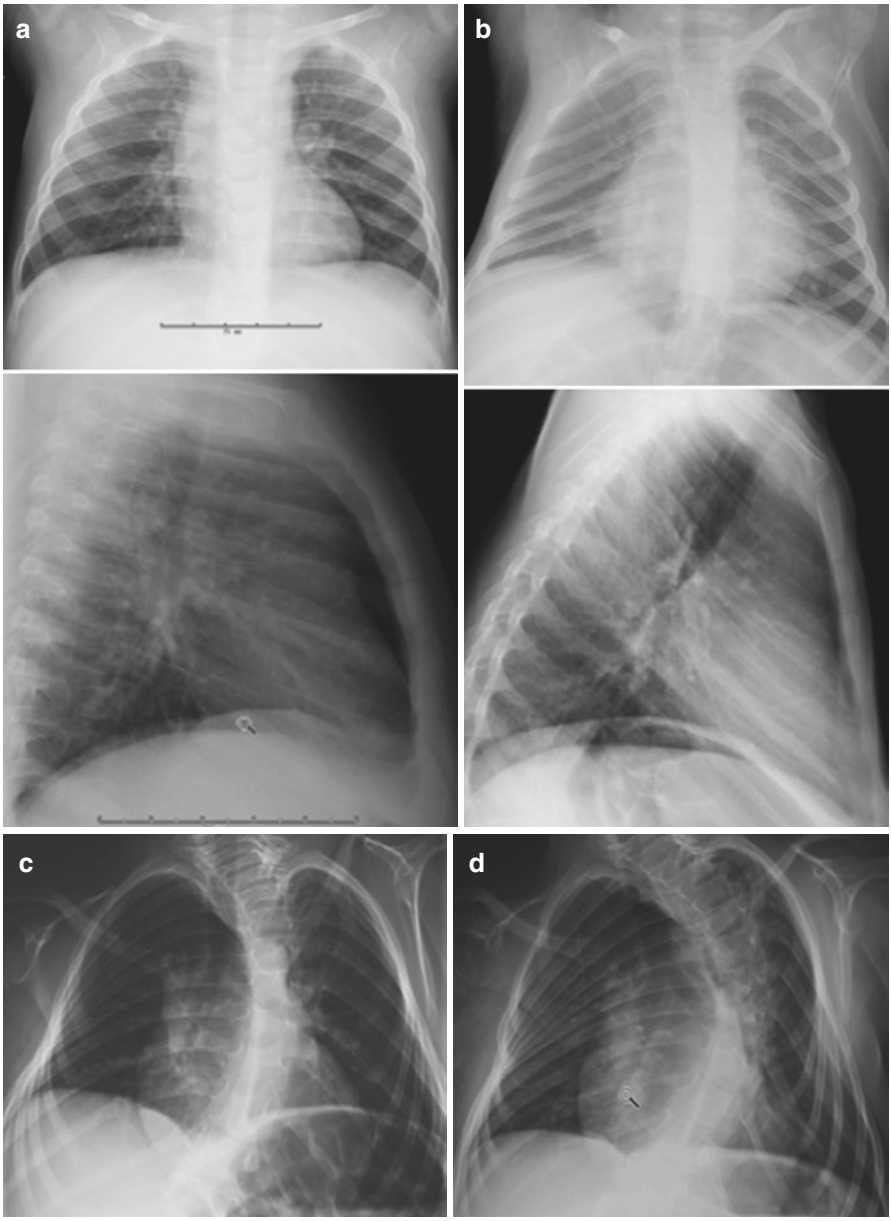

Fig. 8 (**a**) A 10-month-old girl with SMA-2 at 10 months of age with a normally shaped chest and with no scoliosis, (**b**) at 3 years of age with early thoracolumbar scoliosis and bilateral rib delineation and kyphosis, (**c**) at 5 years of age with worse scoliosis and greater left side rib cage collapse, and (**d**) at 6.5 years of age with further worsening before surgical treatment. (Permission to use this figure is granted by Oscar Henry Mayer, MD. All rights retained by the author.)

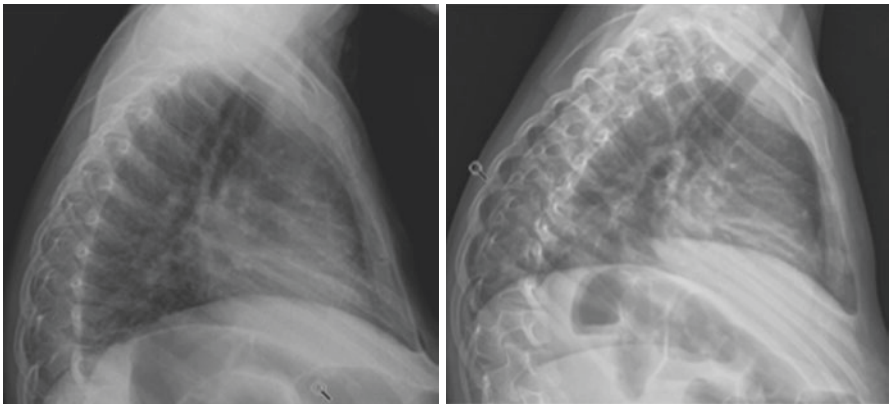

Fig. 8 (continued)

DMD and SMA would place relatively modest demands on their respiratory system compared to an otherwise healthy child with EOS. Because of that and the inexorable progression to chronic respiratory failure in DMD and SMA, some might consider the issue of slowing or stopping spine and lung growth in exchange for spinal stabilization not important.

More recently, a more enlightened approach has been taken, and growth-sparing constructs like growing rods (non-FDA Approved) and the VEPTR have been used in the SMA population. Experience with growing rods has shown good correction of the spinal curve but an inability to halt the progression of the chest wall collapse [7]. The VEPTR has been used successfully in the SMA-2 population with modification to support the lateral chest wall [8] and appears to support the chest wall well through the use of multiple constructs (Fig. 9a, b). However, as of yet, there are no long-term outcomes data to demonstrate the efficacy of this approach.

Hypertonic Scoliosis

While having hypotonic axial skeleton musculature can produce scoliosis because of an inability to maintain an erect posture, hypotonic scoliosis can produce similar problems related to asymmetric tone across the spine and in the costovertebral joints resulting in contractures similar to those in the extremities. Beyond the impact in respiration, there can be a substantial quality of life issue related to back pain and with pelvic obliquity the related challenge of sitting comfortably in a wheel chair (Fig. 10a, b). Without early recognition, the chest wall and spinal distortion can progress rapidly to a severity in which the substantial thoracic reconstruction needed can no longer be performed safely.

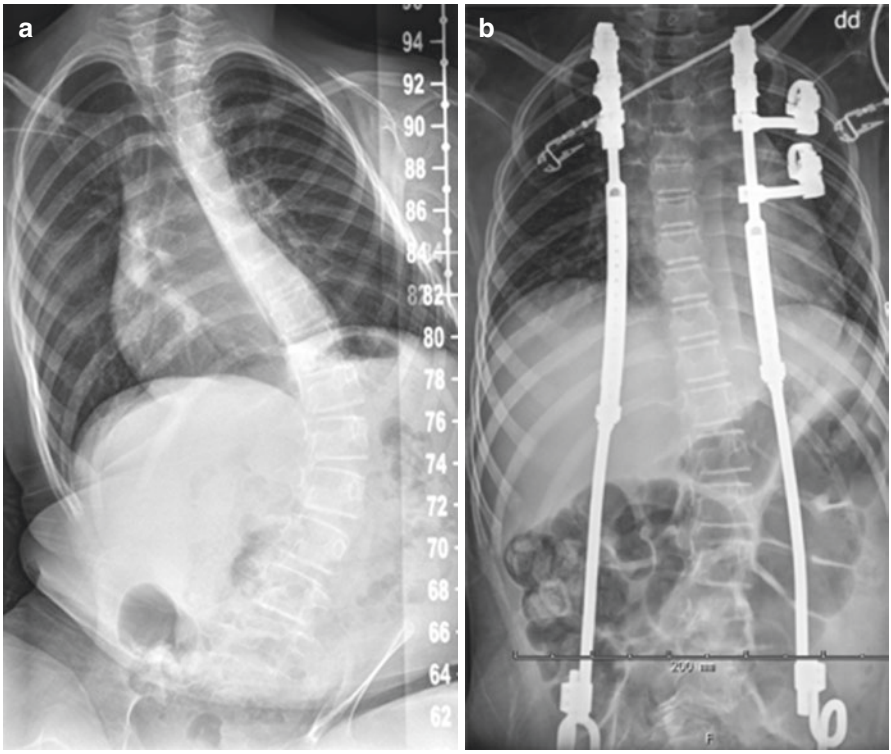

Fig. 9 (**a**) A 9-year-old patient with SMA-2 and thoracolumbar scoliosis and (**b**) at 9.5 years old after bilateral VEPTR insertion. (Permission to use this figure is granted by Oscar Henry Mayer, MD. All rights retained by the author.)

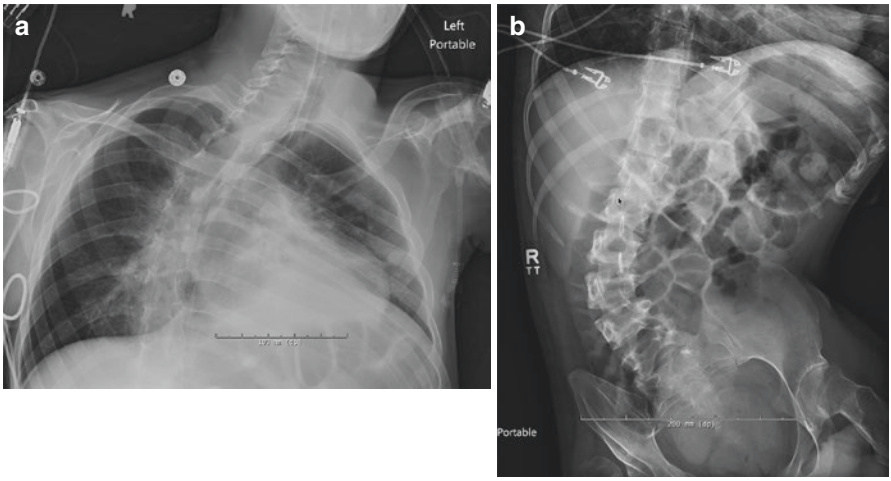

Fig. 10 A 26-year-old male patient with hypertonic scoliosis due to Leigh syndrome (**a**) with a thoracic curve and (**b**) a severe low lumbar curve and pelvic obliquity. (Permission to use this figure is granted by Oscar Henry Mayer, MD. All rights retained by the author.)

The preferred approach is a combination of axial skeleton support and using external support, both in wheel chair positioning and in some situations bracing. However, it can be argued that in a condition of hypertonia and the potential for joint contractures, the restricting motion is the wrong approach. Be that as it may, the alternate approach of maintaining chest wall motion and flexibility of the costovertebral and intraspinal joints is largely not established beyond scant unpublished experience.

The preferred approach is surgical in an attempt to correct early spinal deformity; however, lacking any effective way to assess respiratory function in these patients, many of whom also have coincident neurocognitive issues, the decision to intervene surgically can be highly subjective. It is largely based on the severity and progression of the curve and the patient's level of comfort and quality of life, which is largely determined by the caregivers. The outcome can certainly be determined by improvement in chest wall and spine deformity and most importantly improvement in the patient's level of comfort.

Chest Wall Hypoplasia

There are two models for chest wall hypoplasia. The first is abnormality in vertical growth, with Jarcho-Levin syndrome as a prime example, and the second is abnormality in lateral growth, as seen in Jeune syndrome.

Jarcho-Levin syndrome includes two different subtypes, each of which has a substantial defect in spinal formation, spondylocostal dysostosis (SCD), and spondylothoracic dysplasia (STD). SCD is most similar to the original condition described by Drs. Jarcho and Levin, which involves variable abnormalities in spine and rib formation. The vertebral malformation can range from hemivertebra or severely small and malformed vertebra to fused vertebra in addition to rib absence or rib fusion, but the defect is unilateral. However, STD is a bilateral process that usually involves multisegment spine fusion usually with a mass of posterior rib fusion that produces ribs that radiate out in a fan-like orientation.

The most commonly reported surgical approach for SCD is similar to that for EOS with lateral ribcage support involving a VEPTR spanning the defect to place the spine in proper alignment and encouraging normal spine growth. The outcome data are scant but generally show a stabilization of the spine and an improvement in spine growth, but no pulmonary function outcome measures have been reported [9].

STD typically presents with more significant chest wall restriction and has historically had a mortality rate above 80% in infancy with no intervention. While the skeletal abnormality is striking in the coronal plane, the sagittal imaging is perhaps even more so with a short thoracic spine and a broad AP diameter with a diaphragm with a larger radius of curvature which should make it less mechanically efficient (Fig. 11). In the small amount of reported experience in surgically managing STD, there has been positive experience reported using a series of V-shaped osteotomies through the fusion mass and bilateral VEPTR devices placed posteriorly from rib to rib close to the spine [6].

Jeune syndrome is caused by abnormal rib growth with short ribs with a small radius of curvature that end very posteriorly and a relatively long cartilage segment connecting the anterior edge of the ribs to the sternum. In the classic severe cases,

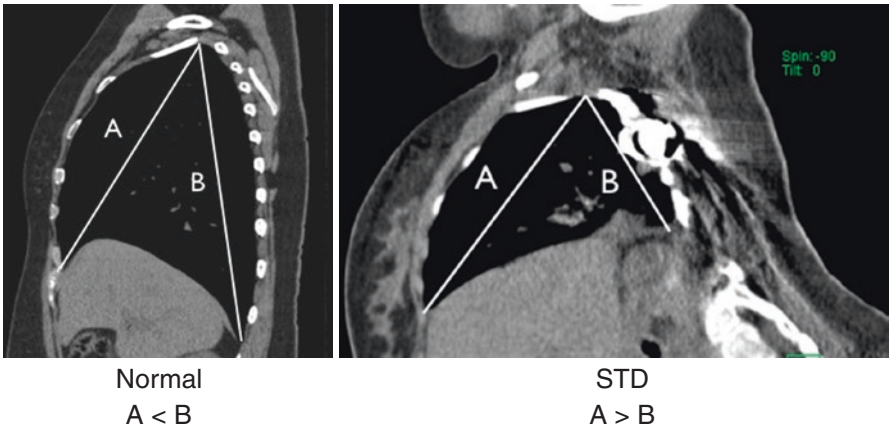

Fig. 11 Coronal chest imaging of an unaffected child and a child with spondylothoracic dysplasia demonstrating a short spine (**a**) relative to superior thorax to anterior area of apposition (**b**) and a diaphragm with a larger radius of curvature. (Permission to use this figure is granted by Oscar Henry Mayer, MD. All rights retained by the author.)

the condition is also known as "asphyxiating thoracic dystrophy," which is an apropos description in that typically the patient's chest does not grow properly and eventually restricts respiration and causes respiratory failure or death. In transverse plane the chest becomes almost square with the heart being exclusively in the chondral portion of the chest and taking up a much larger portion of the thorax than normal (Fig. 12a). The thorax is markedly narrow with a relatively protuberant abdomen (Fig. 12b), and on computed tomography imaging showing just the ribs, the chest wall is cylindrical with all the ribs having roughly the same length.

While the initial attempt to surgically treat the defect involved sternotomy and bone grafting, over the last 20 years, two techniques have been used and reported: the lateral thoracic expansion (LTE) technique and a modification of the VEPTR with smaller radius of curvature devices placed laterally.

The LTE involves making a series of offset osteotomies along the lower ribs and fusing the long ends together and expanding the rib cage laterally resulting in a wider thorax [10]. The periosteum is then stripped off the ribs and placed in the open area between the short segments with eventual rib regrowth. The reported pulmonary outcomes are favorable after the initial insertion, but there are no data reported on long-term outcomes [11]; however, the major criticism of the technique is that it is done once and there is no potential for further growth.

The VEPTR device has been used with a smaller radius of curvature device placed laterally and a series of in-line vertical osteotomies through the middle six to eight ribs both anteriorly and posteriorly (Fig. 13a), and about 4 months later the same procedure is repeated on the contralateral side (Fig. 13b). The freed block of rib is pulled laterally and connected to the VEPTR device. The periosteum is then stripped off the ribs and sutured in the space between the rib ends [12]. After both devices are placed, the chest is expanded once every 4–6 months and creates a substantial change in the chest shape moving from a square to a triangular appearance (Fig. 14a–c).

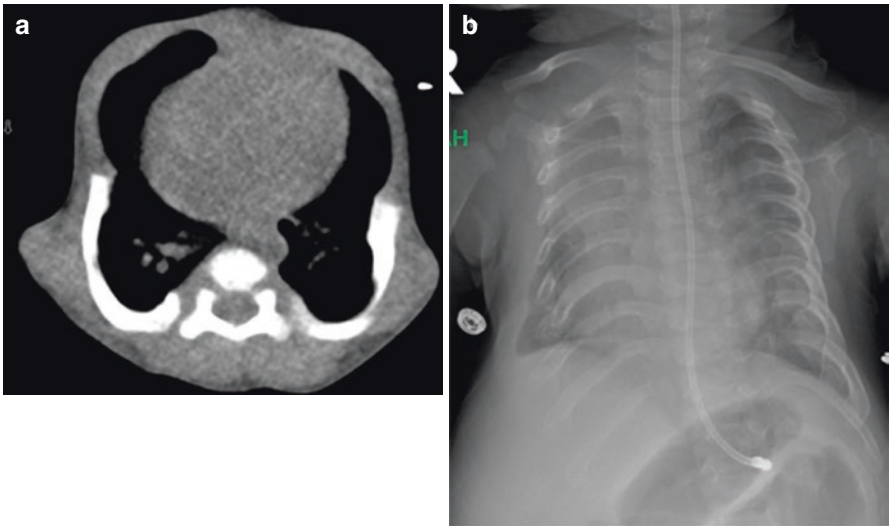

Fig. 12 Jeune syndrome in an 8-month-old male with (**a**) "square"-shaped chest with the heart in an expanded chondral portion of the thorax, and (**b**) anteroposterior radiograph showing a narrow chest and a relatively large abdominal diameter. (Permission to use this figure is granted by Oscar Henry Mayer, MD. All rights retained by the author.)

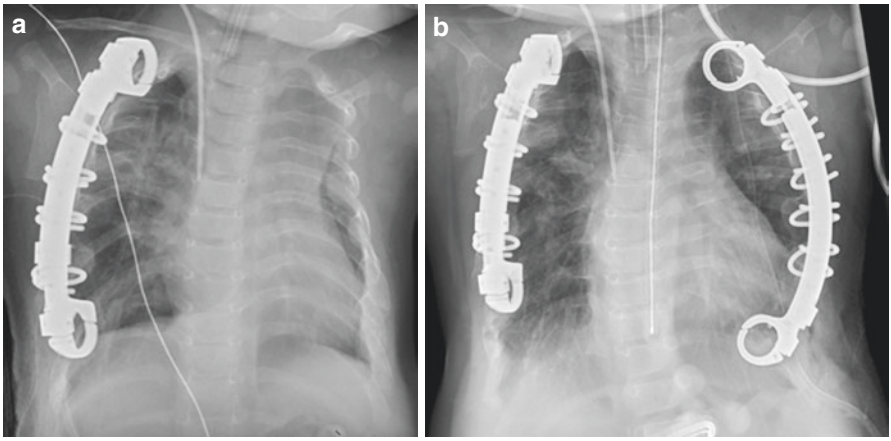

Fig. 13 (**a**) A 7-month-old with Jeune syndrome s/p right osteotomies and VEPTR insertion and (**b**) s/p left osteotomies and VEPTR insertion. (Permission to use this figure is granted by Oscar Henry Mayer, MD. All rights retained by the author.)

The largest cohort of patients with Jeune syndrome who had VEPTR placed bilaterally was recently reported and showed that there was a strong trend toward decreased respiratory support and there were significant increases in chest wall and spine growth [12]. Though the data were not normalized for growth, since the

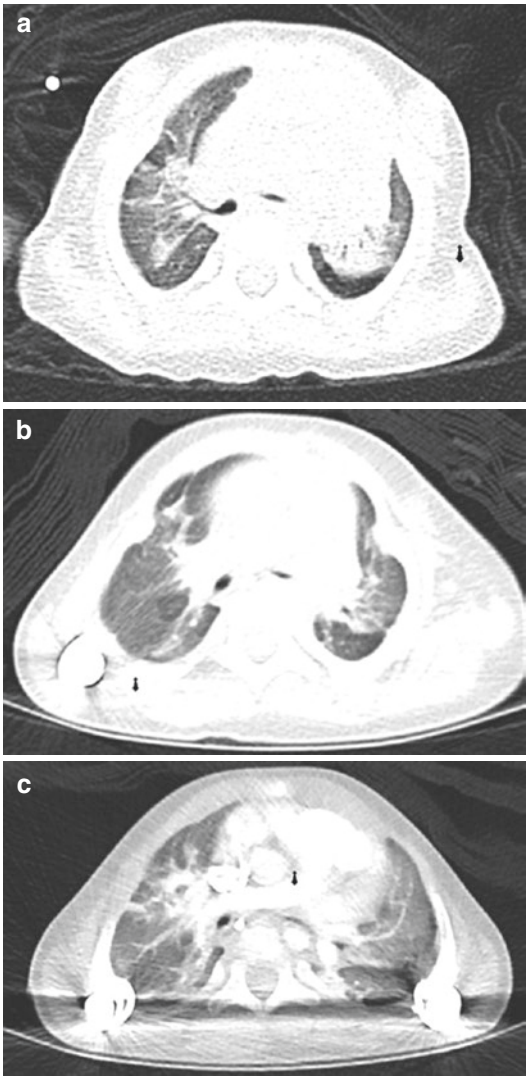

Fig. 14 Jeune syndrome (**a**) at 5 months, (**b**) at 11 months s/p right VEPTR, and (**c**) at 15 months s/p left VEPTR demonstrating the progression from a "square" thorax to a triangular thorax due to lateral chest wall expansion. (Permission to use this figure is granted by Oscar Henry Mayer, MD. All rights retained by the author.)

expectation with Jeune syndrome is minimal or no growth, any growth could be seen as an excellent outcome not to mention the improved survival of over 70% compared to an almost universally fatality if left untreated [12].

Chest Wall Hyperplasia

Chest wall hyperplasia due to sternal and costal cartilage growth abnormality is by far the most common type of chest wall deformity, and among its two types, pectus excavatum and pectus carinatum, pectus excavatum accounts for 90% of pediatric

chest wall disorders [13]. Though the genetic abnormality causing primary pectus excavatum and carinatum has not been clearly identified, it is believed to be caused by a cartilage growth abnormality. In the case of pectus excavatum, the growth defect displaces the sternum inwardly and typically symmetrically, while in pectus carinatum the sternum is displaced outward and can be asymmetric.

Pectus excavatum is three to five times more common in males, and it can be both acquired and congenital [13]. While it can be associated with conditions with known connective tissue or cartilage defects such as Marfan syndrome, Ehlers-Danlos syndrome and osteogenesis imperfecta, it more commonly occurs without an associated underlying condition.

Though pectus excavatum can be present at birth and then resolve by 1 year of age, it typically presents and certainly becomes more prominent during periods of somatic growth and particularly during puberty. Pectus excavatum typically has little functional impact with normal lung volumes and no exercise intolerance but may have a large impact on self-image, which typically occurs more in males than in females. Severe pectus excavatum, however, can cause restrictive respiratory disease with exercise intolerance, specifically with reduced maximal oxygen uptake during exercise [14]. In addition, if the sternum displaces or distorts the heart, it can cause an electrocardiac abnormality or impact systolic function.

Pectus excavatum is graded using the pectus severity (Haller) index (Fig. 15a, b), which is calculated from a chest CT scan as the ratio of the inner diameter of the rib cage to the distance between the anterior portion of the spine and the inner side of

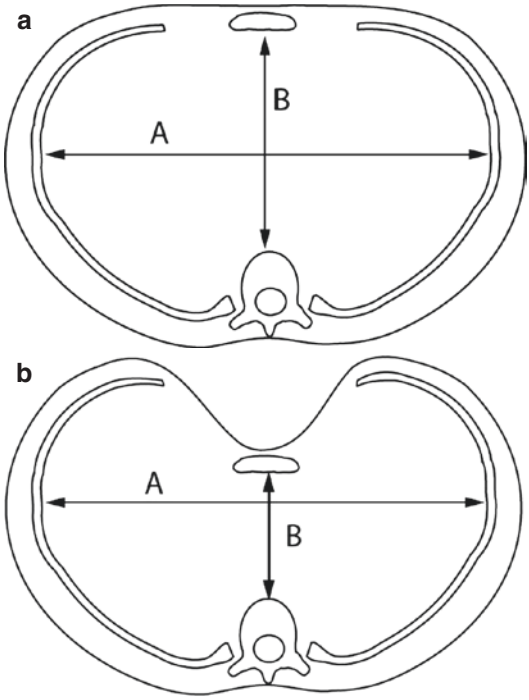

Fig. 15 The pectus severity (Haller) index in an model of (**a**) a normal chest and (**b**) a chest with pectus excavatum with the PSI = A/B. (Permission to use this figure is granted by Oscar Henry Mayer, MD. All rights retained by the author.)

the sternum. A normal index is less than 2.5, while an index of over 3.25 is felt to indicate a need for surgical correction.

The early approaches to pectus excavatum repair focused on detaching portions of the diaphragm or abdominal musculature and then moved into the direct remodeling of the cartilage between the sternum and cartilage in the Ravitch procedure, which remained the standard approach for many years. When it was recognized by Haller et al. that this procedure may lead to an acquired thoracic dystrophy [15], the procedure was modified to remold the chest wall cartilage and to perform a sternal osteotomy and bring the sternum outward the to the appropriate position but to not impact the costal growth plates [16]. This modified approach remains a popular approach to surgical repair.

Nuss et al. developed a different approach entirely in addressing the sternum from within using one or two rigid bars contoured to the chest shape [17]. The bar is then inserted through an axillary intercostal space, and the bar is gently advanced anteriorly in front of the lungs and heart to the contralateral intercostal space at the same level. The bar is then rotated superiorly under the sternum to advance it anteriorly where it is then sutured in place.

A relatively new and relatively less invasive procedure called the magnetic minimover has been developed by Harrison et al. and involves placing a magnet underneath the sternum with an opposite pole magnet placed on a small chest shell over the medial portion of the chest and then strapped in place and worn almost continuously for the better part of a year [18].

Ultimately, the improvement after pectus excavatum repair is in chest contour and self-image, with little if any improvement in pulmonary function.

Pectus carinatum is also more common in males than in females and can be subdivided into two different types based on location. Chondrogladiolar prominent defects are focused on the lower gladiolar component of the sternum and accounts for over 95% of pectus carinatum defects with the upper sternal chondromanubrial prominent defects accounting for the other. The defect is more commonly asymmetric than pectus excavatum defects. As in pectus excavatum, pectus carinatum defects become more prominent with growth. Similar to pectus carinatum, the most significant issue with pectus carinatum is the cosmetic appearance, but it is not typically associated with respiratory difficulty.

Assessment and treatment are a bit less certain than with pectus carinatum in that while chest CT can clearly demonstrate the sternal distortion, there is no outcome measure, similar to the pectus severity index, that is helpful in describing severity and then determining when treatment is indicated. This is likely since the indication for treatment is largely based on appearance and not related to function.

Unlike in pectus excavatum, there is a viable nonsurgical option in bracing which has been shown to be effective in situations where the deformity is somewhat flexible and compressible and if the patient can be compliant with wearing the brace (23 h a day) for 2–6 months [19]. If neither of these apply, then surgery can be performed with the typical approach being the modified Ravitch approach with which there have been promising results [20].

Conclusion

The chest wall and spine are integrated together and function optimally when both units are working well. Because of this interrelation, if one unit is dysfunctional, the other will be impacted also. Therefore, treatment of chest wall and spine disease requires attention to both units together. Utilizing growth in this correction is critical in insuring a good long-term outcome.

References

1. Karol LA, Johnston C, Mladenov K, Schochet P, Walters P, Browne RH. Pulmonary function following early thoracic fusion in nonneuromuscular scoliosis. J Bone Joint Surg Am. 2008;90(6):1272–81.
2. Motoyama EK, Deeney VF, Fine GF, Yang CI, Mutich RL, Walczak SA, et al. Effects on lung function of multiple expansion thoracoplasty in children with thoracic insufficiency syndrome: a longitudinal study. Spine. 2006;31(3):284–90.
3. Mayer OH, Redding G. Early changes in pulmonary function after vertical expandable prosthetic titanium rib insertion in children with thoracic insufficiency syndrome. J Pediatr Orthop. 2009;29(1):35–8.
4. Galasko CS, Williamson JB, Delaney CM. Lung function in Duchenne muscular dystrophy. Eur Spine J. 1995;4:263–7.
5. Fujak A, Raab W, Schuh A, Kreß A, Forst R, Forst J. Operative treatment of scoliosis in proximal spinal muscular atrophy: results of 41 patients. Arch Orthop Trauma Surg. 2012;132(12):1697–706.
6. Campbell RM Jr, Smith MD. Thoracic insufficiency syndrome and exotic scoliosis. J Bone Joint Surg Am. 2007;89(Suppl 1):108–22.
7. McElroy MJ, Shaner AC, Crawford TO, Thompson GH, Kadakia RV, Akbarnia BA, et al. Growing rods for scoliosis in spinal muscular atrophy: structural effects, complications, and hospital stays. Spine. 2011;36(16):1305–11.
8. Tobert DG, Vitale MG. Strategies for treating scoliosis in children with spinal muscular atrophy. Am J Orthop. 2013;42:E99–E103.
9. Ramirez N, Flynn JM, Emans JB, Betz R, Smith JT, Price N, et al. Vertical expandable prosthetic titanium rib as treatment of thoracic insufficiency syndrome in spondylocostal dysplasia. J Pediatr Orthop. 2010;30(6):521–6.
10. Davis JT, Long FR, Adler BH, Castile RG, Weinstein S. Lateral thoracic expansion for Jeune syndrome: evidence of rib healing and new bone formation. Ann Thorac Surg. 2004;77(2):445–8.
11. Davis JT, Heistein JB, Castile RG, Adler B, Mutabagani KH, Villalobos RE, et al. Lateral thoracic expansion for Jeune's syndrome: midterm results. Ann Thorac Surg. 2001;72(3):872–7.
12. O'Brien A, Roth MK, Athreya H, Reinker K, Koeck W, Patil V, et al. Management of thoracic insufficiency syndrome in patients with Jeune syndrome using the 70 mm radius vertical expandable prosthetic titanium rib. J Pediatr Orthop. 2015;35(8):783–97.
13. Fokin AA, Steuerwald NM, Ahrens WA, Allen KE. Anatomical, histologic, and genetic characteristics of congenital chest wall deformities. Semin Thorac Cardiovasc Surg. 2015;21(1):44–57.
14. Nuss D, Kelly RE. Indications and technique of Nuss procedure for pectus excavatum. Thorac Surg Clin. 2010;20:583–97.
15. Haller JA, Colombani PM, Humphries CT, Azizkhan RG, Loughlin GM. Chest wall constriction after too extensive and too early operations for pectus excavatum. Ann Thorac Surg. 1996;61(6):1618–24; discussion 1625.

16. Fonkalsrud EW. Current management of pectus excavatum. World J Surg. 2003;27(5):502–8.
17. Nuss D, Kelly RE, Croitoru DP, Katz ME. A 10-year review of a minimally invasive technique for the correction of pectus excavatum. J Pediatr Surg. 1998;33(4):545–52.
18. Harrison MR, Estefan-Ventura D, Fechter R, Moran AM Jr, Christensen D. Magnetic minimover procedure for pectus excavatum. J Pediatr Surg. 2007;42(1):81–6.
19. Lee RT, Moorman S, Schneider M, Sigalet DL. Bracing is an effective therapy for pectus carinatum: interim results. J Pediatr Surg. 2013;48(1):184–90.
20. Robicsek F, Watts LT, Fokin AA. Surgical repair of pectus excavatum and carinatum. Semin Thorac Cardiovasc Surg. 2010;21:64–75.

Pulmonary Complications of Neuromuscular and Other Genetic Disorders

Alessandro Amaddeo, Sonia Khirani, and Brigitte Fauroux

Introduction

The respiratory system is a complex system involving different organs which interact with each other to provide an efficient breathing, adapted to growth and physiological situations such as rest, sleep, and exercise. This explains why the respiratory system can be affected by various mechanisms which may occur in different diseases not directly involving the lungs, the airways, or the respiratory muscles. A perfect understanding of the different pathophysiological mechanisms that may be involved in and/or responsible for breathing difficulties, sleep-disordered breathing, or respiratory failure is crucial for the appropriate management of the patient. This underlines the importance of an in-depth knowledge of respiratory physiology and of the specific disease, which can only be obtained through an expert pediatric multidisciplinary management. This chapter will give an overview of the pulmonary complications in neuromuscular diseases and other genetic diseases with a focus on the pathophysiological mechanisms involved and the practical management of patients.

A. Amaddeo, M.D. • B. Fauroux, M.D., Ph.D. (✉)
Pediatric Noninvasive Ventilation and Sleep Unit, Hôpital Necker Enfants-Malades, Paris, France

Paris Descartes Faculty, Paris, France

Research Unit Inserm U 955, Team 13, Créteil, France
e-mail: alessandro.amaddeo@aphp.fr; brigitte.fauroux@aphp.fr

S. Khirani, Ph.D.
Pediatric Noninvasive Ventilation and Sleep Unit, Hôpital Necker Enfants-Malades, Paris, France

ASV Santé, Gennevilliers, France
e-mail: sonia_khirani@yahoo.fr

© Springer International Publishing AG 2018

A.C. Koumbourlis, M.A. Nevin (eds.), *Pulmonary Complications of Non-Pulmonary Pediatric Disorders*, Respiratory Medicine,
https://doi.org/10.1007/978-3-319-69620-1_7

Respiratory Physiology

The respiratory system comprises the central drive which commands the respiratory muscles, the airways, the lungs, and the rib cage. This apparatus interacts with other systems, among which the most important is the cardiovascular system, and is capable of adapting its performance to the different physiological situations such as sleep and exercise.

In healthy subjects, the respiratory load, i.e., the effort the subject has to perform to generate a breath, is low, the capacity of the respiratory muscles is normal, and the central drive appropriately commands the respiratory muscles. In disorders characterized by an increase in respiratory load or by a weakness of the respiratory muscles, the central drive increases its demands of the respiratory muscles. However, when this imbalance exceeds a certain threshold, hypoventilation, defined by hypercapnia and hypoxemia, occurs. Severe upper airway obstruction, airway malacia, and advanced lung diseases such as a cystic fibrosis, bronchopulmonary dysplasia, or bronchiolitis obliterans may be responsible for an excessive respiratory load [1–7]. Neuromuscular diseases that involve the motor neuron, the peripheral nerve, the neuromuscular junction, or the muscle may cause respiratory muscle weakness. Chest wall disorders, such as kyphoscoliosis, may be associated with an increase in respiratory load and a mechanical disadvantage leading to a dysfunction of the respiratory muscles. Disorders of the central drive are rare and may be congenital, such as the Ondine's curse (or congenital central hypoventilation syndrome), or acquired due to compression or injury to the brainstem. Some disorders, such as achondroplasia and mucopolysaccharidoses, may be associated with an impairment of two or more components of the respiratory system by causing upper airway obstruction and brainstem compression. Because of physiological "immaturity," young children may be more vulnerable to changes in their respiratory system. It is indeed well known that the diaphragm is less resistant to fatigue in newborns and infants and that younger children have smaller and more collapsible airways [8]. As the respiratory system evolves with the growth of the child, this vulnerability improves with age.

Sleep and exercise are two physiological conditions that put challenge on the respiratory system. Indeed, sleep affects the three components of the respiratory balance. Physiological changes in respiratory and upper airway function, respiratory muscle power, and ventilatory response lead to a reduced ventilation during sleep even in normal subjects, causing a physiological moderate decrease in oxygenation and a rise in the arterial carbon dioxide pressure ($PaCO_2$) (Fig. 1). Indeed, sleep is associated with changes in respiratory mechanics, with an increase in ventilation-perfusion mismatch, an increase in airflow resistance, and a fall in functional residual capacity. Although the activity of the diaphragm is preserved, that of the intercostal and the upper airway muscles is decreased significantly. Finally, central drive and chemoreceptor sensitivity are less efficient during sleep than during wakefulness. All these abnormalities are most pronounced during rapid eye movement (REM) sleep. This explains why respiratory failure exaggerates during sleep [9, 10]. A sleep study represents thus one of the most important investigations in a

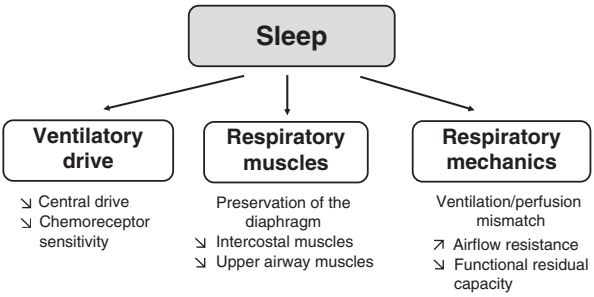

Fig. 1 Physiological changes during sleep

child with any disorder that can affect, directly or indirectly, the respiratory system. General anesthesia may be considered as a "deep" sleep, with the consequent risk of respiratory failure. This is particularly the case in patients with neuromuscular disease because of the profound depressing effects of most of the anesthetic drugs on respiratory muscle function [11].

Exercise, on the other hand, requires an increase in minute ventilation with an increase in tidal volume and respiratory rate. According to the type of underlying disease, a patient will not be able to adapt his tidal volume and/or respiratory rate to the metabolic demands, precipitating ventilatory failure [12, 13]. A similar situation is observed during a chest infection, which may also require an increase in ventilation. This further increase in respiratory muscle demand may be impossible for a patient already breathing at the maximal of his respiratory capacity or reserve [14].

Pulmonary Complications of Neuromuscular Diseases

The respiratory muscles are rarely spared in neuromuscular diseases. The diaphragm is the main inspiratory muscle, accounting for approximately 80% of the inspiration, and the only respiratory muscle which activity persists during sleep and in particular REM sleep [10]. The external intercostal muscles contribute to the inspiration by expanding and stabilizing the chest wall. The accessory inspiratory muscles, such as the sternocleidomastoid and scalene muscles, intervene only in case of an increase in respiratory effort such as exercise or in case of failure of the diaphragm and the intercostal muscles. Expiration is normally passive. However, the expiratory muscles may assist inspiration by a contraction (during expiration)—relaxation (during inspiration) maneuver in case of significant dysfunction or paralysis of the diaphragm [15, 16].

Neuromuscular diseases occurring in childhood may affect the motoneuron, such as spinal muscular atrophy (SMA); the peripheral nerve, such as metabolic or hereditary diseases; the neuromuscular junction, such as myasthenia; or the muscle itself, such as muscular dystrophies or myopathies. Moreover, the type of respiratory muscle that is predominantly involved in a specific neuromuscular disease varies. As such, SMA is characterized by a predominant weakness of the intercostal

muscles, whereas Duchenne muscular dystrophy (DMD) and collagen VI (COLVI) myopathies are characterized by a predominant weakness of the diaphragm [17–19]. This is of major importance for the appropriate respiratory management of patients, for example, a prioritized screening of patients with diaphragm weakness for a sleep study [16, 20]. Different severities of respiratory muscle weakness may be observed in some neuromuscular diseases. Three different clinical phenotypes are observed in SMA, with the type I being the most severe, the type II the intermediate one, and the type III the mildest phenotype. COLVI–related myopathies, characterized by mutations in the *COL6A1-3* genes, present a continuous clinical spectrum going from Bethlem myopathy, the milder form, to Ullrich congenital muscular dystrophy, the most severe form, with intermediate phenotypes [21, 22]. However, there is not always a parallel between the weakness of the peripheral and the respiratory muscles, in particular in case of a predominant involvement of the diaphragm, as in COLVI-related myopathies and selenopathies [22].

In neuromuscular diseases, the respiratory system can be affected by different mechanisms and organs (Table 1). Weakness of the respiratory muscles may translate into difficulties in clearing secretions, sleep-disordered breathing with alveolar hypoventilation, and chest deformity in young children. Weakness of the vertebral muscles may contribute to chest deformity and add a restrictive component to the

Table 1 Pathophysiological mechanisms which may cause respiratory problems in children according to the type of neuromuscular disease and their management

Neuromuscular involvement	Respiratory consequences	Management	Type of neuromuscular disease
Weakness of the respiratory muscles	• Difficulty in clearing secretions • Sleep disordered breathing → (nocturnal) alveolar hypoventilation • Chest deformity in young children	• Cough-assisted techniques • NIV • IPPB and NIV	All types of neuromuscular diseases
Weakness of the vertebral muscles	Thoracic deformity (scoliosis)	Arthrodesis	Selenopathy Nemaline rod myopathy COL IV myopathy LAM A2 myopathy
Cardiac involvement	Cardiorespiratory failure	Medical treatment	Fukutin myopathy Duchenne muscular dystrophy
Bulbar weakness	• False passages, inhalation pneumopathy • Central apneas	• Nutritional support • Ventilatory support	Nemaline rod myopathy Centronuclear myopathy Congenital myasthenic syndrome Myotonic dystrophy type I Spinal muscular atrophy type 0-1 Steinert myotonic dystrophy

Abbreviations: *NIV* noninvasive ventilation, *IPPB* intermittent positive pressure breathing, *COLVI* collagen VI, *LAMA* lamin A 2

respiratory impairment in children with neuromuscular disease. A chest wall deformity may also cause a mechanical disadvantage on the respiratory muscles. The cardiac muscle may be involved in some neuromuscular diseases such as DMD or fukutin myopathy, which may aggravate sleep-disordered breathing and precipitate respiratory failure. Finally, bulbar weakness, as observed in nemaline myopathies, centronuclear myopathies, congenital myasthenic syndrome, myotonic dystrophy type I, and SMA type I, may cause inhalation pneumopathy. Central apneas are a classical feature of Steinert myotonic dystrophy.

Pulmonary Complications of Genetic Diseases

Numerous genetic diseases can adversely affect the respiratory system. It is not possible in this short overview to give an extensive list of all genetic diseases that may cause respiratory problems. The priority will thus be given to the pathophysiological mechanisms that may be encountered in different types of diseases in order to guide to most appropriate management.

Genetic diseases may cause respiratory problems by disrupting ventilatory control, by causing upper airway obstruction, chest deformity, and/or parenchymal lung disease (Table 2). Importantly, the same disease may affect the respiratory system by different mechanisms. Achondroplasia may cause central apneas because of cervico-occipital compression, upper airway obstruction because of a combination of maxillofacial anomalies, and restrictive lung disease because of thoracic scoliosis. Storage disease such as mucopolysaccharidosis may also cause cervico-occipital compression, upper airway obstruction, restrictive lung disease because of thoracic scoliosis, and cardiomyopathy and/or arterial pulmonary hypertension. This underlines the importance of appropriate investigations in order to identify and treat the different pathophysiological mechanisms responsible for a respiratory impairment in an individual patient.

Rett syndrome, ROHHADNET syndrome, Prader-Willi syndrome, Down syndrome, achondroplasia, and storage diseases may cause a dysfunction of central ventilatory control and cause central apneas (Table 2). Upper airway obstruction is a common feature in craniofaciostenosis such as Apert syndrome, Crouzon syndrome, or Pfeiffer syndrome; maxillofacial malformations such as Pierre Robin syndrome, Treacher Collins, or Goldenhar syndrome; storage diseases such as mucopolysaccharidosis or mucolipidosis; congenital bone diseases such as achondroplasia or pycnodysostosis; Beckwith-Wiedemann syndrome; Prader-Willi syndrome; and Down syndrome [23, 24]. Thoracic deformity may cause a restrictive lung disease of various severities (Table 3). Some of these disorders are primary congenital bone diseases such as Jeune asphyxiating thoracic dystrophy whether others may also manifest outside the chest or thorax such as distal arthrogryposis, fibrodysplasia ossificans progressiva, and osteogenesis imperfecta. Finally, some storage diseases such as Niemann-Pick disease may have multi-organ manifestations with parenchymal lung involvement [25].

Table 2 Description of respiratory problems in children with genetic diseases (neuromuscular diseases and Ondine's curse excluded)

Primary abnormality	Respiratory consequences	Management	Diseases
Abnormal ventilatory control	Central apneas False passages	Neurosurgery (decompression) Ventilatory support • Noninvasive ventilation • Invasive ventilation	Rett syndrome, ROHHADNET syndrome Prader-Willi syndrome Achondroplasia Storage diseases: Mucopolysaccharidosis
Upper airway obstruction	Obstructive sleep apnea	Upper airway surgery Ventilatory support • Noninvasive ventilation • Invasive ventilation	Craniofacial malformations Laryngotracheal malformations Storage diseases: Mucopolysaccharidosis
Chest deformity	Restrictive lung disease	Ventilatory support • Noninvasive ventilation • Invasive ventilation	See Table 3
Parenchymal lung disease	Restrictive lung disease, respiratory failure	No specific treatment Symptomatic treatment: Oxygen therapy	Storage diseases: Niemann-pick disease

Table 3 Genetic diseases associated with chest deformity (neuromuscular diseases excluded)

• Jeune asphyxiating thoracic dystrophy
– Genetically heterogeneous ≥9 genes identified, all encoding ciliary proteins
• Distal arthrogryposis
– Characterized by multiple congenital contractures
– DA type 2A (freeman-Sheldon syndrome = most severe form) is caused by mutations in MYH3
• Fibrodysplasia ossificans progressiva:
– Mutations in ACVR1 gene
• Achondroplasia
• Osteogenesis imperfecta
• Storage disorders: Mucopolysaccharidosis
• Neurofibromatosis

Investigations for the Management of Pulmonary Complications of Neuromuscular and Other Genetic Disorders

Deciphering the pathophysiological mechanisms that are responsible for a pulmonary complication in a neuromuscular or other genetic disease requires the appropriate choice and timing of a number of investigations (Table 4). These investigations

Table 4 Diagnostic investigations for the management of pulmonary complications of neuromuscular and other genetic disorders

Investigation	Information
Sleep study	Respiratory events: Central or obstructive apneas/hypopneas Nocturnal gas exchange: Hypoxemia, hypercapnia Sleep architecture and quality: Sleep stages, sleep efficiency, arousals Additional information • Breathing pattern, respiratory rate • Progressive simultaneous decrease in airflow and thoracic and abdominal movements accompanied or not by a change in gas exchange, suggestive of a decrease in central drive or global inspiratory muscle weakness • Paradoxical breathing with opposition phase on the thoracic and abdominal belts, suggestive of diaphragmatic dysfunction or weakness of the intercostal muscles
Lung function tests	Airway obstruction • Airway resistance • Spirometry • Functional residual volume by plethysmography Restrictive lung disease: Lung volumes Daytime gas exchange Exercise test
Respiratory muscles tests (noninvasive)	Inspiratory muscles strength • Maximal static inspiratory pressure • Sniff nasal inspiratory pressure • Indirect: Vital capacity Expiratory muscle strength • Maximal static inspiratory pressure • Peak expiratory flow/peak cough flow
Echocardiography	Cardiac function Arterial pulmonary hypertension
Imaging	Chest X-ray, chest computed tomography Specific imaging: Spine X-ray, brain magnetic resonance imaging

comprise a sleep study, lung function tests adapted to the age and the type of underlying disease, respiratory muscle tests, cardiac investigations, chest X-ray, computed tomography scan, and other specific imaging such as cervicomedullary magnetic resonance imaging.

A sleep study will provide objective data on central and/or obstructive apneas, nocturnal hypoxemia, and/or hypercapnia but also on breathing pattern, periods of reduced ventilation without changes in oxygen or carbon dioxide levels, paradoxical breathing, and their consequences on sleep architecture and sleep quality. A sleep study, by analyzing the airflow with the thoracic and abdominal movements, gives also interesting information on the respiratory events occurring during sleep. The presence of central apneas is the signature of dysfunction of central drive. On the other hand, a tracing showing a decrease of airflow with an opposition phase on the thoracoabdominal belts may of course reflect an obstructive hypopnea but also a paralysis of the diaphragm or the intercostal muscles [9, 26, 27]. Finally, a progressive simultaneous and homogeneous decrease in airflow and thoracic and abdominal

movements, accompanied or not by a change in gas exchange, may be suggestive of a decrease in central drive or global inspiratory muscle weakness [9, 26, 27]. An analysis of the sleep study by a pediatrician who has an expertise in sleep as well as the underlying genetic disease is mandatory for an appropriate and comprehensive interpretation of the tracings. The timing of a sleep study in an individual patient represents a major issue. Indeed, in some diseases, such as achondroplasia or Prader-Willi syndrome, a sleep study is recommended during routine follow-up [28, 29]. In other diseases however, there are no validated guidelines for the performance and timing of a sleep study. Symptoms suggestive of sleep-disordered breathing are poor predictors or markers of nocturnal hypoventilation in children with neuromuscular disease or Down syndrome [30, 31]. Moreover, they may be difficult to evaluate in young children and appear often too late in the course of the disease. Concerning the predictive value of lung function and other respiratory parameters, a large prospective study in children with neuromuscular disorders did not identify a sensitive and specific daytime lung function or respiratory muscle test that was associated with, or predictive of, nocturnal hypoxemia or hypercapnia [32]. The type of neuromuscular disorder should thus be taken into account as nocturnal hypoventilation occurs preferentially in disorders characterized by a prominent diaphragmatic weakness. For example, children with a COLVI myopathy should be screened systematically for sleep-disordered breathing, given their preferential diaphragmatic involvement [22]. Prioritized screening is also recommended for infants or young children with congenital myopathies or rapidly progressive neuromuscular diseases [33]. For other genetic diseases which can have potential adverse pulmonary consequences, the indications for a sleep study should be large. An overnight recording of gas exchange (pulse oximetry with carbon dioxide) should be performed in case of limited availability or access to pediatric sleep studies [34]. Indeed, the observation of nocturnal desaturations and/or hypercapnia may be sufficient to start noninvasive ventilation (NIV) or continuous positive airway pressure [34].

Lung function tests give valuable information on lung volumes, airflows, daytime gas exchange, and exercise tolerance. However, they are limited by the volitional nature of most of the tests, which does not allow their use in young children. In preschool children, global noninvasive parameters measuring airway resistance (by the interrupter or the forced oscillation technique) and functional residual capacity are available, but they have a poor diagnostic value and are more useful for the follow-up of the patient. Exercise tests have the same limitations and can only be performed in older children. Their main interest concerns children with severe lung disease, in whom they allow an objective evaluation of, for example, a rehabilitation or training program.

The evaluation of the performance of the respiratory muscles is of major diagnostic, prognostic, and therapeutic importance in children with neuromuscular disease. For an extensive overview, we recommend the reader to refer to our recent review [35]. Routine and regular lung function and respiratory muscle testing are recommended in children with neuromuscular disease, but these tests are based on noninvasive volitional maneuvers, such as the measurement of lung volumes (vital capacity) and the maximal static pressures that young children may not always be

able to perform. The measurement of the sniff nasal inspiratory pressure (SNIP) is a simple and noninvasive way to assess inspiratory muscle strength in children. A sniff is a natural maneuver which many children over the age of 3–4 years find much easier to perform than maximal static pressures, especially when the test is associated with a visual feedback on a computer screen [36, 37]. Because of its simplicity, SNIP should be part of routine evaluation of muscle strength in children with neuromuscular disease. The main limitation of SNIP is the underestimation of inspiratory muscle strength in case of nasal obstruction, because of adenoids or nasal polyps, or in patients with severe respiratory muscle weakness [37]. Expiratory muscle strength can be measured by the maximal static expiratory pressure, peak expiratory flow, and peak cough flow but also mouth pressure during a whistle, which is a more playful maneuver for children [38]. In very young children or when a more extensive respiratory muscle assessment is necessary, the measurement of the oesogastric pressures is most informative [35]. These respiratory muscle tests may also be useful in children with non-neuromuscular diseases in order to quantify the consequence of the underlying disease on the performance of the respiratory muscles [39].

Other investigations, such as an echocardiography, a cardiac catheterization, and imaging, depend on the type of the underlying disease. Their results should be discussed with an expert in the field, such as a pediatric cardiologist, orthopedic surgeon, or neurosurgeon.

Management of Pulmonary Complications of Neuromuscular and Other Genetic Disorders

It is important to decipher the different mechanisms involved in neuromuscular diseases in order to guide the most appropriate treatment (Table 1). Cough-assisted techniques need to be initiated as soon as the patient presents difficulties in clearing secretions. Different techniques are available, with a choice depending on the age and preference of the patient and the severity of the disease [40, 41]. NIV has to be initiated in case of nocturnal hypoventilation and/or recurrent episodes of chest infection, a priori when requiring a hospital admission [42]. Intermittent positive pressure breathing (IPPB) and/or NIV can promote normal chest wall and lung growth or reverse thoracic deformity in young children with neuromuscular disease [43]. Scoliosis can be stabilized with an arthrodesis which requires an optimal timing and careful preparation [44]. Screening for a cardiomyopathy is systematic in some neuromuscular diseases such as DMD and can be efficiently treated with appropriate drugs such as inhibitors of the angiotensin-converting enzyme. In case of swallowing disorders, appropriate nutritional support should be proposed. And finally, central apneas can be managed with appropriate NIV modes and in particular assisted servo ventilation [45].

The management of pulmonary complications of genetic diseases depends on the type of underlying disease and the physiopathological mechanisms involved (Table 2). The first treatment will be disease-specific, when available, such as bone

marrow transplantation or enzyme replacement therapy in some storage diseases such as mucopolysaccharidosis type I. But for numerous diseases, such a therapy is not (yet) available. The management of the pulmonary problems requires then a multidisciplinary treatment plan, integrating the respiratory disorders (obstructive apneas, central apneas, alveolar hypoventilation) and the possible medical (physiotherapy), surgical (adenotonsillectomy, turbinectomy, mandibular distraction osteogenesis, neurosurgical osteodistraction, cervico-occipital decompression, resection of the aryepiglottic folds, arthrodesis, tracheal reconstruction, etc.), or respiratory support (NIV as a first-line therapy or by means of a tracheostomy) treatments, taking into account the age and growth potential of the child. The complexity of these situations underlines once more the crucial importance of an evaluation and management by a pediatric expert multidisciplinary team.

In conclusion, respiratory problems are extremely common in children with neuromuscular and genetic diseases. The pathophysiological mechanisms are complex and highly variable and require an in-depth analysis by a pediatric team having an expertise in respiratory physiology and genetic diseases. Respiratory problems are responsible for a significant morbidity and mortality in children with neuromuscular and genetic diseases. They remain largely underestimated, underdiagnosed, and thus undertreated. An involvement of the respiratory system should be systematically searched for in numerous genetic diseases by a pediatrician having an interest and expertise in the diagnosis and management of multifaceted respiratory problems.

References

1. Fauroux B, Pigeot J, Polkey MI, Roger G, Boulé M, Clément A, et al. Chronic stridor caused by laryngomalacia in children. Work of breathing and effects of noninvasive ventilatory assistance. Am J Respir Crit Care Med. 2001;164:1874–8.
2. Fauroux B, Pigeot J, Isabey D, Harf A, Clément A, Lofaso F. In vivo physiological comparison of two ventilators used for domiciliary ventilation in children with cystic fibrosis. Crit Care Med. 2001;29:2097–105.
3. Fauroux B, Nicot F, Essouri S, Hart N, Polkey MI, Clément A, Lofaso F. Setting of pressure support in young patients with cystic fibrosis. Eur Resp J. 2004;24:624–30.
4. Essouri S, Nicot F, Clément A, Garabedian E-N, Roger G, Lofaso F, et al. Noninvasive positive pressure ventilation in infants with upper airway obstruction: comparison of continuous and bilevel positive pressure. Intensive Care Med. 2005;31:574–80.
5. Hart N, Polkey MI, Clément A, Boulé M, Moxham J, Lofaso F, et al. Changes in pulmonary mechanics with increasing disease severity in children and young adults with cystic fibrosis. Am J Respir Crit Care Med. 2002;166:61–6.
6. Giovannini-Chami L, Khirani S, Thouvenin G, Ramirez A, Fauroux B. Work of breathing to optimize noninvasive ventilation in bronchiolitis obliterans. Intensive Care Med. 2012;38(4):722.
7. Khirani S, Ramirez A, Aloui S, Leboulanger N, Picard A, Fauroux B. CPAP titration in infants with severe airway obstruction. Crit Care. 2013;17:R167.
8. Davis GM, Bureau MA. Pulmonary and chest wall mechanics in the control of respiration in the newborn. Clin Perinatol. 1987;14:551–79.

9. White JE, Drinnan MJ, Smithson AJ, Griffiths CJ, Gibson GJ. Respiratory muscle activity and oxygenation during sleep in patients with muscle weakness. Eur Respir J. 1995;8:807–14.
10. Dempsey JA, Veasey SC, Morgan BJ, O'Donnell CP. Pathophysiology of sleep apnea. Physiol Rev. 2010;90:47–112.
11. Fauroux B, Cordingley J, Hart N, Clément A, Moxham J, Lofaso F, et al. Depression of diaphragm contractility by nitrous oxide in humans. Anesth Analg. 2002;94:340–5.
12. Fauroux B, Nicot F, Boelle P-Y, Boulé M, Clément A, Lofaso F, et al. Mechanical limitation during CO_2 rebreathing in young patients with cystic fibrosis. Respir Physiol Neurobiol. 2006;153:217–25.
13. Fauroux B, Aubertin G, Clément A, Lofaso F, Bonora M. Which tests may predict the need for noninvasive ventilation in children with neuromuscular disease? Respir Med. 2009;103:574–81.
14. Poponick JM, Jacobs I, Supinski G, DiMarco AF. Effect of upper respiratory tract infection in patients with neuromuscular disease. Am J Respir Crit Care Med. 1997;156:659–64.
15. Hart N, Nickol AH, Cramer D, Ward SP, Lofaso F, Pride NB, et al. Effect of severe isolated unilateral and bilateral diaphragm weakness on exercise performance. Am J Respir Crit Care Med. 2002;165:1265–70.
16. Steier J, Jolley CJ, Seymour J, Kaul S, Luo YM, Rafferty GF, et al. breathing in unilateral diaphragm paralysis or severe weakness. Eur Respir J. 2008;32:1479–87.
17. Nicot F, Hart N, Forin V, Boulé M, Clément A, Polkey MI, et al. Respiratory muscle testing: a valuable tool for children with neuromuscular disorders. Am J Respir Crit Care Med. 2006;174:67–74.
18. Khirani S, Ramirez A, Aubertin G, Boulé M, Chemouny C, Forin V, et al. Respiratory muscle decline in Duchenne muscular dystrophy. Pediatr Pulmonol. 2014;49:473–81.
19. Khirani S, Colella M, Caldarelli V, Aubertin G, Boulé M, Forin V, et al. Longitudinal course of lung function and respiratory muscle strength in spinal muscular atrophy type 2 and 3. Eur J Paediatr Neurol. 2013;17:552–60.
20. Steier J, Jolley CJ, Seymour J, Teschler H, Luo YM, Polkey MI, et al. Screening for sleep-disordered breathing in neuromuscular disease using a questionnaire for symptoms associated with diaphragm paralysis. Eur Respir J. 2011;37:400–5.
21. Allamand V, Brinas L, Richard P, Stojkovic T, Quijano-Roy S, Bonne G. ColVI myopathies: where do we stand, where do we go? Skelet Muscle. 2011;1:30.
22. Quijano-Roy S, Khirani S, Colella M, Ramirez A, Aloui S, Wehbi S, et al. Diaphragmatic dysfunction in Collagen VI myopathies. Neuromuscul Disord. 2014;24:125–33.
23. Girbal IC, Gonçalves C, Nunes T, Ferreira R, Pereira L, Saianda A, et al. Non-invasive ventilation in complex obstructive sleep apnea: a 15 year experience of a pediatric tertiary center. Rev Port Pneumol. 2014;20:146–51.
24. Amaddeo A, Caldarelli V, Fernandez-Bolanos M, Moreau J, Ramirez A, Khirani S, et al. Polygraphic respiratory events during sleep in children treated with home continuous positive airway pressure: description and clinical consequences. Sleep Med. 2015;16:107–12.
25. Guillemot N, Troadec C, de Villemeur TB, Clément A, Fauroux B. Lung disease in Niemann-Pick disease. Pediatr Pulmonol. 2007;42:1207–14.
26. Bourke SC, Gibson GJ. Sleep and breathing in neuromuscular diseases. Eur Resp J. 2002;19:1194–201.
27. Griffon L, Amaddeo A, Mortamet G, Barnerias C, Abadie V, Olmo Arroyo J, et al. Sleep study as a diagnostic tool for unexplained respiratory failure in infants hospitalized in the PICU. J Crit Care. 2016;42:317–23.
28. Wright MJ, Irving MD. Clinical management of achondroplasia. Arch Dis Child. 2012;97:129–34.
29. Cassidy SB, Schwartz S, Miller JL, Driscoll DJ. Prader-Willi syndrome. Genet Med. 2012;14:10–26.
30. Katz SL, Gaboury I, Keilty K, Banwell B, Vajsar J, Anderson P, et al. Nocturnal hypoventilation: predictors and outcomes in childhood progressive neuromuscular disease. Arch Dis Child. 2010;95:998–1003.

31. Lal C, White DR, Joseph JE, van Bakergem K, LaRosa A. Sleep-disordered breathing in Down syndrome. Chest. 2015;147:570–9.
32. Bersanini C, Khirani S, Ramirez A, Lofaso F, Aubertin G, Beydon N, et al. Nocturnal hypoxemia and hypercapnia in children with neuromuscular disorders. Eur Respir J. 2012;39:1206–12.
33. Rutkowski A, Chatwin M, Koumbourlis A, Fauroux B, Simonds A, Consortium CRP. 203rd ENMC international workshop: respiratory pathophysiology in congenital muscle disorders: implications for pro-active care and clinical research 13-15 December, 2013, Naarden, The Netherlands. Neuromuscul Disord. 2015;25:353–8.
34. Amaddeo A, Moreau J, Frapin A, Khirani S, Felix O, Fernandez-Bolanos M, et al. Long term continuous positive airway pressure (CPAP) and noninvasive ventilation (NIV) in children: initiation criteria in real life. Pediatr Pulmonol. 2016;51(9):968–74.
35. Fauroux B, Quijano-Roy S, Desguerre I, Khirani S. The value of respiratory muscle testing in children with neuromuscular disease. Chest. 2015;147:552–9.
36. Stefanutti D, Fitting JW. Sniff nasal inspiratory pressure. Reference values in Caucasian children. Am J Respir Crit Care Med. 1998;159:107–11.
37. Fauroux B, Aubertin G, Cohen E, Clément A, Lofaso F. Sniff nasal inspiratory pressure in children with muscular, chest wall or lung disease. Eur Respir J. 2009;33:113–7.
38. Aloui S, Khirani S, Ramirez A, Colella M, Louis B, Amaddeo A, et al. Whistle and cough pressures in children with neuromuscular disorders. Respir Med. 2016;113:28–36.
39. Hart N, Tounian P, Clément A, Boulé M, Polkey MI, Lofaso F, et al. Nutritional status is an important predictor of diaphragm strength in young patients with cystic fibrosis. Am J Clin Nutr. 2004;80:1201–6.
40. Chatwin M, Ross E, Hart N, Nickol AH, Polkey MI, Simonds AK. Cough augmentation with mechanical insufflation/exsufflation in patients with neuromuscular weakness. Eur Respir J. 2003;21:502–8.
41. Fauroux B, Guillemot N, Aubertin G, Nathan N, Labit A, Clément A, et al. Physiologic benefits of mechanical insufflation-exsufflation in children with neuromuscular diseases. Chest. 2008;133:161–8.
42. Ward S, Chatwin M, Heather S, Simonds AK. Randomised controlled trial of non-invasive ventilation (NIV) for nocturnal hypoventilation in neuromuscular and chest wall disease patients with daytime normocapnia. Thorax. 2005;60:1019–24.
43. Chatwin M, Bush A, Simonds AK. Outcome of goal-directed non-invasive ventilation and mechanical insufflation/exsufflation in spinal muscular atrophy type I. Arch Dis Child. 2011;96:426–32.
44. Khirani S, Bersanini C, Aubertin G, Bachy M, Vialle R, Fauroux B. Noninvasive positive pressure ventilation to facilitate the post operative respiratory outcome of spine surgery in neuromuscular children. Eur J Spine Surg. 2014;23(Suppl 4):S406–S11.
45. Rabec C, Emeriaud G, Amaddeo A, Fauroux B, Georges M. New modes in non-invasive ventilation. Paediatr Respir Rev. 2016;18:73–84.

Pulmonary Complications of Obstetric and Gynecologic Conditions

Amisha Jain and Iman R. Sami-Zakhari

Introduction

A fundamental difference between the female reproductive system compared with virtually every other organ system in the body is that it goes through significant changes on a regular basis during the woman's healthy menstrual cycle and not only in a state of disease as is the case for virtually any other organ system. Even more significant are the changes that occur during pregnancy when the entire body changes to accommodate the developing fetus. Although none of these changes are directly related to the respiratory system, they do exert a significant effect in the mechanics of breathing. Thus, the physician who cares for a woman with respiratory symptoms has to consider if and to what extent they are caused, complicated, or exacerbated by an underlying gynecologic or obstetric condition. This chapter focuses on the normal alterations in pulmonary physiology during pregnancy and how it may affect the natural history of specific respiratory diseases and of course how the respiratory disease may affect the pregnancy outcome. Lung disorders related to gynecologic conditions are also described.

A. Jain, M.D. • I.R. Sami-Zakhari, M.D., M.R.C.P. (✉)
Division of Pulmonary and Sleep Medicine, Children's National Health System, George Washington University, School of Medicine and Health Sciences, Washington, DC, USA
e-mail: ajain@childrensnational.org; ISami@childrensnational.org

© Springer International Publishing AG 2018

A.C. Koumbourlis, M.A. Nevin (eds.), *Pulmonary Complications of Non-Pulmonary Pediatric Disorders*, Respiratory Medicine,
https://doi.org/10.1007/978-3-319-69620-1_8

Physiological Changes During Pregnancy

Profound physiological changes occur in both the pulmonary and cardiovascular systems during pregnancy. Understanding these changes and how they may affect other underlying disorders helps in the management of respiratory disease during pregnancy.

Effects on the Upper Airways

In the upper respiratory tract, edema of the nasal mucosa resulting in symptoms of rhinitis ("rhinitis of pregnancy") has been reported in as many as 20–40% of pregnant women. It characteristically appears during the last 6 weeks of pregnancy in the absence of any infectious or allergic trigger, and it completely resolves within 1–2 weeks after delivery. Its exact cause is not known. Various factors have been implicated in its pathogenesis including the effect of placental growth hormone on the mucosa and increases in the circulating blood volume.

Other alterations in the upper airways include increases in the Mallampati score (that assesses the space between the base of the tongue and the roof of the mouth) and in the neck circumference. The decrease in the size of the upper airways is assumed to be caused by the overall alterations in the lung volumes that affect the caudal traction, and by fat infiltration of the tissues, and it is exacerbated in supine position.

Effects on the Chest Wall

During pregnancy the configuration of the chest wall is altered in order to accommodate the enlarging uterus. The changes include increases in the transverse diameter of the thorax that results into an increase of approximately 50% in the subcostal angle. As a result, the diaphragm is elevated by 4–5 cm. This would significantly impair the ability of the diaphragm to move during inspiration, but it is compensated by an increase in the anteroposterior diameter as well that allows the diaphragm to maintain a fairly normal excursion. However, the overall chest wall compliance decreases. There appears to be no effect on the respiratory muscle strength although the changes in the chest wall configuration probably puts the muscle at a mechanical disadvantage, thus contributing to the increased work of breathing that pregnant women experience. Interestingly, most of the alterations in the chest wall occur primarily during the first trimester of the pregnancy when the uterus is still too small to have any substantial mechanical effect. It is believed that

the chest wall configuration changes as a result of hormonal action, especially of relaxin that relaxes the ligaments of the lower rib cage, thus allowing the increase in the diameters.

Effects on the Lung Volumes and Lung Function

The alterations in the configuration of the chest wall confer surprisingly relatively little change in lung volumes and even less in lung function (Table 1). The most substantial change occurs in the functional residual capacity (FRC) that is usually decreased by about 18% primarily due to a decrease in the expiratory reserve volume (ERV) and residual volume (RV). This is due to elevation of the diaphragm and increased pulmonary blood volume in pregnancy. The inspiratory capacity (IC) remains essentially the same or even increases, and as a result, the total lung capacity (TLC) is only marginally decreased.

There are changes in the respiratory drive and minute ventilation, both of which increase under hormonal influence. The increase in minute ventilation offsets the increased carbon dioxide production, so primary respiratory alkalosis with pH ranging from 7.40 to 7.47 and pCO_2 ranging from 28 to 32 is a normal finding in pregnancy.

Table 1 Changes in lung function during pregnancy

Lung volumes	
TLC	Unchanged or slightly decreased
FRC	Decreased
ERV	Decreased
RV	Decreased
IC	Unchanged or increased
Tidal volume (VT)	Increased
Lower airway function	
FVC	Unchanged or slightly increased
FEV_1	Unchanged
FEV_1/FVC	Unchanged
FEF_{25-75}	Unchanged
Airway resistance (raw)	Unchanged
Gas exchange	
Diffusing capacity	Unchanged
pH	Increased (first trimester > third trimester)
PaO_2	Increased (first trimester > third trimester)
$PaCO_2$	Decreased (first trimester < third trimester)
HCO_3	Decreased

Pulmonary Disorders in Obstetrics

Obstructive Airway Disease

Asthma

Asthma is one of the most common chronic respiratory diseases complicating pregnancy with an estimated prevalence of 3.7–8.4% of all pregnancies. Asthma is clinically characterized by recurrent episodes of reversible bronchoconstriction. There is a bidirectional interaction of asthma and pregnancy where asthma influences pregnancy outcomes and pregnancy affects asthma severity. Poorly controlled asthma is associated with adverse perinatal outcomes; however, when asthma is well controlled, pregnancy is not adversely affected.

Effect of Pregnancy on Asthma

The course of asthma during pregnancy improves in about one-third of women, worsens in one-third, and remains the same in the other one-third. The course is determined by the baseline asthma severity with more severe asthma prior to pregnancy conferring a higher risk of worsening during pregnancy. There is evidence that the course of asthma is similar in subsequent pregnancies. There is evidence that female fetuses are associated with worsening of the maternal asthma, suggesting the influence of hormonal causes.

Effect of Asthma on Pregnancy

Uncontrolled asthma increases the risk of severe maternal and fetal complications including preeclampsia, preterm birth, low birth weight, intrauterine growth restriction, and increased perinatal mortality. Immunological mechanisms in asthma influence pregnancy. It has been shown that poorly controlled asthma in pregnant women is associated with immune reactions that influence fetal growth.

Management

The focus of management is to maintain adequate control of asthma during pregnancy that will improve both maternal and fetal outcomes.

Diagnosis and Monitoring

The diagnosis of asthma is usually known prenatally, but the symptoms may occur for the first time during pregnancy. Spirometry showing lower airway obstruction that is reversible with bronchodilators is very useful in confirming the diagnosis.

However, the absence of an obstructive pattern is not a contraindication to treating the patient if there is sufficient clinical suspicion. Bronchial challenge tests are contraindicated during pregnancy due to the lack of safety data. Performing a skin prick test during pregnancy for the possibility of allergic asthma is also not recommended due to the risk of systemic reactions.

Fractional nitric oxide (FeNO) concentration in exhaled breath is a relatively new tool to monitor asthma control. According to a recent study, FeNO levels are not altered in pregnancy, and they correlate with the level of asthma control. However, as in the nonpregnant population, the limitation of the FeNO is that it reflects primarily the eosinophilic asthma and not all types of asthma. Monthly assessment of asthma control during prenatal visits is strongly recommended as well as patient education.

Treatment

Despite the concern about administering medications during pregnancy and their effect on the fetus, it is safer for pregnant women with asthma to be treated with asthma medications than to experience exacerbations that may increase the risk of perinatal mortality. Most studies have shown no increased perinatal risk with the use of beta-agonist and inhaled corticosteroids. Some epidemiologic studies have shown an increased risk of congenital abnormalities (cleft palate with oral corticosteroids, gastroschisis with bronchodilators) in the offsprings of asthmatic women, but the evidence is far from conclusive. It should be noted that congenital abnormalities develop very early in pregnancy (sometimes before the woman realizes that she is pregnant), and therefore withholding the medications later in pregnancy would confer no benefit.

Albuterol is the preferred reliever medication because of its overall excellent safety profile. Inhaled corticosteroids (ICS) are the preferred controller medication with budesonide being the preferred choice due to the availability of reassuring data in pregnant women. It is important to note that no data indicates that other ICS are unsafe during pregnancy, and if a patient was well controlled before, she should continue taking the same asthma medications during pregnancy.

Long-acting beta-agonists (LABAs) may be used as an alternative controller medication if clinically warranted by symptoms not controlled with ICS. A recent retrospective study showed no difference in the risk profile of step-up therapy with low-dose ICS/LABA inhalers or high-dose ICS in terms of major congenital malformations.

Leukotriene receptor antagonists (LTRAs) seem to be safe based on the animal safety data submitted to FDA; however, availability of human data is scarce.

The use of asthma medications should be continued during labor and delivery. Lumbar epidural anesthesia is preferred over general anesthesia, if cesarean section is required, and ketamine is the preferred anesthetic.

The key in asthma management is remembering that adequate control of asthma can improve the health of both mothers and their babies.

Cystic Fibrosis

Cystic fibrosis (CF) is an autosomal recessive disorder affecting the body's exocrine glands, including the pancreas, sweat glands, and lungs. It is the most common life-shortening genetic disorder in Caucasians with a carrier frequency rate of 1 in 25 and an incidence of 1 in 3000 live births in Caucasians. It is present in other races albeit less commonly with an incidence of 1 in 9000 and 1 in 15,000 live births in Hispanic and African-American populations in the United States. The most common gene deletion in 70% of genes is the delta F508, which leads to a misfolded CF transmembrane conductance regulator protein resulting in impaired movement of water and electrolytes across epithelial surfaces. In the last few decades, there have been improvements in treatment and survival, and the median life expectancy is now 41 years. About 4–5% of female patients become pregnant.

Malnutrition and thick cervical mucus may impair female fertility. Despite the concern that pregnancy would have an adverse impact on the mother, a large US review of 680 pregnant women with CF enrolled in the US Cystic Fibrosis Foundation National Patient Registry (1985 to 1997) demonstrated that survival was actually better in the pregnant female group than in the matched 3327 control patients with CF. They had higher predicted percentages of FEV_1 and higher weights. After adjustment of age, colonization *with Pseudomonas aeruginosa*, pancreatic function, and prepregnancy FEV_1, the pregnancy did not appear harmful. In another case-control study, pregnancy had little effect on patients with stable CF, although poor outcomes were seen in those with severe disease. The presence of pulmonary hypertension, cor pulmonale, or $FEV_1 < 30\%$ predicted is a relative contraindication to pregnancy.

Management

Prior to pregnancy, genetic counseling should be offered and should include a risk estimate of having a child with CF as it can be as high as 50% if the father is heterozygous for the gene. During pregnancy, fetal surveillance to detect early signs of growth restriction is essential.

Pregnant women with CF need regular monitoring by a dedicated team, to achieve favorable pregnancy outcomes. Commonly reported adverse events are fetal growth restriction and prematurity which includes iatrogenic early delivery because of maternal health deterioration. Women with CF are also at an increased risk of developing gestational diabetes. So screening for diabetes, baseline lung function tests as well as dietary supplementation, enzyme supplements, and chest physical therapy are important. Pulmonary exacerbations should be treated aggressively with antibiotic therapy paying attention to the class of medications and using those approved for use during pregnancy.

There is no contraindication to vaginal delivery; however, there is a small risk of pneumothorax if the second stage is very prolonged. General anesthesia should be minimized. There is no contraindication to breastfeeding, but mothers will need to use nutritional supplements in the postnatal period to ensure adequate caloric intake.

Infectious Diseases

The frequency of pneumonia in pregnancy is similar to that in the general population.

Effect of Pneumonia on Pregnancy

Infants born to women who develop pneumonia during pregnancy have a higher risk of being low birth weight and small for gestational age. Pneumonia may also precipitate preterm labor. Intrauterine and neonatal deaths have also been reported. Poor maternal and fetal outcomes occur primarily in mothers with underlying chronic respiratory illnesses.

Effect of Pregnancy on Pneumonia

Pregnancy increases the risk of complications of pneumonia including respiratory failure, and the mortality is higher.

Bacterial Pneumonia

The most common pathogens causing bacterial pneumonia in pregnancy are *Streptococcus pneumoniae*, *Haemophilus influenzae*, and *Mycoplasma pneumonia*. The clinical features are similar to those in nonpregnant patients with fever, cough, dyspnea, and rigors as the presenting symptoms. A chest radiograph may be obtained to confirm the diagnosis. Penicillin, cephalosporins, and macrolides are safe antibiotics for use during pregnancy. Tetracyclines should be avoided as they may cause teeth discoloration in the fetus.

Viral Pneumonia

Influenza epidemics have shown that the morbidity and mortality rate in pregnant women is higher compared with nonpregnant women. Influenza vaccination has been shown to reduce hospitalization rates among pregnant women; therefore, the Centers for Disease Control and Prevention (CDC) recommends inactivated influenza vaccine during the second and third trimesters of pregnancy.

In 2009, a previously unrecognized strain of influenza A (H1N1) virus emerged and caused increased morbidity and mortality in pregnant women. Treatment with oseltamivir in pregnant women provided better protection against maternal-fetal transmission.

Maternal varicella pneumonia is associated with high mortality rates. Antiviral therapy with acyclovir reduces the mortality rates in pregnant patients and should be considered in the treatment of active disease. Passive immunization with varicella

zoster immune globulin (VariZIG) has been shown to reduce the risk of congenital varicella syndrome and is also effective in preventing maternal complications of varicella. The live attenuated vaccine against varicella is contraindicated in pregnancy.

Fungal Pneumonia

Fungal pneumonias are not common during pregnancy. Coccidioidomycosis is the most extensively studied fungal infection in pregnancy and can affect the outcome if it is disseminated. Compared with the general population, the risk of disseminated infection is higher in pregnant women, especially in the third trimester of pregnancy. Possible reasons are impairment of cell-mediated immunity and a stimulatory effect of progesterone on fungal proliferation. Amphotericin is the preferred antifungal for disseminated coccidioidomycosis. Azoles should be avoided during pregnancy due to an association with branchial cleft abnormalities. There is no evidence that other fungal infections, including blastomycosis, histoplasmosis, sporotrichosis, and cryptococcosis, are more severe during pregnancy.

Pneumonia complicating HIV infection in pregnancy is most commonly caused by a yeastlike fungus *Pneumocystis jirovecii*; it should be suspected in the presence of hypoxia that is out of proportion to the chest X-ray findings. Treatment is with high-dose co-trimoxazole/pentamidine with folate supplementation.

Tuberculosis

Pregnancy and tuberculosis have little effect on one another. Patients are often asymptomatic but can present with typical symptoms of cough, night sweats, hemoptysis, and weight loss. Tuberculin skin testing can be used for screening patients, and treatment should not be delayed during pregnancy. Rifampicin, isoniazid, and ethambutol are standard antitubercular drugs approved by the CDC due to their acceptable safety profile. Streptomycin is associated with congenital deafness and is contraindicated. Guidelines for the evaluation and management of newborns born to mothers with tuberculosis should be followed.

Aspiration Pneumonia

Aspiration pneumonia is a major cause of maternal morbidity and mortality. The pregnant woman is predisposed to aspiration during labor and delivery due to increased intra-abdominal pressure from the gravid uterus, relaxed gastroesophageal sphincter due to the effect of progesterone, delayed gastric emptying, vigorous abdominal palpation during examinations, and sedation and analgesia given in the delivery room.

Aspiration of the acidic gastric contents with a pH less than 2.5 induces chemical pneumonitis and pulmonary edema. Most cases of aspiration occur at the time of delivery. If general anesthesia or endotracheal intubation is needed, prophylaxis in the form of H2 blockers, metoclopramide, or sodium citrate is often given before intubation.

The clinical presentation includes tachypnea, bronchospasm, hypoxemia, and hypotension with chest radiograph findings of either isolated or diffuse infiltrates. The timing of presentation depends on the volume of the aspirate with large volumes causing immediate asphyxiation and smaller volumes becoming apparent 6–8 h after the event. Respiratory failure can sometimes manifest in the postpartum period.

Management is supportive and includes oxygen, bronchodilators, and ventilatory support. Antibiotics should be considered early if there is suspicion of bacterial infection. The common bacterial pathogens are *Staphylococcus aureus*, gram-negatives, or anaerobes originating from the oropharynx.

Restrictive Lung Diseases

Restrictive lung diseases are characterized by a decrease in total lung capacity. This can be caused by abnormalities in the pleura, chest wall, and neuromuscular apparatus or alterations in the lung parenchyma. In most cases, due to the large pulmonary reserve, pregnancy is unaffected; however, in severe restriction, problems may arise during pregnancy and labor due to impaired reserve and higher oxygen demands. The gravid uterus pushes the diaphragm upward, thereby further worsening the restriction. As a general rule, patients with a FVC of <1 L or <50% of predicted FVC and those who have pulmonary hypertension are at greater risk of cardiopulmonary complications and hence should consider avoiding pregnancy or consider a therapeutic termination.

Kyphoscoliosis

Kyphoscoliosis is an abnormality of the spine characterized by posterior or lateral curvature or both. Almost half of the cases are idiopathic.

Effect of Kyphoscoliosis on Pregnancy

Depending on the site of primary curvature in pregnant females, there can be cardiopulmonary complications or obstetrical complications such as cephalopelvic disproportion. Other obstetrical complications experienced by pregnant women with kyphoscoliosis include prematurity and low birth weight.

Effect of Pregnancy on Kyphoscoliosis

It is controversial if spinal curvature will worsen during pregnancy**.** Studies have shown that the risk of progression of the curvature is low unless the scoliosis is unstable at the time of pregnancy. The presence of kyphoscoliosis during pregnancy may cause back pain.

Sarcoidosis

Sarcoidosis is a multisystem disorder of unknown etiology that is characterized by noncaseating epithelioid granulomas. The most common site of granuloma formulation is the lungs. Other organs include the lymph nodes, eyes, skin, liver, heart, and nervous system.

Since the disease can involve any organ system, clinical manifestations are variable ranging from dyspnea, nonproductive cough, and chest pain to fever, joint/muscle aches, visual changes, and erythema nodosum. The disease has a variable course with spontaneous remissions occurring in nearly two-thirds of patients.

Effect of Sarcoidosis on Pregnancy

Sarcoidosis has not been found to adversely affect pregnancy outcomes. It is not transmitted to the fetus and does not increase the incidence of maternal or fetal complications.

Effect of Pregnancy on Sarcoidosis

Improvement in sarcoidosis occurs during pregnancy with a tendency to relapse in the postnatal period. Factors that indicate a poor prognosis in pregnancy include parenchymal infiltrates on chest radiograph, advanced radiographic staging, low inflammatory activity, advanced maternal age, requirement for drugs other than steroids for disease control, and the presence of extrapulmonary disease. Except for severely affected patients, sarcoidosis is not a contraindication to pregnancy.

Management

The diagnosis usually warrants a tissue biopsy of the involved organ that shows noncaseating granulomas. The patient may also have other laboratory abnormalities including an increased angiotensin-converting enzyme (ACE) level, elevated liver enzymes, and hypercalcemia.

Pulmonary function tests are abnormal in many patients and generally show a restrictive pattern but may be normal or obstructed if there is endobronchial involvement, stenosis, or airway distortion from parenchymal disease. There may also be a reduction in diffusion capacity.

Systemic steroids are the main stay of therapy and should be continued in pregnancy.

Acute Respiratory Distress Syndrome in Pregnancy

Acute respiratory distress syndrome (ARDS) is a severe form of acute lung injury characterized by severe hypoxemia and bilateral pulmonary infiltrates resulting from increased alveolar-capillary permeability.

ARDS in pregnancy can develop from obstetric and non-obstetric complication. The common obstetric causes are chorioamnionitis, amniotic fluid embolism, trophoblastic embolism, and placental abruption. The most common non-obstetric causes are pneumonia, sepsis, and aspiration.

Due to the changes in the definition of ARDS, it has been difficult to determine the true prevalence of the condition with estimates ranging from 1.5 to 75 cases per 100,000 population. The prevalence of ARDS during pregnancy is comparable to the number in the general population: however, the mortality rates of ARDS for both the mother and the fetus are high.

There is not enough evidence available regarding the management of ARDS in pregnancy, and treatment strategies are extrapolated from the studies on the general population. A multidisciplinary approach is necessary to optimize maternal and fetal outcomes and manage ARDS in pregnancy.

Pulmonary Edema and Pulmonary Vascular Disease

Pulmonary Edema

Acute pulmonary edema in pregnancy is an uncommon yet significant cause of morbidity and mortality with an estimated incidence of 0.08–0.5%. It was reported as the fourth most common form of maternal morbidity in the Scottish Confidential Audit of Severe Maternal Morbidity, which is one of the largest maternal morbidity audits. Acute pulmonary edema may occur during the antenatal, intrapartum, or postpartum periods.

Pregnant women are at an increased risk for pulmonary edema due to the hypervolemia and high cardiac output of pregnancy, the occasional need for tocolytic drugs that affect the vascular bed, and some clinical conditions unique to pregnancy. It is now recognized that in addition to fluid accumulation and retention,

fluid redistribution from the systemic circulation to the pulmonary circulation also plays an important role in causation of pulmonary edema.

Clinically, the patient presents with acute onset of breathlessness, orthopnea, cough, tachycardia, tachypnea, and hypoxemia. Chest X-ray, ECG, and echocardiography may help establish the diagnosis. In contrast to nonpregnant women, serum concentration of B-type natriuretic peptide is not widely utilized in pregnancy.

Transthoracic echocardiography is very helpful in diagnosis and management of the pulmonary edema as it enables assessment of cardiac systolic function.

Treatment is supportive and includes fluid restriction, circulation control with vasodilators, oxygenation, mechanical ventilation if needed, and close monitoring.

Pulmonary Embolism

Pulmonary embolism (PE) is a leading cause of maternal mortality accounting for 20% of maternal deaths in the United States. The estimated incidence of pulmonary embolism is 10.6 per 100,000 with the highest risk during the postpartum period.

Pregnant patients are predisposed to thromboembolic disease for several reasons including (1) an increase in several coagulation factors and a decrease in fibrinolytic activity, leading to a hypercoagulable state, (2) venous stasis caused by uterine compression of the inferior vena cava and the left iliac vein, and (3) trauma to pelvic veins at the time of delivery. This might account for the peak incidence of thromboembolism in the postpartum period, especially after cesarean section.

Other risk factors for developing thromboembolism include a past history of thromboembolism during pregnancy or while taking oral contraceptives, patients more than 35 years of age, prolonged bed rest, complicated or cesarean delivery, and inherited coagulation defects.

Clinical symptoms of pulmonary embolism (PE) include acute onset of dyspnea, tachypnea, tachycardia, and pleuritic chest pain that can rapidly progress to arrhythmias, syncope, and cardiovascular collapse if the PE is massive.

Despite the current availability of an array of diagnostic tests, diagnosis of a pregnant woman with suspected PE is very challenging. Recent ATS guidelines from the American Thoracic Society for evaluation of suspected PE in pregnancy recommend performing a chest radiograph (CXR) as the first test; if the chest X-ray is normal, then lung scintigraphy/ventilation-perfusion (V/Q) scan is recommended and finally computed tomographic pulmonary angiography (CTPA) rather than digital subtraction angiography (DSA) if the ventilation-perfusion (V/Q) scan is negative.

The patient can also be evaluated for the presence of a deep venous thrombosis (DVT), the presence of which increases the likelihood that the patient has a PE. Again, it is very difficult to diagnose DVT during pregnancy since contrast venography, which is the diagnostic test for DVT in nonpregnant patient, is usually performed in a limited manner to minimize the radiation exposure, thus decreasing the sensitivity of the test.

Treatment of DVT and PE necessitates the use of anticoagulants. Heparin is the drug of choice since warfarin crosses the placenta and can cause fetal dysmorphism, congenital heart defects, and growth retardation. Low-molecular-weight heparin (LMWH) is an alternative to standard heparin treatment and appears to be safe in pregnancy with fewer adverse effects such as thrombocytopenia and osteoporosis.

Treatment should be given throughout pregnancy and continued for about 4–6 weeks after delivery. If thrombosis occurs late in the pregnancy, treatment may be required for up to 3 months after delivery.

Thrombolytic therapy has also been used successfully in life-threatening thromboembolism during pregnancy. Other management options for a massive pulmonary embolism in pregnancy include surgical embolectomy and catheter-directed therapy.

Amniotic Fluid Embolism

During uncomplicated pregnancies, small amounts of amniotic fluid may enter the maternal circulation. Amniotic fluid contains fetal debris, including desquamated squamous cells, meconium, lanugo hair, and mucin. In a very small percentage of deliveries (estimated at 7.7 per 100,000 deliveries), amniotic fluid embolism develops with high maternal mortality rates of 80–90%. Clinical signs include sudden onset of severe dyspnea, hypoxemia, cyanosis, cardiovascular collapse, seizures, and coma that may occur during labor and delivery. This may progress to ARDS and disseminated intravascular coagulation (DIC).

Risk factors for developing amniotic fluid embolism include premature rupture of membranes, advanced maternal age, meconium staining of amniotic fluid, multiparity, and cesarean section. Disruption of the uterine veins has a role in pathogenesis. Two possible sites of entry are at the site of placental separation and small tears in the lower uterus and endocervix. It is unclear how much amniotic fluid is required to initiate the syndrome. The diagnosis can be made by the presence of a large amount of fetal squamous cells, mucin, and lanugo in the blood removed from the distal lumen of a wedged pulmonary artery catheter.

Treatment is primarily supportive for disseminated intravascular coagulation and cardiopulmonary failure.

Air Embolism

Venous air embolism results from entrapment of air in the venous system. It is an infrequent complication of pregnancy but can occasionally occur during labor and delivery especially during cesarean sections, induced abortions, manual extraction of placenta, and vacuum and forceps delivery. It has been also reported as a possible complication of oro-genital sex during pregnancy.

Air passes beneath the fetal membranes and into the circulation of the subplacental sinuses. Nonfatal air embolism during cesarean section may be more common than appreciated (studies suggest an incidence as high as 50%). A lethal air embolism

may follow a bolus of 3–5 cc/kg of air. The clinical presentation is acute onset tachypnea, chest pain, and gasping due to obstruction of pulmonary arterial blood flow. Diagnosis is very difficult and requires a high index of suspicion. Transesophageal echocardiogram offers the most sensitive measurement of air trapped within the right atrium or ventricle; however, it has the limitation of being invasive. Precordial Doppler is less sensitive but noninvasive.

Management includes optimum patient positioning, aspiration of air, discontinuation of nitrous oxide, administration of 100% oxygen, and flooding the surgical site with saline to prevent further air entry. There are case reports of maternal and fetal death with venous air embolism, so familiarity with this syndrome is important if prompt and appropriate therapy is to be provided.

Pulmonary Arteriovenous Malformation

Pulmonary arteriovenous malformations (PAVMs) are abnormal communications between the pulmonary and systemic circulation, which cause a right-to-left shunt. More than half of the cases reported during pregnancy are associated with hereditary telangiectasia, an autosomal dominant disorder characterized by the development of multiple arteriovenous malformations in the skin, mucous membranes, and/or visceral organs.

These PAVMs may expand during pregnancy because of the increase in blood volume, cardiac output, and venous distensibility, which increases the likelihood of rupture leading to life-threatening hemoptysis and hemothorax.

Diagnosis is based upon transthoracic contrast echocardiography and CT scan that also help to plan percutaneous embolization, which is the treatment of choice during pregnancy.

Spontaneous Pneumothorax in Pregnancy

Spontaneous pneumothorax is primary when it occurs in a person with no apparent lung disease or secondary as a complication of preexisting lung disease. It is rare in pregnancy. It can occur in the pre- or postpartum period but is most common during labor when the increase in alveolar intrathoracic pressure causes rupture of previously unrecognized blebs in the subpleural space.

Common predisposing factors for pneumothorax in pregnancy are previous respiratory infections, asthma, or a previous pneumothorax unrelated to pregnancy.

The diagnosis may be obscured due to other causes of dyspnea in pregnancy or the discomfort of parturition. This is a potentially serious situation since any impairment in ventilation during pregnancy can have detrimental effects on both the mother

and fetus. Spontaneous pneumothorax should be considered in a pregnant woman with acute onset dyspnea, chest pain, or history of prior pneumothorax. Prompt recognition and timely treatment of pneumothorax can prevent complications. The diagnosis can be confirmed with a chest radiograph with an abdominal shield.

Initial management is generally based on the size of the pneumothorax and may involve observation, drainage with a chest tube, or video-assisted thoracotomy (VATS). If the pneumothorax occurs close to term and is large enough to require placement of a chest tube, induction of labor should be considered with the chest tube in place to avoid recurrence during labor.

There is no evidence that cesarean section is necessary, and it should be performed for obstetric indications only. Patients with recurrent pneumothorax, who require VATS, should undergo surgery after the period of organogenesis and before the pregnancy is too far advanced.

Lung Transplant Patients

Improvement in survival and quality of life in patients with lung transplants has prompted them to consider pregnancy. Successful pregnancy is possible after lung transplantation, but it requires planning and a multidisciplinary team approach involving maternofetal medicine, respiratory and transplant medicine, anesthesia, neonatology, genetics, and social services.

Since the first successful pregnancy reported in 1996 in a patient with single lung transplant, there have been several successful pregnancies. The 2010 report of the National Transplantation Pregnancy Registry reported 30 pregnancies in 21 lung transplant recipients, of which 18 were live births. Cystic fibrosis was the most common cause of lung transplant in 10 out of 21 recipients.

According to the most recently (in 2013) published management update on pregnancy after solid organ transplantation, it is recommended that pregnancy should be avoided for at least 1 year after transplant to minimize the episodes of acute rejection. It is also recommended that adequate and stable graft function should be achieved before pregnancy.

Patients should be counseled regarding the increased risk for both maternal and neonatal complications including prematurity and low birth weight. Of note is that the frequency of congenital malformations is similar to that of the general population (3–4%). The risk of rejection in patients who have stable graft function is not increased, except for patients with lung transplants who have a higher incidence of acute rejection compared with other organs (lung, 36%; heart, 20%; liver, 10%; kidney, 9%).

Lung transplant recipients are at a higher risk of developing hypertension and renal dysfunction. These comorbidities increase the risk of preeclampsia and preterm delivery, (6–13% vs. 2–7% in the general population).

Vaginal delivery is acceptable unless cesarean section is indicated for obstetric reasons. Breastfeeding should be avoided to prevent exposure of the newborn to immunosuppressive drugs.

Obstructive Sleep Apnea

Physiological and hormonal changes of pregnancy may predispose pregnant women to developing OSA. However, the prevalence of OSA among women of reproductive age is estimated to be 5–6%, but the exact prevalence of OSA among pregnant women is not known.

There is some evidence suggesting that OSA is associated with adverse maternal and fetal outcomes, due to low oxygen levels during apneic episodes. There are some protective mechanisms against OSA during pregnancy. High levels of progesterone have a stimulatory effect on the respiratory system, a decrease in REM sleep in later stages of pregnancy, and the rightward shift of the oxyhemoglobin dissociation curve. OSA generally occurs in obese patients and is precipitated by the estrogen-induced airway mucosal edema and vascular congestion.

Snoring is the most common symptom of OSA, but it is less specific than witnessed apneas and choking sensations during sleep for a diagnosis of OSA. There are no specific guidelines for screening pregnant women for OSA; however, it is prudent to evaluate pregnant women with loud snoring and witnessed apneas with overnight polysomnography.

Nasal continuous positive airway pressure (CPAP) is generally well tolerated during pregnancy. Patients should also be encouraged to follow conservative measures such as sleeping in the side position, elevation of the head of the bed, and avoiding the use of alcohol and sedatives.

Postpartum withdrawal of therapy with close follow-up should be considered due to rapid improvement of sleep apnea symptoms in the postnatal period.

Contraception and Pregnancy in Rare Lung Diseases

Rare Diseases are defined as conditions affecting less than 1 in 2000 people (in Europe) or less than 200,000 individuals (in the United States). Rare lung diseases (RLD) constitute 3% of these rare diseases. RLD are chronic in character and often have a poor prognosis. Advances in medicine have improved the survival and the quality of life in these patients, so they seek medical advice in planning their reproductive life.

However, in certain conditions, pregnancy is contraindicated due to the adverse effect on the course of the disease. In lymphangioleiomyomatosis (LAM), there is a very high risk of pneumothorax and loss of lung function, and in primary pulmonary hypertension (PPH), there is a high risk of mortality.

The contraceptive method should be individualized based on the personal choices of the patients and on the underlying disease process. All patients can safely use condoms. Oral contraceptives should be used cautiously in patients with cystic fibrosis due to poor absorption; they are absolutely contraindicated in LAM due to disease progression from exogenous estrogen. Since pregnancy is contraindicated in LAM, surgical sterilization should be considered in patients with LAM and PPH. Consideration should also be given to the future possibility of lung transplantation; therefore, combined hormone contraceptives should be avoided due to the risk of pulmonary thromboembolism. Currently, the experience in managing the reproductive health of women with RLD is limited, but based on the current experience, individualized and multidisciplinary approach is recommended to assist patients in making the best decisions about contraception and pregnancy.

Gynecologic Disorders and the Lungs

Thoracic Endometriosis Syndrome

Endometriosis is a condition characterized by the presence of endometrial tissue outside of the uterine cavity or myometrium. It is encountered most commonly in pelvic structures such as the ovary, uterine ligaments, pelvic peritoneum, cervix, labia, and vagina. Thoracic endometriosis syndrome (TES) is defined as the presence of endometrial tissue in or around the lung. Endometrial tissue may be present in the lung parenchyma, visceral and parietal pleura, diaphragm, and endobronchial sites. There are four distinct clinical entities:

(a) Catamenial pneumothorax
(b) Catamenial hemothorax
(c) Hemoptysis
(d) Pulmonary nodules

The clinical manifestations of TES imply the presence of endometrial tissue in the thoracic cavity that undergoes cyclical sloughing in response to the physiologic hormonal variations, and the clinical presentation depends on the affected structures.

How endometrial tissue migrates to the thoracic cavity has remained elusive; however, three theories have been proposed to explain it:

(a) Retrograde menstruation with subsequent transperitoneal-transdiaphragmatic migration of endometrial tissue
(b) Coelomic metaplasia
(c) Lymphatic or hematogenous embolization from the uterus or pelvis

The disease probably has a multifactorial etiology, since none of these theories can fully explain all the clinical manifestations of TES.

Since TES is a rare condition, a high index of suspicion is the key to timely diagnosis. The clinical presentation is of a woman in her reproductive years (with a peak incidence between the ages of 30 and 35 years), who reports recurrent episodes of chest pain, dyspnea, or cough around the time of her menstrual cycle. Catamenial pneumothorax accounts for only 2.5–5% of cases of spontaneous pneumothorax in women even though it is the presenting symptom in 73% of cases of TES, followed by hemothorax in 14% and hemoptysis in 7%.

Physical examination findings are nonspecific. CT and MRI have been shown to be helpful in the diagnosis. MRI may be superior to CT since it helps in differentiating pleural from parenchymal implants. Bronchoscopy has a limited role in diagnosis due to the peripheral location of the disease and the low diagnostic yield of bronchial washings. In the era of endoscopic surgery, VATS allows direct visualization of the lung and diaphragmatic surfaces for endometrial implants. The size of the implants usually ranges from a few millimeters to a centimeter, and depending on the timing during the menstrual cycle, their color varies from brown to violet. Exploratory thoracotomy now has a limited role in the diagnosis and is used in cases of failure of VATS exploration.

Catamenial Pneumothorax

Catamenial pneumothorax (CP) refers to the occurrence of spontaneous pneumothorax during mensuration. It is also known as menstruation-related spontaneous pneumothorax (MSP) which was first reported in the 1950s by Maurer et al., who defined it as pneumothorax occurring within 24–72 h after onset of menses. In 1972, Lillington et al. introduced the term catamenial pneumothorax for spontaneous pneumothorax associated with menses. Previously considered to be rare, current knowledge suggests that CP is a more common reason for spontaneous pneumothoraces in women of reproductive age. As mentioned in the previous section, CP is frequently associated with thoracic endometriosis syndrome (TES), but there might be other etiological mechanisms. The etiology of the remainder is obscure, but a number of theories have been proposed. During menstruation, the absence of the normal cervical mucus plug provides a connection between the ambient air and the abdominal cavity through the uterus and fallopian tubes, hence allowing the air to move across the diaphragm through right-sided diaphragmatic fenestrations into the pleural space. This may account for the fact that 90–95% of MSPs are right-sided. A second theory is that bronchospasm with air trapping and pneumothorax may occur due to high levels of prostaglandin F2 during menstruation. The third theory is that pleural blebs or bullae are more prone to rupture during menstruation because of hormonal changes. For cases that are not clearly associated with systemic

endometriosis, thoracoscopy during menstruation helps determine the etiology. Successful treatment necessitates a combined medical and surgical approach.

The medical therapy of TES primarily focuses on blocking the hormonal support from the ovaries that fosters the growth of the endometrial tissue. It consists of oral contraceptives, progestational agents, danazol, and gonadotropin-releasing hormone (GnRH) agonists. Surgical approaches include excision, local laser ablation, or pleurodesis. The recurrence rate with medical treatment exceeds 50% and subsequently requires surgical management. Conversely, there are reports of recurrence after surgical treatment of MSP that responded to subsequent hormonal therapy, so the current opinion is a sequential medical-surgical or surgical-medical approach.

Lymphangioleiomyomatosis

Lymphangioleiomyomatosis (LAM) was a disease of unknown origin in the mid-1990s, with no effective treatment. During the last decade, substantial progress has been made in understanding the natural history of the disease with support from NHLBI (National Heart, Lung, and Blood Institute). Once defined as a fatal disease of women of childbearing age, it is now known that LAM occurs in postmenopausal women as well.

LAM is a rare, slowly progressive, multisystem disorder of women characterized by proliferation of abnormal smooth muscle-like cells (LAM cells) associated with cystic lesions in the lungs and in the axial lymphatics (lymphangioleiomyomas) and angiomyolipomas. In the lungs, the cells are present along the pulmonary blood vessels, lymphatics, and bronchioles.

LAM occurs in association with tuberous sclerosis complex (TSC) which is an autosomal dominant syndrome characterized by multisystem hamartoma-like tumor growths or sporadically with no evidence of a genetic abnormality. Sporadic LAM is rare with a prevalence of 2–5/million. In both cases, LAM is caused by a mutation in one of the two tumor suppressor genes TSC1 or TSC2 that produce hamartin and tuberin, respectively.

LAM most frequently presents with progressive breathlessness, recurrent pneumothorax, hemoptysis, or chylothorax. Extrapulmonary manifestations include an intra-abdominal hemorrhage or an abdominal mass. Patients who present with dyspnea and hemoptysis generally have a more severe disease and higher mortality than those presenting with pneumothorax.

LAM histology score (LHS), quantitative CT scan, and pulmonary function testing including exercise testing assist in assessing severity of the disease. Airflow obstruction and decreased lung diffusion capacity are the most frequent lung function abnormalities in LAM. Exercise tests are frequently abnormal in LAM patients who have low-grade pulmonary hypertension which worsens on exercise. Currently the best methods to assess the severity and progression of lung disease are frequent monitoring of FEV1 and DLCO and the 6-min walk test.

The focus of current research is to identify possible treatment targets. Studies have shown a potential role for sirolimus (rapamycin), an immunosuppressant drug that inhibits the hyperphosphorylation of ribosomal protein S6 and p70S6 kinase activation which is unregulated in LAM cells in the absence of tuberin (protein product of TSC2 gene). Another potential drug doxycycline is an inhibitor of matrix metalloproteinase (MMP) and has shown improvement in FEV1 and DLCO when used in the treatment of patients with severe LAM. Antiestrogen therapy and oophorectomy, which were once considered conventional therapies, are no longer universally recommended.

Trophoblastic Embolization

Gestational trophoblastic disease (GTD) is a term used for a rare group of pregnancy-related disorders ranging from benign, partial, and complete hydatidiform mole, invasive and metastatic mole, and malignant choriocarcinoma.

Trophoblastic pulmonary embolization is a rare complication of GTD and can occur following abdominal hysterectomy for invasive mole as well as after molar evacuation. The clinical course is dramatic with acute onset dyspnea, tachypnea, bilateral pulmonary infiltrates, and low oxygen levels. Possible etiologies for pulmonary findings include pulmonary trophoblastic embolization, hypervolemia, aspiration, DIC, and hyperthyroidism.

Although not very common, pulmonary trophoblastic embolization should be considered part of the differential diagnosis if a patient has acute onset respiratory distress in the postoperative period.

Malignant choriocarcinoma is associated with metastases to the lungs, which is the most common site of metastases.

Ovarian Hyperstimulation Syndrome

Ovarian hyperstimulation syndrome (OHSS) is an exaggerated response to the use of exogenous gonadotropins to induce ovulation for in vitro fertilization.

The syndrome has a broad spectrum of clinical presentations ranging from abdominal pain from ovarian enlargement, ovarian cysts, ascites, dyspnea, intravascular volume depletion, and acute renal failure.

OHSS is characterized by increased capillary permeability resulting in fluid shift from the intravascular space to third space compartments. Various factors have been previously implicated in the process including estrogen, prolactin, histamine, and prostaglandins, but recently it is thought to be related to vasoactive mediators such as interleukins, tumor necrosis factor-α, endothelin-1, and vascular endothelial growth factor (VEGF).

Risk factors to developing OHSS include young age, low body weight, polycystic ovary syndrome (PCOS), use of higher dose of exogenous gonadotropins, and previous episodes of OHSS.

Pulmonary manifestations include dyspnea that may result from decreased diaphragmatic movement due to abdominal enlargement. Other rare complications include pleural effusion, pulmonary edema, atelectasis, and acute respiratory distress syndrome (ARDS). Pulmonary embolism is a life-threatening complication and may occur due to hypercoagulable state.

Treatment is supportive and directed at maintaining intravascular blood volume. OHSS is a self-limiting disease, so most patients respond to medical therapy, and surgical intervention is required only for complications such as ruptured ovarian cyst or ovarian torsion. Thoracocentesis may be needed for bilateral or persistent pleural effusions.

Polycystic Ovarian Syndrome and Obstructive Sleep Apnea

Polycystic ovarian syndrome (PCOS) is a common endocrine disorder affecting almost 5–8% of females and characterized by menstrual irregularity, hyperandrogenism, obesity, and polycystic ovaries.

Patients with PCOS are at increased risk of various metabolic derangements such as insulin resistance, glucose intolerance, dyslipidemia, and hypertension.

Obstructive sleep apnea (OSA) has been recently recognized as a significant contributing factor to the pathophysiology of metabolic derangements in PCOS. Recent studies have shown that there are two distinct clinical entities: PCOS with OSA and PCOS without OSA. PCOS women with OSA may be at much higher risk for the development of diabetes and cardiovascular disease than PCOS women without OSA. The risk for OSA in PCOS is 30-fold higher than in similarly obese women.

It is proposed that OSA possibly triggers one or more of three major hormonal responses that contribute to the metabolic abnormalities associated with it. They are:

(a) Activation of the hypothalamic-pituitary-adrenal (HPA) axis with increased cortisol production and secretion
(b) Increased catecholamine output from sympathetic nervous system stimulation
(c) Increased release of adipokines from the adipose tissue

Treatment of patients with OSA in PCOS with CPAP is important as it improves the metabolic profile.

Bibliography

1. Weinberger SE, Weiss ST, Cohen WR, Weiss JW, Johnson TS. Pregnancy and the lung. Am Rev Respir Dis. 1980;121(3):559–81.

2. Hegewald MJ, Crapo RO. Respiratory physiology in pregnancy. Clin Chest Med. 2011;32(1):1–13.
3. Bhatia P, Bhatia K. Pregnancy and the lungs. Postgrad Med J. 2000;76(901):683–9.
4. Dombrowski MP, Schatz M. Asthma in pregnancy. Clin Obstet Gynecol. 2010;53(2):301–10.
5. Stone S, Nelson-Piercy C. Respiratory disease in pregnancy. Obstet Gynaecol Reprod Med. 2009;20(1):14–21.
6. Mehta N, Chen K, Hardy E, Powrie R. Respiratory disease in pregnancy. Best Pract Res Clin Obstet Gynaecol. 2015;29(5):598–611.
7. Mehta N, Chen K, Powrie RO. Prescribing for the pregnant patient. Cleve Clin J Med. 2014;81(6):367–72.
8. National Heart, Lung, and Blood Institute, National Asthma Education and Prevention Program Asthma and Pregnancy Working Group. NAEPP expert panel report. Managing asthma during pregnancy: recommendations for pharmacologic treatment—2004 update. J Allergy Clin Immunol. 2005;115(1):34–46.
9. Tamasi L, Horvath I, Bohacs A, Muller V, Losonczy G, Schatz M. Asthma in pregnancy—immunological changes and clinical management. Respir Med. 2011;105(2):159–64.
10. Gilljam M, Antoniou M, Shin J, Dupuis A, Corey M, Tullis DE. Pregnancy in cystic fibrosis. Fetal and maternal outcome. Chest. 2000;118(1):85–91.
11. Gyi KM, Hodson ME, Yacoub MY. Pregnancy in cystic fibrosis lung transplant recipients: case series and review. J Cyst Fibros. 2006;5(3):171–5.
12. Coscia LA, Constantinescu S, Moritz MJ, Frank AM, Ramirez CB, Maley WR, et al. Report from the national transplantation pregnancy registry (NTPR): outcomes of pregnancy after transplantation. Clin Transpl. 2009:103–22.
13. Shaner J, Coscia LA, Constantinescu S, McGrory CH, Doria C, Moritz MJ, et al. Pregnancy after lung transplant. Prog Transplant. 2012;22(2):134–40.
14. Divithotawela C, Chambers D, Hopkins P. Pregnancy after lung transplant: case report. Breathe (Sheff). 2015;11(4):291–5.
15. Sciscione AC, Ivester T, Largoza M, Manley J, Shlossman P, Colmorgen GH. Acute pulmonary edema in pregnancy. Obstet Gynecol. 2003;101(3):511–15. doi: S0029784402027333.
16. Venkata C, Venkateshiah SB. Sleep-disordered breathing during pregnancy. J Am Board Fam Med. 2009;22(2):158–68.
17. Shechter A, Varin F, Boivin DB. Circadian variation of sleep during the follicular and luteal phases of the menstrual cycle. Sleep. 2010;33(5):647–56.
18. Vgontzas AN, Legro RS, Bixler EO, Grayev A, Kales A, Chrousos GP. Polycystic ovary syndrome is associated with obstructive sleep apnea and daytime sleepiness: role of insulin resistance. J Clin Endocrinol Metab. 2001;86(2):517–20.
19. Batman PA, Thomlinson J, Moore VC, Sykes R. Death due to air embolism during sexual intercourse in the puerperium. Postgrad Med J. 1998;74(876):612–3.
20. Dennis AT, Solnordal CB. Acute pulmonary oedema in pregnant women. Anaesthesia. 2012;67(6):646–59.
21. Esplin MS, Varner MW. Progression of pulmonary arteriovenous malformation during pregnancy: case report and review of the literature. Obstet Gynecol Surv. 1997;52(4):248–53.
22. Gossage JR, Kanj G. Pulmonary arteriovenous malformations. A state of the art review. Am J Respir Crit Care Med. 1998;158(2):643–61.
23. Alifano M, Trisolini R, Cancellieri A, Regnard JF. Thoracic endometriosis: current knowledge. Ann Thorac Surg. 2006;81(2):761–69. doi: S0003-4975(05)01322-6.
24. Azizad-Pinto P, Clarke D. Thoracic endometriosis syndrome: case report and review of the literature. Perm J. 2014;18(3):61–5.
25. Seckl MJ, Sebire NJ, Berkowitz RS. Gestational trophoblastic disease. Lancet. 2010;376(9742):717–29.

26. Garner EI, Chang-Lee WY, Lu KH, Goldstein DP, Berkowitz RS. Trophoblastic pulmonary embolization after hysterectomy for invasive complete mole. A case report. J Reprod Med. 1999;44(10):908–12.
27. Ngan HY, Seckl MJ, Berkowitz RS, Xiang Y, Golfier F, Sekharan PK, et al. Update on the diagnosis and management of gestational trophoblastic disease. Int J Gynaecol Obstet. 2015;131(Suppl 2):S123–6.
28. Bissler JJ, McCormack FX, Young LR, Elwing JM, Chuck G, Leonard JM, et al. Sirolimus for angiomyolipoma in tuberous sclerosis complex or lymphangioleiomyomatosis. N Engl J Med. 2008;358(2):140–51.
29. Iannuzzi MC, Rybicki BA, Teirstein AS. Sarcoidosis. N Engl J Med. 2007;357(21):2153–65.
30. Korom S, Canyurt H, Missbach A, Schneiter D, Kurrer MO, Haller U, et al. Catamenial pneumothorax revisited: clinical approach and systematic review of the literature. J Thorac Cardiovasc Surg. 2004;128(4):502–8.
31. Sahn SA, Heffner JE. Spontaneous pneumothorax. N Engl J Med. 2000;342(12):868–74.
32. Lara B, Fornet I, Goya M, López F, De Miguel JR, Molina M, et al. Contraception, pregnancy and rare respiratory diseases. Arch Bronconeumol. 2012;48(10):372–8.
33. Leung AN, Bull TM, Jaeschke R, Lockwood CJ, Boiselle PM, Hurwitz LM, et al. American Thoracic Society documents: an official American Thoracic Society/Society of Thoracic Radiology clinical practice guideline—evaluation of suspected pulmonary embolism in pregnancy. Radiology. 2012;262(2):635–46.
34. Nitsche K, Ehrmann DA. Obstructive sleep apnea and metabolic dysfunction in polycystic ovary syndrome. Best Pract Res Clin Endocrinol Metab. 2010;24(5):717–30.
35. Peavy H, Gail D, Kiley J, Shurin S. A national heart, lung, and blood institute history and perspective on lymphangioleiomyomatosis. Lymphat Res Biol. 2010;8(1):5–8.
36. Practice Committe of the American Society for Reproductive Medicine. Ovarian hyperstimulation syndrome. Fertil Steril. 2003;80(5):1309–14.

Disorders of Central Respiratory Control

Eliot S. Katz

Abbreviations

CM	Chiari malformation
CO_2	Carbon dioxide
CSF	Cerebrospinal fluid
H^+	Hydrogen ion concentration
NREM	Non-rapid eye movement
O_2	Oxygen
OSA	Obstructive sleep apnea
P_aCO_2	Arterial partial pressure of carbon dioxide
P_aO_2	Arterial partial pressure of oxygen
PCO_2	Partial pressure of carbon dioxide
REM	Rapid eye movement
S_aO_2	Arterial oxygen saturation

Anatomy

Neural networks contributing to respiratory control are located bilaterally in interconnected medullary aggregations known as the dorsal respiratory group (DRG) and the ventral respiratory group (VRG). The respiratory pattern generator consists

E.S. Katz, M.D.
Division of Respiratory Diseases, Department of Medicine, Children's Hospital, Harvard Medical School, Boston, MA, USA
e-mail: eliot.katz@childrens.harvard.edu

© Springer International Publishing AG 2018

A.C. Koumbourlis, M.A. Nevin (eds.), *Pulmonary Complications of Non-Pulmonary Pediatric Disorders*, Respiratory Medicine,
https://doi.org/10.1007/978-3-319-69620-1_9

of a small group of neurons in the VRG termed the pre-Botzinger complex. Neurons in the pre-Botzinger complex express opioid receptors (they slow the respiratory rate) and neurokinin-1 receptors (they increase the respiratory rate) and project to the DRG in the nucleus tractus solitarius (NTS). Though opioids depress breathing, an opioid antagonist has no effect on eupneic breathing. The NTS also receives afferent inputs that modulate respiration from the peripheral arterial chemoreceptors, skeletal muscle metaboreceptors, baroreceptors, upper airway, and lungs. The various respiratory rhythm inputs are integrated in the NTS and project temporally to the various respiratory motor neurons, including hypoglossal pre-activation (upper airway dilators), followed by the intercostal and the phrenic nerves (diaphragm). Another VRG medullary area, the Botzinger complex, plays an active role during expiration. The pons also contains an area important for the termination of inspiration termed the pontine respiratory group with interconnections to the cortex, hypothalamus, and NTS. Lesions of the pons may adversely prolong inspiration to the point of asphyxia. This abnormal breathing pattern is called "apneusis" ("lack of breath").

The ascending arousal system that maintains wakefulness also imparts an excitatory influence on ventilation, the "wakefulness stimulus," which is lost at sleep onset. Numerous neurotransmitters influence the central pattern generator including the excitatory glutamate (activating both N-methyl-d-aspartate (NMDA) and non-NMDA receptors) and the inhibitory GABA and glycine. Sleep onset is initiated by the ventrolateral preoptic area that projects via GABA inhibition to the ascending arousal system. The excitatory influence of wakefulness on ventilation is lost at sleep onset. Also, this pathway may contribute to the respiratory depression observed with GABA-mediated medications including benzodiazepines, barbiturates, and anesthetics. The lower respiratory motor neurons in the anterior horn of the spinal cord receive separate upper motor neuron input from the central respiratory pattern generating network in relation to involuntary, voluntary (e.g., vocalization), and reflex (e.g., hiccup) control of breathing.

Central chemoreceptors are located on the ventral surface of the medulla and respond primarily to the acidity of the cerebrospinal fluid. The cerebrospinal fluid is separated from the arterial blood by the blood-brain barrier that prevents H+ ion and bicarbonate from equilibrating, but CO_2 diffuses freely with a time constant of approximately 1 min. Ventilatory drive output is inversely related to pH. Cerebral blood flow appears to be an important determinant of central CO_2 sensitivity with increases in cerebral blood flow decreasing the hypercapnic ventilatory response. Conversely, pharmacologic agents that decrease cerebral blood flow increase the hypercapnic ventilatory drive. There are also hypoxia-sensitive neurons centrally distributed in the nucleus tractus solitarius, locus coeruleus, raphe nuclei, and retrotrapezoid nucleus that may contribute to increased ventilatory drive.

The peripheral chemoreceptors are located at the bifurcation of the common carotid artery and on the aortic arch. They are sensitive to the P_aCO_2, P_aO_2, and H^+ ion concentration (due to either a respiratory or metabolic acidosis) in the arterial blood and provide afferent information to the NTS with a short time constant (seconds), allowing breath-by-breath modulation of breathing. The peripheral chemore-

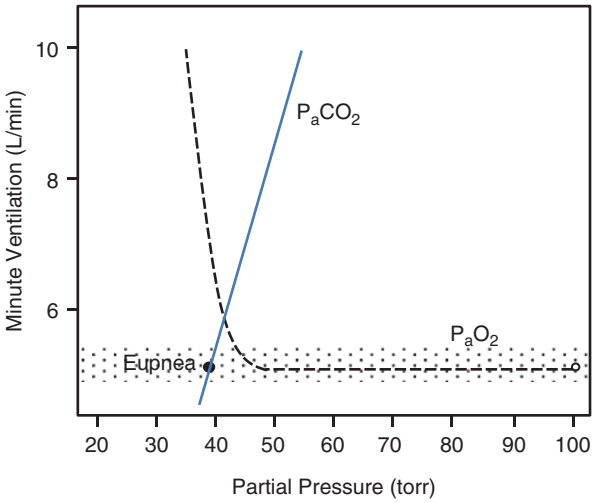

Fig. 1 The relationship between the arterial oxygen (P_aO_2) and carbon dioxide pressure (P_aCO_2) and the minute ventilation. Starting at a normal baseline, there is very little change in ventilation with decreases in the P_aO_2 until levels have decreased below 50 mmHg. By contrast, very small changes in the P_aCO_2 result in marked changes in ventilation

ceptors are sensitive to the P_aO_2, rather than the total oxygen content of the blood, and therefore do not detect anemia or methemoglobinemia. The response of the carotid bodies to hypoxia is under neural and neurochemical control (the latter is inhibited by alpha-2 agonists). The ventilatory response to P_aO_2 demonstrates minimal changes until the P_aO_2 is reduced to 50 mmHg but is more nearly linear with changes in the P_aCO_2 (Fig. 1). The carotid bodies are also responsive to hypotension, elevated body temperature, serum potassium, glucose, insulin, some cytokines, and drugs (such as nicotine, acetylcholine). Importantly, the sensitivity of the carotid bodies is modifiable in disease states such as intermittent hypoxia and heart failure and may contribute to the ventilatory control instability observed in these conditions.

The aforementioned central and peripheral chemoreceptors do not exert total control over the ventilatory control system. In fact many other receptors predominate under different circumstances. Skeletal muscle metaboreceptors respond to H^+, potassium, and osmolarity during exercise. Stretch receptors within the lung provide afferent feedback that may affect the respiratory rhythm or resistance. The Hering–Breuer inflation reflex utilizes these stretch receptors' input following lung inflation to reduce respiratory effort and as a bronchodilator. The tidal volumes necessary to initiate the reflex are generally above that seen in typical adults, but the reflex is active in infants. Increasingly negative pressure in the upper airway results in reflex activation of pharyngeal dilator muscles that are important in maintaining airway patency during sleep. Stimulation of juxta-pulmonary capillary receptors in the walls of the pulmonary capillaries in the setting of vascular congestion or pulmonary edema reflexively causes an increased respiratory rate. Arterial baroreceptors sense changes in blood pressure, with elevated pressures depressing ventilation.

Brainstem abnormalities including trauma, degenerative disease, infection, and malignancy may result in prolonged or more frequent respiratory pauses. Chiari

malformations (CM) are characterized by congenital or acquired herniations of the cerebellum or brainstem through the foramen magnum, potentially causing symptoms of brainstem compression. Leigh's syndrome is a mitochondrial disorder with brainstem involvement that results in prolonged central apneas and apneusis. Joubert syndrome is characterized by structural abnormalities of the hindbrain commonly associated with central apnea during sleep. Narcotic agents may produce central apnea in otherwise normal children or exacerbate apnea in children with underlying conditions such as OSA, congenital central hypoventilation syndrome, CM, or brain tumors. Opiates suppress the ventilatory response to hypoxia and hypercapnia. Opiates also increase the upper airway resistance, further reducing the minute ventilation. Opiates can produce or exacerbate sleep-disordered breathing including obstructive sleep apnea, central sleep apnea, and complex sleep apnea. Rapidly acting opiates such as fentanyl are particularly likely to produce hypoventilation and apnea, whereas the effects of slower-acting agents are attenuated by the resultant hypercapnia. Propofol has also been associated with temporary central apnea at a rate of 31 of 10,000 administrations.

Physiology

During wakefulness and non-rapid eye movement (NREM) sleep, the breathing pattern is typically a regularly alternating inspiration and expiration without pauses. The respiratory rate and tidal volume are adjusted by a feedback control system that aims to maintain the carbon dioxide, oxygen, and acid-base balance in an acceptable range. The primary determinant regulating breathing is the P_aCO_2 and to a much lesser extent the P_aO_2. The influence of CO_2 on ventilation (P_aCO_2 ventilatory response curve) is essentially linear over the range of 20–80 mmHg (see Fig. 1). The slope of an individual's CO_2 ventilatory response curve has a trait variability within the population and changes in relation to state, circadian time, and medications. Increased peripheral chemoreceptor drive steepens the slope of the central chemoreceptor gain. Acidosis shifts the curve to the left and metabolic alkalosis to the right without changing the slope of the curve (see Fig. 2c). At very high levels of CO_2 (>100 mmHg), ventilation may become depressed (CO_2 narcosis). Conversely, changes in ventilation have a hyperbolic relationship to the P_aCO_2 (the metabolic hyperbola) (see Fig. 2a). The intersection of the metabolic hyperbola and the P_aCO_2 ventilatory response curve is the steady-state P_aCO_2. Hypoxemia causes the P_aCO_2 ventilatory response curve to shift to the left with a steeper slope indicating increased ventilatory drive, likely related to enhanced peripheral chemoreceptor input (see Fig. 2b). Other causes of hyperventilation include metabolic acidosis, elevated intracranial pressure, anxiety, and drug effects. The principal determinant of the metabolic hyperbola is the metabolic rate (CO_2 production). During a complete apnea, the P_aCO_2 increases at a rate of approximately 2–6 mmHg/min.

The feedback mechanism governing the normal respiratory rhythmicity is a complex interaction between mechanoreceptors and chemoreceptors with the brainstem

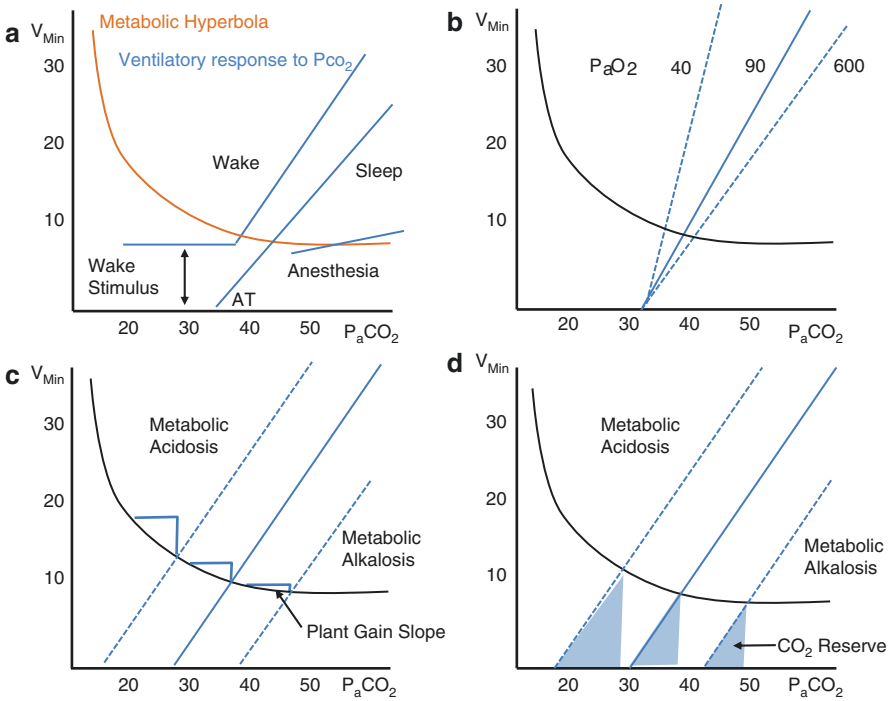

Fig. 2 (**a**) Ventilatory response to P_aCO_2 during wakefulness, sleep, and anesthesia. The ventilatory response to P_aCO_2 represents the level of ventilation induced by a given P_aCO_2. The metabolic hyperbola represents the resultant P_aCO_2 for a given level of ventilation. The intersection of these lines is the eupneic breathing level and there emerges an apneic threshold level of P_aCO_2 during sleep. (**b**) Ventilatory response to P_aCO_2 and oxygen dependence of P_aCO_2 versus ventilation. (**c**) Ventilatory response to P_aCO_2 shifts in response to acidosis or alkalosis. At higher P_aCO_2, the set point is on the flat portion of the metabolic hyperbola, and therefore the plant gain is high (ΔP_aCO_2/Δventilation). The reverse is true for a low P_aCO_2 set point. (**d**) Influence of acid-base status and P_aO_2 on apnea threshold and the CO_2 reserve

central respiratory generator networks. The primary consideration is the reciprocal relationship between P_aCO_2 and ventilation that can be modeled in engineering terms as a "loop gain," a metric of the overall chemosensitivity of the ventilator control feedback system (see Fig. 3). The loop gain reflects the ratio between the ventilatory response and a ventilatory perturbation. If the loop gain ratio is >1, respiratory disturbances lead to greater reciprocal disturbances giving rise to an unstable system, characterized by alternating hyper- and hypoventilation. By contrast, systems with a loop gain <1 lead to a stable steady state. Conceptually, the respiratory loop gain is comprised of three components:

1. *Controller gain*: the output of the respiratory pattern generator in response to a given input of P_aCO_2 and P_aO_2, a measure of chemoreceptor activity.
2. *Plant gain*: the magnitude of CO_2 changes in response to a given level of ventilatory drive output. The determinants of plant gain include any mechanisms that

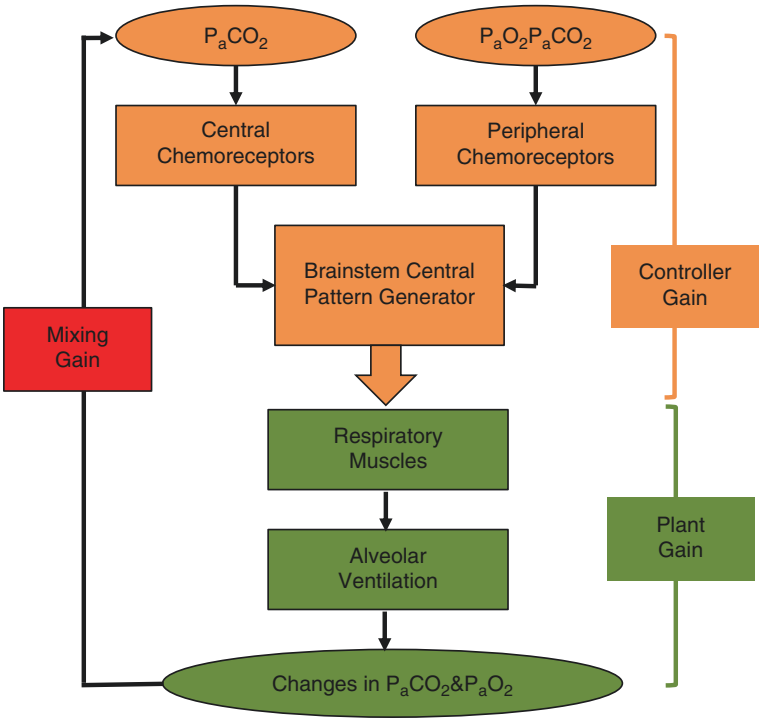

Fig. 3 Schematic diagram of ventilator control system

influence the CO_2 stores including respiratory muscle responsiveness, dead space ventilation, ventilation/perfusion matching, lung volumes, hemoglobin, tissue spaces, and cardiac output.

3. *Mixing gain*: represents the circulatory delay between the lungs and the peripheral chemoreceptors, the thoracic blood volume, and the brain extracellular fluid volume that contributes to ventilatory overshooting and undershooting. In addition to the aforementioned chemical control of breathing mechanisms, there are also mechanoreceptor inputs that serve to augment or decrease the ventilatory drive.

Homeostatic oxygen sensing is primarily performed by the carotid body and to a lesser extent the aortic bodies. Low oxygen levels may also depress brainstem functioning directly. The contribution of oxygen chemoreceptor input to eupneic ventilation can be estimated by the decrement in ventilation in response to a single breath of 100% oxygen (the Dejour test). The response to a hyperoxic challenge results in a ventilation decrease. The decrease varies according to age. It is highest in preterm infants (40%). It is significantly less in term infants (14%) and even lower among adults (10%), respectively. Thus, the baseline oxygen tension has an important contribution to respiratory drive, especially in premature infants. Under normocapnic conditions, a decrease in the arterial oxygen pressure (P_aO_2) between 100 and

50 torr, there is little increase in the minute ventilation. This is not surprising as the hemoglobin disassociation curve predicts little drop in the oxygen saturation over this interval. As the P_aO_2 is lowered below 50 torr, there are dramatic increases in ventilation (see Fig. 1), and the hypercapnic ventilatory response slope becomes steeper (see Fig. 2b). The increase in ventilation observed with hypoxemia is counterbalanced by the resultant decrease in CO_2 that slows down the ventilation. Thus, asphyxia results in an augmented chemoreceptor response. The output of the respiratory pattern generator is also adjusted upward temporarily following the conclusion of an episode of hypoxemia. This is termed "long-term facilitation" and results in an increase stimulation of upper airway muscles and the diaphragm.

Sleep

During non-rapid eye movement (NREM) sleep, there is a reduction in the suprapontine behavioral inputs to the respiratory pattern generator leaving chemical control of breathing as the predominant determinant of ventilation. Thus, at sleep onset, there is a reduction in the hypoglossal and intercostal motor neuron activity, resulting in an increased upper airway resistance and decreased respiratory effort. In addition, sleep is associated with a decreased ventilatory responsiveness to CO_2 and O_2 and a decreased metabolic rate, leading to a 10–15% overall reduction in the minute ventilation. Concomitantly, there is a reduction in lung volume during sleep that will accentuate gas exchange variability, especially during apneas. On balance, the arterial CO_2 pressure increases 3–7 torr during sleep, and the arterial oxygen pressure decreases by 5–10 torr.

A major factor predisposing toward ventilatory instability during NREM sleep is the emergence of an "apneic threshold" 1–5 mmHg below the eupneic P_aCO_2 (see Fig. 2a). During apnea, there is an accumulation of CO_2 and a decline in oxygenation, contributing to a subsequent chemoreceptor-induced ventilatory overshoot. The closer the apneic threshold is to the eupneic P_aCO_2 (the "CO_2 reserve"), the more unstable the system. The CO_2 reserve is inversely related to the plant gain (see Fig. 2c) and to the slope of the ventilatory response to P_aCO_2 below eupnea. In infants, the apneic threshold during sleep is 1–3 torr below the sleep eupneic level, compared to 2–5 torr in adults. Following a hypocapnia-induced apnea, an increase in P_aCO_2 of 1–4 mmHg above the apneic threshold is required to reinitiate breathing. However, the apneic threshold during NREM sleep varies in relation to the controller and plant gain. Thus, increasing respiratory drive resulting in a lower baseline P_aCO_2 does not necessarily predispose toward apnea (see Fig. 2d). At higher levels of respiratory drive, the feedback loop is operating at a steeper portion of the metabolic hyperbola (ventilation vs. P_aCO_2 curve). Thus, at higher levels of respiratory drive (lower P_aCO_2), the change in ventilation required to alter the P_aCO_2 increases (i.e., the plant gain is reduced) (see Fig. 2c). A reduction in the plant gain stabilizes the breathing pattern by requiring larger changes in ventilation to further reduce the P_aCO_2. In addition, when the P_aCO_2/ventilation slope remains the same

as it does with some acid-base-induced ventilatory perturbations, the CO_2 reserve increases with higher levels of respiratory drive (see Fig. 2d). Thus, in the setting of metabolic acidosis, the apneic threshold is less likely to be reached, and the opposite is true for metabolic alkalosis (see Fig. 2d). With hypoxemia however, an increase in respiratory drive (decrease in P_aCO_2) is accompanied by an increase in the slope of the $PaCO_2$/ventilation curve below eupnea, thereby reducing the CO_2 reserve (see Fig. 2b). Note that with hypoxemia, the slope of the P_aCO_2/ventilation curve is also increased above eupnea, which will predispose toward increased ventilatory overshoots in response to hypoventilation-induced increases in the P_aCO_2. Further, sustained hypoventilation elevating the P_aCO_2 does not necessarily reduce the likelihood of intermittent reductions in the P_aCO_2 below the apneic threshold. Metabolic acidosis or alkalosis often leaves the P_aCO_2/ventilation relationship unchanged, and therefore the CO_2 reserve simply varies inversely with the plant gain (see Fig. 2d). By contrast, hypoxemia and heart failure increase the slope of the $PaCO_2$/ventilation curve and therefore decrease the CO_2 reserve. Note that hypoxemia has two disparate influences on ventilator stability during sleep. The resultant lower CO_2 places the set point on the steeper portion of the metabolic hyperbola, thus decreasing plant gain which stabilizes breathing. At the same time, hypoxemia increases the hypercapnic ventilation drive below eupnea resulting in the narrower CO_2 reserve, making apnea more likely. The latter mechanism is predominant, and ventilatory instability is frequently observed during sleep, especially at high altitude.

In NREM sleep, the breathing is principally regulated by the P_aCO_2 resulting in regular breathing with few pauses. By contrast, in rapid eye movement (REM) sleep, breathing is influenced by central REM processes rather than chemical drive, resulting in a highly irregular rhythm with frequent respiratory pauses. In REM sleep, there is a decrease in slope of the P_aCO_2/ventilation curve and therefore an increase in the CO_2 reserve. Phasic REM, associated with rapid eye movements, results in supra-pontine inputs to the central respiratory generator resulting in abrupt decreases in motor output to the upper airway and decreased minute ventilation. The decrease in the CO_2 ventilatory response and increase in the CO_2 reserve during REM sleep make periodic breathing less likely at altitude or in the setting of heart failure.

Arousal refers to a paroxysmal increase of electrocortical activity during sleep that can be a constitutive part of the sleep architecture or the result from a sleep-related breathing disorder or body movement. Arousals are often accompanied by an abrupt increase in heart rate and minute ventilation, resulting in sleep fragmentation. During arousal there is a shift toward the wakeful level of ventilatory responsiveness to CO_2, and the wakefulness stimulus to breathe returns, thus increasing minute ventilation. Importantly, the ventilatory response to arousal far exceeds the required increase in ventilation necessary to reverse a hypopnea or apnea, and thus it results in a ventilatory overshoot. This excessive increase in ventilation results in relative hypocapnia that induces a reduction in central respiratory drive including upper airway motor tone, facilitating obstructive cycling. Thus, both the arousal threshold and the ventilatory response to arousal are measurable phenotypical

determinants of ventilatory control stability. Patients with low arousal thresholds or high ventilator responses to arousal may be predisposed toward obstructive cycling during sleep.

Children with obstructive sleep-disordered breathing have smaller and more collapsible upper airways in comparison to control subjects. Nevertheless, even children with severe OSA are often able to sustain stable breathing most of NREM sleep, indicating successful neuromuscular compensation. Obstructive events are more prevalent during REM sleep in children. The etiology of REM state vulnerability includes generalized muscle atonia, specific paroxysmal REM inhibitory processes affecting the hypoglossal nucleus, and diminished chemoreceptor/mechanoreceptor responsiveness. In NREM sleep, both afferent activities (chemo- and mechanoreceptors) are more robust. Oscillations in P_aCO_2 affect the upper airway tone and therefore the expression of OSA. Arousal-driven ventilatory overshoots appear to be a major contributor to hypocapnic-induced airway collapse. The primary determinants of upper airway motor tone are chemoreceptors (P_aCO_2), mechanoreceptors (airway negative pressure), and state-specific respiratory drive. Thus, ventilatory control instability is a major contributor to the pattern of obstructive sleep-disordered breathing.

Acid-Base Alterations

Cellular function is critically dependent on the concentration of H^+ ion ($[H^+]$) for the normal activity of intracellular proteins. The primary determinant of $[H^+]$ is the ratio of the concentrations of bicarbonate (mostly regulated by the kidney) and carbon dioxide (modulated by the lungs). The inverse logarithm of $[H^+]$ is termed the pH. The interrelationship between CO_2 and bicarbonate is governed by the following reaction:

$$\text{Dissolved}\,CO_2 + H_2O \overset{\text{Carbonic anhydrase}}{\rightleftarrows} H_2CO_3 \rightleftarrows H^+ + HCO3^-$$

Carbonic anhydrase is a group of enzymes that catalyze the rapid bidirectional conversion of carbon dioxide and water to bicarbonate and H^+ ions. Carbonic anhydrase augments this conversion to the extent that diffusion of the substrates is the rate-limiting step, thus optimizing the maintenance of acid-base balance. Besides bicarbonate, the primary buffers in the blood include phosphate and proteins. Note that CO_2 has minimal solubility in the gas phase (<10%). Thus, the majority is bound to hemoglobin (20%) or is converted by this reaction to carbonic acid (70%) during its transit to the lungs, mostly in red blood cells. In the lungs, the reverse reaction takes place; carbonic anhydrase catalyzes the conversion of carbonic acid to CO_2 which then diffuses into the alveoli and is expelled. Thus, the volatile nature of the left side of this equation accounts for the importance of the bicarbonate buffering

system. In the periphery, relatively deoxygenated hemoglobin has an increased affinity for H^+, and the reverse is true after hemoglobin is fully oxygenated in the lungs. This mechanism facilitates the movement of CO_2 into the alveolar space without adversely affecting the acid-base balance of the serum.

Cellular metabolism results in the production of acids that must be neutralized to maintain acid-base balance homeostasis. These acids consist of the volatile CO_2 that is excreted by the lungs and nonvolatile acids such as sulfuric and phosphoric acids that are excreted by the kidneys. Note that lactic acid produced during exercise has properties of both volatile and nonvolatile acids. The volatile CO_2 is simply excreted by the respiratory system according to the principles of ventilatory control and buffering discussed above. The kidney regulation of nonvolatile acid excretion and the regulation of serum bicarbonate levels are beyond the scope of this chapter. The renal functions relevant to respiratory physiology are (a) to resorb or excrete filtered bicarbonate; (b) to regenerate buffers consumed by the products of metabolism, including phosphate; and (c) to excrete acids.

The blood-brain barrier is impermeable to H^+ and bicarbonate. In addition, the CSF contains minimal amounts of proteins and therefore is nearly entirely dependent on bicarbonate for buffering. Consequently, changes in PCO_2 in the CSF result in a greater change in H^+ ion compared to the blood that has considerable additional buffering from serum proteins and hemoglobin. CSF has a slightly lower pH and 4–10 mmHg increase in PCO_2 compared to arterial blood, in keeping with the changes seen in mixed venous blood. Changes in PCO_2 are transmitted to the CSF with a time constant of about 1 min.

Perturbations in the levels of the P_aCO_2, H^+, or bicarbonate concentration result in acid-base imbalances as follows (see Table 1):

1. *Respiratory acidosis*: Hypoventilation-induced increased P_aCO_2 and decreased pH. Acute hypercapnia results in an elevation in red blood cell CO_2 that is converted to H^+ and bicarbonate. The bicarbonate is transported into the serum in exchange for chloride, resulting in a rapid elevation in serum bicarbonate. If the hypercapnia persists, over the next few days, the kidney completes the compensation process by increasing bicarbonate reabsorption and enhancing excretion of H^+.
2. *Respiratory alkalosis*: Hyperventilation-induced decreased P_aCO_2 and increased pH. The reverse process involved with acute hypercapnia ensues.
3. *Metabolic acidosis*: Decreased bicarbonate and decreased pH. Metabolic acidosis acutely stimulates an increase in alveolar ventilation resulting in a decrease in the P_aCO_2 by 1.2 mmHg for every 1 mEq/L decrease in serum bicarbonate. Subsequently, the kidney increases bicarbonate reabsorption and increases acid excretion. At the CSF level, when the P_aCO_2 falls, CO_2 diffuses out of the CSF resulting in relative CSF alkalosis that slows breathing toward eupnea.
4. *Metabolic alkalosis*: Increased bicarbonate and increased pH. Metabolic alkalosis acutely results in an increase in the P_aCO_2 by 0.7 mmHg for every 1 mEq/L increase in the serum bicarbonate. Ventilation is suppressed by the alkalosis,

Table 1 Etiology of metabolic disturbances

Respiratory acidosis	Respiratory alkalosis	Metabolic acidosis	Metabolic alkalosis
Impairment of central respiratory pattern generator or chemoreceptors		• Drug overdose (salicylates, alcohol) • Renal tubular acidosis • Gastrointestinal causes – Small bowel/ pancreatic fistula – Ketogenic diet – Diarrhea • Hypoxia • Extreme exercise • Diabetic ketoacidosis • Shock • Anemia	• Vomiting • Diuretics • Steroid therapy • Cushing syndrome • Hyperaldosteronism • Bartter syndrome • Renin-secreting tumor
• Intracranial pathology (tumors, infections, inflammation, injuries) • Medications (narcotics, anesthetics, sedatives) • Oxygen therapy • Congenital central hypoventilation syndrome	• Intracranial pathology (tumors, infections, inflammation, injuries) • Medications (salicylate overdose, progesterone) • Hypoxemia – High altitude – Asthma – Pneumonia – Pulmonary embolism • Anxiety		
Neuromuscular weakness • Muscular dystrophies, • Spinal muscular atrophy • Primary myopathies • CNS infections • Guillain-Barre syndrome • Congenital diaphragmatic hernia • Medications (muscle relaxants)			
Lung disease • Bronchopulmonary dysplasia • Bronchiectasis • Infections			
• Chest wall deformities • Obesity			
Upper airway obstruction • Subglottic stenosis • Severe obstructive sleep apnea			

further increasing the P_aCO_2. Subsequently, the kidney increases bicarbonate excretion and decreases H^+ excretion.

Thus, the lungs facilitate the retention or excretion of metabolically produced CO_2 to provide rapid compensation for metabolic acid-base derangements. Renal compensation for respiratory or metabolic acid-base disorders typically requires 3–6 days. There are many other factors that affect ventilation including cerebral blood flow, baroreceptor input, and changes in metabolism.

Influence of Exercise

Exercise is accompanied by an abrupt increase in oxygen utilization and CO_2 production, yet there is a minimal change in the P_aCO_2, P_aO_2, or H^+ ion until very strenuous activity levels above 60% of maximum. Below the anaerobic threshold, a steady-state matching of CO_2 production and ventilation is typically reached within 3 min. Homeostasis in mild to moderate exercise may be largely independent of chemoreceptors. The non-chemoreceptor mechanisms that adjust ventilation to match the metabolic rate have not been fully elucidated but seem to include hypothalamic feed-forward input, humoral factors, skeletal muscle metaboreceptors, and neural feedback from proprio-receptors in the joint, muscles, and lungs. However, additional supra-pontine structures may also contribute through learned behavior. Other potentially important determinants of ventilation include body temperature, cerebral blood flow, and vascular volumes. Minute ventilation increases linearly with exercise until about 60–70% of an individual's maximal work level, when the production of lactic acid results in markedly increased minute ventilation relative to oxygen consumption, leading to a precipitous drop in the P_aCO_2. As a result, during heavy exercise, the P_aCO_2 decreases by 10–15 torr, and the alveolar PO_2 increases by 10–20 torr above eupneic values.

Altitude

The decrease in barometric pressure that occurs with the ascent to high altitude results in a commensurate drop in the alveolar and arterial oxygen tension. The initial response to this hypoxemia is an increase in ventilation, lasting a few minutes, followed by a decline to a new baseline that remains slightly above the eupneic minute ventilation. During the next month of altitude exposure, ventilation gradually increases further resulting in a decrease in the P_aCO_2 that may intermittently cross the apneic threshold during sleep. Hypoxemia also increases the hypercapnic ventilatory response (increases controller gain), thus narrowing the CO_2 reserve during sleep, making apnea and periodic breathing more likely. Cycling associated with high altitude has a period of 12–34 s. Overtime, this respiratory alkalosis lowers cerebrospinal PCO_2 (raises pH), thus lowering ventilation until a new set point is reached balancing the hypoxemia and hypocapnia. The hypoxic ventilatory drive has a trait variability that accounts for the considerable difference in the effects of altitude between individuals.

Bibliography

1. Ainslie PN, Lucas SJE, Burgess KR. Breathing and sleep at high altitude. Respir Physiol Neurobiol. 2013;188:233–56.
2. Forster HV, Haouzi P, Dempsey JA. Control of breathing during exercise. Compr Physiol. 2012;2:743–77.
3. Dempsey JA, Smith CA, Przybylowski T, Chenuel B, Xie A, Nakayama H, Skatrud JB. The ventilator responsiveness to CO_2 below eupnea as a determinant of ventilator stability during sleep. J Physiol. 2004;560(1):1–11.
4. Lindinger MI, Heigenhauser GJF. Effects of gas exchange on acid-base balance. Compr Physiol. 2012;2:2203–54.

Pulmonary Complications of Mental Health Problems

Chelsea Manchester, Adrynne Frazier, Caitlin Condit, and Daniel Lewin

Introduction

The prevalence of psychiatric disorders, including anxiety, depression, panic, and adjustment disorder, is elevated among patients with pulmonary conditions. Maladaptive coping, stress, and poor affect regulation associated with psychiatric disorders can have a direct impact on a variety of bodily systems and manifest as physical symptoms. These psychological stressors often mimic pulmonary disorders or further complicate and exacerbate existing conditions. This is of particular importance to providers, as stress can often lead to inadequate coping, or the inability to face responsibilities, problems, or difficulties in an adequate manner. For example, psychosocial stress alters susceptibility to infections and systemic illness, reducing the body's ability to fight off colds and other respiratory infections. Likewise, poorly regulated emotional states, such as sadness, depression, rumination, and fears can contribute to, or manifest as, respiratory symptoms in individuals diagnosed with a variety of pulmonary issues. Examples of pulmonary exacerbation include rapid shallow breaths, dyspnea (labored breathing), psychogenic cough, pain, and tightness in the chest. The intricate links between mental and physical health are increasingly recognized as important targets of intervention to improve quality of life and long-term treatment outcomes.

C. Manchester, M.A. • A. Frazier, M.A. • D. Lewin, Ph.D. (✉)
Division of Pulmonary and Sleep Medicine, Children's National Health System, George Washington University, School of Medicine and Health Sciences, Washington, DC, USA
e-mail: cmanchester@gwmail.gwu.edu; adrynne@vt.edu; dlewin@childrensnational.org

C. Condit, M.A.
Department of Psychology, George Washington University School of Medicine and Health Sciences, Washington, DC, USA
e-mail: ccondits@gmail.com

© Springer International Publishing AG 2018

A.C. Koumbourlis, M.A. Nevin (eds.), *Pulmonary Complications of Non-Pulmonary Pediatric Disorders*, Respiratory Medicine,
https://doi.org/10.1007/978-3-319-69620-1_10

In this chapter, we will provide a model of the psychophysiological underpinnings of the relationship between psychiatric disorders, stress, and pulmonary symptoms and exacerbations. We provide information regarding the contribution of emotions and stress to respiratory symptoms such as psychogenic cough, dyspnea, wheezing (especially in vocal cord dysfunction), and asthma. Further, we will discuss complications that arise in pulmonary function due to psychiatric disorders (e.g., maladaptive stress response, somatization of affect, and treatment nonadherence), provide practical tools for non-mental health practitioners to identify psychological conditions (e.g., mood disturbance, anxiety, depression, poor coping, and stress), as well as provide recommendations about when to refer patients for a more comprehensive psychiatric assessment. Lastly, we review interventions that providers can utilize to address mood disturbance, somatic symptoms arising from psychiatric disorders, poor coping skills, maladaptive stress responses, and somaticized tension.

Stress and Emotion Mechanisms

The manifestation of stress and emotion dysregulation as physical symptoms is called somatization, which is defined as functional physical symptoms (e.g., cough, wheezing, dyspnea, pain) that have no detectable physiological cause. However, when chronic, these functional pulmonary symptoms may lead to decrements in pulmonary function by causing frequent and increasingly severe exacerbations. This in turn results in an increasing number of (often invasive) evaluation procedures (e.g., bronchoscopy and/or computed tomography) and treatments (e.g., systemic steroids) that may have long-term negative iatrogenic effects. It is also likely that, in at least some cases, there is a vicious cycle between disease processes, disease symptoms, and functional symptoms leading to more negative outcomes.

Several models explain links between stress, emotion dysregulation, and physical symptoms. Depression and anxiety are not only common sequelae of exposure to stressors but they can also have direct negative consequences on physical function and coping, thereby creating a vicious cycle. Negative psychological states involve cognitive appraisal of threat, anticipation, and prediction of negative outcomes (e.g., hopelessness, rumination, and worry) that through avoidance and "self-fulfilling prophecies" are often reinforced when predictions come true. These cognitive phenomena typically arise from perceptions (i.e., sight, sound, touch) that have concrete physiological and direct links to the sympathetic nervous system. A complex system of neurotransmitters and neuro-hormonal responses, most prominently the monoamine systems (norepinephrine, dopamine, serotonin), are involved in specialized centers of the brain, the gut, and other diverse physical systems that are involved in sympathetic nervous system response. What we call emotion and the feeling of stress are the interaction between physical sensation and cognition. Chronic and acute activation of this system can lead to pulmonary symptoms and a potent feedback loop between pulmonary symptoms, disease pathogenesis, and further emotional distress.

Asthma

Complex models have emerged which describe asthma as an organic disease with a high vulnerability to psychological influences. Not only does psychosocial stress alter susceptibility to infections and systemic illness, but a number of molecular biological studies have also demonstrated that stress can disrupt physiological pathways, including autonomic control of airways, the endocrine system, and immune functions. Similarly, research shows that stress may actually enhance airway inflammation in individuals diagnosed with asthma by modulating immune cell function through neural and hormonal pathways. These disturbances, in turn, can result in the onset of an exacerbation of many pulmonary issues like asthma.

Psychological stress is also known to directly impact respiration, altering the magnitude of the airway inflammatory response that irritants, allergens, and infections cause in individuals diagnosed with asthma. Stressors, anxiety, and fear responses can lead to short, shallow breathing which often has direct effects on an individual's upper airway reactivity. Psychological stress can also amplify the immune response to asthma triggers via biological pathways including the HPA axis, the SAM axis, and the SNS and PNS arms of the autonomic nervous system. Likewise, the gut is particularly sensitive to stress, and chronic stress may increase risk of reflux, an important comorbidity and common trigger of asthma.

In addition to stress, asthma may also be affected by other physiological manifestations of emotion dysregulation. For instance, it has been suggested that emotional states, such as sadness and depression, are linked to an aggravation of symptoms in individuals diagnosed with asthma. More specifically, there is speculation that depression could have a direct effect on airway instability and asthma exacerbation by influencing vagal activity within the body. Researchers have theorized that the influence of depression could be mediated by pathway defects in the function of the autonomic nervous system. On a macro level, depression and anxiety also often lead to inactivity, which can result in poor conditioning. Such deconditioning has been known to increase inflammatory processes and decrements in immune function. Additionally, exposure to stress and negative emotions like sadness can activate the release of chemicals, such as histamines and leukotrienes, that can trigger airway narrowing and provoke asthma exacerbations.

Dyspnea

Shortness of breath, or dyspnea, is a common manifestation of various unrelated respiratory illnesses in children, and its presence does not necessarily correlate with the severity of the disease. For example, dyspnea can result from temporary and mild exacerbants such as exercise or be the manifestation of a serious chronic physiological illness. While there can be many diverse sources for dyspnea, mood dysregulation and stress should not be discounted. Though it is important to consider, it

can be challenging to unravel whether stress and strong emotion are the antecedent of dyspnea or worsening symptoms already present.

Symptoms of stress and anxiety often involve changes in breathing patterns, such as hyper- and hypoventilation and perceived tightening of upper airway musculature. These physical symptoms can increase anxiety that involve cognitive and emotional activation and can lead to increased symptoms. The most severe version of this cycle of psychophysiological activation is a panic attack that involves hyperventilation, increased cardiac rate, impaired cognitive function, perceived loss of control, hopelessness, dread, and fear of catastrophic physical events such as cardiac arrest.

Dyspnea caused by anxiety is often improved by exertion and worsened by rest. One of the best clinical tools that can differentiate between true and false shortness of breath is exertion. Simply asking the patient who suffers from dyspnea if the shortness of breath is made worse or better by activity can clarify the diagnosis. Additionally, if the patient is able to identify their anxiety or stress, it is helpful to ascertain if the anxiety precedes or follows the dyspnea. This would be extremely helpful in establishing whether the mood disorders or stress are the cause or the exacerbation of another illness.

Even when shortness of breath is caused by a health condition, it can still lead to anxiety. In attempting to treat physical symptoms, sadness, anxiety, and hopelessness arising from medical conditions are often overlooked. It can be difficult to diagnose mood disorders in the medically ill when there is significant fatigue or iatrogenic effects of pharmacotherapy, but diagnosis and treatment are essential in order to provide comprehensive management of symptoms. In the event that stress or a mood disorder is exacerbating another medical condition, patients cannot always differentiate between their medical symptoms and mental health symptoms. Targeted interventions can disentangle these complex psychophysiological interactions.

Vocal Cord Dysfunction

Vocal cord dysfunction (VCD) involves constriction in the laryngopharyngeal region that produces partial airway obstruction due to the paradoxical closing of the vocal cords. VCD creates the feeling of difficulty (or inability) to breathe both on inspiration and on exhalation. The symptoms range from mild dyspnea to acute respiratory distress. Patients may complain of an acute and sudden onset of difficulty in breathing; tightness in the throat; noisy, wheezy, or stridorous breathing; difficulty swallowing; and the sensation of choking. They often have difficulty talking and the voice becomes muffled. These symptoms can amplify fear and worry for those who are unsure what is occurring, leading to an increased sympathetic response (e.g., increased respiratory rate, somaticized tension, noradrenergic surges) and worsening of symptoms.

The etiology of VCD is unclear but historically, it has been thought to be psychogenic in origin. However, it is often associated with a variety of other conditions such as upper respiratory infections, exercise, and gastroesophageal reflux or asthma that usually serve more as a trigger rather than as the cause of VCD. In general, physicians have accepted that vocal cord dysfunction can have both psychological and physiological causes. Although a specific psychological cause has not been definitively proven, at least 50% of patients with vocal cord dysfunction have increased rates of mental health problems including anxiety, posttraumatic stress disorder, panic attack, and depression. Thus, it is important to consider the possibility of vocal cord dysfunction asthma, especially when the patient presents with atypical symptoms and/or fails to respond to what appears to be appropriate therapy for asthma. VCD is much more common in females and adolescents, but it has been reported in children as young as 7 years old. In many patients, the episodes of VCD occur during increases in psychosocial stressors. This may be caused by stress, anxiety, and mood disturbance manifesting as somaticized tension. There may also be secondary gain factors. Specifically, stress associated with attending school, school avoidance, and social anxiety can result in somatization, hyper focus on symptoms, and subsequent worsening of symptoms that lead to withdrawal from environments that increase stress. Although psychological factors can be the cause of vocal cord dysfunction, their symptoms can cause greater anxiety or mood challenges, leading to even more severe vocal cord dysfunction in patients with or without a psychiatric etiology. This further highlights the importance of the assessment of stress and mood dysregulation in patients with vocal cord dysfunction.

Due to its similar presentation with a wheezing sound and dyspnea, patients with VCD are often misdiagnosed as having asthma. What can make diagnosis more challenging is that some patients with vocal cord dysfunction also have asthma, and most commonly, an asthma exacerbation can trigger an episode of VCD, but VCD can also progress into an asthma attack. When VCD has not been evaluated, patients often end up in the emergency room where they can be misdiagnosed as having severe refractory asthma or even anaphylaxis due to the fact that their symptoms persist or even worsen despite aggressive treatment with high-dose continuous bronchodilators, systemic steroids, intravenous magnesium sulfate, etc. It is not uncommon for patients to be emergently intubated on the assumption of impending respiratory failure. Although the differentiation between VCD and asthma exacerbation is not always easy, there are some key factors that should be considered. First, most asthma exacerbations evolve over a period of hours or even days, whereas VCD can occur virtually instantaneously. Second, most asthma exacerbations tend to show some (at least transient) response to treatment with bronchodilators, whereas patients with VCD do not. In fact, they often feel worse due to sympathetic nervous system responses such as tachycardia or tremors that are exacerbated by the high-dose β2-agonists. Third, patients in status asthmaticus who develop inspiratory and expiratory wheezing are usually hypoxemic and hypercapnic, whereas patients with VCD are usually normoxemic and actually hypocapnic

due to the hyperventilation. Although, the normal oxyhemoglobin saturation on room air could be pathognomonic, it is often missed because the patients are given 100% oxygen by face mask on the assumption that there is impending respiratory failure. Fourth, a true severe asthma exacerbation usually requires hours or even days to resolve; VCD can resolve instantaneously if the patient gets distracted or if they fall asleep. Fifth, pulmonary function testing during an asthma exacerbation will show a picture of severe lower airway obstruction (Fig. 1). In contrast, patients with VCD will show a picture of fixed airway obstruction with a totally out of proportion severe airflow limitation both on inspiration and exhalation that can improve dramatically without any treatment if the patient relaxes (Fig. 2a, b). Flexible laryngoscopy during an episode of VCD will show the paradoxical movement of the vocal cords and can be extremely useful in reassuring the patients and help them recognize and eventually control the problem. Patients who have been identified as having VCD should receive assessment and in some cases treatment by a behavioral medicine provider.

Psychogenic Cough

Psychogenic cough, or habit cough, is a recurrent cough that is not related to an identifiable underlying disease. It often presents as a loud, barking, or harsh cough that persists for extended periods of time, sometimes years in more extreme cases. The clinical criteria for psychogenic cough consist of repetitive coughing up to several times per minute for extended periods, and even all day, and a total absence

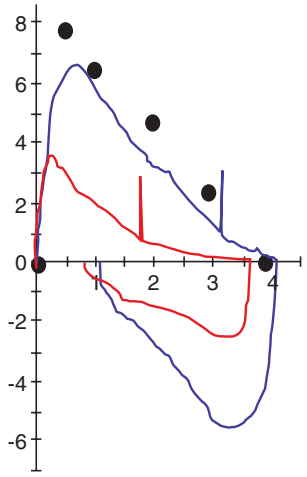

Fig. 1 Maximal expiratory flow-volume curve (MEFVC) of a known asthmatic during an acute exacerbation showing severe lower airway obstruction (*red line*). The same patient after treatments with bronchodilators showing significant reversibility (*blue line*). (*courtesy of A. C. Koumbourlis, MD, Washington, DC*)

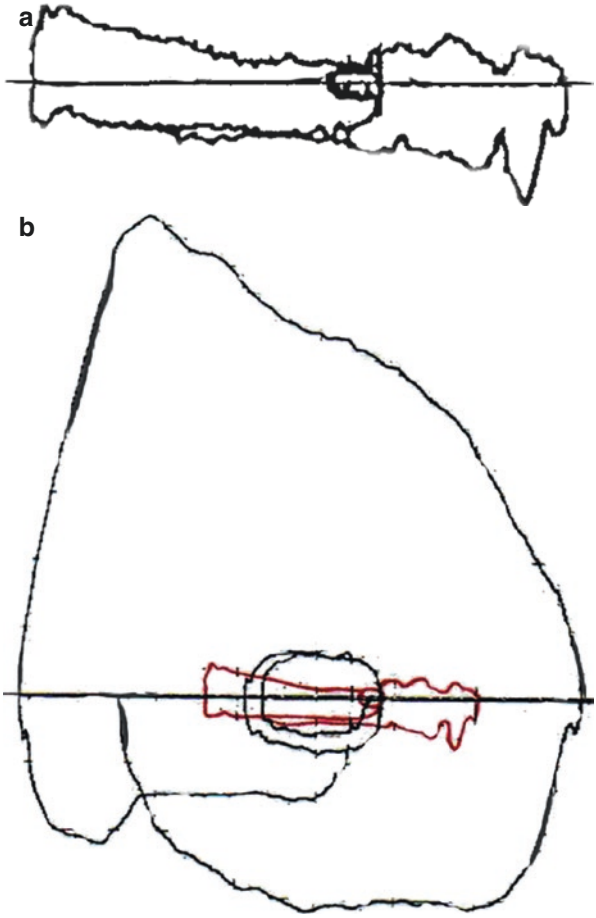

Fig. 2 (**a**) MEFVC of a patient during an acute episode of VCD showing severe flattening of both the inspiratory and expiratory flow-volume curves consistent with very severe fixed airway obstruction. Her breath sounds were barely audible on auscultation, but she did maintain normal oxyhemoglobin saturations on room air. (*courtesy of A. C. Koumbourlis, MD, Washington, DC*). (**b**) Ten minutes after she was engaged into conversation by the respiratory technician, the patient produced a completely normal MEFVC without any treatment. The MEFVC in *red* is the original one. Note also the difference in the size of the tidal breath between the two efforts. (*courtesy of A. C. Koumbourlis, MD, Washington, DC*)

of coughing during sleep. It often follows a viral illness. Even though the cough can sound harsh, the child is usually quite comfortable between coughing bouts and does not experience pain or discomfort. Psychogenic cough is not associated with shortness of breath or wheezing; although it is sometimes treated with standard asthma interventions including bronchodilators, steroids, and antihistamines and evaluated with invasive diagnostic procedures, psychogenic cough can easily be diagnosed based on clinical observation. If not treated with the appropriate intervention, symptoms can continue for extended periods of time.

When persistent, psychogenic cough can be disruptive to social, academic, and workplace activities. It often presents as more severe when the patient is stressed and/or with caregivers and health care providers. It is not uncommon for children to be kept out of school because the cough is disruptive in classrooms. On average,

children with psychogenic cough have higher ratings on obsessive-compulsive disorder scales, and some have a high drive for academic achievement. Self-imposed stress and anxiety may be higher in this group, and the disruptive nature of psychogenic cough can lead to a patterns of avoidance and academic and social setbacks, leading to further avoidance. Clinicians should recognize the unique characteristics of psychogenic cough as distinguished from the many other causes of chronic cough to avoid extensive and expensive evaluative measures and unnecessary pharmacotherapy.

Assessment

Preliminary evaluation of stress, mood disturbance, and coping in pulmonary patients and other patients with chronic medical problems is increasingly viewed as an important component of the medical evaluation, and there are well-established and easy-to-use measures that may be used in medical and medical specialty care practices. To this point, the Cystic Fibrosis Foundation and the European Cystic Fibrosis Society recently released guidelines for screening and treatment of depression and anxiety. After an exhaustive review, the authors of the cystic fibrosis guidelines recommended the Patient Health Questionnaire (PHQ-9) and the Generalized Anxiety Disorders scale (GAD-7) which are open access measures that take just a few minutes to administer and score. Additional measures developed by the National Institutes of Health called Patient-Reported Outcomes Measurement Information System (PROMIS) are also open access measures that assess anxiety, depression, and other mental health symptoms based on both patient and caregiver report. One additional open access brief measure that has been used extensively to evaluate stress in medical patients is the Perceived Stress Scale (PSS). Each of these measures which range in length from 7 to 10 items yields a total score that indicates the presence or absence mental health symptoms. It should also be noted that the PHQ has one question on suicidality and if endorsed, immediate assessment by a health provider is necessary to determine suicidal risk (e.g., does the patient have a plan for self-harm and is there potential for the patient to carry out the plan) and make either an urgent referral or when risk is low, a referral to a mental health provider who optimally has some experience working with patients who have comorbid medical and psychiatry disorders. Referral to a mental health specialist should be considered when any of these scale scores are elevated.

Secondary gain, avoidance, and motivation are also important factors to evaluate and help to point toward the level of mental health intervention that might be required. For each of the pulmonary problems discussed above, secondary gain can be persistent and difficult to address. For example, the attention a child receives from their parents when they present with functional or other pulmonary disease symptoms can be very reinforcing or rewarding even when the attention is negative. While often not a fully conscious behavior on the part of the child and best if not

defined as manipulative, changes in parent attention to the patient and their siblings and a shift in how a symptom is attended to are often necessary. For children who have missed school due to their pulmonary problem or who have social anxiety, maintenance of the symptom is reinforced by avoidance of a stressor (getting back to school after falling behind or avoidance of social situations) however maladaptive the coping response. Finally, assessing the child's motivation directly and identifying possible external motivators for parents to put in place can help to reduced symptoms.

Interventions

Interventions for functional pulmonary problems include education; protocols or components of cognitive behavior therapy (CBT) to address symptoms of depression, anxiety, coping, and mindfulness; and stress reduction techniques. Some components of these interventions can be implemented by any provider who has some training in CBT, but in more complex and persistent cases, referral to a pediatric behavioral medicine specialist may be necessary. Key components of these interventions are described below.

Education

The initial step in any intervention is to provide the patient and their caregivers with a clear explanation of the psychophysiological origins of pulmonary symptoms. The explanations should be simple enough to be understood by a young child, and by engaging them, they are assigned a role and, to some degree, control in implementing an intervention. Even a young child can understand that symptoms of an asthma exacerbation, vocal dysfunction, or dyspnea can have both a cognitive component and a psychophysiological stress response.

Sample Script for Educating Patients and Caregivers (Psychophysiological Sympathetic Response)

If you are crossing a street and look up and see a car racing toward you, your body responds automatically with a burst of adrenaline which increases heart and respiratory rate and allows an immediate response such as jumping out of the way. For some people, this protective response can occur when they feel a change in their body (tightness in the chest or wheezing) or an anxious thought that is related ("what if I have a problem breathing when I get on the school bus?") or unrelated to a physical symptoms ("I didn't understand my math homework and my teachers

might call on me and make me look dumb"). Understanding this link between the physical symptom and the thought is a first step to calming and preventing a response that could initiate or worsen symptoms.

Similarly for psychogenic cough, education about the origin and maintenance of the symptom is an important initial step in treatment.

Sample Script for Educating Parents and Caregivers (Psychogenic Cough)

When you cough it is like clapping your hands together which when done repeatedly causes discomfort and actual irritation of muscles and skin. When your cough started a while ago, you had a lot of mucous and your cough helped to clear your airway. Now you do not have any more mucous, but you have a lingering sensation in our airway due to repeated coughing. When you learn to decrease the frequency of your cough, those sensations will gradually go away.

Defining the Symptoms

There is a great deal of overlap of respiratory symptoms. These include somaticized tensions often localized to the respiratory system, constriction of upper airway tissue and muscles, hyper focus on symptoms, hypoventilation and hyperventilation, and itchiness or tickle. An initial step in treatment of functional pulmonary symptoms is a careful inquiry into the actual symptoms. The inquiry into the sensation of physical symptoms varies by patient age, verbal fluency, and capacity to focus on physical symptoms. While simple explanations similar to the scripts above are often sufficient, younger patients may benefit from drawing pictures with colors representing sensations; coming up with descriptors (e.g., pressure, dry tickle) and lists cutting across a range of sensory modalities can also be helpful for some patients. A focus on the progression of sensation may also be particularly helpful. For example, patients with psychogenic cough can usually describe the sensation in their upper airway that precedes the cough. Once identified, the cause of the sensation can be described in detail and linked to a specific part of the anatomy, and then the patient can be instructed to observe and not respond to the stimuli or told to take a calm breath or a sip of water. These behaviors delay the cough, distract from the impulse to cough, and give the patient a sense of control and a very palpable sense of relief when they do not cough. Linking sensation of symptoms to the actual physical phenomena and providing basic education about how symptoms develop is a very useful tool for decreasing a problematic response (i.e., cough, hyperventilation, tensing of upper airway musculature).

Decreasing Stress

Stress responses and coping with overwhelming thoughts about perceived illness and actual environmental demands are important treatment targets. Cognitive therapies, a key component of CBT are very effective interventions for maladaptive coping. A framework work for categorizing stressors is a first step to putting them in context and controlling them (see Table 1). For example,

1. A hospitalized teenager who is stressed about school could define their concerns about missed homework as an acute but controllable (A + C) stressor.
2. A 7-year-old with severe asthma avoids going to their outpatient appointments because they have a fear of being hospitalized could define their fear as a chronic and uncontrollable stress (C + UC).

Categorizing a stressor or fear is the first step toward addressing it. Mindfulness-Based Stress Reduction is a validated intervention that combines cognitive techniques with mental and physical relaxation (i.e., deep breathing, guided imagery, yoga) that can be tailored to meet the patient's preferences and physical limitations. These techniques have demonstrated efficacy in decreasing stress and anxiety and improving coping.

Emotion Dysregulation, Depression, and Anxiety

The most efficacious interventions for emotional and persistent mental health problems are cognitive behavior therapy (CBT) and acceptance and commitment therapy (ACT). These interventions can be used in both children and adults but must be implemented by a licensed provider who has received specific training in implementing protocols with specific populations (e.g., psychologists, social workers, psychiatrists, nurse practitioners). These intervention protocols include modules that may be adapted for an individual's needs or age group. Most of these interventions are provided over 6–8 weekly treatments with occasional follow-up treatment sessions. Both CBT and ACT protocols involve careful definition of the target problems; matching goals and principles between the therapist, caregiver, and patients; cognitive modification (reframing, stopping, or changing negative thoughts and predictions); relaxation (e.g., meditation and breathing exercises); identifying reinforcements and patterns of social behavior that maintain problems; guided exposure to anxiety-producing stimuli; rehearsal of scenarios that produce negative emotions and psychophysiological symptoms; and relapse prevention (e.g., how to identify and cope with reemergence of symptoms).

Table 1 Defining stressors

	Acute	Chronic
Controllable	A + C	C + Ch
Uncontrollable	A + UC	Ch + UC

In summary, there is a complex relationship between mental health problems and pulmonary symptoms that are functional or can be linked to a persistent or distal physiological etiology. In all cases, at least brief evaluation of affect regulation (sad and depressed mood and anxiety), stress, and coping is warranted to arrive at a differential diagnosis or to improve prognosis. There are numerous open access measures to evaluate mental health status as well as efficacious treatment protocols to decrease physical symptoms and concurrently treat mood disturbance, stress response, coping, and psychiatric disorders.

Bibliography

1. Abu-Hasan M, Tannous B, Weinberger M. Exercise-induced dyspnea in children and adolescents: if not asthma then what? Ann Allergy Asthma Immunol. 2005;94(3):366–71.
2. Bahrainwala AH, Simon MR. Wheezing and vocal cord dysfunction mimicking asthma. Curr Opin Pulm Med. 2001;7(1):8–13.
3. Bloomberg GR, Chen E. The relationship of psychologic stress with childhood asthma. Immunol Allergy Clin N Am. 2005;25(1):83–105.
4. Chen E, Miller GE. Stress and inflammation in exacerbations of asthma. Brain Behav Immun. 2007;21(8):993–9.
5. Doshi DR, Weinberger MM. Long-term outcome of vocal cord dysfunction. Ann Allergy Asthma Immunol. 2006;96(6):794–9.
6. Eccleston C, Fisher E, Law E, Bartlett J, Palermo TM. Psychological interventions for parents of children and adolescents with chronic illness. Cochrane Database Syst Rev. 2015;4:CD009660. Epub 2015/04/16.
7. Haczku A, Panettieri RA. Social stress and asthma: the role of corticosteroid insensitivity. J Allergy Clin Immunol. 2010;125(3):550–8.
8. Husein OF, Husein TN, Gardner R, Chiang T, Larson DG, Obert K, et al. Formal psychological testing in patients with paradoxical vocal fold dysfunction. Laryngoscope. 2008;118(4):740–7.
9. Irwin RS, Glomb WB, Chang AB. Habit cough, tic cough, and psychogenic cough in adult and pediatric populations: Accp evidence-based clinical practice guidelines. Chest. 2006;129(1_suppl):174S–9S.
10. Kenn K, Balkissoon R. Vocal cord dysfunction: what do we know? Eur Respir J. 2011;37(1):194–200.
11. Kimura T, Yokoyama A, Kohno N, Nakamura H, Eboshida A. Perceived stress, severity of asthma, and quality of life in young adults with asthma. Allergol Int. 2009;58(1):71–9.
12. Kallesoe KH, Schroder A, Wicksell RK, Fink P, Ornbol E, Rask CU. Comparing group-based acceptance and commitment therapy (ACT) with enhanced usual care for adolescents with functional somatic syndromes: a study protocol for a randomised trial. BMJ Open. 2016;6(9):e012743. Epub 2016/09/17.
13. Loerbroks A, Apfelbacher CJ, Bosch JA, Stürmer T. Depressive symptoms, social support, and risk of adult asthma in a population-based cohort study. Psychosom Med. 2010;72(3):309–15.
14. Ludwig DS, Kabat-Zinn J. Mindfulness in medicine. JAMA. 2008;300(11):1350–2. https://doi.org/10.1001/jama.300.11.1350. PubMed PMID: 18799450. Epub 2008/09/19.

15. Mancuso CA, Westermann H, Choi TN, Wenderoth S, Briggs WM, Charlson ME. Psychological and somatic symptoms in screening for depression in asthma patients. J Asthma. 2008;45(3):221–5.
16. Morris MJ, Allan PF, Perkins PJ. Vocal cord dysfunction: etiologies and treatment. Clin Pulm Med. 2006;13(2):73–86.
17. Oh Y-M, Kim YS, Yoo SH, Kim SK, Kim DS. Association between stress and asthma symptoms: a population-based study. Respirology. 2004;9(3):363–8.
18. Ramanuja S, Kelkar P. Habit cough. Ann Allergy Asthma Immunol. 2009;102(2):91–5.
19. Rietveld S, van Beest I, Prins PJM. The relationship between specific anxiety syndromes and somatic symptoms in adolescents with asthma and other chronic diseases. J Asthma. 2005;42(9):725–30.
20. Ritz T, Steptoe A, DeWilde S, Costa M. Emotions and stress increase respiratory resistance in asthma. Psychosom Med. 2000;62(3):401–12.
21. Schneider A, Löwe B, Meyer FJ, Biessecker K, Joos S, Szecsenyi J. Depression and panic disorder as predictors of health outcomes for patients with asthma in primary care. Respir Med. 2008;102(3):359–66.
22. Tilles SA. Vocal cord dysfunction in children and adolescents. Curr Allergy Asthma Rep. 2003;3(6):467–72.
23. Warner CM, Colognori D, Kim RE, Reigada LC, Klein RG, Browner-Elhanan KJ, et al. Cognitive-behavioral treatment of persistent functional somatic complaints and pediatric anxiety: an initial controlled trial. Depress Anxiety. 2011;28(7):551–9. Epub 2011/06/18.
24. Weinberger M, Abu-Hasan M. Pseudo-asthma: when cough, wheezing, and dyspnea are not asthma. Pediatrics. 2007;120(4):855–64.

Pulmonary Complications of Rheumatologic Disorders

Rosemary Megalaa, Anastassios C. Koumbourlis, and Iman R. Sami-Zakhari

Introduction

Depending on the tissues/organs that are primarily affected, the rheumatologic disorders are often subdivided into rheumatologic disorders, connective tissue disorders, vasculitides, and mixed disorders (Table 1). However, there is a big overlap among them.

The pulmonary complications of the rheumatologic disorders tend to appear late in the course of the disease, but it is not uncommon for a respiratory complication to be among the first manifestations. Thus, when evaluating a patient with a known rheumatologic disorder, it is very important to anticipate the development of respiratory complications. Conversely, one should consider the possibility of an underlying rheumatologic disorder when confronted with a patient whose respiratory symptoms cannot be easily explained by a typical respiratory illness.

Pathogenesis

The pathogenesis of the respiratory complications is complex and varies among the different rheumatologic disorders. From a practical standpoint, the damage to the lungs, pleura, and airways can be seen as an exaggerated response of the tissues to

R. Megalaa, D.O. • I.R. Sami-Zakhari, M.D., M.R.C.P. (✉)
Division of Pulmonary and Sleep Medicine, Children's National Health System, School of Medicine and Health Sciences, George Washington University, Washington, DC, USA
e-mail: RMegalaa@childrensnational.org; ISami@childrensnational.org

A.C. Koumbourlis, M.D., M.P.H.
Division of Pulmonary and Sleep Medicine, Children's National Medical Center, George Washington University, School of Medicine and Health Sciences, Washington, DC, USA
e-mail: akoumbou@childrensnational.org

© Springer International Publishing AG 2018

A.C. Koumbourlis, M.A. Nevin (eds.), *Pulmonary Complications of Non-Pulmonary Pediatric Disorders*, Respiratory Medicine,
https://doi.org/10.1007/978-3-319-69620-1_11

Table 1 Common rheumatologic and connective tissue diseases and vasculitides in children

Rheumatologic disorders	Connective tissue disorders	Vasculitides
• Childhood systemic lupus erythematosus (cSLE) • Juvenile idiopathic (rheumatoid) arthritis (JIA/JRA) • Sarcoidosis • Antiphospholipid syndrome • Goodpasture syndrome (GPS)	• Systemic sclerosis (scleroderma) (SSc) • Mixed connective tissue disease (MCTD) • Juvenile dermatomyositis (JDM) • Sjogren's syndrome • Relapsing polychondritis	*Large-vessel vasculitis* • Takayasu's arteritis *Medium-sized vasculitis* • Childhood polyarteritis nodosa • Cutaneous polyarteritis • Kawasaki disease *Small-sized vasculitis* I. *Granulomatous* • Granulomatosis with polyangiitis (GPA) (Wegener's granulomatosis) • Churg-Strauss syndrome (CSS) II. *Nongranulomatous* • Microscopic polyangiitis (MPA) • Henoch-Schonlein purpura • Isolated cutaneous leukocytoclastic vasculitis • Hypocomplementemic urticarial vasculitis *Other* • Behcet's disease

an autoimmune inflammatory process that leads to major remodeling and possibly destruction (fibrosis). The exact mechanisms of both the autoimmune insult and of the response of the tissues remain unclear. With regard to the effects on the respiratory system, it has been suggested that it may be related to macrophages that in the process of ingesting environmental toxins, pathogenic organisms or antigens may become antigenic themselves causing activation of autoreactive CD4 T lymphocytes and B lymphocytes that result into the development of autoantibodies.The antibodies implicated in the pathogenesis of the various rheumatologic disorders tend to differ but may not be specific to only one particular disorder (Table 2). Considering that the exposures that presumably trigger these mechanisms universal, it is reasonable to assume that there are other host-related (probably genetic) factors that determine the autoimmune response.

Despite the differences in the initial mechanisms, the fibrosis that is the end result of the pathogenic process develops through a mechanism that seems to be the same for the various disorders and consists of deposition of collagen and possibly other deposits of extracellular matrix (ECM) caused by the activation of pulmonary fibroblasts. The activation of fibroblasts is promoted by various growth factors (e.g., platelet-derived growth factor) and cytokines (e.g., IL-1β, IL-6). The lung epithelial cells also contribute to the fibrosis through the so-called epithelial-mesenchymal transition (EMT) process in the end of which they convert themselves into fibroblasts and myofibroblasts that then begin producing ECM.

Table 2 Antibodies associated with specific rheumatologic disorders

Rheumatologic condition	Implicated antibodies
Juvenile polymyositis/dermatomyositis (JPS/JDS)	• Myositis-specific and myositis-associated antibodies (anti-Jo1) • Melanoma differentiation-associated protein-5 (MDA-5)
Systemic sclerosis of childhood (SSc)	• Anti-Sc170 antibodies • Nucleolar staining antinuclear antibody (ANA) • Anticentromere antibodies (ACA)
Systemic lupus erythematosus (SLE)	• Anti-ribonucleoprotein (anti-U1RNP)
Granulomatosis with polyangiitis (GPA) (Wegener's granulomatosis)	• Anti-neutrophil cytoplasmic antibodies against proteinase 3 (PR3-ANCA) with cytoplasmic immunofluorescence pattern (c-ANCA)
Eosinophilic granulomatosis with polyangiitis (EGPA) (Churg-Strauss syndrome)	• Anti-neutrophil cytoplasmic antibodies against myeloperoxidase (MPO-ANCA) with perinuclear immunofluorescence pattern (p-ANCA)
Microscopic polyangiitis (MPA)	• Anti-neutrophil cytoplasmic antibodies against myeloperoxidase (MPO-ANCA) with perinuclear immunofluorescence pattern (p-ANCA)

Specific Effects on the Components of the Respiratory System

Rheumatologic disorders can affect virtually any part of the respiratory system. However the prevalence and the extent vary significantly among them (Table 3). Not every rheumatologic disorder affects the same component of the respiratory system, and therefore the type of pulmonary complication may give clues as to the nature of the underlying disorder. The symptoms may follow an insidious course (as is the case in the development of interstitial lung disease and/or pulmonary hypertension), but they can also present acutely with respiratory distress or even respiratory failure (as in the case of acute lupus pneumonitis). In spite of their severity, the pulmonary manifestations are rarely pathognomonic of a particular disorder, and therefore one should consider many other clinical and laboratory findings in order to make the diagnosis.

Chest Wall

Certain rheumatologic disorders cause muscle weakness and chest wall rigidity. Muscle weakness may be due to the underlying disease such as dermatomyositis/polymyositis or to prolonged use of systemic corticosteroids that are the mainstay of therapy for many of them. The muscle weakness seen in dermatomyositis or polymyositis can lead to aspiration pneumonia secondary to pharyngeal muscle weakness.

Table 3 Effects and prevalence of common rheumatologic disorders on the various components of the respiratory system

	JIA	SLE	JDM	MCTD	Sarcoidosis	SSc	GPA	MPA
Pulmonary complications at any point	<10%	80%	65%	75%	90%	50%	>50%	10–30%
Present at initial presentation	1+	2+	1+	1+	3+	3+	3+	1+
Chest wall	1+	1+	3+	1+	NR	1+	NR	NR
Diaphragm	NR	2+	2+	NR	NR	NR	NR	NR
Pleura and pleural space	2+	3+	NR	2+	NR	NR	NR	NR
Larynx and trachea	1+	1+	NR	NR	2+	NR	2+	NR
Lower airways (bronchiectasis)	1+	1+	1+	2+	1+	3+	NR	NR
Acute pneumonitis	1+	2+	1+	1+	NR	1+	NR	NR
Interstitial lung disease	1+	1+	1+	2+	1+	3+	NR	NR
Granulomas	NR	NR	NR	NR	3+	NR	3+	NR
Diffuse alveolar hemorrhage	1+	1+	NR	1+	NR	1+	2+	3+
Pulmonary hypertension	NR	1+	1+	2+	NR	2+	NR	1+

NR not reported

Systemic sclerosis (scleroderma) causes chest wall rigidity due to the "hardening" of the skin that is one of the characteristic features of this disorder. Chest wall rigidity may be also seen in ankylosing spondylitis due to fusion of the costovertebral joints.

Diaphragm

Involvement of the diaphragm may be seen in dermatomyositis or polymyositis and leads to diaphragmatic elevation, reduced lung volumes, and basilar atelectasis. Loss of lung volume may also be seen in SLE or in combination of SLE and Sjogren's syndrome causing the so-called shrinking lung syndrome. That is believed to be related to diaphragmatic dysfunction. The condition appears to respond well to treatment with oral steroids, and if the primary underlying disease is adequately treated, the shrinking lung syndrome is rarely disabling or progressive.

Pleura and Pleural Space

SLE and JIA are the most common rheumatologic diseases that affect the pleural cavity. Pleural effusions in SLE occur in 30–50% of the affected patients. They may be unilateral or bilateral, and they are frequently associated with pericardial effusions. Pleural effusions are exudative, and they may be the initial clinical finding in

SLE (Fig. 1). Predominance of lymphocytes or polymorphs, low glucose concentration, and low complement levels characterize these effusions.

In JIA, pleural effusions can also be either unilateral or bilateral, may persist for months, and are typically exudative. They also show lymphocyte predominance, low glucose, elevated LDH and protein, and depressed complement levels. Patients may also have pleuritis which is usually accompanied by pericarditis. These exudative effusions must be differentiated from infectious exudative effusions and transudative effusions arising from renal or cardiac disease. Other rheumatologic diseases with pleural involvement are MCTD and Sjogren's syndrome.

Upper Airways

Cricoarytenoid arthritis occurs in JIA causing symptoms such as voice changes, sore throat, foreign body sensation, throat fullness, aspiration, and choking. Tracheal stenosis can occur in relapsing polychondritis and xerotrachea in Sjogren's syndrome, whereas subglottic stenosis is a fairly common feature of GPA (Wegener's granulomatosis). Depending on which part of the airways is affected, the symptoms may include hoarseness, nonproductive cough, difficulty in breathing, and persistent biphasic wheezing. Life-threatening narrowing of the upper airway necessitating a tracheostomy can occur in GPA due to granuloma formation and in relapsing polychondritis (Fig. 2).

Lower Airways

Bronchiectasis can occur in JIA as a direct effect or indirectly due to aspiration and/or recurrent infections. This diagnosis is best made by high-resolution CT scan of the chest (Fig. 3). Bronchiolitis is another relatively common manifestation of

Fig. 1 Left pleural effusion in adolescent female with SLE

Fig. 2 Circumferential thickening of subglottic airway in patient with relapsing polychondritis

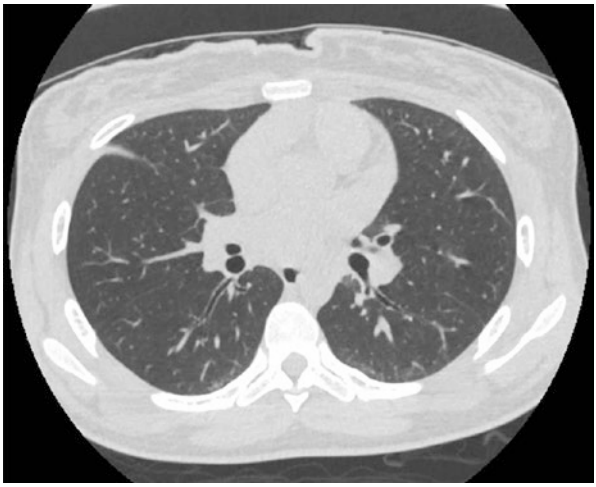

Fig. 3 Mild bronchiectasis in patient with scleroderma

various rheumatologic disorders. There are two main types of bronchiolitis: cellular and fibrosing. Cellular bronchiolitis is further subdivided into follicular and diffuse panbronchiolitis. Fibrosing bronchiolitis is also referred to as bronchiolitis obliterans (BO) and usually occurs in conjunction with organizing pneumonia. The distinction between the two kinds of bronchiolitis is important because cellular

bronchiolitis may be responsive to treatment with anti-inflammatory agents such as steroids and macrolides, whereas BO is very poorly responsive to treatment. Cellular bronchiolitis occurs most commonly in JIA and less commonly in ankylosing spondylitis and SLE. BO is seen most commonly in JIA (Fig. 4).

Alveolar Involvement/Air Space Disease

Organizing pneumonia occurs in several rheumatologic disorders but is seen most commonly in JIA, SLE, Sjogren's syndrome, and JDM/JPM. The pneumonia is often peripheral in distribution, but can be peribronchial and perivascular. It may be patchy or diffuse. Radiography shows patchy ground-glass opacities and consolidation that are best seen on HRCT scans (Figs. 5 and 6). Typical pathologic features are nodular plugs of connective tissue in small airways that have a patchy distribution, mild interstitial chronic inflammation with little or no fibrosis, and preservation of lung architecture.

Fig. 4 Bronchiolitis obliterans with mosaic appearance on chest CT

Fig. 5 Right upper lobe organizing pneumonia in a patient with relapsing polychondritis

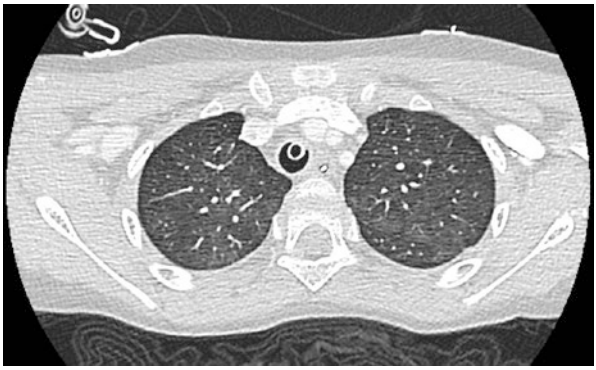

Fig. 6 Complete resolution in the same patient after treatment with steroids

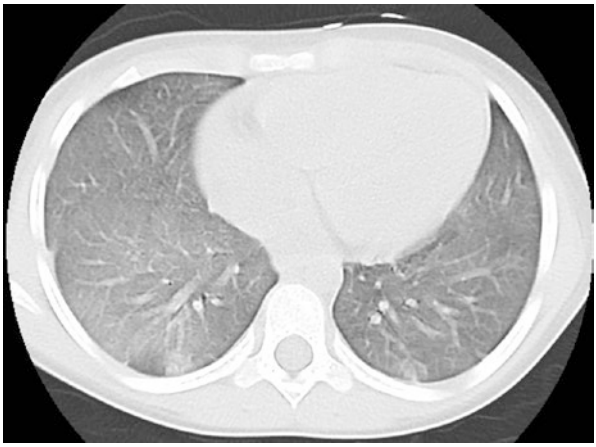

Fig. 7 Diffuse ground glass in patient with SLE

Interstitium

Interstitial lung disease (ILD) may develop in an insidious manner with progressive exertional dyspnea, chronic cough, pleuritic chest pain, and basal rales. As this may be the first manifestation of connective tissue disease, serologic testing is recommended for anyone presenting with ILD. ILD is more common in JIA and systemic sclerosis than in SLE. If chronic pneumonitis is seen in SLE, one should also consider Sjögren's syndrome, infection, or drug toxicity. There is a spectrum of ILD, with a picture of nonspecific interstitial pneumonitis (NSIP) at one end and usual interstitial pneumonitis (UIP) at the other end. In the former there are ground-glass opacities and increased interstitial markings with little or no honeycombing (Fig. 7). In the latter the reticular markings are much more prominent with honeycombing and traction bronchiectasis (Fig. 8). The ground-glass opacities are much less obvious. The pathology of ILD is initially characterized by chronic inflammatory

Fig. 8 Progression of interstitial lung disease with pulmonary fibrosis and traction bronchiectasis

changes in the alveolar walls and the presence of large mononuclear cells in the alveolar spaces. This is accompanied by interstitial fibrosis. As the disease progresses, there is an increase in fibrosis with honeycombing and fibroblastic foci. The distribution also becomes subpleural.

Diffuse interstitial fibrosis in JRA is an indicator of poor prognosis and is seen more commonly in those with subcutaneous nodules. ILD is common in systemic sclerosis with some studies showing prevalence as high as 80%. Pulmonary involvement in SSc is often asymptomatic. Adult dermatomyositis has up to 50% pulmonary involvement with predominance of ILD, which may also develop with or after the onset of skin and muscle manifestations. Contrary to adult dermatomyositis, symptomatic pulmonary involvement is rare in children with juvenile dermatomyositis. Pneumomediastinum with interstitial pneumonitis is a common adult complication which may also be seen in juvenile dermatomyositis.

Treatment with anti-inflammatory and immunomodulating agents may slow down or even partially reverse the course of ILD if it is early in the course of the disease. UIP however is poorly responsive to treatment.

Pulmonary Vasculature

Involvement of the pulmonary vasculature can occur in one of several ways:

Pulmonary arterial hypertension (PAH)

Pulmonary arterial hypertension (PAH) has been reported in almost every type of connective tissue diseases. Patients present with lethargy, reduced exercise capacity, anorexia, chest pain, syncope that may be related to exertion, and congestive heart failure. Isolated PAH occurs in 10–30% of patients with systemic sclerosis. Reduced DLCO of less than 80%, PAH, and pulmonary fibrosis is one of the minor criteria in diagnosing juvenile systemic sclerosis. PAH also occurs in asso-

ciation with parenchymal lung disease. It is rare in patients with JIA without parenchymal disease. In pediatric SLE, the prevalence of PAH as determined by echocardiogram was found to be 4.2% as opposed to adults who have a higher prevalence of 14%. The presence of PAH is a poor prognostic sign, as treatment with endothelin receptor antagonists is less effective than in idiopathic PAH. Consideration of venous thrombosis and thromboembolic disease should be considered in acute respiratory decline in SLE along with dyspnea, pleuritic chest pain, and hemoptysis.

Vasculitis

The ANCA-associated vasculitis (AAV) syndromes are characterized by necrotizing vasculitis of small vessels, with frequent pulmonary and renal involvement. The AAV syndromes with frequent pulmonary involvement are Wegener's granulomatosis or GPA, microscopic polyangiitis (MPA), and Churg-Strauss syndrome (CSS). GPA is characterized by granuloma formation (discussed below) as well as vasculitis. CSS has an initial phase with symptoms of asthma and rhinitis. This is followed by eosinophilia and finally by the vasculitic phase. The latter has two types: an ANCA-positive type with more frequent renal involvement and an ANCA-negative type with greater eosinophilia and more cardiac and pulmonary disease.

Diffuse Alveolar Hemorrhage (DAH)

Pulmonary hemorrhage is seen in SLE and has been reported to occur at disease onset. Lupus patients with acute pulmonary hemorrhage should be carefully investigated for pulmonary infections and treated empirically with antibiotics as this may improve survival. Infection is the major cause of mortality in pediatric SLE which prompts aggressive investigation and treatment of infectious complications. DAH is a serious life-threatening complication of SLE. In adult series the mortality is up to 50%. DAH is also commonly present in the vasculitides—GPA and MPA. Less common causes are isolated pulmonary capillaritis and anti-glomerular basement membrane antibody syndrome. The clinical presentation is one of severe dyspnea with or without hemoptysis, accompanied by a sudden drop in hemoglobin, which may progress to respiratory failure. The CXR and HRCT show diffuse alveolar opacities that are indistinguishable from infection or effusions (Fig. 9). In SLE, presentation of sudden deterioration in respiratory function, fever, dyspnea, and hemoptysis should alert the physician of acute lupus pneumonitis and alveolar hemorrhage. Although rare, this complication may occur suddenly anytime during the disease process or may be the presenting symptom. Hemoptysis with dyspnea and cough may also be commonly seen in GPA at nearly 75% of childhood cases.

Fig. 9 Diffuse bilateral pulmonary opacities and consolidation in patient with diffuse alveolar hemorrhage

Pulmonary Nodules

Noncaseating granulomatous lesions or nodules are the hallmark of sarcoidosis. They can occur in any organ of the body. The pathology shows organized collections of predominantly $CD4^+$ T lymphocytes and mononuclear phagocytes (epithelioid cells, macrophages, and multinucleated giant cells). Schaumann and asteroid inclusion bodies may also be present. In the lung the granulomas are located in perilymphatic areas, near the bronchioles, the subpleural space, and the perilobular spaces. They usually heal with preservation of the lung parenchyma, but in 20–25% fibroblast proliferation results in the formation of fibrotic scar tissue. Patients present with dyspnea and cough. Physical examination may be normal or reveal crackles and wheeze. Radiology shows mediastinal lymphadenopathy, +/− parenchymal infiltrates that may progress to fibrosis.

GPA is a vasculitic syndrome characterized by the formation of caseating granulomas. The largest case series describing chest CT findings in 18 children with GPA showed pulmonary involvement in 90% of newly diagnosed patients. Ninety percent had pulmonary nodules, 52% had ground-glass opacification, and 45% had air space opacification. Two-thirds of the patients had multiple nodules (more than five), and the size was larger than 5 mm (Fig. 10). Cavitation was present in 17%.

Indirect Complications

Pulmonary complications may occur in many rheumatologic disorders as a result of reaction to or toxicity of biologic agents used in their treatment. For details of these potential complications, see Chapter "Pulmonary Complications of Drug Therapy". Respiratory infections are very common causes of complications due to the immunosuppression that is part of the therapy of these disorders.

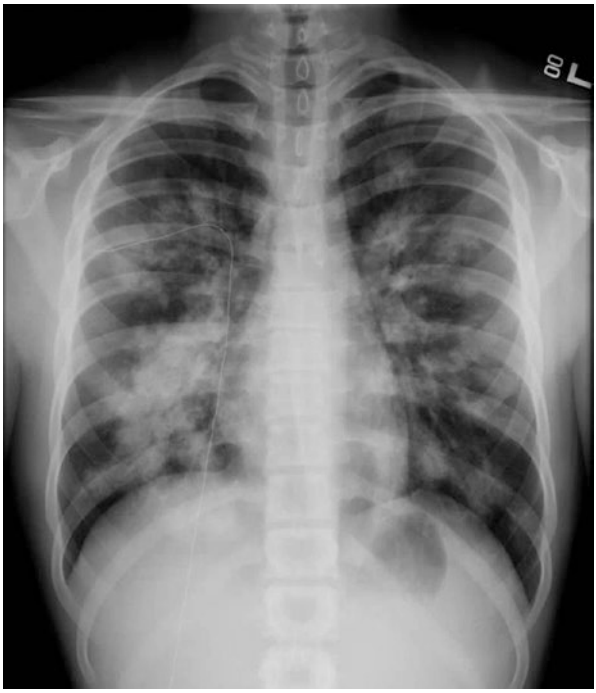

Fig. 10 Pulmonary nodules demonstrated on this PA chest radiograph in a patient with granulomatosis with polyangiitis

When to Suspect an Underlying Rheumatologic Disorder

Involvement of the respiratory system occurs with variable frequency in rheumatologic disease and is a major cause of morbidity and even mortality. Evaluation of a patient with known rheumatologic disease is relatively easy because there are specific manifestations that should be confirmed or ruled out. It is far more difficult to determine whether the presenting symptom in a patient is due to an underlying rheumatologic disorder. Although no sign or symptom (especially among the respiratory ones) is pathognomonic of any condition, several of them should at least raise the suspicion of an underlying rheumatologic disorder.

A. Clinical Symptoms

- Unexplained constitutional symptoms (e.g., fever, fatigue, weight loss, malaise)
- Unexplained and progressive dyspnea especially on exertion (it may be the presenting symptoms of underlying ILD and/or pulmonary hypertension)
- Unexplained persistent pleuritic pain
- Recurrent severe otorhinolaryngological problems involving primarily the nose (rhinitis, epistaxis, nasal crusts, perforation of the nasal septum, damage of the turbinates) but also of the sinuses (sinusitis) and ears (otitis media; sensorineural or conductive hearing loss)
- Unexplained hemoptysis

B. Radiographic Findings

- Unexplained subglottic and/or tracheal stenosis
- Pleural and/or pericardial effusions in the absence of an infectious or malignant cause
- Unexplained bronchiectasis
- Incidental finding of nodules and/or of ILD in chest radiographs and/or computed tomography scans

C. Abnormal Pulmonary Function Test

- Unexplained pattern of restrictive lung disease (especially associated with decrease in the diffusing capacity) in routine pulmonary function testing

Evaluation

In patients with known rheumatologic disease as well as those who are presenting with unexplained respiratory tract disease, a careful history should be obtained followed by a complete examination to enable a differential diagnosis to be made. This should be followed by a chest X-ray and performance of pulmonary function testing (PFT). If PFTs and plain chest radiology are abnormal, they should be followed by high-resolution CT of the chest. Bronchoscopy and BAL should be also considered especially if infection is high in the differential diagnosis list. Lung biopsy becomes necessary if no diagnosis has been established with the less invasive methods and the patient remains symptomatic with worsening symptoms and/or if therapy with drugs that have potential side effects is contemplated.

Pulmonary Function Testing

In children with active rheumatologic disease, the lung impairment can be often detected by pulmonary function testing (PFTs) before the chest radiographs become abnormal. The tests that are routinely performed to assess pulmonary function are measurement of lung volumes and airflow rates, with inspiratory and expiratory flow volume loops. Measurement of diffusion capacity and oxygen saturation at baseline and after a 6-min walk helps to detect more subtle abnormalities of gas exchange. Measurement of maximal inspiratory and expiratory pressures (MIP/MEP) is recommended when chest wall rigidity or weakness is suspected. Finally, progressive cardiopulmonary testing is particularly useful in cases of progressive PAH and/or ILD. Any of the tests alone or in combination is almost never pathognomonic. However, they can be very important as to the nature (restrictive vs. obstructive vs. mixed lung disease) and the severity of the illness. They are even more invaluable when repeated over time in assessing the progression of the disease and/or the effectiveness of the treatment.

Patients with ILD will typically show a restrictive pattern in their PFTs consisting of decreased lung volumes and proportional decreases in the FEV_1 and the expi-

ratory flow rates. The ratio FEV1/FVC is normal or increased reflecting the increased elastic recoil of the lung. An obstructive pattern can be also seen in patients with significant pulmonary hypertension (affecting primarily the small airways). Obstructive pattern can be also in patients with bronchiectasis or bronchiolitis obliterans. Patients with upper airway involvement (e.g., in subglottic or tracheal stenosis) will show a picture of fixed airway obstruction in which there will be flattening of both the inspiratory and expiratory flow volume curves (Fig. 11).

Abnormalities in lung diffusion capacity for carbon monoxide (DLCO) usually occur relatively late in the course of the disease. However, oxygen desaturation after the 6-min walk test or during cardiopulmonary exercise testing may be evident earlier in the course of the disease. Measurement of the diffusing capacity can be extremely helpful in cases when alveolar hemorrhage is suspected. This is because the molecules of inhaled carbon monoxide are bound to the free red blood cells in the alveoli, thus producing an artificially high value for the diffusing capacity especially when the lung volumes are decreased. In such cases, decrease in the value of the DLCO is actually a sign of improvement denoting the decreasing number of red blood cells in the alveoli.

In JIA, more than 50% of asymptomatic patients demonstrate abnormal PFTs. Restrictive disease patterns have been more commonly identified than obstructive abnormalities, and some patients may have a diffusion abnormality. Isolated abnormal PFTs in children with lupus do not predict progressive lung disease. Chest CT findings in pediatric SLE did not correlate with PFT abnormalities; therefore routine screening of asymptomatic pediatric lupus patients with CT is not recommended.

As with JIA and SLE, PFTs in juvenile dermatomyositis may show a restrictive defect, with decreased lung volumes, and a normal or elevated FEV1 to FVC ratio, as well as abnormal DLCO. Children with JDM should be closely monitored with pulmonary function testing to ensure that slowly progressive ILD does not develop as seen in adult DM.

Reduced DLCO in systemic sclerosis may be the only early indication of ILD or PAH. Much like previously mentioned rheumatologic diseases, a restrictive PFT

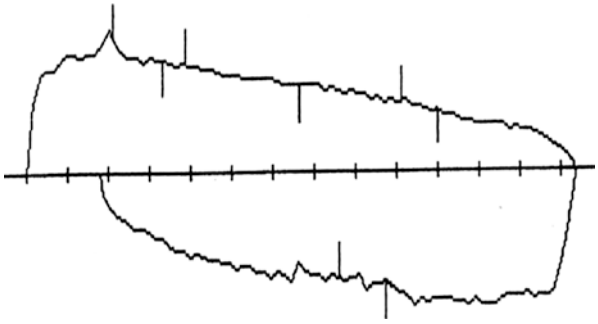

Fig. 11 Maximal flow-volume curves from a patient with severe acquired tracheal stenosis. Both the inspiratory and expiratory flow-volume curves are flattened creating an almost rectangular appearance

pattern with reduced forced vital capacity can occur in systemic sclerosis and may not correlate with abnormal lung radiograph findings.

Routine evaluation of pulmonary function testing is recommended in all patients with rheumatologic disease who are old enough and able to perform PFTs at least annually, even in the absence of respiratory symptoms to optimize treatment and prevent possible treatment-related complications.

Radiology

In patients with suspected lung or airway disease, chest and airway radiographs should be obtained. They may demonstrate the abnormalities, but CT imaging of the airway or lungs is much more sensitive and is indicated in all patients with suspected ILD or pulmonary nodules. As mentioned previously, the radiology findings do not always correlate with PFTs or the presence and severity of the symptoms.

Bronchoscopy and bronchoalveolar lavage

Bronchoscopy and bronchoalveolar lavage (BAL) should also be considered in patients with suspected lung disease in rheumatologic disorders. Nevertheless it is helpful in certain situations such as in DAH where the finding of BAL macrophages loaded with hemosiderin is helpful in making the diagnosis. When the BAL demonstrates increased eosinophils, this suggests a diagnosis of hypersensitivity pneumonitis possibly due to drug toxicity or presence of the Churg-Strauss syndrome. A lymphocytosis with a high CD4/CD8 ratio in BAL fluid is considered characteristic of pulmonary sarcoidosis. An increase in BAL leukocytes, especially granulocytes (neutrophils and eosinophils) or lymphocytes, is also seen in patients with ILD and indicates the presence of alveolitis. Finally, bronchoscopy and BAL are indicated in patients with a suspected infectious process where recovery of the organisms is necessary in guiding the antimicrobial (antiviral or antifungal) selection.

Lung Biopsy

Lung biopsy is indicated in selected cases and can aid in the diagnosis of an organizing pneumonia, bronchiolitis obliterans, as well as differentiating between granulomas that are caseating such as those seen in GPA versus those that are non-caseating that occur in sarcoidosis. It can also aid in assessing the severity of interstitial lung disease by assessing the cellularity and degree of fibrosis. This may help tailor the treatment required.

Bibliography

1. Helmick CG, Felson DT, Lawrence RC, Gabriel S, Hirsch R, Kwoh CK, et al. Estimates of the prevalence of arthritis and other rheumatic conditions in the United States—Part I. Arthritis Rheum. 2008;58(1):15–25.
2. Lawrence RC, Felson DT, Helmick CG, Arnold LM, Choi H, Deyo RA, et al. Estimates of the prevalence of arthritis and other rheumatic conditions in the United States—Part II. Arthritis Rheum. 2008;58(1):26–35.
3. Wagener JS, Hay TC. Chapter 47—Collagen vascular disorders. In: Meloni D, Carter KL, editors. Pediatric respiratory medicine. St. Louis: Mosby; 2008. p. 692–703.
4. Rabinovich CE. Pulmonary complications of childhood rheumatic disease. Paediatr Respir Rev. 2012;13:29–36.
5. Quezada A, Ramos S, Garcia M, Norambuena X, Pavon D. Lung involvement in rheumatologic diseases in children. Allergol Immunopathol. 2012;40(2):88–91.
6. Anaya JM, Diethelm L, Ortiz LA, Gutierrez M, Citera G, Welsh RA, et al. Pulmonary involvement in rheumatoid arthritis. Semin Arthritis Rheum. 1995;24(4):242–54.
7. Cojocaru M, Mihaela I, Silosi I, Vrabie CD. Pulmonary manifestations of systemic autoimmune diseases. Maedica (Buchar). 2011;6(3):224–9.
8. Quismorio FP. Pulmonary involvement in ankylosing spondylitis. Curr Opin Pulm Med. 2006;12(5):342–5.
9. Zamora-Legoff JA, Krause ML, Crowson CS, Ryu JH, Matteson EL. Progressive decline of lung function in rheumatoid arthritis-associated interstitial lung disease. Arthritis Rheumatol. 2017;69(3):542–9.
10. Dell SD, Schneider R. Chapter 57—Pulmonary involvement in the systemic inflammatory diseases of childhood. In: Wilmott RW, Kendig EL, Boat TF, et al., editors. Kendig and Chernick' disorders of the respiratory tract in children. Philadelphia: Saunders Elsevier; 2012. p. 822–47.
11. Johnson SR, Gladman DD, Urowitz MB, Okutucu S, Er E, Kaya B, et al. Pulmonary hypertension in systemic lupus. Lupus. 2004;13(7):506–9.
12. Alkady EA, Helmy HA, Mohamed-Hussein AA. Assessment of cardiac and pulmonary function in children with juvenile idiopathic arthritis. Rheumatol Int. 2012;32(1):39–46.
13. Silverman E, Eddy A. Chapter 21—Systemic lupus erythematosus. In: Cassidy JT, Petty RE, Laxer RM, et al., editors. Textbook of pediatric rheumatology. Philadelphia: Elsevier; 2011. p. 318.
14. Beresford MW, Cleary AG, Sills JA, Couriel J, Davidson JE. Cardio-pulmonary involvement in juvenile systemic lupus erythematosus. Lupus. 2005;14(2):152–8.
15. Lilleby V, Aaløkken TM, Johansen B, Førre Ø. Pulmonary involvement in patients with childhood-onset systemic lupus erythematosus. Clin Exp Rheumatol. 2006;24(2):203–8.
16. Al-Mayouf SM, Al-Eid W, Bahabri S, Al-Mofada S. Interstitial pneumonitis and air leakage in juvenile dermatomyositis. Rheumatology. 2001;40(5):588–90.
17. Misra R, Singh G, Aggarwal P, Aggarwal A. Juvenile onset systemic sclerosis: a single center experience of 23 cases from Asia. Clin Rheumatol. 2007;26(8):1259–62.
18. Russo RA, Katsicas MM. Clinical characteristics of children with juvenile systemic sclerosis: follow-up of 23 patients in a single tertiary center. Pediatr Rheumatol. 2007;5:6.
19. Kuwana M, Watanabe H, Matsuoka N, Sugiyama N. Pulmonary arterial hypertension associated with connective tissue disease: meta-analysis of clinical trials. BMJ Open. 2013;3:e003113.
20. Self SE. Autoantibody testing for autoimmune disease. Clin Chest Med. 2010;31(3):415–22.
21. Kowal-Bielecka O, Kowal K, Chyczewska E. Utility of bronchoalveolar lavage in evaluation of patients with connective tissue diseases. Clin Chest Med. 2010;31(3):423–31.
22. Hant FN, Herpel LB, Silver RM. Pulmonary manifestations of scleroderma and mixed connective tissue disease. Clin Chest Med. 2010;31(3):433–49.
23. Antin-Ozerkis D, Evans J, Rubinowitz A, Homer RJ, Matthay RA. Pulmonary manifestations of rheumatoid arthritis. Clin Chest Med. 2010;31(3):451–78.
24. Kamen DL, Strange C. Pulmonary manifestations of systemic lupus erythematosus. Clin Chest Med. 2010;31(3):479–88.

25. Kokosi M, Riemer EC, Highland KB. Pulmonary involvement in Sjögren syndrome. Clin Chest Med. 2010;31(3):489–500.
26. Kalluri M, Oddis CV. Pulmonary manifestations of the idiopathic inflammatory myopathies. Clin Chest Med. 2010;31(3):501–12.
27. Rafeq S, Trentham D, Ernst A. Pulmonary manifestations of relapsing polychondritis. Clin Chest Med. 2010;31(3):513–8.
28. Frankel SK, Jayne D. The pulmonary vasculitides. Clin Chest Med. 2010;31(3):519–36.
29. Ford HJ, Roubey RAS. Pulmonary manifestations of the antiphospholipid antibody syndrome. Clin Chest Med. 2010;31(3):537–45.
30. Kanathur N, Lee-Chiong T. Pulmonary manifestations of ankylosing spondylitis. Clin Chest Med. 2010;31(3):547–54.
31. Bolster MB. Osteoporosis and bone health in patients with lung disease. Clin Chest Med. 2010;31(3):555–63.
32. Meyer KC, Decker C, Baughman R. Toxicity and monitoring of immunosuppressive therapy used in systemic autoimmune diseases. Clin Chest Med. 2010;31(3):565–88.
33. Lee JC, Ahya VN. Lung transplantation in autoimmune diseases. Clin Chest Med. 2010;31(3):589–603.
34. Behr J. Approach to the diagnosis of interstitial lung disease. Clin Chest Med. 2012;33(1):1–10.
35. Jawad H, Chung JH, Lynch DA, Newell JD Jr. Radiological approach to interstitial lung disease: a guide for the nonradiologist. Clin Chest Med. 2012;33(1):11–26.
36. Jones KD, Urisman A. Histopathologic approach to the surgical lung biopsy in interstitial lung disease. Clin Chest Med. 2012;33(1):27–40.
37. Antin-Ozerkis D, Rubinowitz A, Evans J, Homer RJ, Matthay RA. Interstitial lung disease in the connective tissue diseases. Clin Chest Med. 2012;33(1):123–49.
38. Jacob J, Nair A, Hansell DM. High-resolution computed tomography of the pulmonary manifestations of connective tissue diseases. Semin Respir Crit Care Med. 2014;2(35):166–80.
39. Bonnaela F, Costabel U. Biomarkers in connective tissue disease-associated interstitial lung disease. Semin Respir Crit Care Med. 2014;2(35):181–200.
40. Urisman A, Jones KD. Pulmonary pathology in connective tissue disease. Semin Respir Crit Care Med. 2014;2(35):201–12.
41. Wells AU, Margaritopoulos GA, Antoniou KM, De Paulis A, Guiducci S, Matucci-Cerinic M. Interstitial lung disease in systemic sclerosis. Semin Respir Crit Care Med. 2014;2(35):213–21.
42. Lake F, Proudman S. Rheumatoid arthritis and lung disease: from mechanisms to a practical approach. Semin Respir Crit Care Med. 2014;2(35):222–38.
43. Hallowell RW, Ascherman DP, Danoff SK. Pulmonary manifestations of polymyositis/dermatomyositis. Semin Respir Crit Care Med. 2014;2(35):239–48.
44. Mittoo S, Fell CD. Pulmonary manifestations of systemic lupus erythematosus. Semin Respir Crit Care Med. 2014;2(35):249–54.
45. Kreider M, Highland K. Pulmonary involvement in Sjögren syndrome. Semin Respir Crit Care Med. 2014;2(35):255–64.
46. Maher TM. Immunosuppression for connective tissue disease–related pulmonary disease. Semin Respir Crit Care Med. 2014;2(35):265–73.
47. Fischer A, du Bois R. Interstitial lung disease in connective tissue disorders. Lancet. 2012;380:689–98.
48. M C, Bansal M, Hartl D. Pulmonary manifestations of rheumatologic diseases. Curr Opin Pediatr. 2017;29(3):311–9.
49. Filocamo G, Torreggiani S, Agostoni C, Esposito S. Lung involvement in childhood onset granulomatosis with polyangiitis. Pediatr Rheumatol. 2017;15(1):28.
50. Calatroni M, Oliva E, Gianfreda D, Gregorini G, Allinovi M, Ramirez GA. ANCA-associated vasculitis in childhood: recent advances. Ital J Pediatr. 2017;43(1):46.

Pulmonary Complications of Obesity

Prateek J. Shukla and Anastassios C. Koumbourlis

Definition of Obesity

Obesity is defined as body weight that is grossly higher than what is considered healthy for a given height, and it is usually the result of the accumulation of excess fats in the body. The body mass index (BMI) is one of the most commonly used methods for the quantification of obesity in clinical practice. The BMI is derived by dividing the body weight (in kg) by the square of the height (in m). The BMI is a screening tool that corresponds with associated risk factors, but it is neither pathognomonic nor predictive by itself. In the adult population, individuals with BMI between 25 and 30 are considered overweight, whereas those with BMI of 30 or higher are considered obese. Obesity can be further subdivided into three categories: class 1 with BMI of 30–35, class 2 with BMI of 35–40, and class 3 with BMI of 40 or higher. Class 3 is often also described as morbid obesity. In children whose body changes normally as they grow, obesity is assessed not on the absolute value of the BMI but on the percentile to which a given BMI belongs according to the child's age. Thus, children with BMI for age between 85th and 94th percentile are considered overweight, and those with BMI above the 95th percentile are considered obese. Other methods for quantifying excessive adipose tissue include percentage body fat measurements and skinfold thickness. It should be noted that the body habitus differs between races, and therefore any assessment of normalcy or obesity should be based on reference populations of the same race.

P.J. Shukla, M.D.
Division of Pulmonary and Sleep Medicine, Children's National Health System, School of Medicine and Health Sciences, George Washington University, Washington, DC, USA
e-mail: pshukla@childrensnational.org

A.C. Koumbourlis, M.D., M.P.H. (✉)
Division of Pulmonary and Sleep Medicine, Children's National Medical Center, George Washington University, School of Medicine and Health Sciences, Washington, DC, USA
e-mail: akoumbou@childrensnational.org

© Springer International Publishing AG 2018

A.C. Koumbourlis, M.A. Nevin (eds.), *Pulmonary Complications of Non-Pulmonary Pediatric Disorders*, Respiratory Medicine,
https://doi.org/10.1007/978-3-319-69620-1_12

The Pathophysiology of Obesity

Obesity has been associated with a variety of pathophysiologic conditions (Fig. 1). The exact mechanism(s) of these associations is anything but conclusive, and the available evidence is often contradictory. However, they are all important for the physician to consider when evaluating a patient's symptoms. Following are brief descriptions of the most important associations in which obesity may serve as cause, modifying or exacerbating factor.

Effects of Obesity on Lung Volumes

Measurements of lung volumes in obese patients have consistently shown a decrease in the functional residual capacity (FRC) especially when the subject is in supine position. This decrease is assumed to be the result of the limited diaphragmatic excursion due to accumulation of fat around the thorax and in the abdomen. The decrease in FRC is almost exclusively due to decrease of the expiratory reserve

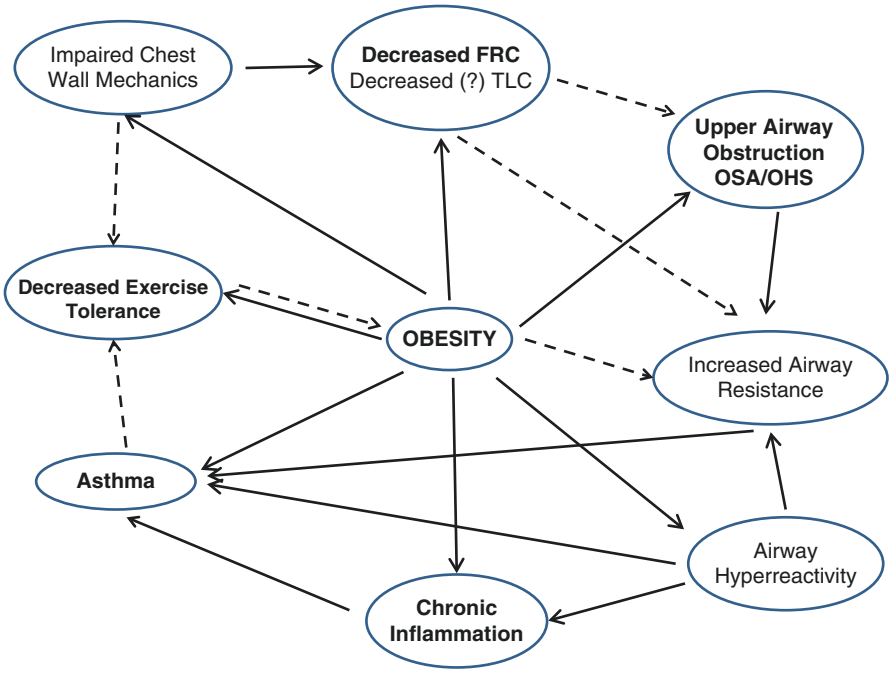

Fig. 1 Schematic diagram depicting the interrelationships between obesity and various pathologic conditions. The *bold lines* represent strong associations between the various entities, whereas the *dashed lines* represent suspected ones

volume (ERV), while the residual volume (RV) remains essentially unchanged. The decrease in FRC is usually accompanied by an increase in the inspiratory capacity (IC), and as a result, the total lung capacity (TLC) and/or the vital capacity (VC) remain relatively stable. Although there is a direct relationship between decreased FRC and BMI, it appears that the critical factor for the decrease in FRC is actually not overall body weight but rather the distribution of the weight and specifically the fat that accumulates in the waist area. It has been shown that a waist circumference of >100 cm is associated with significant decreases in the FVC, FEV_1, and FEV_1/FVC compared with individuals whose waist circumference is <100 cm.

Effects of Obesity on Respiratory System Mechanics

Obesity has been associated with decreased respiratory system compliance. This is in part due to the accumulation of fat around the chest wall that limits its expansion. There are also many other factors that may be implicated in decreased compliance although the evidence is not conclusive. Such factors include the accumulation of fat in the subpleural space that could theoretically limit the space that the lungs have to expand, increased blood flow through the lungs that makes them less compliant, closure of dependent airways and development of atelectasis, and increased alveolar surface tension due to the lower FRC.

In addition to decreased compliance, there is evidence of increased respiratory system resistance (or decreased airway conductance) suggesting an overall narrowing of the airways. The airway resistance is dependent on the lung volumes, and it is at its highest at low lung volumes and at its lowest near TLC. Considering that the FRC in obese individuals is decreased, it is to be expected that the airway resistance will be higher than normal even in the absence of any airway disease. Interestingly some of these findings seem to be gender specific. For example, the decreased airway conductance has been documented in men but not in women suggesting a hormonal effect. However, the exact mechanism is not known.

Effects of Obesity on Airway Function

Upper Airways

Obese patients are at increased risk (estimated to be as high as 400% higher than that among nonobese individuals) of developing significant upper airway obstruction that most commonly manifests itself as obstructive sleep apnea (OSA). The exact mechanism is not completely understood but it appears to be mostly related to the accumulation of fat in the neck and in the abdomen. Increased adipose tissue deposition in the structures surrounding the pharynx (and in particular fat infiltration of the airway walls) may cause significant decrease in the lumen of the

pharynx. In addition, enlargement of lymphoid tissue, as a result of increased basal inflammation, contributes to upper airway obstruction. It should be noted that it is the amount of fat in the cervical area and not the neck circumference that creates the problem (e.g., body builders who have large neck circumference due to muscle growth are not necessarily having OSA compared to somebody with the same neck circumference due to fat accumulation). The accumulation of fat in the abdomen may contribute to the reduction of the tracheal lumen by decreasing the traction that is exerted upon the trachea due to the overall reduction in the lung volumes. When OSA is associated with hypertrophy of the tonsils and adenoids, adenotonsillectomy provides significant relief from obstruction in nonobese individuals. However, in the majority of obese individuals, adenotonsillectomy is not nearly as effective, and as a result noninvasive positive airway pressure may be required.

Lower Airway Function

Obesity per se has surprisingly little effect on the lower airway function as measured by spirometry. The FEV_1 and the FEV_1/FVC ratio tend to be preserved even in morbid obesity. So, in the absence of other underlying pathologies (e.g., asthma, COPD), the lower airway function is within the normal range or suggestive of mild restrictive lung defect (i.e., decrease in the FEV_1 and of the expiratory flow rates that is proportional to the decrease in FVC). However, more recent studies utilizing newer methods of evaluation (such as forced oscillation, single and multiple breath washout, and lung clearance index (LCI)) have provided evidence of peripheral airway obstruction and ventilation heterogeneity that appeared to be independent of the reduced FRC. Different mechanisms have been implicated in the pathogenesis of these findings including cellular damage from chronic exposure to inflammatory agents, such as TNF-α and IL-6 that have been associated with obesity, as well as due to lipid deposition in the airways. Overall, obesity is associated with some changes in the lower airway function whose clinical significance is still debatable.

Effects of Obesity on Gas Exchange

In general, obese individuals have normal or near-normal heterogeneity of ventilation as measured by techniques such as nitrogen washout or LCI. However, imaging studies have shown that the distribution of ventilation is different among obese individuals compared with healthy nonobese subjects. Specifically in healthy individuals, most of the ventilation is directed in the lower zones of the lungs where most of the perfusion occurs. In contrast, in obese individuals, the majority of the ventilation is directed toward the upper lung zones, whereas the perfusion remains in the lower zones, thus creating ventilation-perfusion mismatch and mild hypoxemia but not hypercapnia. The diffusing capacity is generally normal, and sometimes it may even be increased because of increased blood volume in the lungs.

Effects of Obesity on Airway Reactivity

There is evidence (primarily from animal studies) that obesity is associated with airway hyperreactivity (AHR) that is assumed to be due to chronic low-grade systemic inflammation. In animal models of obesity, decreases in FRC are noticeable even with modest increases in weight. In contrast, increases in AHR (evidenced by increased hyperresponsiveness to methacholine) require increase in the weight of more than 45% of the physiologic. Studies in humans have yielded conflicting evidence. While some studies have shown increased AHR among obese patients (with the strongest association seen in patients with severe AHR), other studies have failed to show association between obesity and AHR despite respiratory symptoms consistent with AHR (e.g., wheezing). Similarly, there is an unclear association between obesity and exercise-induced bronchospasm due to the confounding factors of deconditioning and increased metabolic requirements. Furthermore, some studies have shown a significant association between body fat and AHR but only among obese adult men, whereas others have shown similar associations but in women only. There seems to be no association between BMI and AHR among children and young adults.

Effects of Obesity on Exercise Tolerance

Exercise tolerance is generally decreased among obese patients. The causes are inconclusive but they seem to depend mostly on the following:

(a) *Increased oxygen consumption (VO_2)*: In healthy nonobese individuals, the work of breathing at rest requires only a small fraction (approximately 3%) of the total oxygen consumption. The work of breathing is much higher among obese patients (approximately 70% higher than the physiologic), and the required oxygen consumption can be more than four times higher than the physiologic. This means that obese individuals have very low oxygen reserves and therefore are bound to have exercise intolerance.
(b) *Cardiovascular dysfunction*: There is evidence that obese individuals develop left ventricular dysfunction that may become a limiting factor to exercise.
(c) *Physical deconditioning*: This is probably the most common cause of exercise limitation even among otherwise healthy individuals. Obese individuals tend to live very sedentary lives, and as a result, they become deconditioned.

Effects on Cardiovascular Function

Obese patients tend to live in a hyperdynamic and hypervolemic state that results in a selective hypertrophy of the left ventricle and some degree of left ventricular dysfunction. They are also at increased risk for coronary artery disease. Furthermore obese

patients are having increased pulmonary blood volume presumably due to the recruitment of underperfused capillaries that may contribute to the development of pulmonary hypertension, right ventricular hypertrophy, and possibly right heart failure.

Obesity and Dyspnea

Dyspnea (especially on exertion) tends to be a common manifestation of obesity, but its causes are not very clear. Obese subjects have higher oxygen consumption than nonobese subjects both at rest and at any level of exercise. They are generally able to increase their ventilation sufficiently, so they do not become hypercapneic. However, this increases the work of breathing (especially considering that both the chest wall and the diaphragm are at a mechanical disadvantage due to the accumulation of fat), thus creating a vicious cycle of ever-increasing metabolic demands.

Obesity and Asthma

There is a significant body of literature that shows significant associations between obesity and asthma. Many of the patients with severe asthma tend to be obese and/or have symptoms that are difficult to control. Despite the large body of research, these findings often tend to be controversial. For example, there is no proven association between BMI and AHR among children and young adults. Such association does exist among older adults but only among men and not among women. Younger obese patients with asthma tend to have increased allergic inflammatory markers. In other words, obese patients with asthma do not constitute a homogeneous population, and in fact there are several different phenotypes that have been identified that are briefly summarized below:

The first phenotype refers to patients whose asthma is supposed to be caused by their obesity. Such patients tend to have late-onset asthma that is not associated with increased allergic and inflammatory mediators. Its exact pathogenic mechanism is not known. One mechanism that has been implicated is related to the decrease in FRC that is commonly seen in obese patients. It has been shown that airway hyperreactivity increases when a subject (even healthy ones) breathes at low lung volume. Other potential mechanisms involve alterations in the airway structure (thickness of the alveolar wall) and function caused by increased oxidative stress, impairment of the metabolism of nitric oxide, alterations in the production of certain cytokines, aging, and even alterations in the neuronal control as a result of dietary manipulations such as high-fructose diet.

The second phenotype refers to obese patients who have early onset of asthma that is associated with high IgE and other inflammatory markers. Such patients have a much higher risk for hospital admissions and even higher risk for admission in the ICU. Their symptoms tend to improve with weight loss although the severity of airway hyperreactivity remains unchanged. The specific pathogenic mechanism of

this asthma phenotype appears to be associated with the typical for allergic asthma, elevation of the markers of Th2 inflammation but with more severe manifestations among obese patients compared with the nonobese. Despite its otherwise allergic features, this phenotype is associated with very low levels of eosinophils in the sputum or in the bronchoalveolar lavage fluid. Instead, these patients seem to have very elevated number of eosinophils in the airway wall that may alter its cellular structure. In addition there is evidence of altered cellular metabolism that may contribute to the development of obesity but also in alterations in the body's immune function that may predispose to the development of asthma.

A third phenotype of obese asthma has been recently proposed that is associated with exposures to irritants and pollutants. There is evidence that obese children are much more susceptible to indoor pollutants as well as to outdoor pollutants such as ozone. Although the exact pathogenic mechanism is not known, there is evidence that it may be associated with activation of the NF-κB as well as other inflammatory mediators such as the IL-1β.

Obesity and Endocrine Homeostasis

Increase in adipose tissue results in changes in endocrine homeostasis due to the release of inflammatory mediators such as tumor necrosis factor alpha (TNF-α), leptin, and IL-6 and a decrease in circulating adiponectin. Released by macrophages and adipocytes, these mediators contribute to a pro-inflammatory environment. The most important of these mediators are the following:

Leptin

Leptin is a hormone that normally acts to suppress appetite and stimulate metabolic processes through the hypothalamic axis. Through this function, it regulates energy balance and fat stores within the body. Leptin stimulates a Th1 cytokine response which increases pro-inflammatory cytokines. Circulating blood levels of this protein vary exponentially with fat mass with levels demonstrating circadian properties, being higher overnight. Increased production is primarily thought to be related to an increase in adipose tissue in obesity. Despite increased levels in obesity, there is a decrease in metabolic processes which suggests that there may be an element of leptin resistance.

Interleukin-6

Interleukin-6 acts as a pro-inflammatory cytokine seen at increased levels in obesity. While there have been multiple studies identifying increased levels of IL-6 association with being overweight, it remains unclear how these are directly related. Increased levels of IL-6 suppress adiponectin and increase levels of CRP leading to inflammation within the airways.

Tumor Necrosis Factor Alpha

The NF-κB pathway induces inflammation through activation of cytokines within airway epithelium. TNF-α activates the NF-κB pathway as seen at increased levels in obese individuals.

Adiponectin

Adiponectin is a protein associated with weight loss that also inhibits proliferation of cultured smooth muscle. Through inhibition of NF-κB, IL-6, and TNF-α and upregulation of IL-10 and IL-1 receptor antagonists, it exhibits anti-inflammatory effects. Relative reduction in adiponectin has been associated with increased inflammation. Lower levels of this protein have been observed in obese vs nonobese individuals.

Ghrelin

Produced by ghrelinergic cells in the gastrointestinal tract, ghrelin is a gastric hormone that increases appetite and decreases fat utilization. Commonly referred to as the "hunger hormone," it has anti-inflammatory properties through inhibition of IL-1β, IL-6, and TNF-α. It decreases the inflammation induced by leptin.

Obesity and Control of Breathing

The obesity hypoventilation syndrome (OHS) (also known as Pickwickian syndrome) refers to the combination of obesity and arterial hypercapnia while awake in the absence of other causes of hypoventilation. This syndrome is associated with morbid obesity, and it is rarely seen in children. Excessive strains on the body seen in morbid obesity lead to muscular exhaustion that result in chronic hypoxia, hypercapnia, and blunting of chemoreceptor response to changes in their dissolved balance. The clinical symptoms of OHS resemble those of obstructive sleep apnea, consisting of chronic fatigue, daytime somnolence, and headaches.

Obesity and the Metabolic Syndrome

The metabolic syndrome refers to a combination of various seemingly unrelated conditions including insulin resistance, glucose intolerance, dyslipidemia, hypertension, and obesity. Insulin resistance and especially obesity have been associated with the development and/or poor control of asthma. Studies in animal models of

metabolic syndrome have shown that the metabolic syndrome is associated with increased airway resistance, AHR, and decreased levels of exhaled nitric oxide. These effects (especially lung resistance and lung elastance) are magnified when metabolic syndrome is associated with obesity.

Surgical and Intensive Care Considerations

There is increased morbidity associated with obesity in the perioperative period. Both endocrine abnormalities and anatomical abnormalities increase risk of surgical complications during procedures. Alterations in metabolism of anesthetic agents can add complexity in providing appropriate anesthesia. Postoperative courses are also complicated by increased risk of airway obstruction as noted above. Prior investigation in the form of pulmonary function testing and polysomnography can help to identify individuals at risk as demonstrated by baseline abnormalities in each modality.

Obesity may also affect the course of the illness and the overall prognosis in patients hospitalized with acute lung injury (ALI). Data from adult populations show that mortality among obese patients with ALI is similar to that of nonobese patients. However, obese patients require more prolonged ventilatory support, they have longer length of stay in the ICU and the hospital, and they are more likely to require post-hospital care in rehabilitation units.

Bibliography

1. Reznik M, Hailpern SM, Ozuah PO. Predictors of early hospital readmission for asthma among inner-city children. J Asthma. 2006;43:37–40.
2. Guerra S, Wright AL, Morgan WJ, Sherrill DL, Holberg CJ, Martinez FD. Persistence of asthma symptoms during adolescence: role of obesity and age at the onset of puberty. Am J Respir Crit Care Med. 2004;170:78–85.
3. Castro-Rodriguez JA, Holberg CJ, Morgan WJ, Wright AL, Martinez FD. Increased incidence of asthmalike symptoms in girls who become overweight or obese during the school years. Am J Respir Crit Care Med. 2001;163:1344–9.
4. Wang LY, Cerny FJ, Kufel TJ, Grant BJ. Simulated obesity-related changes in lung volume increases airway responsiveness in lean, nonasthmatic subjects. Chest. 2006;130:834–40.
5. Papoutsakis C, Priftis KN, Drakouli M, Prifti S, Konstantaki E, Chondronikola M, et al. Childhood overweight/obesity and asthma: is there a link? A systematic review of recent epidemiologic evidence. J Acad Nutr Diet. 2013;113(1):77–105.
6. Visness CM, London SJ, Daniels JL, Kaufman JS, Yeatts KB, Siega-Riz AM, et al. Association of childhood obesity with atopic and nonatopic asthma: results from the national health and nutrition examination survey 1999-2006. J Asthma. 2010;47:822–9.
7. Shore SA. Obesity, airway hyperresponsiveness, and inflammation. J Appl Physiol (1985). 2010;108:735–43.
8. Gruchala-Niedoszytko M, Malgorzewicz S, Niedoszytko M, Gnacinska M, Jassem E. The influence of obesity on inflammation and clinical symptoms in asthma. Adv Med Sci. 2013;58(1):15–21.

9. Chinn S, Jarvis D, Burney P. Relation of bronchial responsiveness to body mass index in the ecrhs. European community respiratory health survey. Thorax. 2002;57:1028–33.
10. Schachter LM, Salome CM, Peat JK, Woolcock AJ. Obesity is a risk for asthma and wheeze but not airway hyperresponsiveness. Thorax. 2001;56:4–8.
11. Ciprandi G, Pistorio A, Tosca M, Ferraro MR, Cirillo I. Body mass index, respiratory function and bronchial hyperreactivity in allergic rhinitis and asthma. Respir Med. 2009;103:289–95.
12. McLachlan CR, Poulton R, Car G, Cowan J, Filsell S, Greene JM, et al. Adiposity, asthma, and airway inflammation. J Allergy Clin Immunol. 2007;119(3):634–9.
13. Kershaw EE, Flier JS. Adipose tissue as an endocrine organ. J Clin Endocrinol Metab. 2004;89(6):2548–56.
14. Tzanavari T, Giannogonas P, Karalis KP. Tnf-alpha and obesity. Curr Dir Autoimmun. 2010;11:145–56.
15. Valle M, Martos R, Gascon F, Canete R, Zafra MA, Morales R. Low-grade systemic inflammation, hypoadiponectinemia and a high concentration of leptin are present in very young obese children, and correlate with metabolic syndrome. Diabetes Metab. 2005;31:55–62.
16. Arens R, Sin S, Nandalike K, Rieder J, Khan UI, Freeman K, et al. Upper airway structure and body fat composition in obese children with obstructive sleep apnea syndrome. Am J Respir Crit Care Med. 2011;183:782–7.
17. Nafiu OO, Reynolds PI, Bamgbade OA, Tremper KK, Welch K, Kasa-Vubu JZ. Childhood body mass index and perioperative complications. Paediatr Anaesth. 2007;17(5):426–30.
18. Tait AR, Voepel-Lewis T, Burke C, Kostrzewa A, Lewis I. Incidence and risk factors for perioperative adverse respiratory events in children who are obese. Anesthesiology. 2008;108:375–80.
19. Parameswaran K, Todd DC, Soth M. Altered respiratory physiology in obesity. Can Respir J. 2006;13(4):203–10.
20. AE M, Stapleton RD, Rubenfeld GD, Hudson LD, Caldwell E, Steinberg KP. The association between body mass index and clinical outcomes in acute lung injury. Chest. 2007;131(2):342–8.
21. Desai D, Newby C, Symon FA, Haldar P, Shah S, Gupta S, et al. Elevated sputum interleukin-5 and submucosal eosinophilia in obese individuals with severe asthma. Am J Respir Crit Care Med. 2013;188(6):657–6.
22. Mahadev S, Salome CM, Berend N, King GG. The effect of low lung volume on airway function in obesity. Respir Physiol Neurobiol. 2013;188(2):192–9.
23. Lloyd CM, Saglani S. Eosinophils in the spotlight: finding the link between obesity and asthma. Nat Med. 2013;19(8):976–7.
24. Franco I, Reis R, Ferreira D, Xará S, Ferreira W, Bettencourt N, et al. The impact of neck and abdominal fat accumulation on the pathogenesis of obstructive sleep apnea. Rev Port Pneumol (2006). 2016;22(4):240–2.
25. Dixon AE, Poynter ME. Mechanisms of asthma in obesity. Pleiotropic aspects of obesity produce distinct asthma phenotypes. Am J Respir Cell Mol Biol. 2016;54(5):601–8.
26. Singh VP, Aggarwal R, Singh S, Banik A, Ahmad T, Patnaik BR, et al. Metabolic syndrome is associated with increased oxo-nitrative stress and asthma-like changes in lungs. PLoS One. 2015;10(6):e0129850.
27. Winck AD, Heinzmann-Filho JP, Soares RB, da Silva JS, Woszezenki CT, Zanatta LB. Effects of obesity on lung volume and capacity in children and adolescents: a systematic review. Rev Paul Pediatr. 2016;34(4):510–7.
28. Dixon AE, Holguin F, Sood A, Salome CM, Pratley RE, Beuther DA, et al. American Thoracic Society Ad Hoc Subcommittee on Obesity and Lung Disease. An official American Thoracic Society Workshop report: obesity and asthma. Proc Am Thorac Soc. 2010;7(5):325–35.
29. Mahadev S, Farah CS, King GG, Salome CM. Obesity, expiratory flow limitation and asthma symptoms. Pulm Pharmacol Ther. 2013;26(4):438–43.
30. Deesomchok A, Fisher T, Webb KA, Ora J, Lam YM, Lougheed MD, et al. Effects of obesity on perceptual and mechanical responses to bronchoconstriction in asthma. Am J Respir Crit Care Med. 2010;181(2):125–33.
31. Salome CM, King GG, Berend N. Physiology of obesity and effects on lung function. J Appl Physiol (1985). 2010;108(1):206–11.

Pulmonary Complications of Heterotaxy Syndromes

Thomas G. Saba and Adam J. Shapiro

Introduction

Cilia are evolutionarily conserved hair-like organelles on the surface of cells that facilitate interactions of cells with their environments. The various functions of cilia, including cell locomotion, fluid movement, signaling, and sensation of the extracellular environment, play important roles in organ development and function. The rapidly expanding understanding of ciliary structure, functional roles, and genetics has led to the discovery of several congenital disorders linked to cilia, including primary ciliary dyskinesia (PCD), a disease of chronic oto-sinopulmonary infections, and heterotaxy syndrome, a disorder of internal organ placement defects. While these disorders result from dysfunction of different types of human cilia, their clinical overlap supports an integrated model of human cilia that can cause a vast array of overlapping diseases known as ciliopathies. In this chapter, we will review the basic structure and function of cilia and explore how ciliopathies lead to clinical diseases, with a specific focus on primary ciliary dyskinesia and heterotaxy syndrome.

T.G. Saba, M.D. (✉)
Division of Pediatric Pulmonology, University of Michigan, Ann Arbor, MI, USA
e-mail: tsaba@med.umich.edu

A.J. Shapiro, M.D.
Pediatric Respiratory Medicine, Montréal Children's Hospital, McGill University Health Centre Research Institute, Montréal, QC, Canada
e-mail: adam.shapiro@muhc.mcgill.ca

© Springer International Publishing AG 2018

A.C. Koumbourlis, M.A. Nevin (eds.), *Pulmonary Complications of Non-Pulmonary Pediatric Disorders*, Respiratory Medicine,
https://doi.org/10.1007/978-3-319-69620-1_13

Ciliary Physiology

Cilia are membrane-bound, centriole-derived, microtubule-containing projections from the cell surface [1–3]. The basic axonemal structure is highly conserved from primitive to higher organisms, which has permitted the study of ciliary structure, function, and genetics using primitive models [4]. Cilia are expressed on almost every cell type in the human body, and they exert various tissue-specific functions during development, tissue morphogenesis, and homeostasis. The basic structure of a cilium involves microtubules formed by αβ tubulin heterodimers projecting from a basal body and surrounded by a ciliary membrane. Outer and inner dynein arms are ATPase motors attached to the microtubules, which facilitate sliding relative to each other and provide the driving force for ciliary movement. Radial spokes regulate dynein arm activity, sending signals from the central apparatus to the dynein arms. Nexin links connect two adjacent microtubular doublets, limiting sliding between microtubules (Fig. 1).

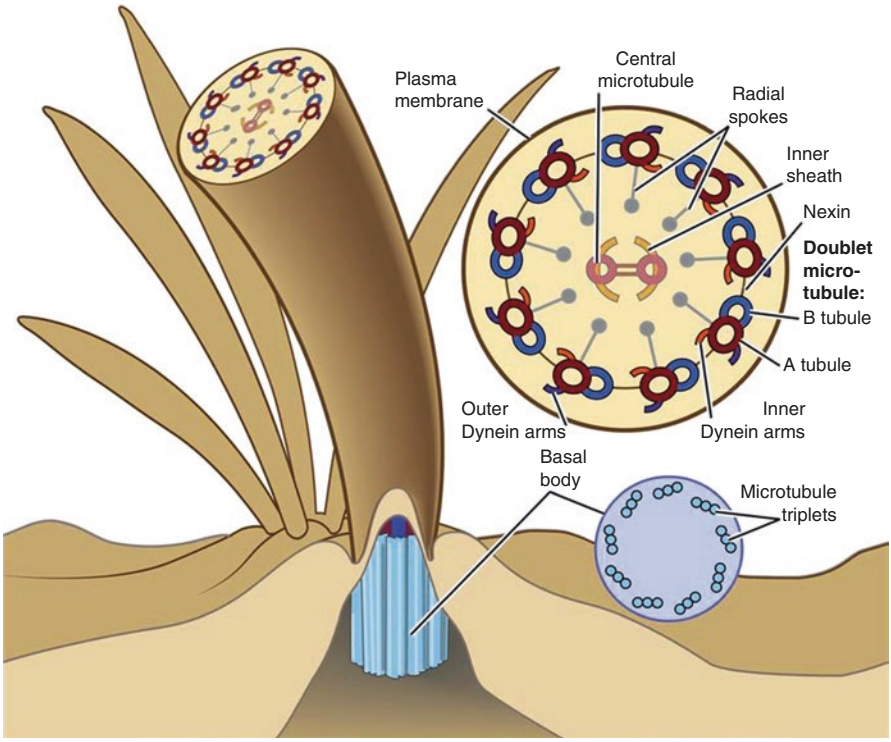

Fig. 1 Ciliary ultrastructure. Reprinted from Knowles et al. [44] with permission of the American Thoracic Society. Copyright© 2016 American Thoracic Society. The American Journal of Respiratory and Critical Care Medicine is an official journal of the American Thoracic Society

In mammals, cilia adhere to two major patterns observed under electron microscopy: "9 + 2", in which 9 microtubule pairs surround a central microtubule pair, and "9 + 0", in which there is no central microtubule pair or radial spokes. Cilia can be motile or immotile. Motile cilia work via coordinated beating to generate fluid movement. Motile 9 + 2 cilia exist in the airways, brain, and reproductive tract, and they are responsible for transporting extracellular fluid along the epithelial surface. Motile 9 + 2 cilia move in a synchronous planar waveform with a forward effective stroke followed by a return stroke at about 8–12 Hz. A mature ciliated airway epithelial cell has approximately 200 uniform motile cilia attached to its surface. Motile 9 + 0 cilia, lacking a central doublet and radial spokes, are found in the embryonic node and move in a rotational pattern that directs leftward flow of extracellular fluid, thereby establishing the left-right (L-R) axis and asymmetric organ placement (Fig. 2).

Non-motile cilia are sensory organelles that act as "antennae" sampling the extracellular environment and transmitting signals to the cell interior. Non-motile cilia lack dynein arms, radial spokes, and a central pair and are located in the inner ear, kidney tubular epithelia, bile duct epithelia, pancreatic ducts, bones, and eyes. With such extensive involvement in different tissues and at different stages of development, a genetic defect in one of the hundreds of complex ciliary structural proteins can have significant consequences for appropriate tissue development and function [5, 6].

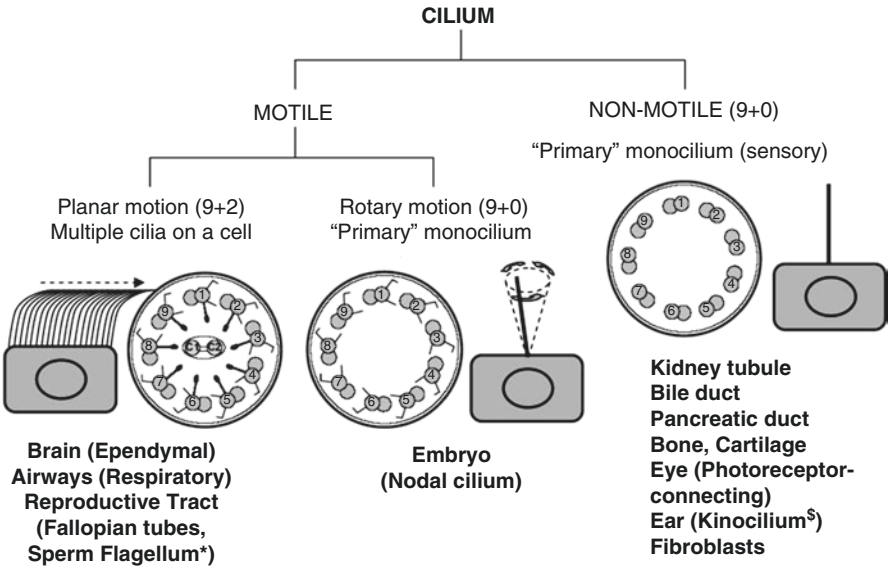

Fig. 2 Ciliary structure and function in different organs. Reprinted from Leigh et al. [106] with permission of Nature Publishing Group

Primary Ciliary Dyskinesia

Primary ciliary dyskinesia is an autosomal recessive disorder caused by mutations in genes encoding ciliary structural proteins as well as cytoplasmic and regulatory proteins forming motile respiratory cilia [7]. Rare autosomal dominant [8] and X-linked [9, 10] cases have been reported. PCD has an estimated prevalence of 1:15,000 to 1:30,000 live births, although these numbers are based on population studies of laterality defects and bronchiectasis, which likely underestimate the true disease prevalence [11, 12]. Less than 1000 patients have a well-established PCD diagnosis in the United States, although this number is expected to increase significantly over the next several years with the establishment of greater PCD awareness and improved diagnostic testing.

Approximately 50% of PCD patients have organ laterality defects, with the majority of these displaying situs inversus totalis (complete mirror image organ arrangement). However, recent studies have also linked PCD to other disorders of organ laterality, including heterotaxy syndrome. In PCD, ineffective mucociliary clearance leads to chronic otitis media with effusions, chronic pansinusitis, and recurrent lower respiratory tract infections. Nearly 100% of patients with classic PCD have daily, year-round wet cough and daily, year-round nasal congestion, often starting at birth. Bronchiectasis is universal in PCD adults and occurs in at least 50–80% of children [13–15]. Greater than 90% of PCD patients have chronic otitis media [13, 15] although some studies report a lower prevalence in adulthood [16]. Nearly 80% of children have abnormal hearing at age 3 [17]. In adults with PCD, dysmotility of spermatozoa and the fimbriae within fallopian tubes lead to near universal infertility in men and reduced fertility with increased risk for ectopic pregnancy in women [18, 19]. The majority of pediatric patients with PCD (>80%) have a history of neonatal respiratory distress despite term birth. Interestingly, the prevalence of neonatal respiratory distress seems to be lower among patients who were diagnosed for PCD in adulthood. It is unclear whether this represents a different phenotype or simply poor recollection [15]. The presentation in the newborn period is variable and ranges from need for oxygen supplementation that may last from days to weeks to respiratory failure with intubation and mechanical ventilation. Newborns with PCD are often misdiagnosed with transient tachypnea of the newborn, neonatal pneumonia, or meconium aspiration. Retrospectively, patients diagnosed with PCD had longer need for supplemental oxygen therapy (usually >48 h), later onset of neonatal respiratory distress (median 12 h of life), and a significantly higher frequency of lobar collapse on chest X-ray as compared to otherwise healthy newborns who required chest X-rays for neonatal respiratory issues [20]. This neonatal presentation implies that cilia play an important role in the clearance of fetal lung fluid and the transition to an air-filled lung.

With the establishment of the Genetic Disorders of Mucociliary Clearance Consortium [21], an international PCD registry [22], and the PCD Foundation in North America and the BESTCILIA group in Europe, clinical features and patterns of PCD have been recognized and are being used to identify patients needing con-

firmatory PCD testing. Four clinical features in children, including (1) organ laterality defects; (2) unexplained neonatal respiratory distress at term birth; (3) early-onset, year-round nasal congestion; and (4) early-onset, year-round wet cough, are predictive of PCD with a sensitivity and specificity of 0.21 and 0.99 with all four clinical features, 0.50 and 0.96 with three clinical features, and 0.80 and 0.72 with two clinical features, respectively [23]. Early onset is defined as symptoms appearing before 6 months of age, but most symptoms are present from birth.

Lung function in PCD is impaired, although among patients treated for PCD with aggressive airway clearance and antibiotics, some studies suggest stable forced expiratory volume in 1 s (FEV_1) over time [24, 25]. However, other studies demonstrate a progressive decline in FEV_1 in one-third of treated PCD patients [13, 26, 27]. Common bacterial sputum pathogens among PCD patients include *Haemophilus influenzae*, *Staphylococcus aureus*, *Streptococcus pneumoniae*, and *Moraxella catarrhalis*. *Pseudomonas aeruginosa*, including the mucoid variety, shows increasing prevalence with age and is present in nearly 44% of adult and 9–20% of pediatric patients. Lung function, measured by FEV_1, is lower among adults colonized with *P. aeruginosa* [27]. Nontuberculous mycobacteria is present in 3–18% of adult sputum cultures and in 3% of pediatric cultures [13, 15, 27, 28].

Diagnosing Primary Ciliary Dyskinesia

The diagnosis of PCD requires a combination of an appropriate clinical phenotype [23] and additional tests to assess ciliary structure and function. The heterogeneity of ciliary structure and function precludes the ability of any single test to capture all disease-causing ciliary defects. North American and European recommendations exist to standardize testing, diagnosis, and management of PCD [21, 29]. Evaluation of ciliary ultrastructure by electron microscopy (EM) identifies patients with defects of the outer dynein arms (ODA), outer and inner dynein arms (IDA), inner dynein arms with microtubule disorganization, radial spokes, or central apparatus (CA). However, the sensitivity is estimated at 70%, as many PCD-causing genetic mutations have completely normal ciliary ultrastructure or only mild defects that are not easily recognizable on EM [30]. Furthermore, the processing of ciliary biopsies for successful EM examination requires a highly experienced pathology laboratory, and interpretation of more subtle ciliary ultrastructural defects requires the expertise of an experienced EM pathologist [31]. The specificity of EM is compromised by identification of isolated inner dynein arm defects that resolve on repeat EM examinations and by viral-induced secondary ciliary defects being misinterpreted as primary abnormalities [32]. Approximately 20% of EM diagnosed PCD cases are false positive diagnoses when repeat EM studies are performed in specialized PCD clinical centers [33].

Nasal nitric oxide (nNO) measurement is a highly sensitive, specific, and noninvasive diagnostic test for classic PCD in patients older than 5 years of age, who can comply with velum closure maneuvers. Nitric oxide is produced by numerous cell

types and is likely involved in modulating ciliary beat, although its true effects on motile respiratory cilia are unknown. For unclear reasons, nNO is extremely low in people with PCD. Several hypotheses exist to explain this finding, including increased breakdown, reduced biosynthesis, trapping of nNO in obstructed paranasal sinuses, and reduced production/storage capacity in the paranasal sinuses [34], but none are proven. In a patient >5 years old, who is highly suspected of having PCD, a nNO level less than 77 nL/min, measured with a chemiluminescence nitric oxide analyzer, carries a sensitivity and specificity of 0.98 and 0.99, provided other disorders known to lower nNO, such as cystic fibrosis, have been ruled out [35, 36]. Tidal breathing techniques to measure nNO in children less than 5 years old, who cannot complete a velum closure maneuver, are currently under investigation.

A functional ciliary assessment of ciliary waveform analysis on high-speed videomicroscopy can provide confirmation of PCD, but this technique requires considerable skill and experience to perform correctly [37]. This test is successfully used in some highly specialized European PCD centers. Immunofluorescence testing for missing ciliary proteins can also detect some dynein arm and radial spoke defects, but the sensitivity and specificity are not greater than EM testing. Ciliary waveform analysis and immunofluorescence testing are mostly used for research purposes and play a limited role in the clinical diagnosis of PCD in North America. Other tests including nasal saccharin testing, radioaerosol mucociliary clearance tests, ciliary beat frequency alone, or ciliary waveform analysis without high-speed videomicroscopy can provide insight into ciliary function but are not accepted as diagnostic tests for PCD [21].

It is estimated that over 70% of PCD patients have biallelic mutations in one of the 36 genes known to be associated with PCD [7, 38] (Tables 1 and 2). To date, all confirmed cases of PCD have biallelic mutations in the same PCD gene, and there are no cases of digenic mutations (one mutation in each of two different PCD-causing genes) resulting in PCD. The first two PCD-associated genes identified were *DNAI1* [39] and *DNAH5* [40], both components of outer dynein arms. Candidate gene analysis in animal models further identified additional dynein arm defects, including *Dnahc5*, *Dnahc11*, and *Dnaic1*, which are murine homologues of human *DNAH5*, *DNAH11*, and *DNAI1*, respectively [41–43]. The genes currently implicated in PCD are usually classified according to the pattern of ultrastructural defects they cause, including defects of the outer dynein arm, outer and inner dynein arm, inner dynein arm with central apparatus/microtubule disorganization, nexin links/dynein regulatory complex, and central apparatus/radial spokes. Genes encoding proteins involved in formation of the central apparatus and radial spokes have not been associated with laterality defects or congenital heart disease since they do not contribute to the normal structure and function of embryonic nodal cilia [44]. Mutations in some genes encoding nexin-dynein regulatory complex (N-DRC) proteins, which bind to the IDA, cause laterality defects in humans (*CCDC39*, *CCDC40* [13], *GAS8* [45, 46]) while other N-DRC genes (*CCDC164* [47], *CCDC65* [48, 49]) do not.

As more PCD-causing genetic defects are discovered, genotype-phenotype correlations are beginning to be recognized. In one study of 118 children with PCD,

Table 1 Genes associated with PCD and laterality defects in humans

Gene	EM ciliary ultrastructure defect	Association with CHD in humans
DNAH5 [55, 107, 108]	ODA	Yes [55]
DNAI1 [55, 107, 108]	ODA	Yes [55]
DNAI2 [108]	ODA	No
DNAL1 [108, 109]	ODA	No
CCDC114 [110, 111]	ODA	Yes [111]
CCDC151 [112]	ODA	Yes
TXNDC3(NME8) [108, 113]	ODA	No
ARMC4 [114, 115]	ODA	In mouse orthologs
TTC25 [116]	ODA	No [116]
DNAAF1 (LRRC50) [108]	ODA + IDA	No
DNAAF2 (KTU) [52, 108]	ODA + IDA	Yes [52]
DNAAF3 [117]	ODA + IDA	No
C21orf59 [118]	ODA + IDA	No
CCDC103 [119]	ODA + IDA	No
HEATR2 (DNAAF5) [120]	ODA + IDA	Yes [120]
LRCC6 [121, 122]	ODA + IDA	No
DYX1C1 [52, 123]	ODA + IDA	Yes [52, 123]
ZMYND10 [124, 125]	ODA + IDA	No
SPAG1 [126]	ODA + IDA	No
CCDC39 [13, 108, 127]	IDA defect + axonemal disorganization	Yes
CCDC40 [13, 52, 108, 127, 128]	IDA defect + axonemal disorganization	Yes [52]
DNAH11 [30, 52, 108]	Normal	Yes

Adapted from Shapiro et al. [129]

subjects with inner dynein arm and central apparatus/microtubule disorganization defects (IDA + CA/MTD) had lower FEV_1 and body mass index values, with worse bronchiectasis, as compared to PCD patients with other dynein arm defects. Most of the patients with IDA + CA/MTD defects had biallelic mutations in coiled-coil domain-containing proteins encoded by *CCDC39* and *CCDC40* [13]. Conversely, individuals with mutations in *RSPH1*, encoding a radial spoke head protein, have an overall milder PCD phenotype compared to PCD patients with other genetic defects. These differences include higher nNO levels, lower prevalence of neonatal respiratory distress, later onset of daily wet cough, and higher FEV_1 values [50].

Treatment of patients with PCD involves aggressive daily chest physiotherapy, judicious use of antibiotics, inhaled hyperosmolar agents as appropriate, management of chronic otitis and rhinosinusitis, and attention to additional comorbidities, such as infertility. Some therapeutic agents, used in patients with CF and idiopathic bronchiectasis, are also used with anecdotal success in PCD, and clinical trials testing the efficacy and safety of several agents are ongoing in PCD populations [21, 29, 51] (https://clinicaltrials.gov/ct2/show/NCT02871778).

Table 2 Genes associated with PCD but not with laterality defects in humans

Gene	EM ciliary ultrastructure defect	Association with CHD in humans
DNAH8 [130]	Not available	No
GAS8 (DRC4) [45, 46]	IDA defect + axonemal disorganization	No
RSPH4A [108, 131–135]	Mostly normal, CA defects in small proportion of cilia	No
RSPH9 [108, 131, 135, 136]	Mostly normal, CA defects in small proportion of cilia	No
RSPH1 [50, 134, 137]	Mostly normal, CA defects in small proportion of cilia	No
RSPH3 [138]	Mostly normal, CA defects in small proportion of cilia	No
HYDIN [139]	Normal (very occasional CA defect)	No
RPGR [9, 108]	Mixed	No
OFD1 [10, 108]	No defect in ultrastructure but severely disorganized ciliary beating pattern seen on light microscopy	No
CCDC164 (DRC1) [47, 108]	Nexin (N-DRC) link missing; axonemal disorganization in small proportion of cilia	No
CCDC65 (DRC2) [48, 49, 108]	Nexin (N-DRC) link missing; axonemal disorganization in small proportion of cilia	No
MCIDAS[140]	Oligocilia (residual axoneme normal)	No
CCNO [141]	Oligocilia (residual axoneme normal)	No
DNAJB13 [142]	CA defects in 1/3 of cilia	No

Adapted from Shapiro et al. [129]

Heterotaxy Syndrome

Heterotaxy syndrome is an abnormal arrangement of thoracic and abdominal organs from the normal pattern of L-R asymmetry. However, there is some discordance in the literature regarding the nomenclature and categorization of heterotaxy. Historically, classification of laterality defects was based on cardiac atrium position or splenic formation. These approaches have limited the ability to appropriately estimate the population prevalence of laterality defects. In a recent study by Shapiro et al., a simple definition and classification was provided that has been applied in other studies looking at heterotaxy among patients with PCD. The authors divide the laterality defects into three broad categories: situs solitus (SS), situs inversus totalis (SI), Situs ambiguus (SA), and heterotaxy (Fig. 3). Situs inversus totalis involves a total mirror-image arrangement of the organs. Situs ambiguus is defined as any organ laterality defect other than SI, including non-complex cardiovascular malformations (CVM). Heterotaxy is defined as SA with any complex cardiovascular malformation (Table 3) [52, 53].

Approximately 50% of patients with PCD have a laterality defect including SI, SA, and heterotaxy, compared to about 2 per 10,000 in the general population [54].

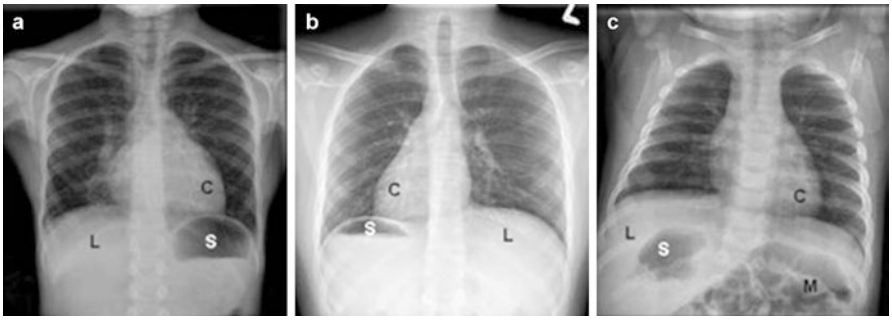

Fig. 3 Images of laterality on chest X-rays. (**a**) situs solitus, (**b**) situs inversus totalis, (**c**) situs ambiguus. *C* cardiac apex, *L* liver, *M* intestinal malrotation, *S* stomach. Reprinted from Shapiro et al. [52] with permission of Elsevier

Table 3 Classification of cardiac and other organ defects among patients with SA

SA + complex CVM (heterotaxy)	SA + simple CVM	SA without cardiac involvement
SA plus any of the following cardiac issues:	SA plus any of the following standard cardiac phenotypes or associations:	SA including any of the following defects:
• Cardiac isomerism	• Dextrocardia	Vascular
• Hypoplastic ventricle with other cardiac lesions (except ASD or APVR alone)	• Mesocardia	• APVR
	• ASD	• Right aortic arch
• L-TGA + LVOTO (PS)	• VSD	• Bilateral or left SVC
• Any defects that do not fit into a standard cardiac phenotype classification or standard associations	• AVSD	• Interrupted or duplicated IVC
	• Common atrium	
	• Tetralogy of Fallot	Abdomen
	• PS or PA	• Asplenia or polysplenia
	• Overriding aorta	
	• DORV	• Intestinal malrotation
	• Ebstein anomaly	
	• Tricuspid atresia	• Midline liver
	• L-TGA, D-TGA	• Left-sided liver
	• Truncus defect	• Right-sided spleen or stomach
	• HPV + VSD or APVR	
		Pulmonary
		• Left- or right-sided pulmonary isomerism

Adapted from Shapiro et al. [52]. Classification based on Botto et al. [53]. *APVR* anomalous pulmonary venous return, *ASD* atrial septal defect, *CVM* cardiovascular malformation, *D-TGA* dextrotransposition of the great arteries, *DORV* double outlet right ventricle, *HPV* hypoplastic ventricle, *IVC* inferior vena cava, *L-TGA* levotransposition of the great arteries, *LVOTO* left ventricular outflow tract obstruction, *PA* pulmonary atresia, *PS* pulmonary stenosis, *SVC* superior vena cava, *VSD* ventricular septal defect

Before the last decade, very little was known about the rate of heterotaxy and congenital heart disease (CHD) among patients with PCD. Kennedy et al. published a retrospective report in 2007 identifying a 6.3% prevalence of heterotaxy, defined broadly as a laterality defect other than SI, among an international cohort of PCD patients. The prevalence of CHD with heterotaxy among PCD patients (1 in 50) was found to be significantly higher than the prevalence of CHD with heterotaxy among non-PCD patients (1 in 10,000), highlighting the important role of cilia in organ laterality and organogenesis [55]. Several years later, Shapiro et al. identified a 12.1% prevalence of situs ambiguus, defined as laterality defects other than SI, and a 41% prevalence of SI, among patients with PCD. Among those with SA, 8 out of 37 had complex cardiovascular malformations (heterotaxy), and 7 out of 37 had simple cardiovascular malformations, not typically classified as heterotaxy. There was no correlation between PCD genetic mutations or EM defects and specific laterality defects [52].

The establishment of L-R asymmetry and organ laterality during vertebrate development involves a complex program of specific gene expression and ciliary function at an organizing L-R coordinator known as the embryonic node [56–59]. Cilia at the node are motile and generate a leftward flow of extraembryonic fluid [60]. The role of motile cilia in this process was initially explained through genetic mutations in *lrd*, which produces a dynein motor protein linked to organ laterality defects in murine models with *inversus viscerum (iv)* [61]. Subsequently, another murine model connected organ laterality defects to primary ciliary dyskinesia through shared mutations in *Dnahc5*, the mouse ortholog of *DNAH5* in humans with PCD. Several additional genes that regulate ciliary formation, maintenance, and function are involved in the creation of L-R asymmetry in the developing embryo [62].

Two theories of embryonic nodal cilia controlling organ placement have emerged. First, differential expression of the ciliary protein, lrd, at the center of the embryonic node and polymyxin-2 at the periphery of the node suggests the existence of two distinct ciliary populations at the node: motile cilia, which generate leftward nodal flow from the center, and peripherally located, non-motile, mechanosensory cilia. Therefore, L-R asymmetry is thought to be a product of both rotational movement of the motile cilia at the center and passive bending of non-motile cilia with calcium ion release at the periphery [63]. This theory helps to explain the existence of laterality defects among patients with non-motile ciliopathies, such as Meckel-Gruber syndrome [64]. The second theory of nodal cilia controlling organ laterality, termed the nodal vesicular parcel model, only involves motile cilia. Researchers postulate that vesicles are transported by nodal flow to the left where their contents, such as sonic hedgehog and retinoic acid, are released and cause calcium-induced downstream signaling events that break symmetry resulting in normal organ placement [65] (Fig. 4).

In addition to genes involved in ciliary structure and function, numerous genes involved in the nodal signaling pathway of L-R asymmetry have been identified in humans and animals [66, 67–82]. One of these first implicated L-R genes was *ZIC3*, an X-linked zinc-finger transcription factor, functioning as a *Nodal* mediator in

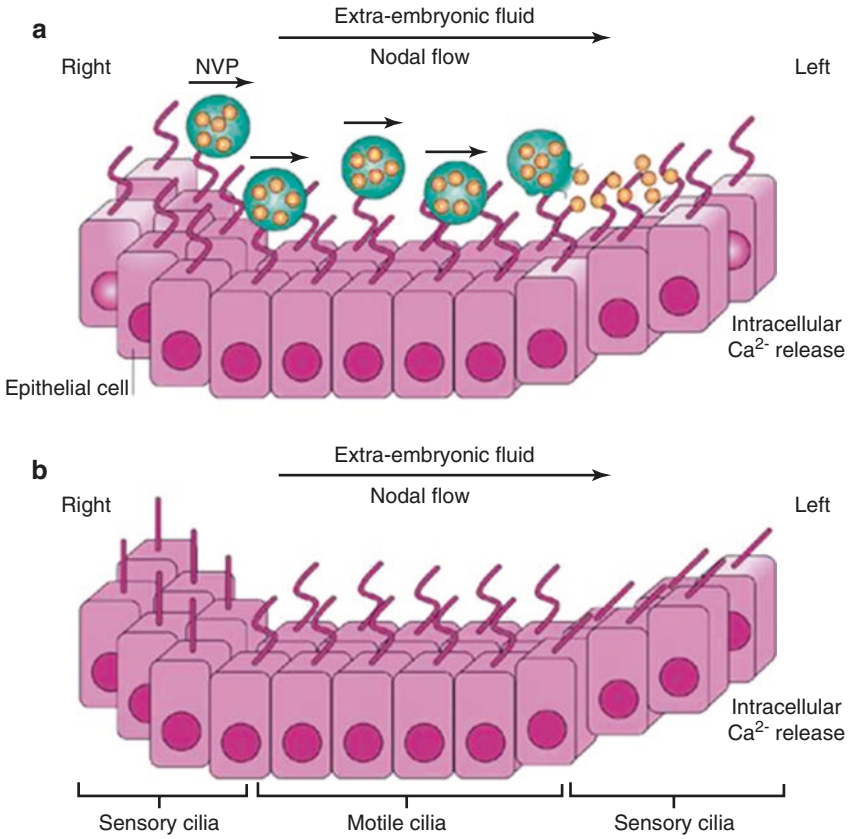

Fig. 4 Model of motile and sensory (non-motile) ciliary involvement in L-R axis determination. In the nodal vesicular parcel (NVP) model (**a**), vesicles filled with sonic hedgehog and retinoic acid are transported from the right to the left side of the embryonic node by nodal flow where they release their contents and induce calcium release. In the two-cilia model (**b**), motile cilia in the center of the node create leftward flow which is sensed by non-motile sensory cilia at the periphery and leads to left-sided calcium release. Reprinted from Fliegauf et al. [57] with permission of Nature Publishing Group

mice and causing heterotaxy in humans [83]. *ZIC3* mutations have not been implicated in PCD. Inheritance mechanisms of heterotaxy are complex, and include X-linked, autosomal recessive, and autosomal dominant modes of inheritance with reduced penetrance and variable expressivity. Naturally, the X-linked form can occur frequently in future progeny and is often tested in clinical cases of heterotaxy syndrome.

Many, but not all of the genes implicated in heterotaxy are involved in ciliary structure and function. Ciliary dysfunction also occurs among patients with isolated congenital cardiac defects, even in the absence of other organ laterality defects [58, 84, 85]. A recent mouse model of atrioventricular septal defects (AVSDs) has shown

that AVSDs are caused by ciliary gene defects affecting either ciliary motility or second heart field (SHF) hedgehog signaling. A large-scale mouse mutagenesis screen among mice with CHD identified 61 mutated genes, including 34 cilia-related genes, 16 genes involved in cilia-transduced cell signaling, and 10 genes regulating vesicular trafficking [86]. Thus, cilia play an active role specifically in cardiac orientation and organogenesis.

Although most patients with disorders of laterality do not have PCD, there is growing evidence that patients with heterotaxy possibly have some form of respiratory cilia dysfunction. In 2011, Swisher et al. found that patients with complex congenital heart disease and heterotaxy had longer postoperative hospital stays, more days on mechanical ventilation, and greater risk for tracheostomy, extracorporeal membrane oxygenation support, or surgical death compared to matched patients with non-heterotaxy congenital heart disease [87]. Additionally, Nakhleh et al. found that 18 of 48 patients with heterotaxy had abnormal ciliary motion on high-speed videomicroscopy. The patients with heterotaxy and abnormal ciliary motion had intermediate nasal nitric oxide levels, yet they were enriched in monoallelic PCD gene variants of the 14 PCD genes tested [88]. Another study among a large group of patients with CHD illustrated a surprisingly high prevalence of ciliary motility defects (33%) and low or borderline nasal nitric oxide levels (32%), regardless of heterotaxy status. However, heterotaxy status was associated with an increased prevalence of both low nasal nitric oxide and abnormal ciliary motion. Patients exhibiting both abnormal ciliary motion and low or borderline nNO had the highest prevalence of respiratory symptoms, yet very few of these subjects were diagnosed with classic PCD [85]. Lastly, a web-based survey of an international heterotaxy patient advocacy group similarly demonstrated a high prevalence (37%) of chronic respiratory symptoms suggestive of PCD [89]. These studies raise awareness of possible respiratory ciliary dysfunction among all heterotaxy patients (even those without classic PCD) and suggest a need for greater screening and intervention in this fragile population. Since the expansion of PCD genetic testing to include over 32 known PCD-causing genes, there has not been a prospective, multi-site protocol examining heterotaxy patients for the true prevalence of classic PCD.

Other Ciliopathy Syndromes

In addition to the cilia-related diseases listed above, motile ciliary dysfunction can lead to other derangements, including hydrocephalus. Hydrocephalus develops in mice with mutations in *Dnahc5* due to poor cerebrospinal fluid (CSF) flow and aqueduct closure (via reduced ependymal ciliary activity) [90]. Although hydrocephalus in mouse models of PCD is common, it is rare among human PCD cases, suggesting additional genetic modifiers influencing CSF flow in humans [91, 92]. Nonetheless, unexplained cerebral ventriculomegaly on prenatal ultrasound

(especially with organ laterality defects) might be an indicator of impaired ciliary function and should trigger consideration of ciliopathies [92, 93].

Bardet-Biedl syndrome, Meckel-Gruber syndrome, Joubert syndrome, autosomal dominant and autosomal recessive polycystic kidney disease, nephronophthisis, retinitis pigmentosa, orofaciodigital syndrome, Ellis-van Creveld syndrome, Jeune syndrome, Alagille syndrome, Alström syndrome, Leber congenital amaurosis, cranioectodermal dysplasia, Senior-Løken syndrome, and Usher syndrome are complex, genetically heterogeneous, non-motile ciliopathy syndromes with overlapping features of multi-organ dysfunction (Table 4). For example, mutations in *CEP290*, normally involved in ciliogenesis and ciliary

Table 4 Non-motile ciliopathy syndromes and associated findings [5, 6, 84, 143]

Syndrome	Clinical manifestation	Respiratory manifestations	Laterality defects
Meckel-Gruber syndrome	Renal fibrocystic disease, polydactyly, intellectual disabilities, CNS anomalies, CHD, cleft lip, cleft palate	No	Yes [64]
Bardet-Biedl syndrome	Obesity, polydactyly, intellectual disability, retinitis pigmentosa, renal anomalies, anosmia, CHD	In animal models [104]	In animal models [144]
Joubert syndrome	CNS anomalies (molar tooth sign), intellectual disabilities, ataxia, retinitis pigmentosa, polydactyly, cleft lip, cleft palate	No	In animal models [145]
ADPKD	Cystic kidney disease, chronic renal failure	Bronchiectasis [98, 99]	Yes[100]
ARPKD	Cystic kidney disease, chronic renal failure, hepatic fibrosis	No	No
Nephronophthisis	Cystic kidney disease, interstitial nephritis, hepatic fibrosis, retinitis pigmentosa	No	Yes [101]
Retinitis pigmentosa	Photophobia, night blindness, progressive blindness	PCD, bronchiectasis, chronic rhinosinusitis [9]	In animal models [146]
Orofaciodigital syndrome type 1	Dysmorphic facies, mental retardation, macrocephaly	PCD [10]	In animal models [147]
Alström syndrome	Obesity, retinitis pigmentosa, diabetes mellitus, hypothyroidism, hypogonadism, skeletal dysplasia	Pulmonary fibrosis, other manifestations [148]	No

ADPKD autosomal dominant polycystic kidney disease, *ARPKD* autosomal recessive polycystic kidney disease

trafficking, are associated with a wide variety of ciliopathy syndromes [94]. Some non-motile ciliopathy syndromes, including Meckel-Gruber syndrome, can present with features more commonly found among motile ciliopathies, such as laterality defects [64], highlighting the redundancy of ciliary building blocks among varying ciliary types as well as the dual responsibility of both motile and non-motile cilia in L-R axis determination. While the possibility of unrecognized PCD in various non-motile ciliopathies is intriguing, this connection remains largely unexplored and limited to only case report level publications.

The pathophysiology of autosomal dominant and autosomal recessive polycystic kidney disease and nephronophthisis occurs via impaired ciliary mechanosensation [57, 95]. Autosomal dominant polycystic kidney disease (ADPKD) is caused by mutations in *PKD1* or *PKD2*, encoding polycystin-1 and polycystin-2, both of which localize to motile and non-motile cilia [96, 97]. Although the role of polycystins in motile respiratory cilia is not known, patients with ADPKD are at increased risk for airway disease, bronchiectasis, and even Kartagener syndrome [98, 99]. Numerous cases of organ laterality defects among patients with ADPKD and nephronophthisis have been reported [100, 101]. Autosomal recessive polycystic kidney disease (ARPKD), caused by mutations in *PKHD1*, has not been associated with pulmonary manifestations or laterality defects in humans.

Diseases of retinal degeneration are associated with defective genes encoding proteins of the photoreceptor sensory cilium [102]. X-linked retinitis pigmentosa, caused by the retinitis pigmentosa guanosine triphosphatase regulator gene (*RPGR*), has been identified as a rare X-linked ciliopathy also resulting in PCD without laterality defects [9]. Cilia in patients with PCD secondary to *RPGR* mutations demonstrate normal beat frequency but impaired orientation and beat coordination [103]. Studies of respiratory cilia in other retinal and non-motile ciliary diseases have resulted in subtle anomalies of respiratory cilia with increased reports of respiratory symptoms, but no confirmed links to classic PCD [104, 105].

Conclusion

Cilia are complex organelles that participate in diverse functions, including mechanical fluid flow, sensation of the extracellular environment, and internal organ placement. When different types of human cilia are dysfunctional, diverse but overlapping syndromes can occur, including PCD and heterotaxy syndrome. A greater understanding of ciliopathy pathophysiology will hopefully inspire ideas for improved patient outcomes, such as the empiric institution of airway clearance among patients with heterotaxy undergoing cardiac surgery, or development of noninvasive, early-life screening modalities for PCD.

References

1. Cardenas-Rodriguez M, Badano JL. Ciliary biology: understanding the cellular and genetic basis of human ciliopathies. Am J Med Genet C Semin Med Genet. 2009;151C(4):263–80.
2. Satir P, Christensen ST. Overview of structure and function of mammalian cilia. Annu Rev Physiol. 2007;69:377–400.
3. Satir P, Pedersen LB, Christensen ST. The primary cilium at a glance. J Cell Sci. 2010;123(Pt 4):499–503.
4. Ostrowski LE, Dutcher SK, Lo CW. Cilia and models for studying structure and function. Proc Am Thorac Soc. 2011;8(5):423–9.
5. Ferkol TW, Leigh MW. Ciliopathies: the central role of cilia in a spectrum of pediatric disorders. J Pediatr. 2012;160(3):366–71.
6. Ware SM, Aygun MG, Hildebrandt F. Spectrum of clinical diseases caused by disorders of primary cilia. Proc Am Thorac Soc. 2011;8(5):444–50.
7. Horani A, Ferkol TW, Dutcher SK, Brody SL. Genetics and biology of primary ciliary dyskinesia. Paediatr Respir Rev. 2016;18:18–24.
8. Narayan D, Krishnan SN, Upender M, Ravikumar TS, Mahoney MJ, Dolan TF Jr, et al. Unusual inheritance of primary ciliary dyskinesia (Kartagener's syndrome). J Med Genet. 1994;31(6):493–6.
9. Moore A, Escudier E, Roger G, Tamalet A, Pelosse B, Marlin S, et al. RPGR is mutated in patients with a complex X linked phenotype combining primary ciliary dyskinesia and retinitis pigmentosa. J Med Genet. 2006;43(4):326–33.
10. Budny B, Chen W, Omran H, Fliegauf M, Tzschach A, Wisniewska M, et al. A novel X-linked recessive mental retardation syndrome comprising macrocephaly and ciliary dysfunction is allelic to oral-facial-digital type I syndrome. Hum Genet. 2006;120(2):171–8.
11. Torgersen J. Situs inversus, asymmetry, and twinning. Am J Hum Genet. 1950;2(4):361–70.
12. Katsuhara K, Kawamoto S, Wakabayashi T, Belsky JL. Situs inversus totalis and Kartagener's syndrome in a Japanese population. Chest. 1972;61(1):56–61.
13. Davis SD, Ferkol TW, Rosenfeld M, Lee HS, Dell SD, Sagel SD, et al. Clinical features of childhood primary ciliary dyskinesia by genotype and ultrastructural phenotype. Am J Respir Crit Care Med. 2015;191(3):316–24.
14. Kennedy MP, Noone PG, Leigh MW, Zariwala MA, Minnix SL, Knowles MR, et al. High-resolution CT of patients with primary ciliary dyskinesia. Am J Roentgenol. 2007;188(5):1232–8.
15. Noone PG, Leigh MW, Sannuti A, Minnix SL, Carson JL, Hazucha M, et al. Primary ciliary dyskinesia: diagnostic and phenotypic features. Am J Respir Crit Care Med. 2004;169(4): 459–67.
16. Pruliere-Escabasse V, Coste A, Chauvin P, Fauroux B, Tamalet A, Garabedian EN, et al. Otologic features in children with primary ciliary dyskinesia. Arch Otolaryngol Head Neck Surg. 2010;136(11):1121–6.
17. Majithia A, Fong J, Hariri M, Harcourt J. Hearing outcomes in children with primary ciliary dyskinesia—a longitudinal study. Int J Pediatr Otorhinolaryngol. 2005;69(8):1061–4.
18. Munro NC, Currie DC, Lindsay KS, Ryder TA, Rutman A, Dewar A, et al. Fertility in men with primary ciliary dyskinesia presenting with respiratory infection. Thorax. 1994;49(7):684–7.
19. Halbert SA, Patton DL, Zarutskie PW, Soules MR. Function and structure of cilia in the fallopian tube of an infertile woman with Kartagener's syndrome. Hum Reprod. 1997;12(1):55–8.
20. Mullowney T, Manson D, Kim R, Stephens D, Shah V, Dell S. Primary ciliary dyskinesia and neonatal respiratory distress. Pediatrics. 2014;134(6):1160–6.
21. Shapiro AJ, Zariwala MA, Ferkol T, Davis SD, Sagel SD, Dell SD, et al. Diagnosis, monitoring, and treatment of primary ciliary dyskinesia: PCD foundation consensus recommendations based on state of the art review. Pediatr Pulmonol. 2016;51(2):115–32.
22. Werner C, Lablans M, Ataian M, Raidt J, Wallmeier J, Grosse-Onnebrink J, et al. An international registry for primary ciliary dyskinesia. Eur Respir J. 2016;47(3):849–59.

23. Leigh MW, Ferkol TW, Davis SD, Lee HS, Rosenfeld M, Dell SD, et al. Clinical features and associated likelihood of primary ciliary dyskinesia in children and adolescents. Ann Am Thorac Soc. 2016;13(8):1305–13.
24. Ellerman A, Bisgaard H. Longitudinal study of lung function in a cohort of primary ciliary dyskinesia. Eur Respir J. 1997;10(10):2376–9.
25. Maglione M, Bush A, Nielsen KG, Hogg C, Montella S, Marthin JK, et al. Multicenter analysis of body mass index, lung function, and sputum microbiology in primary ciliary dyskinesia. Pediatr Pulmonol. 2014;49(12):1243–50.
26. Marthin JK, Petersen N, Skovgaard LT, Nielsen KG. Lung function in patients with primary ciliary dyskinesia: a cross-sectional and 3-decade longitudinal study. Am J Respir Crit Care Med. 2010;181(11):1262–8.
27. Shah A, Shoemark A, MacNeill SJ, Bhaludin B, Rogers A, Bilton D, et al. A longitudinal study characterising a large adult primary ciliary dyskinesia population. Eur Respir J. 2016;48(2):441–50.
28. Alanin MC, Nielsen KG, von Buchwald C, Skov M, Aanaes K, Hoiby N, et al. A longitudinal study of lung bacterial pathogens in patients with primary ciliary dyskinesia. Clin Microbiol Infect. 2015;21(12):1093 e1–7.
29. Strippoli MP, Frischer T, Barbato A, Snijders D, Maurer E, Lucas JS, et al. Management of primary ciliary dyskinesia in European children: recommendations and clinical practice. Eur Respir J. 2012;39(6):1482–91.
30. Knowles MR, Leigh MW, Carson JL, Davis SD, Dell SD, Ferkol TW, et al. Mutations of DNAH11 in patients with primary ciliary dyskinesia with normal ciliary ultrastructure. Thorax. 2012;67(5):433–41.
31. Olin JT, Burns K, Carson JL, Metjian H, Atkinson JJ, Davis SD, et al. Diagnostic yield of nasal scrape biopsies in primary ciliary dyskinesia: a multicenter experience. Pediatr Pulmonol. 2011;46(5):483–8.
32. O'Callaghan C, Rutman A, Williams GM, Hirst RA. Inner dynein arm defects causing primary ciliary dyskinesia: repeat testing required. Eur Respir J. 2011;38(3):603–7.
33. Daniels LA, Leigh MW, Knowles M The diagnostic dilemma of primary ciliary dyskinesia: experience of the GDMCC consortium; In: RDCRN Conference on Clinical Research for Rare Diseases, Bethesda, Maryland; 2010.
34. Walker WT, Jackson CL, Lackie PM, Hogg C, Lucas JS. Nitric oxide in primary ciliary dyskinesia. Eur Respir J. 2012;40(4):1024–32.
35. Leigh MW, Hazucha MJ, Chawla KK, Baker BR, Shapiro AJ, Brown DE, et al. Standardizing nasal nitric oxide measurement as a test for primary ciliary dyskinesia. Ann Am Thorac Soc. 2013;10(6):574–81.
36. Collins SA, Gove K, Walker W, Lucas JS. Nasal nitric oxide screening for primary ciliary dyskinesia: systematic review and meta-analysis. Eur Respir J. 2014;44(6):1589–99.
37. Chilvers MA, Rutman A, O'Callaghan C. Ciliary beat pattern is associated with specific ultrastructural defects in primary ciliary dyskinesia. J Allergy Clin Immunol. 2003;112(3):518–24.
38. Daniels ML, Noone PG. Genetics, diagnosis, and future treatment strategies for primary ciliary dyskinesia. Expert Opin Orphan Drugs. 2015;3(1):31–44.
39. Pennarun G, Escudier E, Chapelin C, Bridoux AM, Cacheux V, Roger G, et al. Loss-of-function mutations in a human gene related to Chlamydomonas reinhardtii dynein IC78 result in primary ciliary dyskinesia. Am J Hum Genet. 1999;65(6):1508–19.
40. Olbrich H, Haffner K, Kispert A, Volkel A, Volz A, Sasmaz G, et al. Mutations in DNAH5 cause primary ciliary dyskinesia and randomization of left-right asymmetry. Nat Genet. 2002;30(2):143–4.
41. Francis RJ, Christopher A, Devine WA, Ostrowski L, Lo C. Congenital heart disease and the specification of left-right asymmetry. Am J Physiol Heart Circ Physiol. 2012;302(10):H2102–11.
42. Lucas JS, Adam EC, Goggin PM, Jackson CL, Powles-Glover N, Patel SH, et al. Static respiratory cilia associated with mutations in Dnahc11/DNAH11: a mouse model of PCD. Hum Mutat. 2012;33(3):495–503.

43. Tan SY, Rosenthal J, Zhao XQ, Francis RJ, Chatterjee B, Sabol SL, et al. Heterotaxy and complex structural heart defects in a mutant mouse model of primary ciliary dyskinesia. J Clin Invest. 2007;117(12):3742–52.
44. Knowles MR, Daniels LA, Davis SD, Zariwala MA, Leigh MW. Primary ciliary dyskinesia. Recent advances in diagnostics, genetics, and characterization of clinical disease. Am J Respir Crit Care Med. 2013;188(8):913–22.
45. Lewis WR, Malarkey EB, Tritschler D, Bower R, Pasek RC, Porath JD, et al. Mutation of growth arrest specific 8 reveals a role in motile cilia function and human disease. PLoS Genet. 2016;12(7):e1006220.
46. Jeanson L, Thomas L, Copin B, Coste A, Sermet-Gaudelus I, Dastot-Le Moal F, et al. Mutations in GAS8, a gene encoding a nexin-dynein regulatory complex subunit, cause primary ciliary dyskinesia with axonemal disorganization. Hum Mutat. 2016;37(8):776–85.
47. Wirschell M, Olbrich H, Werner C, Tritschler D, Bower R, Sale WS, et al. The nexin-dynein regulatory complex subunit DRC1 is essential for motile cilia function in algae and humans. Nat Genet. 2013;45(3):262–8.
48. Horani A, Brody SL, Ferkol TW, Shoseyov D, Wasserman MG, Ta-shma A, et al. CCDC65 mutation causes primary ciliary dyskinesia with normal ultrastructure and hyperkinetic cilia. PLoS One. 2013;8(8):e72299.
49. Fedick AM, Jalas C, Treff NR, Knowles MR, Zariwala MA. Carrier frequencies of eleven mutations in eight genes associated with primary ciliary dyskinesia in the Ashkenazi Jewish population. Mol Genet Genomic Med. 2015;3(2):137–42.
50. Knowles MR, Ostrowski LE, Leigh MW, Sears PR, Davis SD, Wolf WE, et al. Mutations in RSPH1 cause primary ciliary dyskinesia with a unique clinical and ciliary phenotype. Am J Respir Crit Care Med. 2014;189(6):707–17.
51. Kobbernagel HE, Buchvald FF, Haarman EG, Casaulta C, Collins SA, Hogg C, et al. Study protocol, rationale and recruitment in a European multi-centre randomized controlled trial to determine the efficacy and safety of azithromycin maintenance therapy for 6 months in primary ciliary dyskinesia. BMC Pulm Med. 2016;16(1):104.
52. Shapiro AJ, Davis SD, Ferkol T, Dell SD, Rosenfeld M, Olivier KN, et al. Laterality defects other than situs inversus totalis in primary ciliary dyskinesia: insights into situs ambiguus and heterotaxy. Chest. 2014;146(5):1176–86.
53. Botto LD, Lin AE, Riehle-Colarusso T, Malik S, Correa A, National birth defects prevention Study. Seeking causes: classifying and evaluating congenital heart defects in etiologic studies. Birth Defects Res A Clin Mol Teratol. 2007;79(10):714–27.
54. Evans WN, Acherman RJ, Restrepo H. Heterotaxy in southern Nevada: prenatal detection and epidemiology. Pediatr Cardiol. 2015;36(5):930–4.
55. Kennedy MP, Omran H, Leigh MW, Dell S, Morgan L, Molina PL, et al. Congenital heart disease and other heterotaxic defects in a large cohort of patients with primary ciliary dyskinesia. Circulation. 2007;115(22):2814–21.
56. Sutherland MJ, Ware SM. Disorders of left-right asymmetry: heterotaxy and situs inversus. Am J Med Genet C Semin Med Genet. 2009;151C(4):307–17.
57. Fliegauf M, Benzing T, Omran H. When cilia go bad: cilia defects and ciliopathies. Nat Rev Mol Cell Biol. 2007;8(11):880–93.
58. Koefoed K, Veland IR, Pedersen LB, Larsen LA, Christensen ST. Cilia and coordination of signaling networks during heart development. Organogenesis. 2014;10(1):108–25.
59. Pennekamp P, Menchen T, Dworniczak B, Hamada H. Situs inversus and ciliary abnormalities: 20 years later, what is the connection? Cilia. 2015;4(1):1.
60. Nonaka S, Tanaka Y, Okada Y, Takeda S, Harada A, Kanai Y, et al. Randomization of left-right asymmetry due to loss of nodal cilia generating leftward flow of extraembryonic fluid in mice lacking KIF3B motor protein. Cell. 1998;95(6):829–37.
61. Supp DM, Witte DP, Potter SS, Brueckner M. Mutation of an axonemal dynein affects left-right asymmetry in inversus viscerum mice. Nature. 1997;389(6654):963–6.
62. Zhu L, Belmont JW, Ware SM. Genetics of human heterotaxias. Eur J Hum Genet. 2006;14(1):17–25.

63. McGrath J, Somlo S, Makova S, Tian X, Brueckner M. Two populations of node monocilia initiate left-right asymmetry in the mouse. Cell. 2003;114(1):61–73.
64. Yuksel MA, Mammadov Z, Sofiyeva N, Alici Davutoglu E, Temel Yuksel I, Madazli R. An unusual case of Meckel-Gruber syndrome (MKS) associated with visceroatrial heterotaxy and facial anomalies. J Obstet Gynaecol. 2016;36(4):524–5.
65. Tanaka Y, Okada Y, Hirokawa N. FGF-induced vesicular release of Sonic hedgehog and retinoic acid in leftward nodal flow is critical for left-right determination. Nature. 2005;435(7039):172–7.
66. Deng H, Xia H, Deng S. Genetic basis of human left-right asymmetry disorders. Expert Rev Mol Med. 2015;16:e19.
67. Bamford RN, Roessler E, Burdine RD, Saplakoglu U, dela Cruz J, Splitt M, et al. Loss-of-function mutations in the EGF-CFC gene CFC1 are associated with human left-right laterality defects. Nat Genet. 2000;26(3):365–9.
68. Ma L, Selamet Tierney ES, Lee T, Lanzano P, Chung WK. Mutations in ZIC3 and ACVR2B are a common cause of heterotaxy and associated cardiovascular anomalies. Cardiol Young. 2012;22(2):194–201.
69. Mohapatra B, Casey B, Li H, Ho-Dawson T, Smith L, Fernbach SD, et al. Identification and functional characterization of NODAL rare variants in heterotaxy and isolated cardiovascular malformations. Hum Mol Genet. 2009;18(5):861–71.
70. Kinzel D, Boldt K, Davis EE, Burtscher I, Trumbach D, Diplas B, et al. Pitchfork regulates primary cilia disassembly and left-right asymmetry. Dev Cell. 2010;19(1):66–77.
71. Zaidi S, Choi M, Wakimoto H, Ma L, Jiang J, Overton JD, et al. De novo mutations in histone-modifying genes in congenital heart disease. Nature. 2013;498(7453):220–3.
72. De Luca A, Sarkozy A, Consoli F, Ferese R, Guida V, Dentici ML, et al. Familial transposition of the great arteries caused by multiple mutations in laterality genes. Heart. 2010;96(9):673–7.
73. Yang XF, XY W, Li M, Li YG, Dai JT, Bai YH, et al. Mutation analysis of Cited2 in patients with congenital heart disease. Zhonghua Er Ke Za Zhi. 2010;48(4):293–6.
74. Kosaki K, Bassi MT, Kosaki R, Lewin M, Belmont J, Schauer G, et al. Characterization and mutation analysis of human LEFTY A and LEFTY B, homologues of murine genes implicated in left-right axis development. Am J Hum Genet. 1999;64(3):712–21.
75. Watanabe Y, Benson DW, Yano S, Akagi T, Yoshino M, Murray JC. Two novel frameshift mutations in NKX2.5 result in novel features including visceral inversus and sinus venosus type ASD. J Med Genet. 2002;39(11):807–11.
76. Hirayama-Yamada K, Kamisago M, Akimoto K, Aotsuka H, Nakamura Y, Tomita H, et al. Phenotypes with GATA4 or NKX2.5 mutations in familial atrial septal defect. Am J Med Genet A. 2005;135(1):47–52.
77. Robinson SW, Morris CD, Goldmuntz E, Reller MD, Jones MA, Steiner RD, et al. Missense mutations in CRELD1 are associated with cardiac atrioventricular septal defects. Am J Hum Genet. 2003;72(4):1047–52.
78. Perles Z, Cinnamon Y, Ta-Shma A, Shaag A, Einbinder T, Rein AJ, et al. A human laterality disorder associated with recessive CCDC11 mutation. J Med Genet. 2012;49(6):386–90.
79. French VM, van de Laar IM, Wessels MW, Rohe C, Roos-Hesselink JW, Wang G, et al. NPHP4 variants are associated with pleiotropic heart malformations. Circ Res. 2012;110(12):1564–74.
80. Kaasinen E, Aittomaki K, Eronen M, Vahteristo P, Karhu A, Mecklin JP, et al. Recessively inherited right atrial isomerism caused by mutations in growth/differentiation factor 1 (GDF1). Hum Mol Genet. 2010;19(14):2747–53.
81. Iida A, Emi M, Matsuoka R, Hiratsuka E, Okui K, Ohashi H, et al. Identification of a gene disrupted by inv(11)(q13.5;q25) in a patient with left-right axis malformation. Hum Genet. 2000;106(3):277–87.
82. Kato R, Yamada Y, Niikawa N. De novo balanced translocation (6;18)(q21;q21.3 or q22) [corrected] in a patient with heterotaxia. Am J Med Genet. 1996;66(2):184–6.

83. Gebbia M, Ferrero GB, Pilia G, Bassi MT, Aylsworth A, Penman-Splitt M, et al. X-linked situs abnormalities result from mutations in ZIC3. Nat Genet. 1997;17(3):305–8.
84. Barker AR, Thomas R, Dawe HR. Meckel-Gruber syndrome and the role of primary cilia in kidney, skeleton, and central nervous system development. Organogenesis. 2014;10(1):96–107.
85. Garrod AS, Zahid M, Tian X, Francis RJ, Khalifa O, Devine W, et al. Airway ciliary dysfunction and sinopulmonary symptoms in patients with congenital heart disease. Ann Am Thorac Soc. 2014;11(9):1426–32.
86. Li Y, Klena NT, Gabriel GC, Liu X, Kim AJ, Lemke K, et al. Global genetic analysis in mice unveils central role for cilia in congenital heart disease. Nature. 2015;521(7553):520–4.
87. Swisher M, Jonas R, Tian X, Lee ES, Lo CW, Leatherbury L. Increased postoperative and respiratory complications in patients with congenital heart disease associated with heterotaxy. J Thorac Cardiovasc Surg. 2011;141(3):637–44. 44 e1-3
88. Nakhleh N, Francis R, Giese RA, Tian X, Li Y, Zariwala MA, et al. High prevalence of respiratory ciliary dysfunction in congenital heart disease patients with heterotaxy. Circulation. 2012;125(18):2232–42.
89. Shapiro AJ, Tolleson-Rinehart S, Zariwala MA, Knowles MR, Leigh MW. The prevalence of clinical features associated with primary ciliary dyskinesia in a heterotaxy population: results of a web-based survey. Cardiol Young. 2015;25(4):752–9.
90. Ibanez-Tallon I, Gorokhova S, Heintz N. Loss of function of axonemal dynein Mdnah5 causes primary ciliary dyskinesia and hydrocephalus. Hum Mol Genet. 2002;11(6):715–21.
91. Lee L. Riding the wave of ependymal cilia: genetic susceptibility to hydrocephalus in primary ciliary dyskinesia. J Neurosci Res. 2013;91(9):1117–32.
92. Vieira JP, Lopes P, Silva R. Primary ciliary dyskinesia and hydrocephalus with aqueductal stenosis. J Child Neurol. 2012;27(7):938–41.
93. Wessels MW, den Hollander NS, Willems PJ. Mild fetal cerebral ventriculomegaly as a prenatal sonographic marker for Kartagener syndrome. Prenat Diagn. 2003;23(3):239–42.
94. Coppieters F, Lefever S, Leroy BP, De Baere E. CEP290, a gene with many faces: mutation overview and presentation of CEP290base. Hum Mutat. 2010;31(10):1097–108.
95. Nauli SM, Alenghat FJ, Luo Y, Williams E, Vassilev P, Li X, et al. Polycystins 1 and 2 mediate mechanosensation in the primary cilium of kidney cells. Nat Genet. 2003;33(2): 129–37.
96. Pazour GJ, San Agustin JT, Follit JA, Rosenbaum JL, Witman GB. Polycystin-2 localizes to kidney cilia and the ciliary level is elevated in orpk mice with polycystic kidney disease. Curr Biol. 2002;12(11):R378–80.
97. Yoder BK, Hou X, Guay-Woodford LM. The polycystic kidney disease proteins, polycystin-1, polycystin-2, polaris, and cystin, are co-localized in renal cilia. J Am Soc Nephrol. 2002;13(10):2508–16.
98. Moua T, Zand L, Hartman RP, Hartman TE, Qin D, Peikert T, et al. Radiologic and clinical bronchiectasis associated with autosomal dominant polycystic kidney disease. PLoS One. 2014;9(4):e93674.
99. Sayarlioglu H, Dagli CE, Dogan E, Sayarlioglu M, Koksal N. Kartagener's syndrome and polycystic kidney disease. NDT Plus. 2009;2(2):189–90.
100. Onoe T, Konoshita T, Tsuneyama K, Hamano R, Mizushima I, Kakuchi Y, et al. Situs inversus and cystic kidney disease: Two adult patients with this Heterogeneous syndrome. Am J Case Rep. 2013;14:20–5.
101. Otto EA, Schermer B, Obara T, O'Toole JF, Hiller KS, Mueller AM, et al. Mutations in INVS encoding inversin cause nephronophthisis type 2, linking renal cystic disease to the function of primary cilia and left-right axis determination. Nat Genet. 2003;34(4):413–20.
102. Liu Q, Zhang Q, Pierce EA. Photoreceptor sensory cilia and inherited retinal degeneration. Adv Exp Med Biol. 2010;664:223–32.
103. Bukowy-Bieryllo Z, Zietkiewicz E, Loges NT, Wittmer M, Geremek M, Olbrich H, et al. RPGR mutations might cause reduced orientation of respiratory cilia. Pediatr Pulmonol. 2013;48(4):352–63.

104. Shah AS, Farmen SL, Moninger TO, Businga TR, Andrews MP, Bugge K, et al. Loss of Bardet-Biedl syndrome proteins alters the morphology and function of motile cilia in airway epithelia. Proc Natl Acad Sci U S A. 2008;105(9):3380–5.
105. Papon JF, Perrault I, Coste A, Louis B, Gerard X, Hanein S, et al. Abnormal respiratory cilia in non-syndromic Leber congenital amaurosis with CEP290 mutations. J Med Genet. 2010;47(12):829–34.
106. Leigh MW, Pittman JE, Carson JL, Ferkol TW, Dell SD, Davis SD, et al. Clinical and genetic aspects of primary ciliary dyskinesia/Kartagener syndrome. Genet Med. 2009;11(7): 473–87.
107. Zariwala MA, Knowles MR, Omran H. Genetic defects in ciliary structure and function. Annu Rev Physiol. 2007;69:423–50.
108. Zariwala MA, Leigh MW Primary ciliary dyskinesia. In: Pagon RA, Adam MP, Ardinger HH, et al., editors. GeneReviews [Internet]. Updated 3rd Sept 2015. Seattle: University of Washington; 2007. p. 1993–2016.
109. Mazor M, Alkrinawi S, Chalifa-Caspi V, Manor E, Sheffield VC, Aviram M, et al. Primary ciliary dyskinesia caused by homozygous mutation in DNAL1, encoding dynein light chain 1. Am J Hum Genet. 2011;88(5):599–607.
110. Knowles MR, Leigh MW, Ostrowski LE, Huang L, Carson JL, Hazucha MJ, et al. Exome sequencing identifies mutations in CCDC114 as a cause of primary ciliary dyskinesia. Am J Hum Genet. 2013;92(1):99–106.
111. Onoufriadis A, Paff T, Antony D, Shoemark A, Micha D, Kuyt B, et al. Splice-site mutations in the axonemal outer dynein arm docking complex gene CCDC114 cause primary ciliary dyskinesia. Am J Hum Genet. 2013;92(1):88–98.
112. Hjeij R, Onoufriadis A, Watson CM, Slagle CE, Klena NT, Dougherty GW, et al. CCDC151 mutations cause primary ciliary dyskinesia by disruption of the outer dynein arm docking complex formation. Am J Hum Genet. 2014;95(3):257–74.
113. Duriez B, Duquesnoy P, Escudier E, Bridoux AM, Escalier D, Rayet I, et al. A common variant in combination with a nonsense mutation in a member of the thioredoxin family causes primary ciliary dyskinesia. Proc Natl Acad Sci U S A. 2007;104(9):3336–41.
114. Hjeij R, Lindstrand A, Francis R, Zariwala MA, Liu X, Li Y, et al. ARMC4 mutations cause primary ciliary dyskinesia with randomization of left/right body asymmetry. Am J Hum Genet. 2013;93(2):357–67.
115. Onoufriadis A, Shoemark A, Munye MM, James CT, Schmidts M, Patel M, et al. Combined exome and whole-genome sequencing identifies mutations in ARMC4 as a cause of primary ciliary dyskinesia with defects in the outer dynein arm. J Med Genet. 2014;51(1):61–7.
116. Wallmeier J, Shiratori H, Dougherty GW, Edelbusch C, Hjeij R, Loges NT, et al. TTC25 deficiency results in defects of the outer dynein arm docking machinery and primary ciliary dyskinesia with left-right body asymmetry randomization. Am J Hum Genet. 2016;99(2):460–9.
117. Mitchison HM, Schmidts M, Loges NT, Freshour J, Dritsoula A, Hirst RA, et al. Mutations in axonemal dynein assembly factor DNAAF3 cause primary ciliary dyskinesia. Nat Genet. 2012;44(4):381–9. S1-2
118. Austin-Tse C, Halbritter J, Zariwala MA, Gilberti RM, Gee HY, Hellman N, et al. Zebrafish ciliopathy screen plus human mutational analysis identifies C21orf59 and CCDC65 defects as causing primary ciliary dyskinesia. Am J Hum Genet. 2013;93(4):672–86.
119. Panizzi JR, Becker-Heck A, Castleman VH, Al-Mutairi DA, Liu Y, Loges NT, et al. CCDC103 mutations cause primary ciliary dyskinesia by disrupting assembly of ciliary dynein arms. Nat Genet. 2012;44(6):714–9.
120. Horani A, Druley TE, Zariwala MA, Patel AC, Levinson BT, Van Arendonk LG, et al. Whole-exome capture and sequencing identifies HEATR2 mutation as a cause of primary ciliary dyskinesia. Am J Hum Genet. 2012;91(4):685–93.
121. Kott E, Duquesnoy P, Copin B, Legendre M, Dastot-Le Moal F, Montantin G, et al. Loss-of-function mutations in LRRC6, a gene essential for proper axonemal assembly of inner and outer dynein arms, cause primary ciliary dyskinesia. Am J Hum Genet. 2012;91(5):958–64.

122. Horani A, Ferkol TW, Shoseyov D, Wasserman MG, Oren YS, Kerem B, et al. LRRC6 mutation causes primary ciliary dyskinesia with dynein arm defects. PLoS One. 2013;8(3):e59436.
123. Tarkar A, Loges NT, Slagle CE, Francis R, Dougherty GW, Tamayo JV, et al. DYX1C1 is required for axonemal dynein assembly and ciliary motility. Nat Genet. 2013;45(9):995–1003.
124. Zariwala MA, Gee HY, Kurkowiak M, Al-Mutairi DA, Leigh MW, Hurd TW, et al. ZMYND10 is mutated in primary ciliary dyskinesia and interacts with LRRC6. Am J Hum Genet. 2013;93(2):336–45.
125. Moore DJ, Onoufriadis A, Shoemark A, Simpson MA, zur Lage PI, de Castro SC, et al. Mutations in ZMYND10, a gene essential for proper axonemal assembly of inner and outer dynein arms in humans and flies, cause primary ciliary dyskinesia. Am J Hum Genet. 2013;93(2):346–56.
126. Knowles MR, Ostrowski LE, Loges NT, Hurd T, Leigh MW, Huang L, et al. Mutations in SPAG1 cause primary ciliary dyskinesia associated with defective outer and inner dynein arms. Am J Hum Genet. 2013;93(4):711–20.
127. Blanchon S, Legendre M, Copin B, Duquesnoy P, Montantin G, Kott E, et al. Delineation of CCDC39/CCDC40 mutation spectrum and associated phenotypes in primary ciliary dyskinesia. J Med Genet. 2012;49(6):410–6.
128. Becker-Heck A, Zohn IE, Okabe N, Pollock A, Lenhart KB, Sullivan-Brown J, et al. The coiled-coil domain containing protein CCDC40 is essential for motile cilia function and left-right axis formation. Nat Genet. 2011;43(1):79–84.
129. Harrison MJ, Shapiro AJ, Kennedy MP. Congenital heart disease and primary ciliary dyskinesia. Paediatr Respir Rev. 2016;18:25–32.
130. Watson CM, Crinnion LA, Morgan JE, Harrison SM, Diggle CP, Adlard J, et al. Robust diagnostic genetic testing using solution capture enrichment and a novel variant-filtering interface. Hum Mutat. 2014;35(4):434–41.
131. Castleman VH, Romio L, Chodhari R, Hirst RA, de Castro SC, Parker KA, et al. Mutations in radial spoke head protein genes RSPH9 and RSPH4A cause primary ciliary dyskinesia with central-microtubular-pair abnormalities. Am J Hum Genet. 2009;84(2):197–209.
132. Daniels ML, Leigh MW, Davis SD, Armstrong MC, Carson JL, Hazucha M, et al. Founder mutation in RSPH4A identified in patients of Hispanic descent with primary ciliary dyskinesia. Hum Mutat. 2013;34(10):1352–6.
133. Zietkiewicz E, Bukowy-Bieryllo Z, Voelkel K, Klimek B, Dmenska H, Pogorzelski A, et al. Mutations in radial spoke head genes and ultrastructural cilia defects in East-European cohort of primary ciliary dyskinesia patients. PLoS One. 2012;7(3):e33667.
134. Onoufriadis A, Shoemark A, Schmidts M, Patel M, Jimenez G, Liu H, et al. Targeted NGS gene panel identifies mutations in RSPH1 causing primary ciliary dyskinesia and a common mechanism for ciliary central pair agenesis due to radial spoke defects. Hum Mol Genet. 2014;23(13):3362–74.
135. Frommer A, Hjeij R, Loges NT, Edelbusch C, Jahnke C, Raidt J, et al. Immunofluorescence analysis and diagnosis of primary ciliary dyskinesia with radial spoke defects. Am J Respir Cell Mol Biol. 2015;53(4):563–73.
136. Reish O, Slatkin M, Chapman-Shimshoni D, Elizur A, Chioza B, Castleman V, et al. Founder mutation(s) in the RSPH9 gene leading to primary ciliary dyskinesia in two inbred Bedouin families. Ann Hum Genet. 2010;74(2):117–25.
137. Kott E, Legendre M, Copin B, Papon JF, Dastot-Le Moal F, Montantin G, et al. Loss-of-function mutations in RSPH1 cause primary ciliary dyskinesia with central-complex and radial-spoke defects. Am J Hum Genet. 2013;93(3):561–70.
138. Jeanson L, Copin B, Papon JF, Dastot-Le Moal F, Duquesnoy P, Montantin G, et al. RSPH3 mutations cause primary ciliary dyskinesia with central-complex defects and a near absence of radial spokes. Am J Hum Genet. 2015;97(1):153–62.
139. Olbrich H, Schmidts M, Werner C, Onoufriadis A, Loges NT, Raidt J, et al. Recessive HYDIN mutations cause primary ciliary dyskinesia without randomization of left-right body asymmetry. Am J Hum Genet. 2012;91(4):672–84.

140. Boon M, Wallmeier J, Ma L, Loges NT, Jaspers M, Olbrich H, et al. MCIDAS mutations result in a mucociliary clearance disorder with reduced generation of multiple motile cilia. Nat Commun. 2014;5:4418.
141. Wallmeier J, Al-Mutairi DA, Chen CT, Loges NT, Pennekamp P, Menchen T, et al. Mutations in CCNO result in congenital mucociliary clearance disorder with reduced generation of multiple motile cilia. Nat Genet. 2014;46(6):646–51.
142. El Khouri E, Thomas L, Jeanson L, Bequignon E, Vallette B, Duquesnoy P, et al. Mutations in DNAJB13, encoding an HSP40 family member, cause primary ciliary dyskinesia and male infertility. Am J Hum Genet. 2016;99(2):489–500.
143. Horani A, Ferkol TW. Primary ciliary dyskinesia and associated sensory ciliopathies. Expert Rev Respir Med. 2016;10(5):569–76.
144. Yen HJ, Tayeh MK, Mullins RF, Stone EM, Sheffield VC, Slusarski DC. Bardet-Biedl syndrome genes are important in retrograde intracellular trafficking and Kupffer's vesicle cilia function. Hum Mol Genet. 2006;15(5):667–77.
145. Simms RJ, Hynes AM, Eley L, Inglis D, Chaudhry B, Dawe HR, et al. Modelling a ciliopathy: Ahi1 knockdown in model systems reveals an essential role in brain, retinal, and renal development. Cell Mol Life Sci. 2012;69(6):993–1009.
146. Hurd T, Zhou W, Jenkins P, Liu CJ, Swaroop A, Khanna H, et al. The retinitis pigmentosa protein RP2 interacts with polycystin 2 and regulates cilia-mediated vertebrate development. Hum Mol Genet. 2010;19(22):4330–44.
147. Ferrante MI, Romio L, Castro S, Collins JE, Goulding DA, Stemple DL, et al. Convergent extension movements and ciliary function are mediated by ofd1, a zebrafish orthologue of the human oral-facial-digital type 1 syndrome gene. Hum Mol Genet. 2009;18(2):289–303.
148. Ozanturk A, Marshall JD, Collin GB, Duzenli S, Marshall RP, Candan S, et al. The phenotypic and molecular genetic spectrum of Alstrom syndrome in 44 Turkish kindreds and a literature review of Alstrom syndrome in Turkey. J Hum Genet. 2015;60(1):51.

Pulmonary Complications of Drug Therapy

Dimos K. Gidaris, Kostas N. Priftis, and Michael B. Anthracopoulos

Pathogenetic Mechanisms

Various mechanisms have been implicated in the pathogenesis of drug pathogenic toxicity. These include direct cytotoxic damage, generation of reactive oxygen species (biotransformation and oxidative reactions of CYP450 enzymes in the lungs), phospholipidosis (excessive accumulation of phospholipids in the tissues and alveolar macrophage infiltration) induced by cationic amphiphilic drugs, and immune-mediated pulmonary injury (drugs acting as a hapten or as an antigen) [1–3]. In addition, host-related risk factors (Table 1) can predispose or exacerbate the toxicity of a certain drug.

Clinical Disease Types

The presentation of DIRD varies both in its onset and and in its pathologic manifestations. The clinical course may be acute or chronic [4]. Table 2 summarizes diffferent clinical courses of DIRD that reflect the underlying pathology.

D.K. Gidaris, M.R.C.P.C.H., M.R.C.P.E., Ph.D. (✉)
University of Nicosia Medical School, Nicosia, Cyprus
e-mail: dgidaris@doctors.org.uk

K.N. Priftis, M.D.
Allergy-Pneumonology Department, University of Athens, School of Medicine, Athens, Greece
e-mail: kpriftis@otenet.gr

M.B. Anthracopoulos, M.D.
Department of Pediatrics, Pulmonary Division, Medical School of the University of Patras, Rion, Greece
e-mail: manthra@otenet.gr

© Springer International Publishing AG 2018

A.C. Koumbourlis, M.A. Nevin (eds.), *Pulmonary Complications of Non-Pulmonary Pediatric Disorders*, Respiratory Medicine,
https://doi.org/10.1007/978-3-319-69620-1_14

Table 1 Risk factors for drug-induced respiratory diseases

• Cumulative dose—rate of infusion
• Age
• Radiation (prior to or concurrently with drug administration)
• Oxygen therapy
• Synergistic toxic action with other drugs
• Underlying disease (existing pulmonary lesions or history of pulmonary surgery or nephropathy)
• Race (e.g., Japanese and Korean patients have higher incidence of DIRD with methotrexate and tumor necrosis factor, TNF)

Table 2 Course of presentation of DIRD

Acute presentation	Chronic presentation
• Hypersensitivity pneumonitis	• Nonspecific interstitial pneumonia
• Acute eosinophilic pneumonia	• Organizing pneumonia
• Diffuse alveolar damage	
• Noncardiogenic pulmonary edema	
• Acute respiratory distress/acute lung injury	

The entire respiratory system (airways, alveoli, interstitium, vasculature, and the pleural spaces) is susceptible to pharmacologic injury [5]. As a result the produced clinical symptoms are similar to those produced by almost any lung disease (dyspnea, cough, chest pain or tightness, wheezing, hemoptysis) and systemic reactions such as fever and exanthem [4], thus making the differentiation on clinical grounds very difficult. However, there are certain pathologic and/or clinical that are more likely to be produced by certain drugs than others, and they are summarized in Tables 3, 4, 5, 6, 7, and 8.

There are no clear-cut criteria for the diagnosis of pulmonary toxicity. Several lists have been proposed for the classification of DIRD [6, 12]. One of the most recent proposals comes from the Japanese Respiratory Society Committee for formulation of consensus statement for the diagnosis and treatment of drug-induced lung injuries [4] and includes the following:

- History of ingestion of a drug that is known to induce lung injury
- The manifestations (symptoms and signs, imaging findings, and histologic patterns) reported to be induced by a drug
- Exclusion of other causes (infection, manifestation of background disease, cardiorespiratory failure) of the clinical manifestations
- Improvement of the clinical manifestations after drug discontinuation (with or without the administration of steroids)
- Exacerbation of the clinical manifestations after resuming drug administration

It should be noted that the absence of abnormal or new auscultatory findings does not rule out DIRD.

Table 3 Drugs associated with common respiratory symptoms

Drugs associated with *bronchospasm*		Drugs associated with *cough*	
• ACE inhibitors	• Erythromycin	• Amiodarone	• Nebulized
• Acetylcysteine	• Heroin	• ACE inhibitors	• Medications
• Adenosine	• Iodine radiocontrasts	• Fentanyl	• Omeprazole
• Amiodarone	• Iron dextran	• Inhaled insulin	• Propofol
• Aminoglycosides	• Methotrexate	• Isoflurane	• Ribavirin
• Amphotericin B	• Nitrofurantoin	• Methotrexate	• Statins
• Aspirin and NSAIDs	• Penicillins	• Mycophenolate mofetil	• Steroids
• b-blockers	• Piperazine	• Nitrofurantoin	• Sulphonamides
• Carbamazepine	• Propofol		• Topiramate
• Cimetidine	• Rifampicin		
• Cocaine	• Risperidone		
• Cyclophosphamide	• Suxamethonium		
• Cephalosporins	• Sulphonamides		
• Cytokines	• Trimethoprim		
• D-Penicillamine	• Vinblastine		

Table 4 Drugs associated with bronchiolitis obliterans with organizing pneumonia

• Amiodarone	• Interferonsphan
• Amphotericin	• L-Trypt
• Bleomycin	• Minocycline
• Carbamazepine	• Nitrofurantoin
• Cocaine	

Table 5 Drugs that may cause interstitial pneumonitis [4, 6]

• Amiodarone	• Methotrexate
• Bleomycin	• Nitrofurantoin
• Carbamazepine	• Penicillamine
• Co-trimoxazole	• Phenytoin
• Cyclophosphamide	

Table 6 Drugs associated with alveolar disease [7, 8]

• Amiodarone	• Mineral oil
• Aspirin	• Minocycline
• Azathioprine	• Mitomycin C
• Bleomycin	• Morphine
• Carbamazepine	• Nitrofurantoin
• Carmustine	• Phenytoin
• Cyclophosphamide	• Rituximab
• Interferon γ	• Vinblastine
• Methotrexate	

Table 7 Drugs associated with pleural diseases [9, 10]

• Amiodarone	• Nitrofurantoin[b]
• Dantrolene[b]	• Penicillamine[a]
• Hydralazine[a]	• Sclerosing agents
• Isoniazid[a]	• Quinidine[a]
• Isotretinoin[b]	• Valproic acid[b]
• Methotrexate	

[a]Drug-induced SLE
[b]Drugs associated with pleural fluid eosinophilia

Table 8 Drugs that have been associated with vasculitides and alveolar hemorrhage [7, 8, 11]

• Amiodarone	• Nitrofurantoin
• Anticoagulants	• Penicillamine
• Chemotherapeutics	• Penicillin
• Cocaine	• Propylthiouracil
• Hydralazine	• Quinidine
• Isoniazid	• Streptokinase
• Mitomycin C	• Surfactant
• Montelukast	

Table 9 Histologic patterns associated with pulmonary drug reactions [14]

• Pulmonary edema	• Nonspecific interstitial pneumonia
• Alveolar hemorrhage	• Lymphocytic interstitial pneumonia
• Alveolar proteinosis-like reaction	• Acute or chronic eosinophilic pneumonia
• Diffuse alveolar damage	• Small vessel angiitis
• Organizing pneumonia	• Pulmonary arterial hypertension
• Usual interstitial pneumonia-like pattern	• Pulmonary veno-occlusive disease
• Diffuse cellular interstitial infiltrates (± granulomas)	

All adverse drug events concerning the respiratory (or any other) system should be prompty reported to the relevant regulating bodies, even if the association is probable rather than definite [4, 13]. In such cases it is prudent to avoid rechallenging patients with a drug which is suspected for DIRD because it may lead to catastrophic outcomes. Clinicians should also be vigilant for new presentations and associations that have not previously been reported.

The main histologic patterns that a pathologist is faced with in the case of an iatrogenic pulmonary toxicity are summarized in Table 9. However, the list is probably incomplete since many patients with suspected DIRD do not undergo lung biopsy. This makes the prognosis of a DIRD very difficult since the clinical presentation is not always associated with specific histologic findings [15] . In general eosinophilic pneumonia, hypersensitivity pneumonitis, and organizing pneumonia tend to improve after discontinuation of the offending agent. In contrast, diffuse alveolar damage and chronic usual interstitial pneumonia tend to cause more irreversible damage [4].

Pulmonary Toxicity of Commonly Used Non-chemotherapeutic Medications

Nitrofurantoin

Primary use: Nitrofurantoin (a 5-nitrofuran derivative) is a commonly used antibiotic for the treatment of uncomplicated urinary tract infections and for prophylaxis in children with vesicoureteric reflux.

Mechanism of toxicity: The toxic mechanism is possibly related to the production of toxic oxygen species [16], and it is considered to be dose dependent [17].

Incidence of toxicity: Pulmonary complications due to nitrofurantoin are rare with an incidence of 0.0009% [18].

Onset of toxicity: Clinical presentation may be acute, subacute, or chronic [19]. Acute and subacute presentations are more common and are regarded as dose-independent hypersensitivity reactions, occurring few hours to 4 weeks after the initiation of the drug. Chronic presentation includes cases that account for less than 10% of nitrofurantoin-related lung complications. Their onset occurs more than 6 months after the initiation of the therapy.

Clinical presentation: In the acute form, the patient presents with fever, cough, and respiratory distress; on auscultation fine crackles predominate [20]. Wheeze has also been reported. Acute hepatic injury may accompany pneumonitis.

Chronic cases present with a more insidious course characterized by fatigue, cough, and slowly increasing dyspnea over several months; fever is not always present [21]. Auscultatory, radiologic, and spirometric findings resemble those described for acute cases.

Radiographic findings: Chest radiograph may be normal or show bilateral lower lobe infiltrates; pleural effusions are occasionally present.

Pulmonary function testing: Hypoxemia, reduced DLCO, and a restrictive spirometric pattern are considered to be typical.

Histologic and laboratory findings: Histological examination is rarely performed since cessation of the antibiotic tends to be followed by resolution of the symptoms. Eosinophilia, elevated immunoglobulin levels, increased liver enzymes, and high ANA titers (drug-induced lupus syndrome) have been reported. Pathology may show organizing pneumonia with variable fibrosis with (BOOP) or without bronchiolitis obliterans, desquamative interstitial pneumonia, or vasculitis [7].

Radiographic findings: CT scans may reveal bilateral areas of ground-glass opacities, subpleural irregular linear opacities, and patchy consolidation.

Treatment of toxicity: Immediate discontinuation of the drug as soon as possible, since fatalities have been reported [22]. Systemic corticosteroids have been reported as being helpful, although their use is not evidence based [17].

Prognosis: Good, but recurrent cases with acute presentation—following initial misdiagnosis—have been described in adult patients [23]. Eosinophilia can persist for up to 6 weeks after the discontinuation of the drug [16].

Minocycline

Primary use: Minocycline is an antibiotic (semisynthetic derivative of tetracycline) used for the treatment of acne vulgaris in adolescents and less frequently for the treatment of organizing pneumonia in rheumatoid arthritis, other bronchopulmonary infections, and for urinary tract infections [15].

Mechanism of toxicity: Unknown. Accumulation of eosinophils is mediated by interleukin five production by T lymphocytes.

Incidence of toxicity: Unknown. It is considered uncommon, but this is a commonly used drug [15].

Onset of toxicity: Days to weeks postdrug initiation.

Clinical presentation: Minocycline lung toxicity usually presents as organizing pneumonia or as eosinophilic pneumonia. Autoimmune disorders—including lupus—frequently accompany minocycline-induced pulmonary adverse events [20].

Radiographic findings: Patchy multifocal consolidations are typical radiologic findings.

Pulmonary function testing: Spirometric pattern may be restrictive or obstructive.

Laboratory and histologic findings: Peripheral eosinophilia may be an early diagnostic clue. Bronchoalveolar lavage fluid is dominated by eosinophils [15]. The lymphocyte stimulation test—using peripheral blood lymphocytes—for minocycline is not considered to be of diagnostic usefulness.

Treatment of toxicity: Discontinuation of the treatment and use of corticosteroids.

Prognosis: Generally good following cessation of minocycline. Resolution of minocycline-induced organizing pneumonia without recourse to corticosteroids has been reported [24].

Amphotericin B

Primary use: Treatment of severe fungal infections.

Known or suspected mechanism of toxicity: Pulmonary adverse reactions have been reported with the concomitant use of this antifungal and leukocyte transfusion [25] and also with the use of drug alone, both for conventional and lipidic formulations [26]; the mechanism of these reactions has not yet been determined, but injury of the endothelial cells, alteration of neutrophilic function, increased production of TNF by macrophages, stimulated prostaglandin E2 synthesis, and increased monocyte IL 1 expression have been implicated [26]. It has been postulated that slower infusion rates may be safer.

Incidence of toxicity: 0.3–30%. May vary for different preparations, different dosage schemes, and variable infusion rates [26].

Onset of toxicity: Usually within the first few days of treatment.

Clinical presentation: The major clinical characteristics of amphotericin-induced lung toxicity are dyspnea, chest pain and tightness, wheezing, cyanosis, cough, and hemoptysis [26]. Development of pulmonary hypertension has been reported.

Radiographic findings: Diffuse bilateral infiltrates.

Treatment of toxicity: Drug withdrawal and administration of corticosteroids are the only available therapeutic options.

Prognosis: Generally good following drug withdrawal. In a review of 21 cases by Collazos et al., only one fatal reaction was reported [26].

Sulphasalazine (Sulfasalazine)

Primary use: Treatment of inflammatory bowel disease and in rheumatoid arthritis.

Mechanism of toxicity: Unknown. Also it is unclear which of the two components of the drug (sulphapyridine and 5-aminosalicylic acid) is responsible for the pulmonary toxicity.

Incidence of toxicity: It is rare. Parry et al. identified 50 reported cases from 1972 to 1999 [27].

Onset of toxicity: Acute onset 1–6 months into therapy [20].

Clinical presentation: Breathlessness, fever and cough, and hypoxemia are the most common signs and symptoms. Approximately 50% of the patients will have inspiratory crackles on auscultation. Weight loss and chest pain have been also reported [27]. The clinician faced with a patient with respiratory symptoms while treated with sulphasalazine should always bear in mind that the respiratory involvement may also be due to the underlying disease [28, 29].

Radiographic findings: Radiography usually reveals bilateral pulmonary infiltrates. Ground-glass opacities have been reported on HRCT [27].

Laboratory and histologic findings: Bronchoalveoloar lavage (BAL) fluid may be eosinophilic or lymphocytic. The most common histological pattern is that of interstitial pneumonitis, inflammation, and fibrosing alveolitis [27].

Pulmonary function testing: Spirometry may reveal restriction, obstruction, or a mixed pattern [27].

Treatment of toxicity: Prompt drug withdrawal of the drug. Corticosteroids are frequently administered, but the evidence supporting their use is not based on randomized controlled trials [27].

Prognosis: Usually good if the drug is withdrawn, but fatalities have been reported both in children and adults [30, 31]. Parry et al. reported clinical improvement in 90% of the cases they reviewed [27]. The prognosis seems to be better when there is pulmonary eosinophilia and worse when the clinical picture is that of fibrosing alveolitis [27].

Penicillamine

Primary use: Penicillamine is an alpha amino acid metabolite of penicillin used as a chelating agent in the treatment of Wilson's disease. It has been also used for the treatment of cystinuria, rheumatoid arthritis, lead poisoning, and biliary cirrhosis [32].

Mechanism of toxicity: Unclear.

Incidence of toxicity: Drug toxicity is often difficult to establish because the respiratory symptoms are very similar to those produced by the underlying disease process for which the therapy is given [20].

Onset of toxicity: Time of onset of penicillamine lung toxicity can be less than 8 weeks for hypersensitivity reactions, 3–19 months for diffuse alveolitis and bronchiolitis obliterans, and 2–7 years for alveolar hemorrhage [20].

Clinical presentation: Acute and subacute pneumonitis, eosinophilic pneumonia, organizing pneumonia, ARDS, diffuse alveolar hemorrhage, and Goodpasture's disease have been reported as patterns of penicillamine toxicity [32].

Radiographic findings: Diffuse bilateral alveolar or interstitial infiltrates, hyperinflation, or without radiographic findings [20].

Pulmonary function testing: Restrictive (in patients with alveolitis or hypersensitivity reactions) or obstructive pattern (in patients with bronchiolitis obliterans) [20].

Treatment of toxicity: Discontinuation of the medication and administration of corticosteroids.

Prognosis: Good if the drug is withdrawn and the patient receives proper therapy promptly.

Amiodarone

Primary use: Antiarrhythmic drug with Class I, II, III, and IV antiarrhythmic properties that is used in the suppression of supraventricular and ventricular tachyarrhythmias.

Mechanism of toxicity: Amiodarone is an iodinated benzofuran compound that is associated with direct and indirect toxicity ("amiodarone pneumonitis" or "amiodarone lung") that is assumed to be dose related.

Incidence of toxicity: 10–15% of the patients treated may develop toxicity. It is much more common among adult patients, but it has been reported in children [33] and adolescents as well [34].

Onset of toxicity: The symptoms may start months to years after the initiation of treatment and may even manifest after the discontinuation of the medication [35].

Clinical presentation: Progressive dyspnea, malaise, weight loss, dry cough, and pleuritic pain comprise the clinical picture [36]. Diffuse rales, hypoxemia, and respiratory distress signs are the typical clinical findings.

Radiographic findings: Chest radiography usually shows asymmetrical alveolar, interstitial, or mixed alveolar-interstitial shadows. Localized forms of pulmonary toxicity (pleural disease, migratory infiltrates, and single or multiple nodules) have been reported [37]. HRCT usually reveals a more extensive disease [37]; typical HRCT findings in amiodarone lung toxicity include ground-glass opacities; interstitial, alveolar, or mixed infiltrates; and high attenuation areas [37, 38].

Pulmonary function testing: A decrease in the DLCO may be the earliest laboratory indication of amiodarone lung toxicity [39], usually followed by low lung volumes and a restrictive pattern [37] Baseline chest radiograph and PFTs (including DLCO) should be obtained prior to the initiation of amiodarone treatment [40]. The PFTs should be repeated every few months and/or with an increase in the dose due to the cumulative effect of the medication.

Laboratory and histologic findings: Increased ESR, LDH, and leukocytosis are also often observed [36]. Lipid-laden "foamy" alveolar macrophages are typical but not pathognomonic finding in the BAL fluid possibly representing cell death caused by the toxicity [41]; in fact, the absence of foamy macrophages should lead to considering alternative diagnoses [42, 43]. Interstitial pneumonitis, organizing pneumonia, diffuse alveolar hemorrhage, and diffuse alveolar damage [41–43] are the usual histologic findings.

Treatment of toxicity: Discontinuation of the drug (with the consent of the cardiologist) and administration of corticosteroids (for 6–12 months) are the treatments of choice [36].

Prognosis: Clinical improvement may take up to 3 months, whereas radiographic and spirometric improvement takes longer. Mortality ranging 21–33% has been reported in adult patients hospitalized for amiodarone lung [36]. It is worth emphasizing that although amiodarone lung toxicity is dose related, no dose can be considered entirely safe.

Diphenylhydantoin (Phenytoin)

Primary use: Antiepileptic; also used for treatment of neuralgia.

Known or suspected mechanism of toxicity: Lung toxicity is rare. Diphenylhydantoin and other anticonvulsants have been reported as causes of DRESS(drug rash with eosinophilia and systemic symptoms) syndrome [44]. Lung involvement can be subclinical with spirometric [45] or radiologic evidence in the absence of clinical symptoms [46].

Incidence of toxicity: Unknown, but rare.

Onset of toxicity: It can be fairly acute but subacute forms have been also reported.

Clinical presentation: It may be acute with fever, cough, dyspnea, rash, facial edema, lymphadenopathy, and bilateral radiographic infiltrates [47] or chronic with gradual onset of the symptoms. The patients develop crackles and occasionally wheezing [20, 46]. Isolated nocturnal dry cough has also been reported in a young adults [48]. Acute lung injury may be accompanied by renal involvement [49].

Diphenylhydantoin and other anticonvulsants have been reported as causes of DRESS(drug rash with eosinophilia and systemic symptoms) syndrome [44].

Radiographic findings: Radiographic abnormalities have been reported in the absence of overt clinical symptoms [45]. Typical radiographic findings are bilateral alveolar or interstitial infiltrates with or without hilar adenopathy [20].

Pulmonary function testing: Decrease in the spirometric indices suggestive of a restrictive lung defect has been reported even in the absence of overt clinical symptoms [45].

Laboratory and histologic findings: Peripheral eosinophilia. Acute interstitial pneumonitis, lymphocytic interstitial pneumonia, pulmonary fibrosis, and chronic eosinophilic pneumonia are the most common histologic patterns [50].

Treatment of toxicity: Primarily discontinuation of the medication and administration of corticosteroids.

Prognosis: Usually good after the prompt discontinuation of the medication, but fatalities have been reported [51].

Carbamazepine

Primary use: Antiepileptic.

Known or suspected mechanism of toxicity: Immune-mediated hypersensitivity response.

Incidence of lung toxicity: Rare.

Onset of toxicity: Weeks to years after initial exposure.

Clinical presentation: Interstitial pneumonitis has been reported in children, which manifests with fever, weakness, dry cough, and gradually worsening dyspnea [52]. A rash and panhypogammaglobulinemia [52] may also occur. In the adult literature, apart from the aforementioned presentation, DRESS syndrome, bronchiolitis obliterans with organizing pneumonia (BOOP), and pulmonary edema have been reported [53–55].

Radiographic findings: Typical radiographic findings are bilateral alveolar or interstitial infiltrates with or without hilar adenopathy [20].

Pulmonary function testing: Restrictive lung defect.

Treatment of toxicity: Primarily discontinuation of the medication and administration of corticosteroids.

Prognosis: Gradual improvement after drug withdrawal.

Pulmonary Toxicity of Chemotherapy

Pediatric oncology patients undergo multiple treatment modalities (chemotherapy, immunosuppression, radiation, and surgery) that dramatically increase the risk for pulmonary toxicity [20]. Therefore, their physicians should be mindful of this

potentially fatal complication and be in constant collaboration with pediatric oncologists and the other members of the multidisciplinary team [56–59]. Differentiating iatrogenic DIRD in cancer patients from infection, radiation pneumonitis, and cancer recurrence can be quite challenging [59]. Children and adolescents treated for cancer have an increased relative risk of lung fibrosis, recurrent pneumonia, chronic cough, pleurisy, use of supplemental oxygen, abnormal chest wall, exercise-induced shortness of breath, and bronchitis as compared to their siblings [57]. They also carry an increased risk of restrictive (24.0% vs. 4.8%; $P < 0.01$) and diffusion defects (34.7% vs. 9.5%; $P < 0.001$) compared to healthy controls [58].

Chemotherapeutic agents that can produce lung toxicity are selectively summarized in Table 10. Dyspnea, dry cough, malaise, and weight loss are the main clinical features of chemotherapy-induced lung toxicity, whereas pyrexia without chills may be present [60]. On auscultation patients often have inspiratory crackles. The radiographic pattern is usually non-pathognomonic showing diffuse interstitial infiltrative or mixed alveolar-interstitial [60–62]. The decrease in DLCO may precede the clinical and radiographic manifestations of chemotherapy-induced pulmonary adverse events by weeks [60]. BAL can assist in these immunocompromised patients to differentiate DIRD from opportunistic infections and look for cytologic atypia ("bizarre" appearance of pneumocytes that confirm exposure to the drug but do not establish toxicity) [63].

Bleomycin

Primary use: Bleomycin is a cytotoxic mixture of peptide antibiotics obtained from *Streptomyces verticillus*. It is frequently used in the treatment of germ cell tumors and lymphomas [64].

Known or suspected mechanism of toxicity: Bleomycin-induced lung injury is attributed to direct toxicity due to oxidative damage to cell DNA by free radicals released by bleomycin-Fe complexes. If there is no detoxifying enzyme (bleomycin hydrolase), the bleomycin accumulates in the lungs causing proteolysis and direct endothelial injury. This in turn causes an ARDS-like picture with increase in the vascular permeability causing interstitial edema and formation of hyaline membranes caused by the accumulation of proteins and fluid into the alveoli. Multiple cytokines such as TNF-α, IL-1B, and TGF-B cause additional damage and type I pneumocyte apoptosis. These mechanisms lead to eventual fibrosis of the lung parenchyma and bronchi [20]. Risk factors for toxicity include (a) cumulative dose >400 IU/m^2, (b) radiation therapy, (c) exposure to high concentrations of oxygen, (d) young age, (e) impaired renal function, and (f) concurrent use of other chemotherapeutic agents [65].

Incidence of toxicity: It may affect up to 72% of children treated with bleomycin, and it carries a mortality of 1–2%.

Onset of toxicity: Bleomycin lung toxicity has even been reported to occur as late as 10 years after cessation of chemotherapy [66].

Table 10 Chemotherapeutic agents that may cause lung toxicity

Antibiotics	Alkylating agents	Antimetabolites	Nitrosamines	Podophyllotoxins	Immunomodulators	Miscellaneous
Bleomycin	Busulfan	Methotrexate	Bischloroethyl nitrosourea (BCNU)	Etoposide	Interferons (IFNs)	Procarbazine
Mitomycin C	Cyclophosphamide	Cytosine arabinoside	Methyl CCNU	All trans-retinoic acid (ATRA)	Tumor necrosis factor (TNF)-B	Vinblastine
	Chlorambucil	6-Mercaptopurine	Chloroethyl cyclohexyl nitrosourea (CCNU)	Paclitaxel	Interleukin (IL)-2	Zinostatin
	Melphalan	Gemcitabine		Gefitinib		
		Azathioprine		Docetaxel		
		Fludarabine		Imatinib mesylate		
				Novel antitumor agents		
				Irinotecan		

Clinical presentation: Bleomycin lung injury may manifest as a hypersensitivity reaction (acute onset, fever, and peripheral blood or BAL fluid eosinophilia) or in the form of progressive fibrosis [20]. The patient develops progressive exertional dyspnea and dry cough. Rarely, it can mimic metastatic disease, in the form of nodular pulmonary lesions [60]. Vascular toxicity with the development of intimal fibrosis and eventual pulmonary hypertension has been also reported.

Radiographic findings: High-resolution CT reveals a bilateral pattern of fine nodular infiltrates with bibasilar reticular pattern and can be also used for the monitoring of the toxicity [62].

Histologic findings: Type II pneumocyte hyperplasia, hemorrhage, and diffuse alveolar damage.

Pulmonary function testing: Restrictive lung disease with significant decrease in the diffusing capacity (DLCO). A decrease of >60% from baseline is considered to be an indication to discontinue the use of the medication [67]. Interestingly, children treated with lower doses of bleomycin have been found to develop hyperinflation and obstructing pattern.

Treatment of toxicity: Treatment consists of early withdrawal of bleomycin, avoidance of oxygen administration (if possible), and general supportive measures. The use of corticosteroids is a matter of ongoing debate [65, 68], but it should be used only as a last resort (provided that infection has been excluded) [68]. Corticosteroid use is more justified in bleomycin-induced eosinophilic pneumonitis [20].

Prognosis: The severity of the clinical picture depends on the extent of lung parenchyma involvement [68].

Mitomycin C

Primary use: As derivative of *Streptomyces caespitosus*, mitomycin C is an antibiotic mainly used in adult oncology (anal cancer, breast cancer, and non-small cell lung cancer).

Mechanism of toxicity: The mechanism is unclear, but toxicity appears to be dose dependent and also higher when higher concentrations of supplemental oxygen and concomitant administration of other drugs or radiation therapy [69].

Incidence of toxicity: The incidence of pulmonary toxicity for this antineoplastic antibiotic has been reported to be 8–39% [70].

Clinical presentation: Mitomycin C has been associated with a syndrome that consists of thrombotic microangiopathy and acute respiratory failure. Also, acute bronchospasm, interstitial pneumonitis, diffuse alveolar damage, pulmonary hypertension, and pleural disease have been reported [69].

Radiographic findings: Diffuse ground-glass or reticular opacities with occasional fine nodularity are characteristic in cases of mitomycin-induced interstitial pneumonitis.

Pulmonary function testing: DLCO decrease may not precede symptoms.

Treatment of toxicity: Discontinuation of the medication; compared to other chemotherapeutic agents, it appears to have better response to treatment with corticosteroids.

Prognosis: Usually good, except for mitomycin-induced interstitial pneumonitis (40% of patients with mitomycin-induced interstitial pneumonitis will end up with progressive pulmonary insufficiency despite initial good response to corticosteroids).

Cyclophosphamide

Primary use: Cyclophosphamide is an alkylating agent that is used in many malignancies (leukemias, lymphomas, and solid tumors) and in autoimmune disorders.

Known or suspected mechanism of toxicity: Pathogenetic mechanisms are considered to be similar to those of bleomycin-induced lung toxicity (inactivation of antioxidants and production of reactive oxygen metabolites) as well as immunologic reactions [20]. Differences in the local lung drug metabolism attributed to genetic variations may play a role [71], as is the administration of other cytotoxic [72] or noncytotoxic [73] drugs.

Incidence of toxicity: Less than 1% of the treated patients develop late-onset pneumonitis and fibrosis [74].

Onset of toxicity: Early onset occurs between 1 and 6 months after the initiation of treatment, whereas in the late onset, the manifestations may appear months to years after the initiation of treatment.

Clinical presentation: The toxicity presents as early pneumonitis within 6 months of exposure. The clinical symptoms are progressive dyspnea and nonproductive cough. Chest deformity attributed to growth failure during adolescence has been also reported [75].

Radiographic findings: Bilateral diffuse involvement and, occasionally, pleural thickening [20].

Pulmonary function testing: Restrictive pattern with a reduced diffusing capacity.

Histologic findings: Presence of atypical cells in the alveolar and bronchiolar epithelium, hyperplasia of type II pneumocytes, and interstitial and alveolar edema and fibrosis [76].

Treatment of toxicity: Discontinuation of the medication and administration of corticosteroids.

Prognosis: Variable; early onset toxicity is usually reversible. Patients with late-onset symptoms tend to have worse prognosis with than more than half dying due to progressive respiratory failure [76].

Chlorambucil

Primary use: It is used both as an antineoplastic agent and as an immunosuppressant.

Incidence of toxicity: Uncommon.

Onset of toxicity: No direct correlation between duration of treatment and onset of pulmonary toxicity [77].

Clinical presentation: Progressive dyspnea 6 months to 3 years after the initiation of the treatment [20, 60].

Radiographic findings: Reticular infiltrates with diffuse micronodular opacities on HRCT [77].

Histologic findings: Alveolar lining cell dysplasia, interstitial round cell infiltrates, and interstitial fibrosis [78].

Pulmonary function testing: Pattern of restrictive lung disease with gradual decrease in the diffusing capacity. The latter could be used as a practical way for the monitoring of the toxicity.

Treatment of toxicity: Drug withdrawal and administration of corticosteroids are the treatments of choice.

Prognosis: Poor with more than 50% mortality.

Busulfan

Primary use: This drug is used in bone marrow transplantations and—rarely in children—in chronic myelogenous leukemias.

Mechanism of toxicity: The mechanism is unclear, but direct toxicity to epithelial lining cells has been suggested.

Incidence of toxicity: Unknown, but is thought to occur in less than 8% of children treated with busulfan.

Onset of toxicity: Variable and potentially slow onset ranging from as early as 6 weeks to 10 years after the initiation of treatment.

Clinical presentation: Acute pneumonitis, alveolar hemorrhage, and chronic interstitial fibrosis. Cough and progressive exertional dyspnea are the main symptoms; weight loss and pyrexia may occasionally be present. Physical examination may reveal bibasilar crackles.

Radiographic findings: Radiologic involvement (ground-glass opacities, asymmetric peripheral and peribronchial consolidation, centrilobular nodules, reticulation, and dependent consolidation on HRCT) is usually more impressive compared to other chemotherapeutics [60].

Pulmonary function testing: Restrictive pattern with gradual decrease in the diffusing capacity.

Treatment of toxicity: Drug withdrawal and a trial of corticosteroids comprise the only therapeutic options combined with supportive care.

Prognosis: Busulfan-induced fibrosis tends to cause higher mortality than other chemotherapeutic agents; most patients experience progressive respiratory failure and succumb [60].

Carmustine (Bischloroethyl Nitrosourea, BCNU)

Primary use: Carmustine (bischloroethyl nitrosourea, BCNU) is a highly lipid-soluble nitrosourea compound used in the treatment of lymphomas and gliomas and in bone marrow transplantation.

Known or suspected mechanism of toxicity: BCNU is known to cause lung fibrosis that tends to be more prevalent in the upper lung zones. A peculiar feature of BCNU toxicity is the development of pneumothorax; this complication has been associated with the unique topography of lung fibrosis [60]. It has been suggested that co-administration of thymidine may potentiate carmustine's efficacy and at the same time prevent its lung toxicity through modulation of DNA repair enzymes in unaffected tissue [79].

Incidence of toxicity: Late-onset fibrosis has been reported in 20–30% of patients treated with BCNU, but it can be as high 50% among those treated with doses >1500 mg/m^2.

Onset of toxicity: Variable, ranging from as early as 1 month to months or years after the initiation of therapy.

Clinical presentation: Clinical and histopathological characteristics of BCNU toxicity resemble those of bleomycin and cyclophosphamide [20, 60].

Radiographic findings: In early onset lung fibrosis, the more common imaging findings are bilateral diffuse opacities or nodules, localized consolidation, and localized or diffuse interstitial fibrotic changes. In late-onset lung fibrosis, upper zone patchy and linear opacities, volume loss, and apical pleural thickening are the more common radiologic findings.

Pulmonary function testing: Restrictive pattern (with gradual decrease in the diffusing capacity in early onset lung fibrosis but not in late-onset toxicity).

Treatment of toxicity: Treatment options are limited (drug withdrawal and corticosteroids).

Prognosis: Unpredictable but the mortality tends to be much higher compared to that of other chemotherapeutics. Late-onset BCNU lung toxicity carries a worse prognosis.

Methotrexate

Primary use: Methotrexate is a folic acid antagonist used in the treatment of a variety of malignant and nonmalignant conditions (such as juvenile idiopathic arthritis, inflammatory bowel diseases, and psoriasis) due to its antiproliferative, anti-inflammatory, and immunomodulating effects [80].

Known or suspected mechanism of toxicity: The mechanism of lung toxicity secondary to the use of this folate analog is not clear [81]; direct toxicity, hypersensitivity reaction, impaired host resistance to acquired or latent viral infection, and modulation of cytokine expression have been implicated [80, 81]. The toxicity appears to depend on the disease for which the patient is treated with methotrexate [82]. The toxicity does not appear to be dose related.

Incidence of toxicity: 0.3–7.5% [83] but the true incidence may be different; many of the diseases for which the drug is given can cause pulmonary complications. In addition methotrexate is often given together with other drugs that may cause their own toxicity.

Onset of toxicity: The clinical presentation may be acute, subacute, or chronic (range, 12 days to 18 years posttreatment onset).

Clinical presentation: Typically, the patient experiences gradually worsening respiratory distress, progressive nonproductive exertional cough, and occasional thoracic pain [84]. A prodrome of malaise and headache is seen in the acute presentation, which is accompanied by eosinophilia (i.e., features indicative of a hypersensitivity mechanism) [85]. Fine bibasilar crackles are frequently noted on auscultation and hypoxemia is a common finding [84]. Auscultation findings may be disproportionately scarce as compared to the extensive radiologic involvement [83].

Radiographic findings: Chest radiographs usually reveal a diffuse interstitial pattern, with hilar lymphadenopathy. However, unilateral localization, pleural effusions, and a reticulonodular appearance have been also reported in some patients [60, 61, 83].

Pulmonary function testing: Restrictive pattern with a decrease in the diffusing capacity for carbon monoxide (DLCO), hypoxemia, and an increased alveolar-arterial (A-a) gradient [80].

Laboratory findings: The bronchoalveolar lavage fluid shows usually a lymphocytic pattern that is non-specific. The main indication of the BAL is to rule out the presence of infection that may produce similar clinical picture.

Histologic findings: The histologic features of methotrexate toxicity include interstitial inflammation, interstitial fibrosis, type II pneumocyte hyperplasia, granuloma formation, increased intra-alveolar macrophages, and giant cells [82].

Treatment of toxicity: Discontinuation of the medication and—in the more severe cases—administration of corticosteroids are the only available therapeutic approaches.

Prognosis: The prognosis appears to be more favorable as compared to other chemotherapy-induced pneumonitis [60], but fatalities have been reported [82] with a mortality of 13% [80]. Survivors may have persistent physiologic abnormalities [82].

Azathioprine

Primary use: Azathioprine is a prodrug of 6-mercaptopurine that is used to prevent organ transplant rejection and also in a wide array of autoimmune diseases as a steroid-sparing agent.

Mechanism of toxicity: Unclear.

Incidence of toxicity: Low.

Clinical presentation: Interstitial pneumonitis, acute respiratory distress syndrome, and diffuse alveolar hemorrhage [86, 87].

Radiographic findings: Diffuse bilateral interstitial infiltrates.

Histologic findings: Diffuse alveolar damage (hyaline membranes, intra-alveolar edema, and cuboidalization of alveolar epithelium) and usual interstitial pneumonia (reorganization of distal air spaces, atypical epithelial hyperplasia, and varying degrees of fibrosis) are the typical histopathologic patterns [87].

Pulmonary function testing: Restrictive pattern.

Treatment of toxicity: Drug withdrawal and administration of steroids.

Prognosis: Most patients improve following discontinuation of the drug, but fatalities have been reported [86, 87].

Epilogue

The ever expanding list of drugs causing lung toxicity should prompt the busy general pediatrician and specialist alike to refer to current literature and frequently updated websites when considering in their differential diagnosis the possibility of DIRD [8].

References

1. Matsuno O. Drug-induced interstitial lung disease: mechanisms and best diagnostic approaches. Respir Res. 2012;13:39.
2. Ryrfeldt A. Drug-induced inflammatory responses to the lung. Toxicol Lett. 2000;112–113:171–6.
3. Delaunois LM. Mechanisms in pulmonary toxicology. Clin Chest Med. 2004;25(1):1–14.
4. Kubo K, Azuma A, Kanazawa M, Kameda H, Kusumoto M, Genma A, et al. Consensus statement for the diagnosis and treatment of drug-induced lung injuries. Respir Invest. 2013;51(4):260–77.
5. Steinfeld J, Schidlow DV. Therapy-induced pulmonary disease. In: Taussig LM, Landau LI, editors. Pediatric respiratory medicine. 2nd ed. Philadelphia: Mosby Elsevier; 2008. p. 359–63.
6. Camus P, Fanton A, Bonniaud P, Camus C, Foucher P. Interstitial lung disease induced by drugs and radiation. Respiration. 2004;71(4):301–26.
7. Foucher P, Biour M, Blayac JP, Godard P, Sgro C, Kuhn M, et al. Drugs that may injure the respiratory system. Eur Respir J. 1997;10(2):265–79.
8. Camus PH. Pneumotox online. The drug-induced respiratory disease website. Department of Pulmonary Medicine and Intensive Care University Hospital, Dijon, France; 2016. http://www.pneumotox.com/. Accessed 27 Nov 2016.
9. Huggins JT, Sahn SA. Drug-induced pleural disease. Clin Chest Med. 2004;25(1):141–53.
10. Antony VB. Drug-induced pleural disease. Clin Chest Med. 1998;19(2):331–40.
11. Schwarz MI, Fontenot AP. Drug-induced diffuse alveolar hemorrhage syndromes and vasculitis. Clin Chest Med. 2004;25(1):133–40.

12. Irey NS. Tissue reactions to drugs. Am J Pathol. 1976;82(3):613–48.
13. Camus P, Rosenow EC 3rd. Iatrogenic lung disease. Clin Chest Med. 2004;25(1):XIII–XIX.
14. Flieder DB, Travis WD. Pathologic characteristics of drug-induced lung disease. Clin Chest Med. 2004;25(1):37–45.
15. Dykhuizen RS, Zaidi AM, Godden DJ, Jegarajah S, Legge JS. Minocycline and pulmonary eosinophilia. BMJ. 1995;310(6993):1520–1.
16. Kabbara WK, Kordahi MC. Nitrofurantoin-induced pulmonary toxicity: a case report and review of the literature. J Infect Public Health. 2015;8(4):309–13.
17. Bhullar S, Lele SM, Kraman S. Severe nitrofurantoin lung disease resolving without the use of steroids. J Postgrad Med. 2007;53(2):111–3.
18. D'Arcy PF. Nitrofurantoin. Drug Intell Clin Pharm. 1985;19(7–8):540–7.
19. Holmberg L, Boman G, Bottiger LE, Eriksson B, Spross R, Wessling A. Adverse reactions to nitrofurantoin. Analysis of 921 reports. Am J Med. 1980;69(5):733–8.
20. Henry MM, Noah TL. Lung injury caused by pharmacologic agents. In: Boat TF, Bush A, Chernick V, Deterding RR, Ratjen F, editors. Kendig & Chernick's disorders of the respiratory tract in children. 8th ed. Philadelphia: WB Saunders; 2012. p. 1026–35.
21. Rosenow EC III, DeRemee RA, Dines DE. Chronic nitrofurantoin pulmonary reaction. Report of 5 cases. N Engl J Med. 1968;279(23):1258–62.
22. Mullerpattan JB, Dagaonkar RS, Shah HD, Udwadia ZF. Fatal nitrofurantoin lung. J Assoc Physicians India. 2013;61(10):758–60.
23. Williams EM, Triller DM. Recurrent acute nitrofurantoin-induced pulmonary toxicity. Pharmacotherapy. 2006;26(5):713–8.
24. Branley HM, Kolvekar S, Brull D. Minocycline induced organising pneumonia resolving without recourse to corticosteroids. Respir Med. 2009;2:137–40.
25. Wright DG, Robichaud KJ, Pizzo PA, Deisseroth AB. Lethal pulmonary reactions associated with the combined use of amphotericin B and leukocyte transfusions. N Engl J Med. 1981;304(20):1185–9.
26. Collazos J, Martinez E, Mayo J, Ibarra S. Pulmonary reactions during treatment with amphotericin B: review of published cases and guidelines for management. Clin Infect Dis. 2001;33(7):E75–82.
27. Parry SD, Barbatzas C, Peel, Barton JR. Sulphasalazine and lung toxicity. Eur Respir J. 2002;19(4):756–64.
28. Mansi A, Cucchiara S, Greco L, Sarnelli P, Pisanti C, Franco MT, et al. Bronchial hyperresponsiveness in children and adolescents with Crohn's disease. Am J Respir Crit Care Med. 2000;161(3 Pt 1):1051–4.
29. Valletta E, Bertini M, Sette L, Braggion C, Pradal U, Zannoni M. Early bronchopulmonary involvement in Crohn disease: a case report. BMC Gastroenterol. 2001;1:13.
30. Davies D, MacFarlane A. Fibrosing alveolitis and treatment with sulphasalazine. Gut. 1974;15(3):185–8.
31. Leino R, Liippo K, Ekfors T. Sulphasalazine-induced reversible hypersensitivity pneumonitis and fatal fibrosing alveolitis: report of two cases. J Intern Med. 1991;229(6):553–6.
32. Pawadshettar S, Acharya VK, Arun M, Unnikrishnan M, Tantry BV. Penicillamine in interstitial lung disease: a timely remainder of an old foe. Asian J Pharm Clin Res. 2016;9(1):1–3.
33. Labombarda F, Ou P, Stos B, de Blic J, Villain E, Sidi D. Acute amiodarone-induced pulmonary toxicity: an association of risk factors in a child operated by arterial switch operation. Congenit Heart Dis. 2008;3(5):365–7.
34. Kothari SS, Balijepally S, Taneja K. Amiodarone-induced pulmonary toxicity in an adolescent. Cardiol Young. 1999;9(2):194–6.
35. Abuzaid A, Saad M, Ayan M, Kabach A, Haddad TM, Smer A, et al. Acute amiodarone pulmonary toxicity after drug holiday: a case report and review of the literature. Case Rep Cardiol. 2015;2015:927438.
36. Camus P, Martin WJ II, Rosenow EC 3rd. Amiodarone pulmonary toxicity. Clin Chest Med. 2004;25(1):65–75.

37. Wolkove N, Baltzan M. Amiodarone pulmonary toxicity. Can Respir J. 2009;16(2):43–8.
38. Kang IS, Kim KJ, Kim Y, Park SH. The diagnostic utility of chest computed tomography scoring for the assessment of amiodarone-induced pulmonary toxicity. Korean J Intern Med. 2014;29(6):746–53.
39. Magro SA, Lawrence EC, Wheeler SH, Krafchek J, Lin HT, Wyndham CR. Amiodarone pulmonary toxicity: prospective evaluation of serial pulmonary function tests. J Am Coll Cardiol. 1988;12(3):781–8.
40. Sweidan AJ, Singh NK, Dang N, Lam V, Datta J. Amiodarone-induced pulmonary toxicity—a frequently missed complication. Clin Med Insight Case Rep. 2016;9:91–4.
41. Myers JL, Kennedy JI, Plumb VJ. Amiodarone lung: pathologic findings in clinically toxic patients. Hum Pathol. 1987;18(4):349–54.
42. Martin WJ II, Rosenow EC III. Amiodarone pulmonary toxicity. Recognition and pathogenesis (Part 2). Chest. 1988;93(6):1242–8.
43. Martin WJ II, Rosenow EC III. Amiodarone pulmonary toxicity. Recognition and pathogenesis (Part I). Chest. 1988;93(5):1067–75.
44. Oelze LL, Pillow MT. Phenytoin-induced drug reaction with eosinophilia and systemic symptoms (DRESS) syndrome: a case report from the emergency department. J Emerg Med. 2013;44(1):75–8.
45. Hazlett DR, Ward GW Jr, Madison DS. Pulmonary function loss in diphenylhydantoin therapy. Chest. 1974;66(6):660–4.
46. Dixit R, Dixit K, Nuwal P, Banerjee A, Sharma S, Dave L. Diphenylhydantoin (phenytoin)-induced chronic pulmonary disease. Lung India. 2009;26(4):155–8.
47. Michael JR, Rudin ML. Acute pulmonary disease caused by phenytoin. Ann Intern Med. 1981;95(4):452–4.
48. Nascimento FA, Takeshita BT, Kowacs PA. Phenytoin-induced isolated chronic, nocturnal dry cough. Epilepsy Behav Case Rep. 2016;5:44–5.
49. Polman AJ, van der Werf TS, Tiebosch AT, Zijlstra JG. Early-onset phenytoin toxicity mimicking a renopulmonary syndrome. Eur Respir J. 1998;11(2):501–3.
50. Kang CK, Kim MK, Kim MJ, Jun KI, Kim KW, Park SH, et al. Acute respiratory failure caused by phenytoin overdose. Korean J Intern Med. 2013;28(6):736–8.
51. Yermakov VM, Hitti IF, Sutton AL. Necrotizing vasculitis associated with diphenylhydantoin: two fatal cases. Hum Pathol. 1983;14(2):182–4.
52. Goncalves D, Moura R, Ferraz C, Vitor AB, Vaz L. Carbamazepine-induced interstitial pneumonitis associated with pan-hypogammaglobulinemia. Respir Med Case Rep. 2012;5:6–8.
53. Banka R, Ward MJ. Bronchiolitis obliterans and organising pneumonia caused by carbamazepine and mimicking community acquired pneumonia. Postgrad Med J. 2002;78(924):621–2.
54. Narita H, Ozawa T, Nishiyama T, Matsumoto S, Watanabe S, Isshiki A. An atypical case of fulminant interstitial pneumonitis induced by carbamazepine. Curr Drug Saf. 2009;4(1):30–3.
55. Halink DA, Marijnissen RM, Schut AA, Oude Voshaar RC. Drug reaction with eosinophilia and systemic symptoms induced by carbamazepine: DRESSed to kill. Gen Hosp Psychiatry. 2011;33(4):412e5–8.
56. Liles A, Blatt J, Morris D, Wardrop R 3rd, Sharma A, Sznewajs A, et al. Monitoring pulmonary complications in long-term childhood cancer survivors: guidelines for the primary care physician. Cleve Clin J Med. 2008;75(7):531–9.
57. Mertens AC, Yasui Y, Liu Y, Stovall M, Hutchinson R, Ginsberg J, et al. Pulmonary complications in survivors of childhood and adolescent cancer. A report from the Childhood Cancer Survivor Study. Cancer. 2002;95(11):2431–41.
58. Armenian SH, Landier W, Francisco L, Herrera C, Mills G, Siyahian A, et al. Long-term pulmonary function in survivors of childhood cancer. J Clin Oncol. 2015;33(14):1592–600.
59. Marom EM, Onn A, McAleer MF. Complications in the oncologic patient: chest. In: Oncologic imaging: a multidisciplinary approach. Philadelphia: Saunders; 2012. p. 679–91.
60. Limper AH. Chemotherapy-induced lung disease. Clin Chest Med. 2004;25(1):53–64.

61. Lindell RM, Hartman TE. Chest imaging in iatrogenic respiratory disease. Clin Chest Med. 2004;25(1):15–24.
62. Rossi SE, Erasmus JJ, McAdams HP, Sporn TA, Goodman PC. Pulmonary drug toxicity: radiologic and pathologic manifestations. Radiographics. 2000;20:1245–59.
63. Costabel U, Guzman J, Bonella F, Oshimo S. Bronchoalveolar lavage in other interstitial lung diseases. Semin Respir Crit Care Med. 2007;28:514–24.
64. Biya J, Stoclin A, Dury S, Le Pavec J, Mir O, Lazarovici J, et al. Consortium for detection and management of lung damage induced by bleomycin. Bull Cancer. 2016;103(7–8):651–61.
65. Azambuja E, Fleck JF, Batista RG, Menna Barreto SS. Bleomycin lung toxicity: who are the patients with increased risk? Pulm Pharmacol Ther. 2005;18(5):363–6.
66. Tashiro M, Izumikawa K, Yoshioka D, Nakamura S, Kurihara S, Sakamoto N, et al. Lung fibrosis 10 years after cessation of bleomycin therapy. Tohoku J Exp Med. 2008;216(1):77–80.
67. Luursema PB, Star-Kroesen MA, van der Mark TW, Sleyfer DT, Koops HS, Peset R. Bleomycin-induced changes in the carbon monoxide transfer factor of the lungs and its components. Am Rev Respir Dis. 1983;128(5):880–3.
68. Froudarakis M, Hatzimichael E, Kyriazopoulou L, Lagos K, Pappas P, Tzakos AG, et al. Revisiting bleomycin from pathophysiology to safe clinical use. Crit Rev Oncol Hematol. 2013;87(1):90–100.
69. Chan ED, King TE. Mitomycin-C pulmonary toxicity 2016 [updated 16 Sep 2016]. http://www.uptodate.com/contents/mitomycin-c-pulmonary-toxicity#H420682.
70. Linette DC, McGee KH, McFarland JA. Mitomycin-induced pulmonary toxicity: case report and review of the literature. Ann Pharmacother. 1992;26(4):481–4.
71. Hoyt DG, Lazo JS. Acute pneumocyte injury, poly(ADP-ribose) polymerase activity, and pyridine nucleotide levels after in vitro exposure of murine lung slices to cyclophosphamide. Biochem Pharmacol. 1994;48(9):1757–65.
72. Mileshkin L, Prince HM, Rischin D, Zimet A. Severe interstitial pneumonitis following high-dose cyclophosphamide, thiotepa and docetaxel: two case reports and a review of the literature. Bone Marrow Transplant. 2001;27(5):559–63.
73. Bhagat R, Sporn TA, Long GD, Folz RJ. Amiodarone and cyclophosphamide: potential for enhanced lung toxicity. Bone Marrow Transplant. 2001;27(10):1109–11.
74. Segura A, Yuste A, Cercos A, Lopez-Tendero P, Girones R, Perez-Fidalgo JA, et al. Pulmonary fibrosis induced by cyclophosphamide. Ann Pharmacother. 2001;35(7–8):894–7.
75. Alvarado CS, Boat TF, Newman AJ. Late-onset pulmonary fibrosis and chest deformity in two children treated with cyclophosphamide. J Pediatr. 1978;92(3):443–6.
76. Specks U. Cyclophosphamide pulmonary toxicity [updated 21 Aug 2015]. http://www.uptodate.com/contents/cyclophosphamide-pulmonary-toxicity.
77. Dweik RA. Chlorambucil-induced pulmonary injury [updated 3 June 2015]. http://www.uptodate.com/contents/chlorambucil-induced-pulmonary-injury.
78. Cole SR, Myers TJ, Klatsky AU. Pulmonary disease with chlorambucil therapy. Cancer. 1978;41(2):455–9.
79. Hwu WJ, Mozdziesz DE. Molecular basis for thymidine modulation of the efficacy and toxicity of alkylating agents. Pharmacol Ther. 1997;76(1–3):101–16.
80. Balk RA. Methotrexate-induced lung injury [updated 21 July 2016]. http://www.uptodate.com/contents/methotrexate-induced-lung-injury.
81. Kim YJ, Song M, Ryu JC. Mechanisms underlying methotrexate-induced pulmonary toxicity. Expet Opin Drug Saf. 2009;8:451–8.
82. Imokawa S, Colby TV, Leslie KO, Helmers RA. Methotrexate pneumonitis: review of the literature and histopathological findings in nine patients. Eur Respir J. 2000;15(2):373–81.
83. Barrera P, Laan RF, van Riel PL, Dekhuijzen PN, Boerbooms AM, van de Putte LB. Methotrexate-related pulmonary complications in rheumatoid arthritis. Ann Rheum Dis. 1994;53(7):434–9.

84. Kremer JM, Alarcon GS, Weinblatt ME, Kaymakcian MV, Macaluso M, Cannon GW, et al. Clinical, laboratory, radiographic, and histopathologic features of methotrexate-associated lung injury in patients with rheumatoid arthritis: a multicenter study with literature review. Arthritis Rheum. 1997;40(10):1829–37.
85. Rosenow EC 3rd, Limper AH. Drug-induced pulmonary disease. Semin Respir Infect. 1995;10(2):86–95.
86. Scherbak DWR, Singarajah C. Azathioprine associated acute respiratory distress syndrome: case report and literature review. Southwest J Pulm Crit Care. 2014;9(2):94–100.
87. Bedrossian CW, Sussman J, Conklin RH, Kahan B. Azathioprine-associated interstitial pneumonitis. Am J Clin Pathol. 1984;82(2):148–54.

Pulmonary Complications of Radiation Therapy

Donna J. Lee, Daphna Gelblum, and Nancy Lee

Abbreviations

cAMP	Cyclic adenosine monophosphate
COPD	Chronic obstructive pulmonary disease
CTCAE	Common Terminology Criteria for Adverse Event
EORTC	European Organisation for the Research and Treatment of Cancer
FDA	Federal Drug Administration
FEV1	Forced expiratory volume in 1 second
FGFR	Fibroblast growth factor receptor
Gy	Gray
IL-8	Interleukin 8
IMRT	Intensity-modulated radiotherapy
PDGFR	Platelet-derived growth factor
PFT	Pulmonary function testing
QUANTEC	Quantitative Analysis of Normal Tissue Effects in the Clinic
RIF	Radiation-induced fibrosis

D.J. Lee, M.D. (✉)
Section of Pediatric Pulmonology, Joseph M. Sanzari Children's Hospital, Hackensack University Medical Center, Hackensack, NJ, USA
e-mail: Donna.Lee@hackensackmeridian.org

D. Gelblum, M.D.
Department of Radiation Oncology, Memorial Sloan Kettering Cancer Center, West Harrison, NY, USA
e-mail: gelblumd@msk.org

N. Lee, M.D.
Department of Radiation Oncology, Memorial Sloan Kettering Cancer Center, New York, NY, USA
e-mail: Leen2@mskcc.org

© Springer International Publishing AG 2018

A.C. Koumbourlis, M.A. Nevin (eds.), *Pulmonary Complications of Non-Pulmonary Pediatric Disorders*, Respiratory Medicine,
https://doi.org/10.1007/978-3-319-69620-1_15

RILI	Radiation-induced lung injury
RP	Radiation pneumonitis
RT	Radiation therapy
RTOG	Radiation Therapy Oncology Group
SBRT	Stereotactic body radiotherapy
SNP	Single nucleotide polymorphism
TBI	Total body irradiation
TGFβ1	Transforming growth factor beta 1
VEGFR	Vascular endothelial growth factor receptor

Introduction

Radiation therapy (RT) has emerged as an important form of treatment for many types of cancer. It is estimated that more than half of patients with cancer will receive RT as part of their cancer treatment [1]. RT is an important part of the therapeutic regimen for malignancies in and around the thoracic cavity such as primary head and neck cancer, lung cancer, breast cancer, esophageal cancer, and hematologic malignancies [2]. Due to the radiosensitivity (tolerance of cells to the harmful effects of radiation) of lung tissue, radiation-induced lung injury (RILI) is a potential serious complication of thoracic radiation and often is the dose-limiting factor for the prescribed radiation dose. RILI can present early after therapy (within 6 months of treatment completion) as radiation pneumonitis (RP) and/or later as radiation-induced fibrosis (RIF).

The incidence of RILI is not well known; however, symptomatic RP (i.e., patient requiring therapy) has been estimated in the literature to occur in 5–35% of patients receiving thoracic radiation. The large range in reported incidence may be attributed to the non-specific presentation of radiation pneumonitis. Although radiation-induced lung injury refers to both radiation pneumonitis and fibrosis, the majority of literature is concentrated on RP due to its early symptomatic presentation [3–6].

Pathology

Radiosensitivity refers to the susceptibility of cells to the harmful effect of ionizing radiation and is directly proportional to the rate of cell division and inversely proportional to cell differentiation [7]. Highly differentiated cells without ability to replicate, such as cells of the brain, muscle, and nerves, are less susceptible to radiation. In contrast, poorly differentiated rapid replicating cells, such as cancerous cells, are highly sensitive to radiation effect [8]. The lung is a complex organ consisting of series of conducting airways that end in terminal gas exchange units, the alveolar capillary subunits. Although the mucosal lining of the airway can also be damaged during radiation, the depleted mucosa often will promptly be replaced after RT. Thus radiation injury of the conducting airways is uncommon. However,

airway stenosis and fatal hemoptysis have been reported as consequences of external beam radiation [9, 10].

The most radiosensitive subunit of the lung remains the alveolar capillary subunit. The alveolar capillary subunit consists of the alveolar surface, endothelial surface, and the stromal or interstitial space. The alveolar surface is made up of type I pneumocytes which are highly differentiated squamous cells. Type I cells stretch very thin to provide a large surface area for gas exchange. Type I cells cover about 90–95% of the gas exchange area; however, type I pneumocytes cannot replicate and thus are susceptible to injury and insult. Should insult result in cell death, type II pneumocytes will differentiate and replace type I pneumocytes. Although type II pneumocytes cover only a small fraction, roughly 5%, of the alveolar surface area, they are more abundant than type I cells. Type II cells function in the production and secretion of surfactant which decreases the surface tension within the alveoli and replenishes damaged type I cells. Alveolar capillaries are unique in that the vessels consist of a single layer of endothelial cells resting upon a basement membrane. These capillaries are located within the walls of the alveoli separated only by the basement membrane and a potential interstitial space, which may contain fibroblast and collagen [11].

Radiation of normal lung tissue can lead to damage of the alveolar capillary subunit by direct cell death and the release of inflammatory cytokine resulting in inflammation and damage. Radiation can also damage DNA directly leading to cell death or via the presence of free oxygen and nitrogen radicals resulting in chronic oxidative stress. When type I pneumocytes and endothelial cells die, they detach from the basement membrane resulting in exudation of fibrinous material and activation of inflammatory cytokines in the interstitial and alveolar space. Extravasated fibrin and cytokines lead to formation of hyaline membrane impairing gas exchange resulting in hypoxemia. Radiation also leads to death of type II pneumocytes. The inability of the dying type II cells to replenish dead type I pneumocytes results in sustained damage to the alveolar capillary subunit. Radiation also induces release of a large number of cytokines including interleukin 8 (IL-8) and transforming growth factor β 1 (TGFβ1). Influx of TGFβ1 leads to the influx of fibroblasts. After this active pneumonitis stage, lung tissue can repair and restore the alveolar blood barrier or continue further inflammation and poor repair leading to fibrosis [12–18].

Clinical Presentation

Radiation-induced lung injury can present early or late after treatment delivery. Radiation pneumonitis, an early phase injury, typically presents within 6 months after therapy but can present as early as 1 month after completion. Symptoms are typically insidious in onset within the mentioned time frame and are non-specific. The most common presentation is that of dyspnea. Other symptoms such as dry cough, low-grade fever, and chest pain have also been reported. Patients may also have constitutional complaints such as weight loss, fatigue, and malaise presumably due to increased energy expenditure from increased work of breathing. The exam is often non-specific with findings ranging from normal breath sounds to crackles and/or pleural rubs.

Radiologic Features

Most patients after radiation therapy have changes on radiographs whether symptomatic or not. These changes can occur as soon as after the first few doses of RT presumably due to release of surfactant and extravasation of plasma into alveolar space [19]. Although most radiation-induced changes typically occur within the area of the radiation field, changes outside of the radiation field can be seen as well. Findings on chest radiographs are non-specific ranging from ground glass appearance to infiltrates, volume loss, and pleural effusions. Chest CT is more sensitive in detecting parenchymal changes than plain radiograph. Findings on CT scan, however, are not pathognomonic for radiation injury. Most common findings are ground glass opacity or consolidation with sharp linear edges corresponding to the treatment portal. Traction bronchiectasis has also been described [20, 21, 23, 24].

Multiple classification systems for radiation pneumonitis have been developed for the purpose of reporting adverse events. Two of the most commonly used scoring systems reported in the literature include that of CTCAE (Common Terminology Criteria for Adverse Event) and RTOG/EORTC (Radiation Therapy Oncology Group/European Organisation for the Research and Treatment of Cancer). These

Table 1 Severity grading of radiation pneumonitis

Grade	1	2	3	4	5
CTCAE	Asymptomatic; clinical or diagnostic observations only; intervention not indicated	Symptomatic medical intervention indicated; limiting instrumental ADL	Severe symptoms; limiting self care ADL; oxygen indicated	Life-threatening respiratory compromise; urgent intervention indicated (e.g., tracheotomy or intubation)	Death
ROTG/ EORTC	Asymptomatic or mild symptoms (dry cough) Slight radiographic appearances	Moderate symptomatic fibrosis or pneumonitis (severe cough) Low-grade fever Patchy radiographic appearances	Severe symptomatic fibrosis or pneumonitis Dense radiographic changes	Severe respiratory insufficiency/ continuous O_2/ assisted ventilation	Death

CTCAE Common Terminology Criteria for Adverse Events, *CXR* chest X-ray, *ADL* activity of daily living, *O_2* oxygen, *RTOG* Radiation Therapy Oncology Group, *EORTC* European Organisation for the Research and Treatment of Cancer

Note: Table derived from information found on CTCAE v4.03. Cancer Therapy Evaluation Program. Common Terminology for Adverse Events, Version 4.03. National Cancer Institute https://evs.nci.nih.gov/ftp1/CTCAE/About.html; and RTOG/EORTC Late Radiation Morbidity Scorin0067 Schema https://www.rtog.org/ResearchAssociates/AdverseEventReporting/RTOGEORTCLateRadiationMorbidityScoringSchema.aspx

scoring systems report five grades of RP ranging from asymptomatic (grade 1) to death (grade 5) due to radiation pneumonitis (see Table 1). Minor differences are seen within grades 2–4 amongst the different reporting systems. In both systems patients with grade 2 or higher symptoms are symptomatic with dyspnea and limitation of function. Grade 4 patients progress to respiratory failure and need ventilator support, and grade 5 patients die as a result of RP. Patients with RP that are grade 2 or higher require treatment [25, 26].

Radiation-induced fibrosis (RIF), a late phase injury, occurs often between 6 months and 2 years after RT and can occur anywhere in the treatment area not limited to the lung tissue. Lung fibrosis due to RT can occur in isolation or after resolution of RP. Severity of respiratory symptoms correlates to the degree of lung fibrosis including mild to severe limitation, development of secondary pulmonary hypertension, or to full right heart failure/cor pulmonale. Physical exam is again non-specific ranging from mild adventitious breath sounds on exam to tachypnea, cyanosis, clubbing, and signs consistent with right heart failure [16].

Risk Factors

Treatment-Related Risk Factors

The majority of studies looking at risk of radiation pneumonitis are derived from studies of patients treated for non-small cell lung cancer. Risk factors for developing radiation-induced lung injury are divided into treatment factors and patient factors. The treatment factors most important in radiation-induced lung injury are lung volume and total dose delivered. Radiation dose is measured in gray (Gy) where 1 Gy is 1 joule per kilogram of absorbed radiation. The typical dose of radiation used in the treatment of lung cancer is in the range of 45–74 Gy, depending on the clinical situation. The Quantitative Analysis of Normal Tissue Effects in the Clinic (QUANTEC) consisted of a group of physicians and researchers who systematically examined the literature and compiled the list of normal tissue radiation tolerance. Based on the QUANTEC report, the normal lung dose should be limited to mean dose below 20 Gy, and 20 Gy should not be delivered to more than 35% of the total lung volume [27]. Per work by Marks et al., if both of these guidelines are followed, the risk of radiation pneumonitis will be less than 20% [28].

Radiation involving the thorax is most extensively used and studied for treatment of primary lung cancer therapy. Other than treatment for lung cancer, RT involving thoracic cavity can be given as total body irradiation (TBI), an important part of conditioning regimen for bone marrow transplant, or directed at the thorax as part of lymphoma therapy. TBI involving the lung can be given as single dose or fractionated into multiple doses. For primary lung cancer or large tumors within the lung, 3D conformal therapy or intensity-modulated radiotherapy (IMRT) is often

the treatment modality of choice. Both IMRT and 3D conformal therapy use multiple beams of radiation that conform to the outlines of the tumor thereby reducing the inclusion of normal lung tissue. For smaller inoperable tumors, stereotactic body radiotherapy (SBRT), a more sophisticated form of IMRT, is used. SBRT employs multiple beams of radiation from different directions converging on the target tumor resulting in delivery of high dose. These forms of RT allow for less radiation travel through healthy lung tissue but converge at the tumor to deliver the intended high dose. More recent advances of radiotherapy include proton beam radiotherapy that uses a 3D approach or even more advanced intensity-modulated proton therapy. The goals of these modalities are to limit the dose delivered to the healthy lung tissue.

Primary lung cancer is extremely rare in children; therefore, RILI is more often seen secondary to total body irradiation (TBI) before bone marrow transplant. With TBI, most literature suggest limiting single fraction radiation to a mean lung dose of 20 Gy and using a low dose rate schedule. Both are associated with less risk of developing symptomatic RP [29]. The risk of RP is even lower if a multiple fraction regimen is used [30–34].

Patients with locally advanced lung cancer may need more aggressive therapy with both RT and chemotherapy. Early RTOG trials demonstrated that the addition of chemotherapy delivered concurrently with the radiation further increases the risk of RP compared to sequential RT followed by chemotherapy [35]. In contrast, a recent meta-analysis demonstrated that sequential chemotherapy yields a higher risk of RP as well [36]. Despite the higher risk for RT-induced lung injury seen with either concurrent or sequential chemotherapy, chemoradiotherapy may be necessary treatment modality for patients with advanced lung cancer. Bleomycin, gemcitabine, paclitaxel, and carboplatin are amongst the chemotherapy agents that have been shown to increase the risk of developing RT-induced lung injury [35, 37].

Nontreatment-Related Risk Factors

Besides treatment factors, individual patient factors also play a role in development of radiation pneumonitis. These risk factors are well summarized in a recent review published in *Seminars of Radiation*. This comprehensive review looked at all non-dosimetric risk factors that have been published in the literature for the development of radiation-induced lung toxicity. These non-dosimetric factors are discussed in detail below [38].

Although no specific age is identified as risk factor due to conflicting results and heterogeneity amongst the old age reported, older age should be considered as a possible risk factor for development of RP. The majority of studies found that age > 68 years seems to correlate with higher incidence for the development of RP. These studies showed that there is increased odds ratio for radiation pneumoni-

tis with advanced age as compared to younger age [39–41]. However, the same is not seen when the age cutoff is lowered to 60 years [42]. More conflicting result is seen when sex is used as predictive indicator. Although some studies demonstrate that women may be at higher risk for RP, this effect is lost when meta-analysis was applied [36]. There is no apparent bias in the development of radiation pneumonitis based on sex of the patient and tumor stage or volume.

Tumor location also is important in prediction of RP. A higher rate of RP is reported in patients with tumors in the lower lung fields. There is no clear explanation that exists for this finding, but speculations include that of more dense lung tissue in the lower lobes due to gravity resulting in more alveolar capillary subunits involved, more respiratory movement in the lower lung causing tumor migration and requiring larger radiation portals, and higher perfusion to the lower lobe of the lung [43, 44].

Patients with existing lung disease are hypothesized to have higher risk factors for developing RP. Based on a review of the current literature, there is a strong observed correlation with pre-RT interstitial lung disease and the risk of developing RP [45–47]. Conflicting reports are found in the literature with respect to the presence of chronic obstructive pulmonary disease (COPD) or asthma as risk factors in the development of symptomatic RP. Since most studies looking at association with lung disease were done in adult patients with primary lung cancer, the same risks or protections should not be inferred for children.

Contrary to the proven lung damage associated with cigarette smoking, past history or concurrent cigarette smoking had a protective effect on the development of radiation injury. This protective effect is seen in small studies, pooled studies, and meta-analysis [36, 42]. The mechanism of protection from cigarette smoke is not clear. Speculation is that smoke damages the lungs and suppresses the local immune system; thus, no further harm can be induced by ionized radiation.

A history of previous lung radiation and chemotherapy are postulated to increase the risk of RILI. Repeat administration of RT in the thorax may be necessary to treat patients with recurrent or secondary tumor in the chest. However, literature is limited in this topic due to the small number of subjects in reported series. In these small case series, the incidence of RP in RT patients who have had previous radiation ranges from 5 to 21% which is similar for patients undergoing one RT course. Therefore, history of previous RT is not an absolute contraindication for additional RT, but care should be taken in the design and dosimetric treatment planning for these patients. Literature is unclear on the risk of pre-RT chemotherapy and development of RP due to conflicting studies reported on this matter. Despite earlier RTOG reporting of increased risk of concurrent or sequential chemotherapy and RT leading to the development of RILI, concurrent or sequential chemotherapy may be necessary for the treatment of bulky thoracic tumors. Pre RT chemotherapy shrinks tumor volume decreasing the field of radiation which could reduce the risk for radiation pneumonitis. Retrospective analysis of 223 patients who had previous chemotherapy did not demonstrate higher incidence for RP in patients with past

chemotherapy [48], while other report show that pre-RT chemotherapy, especially with mitomycin, is associated with risk of grade 2 or higher RP [49].

Data on pulmonary function testing (PFT) and the risk of development of radiation pneumonitis is confusing. Traditionally only patients with adequate lung function are considered for RT. Although RTOG studies limited patients with at least 0.75 L of FEV1 (forced expiratory volume in 1 s) to participate in protocol therapy, there has been no consistent literature to support the association of pre-RT PFT to the development of RP [38].

Advances in molecular genetics demonstrate that an individual's genetic polymorphism may account for variability in disease severity. Based on the understanding in pathogenesis of RILI, newer focus has been placed on assessing an individual's genetic variation in DNA repair, inflammation, and oxidative stress pathways. It is hypothesized that variation in these genes may account for either amelioration or exacerbation of RT-induced injury. Using single nucleotide polymorphism (SNP) techniques in patients who developed clinically significant RP, more than 20 genes involved in DNA repair, oxidative stress, and inflammatory cytokines have been identified to be associated with higher risk for developing radiation injury. An increasing number of polymorphisms found by SNP correlated positively with higher risk of developing clinically significant RP (see Table 2). Besides the direct cytotoxic effects of radiation, expression of inflammatory cytokines is also important in the radiation injury pathway. Interleukin 8 (IL-8) and transforming growth factor β 1 (TGFβ1) have been implicated in RT-induced lung injury. TGFβ1 and IL-8 have been reported by several studies to correlate well with prediction for development of RP. Persistent elevation of TGFβ1 during, at the end of, or after RT correlated with higher risk of RP, while return of TGFβ1 expression to pretreatment levels was seen in patients who did not develop RP (see Table 3). A full review of the genetic polymorphism amongst patients and the inflammatory cytokine cascade involved in radiation injury is beyond the scope of this chapter. These pathways are currently being investigated as methods to individualize the maximal dose of radiation that can be safely delivered while avoiding the deleterious effect on healthy lung tissue [38].

Differential Diagnosis

Symptoms of RP, such as dyspnea, cough, fatigue, and/or low-grade fever, are nonspecific, and could be seen in other disease entities such as lower respiratory tract infection, cardiac disease, and/or tumor progression. Therefore, radiation pneumonitis should be treated as a diagnosis of exclusion. Care should be taken to exclude other causes before establishing the diagnosis of radiation pneumonitis as misdiagnosis and treatment could lead to increased respiratory morbidity and/or mortality. Although diagnostic testing whether radiologic or bronchoscopic is not specific for RP, it is important for excluding infection, tumor progress, and/or underlying cardiac disease [50, 51].

Table 2 Studies evaluating SNPs and radiation-induced lung toxicity

Study	Patient no.	Endpoint	Gene associated with lung toxicity	Gene function
Pu 2014 [70]	421	≥G2 RP	CDC2 (rs10711) and (rs1871445) DDX58 (rs11795343) and (rs7865082) FGF5 (rs3733336) ETS2 (rs2298560) LIMS1 (rs12469016) GHR (rs4292454) TFEB (rs13202921)	Inflammation
Wen 2014 [71]	362	≥G3 RP	LIN28B (rs314280) LIN28B (rs314276)	RNA binding protein
Pang 2013 [72]	271	≥G3 RP	HSPB1 rs2868371	Oxidative stress pathways
Xiong 2013 [73]	362	≥G3 RP	ATM (rs189037 and rs228590)	DNA repair
Kelsey 2013 [74]	39	Radiologicchange	XRCC1 (rs25487) BRCA1 (rs16942)	DNA repair
Mark 2012 [75]	136	≥G2(G3)RP	MTHFR (rs1801131)	Oxidative stress pathways
Yin 2012 [76]	195	≥G3RP	LIG4 (rs1805388)	DNA repair (NHEJ)
Yin 2012 [77]	193	≥G3 RP	VEGF (rs2010963 and rs3025039)	Angiogenesis
Niu 2012 [78]	46	≥G3 RP	TGFβ1 (rs11466345)	Inflammation
Yin 2011 [79]	261	≥G2 RP	APEX1 D148E GG XRCC1 Q399R AA	DNA repair (BER)
Yang 2011 [80]	253	≥G2 RP	P53 Arg72Pro	Cell cycle regulation, apoptosis, and DNA repair
Hildebrandt 2010 [81]	173	≥G2 RP	IL1A (rs1800587/ rs17561) IL8 (rs4073) TNF (rs1799724) TNFRSF1B (rs1061622) MIF (rs7555622) IL4 (rs2243250) IL4R (rs2070874) IL13 (rs10800925) IL13 (rs20541) NFKBIA (rs1799983) NOS3 (rs1799983)	Inflammation
Zhang 2010 [82]	253	≥G2 RP	ATM (rs189037) and (rs373759)	DNA repair
Yuan 2009 [83]	164	≥G2(G3) RP	TGFβ1 (rs1982073)	Inflammation

BER base excision repair, *NHEJ* non-homologous end joining
Table reprinted from https://doi.org/10.1016/j.semradonc.2014.12.003

Table 3 Studies evaluating the association of plasma cytokines with radiation-induced lung toxicity

Author year	Patients no.	Endpoint	Cytokines (p value)	Sample handling process
Stenmark 2012 [84]	58	≥G2 RP or symptomatic pulmonary fibrosis	IL-8 pre-RT and at weeks 2 and 4 during RT ($p < 0.01$); TGF-β1 ratios at 2 and 4 weeks during RT/ baseline ($p = 0.41, 0.26$)	Platelet-poor plasma[a]
Zhao 2009 [85]	165	≥G2 RILT	TGF-β1 ratio at 4–5 weeks during RT/baseline ($p < 0.001$)	Platelet-poor plasma[a]
Kim 2009 [86]	34	≥G2 RP	Change of TGF-β1 level during RT ($p = 0.0001$)	Platelet-poor plasma[a]
Zhao 2008 [87]	26	≥G2 RILT	TGF-β1 ratio at 4 weeks during RT/baseline ($p = 0.015$)	Platelet-poor plasma[a]
Evans 2006 [88]	121	≥G1 RP	TGF-β1 ratio at end-RT/baseline ($p < 0.001$)	Platelet-poor plasma[a]
Hart 2005 [89]	55	SRILT	IL-8 pre-RT ($p < 0.005$)	Platelet-poor plasma[a]
Jaeger 2004 [90]	68	≥G2 RP	TGF-β1 ratio at 4–6 weeks during RT/ baseline ($p = 0.01$ *inverse relation*)	Plasma[b]
Novakova-Jiresova 2004 [91]	46	Symptomatic RP	TGF-β1 level ($p > 0.05$)	Plasma[b]
Fu 2001 [92]	103	Symptomatic RILT	TGF-β1 level end-RT ($p = 0.007$)	Platelet-poor plasma[a]
Anscher 1998 [93]	73	Symptomatic RP	TGF-β1 level end-RT ($p < 0.05$)	Platelet-poor plasma[a]

Table reprinted from https://doi.org/10.1016/j.semradonc.2014.12.003

[a]These studies used procedures of plasma preparation to minimize the platelet contamination or degradation, by using enough gravities, controlling time and temperature of blood setting before centrifuge, avoiding platelet contamination by using top layer of plasma

[b]Plasma samples may have been contaminated by platelets, as they used 1200 or 1000 g which was not enough to remove the platelets in plasma supernatant

Treatment and Prognosis

No randomized trials have been conducted on the treatment of RP. Grade 1 RP does not require therapy. Recommendation for treatment is made for grade 2 or higher presentation. The current accepted regimen is the use of systemic corticosteroids, typically 0.5 mg to 1 mg/kg body weight or doses ranging from 30 to 60 mg per day.

The typical treatment plan consists of full steroid dosing for 2–4 weeks then a slow taper over a course of 6–12 weeks. For grade 4 RP treatment with systemic steroid is coupled with respiratory support [52, 53]. Most RP patients respond well to steroid therapy. Anecdotal reports of steroid refractory RP have been successfully treated with either azathioprine or cyclosporine A in patients not responding to traditional therapy [54, 55]. Although the majority of patients respond well to systemic corticosteroid, the untoward side effects of systemic steroids led to the investigation of inhaled steroid as alternative therapy. Magaña E reports successful treatment of RP with inhaled fluticasone [56]. Henkenberens C et al. performed a retrospective analysis on patients followed in a single center. This group showed roughly two-thirds of the patients who developed grade 2–3 RP responded to high-dose budesonide 800 mcg daily. Patients who did not respond to inhaled budesonide were changed over to oral prednisone, and there was no report or worsening RP while on budesonide. Responders to budesonide remained well on inhalation therapy [57]. This author has used a short systemic steroid course with quick taper followed by a prolonged course of inhaled beclomethasone HFA (Qvar®) in the treatment of a 4-year-old patient with grade 4 radiation pneumonitis. Inhaled beclomethasone HFA was selected over other reported inhaled corticosteroids due to the size of the particle. In theory inhaled beclomethasone HFA has a mean particle diameter of 1 μm thus improving deposition into the distal lung units and alveoli.

The majority of patients with RP will respond to steroid treatment and become asymptomatic. Response to steroids however does not protect against the onset of radiation fibrosis. The onset of lung fibrosis is late and typically develops 6 months or later after therapy. It is postulated that after RP the body can heal and restore integrity to the alveolar capillary unit or continue to propagate inflammation leading to onset of fibrosis. Unlike RP, there is no convincing treatment reported to date for radiation-induced fibrosis of the lung or otherwise. Recently pirfenidone (Esbriet®) was approved by FDA (Food and Drug Administration) in the treatment of idiopathic pulmonary fibrosis (IPF), a once fatal disease. Pooled data from three multinational phase III trials over a one year span found that use of pirfenidone led to decrease in disease progression compared to placebo with an observed benefit of progression free survival [22]. Pirfenidone is an anti-fibrotic agent that downregulates fibrotic growth factor and procollagen I and II. Pirfenidone is a selective regulator of gene expression implicated in several cytokine signaling pathways including that of transforming growth factorβ1 (TGFβ1) which has been implicated in radiation-induced injury. Promising result of pirfenidone in IPF sparked interest in using this agent as a potential treatment for radiation induced fibrosis. A phase I open-label trial sponsored by the National Cancer Institute in 2007 looked a use of pirfenidone in the treatment of radiation-induced fibrosis. Although not specific for pulmonary fibrosis, this open-label trial found patients treated with pirfenidone reported subjective improvement in various areas of fibrosis and functional scores [58]. Although more work is needed to better delineate the role of pirfenidone in radiation-induced fibrosis, this open-label study does offer hope of treatment for this once untreatable condition.

Another new agent, nintedanib, which has been used for idiopathic pulmonary fibrosis is now being tested together with oral prednisone for the long-term

management of radiation-induced lung injury. Nintedanib is an inhibitor of multiple intracellular tyrosine kinase inhibitors responsible for the development of fibrosis after the presentation of radiation pneumonitis. Nintedanib inhibits fibroblast growth factor receptors 1 and 3 (FGFR 1 and 3), platelet-derived growth factor receptors α and β (PDGFR α and β), and vascular endothelial growth factor receptors 1, 2, and 3 (VEGFR 1, 2, and 3). Each of these receptors has been individually targeted in the treatment of fibrosis, and it is hypothesized that hitting all three together will be even more effective. It has been demonstrated to improve rates of bleomycin-induced lung fibrosis [59]. This medication is currently in clinical trials to study its effectiveness in reducing the incidence of late lung fibrosis in patients who develop acute RP.

Prevention

Although there is symptomatic treatment for RP and hope for possible treatment for radiation fibrosis, prevention may be a better alternative. Several studies have looked at the use of radioprotective agents administered in conjunction with RT to prevent the onset of radiation-induced injury.

Amifostine (Ethyol®)

Amifostine is a cytoprotective agent given during chemotherapy and RT. It is an organic thiophosphate that is supplied as a prodrug. Once administered, the prodrug is then hydrolyzed by alkaline phosphatase. The active compound detoxifies reactive metabolites of platinum and alkylating agents and scavenges free radicals. Amifostine has been used to reduce the incidence of fever, neutropenia, infection, esophagitis, decrease rectal inflammation, decrease nephrotoxicity from chemotherapy, and incidence of xerostomia resulting from RT. Several small series have shown promising results with the drug for the prevention of RIF [60–62], but a recent phase III RTOG trial failed to show significant reduction in RP [63, 64]. At the current time, there is no formal recommendation for the administration of amifostine in radiation therapy patient management.

Pentoxifylline

Pentoxifylline has been studied as a preventive agent for radiation-induced fibrosis. The exact mechanism for its action is not well understood. Pentoxifylline is a methylxanthine and is a competitive nonselective phosphodiesterase inhibitor resulting in the accumulation of intracellular cAMP. Phosphodiesterase blockade leads to decrease in TNF and leukotriene synthesis, thus reducing inflammation. Other

effects of pentoxifylline include improving red blood cell production and reducing blood viscosity and platelet aggregation. Small uncontrolled series demonstrated symptomatic improvement and healing in radiation-induced injury [65, 66]. These results prompted investigation in its use in the prevention of radiation-induced injury; however, a controlled randomized trial did not show any protective benefit, and it is not used in clinical practice [67].

Vitamin E

Vitamin E is known for its antioxidant property, inhibition of TGFβ1, and procollagen production. Use of vitamin E also has shown promising results in uncontrolled series, but no clinical effect was seen when studied in randomized double-blind placebo-controlled trials. The combination of vitamin E and pentoxifylline showed similar promise in uncontrolled series, but when a randomized placebo-controlled trial was conducted, no apparent improvement or prevention of radiation-induced fibrosis was found [67–69].

Despite some promising individual reports of clinical improvement in small case series, at the moment there are no proven cytoprotective agents or treatment protocols for the prevention and treatment of radiation-induced fibrosis to be incorporated into standard radiation treatment protocols. More investigation is needed in the management of this complication from RT.

Conclusion

Radiation-induced lung injury is a known complication of radiotherapy and is often the limiting factor in escalating treatment doses. Both patient-derived and treatment design-related factors play a role in the incidence of this pulmonary complication and should be considered in treatment planning. Currently systemic steroid remains the treatment of choice for radiation pneumonitis; however, inhaled corticosteroids may be an acceptable alternative. At present time there is no known treatment for radiation-induced fibrosis, and more work is needed to delineate the role of pirfenidone and nintedanib. Similarly, more study is needed to determine if cytoprotective agents should be incorporated into standard RT treatment regimen.

References

1. RT Answers: American Society of Radiation Oncology (ASTRO). www.RTanswers.org/statistics. Accessed 6 Sept 2016.
2. DeSantis CE, Lin CC, Mariotto AB, Siegel RL, Stein KD, Kramer JL, et al. Cancer Treatment and Survivorship Statisitics 2014. CA: A Cancer Journal for Clinicians 2014. 64:4 252–71.

3. Bhadra K, Patra NB, Manna A, Kabasi A, Pal J, and Sarkar SKAbnormalities by pulmonary regions studied with computer tomography and clinical correlation following local-regional radiotherapy for breast cancer. South Asian J Cancer 2013. 2:21–4.
4. Rancati T, Wennberg B, Lind P, Svane G, Gagliardi G. Early clinical and radiological pulmonary complications following breast cancer radiation therapy: NTCP fit with four different models. Radiother Oncol. 2007. 82:308–16.
5. Schallenkamp JM, Miller RC, Brinkmann DH, Foote T, Garces YI. Incidence of radiation pneumonitis after thoracic irradiation: Dose-volume correlates. Int J Radiat Oncol Biol Phys. 2007;67(2):410–6.
6. Gokula K, Earnest A, and Wong LC. Meta-analysis of incidence of early lung toxicity in 3-dimensional conformal irradiation of breast carcinomas. Radiation Oncology 2013. 8:268–279.
7. Mosby. Mosby's Medical Dictionary. 9th ed. Amsterdam: Elsevier; 2009.
8. Rubin P, Casarett GW. Clinical radiation pathology as applied to curative radiotherapy. Cancer. 1986;22:768–78.
9. Speiser BL, Spratling L. Radiation bronchitis and stenosis secondary to high dose rate endobronchial irradiation. Int J Radiat Oncol Biol Phys. 1993;25:589–97.
10. Nag S, Kelly JF, Horton JL, Komaki R, Nori D. Brachytherapy for carcinoma of the lung. Oncology. 2001;15:371–81.
11. Murray, editor. Postnatal growth and development of the lung. In: The normal lung. Philadelphia: WB Saunders Company. p. 45–54.
12. Bentzen SM. Preventing or reducing late side effects of radiation therapy: Radiobiology meets molecular pathology. Nat Rev Cancer. 2006;6:702–13.
13. Mikkelsen RB, Wardman P. Biological chemistry of reactive oxygen and nitrogen and radiation-induced signal transduction mechanisms. Oncogene. 2003;22:5734–54.
14. Fleckenstein K, Zgonjanin L, Chen L, Rabbani Z, Jackson IL, Thrasher B, et al. Temporal onset of hypoxia and oxidative stress after pulmonary irradiation. Int J Radiat Oncol Biol Phys. 2007;68:196–204.
15. Wiebe E, Rodriguez, G. Radiation-induced lung injury strategies for reducing damage while optimizing therapeutic dosage. Oncol Exch. 2006;5(2):2.
16. O'Sullivan B, Levin W. Late radiation-related fibrosis; pathogenesis, manifestations, and current management. Semin Radiat Oncol. 2003;13:274–89.
17. Border WA, Noble NA. Transforming growth factor B in tissue fibrosis. N Engl J Med. 1994;331:1286–92.
18. Martin M, Lefaix J, Delanian S. TGF-β1 and radiation fibrosis: a master switch and a specific therapeutic target? Int J Radiat Oncol Biol Phys. 2000;42:277–90.
19. Rubin P, Shapiro DL, Finklestein JN, Penney DP. The early release of surfactant following lung irradiation of alveolar type II cells. Int J Radiat Oncol Biol Phys. 1980;6:75–7.
20. Monson JM, Stark P, Reilly JJ, Sugarbaker DJ, Strauss GM, Swanson SJ, et al. Clinical radiation pneumonitis and radiographic changes after thoracic radiation therapy for lung carcinoma. Cancer. 1998;82:842–50.
21. Skoczylas JZ1, Bentzen SM, Overgaard M, Overgaard J. Time course of radiological lung density changes after postmastectomy radiotherapy. Acta Oncololgy 2000. 39:181–187.
22. Paul W. Noble, Carlo Albera, Williamson Z. Bradford, Ulrich Costabel, Roland M. du Bois, Elizabeth A. Fagan, Robert S. Fishman, Ian Glaspole, Marilyn K. Glassberg, Lisa Lancaster, David J. Lederer, Jonathan A. Leff, Steven D. Nathan, Carlos A. Pereira, Jeffrey J. Swigris, Dominique Valeyre, Talmadge E. King, (2015) Pirfenidone for idiopathic pulmonary fibrosis: analysis of pooled data from three multinational phase 3 trials. European Respiratory Journal 47 (1):243–253.
23. Koenig TR, Munden RF, Erasmus JJ, Sabloff BS, Gladish GW, Komaki R, et al. Radiation injury of the lung after three-dimensional conformal radiation therapy. Am J Roentgenol. 2002;178:1383–8.
24. Theuws JC, Kwa SL, Wagenaar AC, Boersma LJ, Damen EM, Muller SH, et al. Dose-effect relations for early local pulmonary injury after irradiation for malignant lymphoma and breast cancer. Radiother Oncol. 1998;48:33–43.

25. RTOG/EORTC Late Radiation Morbidity Scoring Schema. https://www.rtog.org/ResearchAssociates/AdverseEventReporting/RTOGEORTCLateRadiationMorbidityScoringSchema.aspx. Accessed 9 Sept 2016.
26. CTCAE v4.03. Cancer Therapy Evaluation Program. Common Terminology for Adverse Events, Version 4.03. National Cancer Institute. https://evs.nci.nih.gov/ftp1/CTCAE/About.html. accessed 12 November, 2017.
27. Emami B. Tolerance of normal tissue to radiation. Rep Radiother Oncol. 2013;1(1):35–48.
28. Marks LB, Bentzen SM, Deasy JO, Kong FM, Bradley JD, Vogelius IS, et al. Radiation dose-volume effects in the lung. Int J Radiat Oncol Biol Phys. 2010;76(3 Suppl):S70–6.
29. Keane TJ, Van Dyk J, Rider WD. Idiopathic interstitial pneumonia following bone marrow transplantation: The relationship with total body irradiation. Int J Radiat Oncol Biol Phys. 1981;7:1365–70.
30. Cosset JM, Baume D, Pico JL, Shank B, Girinski T, Benhamou E, et al. Single dose versus hyperfractionated total body irradiation before allogeneic bone marrow transplantation: A non-randomized comparative study of 54 patients at the Institut Gustave-Roussy. Radiother Oncol. 1989;15:151–60.
31. Pino y Torres JL, Bross DS, Lam WC, Wharam MD, Santos GW, Order SE. Risk factors in interstitial pneumonitis following allogenic bone marrow transplantation. Int J Radiat Oncol Biol Phys. 1982;8:1301–7.
32. Shank B, Chu FC, Dinsmore R, Kapoor N, Kirkpatrick D, Teitelbaum H, et al Hyperfractionated total body irradiation for bone marrow transplantation. Results in seventy leukemia patients with allogeneic transplants. Int J Radiat Oncol Biol Phys. 1983;9:1607–11.
33. Deeg HJ, Sullivan KM, Buckner CD, Storb R, Appelbaum FR, Clift RA, et al. Marrow transplantation for acute nonlymphoblastic leukemia in first remission: Toxicity and long-term follow-up of patients conditioned with single dose or fractionated total body irradiation. Bone Marrow Transplant. 1986;1:151–7.
34. Girinsky T, Benhamou E, Bourhis JH, Dhermain F, Guillot-Valls D, Ganansia V, et al. Prospective randomized comparison of single-dose versus hyperfractionated total-body irradiation in patients with hematologic malignancies. J Clin Oncol. 2000;18:981–6.
35. Byhardt RW1, Scott C, Sause WT, Emami B, Komaki R, Fisher B, et al. Response, toxicity, failure patterns, and survival in five Radiation Therapy Oncology Group (RTOG) trials of sequential and/or concurrent chemotherapy and radiotherapy for locally advanced non-small-cell carcinoma of the lung. Int J Radiat Oncol Biol Phys. 1998;42(3):469–78.
36. Vogelius IR, Bentzen SM. A literature based meta analyses of clinical risk factor for development of radiation pneumonitis. Acta Oncol. 2012;51:975.
37. Palma DA1, Senan S, Tsujino K, Barriger RB, Rengan R, Moreno M, et al. Predicting radiation pneumonitis after chemoradiation therapy for lung cancer: an international individual patient data meta-analysis. Int J Radiat Oncol Biol Phys. 2013;85(2):444–50.
38. Kong FM, Wong S. Nondosimetric risk factors for radiaition-induced lung toxicity. Semin Radiat Oncol. 2015;25(2):100–9.
39. Dang J, Li G , Zang S, Zhang S and Yao L. Risk and predictors for early radiation pneumonitis in patients with stage III non-small cell lung cancer treated with concurrent or sequential chemoradiotherapy. Radiat Oncol. 2014;9:172.
40. Tsujino K, Hashimoto T, Shimada T, Yoden E, Fujii O, Ota Y, et al. Combined analysis of V20, VS5, pulmonary fibrosis score on baseline computed tomography, and patient age improves prediction of severe radiation pneumonitis after concurrent chemoradiotherapy for locally advanced non-small-cell lung cancer. J Thorac Oncol. 2014;9(7):983–9904.
41. Schild SE1, Stella PJ, Geyer SM, Bonner JA, McGinnis WL, Mailliard JA, et al. North Central Cancer Treatment Group.Schild SE1, Stella PJ, Geyer SM, Bonner JA, McGinnis WL, Mailliard JA, et Al. North Central Cancer Treatment Group. The outcome of combined-modality therapy for stage III non-small-cell lung cancer in the elderly. J Clin Oncol. 2003;21(17):3201–6.
42. Jin H, Tucker SL, Liu HH, Wei X, Yom SS, Wang S, et al. Dose-volume thresholds and smoking status for the risk of treatment-related pneumonitis in inoperable non-small cell lung cancer treated with definitive radiotherapy. Radiother Oncol. 2009;91(3):427–32.

43. Bradley JD, Hope A, El Naqa I, Apte A, Lindsay PE, Bosch W, et al. A nomogram to predict radiation pneumonitis, derived from a combined analysis of RTOG 9311 and institutional data. Int J Radiat Oncol Biol Phys. 2007;69(4):985–92.
44. Seppenwoolde Y, De Jaeger K , Boersmal L , Belderbos JA, and Lebesque JV. Regional differences in lung radiosensitivity after radiotherapy for non-small-cell lung cancer. Int J Radiat Oncol Biol Phys. 2004;60(3):748–58.
45. Sanuki N, Ono A, Komatsu E, Kamei N, Akamine S, Yamazaki T, et al. Association of computed tomography-detected pulmonary interstitial changes with severe radiation pneumonitis for patients treated with thoracic radiotherapy. J Radiat Res. 2012;53(1):110–6.
46. Yamashita H, Kobayashi-Shibata S, Terahara A, Okuma K, Haga A, Wakui R, et al. Prescreening based on the presence of CT-scan abnormalities and biomarkers (KL-6 and SP-D) may reduce severe radiation pneumonitis after stereotactic radiotherapy. Radiat Oncol. 2010;5:32.
47. Ueki N, Matsuo Y, Togashi Y, Kubo T, Shibuya K, Iizuka Y, et al. Impact of pretreatment interstitial lung disease on radiation pneumonitis and survival after stereotactic body radiation therapy for lung cancer. J Thorac Oncol. 2015;10(1):116–25.
48. Wang S, Liao Z, Wei X, Liu HH, Tucker SL, Hu CS, et al. Analysis of clinical and dosimetric factors associated with treatment-related pneumonitis (TRP) in patients with non-small-cell lung cancer (NSCLC) treated with concurrent chemotherapy and three-dimensional conformal radiotherapy (3D-CRT). Int J Radiat Oncol Biol Phys. 2003;66(5):1399–407.
49. Rancati T, Ceresoli GL, Gagliardi G, Schipani S, Cattaneo GM. Factors predicting radiation pneumonitis in lung cancer patients: a retrospective study. Radiother Oncol. 2003;67(3):275–83.
50. Kocak Z1, Evans ES, Zhou SM, Miller KL, Folz RJ, Shafman TD, et al. Challenges in defining radiation pneumonitis in patients with lung cancer. Int J Radiat Oncol Biol Phys. 2005;62:635–8.
51. Salinas FV, Winterbauer RH, Radiation pneumonitis: A mimic of infectious pneumonitis. Semin Respir Infect. 1995;10:143–53.
52. Bradley J, Movsas B. Radiation pneumonitis and esophagitis in thoracic irradiation. In: Small Jr W, Woloschak GE, editors. Radiation toxicity: a Practical Guide. New York: Springer Science. p. 43.
53. Movsas B1, Raffin TA, Epstein AH, Link CJ Jr. Pulmonary effects of radiation therapy. Chest 1997. 111:1061–76.
54. Muraoka T, Bandoh S, Fujita J, Horiike A, Ishii T, Tojo Y, et al. Corticosteroid refractory radiation pneumonitis that remarkably responded to cyclosporine A. Intern Med. 2002;41:730.
55. McCarthy MJ, Lillis P, Vukelja SJ. Azathioprine as a steroid-sparing agent in radiation pneumonitis. Chest. 1996;109(5):1397–40.
56. Magaña E, Crowell, RE, Radiation Pneumonitis Successfully Treated with Inhaled Corticosteroid. Southern Medical Journal 2003. 96(5) 521–524.
57. Henkenberens C, Janssen S, Lavae-Mokhtari M, Leni K, Meyer A, Christiansen H, et al. Inhalative steroids as an individual treatment in symptomatic lung cancer patients with radiation pneumonitis grade II after radiotherapy - a single-centre experience. Radiat Oncol. 2016;11:12.
58. Simone NL, Soule BP, Gerber L, Augustine E, Smith S, Altemus RM et al. Oral pirfenidone in patients with chronic fibrosis resulting from radiation therapy: pilot study. Radiat Oncol. 2007;2:19.
59. Richeldi L1, Costabel U, Selman M, Kim DS, Hansell DM, Nicholson AG et al. Efficacy of a tyrosine kinase inhibitor in idiopathic pulmonary fibrosis. N Engl J Med. 2011;365(12):1079–87.
60. Antonadou D, Coliarakis N, Synodinou M, Athanassiou H, Kouveli A, Verigos C et al. Clinical Radiation Oncololgy Hellenic Group. Randomized phase III trial of radiation treatment +/− amifostine in patients with advanced-stage lung cancer. Int J Radiat Oncol Biol Phys. 2001;51:915–22.
61. Antonadou D, Throuvalas N, Petridis A, Bolanos N, Sagriotis A, Synodinou M. Effect of amifostine on toxicities associated with radiochemotherapy in patients with locally advanced non-small-cell lung cancer. Int J Radiat Oncol Biol Phys. 2003;57:402–8.
62. Komaki R, Lee JS, Milas L, Lee HK, Fossella FV, Herbst RS, et al. Effects of amifostine on acute toxicity from concurrent chemotherapy and radiotherapy for inoperable non-small-

cell lung cancer: Report of a randomized comparative trial. Int J Radiat Oncol Biol Phys. 2004;58(5):1369–77.
63. Werner-Wasik M, et al. Amifostine as mucosal protectant in patients with locally advanced non–small cell lung cancer (NSCLC) receiving intensive chemotherapy and thoracic radiotherapy (RT): Results of the Radiation Therapy Oncology Group (RTOG) 98 – 01study. Int J Radiat Oncol Biol Phys. 2003;57:S216.
64. Movsas B, Scott C, Langer C, Werner-Wasik M, Nicolaou N, Komaki R, et al. Randomized trial of amifostine in locally advanced non-small-cell lung cancer patients receiving chemotherapy and hyperfractionated radiation: Radiation Therapy Oncology Group trial 98-01. J Clin Oncol. 2005;23:2145–54.
65. Dion MW, Hussey DH, Osborne JW. The effect of pentoxifylline on early and late radiation injury following fractionated irradiation in C3H mice. Int J Radiat Oncol Biol Phys. 1989;17:101–7.
66. Dion MW, Hussey DH, Doornbos JF, Vigliotti AP, Wen BC, Anderson B. Preliminary results of a pilot study of pentoxifylline in the treatment of late radiation soft tissue necrosis. Int J Radiat Oncol Biol Phys. 1990;19:401–7.
67. Delanian S, Porcher R, Balla-Mekias S, Lefaix JL. Randomized Placebo-controlled trial of combined pentoxifylline and tocopherol for regression of superficial radiation induced fibrosis. J Clin Oncol. 2003;21:2545.
68. Baillet F, et al. Alpha-tocopherol treatment or radiofibrosis post-brachytherapy for breast cancer. Radiother Oncol. 1997;97(suppl 43):S3.
69. Delanian S, Balla-Mekias S, Lefaix JL. Striking regression of chronic radiotherapy damage in clinical trial of combined pentoxifylline and tocopherol. J Clin Oncol. 1999;17(10):3283–90.
70. Pu X, Wang L, Chang JY, Hildebrandt MA, Ye Y, Lu C, et al. Inflammation-related genetic variants predict toxicity following definitive radiotherapy for lung cancer. Clin Pharmacol Ther. 2014.
71. Wen J, Liu H, Wang Q, Liu Z, Li Y, Xiong H, et al. Genetic variants of the LIN28B gene predict severe radiation pneumonitis in patients with non-small cell lung cancer treated with definitive radiation therapy. Eur J Cancer. 2014;50(10):1706–16.
72. Pang Q, Wei Q, Xu T, Yuan X, Lopez Guerra JL, Levy LB, et al. Functional promoter variant rs2868371 of HSPB1 is associated with risk of radiation pneumonitis after chemoradiation for non-small cell lung cancer. Int J Radiat Oncol Biol Phys. 2013;85(5):1332–9.
73. Xiong H, Liao Z, Liu Z, Xu T, Wang Q, Liu H, et al. ATM polymorphisms predict severe radiation pneumonitis in patients with non-small cell lung cancer treated with definitive radiation therapy. Int J Radiat Oncol Biol Phys. 2013;85(4):1066–73.
74. Kelsey CR, Jackson IL, Langdon S, Owzar K, Hubbs J, Vujaskovic Z, et al. Analysis of single nucleotide polymorphisms and radiation sensitivity of the lung assessed with an objective radiologic endpoin. Clin Lung Cancer. 2013;14(3):267–74.
75. Mak RH, Alexander BM, Asomaning K, Heist RS, Liu CY, Su L, et al. A single-nucleotide polymorphism in the methylene tetrahydrofolate reductase (MTHFR) gene is associated with risk of radiation pneumonitis in lung cancer patients treated with thoracic radiation therapy. Cancer. 2012;118(14):3654–65.
76. Yin M, Liao Z, Liu Z, Wang LE, O'Reilly M, Gomez D, et al. Genetic variants of the nonhomologous end joining gene LIG4 and severe radiation pneumonitis in nonsmall cell lung cancer patients treated with definitive radiotherapy. Cancer. 2012;118(2):528–35.
77. Yin M, Liao Z, Yuan X, Guan X, O'Reilly MS, Welsh J, et al. Polymorphisms of the vascular endothelial growth factor gene and severe radiation pneumonitis in non-small cell lung cancer patients treated with definitive radiotherapy. Cancer Sci. 2012;103(5):945–50.
78. Niu X, Li H, Chen Z, Liu Y, Kan M, Zhou D, Li Z, Ye X, Shen S, Lv C, et al. A study of ethnic differences in TGFbeta1 gene polymorphisms and effects on the risk of radiation pneumonitis in non-small-cell lung cancer. J Thorac Oncol. 2012;7(11):1668–75.
79. Yin M, Liao Z, Liu Z, Wang LE, Gomez D, Komaki R, et al. Functional polymorphisms of base excision repair genes XRCC1 and APEX1 predict risk of radiation pneumonitis in patients with non-small cell lung cancer treated with definitive radiation therapy. Int J Radiat Oncol Biol Phys. 2011;81(3):e67–73.

80. Yang M, Zhang L, Bi N, Ji W, Tan W, Zhao L, et al. Association of P53 and ATM polymorphisms with risk of radiation-induced pneumonitis in lung cancer patients treated with radiotherapy. Int J Radiat Oncol Biol Phys. 2011;79(5):1402–7.
81. Hildebrandt MA, Komaki R, Liao Z, Gu J, Chang JY, Ye Y, et al. Genetic variants in inflammation-related genes are associated with radiation-induced toxicity following treatment for non-small cell lung cancer. PLoS One. 2010;5(8):e12402.
82. Zhang L, Yang M, Bi N, Fang M, Sun T, Ji W, et al. ATM polymorphisms are associated with risk of radiation-induced pneumonitis. Int J Radiat Oncol Biol Phys. 2010;77(5):1360–8.
83. Yuan X, Liao Z, Liu Z, Wang LE, Tucker SL, Mao L, et al. Single nucleotide polymorphism at rs1982073:T869C of the TGFbeta 1 gene is associated with the risk of radiation pneumonitis in patients with non-small-cell lung cancer treated with definitive radiotherapy. J Clin Oncol. 2009;27(20):3370–8.
84. Stenmark MH, Cai XW, Shedden K, Hayman JA, Yuan S, Ritter T, et al. Combining physical and biologic parameters to predict radiation-induced lung toxicity in patients with non-small-cell lung cancer treated with definitive radiation therapy. Int J Radiat Oncol Biol Phys. 2012;84(2):e217–22.
85. Zhao L, Wang L, Ji W, Wang X, Zhu X, Hayman JA, et al. Elevation of plasma TGF-beta1 during radiation therapy predicts radiation-induced lung toxicity in patients with non-small-cell lung cancer: a combined analysis from Beijing and Michigan. Int J Radiat Oncol Biol Phys. 2009;74(5):1385–90.
86. Kim JY, Kim YS, Kim YK, Park HJ, Kim SJ, Kang JH, et al. The TGF-beta1 dynamics during radiation therapy and its correlation to symptomatic radiation pneumonitis in lung cancer patients. Radiat Oncol. 2009;4:59.
87. Zhao L, Sheldon K, Chen M, Yin MS, Hayman JA, Kalemkerian GP, et al. The predictive role of plasma TGF-beta1 during radiation therapy for radiation-induced lung toxicity deserves further study in patients with non-small cell lung cancer. Lung Cancer. 2008;59(2):232–9.
88. Evans ES, Kocak Z, Zhou SM, Kahn DA, Huang H, Hollis DR, et al. Does transforming growth factor-beta1 predict for radiation-induced pneumonitis in patients treated for lung cancer? Cytokine. 2006;35(3–4):186–92.
89. Hart JP, Broadwater G, Rabbani Z, Moeller BJ, Clough R, Huang D, et al. Cytokine profiling for prediction of symptomatic radiation-induced lung injury. Int J Radiat Oncol Biol Phys. 2005;63(5):1448–54.
90. De Jaeger K, Seppenwoolde Y, Kampinga HH, Boersma LJ, Belderbos JS, Lebesque JV. Significance of plasma transforming growth factor-beta levels in radiotherapy for non-small-cell lung cancer. Int J Radiat Oncol Biol Phys. 2004;58(5):1378–87.
91. Novakova-Jiresova A, Van Gameren MM, Coppes RP, Kampinga HH, Groen HJ. Transforming growth factor-beta plasma dynamics and post-irradiation lung injury in lung cancer patients. Radiother Oncol. 2004;71(2):183–9.
92. Fu XL, Huang H, Bentel G, Clough R, Jirtle RL, Kong FM, et al. Predicting the risk of symptomatic radiation-induced lung injury using both the physical and biologic parameters V(30) and transforming growth factor beta. Int J Radiat Oncol Biol Phys. 2001;50(4):899–908.
93. Anscher MS, Kong FM, Andrews K, Clough R, Marks LB, Bentel G, et al. Plasma transforming growth factor beta1 as a predictor of radiation pneumonitis. Int J Radiat Oncol Biol Phys. 1998;41(5):1029–35.

Pulmonary Complications of Solid Organ Transplantation

Sylvia Szentpetery, Daniel J. Weiner, and Geoffrey Kurland

Introduction

Solid organ transplantation (SOT), such as liver, kidney, intestinal or multi-visceral transplant, is a complex undertaking, requiring consideration of appropriate timing for the procedure, the surgical approach, and multidisciplinary posttransplant care. Immunosuppression to prevent organ rejection is a pillar of postoperative care following transplantation, and this increases risk of opportunistic infections. Because of their exposure to the external environment, the lungs are particularly prone to such infectious complications following non-pulmonary SOT. In addition, there are noninfectious pulmonary complications following SOT. These may be secondary to the primary reason for the SOT, to surgical complications accompanying transplantation or to drug toxicity. In this chapter we will discuss these pulmonary complications of non-pulmonary solid organ transplant.

Postoperative Surgical Complications

Pulmonary Edema and Pleural Effusion

Pulmonary edema commonly occurs as an early complication following solid organ transplantation, often the result of increased hydrostatic pressure secondary to vigorous fluid or blood product administration in the intraoperative and

S. Szentpetery, M.D. • D.J. Weiner, M.D. • G. Kurland, M.D. (✉)
Division of Pediatric Pulmonology, Children's Hospital of Pittsburgh, Pittsburgh, PA, USA
e-mail: szentpet@musc.edu; danieljweiner@verizon.net; Geoffrey.kurland@chp.edu

© Springer International Publishing AG 2018

A.C. Koumbourlis, M.A. Nevin (eds.), *Pulmonary Complications of Non-Pulmonary Pediatric Disorders*, Respiratory Medicine,
https://doi.org/10.1007/978-3-319-69620-1_16

postoperative periods. Decreased oncotic pressure, as in hypoalbuminemia, seen in chronic liver disease, kidney disease, protein-losing enteropathy, or chronic malnutrition may also lead to pulmonary edema. Changes in vascular permeability, as with immune-mediated transfusion-related acute lung injury (TRALI), may also play a role.

Pleural effusions are also a well-described occurrence, noted in 30–50% of pediatric hepatic transplants [1]. Decreased oncotic pressure or increased hydrostatic pressure is contributory. Less commonly, pulmonary lymphatic drainage may be disrupted or overwhelmed, resulting in chylous effusions as seen following cardiac transplant. Ascites within the abdominal cavity may also translocate and contribute to pleural fluid collections. Notation of duration and location of effusions is critical, as right-sided effusions are characteristics following hepatic transplant. Left-sided or persistent effusions should prompt evaluation for potential etiologies, as persistent effusion has been associated with liver allograft rejection [2].

Diaphragmatic Paresis or Paralysis

Among the more common findings following thoracic surgery, such as with cardiac transplantation, is an elevated unilateral hemidiaphragm on chest radiograph [3]. Mechanisms of injury vary, including phrenic nerve exposure to cooling agents, trauma, as well as ischemia [4]. Right-sided diaphragm paresis can be seen following liver transplantation, although the literature is scant. Electrocautery to achieve hemostasis in the area of the right hemidiaphragm during native hepatectomy is felt to be the most likely explanation for this complication (R. Sindhi, MD. 2016. Personal Communication, December 9). Elevation of the hemidiaphragm leads to reduced potential space for the ipsilateral lung, with patient presentations ranging from asymptomatic to respiratory insufficiency or failure. Unexplained hypoxemia, tachypnea, respiratory distress, or failure to wean from ventilatory support postoperatively may be present. Diagnostic testing includes fluoroscopy or chest ultrasound to assess for the presence of diaphragmatic motion, with particular attention to the presence of paradoxical inspiratory upward movement of an affected hemidiaphragm. Treatment varies with severity of respiratory symptoms. Ventilatory support is provided if needed, with consideration of surgical plication should respiratory symptoms be persistent.

Relatively large donor organ size is another potential cause of impaired diaphragmatic excursion following orthotopic liver transplant. Relative mismatch of hepatic donor and recipient size may lead to right-sided diaphragmatic elevation and impaired respiratory muscle force. Localized atelectasis, while potentially addressed with noninvasive positive pressure ventilation and airway clearance techniques, pneumonia may ultimately develop, requiring antimicrobial therapy [5].

Diaphragmatic hernia following liver transplantation is a rare but serious complication. While some cases are noted soon after transplantation, there are also several

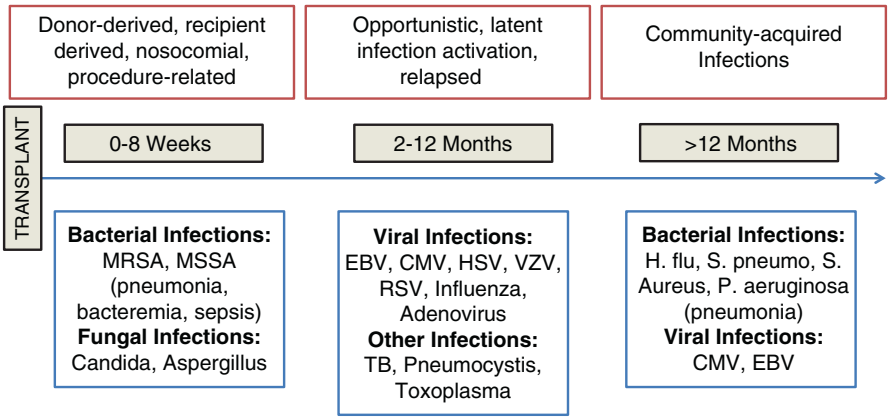

Fig. 1 Timeline of posttransplantation infections

case reports of delayed presentation. Although the possibility of a pre-existing diaphragmatic defect is recognized, vigorous electrocautery to achieve hemostasis in the area of the diaphragm is also suggested as a potential factor leading to an acquired hernia following transplantation [6, 7].

Pulmonary Infections

The lung is a common target of posttransplant infectious complications, and such infections depend on a variety of underlying factors including time since transplant, underlying indication for transplantation, presence of central vascular catheters, need for invasive mechanical ventilation, level of immunosuppression and, for certain, viral pathogens, and donor/recipient serological compatibilities. Relatively early following SOT, bacterial infections tend to be more common, in part because of the presence of central vascular catheters and the common requirement for mechanical ventilation (Fig. 1). Fungal pathogens may also be seen during this particularly vulnerable period (Tables 1 and 2).

Bacterial Infections

Bacterial pathogens associated with pneumonia in the transplant recipient include those associated with pneumonia in the normal pediatric host. *S. aureus* (including methicillin-resistant strains), *S. pneumoniae*, and *H. influenzae* are the most common organisms encountered. *Chlamydia pneumoniae* and *Legionella pneumophila* may also be seen [8]. Also notable is *Pseudomonas aeruginosa*, which is associated with pneumonia in hospitalized, immunocompromised children, particularly in the setting of mechanical ventilation.

Table 1 Outline of posttransplant infections

Pathogen	Mode of transmission	Usual time of presentation	Presenting features	Diagnosis	Treatment
S. pneumonia, *H. influenzae*, *S. aureus*, MRSA	Environmental	0–8 weeks	Fever, cough, infiltrates	Sputum culture, BAL	Targeted antibiotic therapy
Chlamydia spp., Legionella	Environmental	After 8 weeks	Persistent cough	Sputum culture, BAL	Targeted antibiotic therapy
Pseudomonas, *Klebsiella* spp.	Equipment contamination (e.g., mechanical ventilation)	0–8 weeks	Fever, infiltrates, leukocytosis	Tracheal aspirate, BAL	Targeted antibiotic therapy
Candida	Environmental	0–16 weeks	Fever, infiltrates, sepsis	Biopsy (needle, wedge, transbronchial) > BAL	Ketoconazole Amphotericin B
Aspergillus	Environmental	<4 weeks, >20 weeks	Fever, cough, abscess, interstitial ds.	Biopsy (needle, wedge, transbronchial) > BAL, Ag test	Voriconazole Itraconazole Amphotericin B
Histoplasma	Environmental (Ohio, Mississippi River valley)	Immediate to late	Fever, hilar adenopathy, infiltrates	Urine, blood, BAL EIA, culture, tissue pathology	Amphotericin B Itraconazole
Blastomyces	Environmental (Ohio, Mississippi River valley)	Immediate to late	Fever, hilar adenopathy, infiltrates	BAL, sputum or tissue culture, pathology	Amphotericin B
Mucor, *Rhizopus*	Environmental	Immediate to late	Fever, chest pain, hemoptysis	Sputum, BAL pathology	Amphotericin B Posaconazole Surg. resection
CMV	Donor-related, environmental	4–24 weeks	Fever, cough, dyspnea	Blood, Ag. detection, BAL PCR, culture, tissue path	Ganciclovir (prophylaxis recommended)
EBV	Donor-related, environmental	4–24 weeks	Viral syndrome, PTLD, lymphoma	Blood, BAL PCR, culture, tissue path	Reduction of immunosuppression

Pathogen	Mode of transmission	Usual time of presentation	Presenting features	Diagnosis	Treatment
Influenza	Environmental	Immediate to late	Fever, myalgia, secondary pneumonia	Respiratory PCR, culture	Oseltamivir Zanamivir
RSV	Environmental	Immediate to late	Fever, cough, bronchiolitis	Respiratory PCR, culture	None
Adenovirus	Environmental	Immediate to late	Fever, cough, pneumonia	Respiratory PCR, culture	Cidofovir
M. tuberculosis	Person-to-person	Immediate to late	Cough, focal or diffuse infiltrate	Quantiferon gold, gastric aspirate, tissue, or BAL	Three active drugs (INH, pyrazinamide, ethambutol, etc.)
P. jirovecii	Environmental	>4 weeks onward	Dyspnea, tachypnea, fever, infiltrates	Sputum, BAL pathology, PCR	TMP-SMX, pentamidine, dapsone (prophylaxis recommended)
Toxoplasma	Environmental	4–24 weeks	Fever, cough, chest pain	Serology, PCR, histopathology	TMP-SMX, pyrimethamine

Table 2 Posttransplant infections according to the time of presentation

Early (0–8 week posttransplant)	Intermediate (>4 week posttransplant)	Late (>24 week posttransplant	No specific timing
S. pneumoniae, *H. influenzae*, *S. aureus*, MRSA	*Chlamydia*	*Aspergillus*	*Histoplasma*
Pseudomonas	Legionella		*Blastomyces*
Candida	CMV		*Mucor*
Aspergillus	EBV		*Rhizopus*
	P. jirovecii		Influenza
	Toxoplasma		RSV
			Adenovirus
			M. tuberculosis

Ventilator-Associated Pneumonia

The early posttransplant period may be complicated by infection from a variety of sources. Among those associated with prolonged mechanical ventilation and intensive care duration is ventilator-associated pneumonia (VAP). Suspicion is raised for VAP in the setting of new or worsening pulmonary infiltrates on chest film, fever, purulent airway secretions, as well as peripheral leukocytosis [9]. Bacteria commonly associated with VAP include *Pseudomonas aeruginosa*, *Klebsiella* species *(pneumoniae, oxytoca)*, *E.coli*, *Enterobacter* species, *and S. aureus*. Infections leading to VAP may also be polymicrobial. Treatment includes antibiotic therapy, ideally tailored to culture results from a bronchoalveolar lavage or tracheal aspirate.

Patients undergoing orthotopic liver transplant are at risk for VAP due to suboptimal nutrition, potential diaphragmatic dysfunction, as well as hypoalbuminemia and risk for pulmonary edema. Factors significantly associated with VAP in this population include duration of mechanical ventilation, need for RBC transfusion, as well as need for vasoactive medications [2]. Techniques for prediction of pulmonary edema and potential mechanical ventilation implications continue to be evaluated [10].

Fungal Infections

Aspergillus Species

Aspergillus fungal organisms are ubiquitous, present in the soil as well as the healthcare setting. The most common species which are disease causing in the immunocompromised host include *Aspergillus fumigatus*, *A. niger*, and *A. flavus*. The most common manifestation of clinically significant *Aspergillus* infection in this population is pneumonia; however invasive disease such as acute invasive pulmonary

aspergillosis and chronic necrotizing aspergillosis is possible, more commonly occurring in patients with malignancy or following hematopoietic stem cell transplant [11]. Tissue and bronchoalveolar lavage samples are notable for septate hyphae with 45-degree dichotomous branching, best visualized with methenamine silver stain. Tissue examination is ideal; however *Aspergillus* can be isolated in BAL fluid in roughly 50% of cases. Serum or BAL *Aspergillus* galactomannan antigen (Platelia antigen) testing may also be considered [12]. Invasive *Aspergillus* disease, while associated with significant morbidity and mortality, is rare outside of lung transplant. Treatment options include oral itraconazole, voriconazole, amphotericin B (lipid formulation), caspofungin, or intravenous itraconazole.

Candida Species

Candida albicans and *tropicalis* are the most common causes of fungal pneumonia in the setting of primary fungal sepsis in the posttransplant patient. Tissue specimens demonstrate oval budding yeast with pseudohyphae on silver stain. Clinically patients may present with bronchopneumonia, alveolar exudate, as well as pulmonary hemorrhage. Therapy is with amphotericin B, in conjunction with or without flucytosine for synergistic effect. Fluconazole is a typical prophylaxis agent posttransplant; however azole-resistant non-albicans *Candida* infections have been reported [13].

Histoplasmosis

Histoplasma capsulatum is also a ubiquitous soil fungus, endemic in the United States within the Ohio River valley and in areas bordering the lower Mississippi River. *Histoplasma* growth is common in bird and bat droppings. Infection may occur in immunocompetent children as well as the immunocompromised. While many immunocompetent children may be asymptomatic, infected, immunocompromised patients may develop acute pneumonia with fever, pulmonary infiltrates, and hilar adenopathy. Disseminated disease with hepatosplenomegaly may also occur. Treatment is typically with amphotericin B, though itraconazole may also be the primary treatment.

Blastomycosis

Infection with *Blastomyces dermatitidis* occurs most commonly in the endemic areas of North America, including the western and northern Great Lakes Basin, along the shore of the St. Lawrence River Valley, surrounding the Ohio and Mississippi River valleys as well as parts of Canada. The organism thrives in moist soil with decomposing organic matter. Infection with *Blastomyces* is less common

than histoplasmosis. Diffuse pulmonary infiltrates and chronic granulomatous pulmonary disease may be seen, as well as ulcerated skin lesions. The most effective antifungal treatment remains amphotericin B.

Mucormycosis

Mucormycosis is a fungal disease caused by organisms within the order *Mucorales*, including *Rhizopus*, *Mucor*, or *Cunninghamella* species. This group of fungi is characterized by broad, nonseptate hyphae with a "twisted ribbon" appearance.

Rhizopus pneumonia, the most common pathogen leading to mucormycosis in immunosuppressed patients, is insidious, localized, and progressive despite intervention with antifungal therapy [14]. Chest pain, fever, and hemoptysis are common associated symptoms. Cavitary disease may occur with further dissemination via the bloodstream. Pulmonary hemorrhage and airway obstruction have been described as complications. Treatment is amphotericin B as well as surgical resection, if feasible.

Viral Infections

There are multiple potential viral pathogens that may affect the respiratory tract following SOT. Several of these are well documented, such as cytomegalovirus (CMV) and Epstein-Barr Virus (EBV), and exposures are usually documented serologically (antibody titers) or with other molecular measures of viral protein (e.g., PP65 for CMV) or genetic material (e.g., by PCR). Patients who are serologically mismatched for either CMV or EBV (donor serologically positive, recipient serologically negative) are at an increased risk for transmission of the pathogen from the transplanted organ. Prophylaxis, with ganciclovir or valganciclovir, which is most effective against CMV, is recommended. Continued monitoring of the sero-naïve recipient in the posttransplant period is recommended. Because there is no effective prophylaxis for EBV, the D+/R- recipient must be monitored regularly with PCR [15] to alert the clinicians of increase in EBV virions, with the risk for the development of posttransplant lymphoproliferative disease (PTLD), which will be discussed below.

There are several less common viral pathogens that deserve mention in this population. These include the polyomavirus known as BK, which is more commonly seen following renal or multi-visceral transplantation and can sometimes lead to respiratory infections.

Community-acquired viral respiratory pathogens such as adenovirus, rhinovirus, influenza, respiratory syncytial virus (RSV), metapneumovirus, and parainfluenza virus, each of which can lead to lower respiratory disease, can have devastating effects in the immunosuppressed patients.

Community-Acquired Viral Infections

Herpesviruses

Cytomegalovirus (CMV)

Cytomegalovirus (CMV) is a ubiquitous herpesvirus affecting immunosuppressed children of all age ranges. Viral carriage may not always lead to disease, with contributions from underlying immune status, allograft type, patient age, and prophylaxis [16]. CMV disease varies broadly from CMV syndrome characterized by fever, malaise, leukopenia, and/or thrombocytopenia to CMV tissue-invasive disease such as pneumonitis, carditis, or hepatitis. The incidence of CMV pneumonitis has been estimated at 3% of patients with symptomatic disease [17].

In addition to viral effects, CMV has been associated with indirect immunomodulatory effects including increased susceptibility to opportunistic infection, EBV-related posttransplant lymphoproliferative disease (PTLD), as well as graft rejection [18]. Among liver transplant recipients with donor mismatch (CMV-seronegative recipient with seropositive donor), a common prophylaxis strategy includes IV ganciclovir for approximately 100 days, followed by oral valganciclovir [19].

Diagnosis is typically rapid, by CMV-DNA polymerase chain reaction or antigen detection. Culture from tissue, urine, or respiratory secretions/bronchoalveolar lavage (BAL) is also possible, with immunofluorescence and DNA hybridization alternative techniques in BAL. Prevention is via CMV seronegative or leukocyte-reduced blood products, immune globulin, or antiviral therapies. Intravenous ganciclovir is the gold standard therapy.

Epstein-Barr Virus (EBV)

Epstein-Barr virus is a human herpesvirus capable of sustained latent infection. In the normal host, proliferation of EBV-infected B lymphocytes is limited by cytotoxic T lymphocytes. Immunosuppression as in solid organ transplant, however, impairs cytotoxic T cells with the potential for unrestricted lymphoproliferation known as posttransplant lymphoproliferative disease (PTLD), particularly if primary infection occurs posttransplant. EBV infection also manifests with a wide range of presentations in the immunocompromised host, ranging from asymptomatic seroconversion to a non-specific viral illness, mononucleosis, PTLD, and lymphoma all being possible [20].

Primary EBV infection posttransplant, either donor-associated (donor seropositive, recipient seronegative) or in the setting of EBV-naïve donor and recipient, is a well-defined risk factor for early PTLD (less than 12 month posttransplant). The pediatric population is at higher risk given the larger proportion of seronegative patients undergoing transplant. The incidence of PTLD varies with the type of organ transplant and with small intestinal transplant recipients having the highest risk; heart, liver, and pancreas recipients at moderate risk; and kidney transplant patients at lower risk. [21] Quantitative measurement of EBV viral load in the blood should be followed serially in patients at risk for donor-to-recipient transmission of EBV or

primary EBV. Symptoms may include fever, lymphadenopathy, mononucleosis, focal neurological disturbance, or graft dysfunction. Diagnostics include quantitative EBV assays as well as CT scan of the chest, abdomen, and pelvis. Pathology is the gold standard for diagnosis and classification. Reduction of immunosuppression is a widely accepted initial management strategy, with antivirals, immune globulin, interferon, and chemotherapy less uniformly utilized.

Complications of EBV

Posttransplant lymphoproliferative disease (PTLD): The immunosuppression required for recipients of solid organ transplant leads to an increased risk of posttransplant lymphoproliferative disease (PTLD). In the setting of immunosuppression causing T-lymphocyte depletion, uncontrolled EBV-driven B-lymphocyte proliferation can occur. Such unregulated proliferation of B cells may range from benign polyclonal B-cell expansion to aggressive immunoblastic B-cell lymphoma [22]. Less commonly, PTLD may result from T-cell or natural killer cell proliferation [23, 24]. Due to the high proportion of EBV-associated cases, viral load assessment of the posttransplant patient is of the utmost importance.

PTLD in the pediatric population typically occurs within the first 2 years of solid organ transplant, during the highest intensity phase of immunosuppression. Key risk factors include age and organ transplanted [25]. Incidence by organ transplanted range from 2.2% in kidney transplant recipients to 5% among heart and liver transplant recipients. Recipients of multiple organs have higher risk of PTLD than those receiving a single organ. Of note, if the recipient is EBV naïve at the time of transplant, the risk of PTLD within 5 years of transplant increases by two- to fourfold [26].

Presentation of PTLD varies by organ transplanted and may be non-specific [27]. Common symptoms include fever, weight loss, and fatigue. New-onset snoring or mouth breathing in the setting of rising EBV viral load may suggest tonsillar or adenoidal PTLD. Respiratory symptoms as well as lung nodules may be presenting symptoms and must be distinguished from other infectious causes [29]. Finally, fulminant PTLD may present as acute, rapidly progressive inflammatory disease with respiratory failure, shock, and failure of the transplanted organ.

First-line treatment includes reduction of immunosuppression by 50% or more to restore cytotoxic T-cell function [28]. This must be balanced with increased risk of rejection. Should reduced immunosuppression be unsuccessful, chemotherapy or immune-based therapies may be used. These include the CD20-antibody rituximab as well as EBV-specific cytotoxic T lymphocytes [29].

Polyomaviruses

Among the most common community-acquired infections are polyomaviruses such as BK virus and JC virus. Though these are ubiquitous and encountered in childhood, reactivation or primary disease in the immunocompromised host may lead to pulmonary disease [30]. While BK virus is more commonly associated with nephropathy and hemorrhagic cystitis, cases of pneumonitis have been rarely

identified [31]. Other polyomaviruses such as JC virus and WU virus have not been associated with pulmonary manifestations.

Respiratory Viruses

Respiratory viral infections have been increasingly identified as causative of transplant morbidity and mortality in addition to graft failure [32]. While the typical manifestation of such viruses is upper or lower respiratory tract infection, progression to pneumonia is more common among solid organ transplant patients. Bacterial coinfection or superinfection is also possible. Prolonged periods of viral shedding may also occur. Diagnosis is possible by rapid antigen assay, culture, PCR, or antibody assessment with histology confirmatory for invasive disease. Treatment is generally supportive, with medical therapies varying by organism.

Influenza

Influenza virus remains a significant pathogen, both among immunocompetent and immunosuppressed hosts. Pandemics, as recently with the influenza A H1N1 strain in 2009, may occur on a yearly basis, with similar prevention and therapy strategies as with seasonal influenza. Patients who have undergone solid organ transplant are at high risk for adverse outcomes and are candidates for treatment with oseltamivir or zanamivir if infected [33]. Vaccination for transplant recipients is recommended annually.

Respiratory Syncytial Virus

Respiratory syncytial virus (RSV) has been noted as an important pathogen in immunocompromised patients in both the pediatric and adult populations. Though typically manifested with upper respiratory symptoms, lower respiratory system involvement is associated with immunosuppressed status. Clinical presentation may vary from a self-limited viral syndrome to respiratory distress or failure with diffuse airspace opacities on chest imaging. Diagnosis is typically by nasopharyngeal swab enzyme immunoassay (EIA) or culture. Treatment is generally supportive, with prompt treatment of secondary sequelae such as bacterial superinfection. Prophylaxis with monoclonal antibody (palivizumab) is available, however not typically advised following solid organ transplantation without concomitant cardiopulmonary disease. Despite this, a recent survey of US solid organ transplant centers noted use of palivizumab in approximately 50% of transplant centers among SOT candidates and recipients less than 1 year of age [34].

Adenovirus

Adenoviral infection presents with a variety of presentations, ranging from asymptomatic infection to life-threatening pneumonia. Organ-specific involvement may lead to hepatitis, gastritis, cystitis, and others. Disseminated disease has

also been observed with high mortality in the immunosuppressed. Treatment is typically supportive, with antiviral therapy such as cidofovir considered in the most severely ill [35].

Opportunistic Infections

Mycobacterium Tuberculosis

Tuberculosis is an additional organism impacting both immunocompromised and immunocompetent hosts. Though rare in transplant centers, outcomes following tuberculosis among the immunosuppressed may lead to significant morbidity and mortality [36].

Pneumocystis Jirovecii

Pneumocystis pneumonia is considered a significant potential risk in the posttransplant patient. Pneumonia manifests with bilateral opacities, pulmonary edema, decreased compliance, and altered gas exchange as the alveoli are filled with trophozoites and protein-rich debris altering surrounding permeability [37]. Risk is highest during the first 12 months following transplant. Prophylaxis is recommended for a minimum of 6–12 months, with oral trimethoprim-sulfamethoxazole [38]. Indefinite prophylaxis is common in patients with higher levels of immunosuppression. Alternatives for prophylaxis include oral atovaquone or dapsone as well as aerosolized pentamidine. Intravenous pentamidine may be used but is not generally recommended for prophylaxis.

Toxoplasma Gondii

Toxoplasma infection is a primary concern among cardiac transplant patients; however other solid organ transplant recipients such as the kidney or liver have also been reported [39]. *Toxoplasma* can remain encysted in muscle tissue, with infection acquired posttransplant following reactivation of a dormant cyst in a seronegative recipient. Manifestations range from fever syndrome, myocarditis, pneumonia, chorioretinitis, or CNS involvement. Prophylaxis includes pyrimethamine/sulfadiazine with donor-positive status, with trimethoprim- sulfamethoxazole in positive recipients.

Drug Toxicity

While the therapeutic mainstay of patient care in the posttransplant period is immunosuppression, care must be taken in monitoring for secondary effects from these drugs.

Sirolimus (rapamycin) is a macrolide compound that suppresses the immune system by reducing production of IL-2 via action on the mechanistic target of rapamycin (mTOR), leading to reduced T- and B-cell activation. It is most com-

monly used in renal, cardiac, and other solid organ transplants; however it has also been used following hematopoietic stem cell transplant. Pulmonary toxicity has been described in multiple patterns [40], including organizing pneumonia, interstitial pneumonitis, pulmonary alveolar proteinosis, or alveolar hemorrhage [41]. Acute toxicity with respiratory distress syndrome has also been described [42]. Drug discontinuation or dose reduction should be considered with suspicion of toxicity. High-dose systemic steroids have also been utilized. Tacrolimus, which similarly suppresses the immune system via the IL-2 pathway, has also been associated with pulmonary complications in solid organ transplant recipients. Bronchiolitis obliterans has been reported and believed to be drug-related in a renal transplant patient [43].

Everolimus, a sirolimus-derived agent, acts similarly via mTOR inhibition. It is also used for variable solid organ (cardiac, hepatic) transplants and is under research for use in malignancies. Though initially thought to be free from the pulmonary toxicity seen with sirolimus, pneumonitis [44] as well as acute respiratory failure has been described [45].

Mycophenolate mofetil (CellCept) inhibits inosine monophosphate dehydrogenase (IMPDH), an enzyme required for B- and T-cell nucleotide synthesis. It is commonly used in cardiac, hepatic, and renal transplantation. Pulmonary toxicity may present with acute respiratory failure, pulmonary fibrosis [46], as well as pulmonary hemorrhage [47].

A high index of suspicion should be maintained for persistent or recurrent respiratory illnesses in this patient population. Though symptoms may wax and wane, a generalized decline in respiratory status is described if the medication in question is continued. Diagnostic considerations include pulmonary function testing if the patient is able (including measurement of diffusing capacity) as well as trend values over time. Testing following removal of any agents should also be considered. Imaging is generally non-specific, though disease is often diffuse.

References

1. Feltracco P, Carollo C, Barbieri S, Pattenuzzo T, Ori C. Early respiratory complications after liver transplantation. World J Gastroenterol. 2013;19(48):9271–81.
2. Mack CL, Mills JM, Whitington PF, Alonso EM. Pulmonary complications following liver transplantation in pediatric patients. Pediatr Transplant. 2000;4(1):39–44.
3. Huddleston CB, Richey SR. Heart-lung transplantation. J Thorac Dis. 2014;6(8):1150–8.
4. Aguirre VJ, Sinha P, Zimmet A, Lee GA, Kwa L, Rosenfeldt F. Phrenic nerve injury during cardiac surgery: mechanisms, management and prevention. Heart Lung Circ. 2013;22(11):895–902.
5. De Gaspari A, Feltracco P, Ceravola E, Lee GA, Lachlan K, Rosenfeldt F. Pulmonary complications in patients receiving a solid-organ transplant. Curr Opin Crit Care. 2014;20(4):411–9.
6. Yazdani M, Park E, Udayasankar U. Postsurgical diaphragmatic herniation: a rare delayed complication of pediatric intra-abdominal surgery. J Pediatr Surg. 2016;51(2):333–5.
7. Kirnap M, Akdur A, Ozcay F, Soy E, Coskun M, Moray G, et al. Diaphragmatic hernia after pediatric liver transplant. Exp Clin Transplant. 2015;13(5):471–4.

8. Letourneau AR, Issa NC, Baden LR. Pneumonia in the immunocompromised host. Curr Opin Pulm Med. 2014;20(3):272–9.
9. Siniscalchi A, Aurini L, Benini B, Gamberini L, Nava S, Viale P, et al. Ventilator associated pneumonia following liver transplantation: etiology, risk factors and outcome. World J Transplant. 2016;6(2):389–95.
10. Garutti I, Sanz J, Olmedilla L, Tranche I, Vilchez A, Fernandez-Quero L, et al. Extravascular lung water and pulmonary vascular permeability index measured at the end of surgery are independent predictors of prolonged mechanical ventilation in patients undergoing liver transplantation. Anesth Analg. 2015;121(3):736–45.
11. Steinbach WJ. Invasive aspergillosis in pediatric patients. Curr Med Res Opin. 2010;26(7):1779–87.
12. Miceli MH, Maertens J. Role of non-culture based tests, with an emphasis on galactomannan testing for the diagnosis of invasive aspergillosis. Semin Respir Crit Care Med. 2015;36(5):650–61.
13. Kremery V, Barnes AJ. Non-albicans Candida spp. causing fungaemia: pathogenicity and antifungal resistance. J Hosp Infect. 2002;50(4):243–60.
14. Vazquez JA, Micelli MH, Alangaden G. Invasive fungal infections in transplant recipients. Ther Adv Infect Dis. 2013;1(3):85–105.
15. Chiou C, Groll A. Pediatric infectious diseases: the requisites in pediatrics. 1st ed. Philadelphia: Elsevier; 2008.
16. Tamm M, Traenkle P, Grill B, Soler M, Bollinger CT, Dalquen P, et al. Pulmonary cytomegalovirus infection in immunocompromised patients. Chest. 2001;119(3):838–43.
17. Ho M. Advances in understanding cytomegalovirus infection after transplantation. Transplant Proc. 1994;26(5 Suppl 1):7–11.
18. Fishman JA, Rubin RH. Infection in organ-transplant recipients. N Engl J Med. 1998;338(24):1741–51.
19. Holt C, Winston D. Transplantation of the liver. 2nd ed. Philadelphia: Elsevier; 2005.
20. Munksgaar B. Epstein-Barr virus and lymphoproliferative disorders after transplantation. Am J Transplant. 2004;4(Suppl. 10):59–65.
21. Cockfield SM. Identifying the patient at risk for post-transplant lymphoproliferative disease. Transpl Infect Dis. 2001;3:70–8.
22. Loren AW, Tsai DE. Post-transplant lymphoproliferative disorder. Clin Chest Med. 2005;26(4):631–45.
23. Tiede C, Maecker-Kolhoff B, Klein C, Kreipe H, Hussein K. Risk factors and prognosis in T-cell posttransplantation lymphoproliferative diseases: reevaluation of 163 cases. Transplantation. 2013;95(3):479–88.
24. Hsi ED, Picken MM, Alkan S. Post-transplantation lymphoproliferative disorder of the NK-cell type: a case report and review of the literature. Mod Pathol. 1998;11(5):479–84.
25. Schober T, Framke T, Kreipke H. Characteristics of early and late PTLD development in pediatric solid organ transplant recipients. Transplantation. 2013;95(1):240–6.
26. Wistinghausen B, Gross TG, Bollard C. Post-transplant lymphoproliferative disease in pediatric solid organ transplant recipients. Pediatr Hematol Oncol. 2013;30(6):520–31.
27. Pinho-Apezzato ML, Tannuri U, Tannuri AC. Multiple clinical presentations of lymphoproliferative disorders in pediatric liver transplant recipients: a single-center experience. Transplant Proc. 2010;42(5):1763–8.
28. Gross TG, Savoldo B, Punnett A. Posttransplant lymphoproliferative diseases. Pediatr Clin N Am. 2010;57(2):481–503.
29. Haque T, Wilkie GM, Jones MM. Allogeneic cytotoxic T-cell therapy for EBV-positive posttransplantation lymphoproliferative disease: results of a phase 2 multicenter clinical trial. Blood. 2007;110(4):1123–31.
30. Pinto M, Dobson S. BK and JC virus: a review. J Infect. 2014;68(Suppl 1):S2–8.
31. Sandler ES, Aquino VM, Goss-Shohet E, Hinrichs S, Krisher K. BK papova virus pneumonia following hematopoietic stem cell transplantation. Bone Marrow Transpl. 1997;20(2):163–5.

32. Englund JE, Whimbey EE. Community-acquired respiratory viruses after hematopoietic stem cell or solid organ transplantation. Transplant infections. 1st ed. Baltimore: Lippincott Williams & Wilkins; 2003.
33. Kumar D, Morris MI, Kotton CN, Fischer SA, Michaels MG, Allen U, et al. Guidance on novel influenza A/H1N1 in solid organ transplant recipients. Am J Transplant. 2010;10(1):18–25.
34. Michaels MG, Fonseca-Aten M, Green M, Charsha-May D, Friedman B, Seikaly M, et al. Respiratory syncytial virus prophylaxis: a survey of pediatric solid organ transplant centers. Pediatr Transplant. 2009;13(4):451–6.
35. Bhadri VA, Lee-Horn L, Shaw PJ. Safety and tolerability of cidofovir in high-risk pediatric patients. Transpl Infect Dis. 2009;11(4):373–9.
36. American Society of Transplantation Infectious Diseases Community of Practice. Mycobacterium tuberculosis. Am J Transplant. 2004;10:37–41.
37. Catherinot E, Lanternier F, Bougnoux ME. Pneumocystis jirovecii pneumonia. Infect Dis Clin N Am. 2010;24(1):107–38.
38. Kimberlin DW, Brady MT, Jackson MA, Long SS, editors. Red Book. 2015 report of the Committee on Infectious Diseases. 30th ed. Elk Grove Village: American Academy of Pediatrics; 2015.
39. Michaels MG, Wald ER, Fricker FJ, del Nido PJ, Armitage J. Toxoplasmosis in pediatric recipients of heart transplants. Clin Infect Dis. 1992;14(4):847–51.
40. Feagans J, Victor D, Moehlman M, Florman SS, Regenstein F, Balart LA, et al. Interstitial pneumonitis in the transplant patient: consider sirolimus-associated pulmonary toxicity. J La State Med Soc. 2009;161(3):166. 168–72
41. Garrod AS, Goyal RK, Weiner DJ. Sirolimus-induced interstitial lung disease following pediatric stem cell transplantation. Pediatr Transplant. 2015;19(3):E75–7.
42. Das BB, Shoemaker L, Subramanian S, Johnsrude C, Recto M, Austin EH. Acute sirolimus pulmonary toxicity in an infant heart transplant recipient: case report and literature review. J Heart Lung Transplant. 2007;26(3):296–8.
43. Cuhna BA, Syed U, Mickail N. Renal transplant with bronchiolitis obliterans organizing pneumonia (BOOP) attributable to tacrolimus and herpes simplex virus (HSV) pneumonia. Heart Lung. 2012;41(3):310–5.
44. Otton J, Hayward CS, Keogh AM, Glanville AR, MacDonald PS. Everolimus-associated pneumonitis in 3 heart transplant recipients. J Heart Lung Transplant. 2009;28(1):104–6.
45. Depuydt P, Nollet J, Benoit D. Fatal acute pulmonary injury associated with everolimus. Ann Pharmacother. 2012;46(3):e7.
46. Gross DC, Sasaki TM, Buick MK, Light JA. Acute respiratory failure and pulmonary fibrosis secondary to administration of mycophenolate mofetil. Transplantation. 1997;64(11):1607–9.
47. Gorgan M, Bockorny B, Lawlor M, Volpe J, Fiel-Gan M. Pulmonary hemorrhage with capillaritis secondary to mycophenolate mofetil in a heart-transplant patient. Arch Pathol Lab Med. 2013;137(11):1684–7.

Index

A
Acceptance and commitment therapy (ACT), 187
Achalasia, 25, 26
Achondroplasia, 131
Acute chest syndrome (ACS), 32, 33
Acute lung injury (ALI), 217
Acute lymphoblastic leukaemia (ALL), 36
Acute lysis pneumopathy, 54
Acute myeloid leukaemia (AML), 36
Acute respiratory distress syndrome (ARDS), 15, 16, 149
Adenoviral infection, 288, 291
Airway compression, 17, 18
Airway obstruction, 25, 80, 93
  lower airway (*see* Lower airway obstruction)
  physiology
    biphasic stridor, 80
    expiratory stridor, 80
    extrathoracic and intrathoracic obstruction, 80, 81
    flow-volume loops, 80, 81
    inspiratory stridor, 80
  tracheostomy
    aerodigestive model, 98
    aspiration, 97
    dysphagia, 97
    indications, 97
    mortality rate, 97
    mucociliary clearance, 97
    swallowing dysfunction, 97
  upper airway obstruction (*see* Upper airway obstruction)
Airway reactivity, 213
Airway soilage
  laryngotracheoesophageal cleft, 94, 95
  tracheoesophageal fistulas, 96, 97
Alagille syndrome, 231
Alström syndrome, 231
Alveolar capillary subunits, 265
Alveolar disease, drugs, 243
Alveolar hemorrhage, , drugs, 244
Amniotic fluid embolism, 151
Anaemia
  arterial-alveolar gradient post-transfusion, 40
  in cystic fibrosis patients, 40
  iron deficiency, 39
  physiological response, 40
  SCD, 34
ANCA-associated vasculitis (AAV) syndromes, 200
Ankylosing spondylitis, 197
Antibiotic therapy, 286
Aortopexy, 91
Apneusis, 164
Ascending arousal system, 164
Aspergillus fungal disease, 286
Asphyxiating thoracic dystrophy. *See* Jeune syndrome
Aspiration
  anatomical malformations, 22
  complications, 23
  diagnostic evaluations, 23, 24
  early detection and management, 23
  esophagus and airway, abnormal connection, 79
  GERD, 23
  laryngopharyngeal sensation, 22

© Springer International Publishing AG 2018

A.C. Koumbourlis, M.A. Nevin (eds.), *Pulmonary Complications of Non-Pulmonary Pediatric Disorders*, Respiratory Medicine,
https://doi.org/10.1007/978-3-319-69620-1

Aspiration (*cont.*)
oropharyngeal aspiration, 22
recurrent pneumonia, 94
respiratory morbidity and mortality, 22
supraglottoplasty, 94
symptoms, 22
tracheostomy, 97
upper airway obstruction, 93
Aspiration pneumonia, 146, 147
Asthma, 34, 179, 183, 214, 215, 269
obstetric disorders
baseline asthma severity, 142
diagnosis and monitoring, 142, 143
maternal and fetal complications, 142
prevalence, 142
treatment, 143
Atelectasis, 5
Atrioventricular septal defects (AVSDs), 229
Autosomal dominant and autosomal recessive polycystic kidney disease, 231, 232

B
Bacterial infections, 283
Bacterial pneumonia, 145
Bardet-Biedl syndrome, 231
Biallelic mutations, 224
Blastomyces dermatitidis, 287
Blastomycosis, 287, 288
Bleeding disorders
corticosteroids, 42
DAH, 41, 42
haemophilia, 41
recombinant activated factor VII, 41
treatment options, 41
Bleomycin, 58, 59
Bleomycin-induced lung fibrosis, 274
Blood and bone marrow transplantation (BMT), 63–69
chronic lung injury, 61
GVHD, 66
infectious complications
late phase, 63, 64
post-engraftment phase, 63, 64
pre-engraftment phase, 63, 64
risk factors, 63
long-term follow-up protocols, 61, 69
mortality rates, 61
non-infectious complications, 66
BOS, 66
CBO, 66
endothelial injury, 67, 68
GVHD, 65
idiopathic pneumonia syndrome, 65
interstitial lung disease, 68, 69
mucositis, 64
PTLD, 67
pulmonary oedema, 64
restrictive lung disease, 68, 69
post-BMT pulmonary complications, 61, 62
Blood-brain barrier, 172
Body mass index (BMI), 209
Bronchial challenge tests, 143
Bronchiectasis, 195, 222
Bronchiolitis obliterans syndrome (BOS), 66, 197, 205, 243, 293
Bronchoalveolar lavage (BAL), 65, 205
Bronchoscopy, 205
Bucket-handle effect, 108
Busulfan, 59

C
Candida albicans, 287
Candida tropicalis, 287
Carbamylating agents, 59
Carbonic anhydrase, 171
Cardiac asthma, 15
Cardiomegaly, 5, 6
Cardiomyopathy, 135
Cardiopulmonary bypass (CPB), 15
Cardiovascular disorders
cardiac asthma, 15
cardiomegaly, 5, 6
clinical features, 11, 12
congenital vascular abnormalities
double aortic arch, 7
left aortic arch, 8
right aortic arch, 7, 8
heart failure, 13
normal anatomic relationships
aorta, 3, 4
brachiocephalic artery, 3, 4
heart location, 2
left and right hilum, 2, 3
left atrium, 2
pulmonary artery, 3, 4
pulmonary veins, 5
right atrium, 2
superior vena cava and azygos vein, 4, 5
perioperative complications
airways compression, 17, 18
chylothorax, 17
diaphragmatic paresis/paralysis, 16

plastic bronchitis, 17
pleural effusions, 16
reperfusion injury, 15
vocal cord paralysis, 16
peripheral edema, 14
pulmonary edema, 14
pulmonary function testing, 13, 14
pulmonary hemorrhage/hemoptysis, 15
radiographic studies, 12, 13
tracheal compression
anomalous brachiocephalic artery, 9, 10
left pulmonary artery sling, 10
Scimitar syndrome, 10, 11
tracheobronchial compression, 11
Catamenial pneumothorax (CP), 156, 157
Cell differentiation, 264
Cellular bronchiolitis, 196, 197
Cellular function, 171
Cellular metabolism, 172
Central apneas, 133
Central chemoreceptors, 164
Central sleep apnea, 166
Cerebral blood flow, 164
Cerebral ventriculomegaly, 230
Chemotherapy, lung toxicity, 252
azathioprine, 257, 258
bleomycin, 251, 253
busulfan, 255
carmustine, 256
chlorambucil, 255
clinical features, 251
cyclophosphamide, 254
methotrexate, 256, 257
mitomycin C, 253
radiographic pattern, 251
treatment modalities, 250
Chest wall disorders, 109, 110, 113–118
chest wall hyperplasia, 121–123
chest wall hypoplasia (*see* Chest wall hypoplasia)
kyphoscoliosis, 128
scoliosis, 108, 110
bracing and serial casting, 110
EOS (*see* Early onset scoliosis (EOS))
hypertonic scoliosis, 116–118
hypotonic scoliosis, 113–117
with left rib and spine hypoplasia, 109
with left-sided bar vertebra, 109
Chest wall hyperplasia
pectus carinatum, 123
pectus excavatum, 121–123
Chest wall hypoplasia, 118–121
Jarcho-Levin syndrome
SCD, 118
STD, 118, 119
Jeune syndrome
causes, 118
LTE technique, 119
narrow chest, 119, 120
square-shaped chest, 119, 120
VEPTR insertion, 119–121
Chiari malformations (CM), 165–166
Chronic obstructive pulmonary disease (COPD), 269
Chronic pulmonary aspiration, 93
Chronic thromboembolic pulmonary hypertension (CTEPH), 43
Churg-Strauss syndrome (CSS), 200, 205
Chylothorax, 17
Cilia
axonemal structure, 220
cell interactions, 219
congenital disorders, 219
extracellular environment, sensation, 232
fluid movement, 221
function, 221, 223
heterogeneity, 223
integrated model of, 219
internal organ placement, 232
mature ciliated airway epithelial cell, 221
mechanical fluid flow, 232
motility, 221, 229
nasal nitric oxide measurement, 223
non-motile, 221, 229
physiology, 220, 221
structure, 221
types of, 219, 232
ultrastructure, 220, 223
Ciliary waveform analysis, 224
Ciliogenesis, 231
Ciliopathy, 232
CMV-DNA polymerase chain reaction, 289
Cognitive behavior therapy (CBT), 185, 187
Collagen VI (COLVI) myopathy, 134
Community-acquired viral respiratory infections
drug toxicity, 293
everolimus, 293
herpesvirus, 289
mycophenolate mofetil, 293
pathogens, 288
tacrolimus, 293
Complex sleep apnea, 166
Congenital vascular abnormalities
double aortic arch, 7
left aortic arch, 8
right aortic arch, 7, 8

Constrictive bronchiolitis obliterans (CBO), 65, 66
Cough-assisted techniques, 135
Cranioectodermal dysplasia, 231
Cricoarytenoid arthritis, 195
Cryptogenic organising pneumonia (COP), 69
Cyclophosphamide, 37
Cystic fibrosis (CF), 144
Cytomegalovirus (CMV) syndrome, 289

D
Dermatomyositis, 194
Diaphragmatic paresis/paralysis, 16, 282, 283
Diffuse alveolar haemorrhage (DAH), 41, 42, 65, 200, 201
Diffuse bilateral pulmonary opacities, 201
Diffuse interstitial fibrosis, 199
Disseminated disease with hepatosplenomegaly, 287
Dorsal respiratory group (DRG), 163
Double aortic arch, 7
Double-stage laryngotracheoplasty, 87
Doxorubicin, 38
Drug induced lung toxicity, 245–250
  diagnosis and treatment, 242
  direct cytotoxic damage, 241
  immune-mediated pulmonary injury, 241
  non-chemotherapeutic medications
    amiodarone, 248, 249
    amphotericin B, 246
    carbamazepine, 250
    diphenylhydantoin, 249, 250
    minocycline, 246
    nitrofurantoin, 245
    penicillamine, 248
    phenytoin, 249, 250
    sulfasalazine, 247
  pathogenesis, 241
  phospholipidosis, 241
  reactive oxygen species generation, 241
Drug-induced respiratory diseases (DIRD)
  classification, 242
  clinical courses, 241, 242 (*see also* Drug induced lung toxicity)
  histologic patterns, 244
  host-related risk factors, 241, 242
  symptoms, 243
Duchenne muscular dystrophy (DMD) scoliosis, 113, 114
Dysphagia, 27
  tracheostomy, 97
Dyspnea, 179, 180, 214

E
Early onset scoliosis (EOS)
  causes, 110
  forced vital capacity, 110
  halo gravity traction, 110
  MAGEC rods, 110, 112
  spinal growing rods, 110, 111
  VEPTR, 110–112
EBV-related posttransplant lymphoproliferative disease (PTLD), 289
Ellis-van Creveld syndrome, 231
Embryonic nodal cilia, 228
Endobronchial stenting, 91
Endocrine homeostasis
  adiponectin, 216
  ghrelinergic cells, 216
  interleukin-6, 215
  leptin, 215
  tumor necrosis factor-α, 216
Eosinophilic esophagitis (EOE)
  clinical investigations, 24
  diagnosis, 25
  etiology, 24
  prevalence, 24
  pulmonary symptomatology, 24
  symptoms, 24, 25
Epithelial-mesenchymal transition (EMT) process, 192
Epstein-Barr virus (EBV), 289, 290
Esophageal atresia (EA), 27
Esophagogram, 12, 13
Exercise tolerance, 213
Extra-thoracic space-occupying tumours, 55

F
Feedback mechanism, 166
Fibrosing bronchiolitis, 196
Fluconazole, 287
Fulcrum effect, 108
Fungal infections, 286–288
Fungal pneumonia, 146

G
Gastroesophageal reflux disease (GERD), 23, 27
Gastrointestinal diseases, 22–27
  anatomic abnormalities
    achalasia, 25, 26
    airway obstruction, 25
    esophageal atresia, 27

hepatopulmonary syndrome, 27, 28
inflammatory changes
aspiration, 22–24
dysphagia, 22, 23
EOE, 24, 25
Gene expression, 273
Generalized Anxiety Disorders scale (GAD-7), 184
Genetic polymorphism, 270
Gestational trophoblastic disease (GTD), 158
Graft-versus-host disease (GHVD), 39, 65
Granulomatosis with polyangiitis, 202
Gynecologic disorders
catamenial pneumothorax, 156, 157
LAM, 157, 158
OHSS, 158, 159
OSA, 159
PCOS, 159
TES, 155, 156
trophoblastic embolization, 158

H
Habit cough, 182
Haematologic disorders, 32, 34, 39, 40
anaemia
arterial-alveolar gradient posttransfusion, 40
in cystic fibrosis patients, 40
iron deficiency, 39
physiological response, 40
bleeding disorders, 41, 42
HSCT effects, 38, 39
hyperviscosity, 42, 43
iron overload (*see* β-thalassaemias)
leukaemia, 36–38
SCD (*see* Sickle cell disease (SCD))
thromboembolism, 43, 44
Haematopoietic stem cell transplantation (HSCT) effects, 38, 39
Haemolysis, 33
Haemophilia, 41
Haller index, 122
Halo gravity traction, 110
Heart failure, 13
Hepatopulmonary syndrome (HPS), 27, 28
Hering–Breuer inflation reflex, 165
Herpesviruses, 289, 290
Heterotaxy syndrome, 226, 228, 230
Histoplasma capsulatum, 287
Histoplasmosis, 287
Homeostatic oxygen sensing, 168
Hydrocephalus, 230
Hyperleukocytosis, 42, 53
Hypertonic scoliosis, 116–118
Hyperviscosity, 42, 43
Hypoalbuminemia, 286
Hypoxemia, 170

I
Idiopathic bronchiectasis, 225
Idiopathic pneumonia syndrome (IPS), 65
Idiopathic pulmonary fibrosis, 273
nintedanib, 273
oral prednisone, 273
Idiopathic pulmonary haemosiderosis (IPH), 41, 42
Immunofluorescence testing, 224
Inflammatory cytokine cascade, 270
Influenza virus, 288, 291
Inhaled corticosteroids (ICS), 143
Intensity-modulated radiotherapy (IMRT), 267
Interstitial lung disease (ILD), 198
Interstitial pneumonitis, drugs, 243
Intracranial tumours, 55
Intrathoracic airway obstruction, 89

J
Jarcho-Levin syndrome
SCD, 118
STD, 118, 119
Jeune syndrome, 231
causes, 118
LTE technique, 119
narrow chest, 120
square-shaped chest, 120
VEPTR insertion, 119–121
Joubert syndrome, 231
Juvenile dermatomyositis, 199, 204

K
Kartagener syndrome, 232
Kyphoscoliosis, 128, 147, 148

L
Langerhans cell histiocytosis (LCH), 54
Laryngomalacia, 82–84
Laryngotracheoesophageal cleft (LTEC), 94, 95
Lateral thoracic expansion (LTE) technique, 119
Leber congenital amaurosis, 231

Left pulmonary artery sling, 10
Leigh's syndrome, 166
Leukaemia
ALL, 36
AML, 36
chemotherapy, 37, 38
lung function post childhood leukaemia, 37
pulmonary infiltrates, 54
treatment, 36
Leukotriene receptor antagonists (LTRAs), 143
Ligamentum arteriosum, 6
Long-acting beta-agonists (LABAs), 143
Lower airway obstruction, 93–97
airway soilage (*see* Airway soilage)
intrathoracic airway obstruction, 89
tracheal stenosis, 92, 93
tracheobronchomalacia, 90–92
wheezing, 89, 90
Lower respiratory disease, 288
Lung function, post childhood leukaemia, 37
Lung syndrome, 194
Lymphangioleiomyomatosis (LAM), 154, 155, 157, 158

M
Mechanical ventilation implications, 286
Mechanistic target of rapamycin (mTOR), 292
Meckel-Gruber syndrome, 228, 231, 232
Mediastinal tumours, 54
Menstruation-related spontaneous pneumothorax (MSP). *See* Catamenial pneumothorax (CP)
Metabolic acidosis, 166
Metabolic alkalosis, 166
Metabolic disturbances, 173
Metabolic syndrome, 216, 217
Metapneumovirus, 288
Methotrexate, 37
Micrognathia, 88, 89
Microscopic polyangiitis (MPA), 200
Mild bronchiectasis, 196
Molecular genetics, 270
Morbid obesity, 209, 216
Motile ciliary dysfunction, 230
Motile ciliopathies, 232
Mucopolysaccharidosis, 131
Mucormycosis, 288
Mucositis, 64
Mycobacterium Tuberculosis, 292

N
Nasal saccharin testing, 224
Neonatal respiratory distress, 222
Nephronophthisis, 231
Neural networks, 163
Neuromuscular and genetic disorders
achondroplasia, 131
bulbar weakness, 131
cardiomyopathy, 135
central apneas, 133
COLVI myopathies, 130, 134
cough-assisted techniques, 135
diagnostic investigations, 132, 133
exercise tests, 134
lung function tests, 134
metabolic/hereditary diseases, 129
mucopolysaccharidosis, 131
myasthenia, 129
nocturnal hypoventilation, 134
noninvasive volitional maneuvers, 134
pathophysiological mechanisms, 130, 131, 136
respiratory muscle weakness, 128
respiratory problems, 131, 132
sleep study, 133, 134
SMA, 129, 130
SNIP measurement, 135
thoracic deformity, 131, 132
treatment, 135
Niemann-Pick disease, 131
Nitrosoureas, 59
Nocturnal hypoventilation, 134
Nodal vesicular parcel (NVP) model, 228, 229
Noncaseating granulomatous lesions/nodules, 201
Non-heterotaxy congenital heart disease, 230
Non-mental health practitioners, 178
Non-motile ciliopathy syndrome, 231, 232
Non-rapid eye movement (NREM) sleep, 166, 169–171
Nonspecific interstitial pneumonitis (NSIP), 198
Nucleus tractus solitarius (NTS), 164

O
Obesity
on airway reactivity, 213
with asthma, 214, 215
breathing control, 216
classes, 209
coronary artery disease, 213
definition, 209
and dyspnea, 214

endocrine homeostasis, 215, 216
on exercise tolerance, 213
expiratory reserve volume, 210–211
fat excess accumulation, 209
functional residual capacity, 210
on gas exchange, 212
hyperdynamic and hypervolemic state, 213
inspiratory capacity, 211
on lower airway obstruction, 212
lung volume measurement, 210
and metabolic syndrome, 216–217
and OHS, 216
pathologic conditions, 210
pathophysiology, 210
residual volume, 211
respiratory system mechanics, 211
surgical complications, 217
total lung capacity, 211
on upper airway obstruction, 211, 212
ventricular dysfunction, 213
vital capacity, 211
Obesity hypoventilation syndrome (OHS), 216
Obstetric disorders, 142–149
amniotic fluid embolism, 151
obstructive airway disease
ARDS, 149
asthma, 142, 143
cystic fibrosis, 144
kyphoscoliosis, 147, 148
pneumonia, 145–147
sarcoidosis, 148, 149
tuberculosis, 146
PAVMs, 152
pulmonary edema, 149, 150
pulmonary embolism, 150, 151
spontaneous pneumothorax, 152, 153
venous air embolism, 151, 152
Obstructive cycling, 170
Obstructive pattern, 204
Obstructive sleep apnea (OSA), 154, 159, 166, 211
Obstructive sleep-disordered breathing, 171
Orofaciodigital syndrome, 231
Orthotopic liver transplant, 286
Ovarian hyperstimulation syndrome (OHSS), 158, 159

P

Parainfluenza virus, 288
Patient Health Questionnaire (PHQ-9), 184
Patient-Reported Outcomes Measurement Information System (PROMIS), 184
Pectus carinatum, 121, 123
Pectus excavatum, 121, 122
Perceived Stress Scale (PSS)., 184
Peri-engraftment respiratory distress syndrome (PERDS), 65
Peripheral chemoreceptors, 164
Peripheral edema, 14
Peripheral leukocytosis, 286
Pickwickian syndrome, 216
Plastic bronchitis, 17
Pleural diseases, drugs, 244
Pleural effusions, 16
Pneumocystis Jirovecii, 292
Pneumocystis pneumonia, 292
Pneumocytes, 265
Pneumomediastinum with interstitial pneumonitis, 199
Pneumonia, obstetric disorders
aspiration pneumonia, 146, 147
bacterial pneumonia, 145
fungal pneumonia, 146
intrauterine and neonatal deaths, 145
preterm labor, 145
viral pneumonia, 145, 146
Polycystic ovarian syndrome (PCOS), 159
Polycythaemia, 42
Polymyositis, 194
Polyomaviruses, 288, 290
Posttransplant infectious complications, 283
Posttransplant lymphoproliferative disease (PTLD), 288–290
Prader-Willi syndrome, 112
Pregnancy, 140, 141, 155–159
gynecologic disorders (*see* Gynecologic disorders)
in lung transplant patients, 153, 154
OSA, 154
physiological changes
chest wall, 140, 141
lung function, 141
upper airways, 140
in rare lung diseases, 154, 155
Primary ciliary dyskinesia (PCD), 219
in adulthood, 222
autosomal recessive disorder, 222
clinical features and patterns, 222
clinical trials, 225
cytoplasmic and regulatory proteins, 222
diagnosis, 222–225
encoding ciliary structural proteins, 222
genetic defects, 224
genetic testing, 230
ineffective mucociliary clearance, 222
and laterality defects, humans, 225
lung function in, 223

Primary ciliary dyskinesia (PCD) (*cont.*)
neonatal respiratory distress, 222
organ laterality, 222
prevalence, 222
situs inversus totalis, 222
supplemental oxygen therapy, 222
treatment, 225
Primary lung cancer, 53, 268
Prophylaxis strategy, 289
Pseudoachalasia, 26
Psychiatric disorders
avoidance and motivation, 185
complications, 178
prevalence, 177
psychophysiology, 177
secondary gain, 185
stress and emotion dysregulation, 178
Psychogenic cough, 182, 186
Pulmonary arterial hypertension (PAH), 68, 199, 200
Pulmonary arteriovenous malformations (PAVMs), 152
Pulmonary edema, 14, 286
in pregnancy, 149, 150
Pulmonary embolism (PE), 43, 60
in pregnancy, 150, 151
Pulmonary fibrosis, 199
Pulmonary function testing (PFT), 203–205, 270
amiodarone, 249
azathioprine, 258
bleomycin, 253
busulfan, 255
carbamazepine, 250
carmustine, 256
chlorambucil, 255
cyclophosphamide, 254
diphenylhydantoin, 250
methotrexate, 257
minocycline, 246
mitomycin C, 253
nitrofurantoin, 245
penicillamine, 248
and polysomnography, 217
restrictive spirometric pattern, 245
sulfasalazine, 247
Pulmonary hemorrhage/hemoptysis, 15, 200
Pulmonary infiltrates
in leukaemia and lymphoma, 54
pulmonary leukostasis, 53
Pulmonary leukostasis, 53
Pulmonary malignancies
bronchoalveolar lavage, 56
chemotherapy
alkylating agents, 59
bleomycin, 58, 59
chemotherapeutic agents, 57
corticosteroids, 58
drug-induced lung toxicity, 58
interstitial pneumonitis, 58
permanent fibrosis, 58
pulmonary-toxic chemotherapies, 57
synergistic toxicity, 58
complications, 52
CT-guided fine-needle biopsy, 56
endotracheal and endobronchial lesions, 53
extra-thoracic space-occupying tumours, 55
intracranial tumours, 55
LCH, 54
long-term follow-up protocols, 69
mediastinal tumours, 54
metastases, 53
multifactorial immune defects, 55
normal lung growth and development, 60
primary lung tumours, 53
pulmonary infiltrates
acute lysis pneumopathy, 54
differentials, 56
hyperleukocytosis, 53
in leukaemia and lymphoma, 54
pulmonary leukostasis, 53
respiratory infections, 56
respiratory pathogens, 55, 56
surgical interventions, 59, 60
thoracoscopic/open lung biopsy, 56
thromboembolic complications, 60
Pulmonary oedema, 64
Pulmonary-toxic chemotherapies, 57
Pulmonary vasculature, 199, 200
Pulmonary venolobar syndrome, 10, 11
Pulmonary veno-occlusive disease (PVOD), 68
Pump-handle effect, 108

R

Radiation-induced fibrosis (RIF), 264, 267, 273
Radiation-induced lung injury (RILI), 264, 265
Radiation-induced lung toxicity
development of, 268
plasma cytokines, 272
and SNPs, 271
Radiation pneumonitis (RP), 265
alveolar capillary unit, 273
azathioprine, 273

classification systems, 266
cyclosporine A, 273
diagnostic testing, 270
inhaled beclomethasone HFA, 273
inhaled fluticasone, 273
inhaled steroid, 273
nontreatment-related risk factors, 268–270
prevention, 274
scoring systems, 266
severity grading, 266, 267
steroid treatment, 273
symptomatic treatment, 264, 274
symptoms, 270
systemic steroids, 273
treatment plan, 273
treatment-related risk factors, 267, 268
tumor location, 269
Radiation therapy (RT)
amifostine, 274
cancer treatment, 264
chest CT, 266
cytoprotective agents, 275
of healthy lung tissue, 265
pentoxifylline, 274
phosphodiesterase blockade, 274
radiation-induced lung injury, 275
radiosensitivity, 264
symptomatic, 266
vitamin E, 275
Radioaerosol mucociliary clearance tests, 224
Radiosensitivity, 264
Rapid eye movement (REM) sleep, 170
Relapsing polychondritis, 197
Renal/multi-visceral transplantation, 288
Respiratory distress syndrome, 293
Respiratory loop gain, 167
Respiratory pattern generator, 163
Respiratory symptoms, 232
Respiratory syncytial virus (RSV), 288, 291
Respiratory system, 128
advanced lung diseases, 128
airway malacia, 128
central drive, 128
chemoreceptor sensitivity, 128
chest wall disorders (*see* Chest wall disorders)
exercise, 129
hypercapnia, 128
hypoxemia, 128
mechanics, 211
neuromuscular and genetic disorders (*see* Neuromuscular and genetic disorders)
physiological changes, 128, 129
rapid eye movement sleep, 128
respiratory load, 128
sleep and exercise, 128
upper airway obstruction, 128
Respiratory tract disease, 203
Respiratory viral infections, 291
Retinal degeneration, 232
Retinitis pigmentosa, 231
Rheumatologic disorders, 193–195, 197
antibodies, 193
clinical symptoms, 202
and connective tissue diseases, 192
effects and prevalence, 194
indirect complications, 201
lung biopsy, 203
morbidity, 202
mortality, 202
pathogenesis, 191, 192
patient evaluation, 191
pleural effusion, 195
radiographs, 203
respiratory system, effects
alveolar involvement/air space disease, 197
chest wall rigidity, 193
diaphragm, 194
lower airway, 195
pleural effusions, 194
prevalence, 193
pulmonary complication, 193
respiratory symptoms, 191
upper airways, 195
subglottic airway, patient with relapsing polychondritis, 196
Rhinovirus, 288
Rhizopus pneumonia, 288
Robin sequence (RS), 88, 89
RT-induced injury, 270

S

Sarcoidosis, 148, 149, 201
Scimitar syndrome, 10, 11
Senior-Løken syndrome, 231
Serum/BAL *Aspergillus* galactomannan antigen (Platelia antigen) testing, 287
Severe acquired tracheal stenosis, 204
Sickle cell disease (SCD), 33, 34
acute chest syndrome, 32, 33
bronchial hyperreactivity, 33
chronic lung disease, 33
impulse oscillometry, 34
inhaled steroids, 34

Sickle cell disease (SCD) (*cont.*)
lung function abnormalities
anaemia, 34
asthma, 34
deoxygenation, 33
haemolysis, 33
spirometry, 34
Sickle chronic lung disease (SCLD), 33
Single nucleotide polymorphism (SNP) techniques, 270
Situs ambiguus (SA), 227, 228
Situs inversus totalis, 226, 227
Situs solitus, 227
Sjogren's syndrome, 194
Skin prick test, 143
Sleep fragmentation, 170
Sniff nasal inspiratory pressure (SNIP) measurement, 135
Solid organ transplantation (SOT), 281–286
immunosuppression, 281
infectious complications, 281
non-pulmonary
chylous effusions, 282
elevated unilateral hemidiaphragm, 282
left-sided/persistent effusions, 282
oncotic/hydrostatic pressure, 282
pleural effusions, 282
pleural fluid collections, 282
posttransplantation infections, 283–286
pulmonary edema, 281
post transplant care, 281
surgical approach, 281
Spinal muscular atrophy (SMA), 113, 115–117, 129, 130
Spirometry, 142
Spondylocostal dysostosis (SCD), 118
Spondylothoracic dysplasia (STD), 118, 119
Spontaneous pneumothorax, 152, 153
Stereotactic body radiotherapy (SBRT), 268
Stressors, 187, 188
Subglottic stenosis (SGS), 86, 88
Systemic lupus erythematosus (SLE), 194

T
β-Thalassaemias
abnormal haemoglobin synthesis, 35
cardiac complications, 36
chest radiograph abnormalities, 36
lung function abnormalities, 35, 36
pulmonary function, 35
respiratory function monitoring, 36
Thoracic endometriosis syndrome (TES), 155, 156
Thromboembolism, 43, 44
Tongue-lip adhesion (TLA)., 89
Total body irradiation (TBI), 267
Toxoplasma infection, 292
Tracheal stenosis, 11, 92, 93
Tracheobronchomalacia
aortopexy, 91
bare metal stents, 91
bioabsorbable stents, 91
covered metallic/nitinol stents, 91
diagnosis, 91
endobronchial stenting, 91
management strategy, 91
self-expanding stents, 91
silicone stents, 91
symptoms, 90
tracheostomy, 91
Tracheoesophageal fistulas (TEF), 27, 96, 97
Tracheostomy
aerodigestive model, 98
aspiration, 97
dysphagia, 97
indications, 97
mortality rate, 97
mucociliary clearance, 97
respiratory consequences, 93
swallowing dysfunction, 97
tracheobronchomalacia, 91
Traction bronchiectasis, 199, 266
Tuberculin skin testing, 146
Tuberculosis, 146

U
Upper airway obstruction, 131
acquired lesions, 81, 83
congenital lesions, 81, 82
laryngomalacia, 82–84
primary infections, 81
Robin sequence, 88, 89
subglottic stenosis, 86–88
VFI, 85, 86
Usher syndrome, 231
Usual interstitial pneumonitis (UIP), 198

V
Varicella zoster immune globulin (VariZIG), 145–146
Vasculitides, 192, 244
Vasculitis, 200
Venous air embolism, 151, 152
Venous thromboembolism (VTE), 43
Ventilator-associated pneumonia (VAP), 286

Ventilatory control system, 165, 168
Ventilatory response, 167
Ventral respiratory group (VRG), 163
Vertical expandable prosthetic titanium rib (VEPTR)
EOS, 110–112
Jeune syndrome, 119–121
Viral infections, 288
Viral pneumonia, 145, 146
Vocal cord dysfunction (VCD), 180, 181
Vocal cord paralysis, 16
Vocal fold immobility (VFI), 85, 86

W
Wegener's granulomatosis, 195, 200
White blood cells abnormalities. *See* Leukaemia

X
X-linked ciliopathy, 232
X-linked retinitis pigmentosa, 232