Chang *et al. BMC Oral Health* (2025) 25:246
https://doi.org/10.1186/s12903-025-05588-0

BMC Oral Health

RESEARCH Open Access

Development of a diagnostic classification model for lateral cephalograms based on multitask learning

Qiao Chang[1], Shaofeng Wang[1], Fan Wang[1], Beiwen Gong[1], Yajie Wang[2,3], Feifei Zuo[3], Xianju Xie[1*] and Yuxing Bai[1*]

Abstract

Objectives This study aimed to develop a cephalometric classification method based on multitask learning for eight diagnostic classifications.

Methods This study was retrospective. A total of 3,310 lateral cephalograms were collected to construct a dataset. Eight clinical classifications were employed, including sagittal and vertical skeletal facial patterns, maxillary and mandibular anteroposterior positions, inclinations of upper and lower incisors, as well as their anteroposterior positions. The images were manually annotated for initially classification, which was verified by senior orthodontists. The data were randomly divided into training, validation, and test sets at a ratio of approximately 8:1:1. The multitask learning classification model was constructed based on the ResNeXt50_32×4d network and consisted of shared layers and task-specific layers. The performance of the model was evaluated using classification accuracy, precision, sensitivity, specificity and area under the curve (AUC).

Results This model could perform eight clinical diagnostic classifications on cephalograms within an average of 0.0096 s. The accuracy of the six classifications was 0.8–0.9, and the accuracy of the two classifications was 0.75-0.8. The overall AUC values for each classification exceeded 0.9.

Conclusions An automatic diagnostic classification model for lateral cephalograms was established based on multitask learning to achieve simultaneous classification of eight common clinical diagnostic items. The multitask learning model achieved better classification performance and reduced the computational costs, providing a novel perspective and reference for addressing such problems.

Keywords Cephalometry, Deep learning, Image classification, Multitask learning

*Correspondence:
Xianju Xie
dentist.x@163.com
Yuxing Bai
byuxing@ccmu.edu.cn
[1]Department of Orthodontics, Beijing Stomatological Hospital, Capital Medical University, Beijing, China
[2]Department of Engineering Physics, Tsinghua University, Beijing, China
[3]LargeV Instrument Corporation Limited, Beijing, China

© The Author(s) 2025. **Open Access** This article is licensed under a Creative Commons Attribution-NonCommercial-NoDerivatives 4.0 International License, which permits any non-commercial use, sharing, distribution and reproduction in any medium or format, as long as you give appropriate credit to the original author(s) and the source, provide a link to the Creative Commons licence, and indicate if you modified the licensed material. You do not have permission under this licence to share adapted material derived from this article or parts of it. The images or other third party material in this article are included in the article's Creative Commons licence, unless indicated otherwise in a credit line to the material. If material is not included in the article's Creative Commons licence and your intended use is not permitted by statutory regulation or exceeds the permitted use, you will need to obtain permission directly from the copyright holder. To view a copy of this licence, visit http://creativecommons.org/licenses/by-nc-nd/4.0/.

Introduction

Cephalometric analysis is used to analyze the structure of cranial and maxillofacial soft and hard tissues, along with their relationships, thereby facilitating accurate diagnosis and treatment planning. Conventional cephalometric analysis involves annotating landmarks, measuring angles and distances. These measurements are then compared with the normal values to perform diagnostic classification. However, manual annotation is not only time-consuming but also prone to intra-observer and inter-observer variability [1]. Therefore, a growing number of studies have employed artificial intelligence (AI) models for landmark detection [2–4]. For instance, the 2015 IEEE ISBI Open Dental X-ray Image Analysis Challenge set 19 landmarks for automatic detection and eight cephalometric measurement items for classification [5, 6]. In addition to calculating these measurements, diagnostic classification is also an important part of automatic cephalometric analysis. However, Lee J evaluated the performance of four automatic cephalometric analysis services and reported that their classification reliability was clinically unacceptable [7].

Reviewing the historical development of orthodontic cephalometric measurements, the process of establishing the measurements and normal values involved selecting subjects with ideal occlusal and well-balanced facial features, analyzing their characteristics, and statistically deriving a mean range [8, 9]. This process aimed to translate the judgment criteria for occlusion and facial aesthetics into quantifiable values for clinical diagnosis. However, diagnoses based solely on these measurement values have several shortcomings: (1) From landmark detection to diagnostic classification, the results are susceptible to many sources of error and difficult to assess. (2) The application of different analysis methods may lead to different conclusions, which may cause confusion for beginners. (3) Directly comparing the normal values may ignore the impact of positional variations in relevant reference planes or landmarks on measurement items, which may result in discrepancies between the outcomes and clinical experience. Thus, there are limitations in classification derived from automatic landmark detection.

To overcome these limitations and improve the reliability of automatic diagnostic classification, several studies have attempted to skip the detection step and directly classify lateral cephalograms [10–14]. One notable advantage of deep learning is its capacity to classify images directly, effectively identifying a mapping relationship between images and diagnosis. Kim HJ et al. compared the performance of two automatic classification methods and found that direct image classification had advantages [12]. This approach reduces classification errors by eliminating the need for annotation and cephalometric measurements. However, these studies mainly focused on the diagnosis of sagittal and vertical skeletal facial patterns and, for dental diagnosis, only overbite, which does not fully address clinical needs. Our group has used the DenseNet-121 network to successfully perform eight diagnostic classifications, including sagittal and vertical skeletal facial patterns, maxillary and mandibular anteroposterior (AP) positions, and inclinations and anteroposterior (AP) positions of the upper and lower incisors [15]. However, the performance of some classifications still needs to be improved.

Current research typically trained models using a single task, without considering the associations between different classification tasks. In addition, the risk of overfitting easily occurs in small sample training, resulting in poor generalization ability. To address the above limitations, multitask learning has been proposed [16]. This approach facilitates information exchange and mutual inspiration across multiple tasks, thereby improving performance, enhancing generalizability, and reducing repetitive model processing. Based on our understanding and application of multitask learning [17], the present study developed a multitask learning-based cephalometric classification model to perform eight diagnostic classifications simultaneously. This model assists orthodontists in diagnosing lateral cephalograms more comprehensively and accurately. The method utilized the commonalities and differences among the classifications to improve the classification performance and reduce repetitive model processing, providing a novel perspective for automatic diagnostic classification of cephalometric cephalograms.

Materials and methods

This retrospective study aimed to develop a multi-task model for lateral cephalometric classification to aid in diagnosis. The model is intended to overcome some of the inherent limitations of classifications based on automatic landmark detection. By integrating these two methods, it can provide better assistance in clinical diagnosis.

Data collection

Ethical approval for this study was obtained from the research ethics committee of Beijing Stomatological Hospital, Capital Medical University (No. CMUSH-IRB-KJ-PJ-2022-49). Informed consent was obtained from all participants and, for minors under 16 years of age, from their parents. The patients were recruited from a single center in China. Patients aged 14 and above who visited the Orthodontic Department of Beijing Stomatology Hospital and underwent cephalometric radiography between January 2015 and December 2021 were randomly included in this study. Patients under 14 years old were excluded due to significant differences in facial

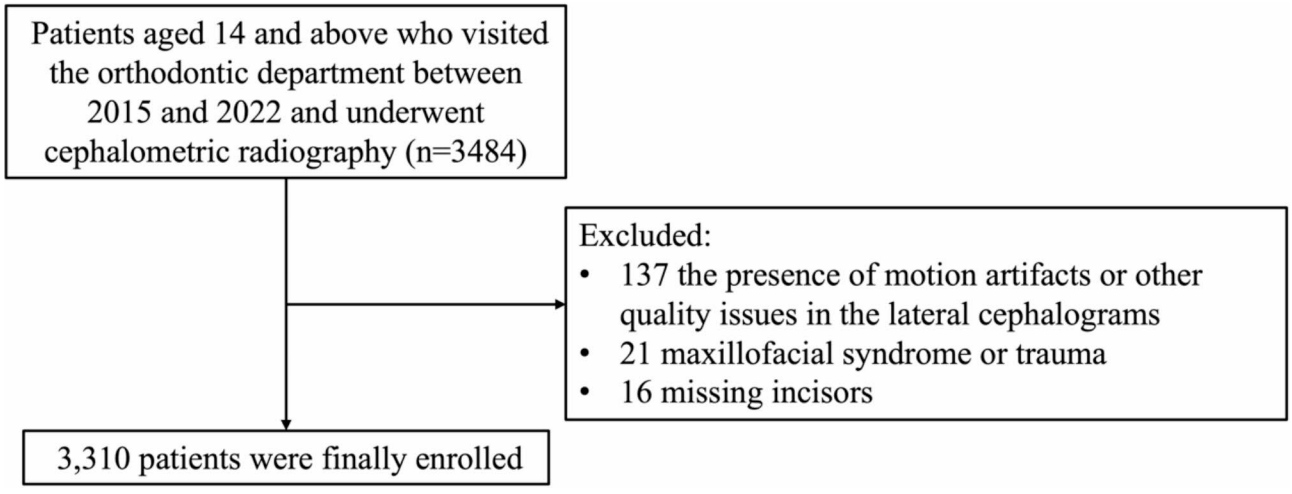

Fig. 1 Data inclusion and exclusion process

features compared to adults [13]. They are in the growth stage and the craniomaxillofacial structures follow different growth patterns. With growth and development, the length of the jaws increases, the sagittal relationship of the jaws changes, and the facial height increases [18, 19]. Therefore, there are differences in the dimension and relationships of the jaw compared to adults. The exclusion criteria were as follows: (1) the presence of motion artifacts or other quality issues in the lateral cephalograms; (2) maxillofacial syndrome or trauma; and (3) missing incisors. Figure 1 shows the inclusion and exclusion processes. Finally, 3,310 patients were enrolled. Reference to previous studies on direct image classification of lateral cephalograms [10–13], which utilized datasets ranging from 1574 to 2662 images, indicates that the dataset size in this study is sufficient for constructing a classification model. All the lateral cephalogram images were obtained using a Kodak 8000 C (Carestream Health Corporation, Toronto, Canada. Parameters: Voltage 80KV, Current 10 mA, X-ray exposure time: 0.5s). The images were stored in tag image file format (Tiff) with a resolution of 1360 × 1840 pixels and an image size of 17.3 × 23.4 cm. During image storage, sensitive information was de-identified to protect patient privacy.

Table 1 The definition and normal range of the measurements corresponding to each classification

Classifications	Measurement	Definition and manual labeled landmarks	Normal range
Sagittal skeletal facial pattern	ANB	The angle of landmarks of A, N, B	2.7 ± 2°
Vertical skeletal facial pattern	SN-GoGn	The angle between SN plane (S, N) and MP plane (Go, Gn)	32.5 ± 5.4°
Maxillary AP position	SNA	The angle of landmarks of S, N, A	82.8 ± 4°
Mandibular AP position	SNB	The angle of landmarks of S, N, B	80.1 ± 3.9°
Inclination of upper incisors	U1-SN	The angle between upper incisors (UIA, UI) and SN plane (S, N)	105.7 ± 6.3°
Inclination of lower incisors	IMPA	The angle between lower incisors (LIA, LI) and MP plane (Go, Gn)	93.9 ± 6.2°
AP position of upper incisors	U1-NA	The distance between landmark UI to NA plane (N, A)	5.1 ± 2.4 mm
AP position of lower incisors	L1-NB	The distance between landmark LI to NB plane (N, B)	6.7 ± 2.1 mm

Data classification

Eight clinical classifications were employed, including sagittal skeletal facial patterns, vertical skeletal facial patterns, maxillary and mandibular AP positions, inclination of upper and lower incisors, as well as their AP positions. All images were independently manually annotated by two clinical orthodontists with 5 and 8 years of experience, respectively (Labelme software, MIT, USA). The average of annotation coordinates was used to calculate the corresponding measurements, and preliminary classifications were performed through comparison with the normal values of Chinese individuals [20]. The manual labels, definitions and normal value range for the measurements corresponding to each classification are shown in Table 1. The classification results were verified by two senior orthodontists who have been working in the orthodontic department of the same institute for more than 20 years and have received uniform, standardized training (Cohen's kappa coefficient: 0.853–0.982). During the verification process, if any diagnoses were found to be inconsistent with clinical diagnostic

experience, more measurements need to be analyzed. Each orthodontist was blinded to the results of the others, as well as to the patients' information. Thus, each lateral cephalogram was assigned eight classification labels. The data from the single center were randomly divided into a training set, a validation set, and a test set at a ratio of approximately 8:1:1, consisting of 2648, 331, and 331 cephalograms, respectively. This is a standard method of partitioning, which is also widely used in multiple deep learning task practices to ensure that the model can be effectively trained and evaluated. There was no patient overlap among groups. $\chi 2$ test was conducted using SPSS Statistics for Windows version 26.0 (IBM, Armonk, NY, USA) to examine the differences in clinical characteristics among the datasets. Pvalue < 0.05 indicates a significant difference in patients' characteristics among the datasets.

Model training

All images were converted to PNG format and resized to 192*256 (width * height). Online data augmentation, including random rotations, adjustments to image contrast, brightness, and other transformations were applied to the lateral cephalograms. During the generation of each batch of training data, it dynamically adjusted the transformation strategies.

The lateral cephalograms of the training set were input into the multitask learning classification network to determine their intrinsic relationships with the eight classification labels. The overall network framework, consisting of shared layers and task-specific layers, is shown in Fig. 2. The sharing layers facilitated the exchange of visual features with rich information among related tasks, which not only reduced the probability of overfitting for each task but also significantly enhanced memory efficiency and inference speed. The specific task layers focused on the unique information for each task to determine the category. Served as the backbone network, the ResNeXt50_32 × 4d network [21] (50 represents the depth of the network, 32 represents the number of groups in the packet convolution, and 4 represents the number of convolution kernels in each group) was pretrained on the large-scale natural image dataset, ImageNet [22]. The network structure consisted of several residual blocks, each consisting of several convolutional layers, grouped convolutional layers, batch normalization layers, and activation layers. The convolution sequence of residual blocks follows a pattern: convolution, grouped convolution, and then another convolution. The first convolutional operation primarily focuses on preliminary feature extraction, capturing local features such as edges, textures, and other low-level details. The second grouped convolution efficiently processes features by dividing the input channels into multiple groups and performing convolution operations independently within each group. This increases the network's channel count and expressive power, allowing it to learn the distinct features between different groups. The third convolutional operation involves the fusion and refinement of features after grouped convolution. This enables the network to learn more advanced, abstract, and comprehensive features, which are conducive to accurate classification. The output of the last grouped convolutional layer was added to the input of the residual block to form a residual connection. The shared layers were based on the ResNeXt50_32 × 4d network, modifying the last fully connected layer to obtain a 512-dimensional vector and connecting the batch normalization layer, the activation layer, and the random deactivation layer. The task-specific layers consisted of eight fully connected layers, each outputting a 3-dimensional vector. These vectors were converted to probability values for their respective categories using the Softmax function. The category with the highest probability is then output as the classification result.

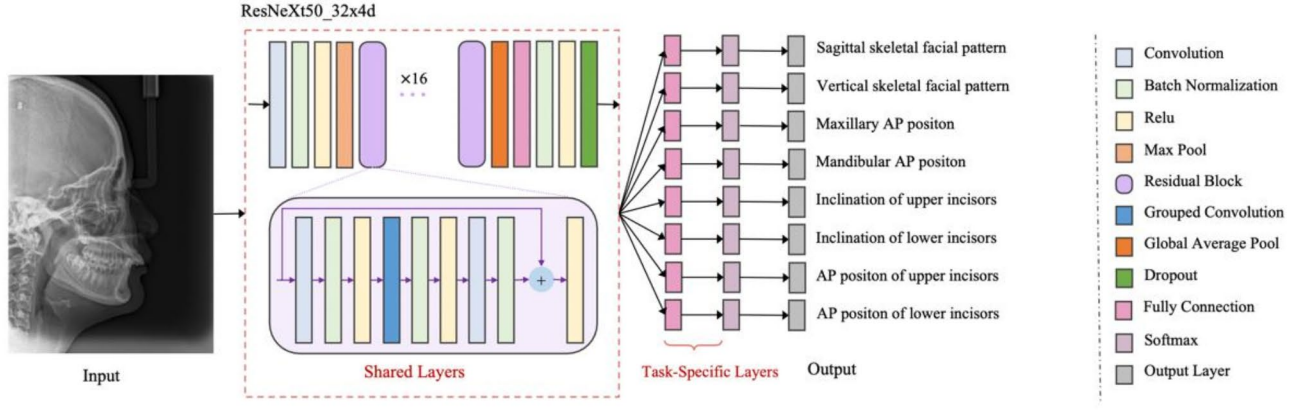

Fig. 2 Diagrams of the model architecture

The model was constructed using the multitask learning framework LibMTL [23] and implemented in the Python. The main software libraries include torch = = 1.8.1 + cu111, torchvision = = 0.9.1 + cu111, numpy = = 1.24.4, and Pillow = = 10.1.0. It was built on a personal computer running the Ubuntu system (20.04) and the NVIDIA GeForce RTX 3080 GPU (NVIDIA, Santa Clara, CA). Pre-training parameters of ImageNet were used for initialization, which mainly affected the weight parameters of the shared layers. The comparative experiments were conducted in terms of soft and hard parameter sharing, weight balancing strategy, network structure, learning rate, optimizer. Specifically, the details are as follows: For hard and soft parameter sharing, comparisons were made between Muti-task Attention Netwok (MTAN) and Hard Parameter Sharing (HPS). In terms of network architecture, we evaluated ResNet18, ResNet34, ResNet50, ResNet101, and ResNeXt50_32 × 4d. For weight balancing strategy, four strategies were compared: Dynamic Weight Average (DWA), Equal Weighting (EW), Gradient Normalization (GradNorm), and Uncertainty Weights (UW). 0.01, 0.001, and 0.0001 were chosen as the learning rate for training respectively. In terms of optimizer, a comparison was made between the classic Stochastic Gradient Descent (SGD) optimizer and Adaptive Moment Estimation (Adam) optimizer. While keeping other hyperparameters unchanged, the performance of the model on the validation set was observed. The batch size chosen was 64. After 100 epochs of training, the loss function tended to stabilize, indicating model convergence. The model with the highest accuracy in the validation set was selected as the final model. The weight balancing strategy, DWA [24], was used to adjust the task weights over time by considering the rate of change in the loss for each task. This method ensured a balance training process among multiple tasks, preventing any single task from dominating the entire training. Focal loss [25] was used for the loss function. 0.001 is determined as the optimal learning rate. We chose the efficient and stable Adam optimizer, which calculated the sample average and sample square average of the gradient of each parameter in the loss function to dynamically adjust the learning rate so that the parameter converges at an appropriate speed. Training parameters (parameter size, model size, training time) and inference time were recorded and compared to the single-task model.

Evaluation

A test set of 331 lateral cephalograms was used to evaluate the model's performance. The accuracy, precision, sensitivity, and specificity of the classification were calculated based on the confusion matrix.

$$Accuracy = \frac{TP + TN}{TP + TN + FP + FN} \tag{1}$$

$$Precision = \frac{TP}{TP + FP} \tag{2}$$

$$Sensitivity = \frac{TP}{TP + FN} \tag{3}$$

$$Specificity = \frac{TN}{TN + FP} \tag{4}$$

Taking the sagittal skeletal facial pattern as an example, TP (true-positive) indicated the correct classification of Class I patients; TN (true-negative) indicated that actual non-Class I patients were correctly classified as non-Class I; FN (false-negative) indicated that actual Class I patients were misclassified as non-Class I; and FP (false-positive) indicated that actual non-Class I patients were misclassified as Class I. Bootstrapping was used to generate 1,000 resampled independent test sets, simulating performance evaluations under varying data distributions. The 95% confidence intervals (CI) were calculated based on these resampled sets. Receiver operating characteristic (ROC) curves and the area under the curve (AUC) were used to assess the performance. The consistency between the model and the standard classification label was evaluated by Cohen's kappa coefficient.

Results

Demographic and clinical characteristic of patients in the datasets

According to the above-mentioned inclusion and exclusion criteria, 3310 patients were finally enrolled, including 1,564 males and 1,746 females, with a mean age of 24.5 ± 8.3 years (range: 14–54 years). The distribution of classifications in each dataset is shown in the Table 2. The differences in clinical characteristics among the datasets had no statistical significance, suggesting that the random grouping was reasonable.

Comparative experiments

The accuracy of validation set with different experimental settings is shown in Table 3. The model with the highest accuracy in the validation set was selected as the final model.

Model performance

This model could perform eight clinical diagnoses on cephalograms the within an average of 0.0096 s. A comparison of the training parameters and inference times between DenseNet-121 for a single task, and the proposed model for eight tasks, is presented in Table 4. The detailed results of the test set are shown as multiclass

Table 2 Distribution of classifications in the training set, validation set, and test set

Classifications	Training set (*n* = 2648)	Validation set (*n* = 331)	Test set (*n* = 331)	*p* value
Sagittal skeletal facial pattern				0.781
Class III	794 (30.0%)	101 (30.5%)	107 (32.3%)	
Class I	824 (31.1%)	95 (28.7%)	102 (30.8%)	
Class II	1030 (38.9%)	135 (40.8%)	122 (36.9%)	
Vertical skeletal facial pattern				0.870
Hypodivergent	586 (22.1%)	78 (23.6%)	70 (21.1%)	
Normodivergent	1373 (51.9%)	167 (50.5%)	180 (54.4%)	
Hyperdivergent	689 (26.0%)	86 (26.0%)	81 (24.5%)	
Maxillary AP position				0.638
Retrognathic maxilla	482 (18.2%)	66 (19.9%)	61 (18.4%)	
Normal maxilla	1646 (62.2%)	191 (57.7%)	203 (61.3%)	
Prognathic maxilla	520 (19.6%)	74 (22.4%)	67 (20.2%)	
Mandibular AP position				0.466
Retrognathic mandible	589 (22.2%)	68 (20.5%)	61 (18.4%)	
Normal mandible	1603 (60.5%)	203 (61.3%)	204 (61.6%)	
Prognathic mandible	456 (17.2%)	60 (18.1%)	66 (19.9%)	
Inclination of upper incisors				0.758
Lingual inclination	462 (17.4%)	55 (16.6%)	52 (15.7%)	
Normal inclination	1176 (44.4%)	139 (42.0%)	149 (45.0%)	
Labial inclination	1010 (38.1%)	137 (41.4%)	130 (39.3%)	
Inclination of lower incisors				0.507
Lingual inclination	609 (23.0%)	74 (22.4%)	80 (24.2%)	
Normal inclination	1212 (45.8%)	167 (50.5%)	149 (45.0%)	
Labial inclination	827 (31.2%)	90 (27.2%)	102 (30.8%)	
AP position of upper incisors				0.772
Retrusion	453 (17.1%)	58 (17.5%)	51 (15.4%)	
Normal	1526 (57.6%)	185 (55.9%)	187 (56.5%)	
Protrusion	669 (25.3%)	88 (26.6%)	93 (28.1%)	
AP position of lower incisors				0.086
Retrusion	914 (34.5%)	109 (32.9%)	105 (31.7%)	
Normal	1168 (44.1%)	168 (50.8%)	149 (45.0%)	
Protrusion	566 (21.4%)	54 (16.3%)	77 (23.3%)	

Table 3 The accuracy of the validation set for different experimental settings

Soft and hard parameter sharing	Weight balancing strategy	Network structure	Learning rate	Optimizer	Accuracy of the validation set
MTAN	EW	ResNet18	0.001	SGD	0.7284
HPS	EW	ResNet 18	0.001	SGD	0.8028
HPS	UW	ResNet 18	0.001	SGD	0.7824
HPS	GN	ResNet 18	0.001	SGD	0.7950
HPS	DWA	ResNet 18	0.001	SGD	0.8053
HPS	DWA	ResNet 34	0.001	SGD	0.8069
HPS	DWA	ResNet 50	0.001	SGD	0.8095
HPS	DWA	ResNet 101	0.001	SGD	0.8002
HPS	DWA	ResNeXt50_32 × 4d	0.001	SGD	0.8125
HPS	DWA	ResNeXt50_32 × 4d	0.01	SGD	0.7820
HPS	DWA	ResNeXt50_32 × 4d	0.0001	SGD	0.7993
HPS	DWA	ResNeXt50_32 × 4d	0.001	Adam	0.8142

confusion matrices in Fig. 3. These confusion matrices visually illustrated the quantity and distribution of both correctly and incorrectly classified samples. The majority of the samples are located in the diagonal position of the confusion matrix, which represents a correct classification. The confusion matrices in Supplementary Fig. 1 are used to compare the distribution of misclassifications. Almost all misclassifications were concentrated between adjacent types, and there was no confusion between two abnormal types, such as classifying skeletal

Table 4 Comparison of training parameters and inference time between DenseNet-121 (single-task) and the proposed model (eight task)

	Params Size (MB)	Model Size (MB)	Training Time (s/epoch)	Inference Time (s/per Image)
Densenet121 (**single task**)	26.54	368.47	12(avg)	0.01423(avg)
ResNeXt50_32×4d (**eight task**)	91.71	447.44	18	0.0069

class II as class III. The accuracy, precision, sensitivity, and specificity of classification were calculated, as shown in Table 5. The accuracy of six classifications was 0.8–0.9, including sagittal and vertical skeletal facial patterns, maxillary and mandibular AP position, inclination and AP position of the lower incisors. For the inclination and AP position of the upper incisors, the accuracy was slightly lower, ranging from 0.75 to 0.8. The ROC curves and AUCs for each classification are provided in Fig. 4; Table 5. The overall AUC values for each classification were above 0.9. The kappa consistency results are shown in Table 6. Except for the AP position of upper incisors, the consistency for the remaining classifications fell within the range of 0.6 to 0.8, indicating substantial consistency. Image examples of correct classifications and misclassifications are shown in Fig. 5.

Discussion

The automatic diagnostic classifications of lateral cephalograms can be classified into two types: those based on automatic landmark detection and those based on images without landmark detection. The error sources in the former type include those related to automatic landmark detection, the calculation process, and variations in the reference planes or landmarks. The measurements require combinations of multiple landmarks, leading to multiple sources of errors and assessment complexities [27]. For measurements at the edge of the normal range, even small errors may lead to misclassification. Additionally, the measurements can be affected by several factors, such as facial height, jaw rotation, and reference plane variations [28]. For instance, the ANB angle is affected by the position of the nasion and mandibular rotation [29]. Direct calculations without taking influencing factors into consideration may lead to inconsistent classifications with clinical judgment. Cephalometric diagnosis is not simply a comparison of normal values; rather, it requires a comprehensive analysis based on the experience of the orthodontist. Direct image classification focuses on the overall anatomical structure instead of relying solely on specific landmarks. Kim HJ [12] found that direct image classification models with larger regions of interest performed better for skeletal classifications, especially when landmark identification is challenging, such as in the presence of impacted teeth or brackets.

It may occur in the clinic that the same lateral cephalogram using different indicators shows different diagnoses. Some studies [11, 13] used ANB and Wits values as diagnostic criteria, and only data with consistent classification results between the two were included. However, it may exclude a part of the critical data (cases in which the results of the two classifications do not coincide), resulting in discontinuity of the data, which may increase the risk of bias in the selection of the sample. In this study, a

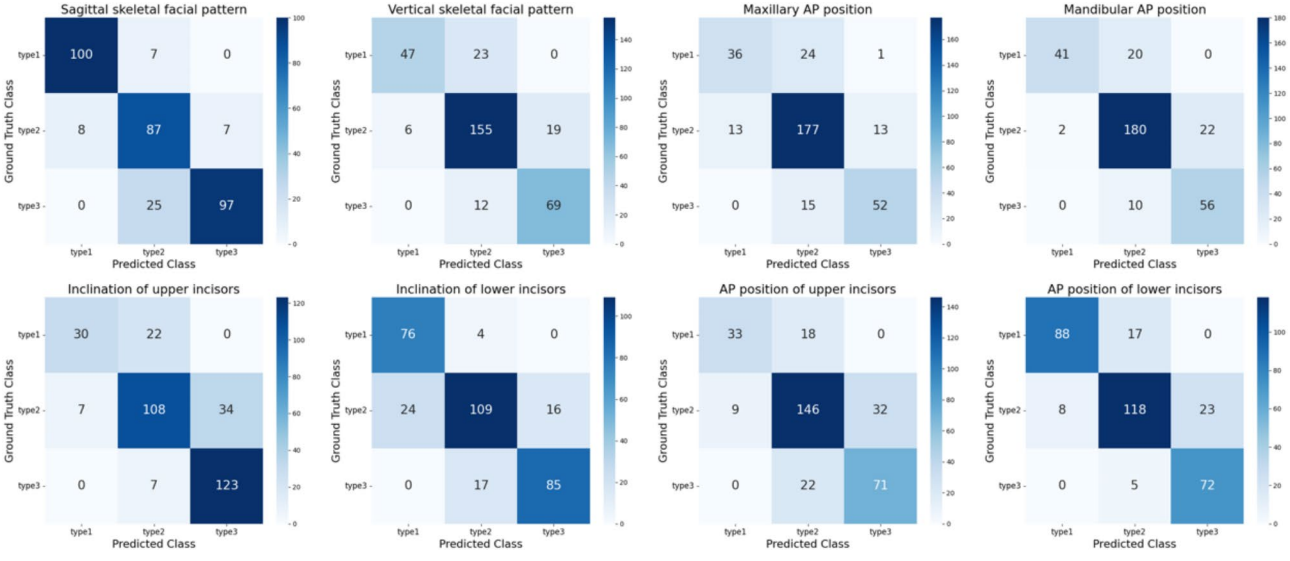

Fig. 3 Confusion matrix of the eight diagnostic classifications. The numbers on the diagonal represent the quantity of correctly classified samples. The higher the numbers, the better the model's performance. The numbers on the off-diagonal represent the quantity of misclassified samples, indicating the distribution of error types

Table 5 Model performance of the eight diagnostic classifications

Classifications		Accuracy (95% CI)	Precision (95% CI)	Sensitivity (95% CI)	Specificity (95% CI)	AUC
Skeletal classification						
Sagittal skeletal facial pattern	Class III	0.955 (0.931–0.976)	0.926 (0.871–0.971)	0.935 (0.884–0.980)	0.964 (0.936–0.987)	0.986
	Class I	0.858 (0.816–0.897)	0.731 (0.652–0.809)	0.853 (0.778–0.920)	0.860 (0.812–0.905)	0.905
	Class II	0.903 (0.870–0.934)	0.933 (0.880–0.975)	0.795 (0.720–0.863)	0.967 (0.942–0.990)	0.971
	Weighted avg	0.858	0.868	0.858	0.933	0.954
Vertical skeletal facial pattern	Hypodivergent	0.912 (0.882–0.940)	0.887 (0.796–0.961)	0.671 (0.557–0.779)	0.987 (0.958–0.992)	0.960
	Normodivergent	0.819 (0.776–0.858)	0.816 (0.763–0.866)	0.861 (0.808–0.911)	0.768 (0.701–0.835)	0.885
	Hyperdivergent	0.906 (0.873–0.937)	0.784 (0.701–0.863)	0.852 (0.772–0.922)	0.924 (0.890–0.955)	0.965
	Weighted avg	0.819	0.823	0.819	0.850	0.943
Maxillary AP position	Retrognathic maxilla	0.885 (0.849–0.918)	0.735 (0.596–0.854)	0.590 (0.468–0.712)	0.952 (0.926–0.977)	0.920
	Normal maxilla	0.804 (0.764–0.846)	0.819 (0.768–0.868)	0.872 0.826–0.915)	0.695 (0.615–0.774)	0.866
	Prognathic maxilla	0.912 (0.882–0.943)	0.788 (0.692–0.883)	0.776 (0.672–0.875)	0.947 (0.920–0.973)	0.942
	Weighted avg	0.801	0.797	0.801	0.794	0.922
Mandibular AP position	Retrognathic mandible	0.934 (0.906–0.961)	0.954 (0.881-1.000)	0.672 (0.548–0.797)	0.993 (0.981-1.000)	0.869
	Normal mandible	0.837 (0.795–0.876)	0.857 (0.808–0.905)	0.882 (0.836–0.924)	0.764 (0.688–0.838)	0.890
	Prognathic mandible	0.903 (0.870–0.931)	0.718 (0.618–0.810)	0.849 (0.764–0.932)	0.917 (0.880–0.946)	0.960
	Weighted avg	0.837	0.847	0.837	0.836	0.947
Dental classification						
Inclination of upper incisors	Lingual inclination	0.912 (0.882–0.943)	0.811 (0.667–0.928)	0.577 (0.435–0.709)	0.975 (0.952–0.993)	0.948
	Normal inclination	0.789 (0.743–0.831)	0.789 (0.718–0.858)	0.725 (0.651–0.795)	0.841 (0.783–0.895)	0.849
	Labial inclination	0.876 (0.840–0.909)	0.783 (0.717–0.848)	0.946 (0.909–0.984)	0.831 (0.778–0.878)	0.950
	Weighted avg	0.789	0.790	0.789	0.858	0.904
Inclination of lower incisors	Lingual inclination	0.915 (0.885–0.946)	0.760 (0.677–0.846)	0.950 (0.899-1.000)	0.904 (0.866–0.941)	0.968
	Normal inclination	0.816 (0.773–0.858)	0.839 (0.775–0.897)	0.732 (0.660–0.799)	0.885 (0.839–0.928)	0.889
	Labial inclination	0.900 (0.867–0.931)	0.842 (0.763–0.909)	0.833 (0.757–0.904)	0.930 (0.894–0.962)	0.961
	Weighted avg	0.816	0.821	0.816	0.903	0.945
AP position of upper incisors	Retrusion	0.918 (0.885–0.949)	0.786 (0.648–0.906)	0.647 (0.518–0.776)	0.968 (0.945–0.986)	0.949
	Normal	0.755 (0.707–0.801)	0.785 (0.725–0.845)	0.781 (0.718–0.838)	0.722 (0.645–0.794)	0.823
	Protrusion	0.837 (0.798–0.879)	0.689 (0.604–0.776)	0.763 (0.677–0.844)	0.866 (0.823–0.906)	0.905
	Weighted avg	0.755	0.758	0.755	0.800	0.905
AP position of lower incisors	Retrusion	0.925 (0.894–0.952)	0.917 (0.853–0.968)	0.838 (0.765–0.908)	0.965 (0.939–0.986)	0.976
	Normal	0.840 (0.801–0.876)	0.843 (0.778–0.902)	0.792 (0.722–0.852)	0.879 (0.832–0.927)	0.908
	Protrusion	0.915 (0.885–0.946)	0.758 (0.677–0.839)	0.935 (0.870–0.986)	0.909 (0.875–0.943)	0.973
	Weighted avg	0.840	0.847	0.840	0.913	0.957

single measurement indicator was used as the initial classification criterion, which was verified by 2 senior orthodontists. During the verification process, if any diagnoses were found to be inconsistent with clinical diagnostic experience, more measurements need to be analyzed. For the diagnosis of sagittal skeletal pattern, besides ANB, we also referred to Wits values, A-B plane to facial plane angle and APDI. On the one hand, the integrity of the data distribution is maintained, and on the other hand, classification errors due to reference plane variability are somewhat excluded. The classification labels contain the diagnostic experience of highly qualified orthodontists, attempting to simulate the diagnostic process of human experts through AI.

Current research on direct image classification of lateral cephalograms involves only 2–3 classifications [10–13]. Our research group has expanded the classification to eight categories [15]. However, previous studies used single-task learning to train models without considering the correlation between tasks. Single-task learning ignores empirical information from other tasks, which results in redundant training. In contrast, multitask learning is better at dealing with multiple related tasks. The bottom layer parameters are uniformly shared, while the top layer parameters of each model remain independent. This strategy reduces the probability of overfitting the original task and improves the model's generalizability [30]. Multitask learning has already been applied in dental AI-related research, including positional classification of mandibular third molars [31], classification of implant brands and treatment stages [32], and evaluation of implant stability [33]. In this study, multitask learning focused on the skeletal and dental classification of lateral cephalograms. There is a certain compensatory relationship between the craniomaxillofacial structures. A vertical problem can obscure or worsen a sagittal problem

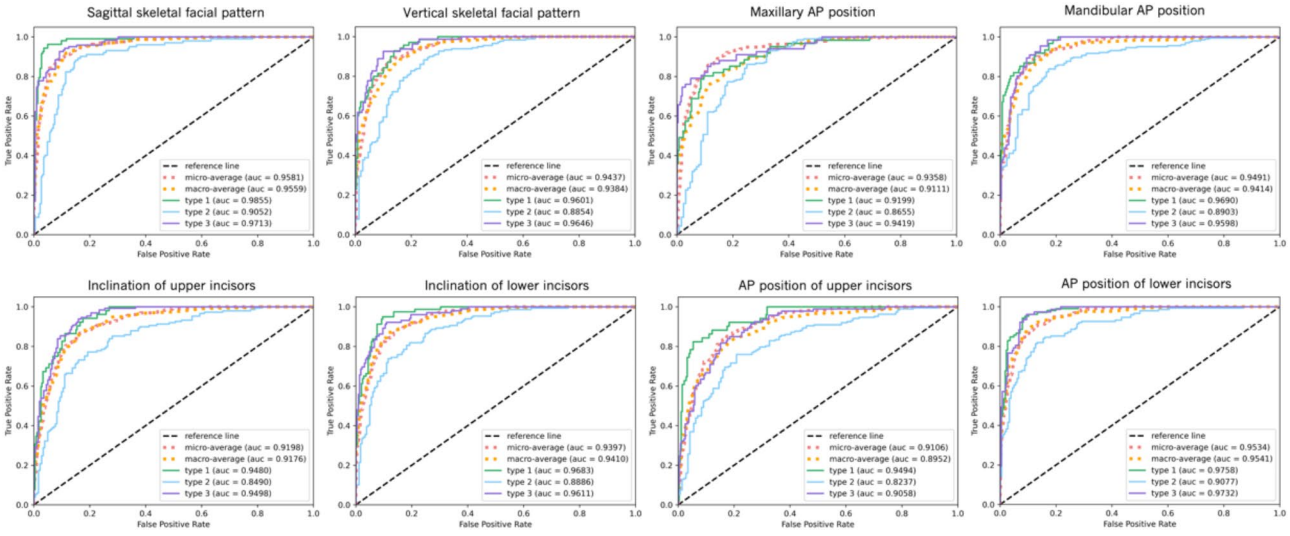

Fig. 4 ROC curves of the eight diagnostic classifications. The closer the ROC curve is to the upper left corner of the graph, the higher the accuracy of the test. The area under the curve (AUC), a measure of general performance, is shown in parentheses

Table 6 Cohen's kappa coefficients for consistency between the model and the standard classification label. Cohen's kappa coefficient < 0.00, poor; 0.00–0.20, slight; 0.21–0.40, fair; 0.41–0.60, moderate; 0.61–0.80, substantial; 0.81–1.00, almost perfect [26]

Classifications	Kappa
Sagittal skeletal facial pattern	0.79
Vertical skeletal facial pattern	0.69
Maxillary AP position	0.62
Mandibular AP position	0.69
Inclination of upper incisors	0.65
Inclination of lower incisors	0.72
AP position of upper incisors	0.58
AP position of lower incisors	0.75

[34]. Dentoalveolar compensation occurs according to skeletal discrepancies [35, 36]. There was a correlation between the sagittal skeletal facial pattern and both the AP position and inclination of incisors. In patients with Class II skeletal facial patterns, the upper incisors tend to be more retracted and lingually inclined, while the lower incisors tend to be more protruded and labially inclined. Therefore, the eight classification tasks in this study were consistent with the application conditions of multitask learning due to their inherent correlations. Its advantages include improving the classification performance, reducing the computational cost, and compensating for certain data defects.

Based on the overall classification results, the average accuracy for dental classification (0.800) was lower than that for skeletal classification (0.827), which was consistent with the single-task results [15]. It is hypothesized that the jaws may have a larger region of interest than the teeth for model training. The ROC curve is a curve drawn using a series of binary classification methods, with the true-positive rate as the vertical coordinate and the false-positive rate as the horizontal coordinate. The closer the ROC curve is to the upper left corner, the better the model classification performance is [37]. The classification performance for each task can be visualized through the ROC curves presented in Fig. 4. The AUC, an index used to quantify the ROC curves, offers a comprehensive evaluation of model performance. The AUC values for all classifications in this study were exceeding 0.90, indicating that the model has excellent discrimination capability for diagnostic classification. The confusion matrix of misclassifications (Fig. 3) shows that almost all misclassifications were concentrated among adjacent types. In the cases close to the classification boundary, the image features between classifications are not clearly distinguished, which may be one of the reasons for misclassifications, as supported by Yu et al. [13]. Additionally, data imbalance may lead to poor classification accuracy for minority classes. The classification performance for the inclination and AP position of upper incisors was lower than that of other classifications. When comparing the classification between upper and lower incisors, they were similar in terms of the regions of interest and the analysis patterns. We hypothesized that the low classification accuracy of upper incisors was associated with data imbalance, due to the more imbalanced distribution of data for upper incisors.

Sagittal and vertical skeletal facial patterns are commonly classified items. In the studies by Yu et al. [13] and Yim et al. [10], the AUCs for sagittal skeletal facial pattern were 0.938 and 0.9517, respectively, while those for vertical skeletal facial pattern were 0.937 and 0.958. In our study, the AUC for sagittal skeletal facial pattern (0.954) was higher than both, and the AUC for vertical

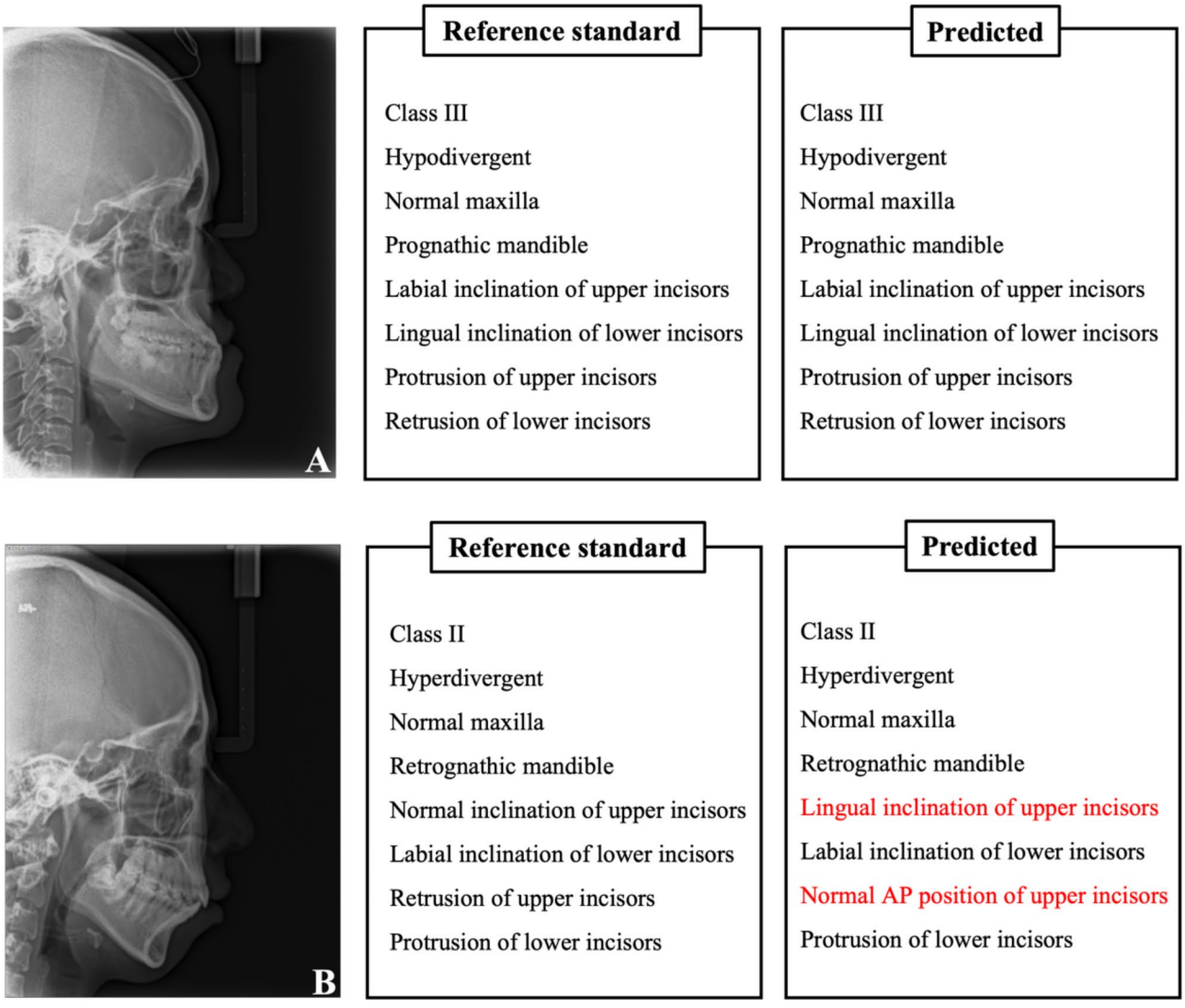

Fig. 5 Image examples of correct classifications(A) and misclassifications(B). Misclassifications were highlighted in red

skeletal facial pattern (0.943) fell between the two. While maintaining high classification performance for these two items, we involved more classifications. Compared with a single-task learning study [15] that also involved 8 classifications, the overall average AUC was essentially the same, approximately 0.94. The number of classifications with an accuracy above 0.8 improved to six, and the minimum classification accuracy improved from 0.727 (single-task) to 0.755. The number of classifications with an accuracy above 0.8 improved to six, and the minimum classification accuracy improved from 0.727 (single-task) to 0.755. For specific classifications, this model showed improvements in maxillary AP position, inclination of lower incisors, and AP position of upper incisors. The improvement in classification performance may be attributed to multitask learning's ability to explore correlations among multiple tasks, thereby making them complementary to the training samples. Multitask learning does not prioritize any specific task, which can reduce the possibility of model overfitting. Overall, for the larger and more unbalanced dataset used in this study, both the performance and the generalizability of the multitask model improved.

Multitask learning solves multiple tasks simultaneously through a single model, which reduces the training time and the total number of parameters [38], as demonstrated by the comparison in Table 4. Using a single-task learning model (DenseNet-121) for eight classification diagnoses, the overall number of parameters and training time were eight times greater than those for a single model. While using multitask learning, only one model was needed to obtain eight classifications simultaneously. By sharing a deep neural network, multitask learning

reduced repetitive calculations, minimized memory usage, and improved inference speed.

The data volume is a critical factor influencing the performance of medical AI models. Medical datasets are inherently characterized by class imbalance. The prevalence of different malocclusions varies significantly, with the number of normal cases significantly greater than that of abnormal cases. Due to the multiple classifications used in this study, it was difficult to balance the data for each classification. For single-task learning, addressing this imbalance typically involves data augmentation or adjusting class loss weights, which requires a lot of parameters tuning. Multitask learning provides another solution for handling imbalanced class data by sharing parameters to find internal connections between classification tasks, similar to implicit data augmentation.

Lateral cephalograms play a crucial role in the diagnosis of craniofacial deformities and the evaluation of their severity, thereby providing valuable information for the decision of appropriate treatment plans. Skeletal deformities (the first four classifications) require orthognathic surgery and growth modification therapy to better improve facial appearance. Incisors with labial inclination and protrusion (the last four classifications) are more indicative of decision to extraction. The automatic landmark detection and direct classification on lateral cephalograms are complementary to each other as part of the automatic analysis system. The quantitative analysis of the former reflects the severity of deformity, while the latter compensates for the limitations of the former and provides a more accurate clinical diagnosis, thereby better assisting in clinical decision-making. Misclassifications can be divided into false negatives and false positives, each with different clinical implications. False negative diagnoses may result in patients missing the optimal treatment time, increasing treatment difficulty. For instance, classifying a patient with skeletal deformities as normal and only using orthodontic treatment will not achieve the expected treatment outcome. Patients with false positive diagnoses may undergo unnecessary and more complex orthodontic treatment. Classifying incisors in normal position as protrusion may increase the possibility of extraction treatment, complicating the treatment and prolonging the treatment duration. In future applications, we will develop software that, through further preprocessing, adjusts image formats and resolutions to make them suitable for clinical use. Orthodontists can simply upload lateral cephalograms to the software to obtain classification results, which can then be integrated with cephalometric measurements for a comprehensive analysis of the radiographs. It should be emphasized that orthodontic treatment plans require comprehensive analysis based on various examinations. In clinical decision-making, it is important to understand the risk of misclassification and make a comprehensive judgment.

This study explored the direct image classification of lateral cephalograms using multitask learnings. It achieved reciprocal benefits in improving classification performance, reducing computational costs, and compensating for certain data deficiencies. AI can provide comprehensive, rapid, and accurate clinical references, but we must keep in mind that it is a tool to assist orthodontists and cannot replace the knowledge and clinical experience of orthodontists. Orthodontists should still rely on their own professional judgment and apply AI cautiously and rationally.

Limitations

It is important to recognize the limitations of this study, including the following:

1. From the perspective of the demographic diversity of the dataset, this study only included patients of a specific ethnicity in China, aged 14 and above. When applied our model to other groups, its performance may be affected due to differences in characteristics compared to the research data. To address this, we plan to collect more data from multiple centers, across multiple ethnicities, and cover a broader age range of patients. Based on this model, we aim to use transfer learning to train models that are suitable for different groups.
2. The model's performance still needs further enhancement, and there exist class imbalance in the dataset. In the future, we will endeavor to further expand the dataset while maintaining a balanced distribution. On the other hand, we will also attempt to overcome the limitations of imbalanced data from algorithms.
3. The evaluation of model performance in this study was only based on a single test set from a single center, which lacks more statistical measures to quantify performance uncertainty. For example, the standard deviation can be used to reflect the stability of model performance across different test sets. We will further conduct a comprehensive assessment of the robustness of model performance and investigate the impact of various factors on its performance.
4. Compared to the classification derived from automatic landmark detection, where doctors can correct errors during the process, this model has the limitation of insufficient interpretability. For interpretability of the image classification model, gradient-weighted class activation mapping (Grad-CAM) is used to visualize the regions of interest during the classification process [39]. The model consists of shared layers and task-specific layers,

and the task-specific layers are used to discriminate the categories. Grad-CAM focuses on the final convolutional layer, which in this model, is part of the shared layers; thus it can't distinguish the classification effect of subsequent task-specific layers. We are also looking for better ways to enhance the interpretability of the model.

Conclusion

In this study, an automatic diagnostic classification model for lateral cephalograms was established based on multitask learning. This model classified eight common clinical items, providing a comprehensive diagnostic reference for clinical application. The multitask learning model achieved better classification performance and reduced the computational costs, providing a new idea and reference for addressing such problems. Future research will explore further optimization of the model and its applicability to different patient populations to ensure wider application in clinical practice.

Abbreviations

AUC	Area under the curve
AI	Artificial intelligence
AP	Anteroposterior
Tiff	Tag image file format
MTAN	Muti-task Attention Netwok
HPS	Hard Parameter Sharing
DWA	Dynamic weight average
EW	Equal Weighting
GradNorm	Gradient Normalization
UW	Uncertainty Weights
SGD	Stochastic Gradient Descent
Adam	Adaptive Moment Estimation
TP	True-positive
TN	True-negative
FN	False-negative
FP	False-positive
ROC	Receiver operating characteristic
CIs	Confidence intervals
Grad-CAM	Gradient-weighted class activation mapping

Supplementary Information

The online version contains supplementary material available at https://doi.org/10.1186/s12903-025-05588-0.

Supplementary Material 1

Acknowledgements

Not applicable.

Author contributions

Q.C.: Conceptualization, Methodology, Resources, Data Curation, Formal analysis, Writing-Original Draft, Writing-Review & Editing. S.W.: Resources, Validation. F.W.: Resources, Writing-Review & Editing. B.G.: Resources, Writing - Review & Editing. Y.W.: Supervision, Software. F.Z.: Methodology, Software, Visualization. X.X.: Conceptualization, Supervision, Project Administration, Funding acquisition. Y.B.: Conceptualization, Funding acquisition, Project administration. All authors have given approval to the final version of the manuscript.

Funding

This study was supported by Beijing Natural Science Foundation (L222024, L232028), Beijing Hospitals Authority Clinical Medicine Development of special funding support (ZLRK202330), Innovation Research Team Project of Beijing Stomatological Hospital, Capital Medical University (CXTD202203) and Beijing Stomatological Hospital, Capital Medical University Young Scientist Program (YSP202101).

Data availability

The datasets generated during and/or analyzed during the current study are not publicly available due to privacy and ethical concerns.

Declarations

Ethics approval and consent to participate

This study was approved by the institutional review board of Beijing Stomatological Hospital, Capital Medical University. (No. CMUSH-IRB-KJ-PJ-2022-49).

Consent for publication

Not applicable.

Competing interests

The authors declare no competing interests.

Received: 18 August 2024 / Accepted: 3 February 2025
Published online: 15 February 2025

References

1. Gliddon MJ, Xia JJ, Gateno J, Wong HT, Lasky RE, Teichgraeber JF, Jia X, Liebschner MA, Lemoine JJ. The accuracy of cephalometric tracing superimposition. J Oral Maxillofac Surg. 2006;64(2):194–202.
2. Chang Q, Wang Z, Wang F, Dou J, Zhang Y, Bai Y. Automatic analysis of lateral cephalograms based on high-resolution net. Am J Orthod Dentofac Orthop. 2023;163(4):501–e508504.
3. Yao J, Zeng W, He T, Zhou S, Zhang Y, Guo J, Tang W. Automatic localization of cephalometric landmarks based on convolutional neural network. Am J Orthod Dentofac Orthop. 2022;161(3):e250–9.
4. Park JH, Hwang HW, Moon JH, Yu Y, Kim H, Her SB, Srinivasan G, Aljanabi MNA, Donatelli RE, Lee SJ. Automated identification of cephalometric landmarks: part 1-Comparisons between the latest deep-learning methods YOLOV3 and SSD. Angle Orthod. 2019;89(6):903–9.
5. Wang S, Li H, Li J, Zhang Y, Zou B. Automatic Analysis of Lateral Cephalograms Based on Multiresolution Decision Tree Regression Voting. *J Healthc Eng* 2018, 2018:1797502.
6. Arik SO, Ibragimov B, Xing L. Fully automated quantitative cephalometry using convolutional neural networks. J Med Imaging (Bellingham). 2017;4(1):014501.
7. Lee J, Bae SR, Noh HK. Commercial artificial intelligence lateral cephalometric analysis: part 1-the possibility of replacing manual landmarking with artificial intelligence service. J Clin Pediatr Dent. 2023;47(6):106–18.
8. Uysal T, Malkoc S. Submentovertex cephalometric norms in Turkish adults. Am J Orthod Dentofac Orthop. 2005;128(6):724–30.
9. Stahl de Castrillon F, Baccetti T, Franchi L, Grabowski R, Klink-Heckmann U, McNamara JA. Lateral cephalometric standards of germans with normal occlusion from 6 to 17 years of age. J Orofac Orthop. 2013;74(3):236–56.
10. Yim S, Kim S, Kim I, Park JW, Cho JH, Hong M, Kang KH, Kim M, Kim SJ, Kim YJ, et al. Accuracy of one-step automated orthodontic diagnosis model using a convolutional neural network and lateral cephalogram images with different qualities obtained from nationwide multi-hospitals. Korean J Orthod. 2022;52(1):3–19.
11. Li H, Xu Y, Lei Y, Wang Q, Gao X. Automatic classification for Sagittal Craniofacial patterns based on different convolutional neural networks. Diagnostics (Basel) 2022, 12(6).
12. Kim HJ, Kim KD, Kim DH. Deep convolutional neural network-based skeletal classification of cephalometric image compared with automated-tracing software. Sci Rep. 2022;12(1):11659.

13. Yu HJ, Cho SR, Kim MJ, Kim WH, Kim JW, Choi J. Automated skeletal classification with lateral cephalometry based on Artificial Intelligence. J Dent Res. 2020;99(3):249–56.
14. Nan L, Tang M, Liang B, Mo S, Kang N, Song S, Zhang X, Zeng X. Automated sagittal skeletal classification of children based on deep learning. Diagnostics (Basel) 2023, 13(10).
15. Chang S, Wang SF, Zuo FF, Wang F, Gong BW, Wang YJ, Xie XJ. [Automated diagnostic classification with lateral cephalograms based on deep learning network model]. Zhonghua Kou Qiang Yi Xue Za Zhi. 2023;58(6):547–53.
16. Caruana R. Learning Many Related Tasks at the Same Time With Backpropagation. In: *International Conference on Neural Information Processing Systems: 1994*; 1994.
17. Zhang Y, Yang Q. A Survey on Multi-task Learning. IEEE Trans Knowl Data Eng. 2022;34(12):5586–609.
18. Bishara SE, Peterson LC, Bishara EC. Changes in facial dimensions and relationships between the ages of 5 and 25 years. Am J Orthod. 1984;85(3):238–52.
19. Birgit T, Maurits P, Ulf A. Roentgen-cephalometric standards for a Swedish population. A longitudinal study between the ages of 5 and 31 years. Eur J Orthod 2005(4):370–89.
20. Zhao Z. Orthodontics, 7 edn. People's Medical Publishing House; 2020.
21. Xie S, Girshick R, Dollár P, Tu Z. Aggregated Residual Transformations for Deep Neural Networks. In: *2017 IEEE Conference on Computer Vision and Pattern Recognition (CVPR)*. 2017: 5987–5995.
22. Morid MA, Borjali A, Del Fiol G. A scoping review of transfer learning research on medical image analysis using ImageNet. Comput Biol Med. 2021;128:104115.
23. Lin B, Zhang Y. LibMTL: a Python Library for Multi-task Learning. In.; 2022: arXiv:2203.14338.
24. Liu S, Johns E, Davison AJ. End-to-end multi-task learning with attention. In.; 2018: arXiv:1803.10704.
25. Lin T-Y, Goyal P, Girshick R, He K, Dollár P. Focal loss for dense object detection. In.; 2017: arXiv:1708.02002.
26. Landis JR, Koch GG. The measurement of observer agreement for categorical data. Biometrics. 1977;33(1):159–74.
27. Ongkosuwito EM, Katsaros C, van 't Hof MA, Bodegom JC, Kuijpers-Jagtman AM. The reproducibility of cephalometric measurements: a comparison of analogue and digital methods. Eur J Orthod. 2002;24(6):655–65.
28. Plaza SP, Reimpell A, Silva J, Montoya D. Relationship between skeletal class II and Class III malocclusions with vertical skeletal pattern. Dent Press J Orthod. 2019;24(4):63–72.
29. Hussels W, Nanda RS. Analysis of factors affecting angle ANB. Am J Orthod. 1984;85(5):411–23.
30. Liu T, Tao D, Song M, Maybank SJ. Algorithm-dependent generalization bounds for Multi-task Learning. IEEE Trans Pattern Anal Mach Intell. 2017;39(2):227–41.
31. Sukegawa S, Matsuyama T, Tanaka F, Hara T, Yoshii K, Yamashita K, Nakano K, Takabatake K, Kawai H, Nagatsuka H, et al. Evaluation of multi-task learning in deep learning-based positioning classification of mandibular third molars. Sci Rep. 2022;12(1):684.
32. Sukegawa S, Yoshii K, Hara T, Matsuyama T, Yamashita K, Nakano K, Takabatake K, Kawai H, Nagatsuka H, Furuki Y. Multi-task Deep Learning Model for classification of Dental Implant Brand and Treatment Stage using Dental Panoramic Radiograph images. Biomolecules 2021, 11(6).
33. Huang Z, Zheng H, Huang J, Yang Y, Wu Y, Ge L, Wang L. The construction and evaluation of a Multi-task Convolutional Neural Network for a Cone-Beam computed-tomography-based Assessment of Implant Stability. Diagnostics (Basel) 2022, 12(11).
34. Ghafari JG, Macari AT. Component analysis of Predominantly Vertical Occlusal problems. Semin Orthod. 2013;19(4):227–38.
35. Kim SJ, Kim KH, Yu HS, Baik HS. Dentoalveolar compensation according to skeletal discrepancy and overjet in skeletal class III patients. Am J Orthod Dentofac Orthop. 2014;145(3):317–24.
36. Anwar N, Fida M. Compensation for vertical dysplasia and its clinical application. Eur J Orthod. 2009;31(5):516–22.
37. Park SH, Goo JM, Jo CH. Receiver operating characteristic (ROC) curve: practical review for radiologists. Korean J Radiol. 2004;5(1):11–8.
38. Zhao Y, Wang X, Che T, Bao G, Li S. Multi-task deep learning for medical image computing and analysis: a review. Comput Biol Med. 2023;153:106496.
39. Linardatos P, Papastefanopoulos V, Kotsiantis S. Explainable AI: a review of machine learning interpretability methods. Entropy (Basel) 2020, 23(1).

Publisher's note

Springer Nature remains neutral with regard to jurisdictional claims in published maps and institutional affiliations.