Journal of Dentistry 146 (2024) 105056

Contents lists available at ScienceDirect

Journal of Dentistry

journal homepage: www.elsevier.com/locate/jdent

Review article

Automatic cephalometric landmark identification with artificial intelligence: An umbrella review of systematic reviews

Alessandro Polizzi *, Rosalia Leonardi

Department of General Surgery and Medical-Surgical Specialties, Section of Orthodontics, University of Catania, Policlinico Universitario "Gaspare Rodolico - San Marco", Via Santa Sofia 78, 95123, Catania, Italy

ARTICLE INFO

Keywords:
Artificial intelligence
Deep learning
Automatic cephalometry
Cone-beam computed tomography
Systematic review

ABSTRACT

Objectives: The transition from manual to automatic cephalometric landmark identification has not yet reached a consensus for clinical application in orthodontic diagnosis. The present umbrella review aimed to assess artificial intelligence (AI) performance in automatic 2D and 3D cephalometric landmark identification.
Data: A combination of free text words and MeSH keywords pooled by boolean operators: Automa* AND cephalo* AND ("artificial intelligence" OR "machine learning" OR "deep learning" OR "learning").
Sources: A search strategy without a timeframe setting was conducted on PubMed, Scopus, Web of Science, Cochrane Library and LILACS.
Study selection: The study protocol followed the PRISMA guidelines and the PICO question was formulated according to the aim of the article. The database search led to the selection of 15 articles that were assessed for eligibility in full-text. Finally, 11 systematic reviews met the inclusion criteria and were analyzed according to the risk of bias in systematic reviews (ROBIS) tool.
Conclusions: AI was not able to identify the various cephalometric landmarks with the same accuracy. Since most of the included studies' conclusions were based on a wrong 2 mm cut-off difference between the AI automatic landmark location and that allocated by human operators, future research should focus on refining the most powerful architectures to improve the clinical relevance of AI-driven automatic cephalometric analysis.
Clinical significance: Despite a progressively improved performance, AI has exceeded the recommended magnitude of error for most cephalometric landmarks. Moreover, AI automatic landmarking on 3D CBCT appeared to be less accurate compared to that on 2D X-rays. To date, AI-driven cephalometric landmarking still requires the final supervision of an experienced orthodontist.

1. Introduction

Orthodontic and maxillofacial treatments are intricate processes, necessitating a meticulous understanding of craniofacial structures. Cephalometry, involving the radiographic assessment of the head and face, serves as an indispensable diagnostic tool in these domains. Moreover, the identification and measurement of cephalometric landmarks constitute a cornerstone in formulating treatment plans. The identification of cephalometric landmarks, points on the facial and cranial structures with defined anatomical significance, forms the foundation for cephalometric analysis [1].

Manually identifying and labeling significant anatomical points on cephalograms, or lateral skull radiographs, is the gold standard for this process [2]. Traditionally, this has been conducted on two-dimensional (2D) lateral X-rays even though with its limitations. In fact, 2D cephalograms project three-dimensional (3D) craniofacial features onto a 2D surface, resulting in the superimposition of bilateral structures and image distortion with some regions reduced and others enlarged [3]. Some researchers have suggested 3D cephalometric analysis as a solution to 2D cephalogram drawbacks. This analysis is predicated on 3D craniofacial images obtained by computed tomography (CT) or cone beam computed tomography (CBCT) imaging methods [4,5]. However, there is no validated landmarks list or universally accepted 3D analysis [6].

Traditionally, cephalometric analysis, even performed in 2D or 3D fashion, has been undertaken manually, relying on the expertise of

* Corresponding author: Department of General Surgery and Medical-Surgical Specialties, Section of Orthodontics, University of Catania, Policlinico Universitario "Gaspare Rodolico - San Marco", Via Santa Sofia 78, 95123, Catania, Italy.
E-mail address: alessandro.polizzi@phd.unict.it (A. Polizzi).

https://doi.org/10.1016/j.jdent.2024.105056
Received 11 March 2024; Received in revised form 25 April 2024; Accepted 7 May 2024
Available online 8 May 2024
0300-5712/© 2025 The Authors. Published by Elsevier Ltd. This is an open access article under the CC BY license (http://creativecommons.org/licenses/by/4.0/).

clinicians to identify and measure these landmarks on radiographic images. While effective, manual cephalometric analyses are inherently time-consuming and subject to inter-observer variability, which can influence the accuracy and reliability of the measurements [7–9].

In this context, artificial intelligence (AI) is a cutting-edge technology that enables digital systems to carry out activities that are typically completed by humans, learn from experience, and adapt to it [10]. Machine learning (ML) models are one of the most widely utilized AI applications in dentistry, since they may enhance their behavior when new data is supplied by learning from prior examples and using a combination of statistical and probabilistic tools [11]. ML algorithms utilize various methods to handle data. Unsupervised learning organizes and identifies patterns in input data, while supervised learning requires both inputs and corresponding outputs (labels) to train the model, adjusting internal parameters based on the error between estimations and labels to minimize future errors [12].

In recent years, the integration of AI technologies into medical imaging has ushered in transformative advancements [13,14], particularly in the field of cephalometry. Integrating AI into cephalometric analyses aims to address the challenges related to manual landmarking, allowing the possibility of standardized, rapid, and reproducible landmark identification. In AI-based cephalometry, whether semiautomatic or fully automatic, training refers to the process of teaching the AI model to accurately perform the desired tasks, such as landmark detection, measurement estimation, or anatomical structure segmentation, using annotated data [15,16]. In semiautomatic cephalometry, AI models assist human operators by providing tools for landmark detection, measurement estimation, or image segmentation. These models typically require some level of user interaction for validation or correction of results. Fully automatic cephalometry systems rely solely on AI models to perform all aspects of landmark detection, measurement estimation, and analysis without human intervention. These systems are trained on large datasets and are capable of processing images independently [17, 18].

Since automatic cephalometric analysis learns to average out landmarking mistakes, it is questioned if AI could eventually surpass manual landmarking in accuracy [19]. Numerous numerical techniques, such as knowledge-based, atlas-based, and learning-based algorithms, have been presented [20,21]. Knowledge-based algorithms rely on predefined rules or expert knowledge to analyze images and extract cephalometric measurements. These rules are typically encoded into the algorithm based on the understanding of anatomical structures and landmarks. Knowledge-based algorithms may use edge detection, pattern recognition, or geometric constraints in 2D images or voxel-based analysis or surface-based methods in 3D images to identify landmarks and perform measurements. Atlas-based algorithms rely on pre-segmented atlases or templates containing labeled anatomical structures. These atlases serve as reference models for aligning and matching structures in new images. In 2D cephalometry, atlas-based algorithms may involve registering a standard cephalometric template onto the patient's image using techniques like affine or non-rigid registration. Landmarks and measurements are then extracted based on the aligned template. In 3D cephalometry, atlas-based algorithms perform a similar process but in three dimensions. Learning-based algorithms, such as ML and deep learning (DL) models (a subset of ML), learn patterns and features directly from training data. These algorithms do not rely on predefined rules but instead extract relevant information from the images themselves. In 2D cephalometry, learning-based algorithms, such as convolutional neural networks (CNNs), are trained on annotated datasets to detect landmarks and estimate measurements directly from the images. The networks learn to identify patterns associated with landmarks and measurements. Similarly, in 3D cephalometry, learning-based algorithms utilize 3D CNNs or other DL architectures to analyze volumetric data and extract cephalometric measurements in the CBCT scans [22, 23].

The advent of DL, which leverages neural networks to analyze and interpret data, has particularly fueled the rapid progress in automatic cephalometric landmark identification [24]. CNNs and other DL architectures have demonstrated remarkable capabilities in image recognition tasks, making them well-suited for the intricate patterns and structures present in cephalometric radiographs [25–27]. These AI models have been supposed to recognize and locate specific anatomical landmarks with a level of accuracy and efficiency that might even surpass human performance. As a result, the application of AI in cephalometry holds the potential to speed up the workflow of orthodontics and maxillofacial surgery, streamlining the diagnostic process and fostering a more personalized approach to patient care.

The transition from manual to automatic cephalometric landmark identification, however, has not yet reached a consensus for clinical application in orthodontic diagnosis. The existing body of literature on this subject is extensive, encompassing a multitude of studies and systematic reviews that vary in methodologies, datasets, and evaluation metrics. To distill meaningful insights and facilitate a comprehensive understanding of the current state of the field, an umbrella review of systematic reviews has been undertaken to systematically assess and synthesize the findings of multiple systematic reviews, providing a panoramic perspective on the strengths, weaknesses, and trends of AI-driven cephalometric landmarks identification.

Therefore, the present umbrella review aims to assess the performance of AI models in automatic cephalometric landmark identification, offering a consolidated view of the evidence base and delineating the key challenges that persist and future trajectories.

2. Materials and methods

2.1. Research strategy

The present umbrella review followed the Preferred Reporting Items for Systematic Reviews and Meta-analyses (PRISMA) guidelines [28] and it has also been registered on the PROSPERO database (registration number: CRD42024497889). The present population, intervention, comparison, and outcomes (PICO) question was employed following the umbrella review's aim: "Are 3D CBCT and 2D lateral x-rays cephalometric landmarks (P) identified automatically by artificial intelligence (I) comparable to that derived from manual landmarking performed once or more times by one or more trained operators (C) in terms of accuracy (O)"? To detect potential systematic reviews and/or meta-analysis regarding AI automatic landmark identification for cephalometric analysis from 3D CBCT or 2D lateral cephalograms, in December 2023, a research strategy with no time restrictions has been performed combining MeSH terms and free text words pooled through boolean operators ('AND', 'OR') on the following databases: PubMed, Scopus, Web of Science, Cochrane Library (for Cochrane reviews) and LILACS. The following research strategy has been used to find suitable articles: Automa* AND cephalo* AND ("artificial intelligence" OR "machine learning" OR "deep learning" OR "learning").

2.2. Inclusion and exclusion criteria

The following inclusion criteria have been considered to select eligible studies: (1) study design (systematic reviews with or without meta-analysis), (2) language (English, available in full-text), (3) no timeline settings (to not exclude less recent systematic reviews), (4) subject of the study (AI fully-automatic landmark identification for cephalometric analysis from 3D CBCT or 2D lateral cephalograms). For the present umbrella review, AI has been considered as the development of computer systems capable of performing complex tasks that typically require human intelligence such as learning from data, reasoning, problem-solving, perception, understanding natural language, and interacting with the environment. On the other hand, routine computational tasks that follow predefined rules without learning or adaptation, such as basic arithmetic calculations, data sorting, executing

predetermined algorithms, or traditional software applications that perform specific, narrow tasks without exhibiting learning capabilities or autonomy have not been considered AI. AI-assisted methods where human interference had a significant impact on the performance of the algorithms have not been considered in the present umbrella review.

The studies should, to the greatest extent feasible, satisfy the primary standards set by the centre for Review and Dissemination [29] or the Cochrane Collaboration [30]. Prospective, retrospective, cross-sectional, opinion articles, conference reports, case reports, narrative, and scoping reviews have been excluded from the present study.

2.3. Selection of eligible systematic reviews and data extraction

The selection of eligible Systematic reviews has been performed with EndNote 20 desktop version [31]. Records identified through database searches underwent an initial screening for duplicates which were manually removed. Potentially relevant articles were selected based on information from titles and abstracts. The articles evaluated as eligible by two reviewers underwent a further review in the full-text versions for adherence to the inclusion criteria. The inclusion of a third reviewer not involved in the study was considered to resolve eventual disputes over the selection of articles. The data extracted from the systematic reviews included in the present umbrella review were: authors, year of publication, aim of the review, included studies, risk of bias assessment tool, AI algorithms included, mean discrepancy, and conclusions.

2.4. Risk of bias assessment

Risk of bias assessment was performed by two independent reviewers using the risk of bias in systematic reviews (ROBIS) tool [32], which evaluates systematic reviews and meta-analyses. The judgment of the risk of bias for selected studies depended on 4 domains: (1) study eligibility criteria, (2) identification and study selection, (3) data collection and study appraisal, and (4) synthesis and findings. These were considered together for allocating a “low,” “high,” or “unclear” risk of bias score. Each domain is characterized by five or six signaling questions which answers could be: yes (Y), probably yes (PY), probably no (PN), no (N), not informed (NI), or not applicable (NA). Before the bias assessment, all reviewers reached a consensus over the scoring system and cut-off points, as previously published [33]. The authors established the following grading scheme with relation to bias within each domain: "High risk" was indicated if several signaling questions were assessed as PN/N/NI, "unclear risk" was indicated if one question was judged as PN/N/NI, and "low risk" was indicated if all signaling questions were rated as Y/PY. Additionally, the overall risk of bias was assessed using the following criteria: (1) if 4 domains were deemed to be “low risk” or just 1 of the 4 ones as “unclear risk” the rating was “low”; (2) if 2 or more were deemed to be "unclear risk," the rating would be “moderate”; and if 1 or more were deemed to be "high risk," the rating would be “high”. Eventual disagreements between the review authors were solved by discussion or with the involvement of a third reviewer not involved in the study where necessary.

3. Results

3.1. Selection of included articles

The records identified through database searching were 588: 161 from Pubmed, 249 from Scopus, 168 from Web of Science, 4 from Cochrane Library, and 6 from Lilacs. 296 duplicates were removed and 292 records were screened for titles and abstracts. 277 papers were excluded and 15 articles were assessed for eligibility in full-text. 4 studies were not included for the following reasons: conference paper, no English full-text available and non-systematic design. Finally, 11 systematic reviews [23,34–43] were included for qualitative synthesis (Fig. 1).

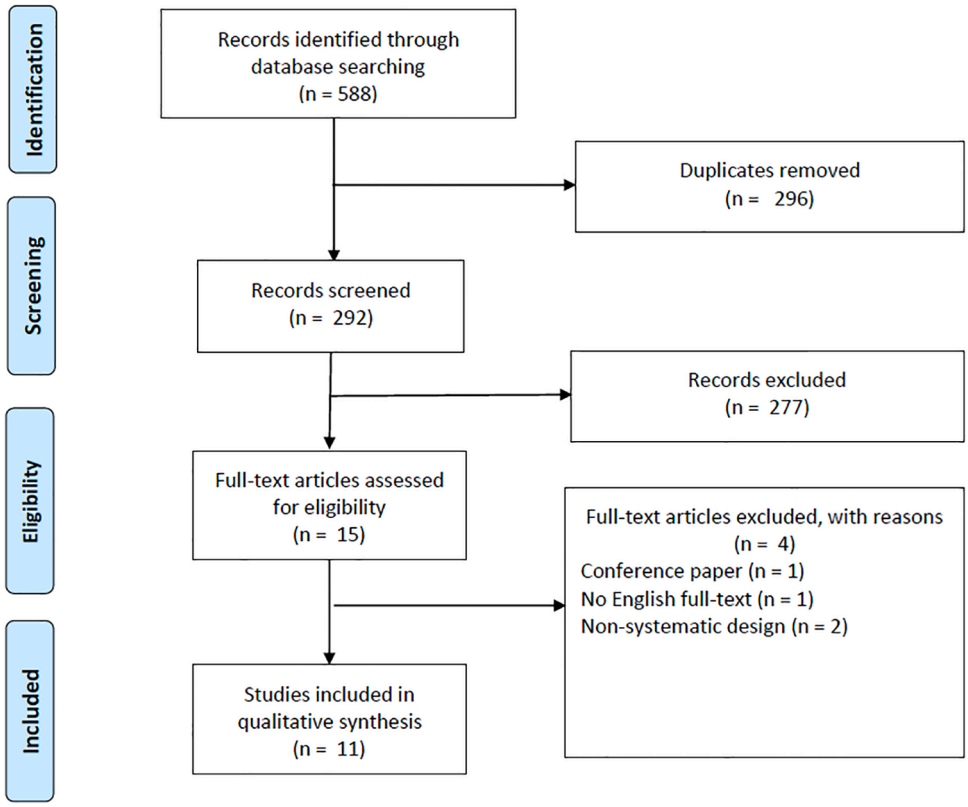

Fig. 1. PRISMA flow diagram of the present umbrella review.

3.2. Risk of bias results

The results of the risk of bias according to the ROBIS guidelines are presented in Table 1. 7 systematic reviews [34,35,37–39,41,42] presented an overall high risk of bias, 1 study [43] a moderate risk and the remaining 3 articles a low risk of bias [23,36,40]. Domain 1 (study eligibility criteria) was generally characterized by a low risk, and some studies presented moderate or high risk mainly because the inclusion criteria were too general and subject to interpretability. More specifically, 3 articles [34,37,39] did not provide in the inclusion criteria specific information on the use of AI in orthodontics, leading to the possibility of different interpretations. Rauniyar et al. [41] excluded articles regarding the analysis of "cephalometrically irrelevant landmarks" without providing specific selection criteria. In the article of Junaid et al. [38] not enough information is provided to understand the appropriateness of the eligibility criteria in relation to the study design. For domain 2 (identification and selection of studies) only 1 paper showed a low risk of bias [23], mainly due to lacking full presentation of the search strategy [34,35,38–41] and for not considering all the main electronic databases for bibliographic research including Scopus [35,42,44]. Moreover, Albalawi et al. [34] did not specify how many authors have been involved in the selection of articles and how eventual choice discrepancies have been managed. One systematic review [43] included articles published in a very strict timeline range (2020–2022). Even for domains 3 and 4, most studies presented a high risk of bias. This occurred because there was no mention of a strategy to minimize data collection errors [34,35,38,39,41,43], the quantitative results of accuracy in landmark identification were not reported [34,38] (in some cases only a subjective evaluation of the data in terms of AI efficiency, neutrality or non-efficiency was reported), and the repercussions of the risk of bias assessment results were not discussed [34,35,37–39,41]. Moreover, De Queiros et al. [36] did not specify whether more than one author performed the risk of bias assessment. A weighted bar chart for the risk of bias in the selected reviews is shown in Fig. 2.

3.3. Qualitative synthesis of the included studies

An accurate schematic description of the included articles is provided in Table 2. A more in-depth analysis of the inclusion of the articles in each systematic review is shown in Supplementary Table 1. The number of included articles related to automatic cephalometric analysis ranged from 6 to 40. The performance of the AI models was evaluated on 2D [40,41], 3D images [23,43], or both [34–38,42]. A review did not clarify what type of radiographs the accuracy of the AI was evaluated [39]. Most of the included systematic reviews [23,35–37,39,41–43] adopted the QUADAS-2 (Quality Assessment of Diagnostic Accuracy Studies 2) tool for the risk of bias assessment. Another systematic review [38] employed the CHSRI (Cochrane Handbook for Systematic Reviews of Interventions) tool, whereas the remaining 2 papers did not perform a risk of bias analysis [34,40]. Regarding the AI algorithms, the most used were CNNs and DL [23,34,35,37–39,42,43], followed by artificial neural networks (ANNs) and ML [23,34,37,38,40]. 2 papers did not specify the algorithms employed in the included studies [36,41]. The diagnostic accuracy of these models was expressed as the average discrepancy compared to the reference standard or as the mean success detection rate within 2 mm. When reported separately, the mean discrepancy of AI models ranged from 0.581 mm to 2.59 mm for 2D radiograph subgroups and from 1.88 mm to 7.61 mm for 3D radiograph subgroups. The mean success detection rate within 2 mm ranged from 43.75 % to 88.49 % for 2D images and from 64.16 % to 87.13 % for 3D images. 2 papers did not report quantitative results for accuracy [34,39], whereas some systematic reviews did not distinguish performance results in 2D and 3D radiographs [37,38,42]. Only 3 systematic reviews reported the mean accuracy for single cephalometric points [23,36,40] (Table 3). The older systematic review [40] generally reported less precise accuracy values than the more recent reviews. Furthermore, most of the points detected in 2D lateral cephalograms were subjected to lower accuracy errors compared to their counterparts evaluated in 3D CBCTs. De Queiroz et al. [36] reported a mean accuracy of < 2 mm for most evaluated points in

Table 1

Risk of bias of the included studies. (X) High risk, (−) Unclear risk (Moderate for overall risk of bias), (+) Low risk.

Review	Phase 2				Phase 3
	1. Study Eligibility Criteria	2. Identification and Selection of Studies	3. Data Collection and Study Appraisal	4. Synthesis and Findings	5. Risk of Bias in the Review
Alabawi F, et al. 2022 [34]	−	X	X	X	X
Cao L, et al. 2022 [35]	+	X	X	−	X
de Queiroz TBM, et al. 2023 [36]	+	+	−	+	+
Dot G, et al. 2020 [23]	+	−	+	+	+
Hung K, et al. 2020	−	−	+	X	X
Junaid N, et al. 2022 [38]	X	X	X	X	X
Khanagar SB, et al. 2021 [39]	X	−	X	X	X
Leonardi R, et al. 2008 [40]	+	−	+	+	+
Rauniyar S, et al. 2023 [41]	−	X	X	X	X
Schwendicke F, et al. 2021 [42]	+	X	+	+	X
Serafin M, et al. 2023 [43]	+	−	−	+	−

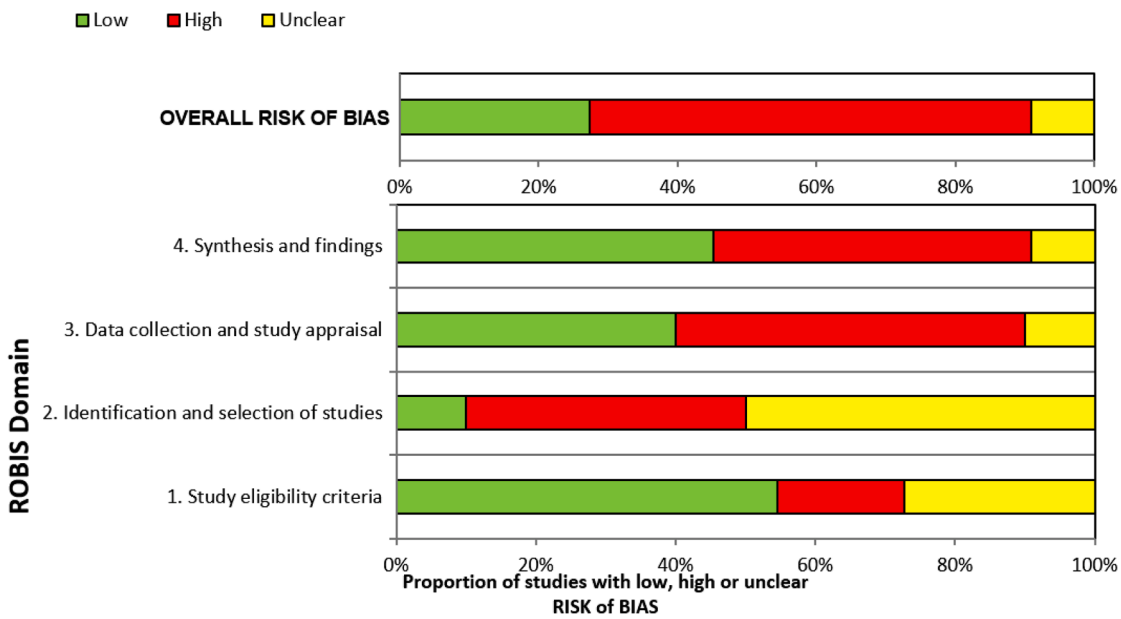

Fig. 2. Weighted bar chart of the risk of bias in the included studies.

2D lateral cephalograms (except gonion), whereas many more landmarks were subjected to lower accuracy in the 3D analysis [23,36].

4. Discussion

In recent years, the integration of AI technologies into medical imaging has ushered in transformative advancements, particularly in the field of dentistry and maxillofacial surgery. AI automatic cephalometry could play a pivotal role in orthodontics and other branches of dentistry by providing crucial anatomical landmarks for treatment planning. This paper aimed to present a comprehensive exploration of the current state of AI-driven automatic cephalometric landmark identification through the lens of an umbrella review of systematic reviews. Leveraging the collective insights from existing systematic reviews, the present study offers a panoramic view of the achievements, challenges, and future prospects of AI-driven cephalometric landmark identification. This research contributes to the ongoing discourse surrounding the application of AI in healthcare, with a specific focus on its potential to enhance accuracy, efficiency and speed in orthodontic diagnosis.

One of the central themes that emerges from the present study is the substantial progress achieved in the application of AI to cephalometry. A general improvement in landmark identification has been reported in the most recent systematic reviews compared to the oldest [23,36,40]. This could be explained by the rapid improvement and progressive refinement of AI algorithms over the years. The integration of computer vision and DL models, particularly CNNs, has demonstrated commendable accuracy in landmark identification [34]. The ability of these models to discern landmarks in cephalometric radiographs holds promise for streamlining diagnostic workflows, reducing the burden of manual landmark identification, and potentially mitigating inter-observer variability [2].

However, amidst these promising advancements, it becomes evident that the performance of AI models is intricately linked to several factors, each deserving careful consideration. The size and diversity of training datasets emerge as critical determinants of model generalizability [45]. Systematic reviews included in our umbrella analysis reveal a spectrum of dataset characteristics, emphasizing the need for standardized, large-scale datasets that encompass the diverse anatomical variations present in different patient populations. The development of such datasets is not only crucial for enhancing the accuracy of landmark identification but also for ensuring the robustness of AI models across varied clinical scenarios.

Moreover, architectural configurations of neural networks and training strategies play pivotal roles in determining the efficacy of AI-driven automatic landmark identification. Fine-tuning these parameters is an ongoing challenge, as evidenced by the variability in reported outcomes across the included systematic reviews. Future research endeavors should focus on refining neural network architectures and establishing standardized protocols for model training and validation [46]. This iterative refinement process is essential to elevate the reliability and generalizability of AI models, fostering their seamless integration into clinical practice.

Regarding 2D evaluations, hybrid machine learning approaches better identified sella landmark compared to the model-based approach. This may be caused by the sella's great degree of morphology variation [40]. Using the hybrid technique, the anterior nasal spine, gonion, and porion were also detected with greater accuracy. On the other hand, the knowledge-based, model-based, and hybrid approaches all had the almost equal capacity to identify nasion. Overall, the technique that employs hybrid methodologies produced superior outcomes with an accuracy that is near to that appropriate for practical application.

On the other hand, inaccuracies in the projection and identification of structures occur when cephalometric analysis evaluation employs 2D images of 3D structures [47]. CBCT has been suggested as a way to get over these restrictions by moving from 2D to 3D cephalometric analysis [48]. The capacity to analyze intricate face structures, avoid geometric distortion of the image, and accurately identify anatomical components are some benefits of employing 3D images for this endeavor [49]. So, granted that the identification of cephalometric points in 3D radiographs is clinically easier than in 2D x-rays, it has not yet been established if the same is true for AI. In this regard, the subgroup analysis performed by De Queiroz et al. [36] evaluated how the kind of image affected the AI landmarking accuracy. The findings demonstrated that the employment of 2D images was associated with reduced disparity between AI and human identifications for specific landmarks such as sella, supramentale, gnathion, lower incisal incision, and posterior nasal spine. Nonetheless, an overall analysis of the data revealed comparable levels of AI landmark identification accuracy in 2D and 3D images. The present data may be explained for a fewer number of samples of 3D radiographs, leading to less precise results for this subgroup compared to that of 2D x-rays. Therefore, due to the exploratory nature of these results, caution should be used when comparing 2D and 3D AI automatic

Table 2
Characteristics of the included studies. NS (not specified). For AI algorithms: ANN (artificial neural network), BCNN (Bayesian convolutional neural network), CNN (convolutional neural network), DL (deep learning), ML (machine learning), YOLOv3 (You-Only-Look-Once version 3). For the risk of bias assessment: CHSRI (Cochrane Handbook for Systematic Reviews of Interventions), QUADAS-2 (Quality Assessment of Diagnostic Accuracy Studies 2).

Study	Aim	Included studies	Risk of bias tool	AI algorithms	Mean discrepancy	Conclusions
Albalawi et al. 2022 [34]	To provide updates regarding the use of AI for diagnostic and treatment planning.	17 articles: 2D lateral cephalograms (13); CT scans (1); CBCT (3).	None.	CNNs (14), BCNNs (1), ANNs (1), ML (1).	NS. 16 articles were considered to report "effective" results for AI performance, and 1 article with "neutral" results.	Artificial Intelligence is reliable, faster, and capable of doing tasks automatically with an efficiency comparable to that of skilled medical professionals.
Cao et al. 2022 [35]	To evaluate the existing deep learning methods for 2D and 3D cephalometric landmark identification in terms of accuracy and reliability.	19 articles: 2D radiographs (15); 3D radiographs (4).	QUADAS-2: in the majority of the studies, a high risk of bias and applicability concerns were present for data selection and reference test.	DL	Pooled mean deviation: 0.054 mm. For 2D radiographs subgroups, the landmark identifications were mostly below the 2 mm threshold (mean deviation −0.581 mm / proportion of correct predictions 0.799); for 3D subgroup, the predictions were above the 2 mm threshold (mean 2.435 mm / proportion of correct predictions 0.870).	The accuracy of DL algorithms in detecting cephalometric landmarks was comparatively high. However, there was a significant chance of bias and the accuracy of identification varied throughout landmarks.
de Queiroz Tavares Borges Mesquita et al. 2023 [36]	To evaluate the level of agreement between AI and human registration for annotating cephalometric landmarks.	40 articles: cephalograms (27); CBCT (13).	QUADAS-2: for the patient selection and reference test domains, the majority of studies showed a significant risk of bias.	NS	Mean error range: 1.03 ± 1.29 - 2.59 ± 3.45 mm (2D) and 1.88 ± 1.10 - 7.61 ± 3.61 mm (3D). 2 mm threshold agreement rate range: 43.75–88.49 % (2D), 64.16–87.13 % (3D).	AI automatic landmarking performs well both on 2D and 3D radiographs.
Dot et al. 2020 [23]	To evaluate automated landmarking's precision and predictability for cephalometric analysis of 3D radiographs.	11 articles.	QUADAS-2: unclear risk of bias in 7 studies for patient selection and in 5 studies for reference standard.	2 Atlas-based, 2 Knowledge-based, 1 random forest, 3 DL, 1 Elastic Bunch Graph Matchingbased, 1 Active shape model (ASM) + Knowledge-based method	Mean discrepancy when reported (from 6 studies): 2.215 mm.	The mean errors of AI automatic landmarking ranged from 0.50 to 5 mm, depending on the method and the landmarks.
Hung et al. 2020 [37]	To assess the use of AI in dentistry and maxillofacial radiology.	19 articles: cephalograms (11), CBCT (8).	QUADAS-2: NS for studies regarding automatic cephalometric analysis.	1 Spatial spectroscopy, 15 ML, 1 ANN, 1 DL, 1 available from a software.	Mean discrepancy range when reported (from 18 studies): 1.42–4.79 mm.	Despite the promising results of AI automatic cephalometric landmarking, it will be necessary to confirm their reliability in clinical practice.
Junaid et al. 2022 [38]	To examine the body of research on the application of AI for cephalometric landmarks.	17 articles: 2D and 3D radiographs.	CHSRI: 12 studies with "low" risk and 12 with "moderate" risk.	1 YOLOv3, 8 CNN, 1 DL, 1 ML, 1 decision tree, 1 random forest.	Mean success detection rate range within 2 mm (from 3 studies): 65.7–79.4 %.	Convolutional neural networks (CNNs) perform exceptionally well, with precision and accuracy comparable to that of a skilled orthodontist, and can execute diagnostic tasks that are clinically acceptable.
Khanagar et al. 2021 [39]	To assess the efficacy of AI in orthodontics.	6 articles: design and kind of radiographs NS.	QUADAS-2: NS for studies regarding automatic cephalometric analysis.	CNNs	NS. All 6 articles were considered to report "effective" results for AI performance.	AI performed very well, matching the expert examiners' accuracy and precision.
Leonardi et al. 2008 [40]	To outline AI automatic reliability in landmarking cephalograms.	8 articles (design NS): 2D cephalograms.	None.	3 hybrid approaches, 2 image filtering plus Knowledge-based method, 3 Model-based methods.	Mean accuracy was reported for each landmark (20) separately. Except for a single research, the automatically identified landmarks' mean errors exceeded 2 mm, and the standard deviations, when disclosed, similarly displayed elevated levels.	The systems are not precise enough to be employed in clinical settings because of greater error compared to hand tracing.

(*continued on next page*)

Table 2 (*continued*)

Study	Aim	Included studies	Risk of bias tool	AI algorithms	Mean discrepancy	Conclusions
Rauniyar et al. 2023 [41]	To assess the accuracy of AI and ML for landmarks detected cephalometrically compared to manual tracing.	7 articles (design NS): 2D radiographs	QUADAS-2: low risk in most studies, however, 4 studies showed high risk regarding applicability concerns.	NS.	Mean success detection rate within 2 mm (from 5 studies): 78.6 %.	AI has demonstrated very promising and favorable outcomes when used for cephalometric landmark detection compared to manual tracing.
Schwendicke et al. 2021 [42]	To evaluate the DL's cephalometric landmark detection accuracy and supporting data on 2D and 3D images.	19 articles (design NS): 15 lateral cephalograms, 4 CBCT.	QUADAS-2: A generally high risk of bias was detected and the majority of the studies showed applicability concerns, mostly related to reference test and data selection.	CNNs.	Mean success detection rate within 2 mm: 0.799.	DL accuracy was comparatively good but a significant risk of bias was present. Therefore, it is necessary to demonstrate the generalizability and robustness of DL for landmark detection.
Serafin et al. 2023 [43]	To compare the precision of DL landmarking vs manual tracing for 3D cephalometric analysis.	15 articles (design NS): CT/CBCT	QUADAS-2: the existence of problems for many domains in each investigation raised the potential for bias.	CNNs.	Mean discrepancy: 2.44 mm.	Excellent accuracy was demonstrated by the newest deep learning systems for automated 3D cephalometric landmarking.

Table 3
Mean localization accuracy in millimeters of most reported cephalometric landmarks from 2D lateral cephalograms or 3D CBCT. [a] Overall summary mean (2D-3D).

Cephalometric landmark	De Queiroz et al. 2023 [36]		Dot et al. 2020 [23]	Leonardi et al. 2008 [40]
	2D (n° of studies)	3D (n° of studies)	3D (n° of studies)	2D (n° of studies)
Anterior nasal spine	1.62 (11)	1.54 (11)	2.61 (7)	2.53 (6)
Articulare	1.51 (5)[a]		–	
Condylar left	–	–	2.44 (3)	–
Condylar right	–	–	1.93 (3)	–
Frontozygomatic left	–	–	2.10 (3)	–
Frontozygomatic right	–	–	1.88 (3)	–
Gnathion	0.98 (11)	1.85 (11)	1.92 (5)	2.53 (4)
Gonion	2.12 (13)	2.60 (13)	–	3.13 (6)
Gonion left	–	–	2.29 (7)	–
Gonion right	–	–	2.63 (7)	–
Lateral zygomatic left	–	–	2.21 (3)	–
Lateral zygomatic right	–	–	2.00 (3)	–
Lower incisal incision	1.20 (10)	2.66 (10)	–	2.22 (6)
Lower incisor root	–	–	–	2.75 (4)
Lower lip	1.47 (6)[a]		-	0.34 (1)
Menton	0.95 (13)	1.43 (13)	1.54 (8)	2.2 (6)
Nasion	1.43 (17)	1.45 (17)	2.26 (9)	2.57 (7)
Orbitale	1.94 (14)	2.44 (14)	–	3.31 (6)
Orbitale left	–	–	1.86 (6)	–
Orbitale right	–	–	2.30 (6)	–
Pogonion	1.26 (11)	1.87 (11)	2.21 (9)	2.21 (7)
Point A	–	–	2.00 (5)	2.21 (7)
Point B	–	–	2.21 (6)	2.61 (5)
Porion	1.22 (13)	2.98 (13)	–	4.80 (5)
Posterior nasal spine	1.10 (11)	2.32 (11)	2.22 (5)	2.88 (4)
Sella	1.13 (11)	2.69 (11)	2.25 (5)	3.01 (6)
Soft tissue pogonion	2.07 (5)[a]		-	-
Subnasale	1.07 (5)[a]		-	-
Subspinale	1.66 (12)	2.32 (16)	–	–
Supramentale	1.63 (14)	2.38 (14)	–	–
Upper incisal incision	1.01 (13)	1.79 (13)	–	1.94 (8)
Upper incisor root	–	–	–	1.82 (6)
Upper lip	1.69 (6)[a]		-	0.54 (1)

cephalometric landmarking accuracy. In addition, the best accuracy in automatic 3D landmark identification results was achieved using DL, but specific landmarks (gonion left, gonion right, pogonion, and gnathion) presented increased standard deviations compared to others [23]. Furthermore, a limited number of 3D cephalometric points were used to evaluate the majority of the algorithms for 3D CBCT. As a result, the majority of these techniques, which are unable to do a thorough 3D cephalometric analysis, are rendered clinically unsuitable [23]. Therefore, the fact that 3D images were characterized by smaller samples might explain these findings.

Furthermore, the clinical relevance of AI-driven cephalometric analyses is a crucial factor that must be considered. It has been suggested that acceptable levels of accuracy for orthodontic clinical practice and research are 0.59 mm of total error for the x coordinate and 0.56 mm for the y coordinate [50]. This Euclidian distance was obtained from a meta-analysis [50] in which the error distribution for 15 lateral cephalometric landmarks was compared. Based on this distribution, the authors calculated the weighted standards for the magnitude of error of these 15 landmarks based on the amplitude of the samples size, obtaining a total error of 0.59 mm for the x-axis and 0.56 mm for the y-axis. Finally, the Euclidean distance was obtained by calculating the square root of the sum between the square of the total error on the x-axis and the square of that in the y-axis: $\sqrt{0.59^2 + 0.56^2} = 0.81$ mm. Thus, $\pm$ 0.81 mm should be the Euclidian magnitude of error. Regretfully, this latter value has been mentioned in very few of the published studies on AI automatic landmark location. Most investigations considered success to be achieved when there was a difference of $\leq$ 2 mm between the landmark location determined automatically by AI and that allocated by a human operator [51–53]. As a result, most studies' conclusions were based on a wrong cut-off according to the article of Trpkova et al. [50] and were more positive and not reliable in relationship to the degree of evidence in the translation of AI advancements into tangible clinical benefits. Therefore, the accuracy results reported for the majority of AI models should be reinterpreted in light of clinical reproducibility, as a deviation of 1–2 mm in the localization of different cephalometric points may have a significant impact mostly on linear measurements but also on angular values, and consequently on the orthodontic diagnosis and treatment. Establishing a robust link between technological advancements and clinical relevance is pivotal for garnering widespread acceptance and adoption of AI in cephalometric analyses. In addition, depending on the algorithm used, the error detected was different for each point. Therefore, using more AI models or reducing the cephalometric points to be identified could be considered since some points were detected with greater accuracy. So, to use AI landmarking, the

cephalometric analysis should be based only on those points. In this regard, the impact of the type of cephalometric analysis on the accuracy of AI landmarking is still unexplored. In the future, it could be useful to evaluate whether the selection of specific points and linear and angular measurements allows the AI to obtain clinically acceptable results in accuracy and a cephalometric analysis sufficiently complete for a correct orthodontic diagnosis.

Moreover, since manual landmarking has been considered as the reference standard to assess the accuracy of AI-driven fully automatic cephalometric analysis, the inaccuracies and challenges related to inter/intra-operator variability in manual landmark identification might potentially extend to the interpretations of data provided by AI. This might be seen as one of the major limitations when interpreting the available data on AI accuracy in recognizing cephalometric landmarks [19]. Therefore, to date, fully automatic landmarking via AI always requires the final supervision of the clinician.

Unfortunately, among the 11 systematic reviews included, only 4 reported the specific landmarks' accuracy results, as such data were not analyzed in the other studies.

In addition, the recommended Euclidean distance of 0.81 mm was indicated from a meta-analysis dating back to 1997 and was based only on 2D lateral cephalometric data (x-axis and y-axis) [50]. In light of the new data available in the literature, it is recommended to conduct updated studies evaluating the ideal cut-off errors on the x-axis, y-axis, and z-axis (for 3D CBCT cephalometric analysis), to weigh the accuracy results obtained with AI automatic landmarking. Furthermore, from a clinical-translational point of view, research should not focus on the single cephalometric point cut-off error only, as the orthodontic cephalometric diagnosis results from the evaluation of planes and angles that are obtained from different cephalometric points at the same time. Therefore, the error of the individual cephalometric point should also be contextualized on the planes and angles formed by them, which are the real outcomes to be evaluated during cephalometric analysis. Since some algorithms identify some points with more accuracy, while other models identify others better, it may be useful to study in the future how the combination of different algorithms can increase the accuracy of automatic cephalometric analysis to a clinically acceptable level.

In contemplating the future trajectories of AI in cephalometry, the present umbrella review highlights the need for collaborative efforts among bioinformatics researchers and orthodontic clinicians. In fact, to obtain an accurate AI-driven automatic cephalometric analysis it is not only necessary to significantly reduce the discrepancies between automatic and manual detection but also to ensure that the degree of discrepancy obtained does not have a clinical impact on the orthodontic diagnosis and the consequent therapeutic choices. Previous literature has based the AI effectiveness in automatic cephalometric landmarking on a wrong cut-off. Thus, the conclusions were misleading. The present umbrella review overcomes this pitfall. Therefore, this study aimed to assess if the results reported in the literature have a translational impact (not purely computational) which can be significant for daily clinical use. The key message of this paper is to give a new direction to future search, to outline the need to identify updated accuracy cut-off errors on the x-axis, y-axis and z-axis, and to establish whether fully automatic AI-driven landmarking might replace or at least integrate conventional manual landmarking, improving the effectiveness and efficiency of orthodontic diagnosis, without affecting its accuracy and reliability. In this sense, standardization of methodologies, sharing of benchmark datasets, and open collaboration will be essential for accelerating progress and fostering a collective understanding of the challenges.

5. Conclusions

While considering over the years some improvements of fully automatic AI-driven cephalometric landmarks detection in accuracy and efficiency, there are still challenges that warrant concerted attention. Depending on the AI algorithm used, the error detected was different for each point. Moreover, considering that most studies' conclusions were based on a wrong cut-off in accuracy, AI has exceeded the recommended magnitude of error for the majority of landmarks. 3D CBCT had the advantages of the absence of geometric distortions and superpositions of anatomical structures. However, the reduced number of samples of 3D radiographs and a limited number of evaluated 3D cephalometric points may explain the more imprecise results of AI automatic landmarking on 3D CBCT compared to that on 2D x-rays. Furthermore, another limitation was related to the possible influences of inter/intra-operator variability in manual landmarking (the reference standard) on the interpretations of data obtained with AI considered as the comparator. Based on these findings, to date, AI-driven automatic cephalometric landmarking still requires the final supervision of an experienced orthodontist. Future research should focus on refining the most powerful architectures and establishing standardized protocols and selected cephalometric landmarks to improve the clinical relevance of AI-driven automatic cephalometric analysis.

Availability of data and materials

The datasets used and/or analyzed during the current study are available from the corresponding author upon reasonable request.

Funding

This research received no specific grant from funding agencies in the public, commercial, or not-for-profit sectors.

CRediT authorship contribution statement

Alessandro Polizzi: Writing – review & editing, Writing – original draft, Methodology, Investigation, Formal analysis, Data curation. **Rosalia Leonardi:** Writing – review & editing, Validation, Supervision, Project administration, Investigation, Formal analysis, Conceptualization.

Declaration of competing interest

The authors declare that they have no known competing financial interests or personal relationships that could have appeared to influence the work reported in this paper.

Acknowledgments

We thank Prof. Antonino Lo Giudice (DDS, MSc Orthod., PhD) of the University of Catania for offering his help in resolving disagreements between the review authors in the selection of eligible articles and risk of bias assessment.

Supplementary materials

Supplementary material associated with this article can be found, in the online version, at doi:10.1016/j.jdent.2024.105056.

References

[1] W.B. Downs, The role of cephalometrics in orthodontic case analysis and diagnosis, Am. J. Orthod. 38 (3) (1952) 162–182.
[2] E. Celik, O. Polat-Ozsoy, T.U. Toygar Memikoglu, Comparison of cephalometric measurements with digital versus conventional cephalometric analysis, Eur. J. Orthod. 31 (3) (2009) 241–246.
[3] B.F. Gribel, M.N. Gribel, D.C. Frazão, J.A. McNamara Jr, F.R. Manzi, Accuracy and reliability of craniometric measurements on lateral cephalometry and 3D measurements on CBCT scans, Angle Orthod. 81 (1) (2011) 26–35.
[4] R. Olszewski, G. Cosnard, B. Macq, P. Mahy, H. Reychler, 3D CT-based cephalometric analysis: 3D cephalometric theoretical concept and software, Neuroradiology. 48 (2006) 853–862.
[5] S.-H. Lee, T.-J. Kil, K.-R. Park, B. Kim, J.-G. Kim, Z. Piao, P. Corre, Three-dimensional architectural and structural analysis—A transition in concept and

design from Delaire's cephalometric analysis, Int. J. Oral Maxillofac. Surg. 43 (9) (2014) 1154–1160.
[6] P. Pittayapat, N. Limchaichana-Bolstad, G. Willems, R. Jacobs, Three-dimensional cephalometric analysis in orthodontics: a systematic review, Orthod. Craniofac. Res. 17 (2) (2014) 69–91.
[7] R.K.W. Schulze, M.B. Gloede, G.M. Doll, Landmark identification on direct digital versus film-based cephalometric radiographs: a human skull study, Am. J. Orthod. Dentofac. Orthop. 122 (6) (2002) 635–642.
[8] M. Erkan, H.G. Gurel, M. Nur, B. Demirel, Reliability of four different computerized cephalometric analysis programs, Eur. J. Orthod. 34 (3) (2012) 318–321.
[9] A. Cohen, Uncertainty in cephalometrics, Br. J. Orthod. 11 (1) (1984) 44–48.
[10] F.a. Schwendicke, W. Samek, J. Krois, Artificial intelligence in dentistry: chances and challenges, J. Dent. Res. 99 (7) (2020) 769–774.
[11] S.N. Asiri, L.P. Tadlock, E. Schneiderman, P.H. Buschang, Applications of artificial intelligence and machine learning in orthodontics, APOS Trends Orthod. 10 (1) (2020) 17–24.
[12] J. Faber, C. Faber, P. Faber, Artificial intelligence in orthodontics, APOS Trends Orthod. 9 (4) (2019) 201–205.
[13] A. Polizzi, V. Quinzi, V. Ronsivalle, P. Venezia, S. Santonocito, A. Lo Giudice, R. Leonardi, G. Isola, Tooth automatic segmentation from CBCT images: a systematic review, Clin. Oral. Investig. (2023) 1–16.
[14] R. Leonardi, A.L. Giudice, M. Farronato, V. Ronsivalle, S. Allegrini, G. Musumeci, C. Spampinato, Fully automatic segmentation of sinonasal cavity and pharyngeal airway based on convolutional neural networks, Am. J. Orthod. Dentofac. Orthop. 159 (6) (2021) 824–835.e1.
[15] J. He, S.L. Baxter, J. Xu, J. Xu, X. Zhou, K. Zhang, The practical implementation of artificial intelligence technologies in medicine, Nat. Med. 25 (1) (2019) 30–36.
[16] F. Kunz, A. Stellzig-Eisenhauer, F. Zeman, J. Boldt, Artificial intelligence in orthodontics: evaluation of a fully automated cephalometric analysis using a customized convolutional neural network, J. Orofac. Orthoped./Fortschritte Kieferorthop. 81 (1) (2020).
[17] R. Zaheer, H.Z. Shafique, Z. Khalid, R. Shahid, A. Jan, T. Zahoor, R. Nawaz, M. ul Hassan, Comparison of semi and fully automated artificial intelligence driven softwares and manual system for cephalometric analysis, (2023).
[18] R. Mitra, A. Chauhan, S. Sardana, S.M. Londhe, B. Jayan, R. Maurya, Determination of the comparative accuracy of manual, semi-digital, and fully digital cephalometric tracing methods in orthodontics, J. Dent. Defense Sec. 14 (2) (2020) 52–58.
[19] C. Lindner, C.-W. Wang, C.-T. Huang, C.-H. Li, S.-W. Chang, T.F. Cootes, Fully automatic system for accurate localisation and analysis of cephalometric landmarks in lateral cephalograms, Sci. Rep. 6 (1) (2016) 33581.
[20] A. Gupta, O.P. Kharbanda, V. Sardana, R. Balachandran, H.K. Sardana, A knowledge-based algorithm for automatic detection of cephalometric landmarks on CBCT images, Int. J. Comput. Assist. Radiol. Surg. 10 (2015) 1737–1752.
[21] J. Zhang, M. Liu, L. Wang, S. Chen, P. Yuan, J. Li, S.G.-F. Shen, Z. Tang, K.-C. Chen, J.J. Xia, Joint craniomaxillofacial bone segmentation and landmark digitization by context-guided fully convolutional networks, in: Medical Image Computing and Computer-Assisted Intervention– MICCAI 2017: 20th International Conference, Springer, Quebec City, QC, Canada, 2017, pp. 720–728. September 11-13, 2017, Proceedings, Part II 20.
[22] M. Juneja, P. Garg, R. Kaur, P. Manocha, S. Batra, P. Singh, S. Singh, P. Jindal, A review on cephalometric landmark detection techniques, Biomed. Signal. Process. Control 66 (2021) 102486.
[23] G. Dot, F. Rafflenbeul, M. Arbotto, L. Gajny, P. Rouch, T. Schouman, Accuracy and reliability of automatic three-dimensional cephalometric landmarking, Int. J. Oral Maxillofac. Surg. 49 (10) (2020) 1367–1378.
[24] Y. LeCun, Y. Bengio, G. Hinton, Deep learning, Nature 521 (7553) (2015) 436–444.
[25] H. Kim, E. Shim, J. Park, Y.J. Kim, U. Lee, Y. Kim, Web-based fully automated cephalometric analysis by deep learning, Comput. Methods Programs Biomed. 194 (2020) 105513.
[26] H.W. Hwang, J.H. Moon, M.G. Kim, R.E. Donatelli, S.J. Lee, Evaluation of automated cephalometric analysis based on the latest deep learning method, Angle Orthod. 91 (3) (2021) 329–335.
[27] S. Nishimoto, Y. Sotsuka, K. Kawai, H. Ishise, M. Kakibuchi, Personal computer-based cephalometric landmark detection with deep learning, using cephalograms on the internet, J. Craniofac. Surg. 30 (1) (2019) 91–95.
[28] A. Liberati, D.G. Altman, J. Tetzlaff, C. Mulrow, P.C. Gøtzsche, J.P. Ioannidis, M. Clarke, P.J. Devereaux, J. Kleijnen, D. Moher, The PRISMA statement for reporting systematic reviews and meta-analyses of studies that evaluate health care interventions: explanation and elaboration, J. Clin. Epidemiol. 62 (10) (2009) e1–e34.
[29] Centre for Reviews and Dissemination (CRD) database - University of York. https://www.york.ac.uk/crd/.
[30] J.P. Higgins, Cochrane Handbook For Systematic Reviews of Interventions Version 5.0. 1. The Cochrane Collaboration, 2008. http://www.cochrane-handbook.org.
[31] T. Gotschall, EndNote 20 desktop version, J. Med. Library Assoc.: JMLA 109 (3) (2021) 520.
[32] P. Whiting, J. Savović, J.P. Higgins, D.M. Caldwell, B.C. Reeves, B. Shea, P. Davies, J. Kleijnen, R. Churchill, ROBIS: a new tool to assess risk of bias in systematic reviews was developed, J. Clin. Epidemiol. 69 (2016) 225–234.
[33] G. Melo, J. Duarte, P. Pauletto, A.L. Porporatti, J. Stuginski-Barbosa, E. Winocur, C. Flores-Mir, G. De Luca Canto, Bruxism: an umbrella review of systematic reviews, J. Oral Rehabil. 46 (7) (2019) 666–690.
[34] F. Albalawi, K.A. Alamoud, Trends and application of artificial intelligence technology in orthodontic diagnosis and treatment planning-a review, Appl. Sci.-Basel. 12 (22) (2022).
[35] L. Cao, H. He, F. Hua, Deep learning algorithms have high accuracy for automated landmark detection on 2D lateral cephalograms, J. Evid.-Based Dent. Pract. 22 (4) (2022).
[36] G. de Queiroz Tavares Borges Mesquita, W.A. Vieira, M.T.C. Vidigal, B.A. N. Travençolo, T.L. Beaini, R. Spin-Neto, L.R. Paranhos, R.B. de Brito Júnior, Artificial intelligence for detecting cephalometric landmarks: a systematic review and meta-analysis, J. Digit. Imaging 36 (3) (2023) 1158–1179.
[37] K. Hung, C. Montalvao, R. Tanaka, T. Kawai, M.M. Bornstein, The use and performance of artificial intelligence applications in dental and maxillofacial radiology: a systematic review, Dentomaxillofac. Radiol. 49 (1) (2020) 20190107.
[38] N. Junaid, N. Khan, N. Ahmed, M.S. Abbasi, G. Das, A. Maqsood, A.R. Ahmed, A. Marya, M.K. Alam, A. Heboyan, Development, application, and performance of artificial intelligence in cephalometric landmark identification and diagnosis: a systematic review, Healthcare 10 (12) (2022).
[39] S.B. Khanagar, A. Al-Ehaideb, S. Vishwanathaiah, C. Prabhadevi, S. Patil, S. Naik, H.A. Baeshen, S.S. Sarode, Scope and performance of artificial intelligence technology in orthodontic diagnosis, treatment planning, and clinical decision-making - A systematic review, J. Dent. Sci. 16 (1) (2021) 482–492.
[40] R. Leonardi, D. Giordano, F. Maiorana, C. Spampinato, Automatic cephalometric analysis: a systematic review, Angle Orthod. 78 (1) (2008) 145–151.
[41] S. Rauniyar, S. Jena, N. Sahoo, P. Mohanty, B.P. Dash, Artificial intelligence and machine learning for automated cephalometric landmark identification: a meta-analysis previewed by a systematic review, Cureus. 15 (6) (2023) e40934.
[42] F. Schwendicke, A. Chaurasia, L. Arsiwala, J.H. Lee, K. Elhennawy, P.G. Jost-Brinkmann, F. Demarco, J. Krois, Deep learning for cephalometric landmark detection: systematic review and meta-analysis, Clin. Oral Investig. 25 (7) (2021) 4299–4309.
[43] M. Serafin, B. Baldini, F. Cabitza, G. Carrafiello, G. Baselli, M. Del Fabbro, C. Sforza, A. Caprioglio, G.M. Tartaglia, Accuracy of automated 3D cephalometric landmarks by deep learning algorithms: systematic review and meta-analysis, Radiol. Medica 128 (5) (2023) 544–555.
[44] Reactive oxygen species in inflammation and tissue injury, Antioxid. Redox Signal. 20 (7) (2014) 1126–1167.
[45] V. Golenkov, N. Guliakina, V. Golovko, V. Krasnoproshin, Artificial intelligence standardization is a key challenge for the technologies of the future, in: International Conference on Open Semantic Technologies for Intelligent Systems, Springer, 2020, pp. 1–21.
[46] A. Hagiwara, S. Fujita, Y. Ohno, S. Aoki, Variability and standardization of quantitative imaging: monoparametric to multiparametric quantification, radiomics, and artificial intelligence, Invest. Radiol. 55 (9) (2020) 601.
[47] R. Nalcaci, F. Öztürk, O. Sökücü, A comparison of two-dimensional radiography and three-dimensional computed tomography in angular cephalometric measurements, Dentomaxillofac. Radiol. 39 (2) (2010) 100–106.
[48] W. Li, Y. Lu, K. Zheng, H. Liao, C. Lin, J. Luo, C.-T. Cheng, J. Xiao, L. Lu, C.-F. Kuo, Structured landmark detection via topology-adapting deep graph learning, in: Computer Vision–ECCV 2020: 16th European Conference, Springer, Glasgow, UK, 2020, pp. 266–283. August 23–28, 2020, Proceedings, Part IX 16.
[49] A. Sam, K. Currie, H. Oh, C. Flores-Mir, M. Lagravere-Vich, Reliability of different three-dimensional cephalometric landmarks in cone-beam computed tomography: a systematic review, Angle Orthod. 89 (2) (2019) 317–332.
[50] B. Trpkova, P. Major, N. Prasad, B. Nebbe, Cephalometric landmarks identification and reproducibility: a meta analysis, Am. J. Orthod. Dentofac. Orthoped. 112 (2) (1997) 165–170.
[51] B. Romaniuk, M. Desvignes, M. Revenu, M.-J. Deshayes, Contour tracking by minimal cost path approach: application to cephalometry, in: 2004 International Conference on Image Processing, 2004. ICIP'04, IEEE, 2004, pp. 937–940.
[52] W. Yue, D. Yin, C. Li, G. Wang, T. Xu, Automated 2-D cephalometric analysis on X-ray images by a model-based approach, IEEE Trans. Biomed. Eng. 53 (8) (2006) 1615–1623.
[53] I. El-Feghi, M.A. Sid-Ahmed, M. Ahmadi, Automatic localization of craniofacial landmarks for assisted cephalometry, Pattern. Recognit. 37 (3) (2004) 609–621.