Multimodal Medical Diagnosis from Chest Radiographs and Clinical Triage Data with Explainable Fusion Learning

Luv Gupta
Department of Computing
SRM Institute of Science and technology
Chennai, India
luv.g1902@gmail.com

Madhav bagrodia
Department of Computing
SRM Institute of Science and technology
Chennai, India
madhavbagrodia2@gmail.com

***Abstract*—Automated chest X-ray interpretation systems predominantly rely on imaging data alone, overlooking the rich clinical context available at the point of care. In this work, we present a multimodal deep learning framework that fuses chest radiograph features extracted by a DenseNet-121 backbone with structured clinical triage variables, including vital signs, pain scores, and acuity levels, for multi-label thoracic disease classification. We integrate data from five MIMIC ecosystem sources and the REFLACX dataset to construct a unified cohort of 675 annotated samples spanning five pathologies. We compare image-only, clinical-only, and multimodal model variants and evaluate two fusion strategies: element-wise summation and feature concatenation. The concatenation-based multimodal model achieves a test AUC of 0.826, outperforming the image-only baseline (AUC 0.816). We further incorporate Grad-CAM++ to generate visual explanations and find that concatenation fusion produces more clinically plausible saliency maps than summation fusion, which introduces spatial artifacts. The clinical-only model fails to learn meaningful representations (AUC 0.565), confirming that imaging remains the primary information source. Our results demonstrate modest but consistent gains from clinical data integration, while highlighting persistent overfitting challenges inherent to small-cohort multimodal medical imaging research.**

***Index Terms*—multimodal learning, chest X-ray classification, clinical data fusion, explainable AI, Grad-CAM++, deep learning, medical imaging, DenseNet**

I. Introduction

Chest radiography is the most frequently performed diagnostic imaging examination worldwide, yet its interpretation remains challenging due to the subtle and overlapping appearance of thoracic pathologies [1]. Deep learning systems have achieved radiologist-level performance on several chest X-ray classification benchmarks [2], [3], but these models typically operate on imaging data in isolation, ignoring the clinical context that radiologists routinely consider when formulating diagnoses.

In emergency department (ED) settings, clinicians have access to vital signs, triage assessments, pain scores, and patient demographics before a radiograph is even acquired. This contextual information can disambiguate equivocal imaging findings and improve diagnostic confidence [4]. However, integrating heterogeneous data modalities—continuous-valued images and structured tabular records—into a unified predictive framework poses significant architectural and optimization challenges [5], [6].

A further requirement for clinical adoption of automated diagnostic systems is explainability. Regulatory frameworks and clinical trust demand that model predictions be accompanied by interpretable rationales [7]. Gradient-weighted class activation mapping (Grad-CAM) [8] and its generalization Grad-CAM++ [9] produce spatial heatmaps highlighting image regions contributing to predictions, but their behavior in multimodal architectures—where non-image features also influence the output—has received limited investigation.

In this paper, we address these gaps with the following contributions:

- We construct a multimodal dataset by integrating five MIMIC ecosystem data sources with the REFLACX radiologist annotation dataset, linking chest radiographs with ED triage variables through temporal alignment of clinical records.
- We design and evaluate a multimodal architecture combining a DenseNet-121 image branch with a clinical feature branch, comparing element-wise summation and concatenation fusion strategies.
- We systematically compare image-only, clinical-only, and multimodal model variants, reporting AUC-based evaluation on five thoracic pathologies.
- We analyze Grad-CAM++ explanations under both fusion strategies and demonstrate that concatenation fusion produces more clinically plausible saliency maps than summation fusion.
- We provide an honest assessment of the limitations imposed by small dataset size, including persistent overfitting and the challenges of training multimodal models with limited samples.

II. Related Work

A. Chest X-Ray Classification with Deep Learning

The release of large-scale chest X-ray datasets such as ChestX-ray14 [1], CheXpert [3], and MIMIC-CXR [10] has

catalyzed the development of deep learning systems for automated thoracic disease detection. CheXNet [2] demonstrated that a DenseNet-121 [11] trained on ChestX-ray14 could exceed the average radiologist performance on pneumonia detection. CheXNeXt [12] extended this to multi-label classification across multiple pathologies. These systems established DenseNet-121 as a standard backbone for chest X-ray analysis, a choice we adopt in our work.

B. Multimodal Medical AI

Multimodal learning in medicine has gained increasing attention as a strategy to combine complementary information sources [4], [5]. Kline et al. [6] provide a comprehensive review of multimodal machine learning in precision health, identifying fusion strategy selection as a key design decision. Common approaches include early fusion (concatenation of raw features), late fusion (combining predictions), and intermediate fusion at learned representation levels. Our work adopts intermediate fusion, combining learned features from separate image and clinical branches before a shared decision layer.

C. Explainable AI for Radiology

Grad-CAM [8] produces class-discriminative localization maps by computing the gradient of the target class score with respect to feature maps of a convolutional layer. Grad-CAM++ [9] improves upon this with a weighted combination of positive partial derivatives, yielding better localization for multiple instances of the same class. While these methods are well-established for single-modality image classifiers, their behavior in multimodal architectures—where the gradient signal is shared between image and non-image pathways—remains underexplored.

D. AUC-Oriented Optimization

Standard cross-entropy losses can be suboptimal for imbalanced medical datasets where area under the ROC curve (AUC) is the primary evaluation metric. Yuan et al. [13] propose a compositional surrogate loss for direct AUC maximization (DeepAUC), demonstrating improved generalization on medical image classification tasks. We explore DeepAUC as an alternative training objective in our experiments.

III. Materials and Data Sources

Our multimodal dataset is constructed by integrating six data sources from the MIMIC clinical data ecosystem. Table I summarizes each source and its role.

TABLE I
Data Sources and Their Roles in the Multimodal Pipeline

Source	Role
MIMIC-IV [14]	Patient demographics: age (derived from anchor year), gender
MIMIC-IV ED	Emergency department triage data: temperature, heart rate, respiratory rate, O2 saturation, systolic/diastolic blood pressure, pain score, acuity level
MIMIC-CXR [10]	Chest radiograph metadata, study-level identifiers, and free-text radiology reports
MIMIC-CXR-JPG [15]	JPEG-formatted chest radiographs with CheXpert-derived multi-label annotations
Eye Gaze Data	Radiologist eye-tracking timestamps used to determine `stay_id` via temporal alignment with ED records
REFLACX [16]	Multiple radiologist annotations per image with eye-tracking data and bounding ellipses for abnormality localization

A. Data Integration Pipeline

Linking these sources requires resolving multiple identifier types: `subject_id` (patient), `stay_id` (ED visit), `study_id` (diagnostic study), `dicom_id` (individual image), and `reflacx_id` (radiologist annotation). A key challenge is determining the ED stay associated with each radiograph, as MIMIC-CXR does not directly encode `stay_id`. Following the methodology of the Eye Gaze dataset, we identify `stay_id` by checking whether the radiograph acquisition timestamp falls within the ED stay interval (`stay_intime` $<$ `xray_timestamp` $<$ `stay_outtime`).

A further complication arises from version incompatibilities between MIMIC-IV updates (which changed the `transfer_id` scheme) and MIMIC-CXR, resulting in approximately 30% of records being unmatchable due to `subject_id` misalignment.

B. Label Definition

From the REFLACX annotations, we select the five most prevalent pathologies as target labels:

1) Enlarged cardiac silhouette (cardiomegaly)
2) Atelectasis
3) Pleural abnormality
4) Consolidation
5) Pulmonary edema

REFLACX annotations contain label redundancies (e.g., "high lung volume" and "emphysema" referring to overlapping conditions), which we resolve through automated mapping to canonical labels. All labels are binarized to indicate presence or absence of each pathology, yielding a multi-label classification problem.

C. Final Dataset Characteristics

The integrated dataset comprises 675 annotated samples. Each sample consists of a chest radiograph, nine numerical clinical features (age, temperature, heart rate, respiratory rate, O2 saturation, systolic blood pressure, diastolic blood pressure, pain score, acuity level), one categorical feature (gender), and five binary disease labels. The dataset is split into training (80%), validation (10%), and test (10%) partitions using a fixed random seed.

IV. Methodology

A. Overall Architecture

Our multimodal framework consists of three components: (1) an image feature extraction branch, (2) a clinical data encoding branch, and (3) a fusion and decision module. Fig. 1 illustrates the overall architecture.

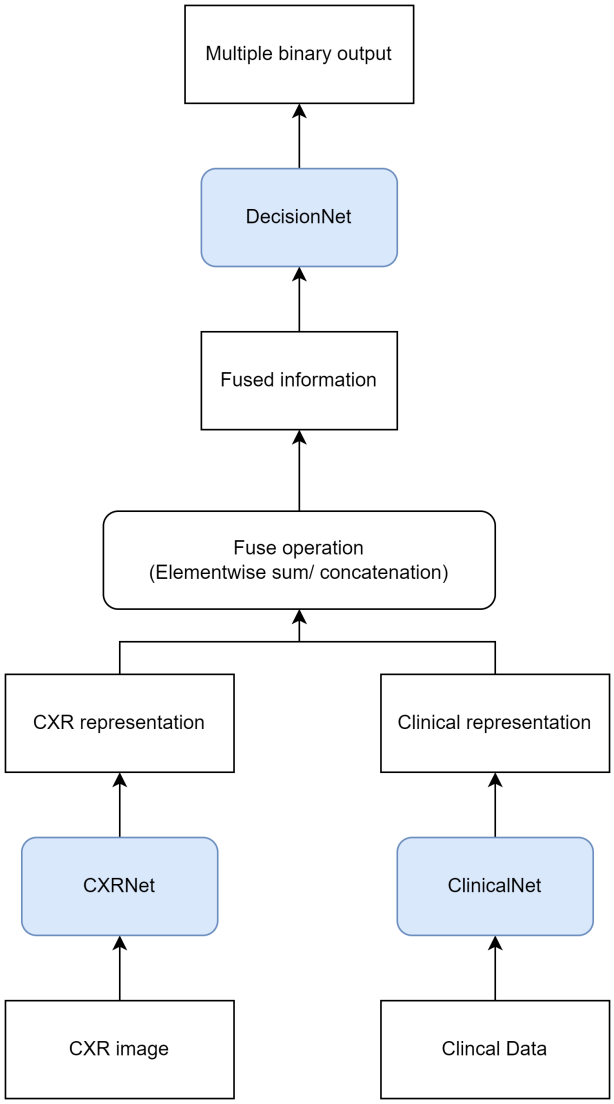

Fig. 1. Multimodal architecture. The image branch (DenseNet-121) and clinical branch (MLP with embedding layer) produce fixed-dimensional feature vectors that are fused via concatenation before the decision layer.

B. Image Branch

The image branch employs a DenseNet-121 [11] pretrained on ImageNet [17]. Input radiographs are resized to 128×128 pixels, randomly cropped to 112×112 during training (center-cropped during evaluation), randomly flipped horizontally, and normalized using ImageNet channel statistics. The final classification layer of DenseNet-121 is replaced with a linear projection to a 64-dimensional feature vector.

C. Clinical Branch

The clinical branch processes the ten triage features through a multi-layer perceptron (MLP). The categorical gender variable is first mapped to a 64-dimensional embedding via a learned embedding layer. This embedding is concatenated with the nine numerical features and passed through a sequence of fully connected layers:

$$\mathbf{h}_1 = \text{LeakyReLU}(\text{LN}(\text{Dropout}(\mathbf{W}_1[\mathbf{e}_g; \mathbf{x}_n] + \mathbf{b}_1))) \quad (1)$$

$$\mathbf{c} = \mathbf{W}_3(\mathbf{W}_2\mathbf{h}_1 + \mathbf{b}_2) + \mathbf{b}_3 \quad (2)$$

where $\mathbf{e}_g$ is the gender embedding, $\mathbf{x}_n$ is the numerical feature vector, LN denotes layer normalization, and $\mathbf{c} \in \mathbb{R}^{64}$ is the output clinical feature vector. Dropout with rate 0.2 is applied for regularization.

D. Fusion Strategies

We compare two intermediate fusion strategies:

Element-wise summation: The image and clinical feature vectors are added element-wise, requiring both branches to produce vectors of identical dimension d:

$$\mathbf{f}_{\text{sum}} = \mathbf{v} + \mathbf{c}, \quad \mathbf{f}_{\text{sum}} \in \mathbb{R}^d \quad (3)$$

Concatenation: The feature vectors are concatenated along the feature dimension:

$$\mathbf{f}_{\text{cat}} = [\mathbf{v}; \mathbf{c}], \quad \mathbf{f}_{\text{cat}} \in \mathbb{R}^{2d} \quad (4)$$

The fused representation is passed to a decision network consisting of a linear layer mapping to five output logits (one per pathology), followed by sigmoid activation during inference.

E. Loss Functions and Training

We employ multi-label soft margin loss (equivalent to binary cross-entropy with logits) as the primary training objective. To address class imbalance, we compute per-class weights as the ratio of negative to total samples for positive predictions and vice versa.

Training uses the Adam optimizer [18] with an initial learning rate of 8×10^{-4} and weight decay of 10^{-5}. A ReduceLROnPlateau scheduler with patience of 2 epochs, threshold of 10^{-3}, and reduction factor of 0.5 adjusts the learning rate based on validation loss. Early stopping with patience of 5 epochs prevents excessive overfitting.

In additional experiments, we explore the DeepAUC loss [13], which directly optimizes the AUC metric through a compositional min-max formulation, as an alternative to standard cross-entropy.

F. Explainability with Grad-CAM++

We employ Grad-CAM++ [9] to generate visual explanations for model predictions. For multimodal models, a wrapper module holds the clinical input constant while varying the image input, enabling gradient computation through the image branch alone. The target layer for Grad-CAM++ is the final convolutional block of the DenseNet-121 backbone. The resulting heatmap is overlaid on the original radiograph to highlight regions contributing to each disease prediction.

V. Experimental Setup

A. Model Variants

We evaluate the following model configurations:

- **Image-Only:** DenseNet-121 with the classification head directly producing five disease logits, trained without clinical features.
- **Multimodal (Concatenation):** Full architecture with DenseNet-121 image branch, clinical MLP branch, and concatenation fusion.
- **Multimodal (Summation):** Same architecture with element-wise summation fusion.
- **Clinical-Only:** Clinical MLP branch alone, without image input.

B. Training Configuration

All REFLACX-based models use a batch size of 16, input resolution of 256×256 (cropped to 112×112), model dimension of 32, embedding dimension of 64, and dropout rate of 0.2. The image branch is initialized from ImageNet-pretrained weights. We train for up to 300 epochs with early stopping.

An initial training attempt with a learning rate of 0.02, adopted from the CheXNeXt [12] schedule designed for a dataset 332 times larger, resulted in the model collapsing to majority-class predictions. Reducing the learning rate to 8×10^{-4} resolved this instability.

C. Evaluation Metrics

We report the area under the receiver operating characteristic curve (AUC) as the primary metric, consistent with standard practice in chest X-ray classification [3]. We additionally report accuracy and per-class confusion matrices on the test partition.

VI. Results

A. Model Variant Comparison

Table II summarizes the performance of all model variants. The multimodal concatenation model achieves the highest test AUC (0.826), representing an improvement of approximately one percentage point over the image-only baseline (0.816). The clinical-only model fails to learn meaningful representations, achieving a test AUC of only 0.627 with near-random confusion matrices—predicting all samples as positive for some classes and all as negative for others.

TABLE II
Performance Comparison of Model Variants

Model	Best Val AUC	Test AUC	Test ACC
Image-Only (300 ep.)	0.816	0.816	79.0%
Multimodal Concat (300 ep.)	0.818	0.826	80.0%
Clinical-Only (300 ep.)	0.565	0.627	56.6%
DeepAUC Image-Only (500 ep.)	0.760	0.821	76.7%
DeepAUC Multimodal (500 ep.)	0.771	0.811	76.1%

B. Overfitting Analysis

A persistent train-validation gap is observed across all variants. For the multimodal concatenation model at 300 epochs, training AUC reaches 0.979 while validation AUC plateaus at 0.827, and training accuracy reaches 90.6% compared to 75.9% on validation. This gap reflects the fundamental constraint of training a model with approximately 8 million parameters on only 540 training samples (80% of 675).

Early stopping identifies the best validation checkpoint at epoch 10 (validation AUC 0.818), indicating that extended training primarily leads to overfitting rather than generalization improvement. The test AUC at epoch 300 (0.826) marginally exceeds the best validation AUC, suggesting that the test partition may be slightly easier than the validation partition due to the small sample sizes involved.

C. Learning Rate Sensitivity

The image-only model trained with a learning rate of 0.02 (following the CheXNeXt schedule) achieves a best validation AUC of 0.770, compared to 0.816 with a learning rate of 8×10^{-4}. The aggressive schedule, designed for a training set of over 200,000 samples, causes optimization instability on our 540-sample training set.

D. DeepAUC Training

Replacing the standard loss with DeepAUC does not yield consistent improvements on our small dataset. The DeepAUC image-only model achieves a test AUC of 0.821, comparable to the standard-loss variant (0.816). Unexpectedly, the DeepAUC multimodal model (test AUC 0.811) slightly underperforms the DeepAUC image-only model, suggesting that direct AUC optimization may interact unfavorably with multimodal fusion when data is scarce.

E. Fusion Strategy Comparison

Both concatenation and summation fusion enable the multimodal model to outperform the image-only baseline. However, concatenation fusion produces superior results in two respects:

Quantitative performance: The concatenation model achieves a higher test AUC (0.826) than the summation variant.

Grad-CAM++ quality: Fig. 2 illustrates a representative comparison. The summation fusion model produces saliency

maps with rectangular artifacts in corner regions of the radiograph, an effect we attribute to the clinical feature signal being distributed across spatial dimensions during backpropagation through the element-wise addition. The concatenation model produces clean saliency maps that highlight anatomically relevant regions, as the image and clinical gradients flow through separate channels before the decision layer.

Fig. 2. Grad-CAM++ visualization comparison. Concatenation fusion produces clinically plausible saliency maps highlighting relevant anatomical regions, while summation fusion introduces corner artifacts due to clinical feature gradients leaking into spatial dimensions.

F. Per-Disease Analysis

Table III presents the test set confusion matrix summary for the multimodal concatenation model. Enlarged cardiac silhouette and pleural abnormality show the strongest discrimination, while pulmonary edema and consolidation exhibit higher false positive rates.

TABLE III
TEST SET CONFUSION MATRIX FOR MULTIMODAL CONCATENATION MODEL (300 EPOCHS)

Pathology	TN	FP	FN	TP
Enlarged cardiac sil.	69	17	4	11
Atelectasis	73	16	4	8
Pleural abnormality	75	12	4	10
Consolidation	73	12	7	9
Pulmonary edema	68	19	6	8

VII. DISCUSSION

A. Value of Clinical Context

The multimodal model's improvement over the image-only baseline, while modest (AUC 0.826 vs. 0.816), is consistent with the hypothesis that triage data provides complementary diagnostic signal. Vital signs such as heart rate, respiratory rate, and oxygen saturation correlate with cardiopulmonary pathologies and may help disambiguate equivocal radiographic findings. The failure of the clinical-only model (AUC 0.627) confirms that triage variables alone are insufficient for disease classification and that imaging remains the dominant modality.

B. Fusion Strategy Implications

The superiority of concatenation over summation fusion has both quantitative and qualitative dimensions. Quantitatively, concatenation preserves the full representational capacity of both branches by doubling the input dimension to the decision layer. Summation, by contrast, forces the image and clinical branches to share a common feature space, which may constrain representation learning.

Qualitatively, the Grad-CAM++ artifacts observed with summation fusion represent a practical concern for clinical deployment. Corner artifacts in saliency maps could erode clinician trust and obscure genuinely relevant image regions. Concatenation fusion maintains cleaner gradient separation between modalities, producing explanations that align with expected anatomy.

C. Challenges of Small-Sample Multimodal Learning

The persistent overfitting observed across all experiments highlights a fundamental tension in multimodal medical AI: integrating additional data modalities increases model capacity and the number of learnable parameters, but small clinical datasets provide insufficient samples to regularize this expanded capacity. Our dataset of 675 samples is orders of magnitude smaller than the datasets used to develop the methods we build upon (ChestX-ray14: 112,120 images; CheXpert: 224,316 images).

Standard regularization techniques—dropout, weight decay, learning rate scheduling, and early stopping—mitigate but do not resolve this gap. DeepAUC optimization, despite its theoretical advantages for AUC-oriented learning, does not provide a clear benefit at this scale.

D. Explainability in Multimodal Architectures

Grad-CAM++ was designed for single-input convolutional networks. In multimodal settings, the gradient signal reflects contributions from all input modalities, complicating interpretation. Our wrapper approach—holding clinical inputs constant while computing image gradients—isolates the image contribution but cannot capture interaction effects between modalities. Developing explainability methods that faithfully represent multimodal feature interactions remains an open challenge.

E. Limitations

This study has several limitations:

- The small dataset size (675 samples) limits statistical power and generalization. Results should be interpreted as preliminary.
- The REFLACX dataset contains annotations from multiple radiologists per image, introducing label noise that we do not model explicitly.
- Version incompatibilities between MIMIC-IV and MIMIC-CXR result in approximately 30% data loss during integration.
- We evaluate only two fusion strategies; attention-based and cross-modal transformer architectures may yield better results.
- The Grad-CAM++ wrapper isolates image gradients but does not capture cross-modal interaction effects.
- Missing clinical values are handled by mean imputation, which may introduce bias.

VIII. Conclusion

We presented a multimodal deep learning framework for thoracic disease classification that integrates chest radiographs with emergency department triage data. By linking five MIMIC data sources with REFLACX annotations, we constructed a unified multimodal dataset and demonstrated that clinical context provides modest but consistent improvements over image-only classification (test AUC 0.826 vs. 0.816). Concatenation fusion outperforms element-wise summation both quantitatively and in terms of Grad-CAM++ explanation quality.

Our findings underscore the potential of multimodal approaches for medical diagnosis while highlighting the significant challenges posed by limited data availability. The clinical-only model's failure confirms that imaging remains the primary diagnostic modality, with triage variables serving a complementary role.

Future work should focus on scaling the multimodal framework to larger cohorts, exploring attention-based fusion mechanisms, incorporating radiology report text as an additional modality, and developing explainability methods specifically designed for multimodal medical architectures. Additionally, investigating semi-supervised and transfer learning strategies may help address the data scarcity challenge that currently limits multimodal medical AI systems.

References

[1] X. Wang, Y. Peng, L. Lu, Z. Lu, M. Bagheri, and R. M. Summers, "ChestX-ray8: Hospital-scale chest X-ray database and benchmarks on weakly-supervised classification and localization of common thorax diseases," *Proceedings of the IEEE Conference on Computer Vision and Pattern Recognition (CVPR)*, pp. 2097–2106, 2017.

[2] P. Rajpurkar, J. Irvin, K. Zhu, B. Yang, H. Mehta, T. Duan, D. Ding, A. Bagul, C. Langlotz, K. Shpanskaya, M. P. Lungren, and A. Y. Ng, "CheXNet: Radiologist-level pneumonia detection on chest X-rays with deep learning," *arXiv preprint arXiv:1711.05225*, 2017.

[3] J. Irvin, P. Rajpurkar, M. Ko, Y. Yu, S. Ciurea-Ilcus, C. Chute, H. Marklund, B. Haghgoo, R. Ball, K. Shpanskaya, J. Seekins, D. A. Mong, S. S. Halabi, J. K. Sandberg, R. Jones, D. B. Larson, C. P. Langlotz, B. N. Patel, M. P. Lungren, and A. Y. Ng, "CheXpert: A large chest radiograph dataset with uncertainty labels and expert comparison," in *Proceedings of the AAAI Conference on Artificial Intelligence*, vol. 33, 2019, pp. 590–597.

[4] J. N. Acosta, G. J. Falcone, P. Rajpurkar, and E. J. Topol, "Multimodal biomedical AI," *Nature Medicine*, vol. 28, no. 9, pp. 1773–1784, 2022.

[5] J. Lipkova, R. J. Chen, B. Chen, M. Y. Lu, M. Barbieri, D. Shao, A. J. Vaidya, C. Chen, L. Zhuang, D. F. K. Williamson, M. Shaban, T. Y. Chen, and F. Mahmood, "Artificial intelligence for multimodal data integration in oncology," *Cancer Cell*, vol. 40, no. 10, pp. 1095–1110, 2022.

[6] A. Kline, H. Wang, Y. Li, S. Dennis, M. Hutch, Z. Cenber, F. Wang, A. Kumar, D. L. Willett, Y. Luo, Y. Peng, and L. Chen, "Multimodal machine learning in precision health: A scoping review," *npj Digital Medicine*, vol. 5, no. 1, p. 171, 2022.

[7] A. Holzinger, G. Langs, H. Denk, K. Zatloukal, and H. Müller, "Causability and explainability of artificial intelligence in medicine," *Wiley Interdisciplinary Reviews: Data Mining and Knowledge Discovery*, vol. 9, no. 4, p. e1312, 2019.

[8] R. R. Selvaraju, M. Cogswell, A. Das, R. Vedantam, D. Parikh, and D. Batra, "Grad-CAM: Visual explanations from deep networks via gradient-based localization," in *Proceedings of the IEEE International Conference on Computer Vision (ICCV)*, 2017, pp. 618–626.

[9] A. Chattopadhay, A. Sarkar, P. Howlader, and V. N. Balasubramanian, "Grad-CAM++: Generalized gradient-based visual explanations for deep convolutional networks," in *IEEE Winter Conference on Applications of Computer Vision (WACV)*. IEEE, 2018, pp. 839–847.

[10] A. E. W. Johnson, T. J. Pollard, N. R. Greenbaum, M. P. Lungren, C.-y. Deng, Y. Peng, Z. Lu, R. G. Mark, S. J. Berkowitz, and S. Horng, "MIMIC-CXR, a de-identified publicly available database of chest radiographs with free-text reports," *Scientific Data*, vol. 6, no. 1, p. 317, 2019.

[11] G. Huang, Z. Liu, L. Van Der Maaten, and K. Q. Weinberger, "Densely connected convolutional networks," in *Proceedings of the IEEE Conference on Computer Vision and Pattern Recognition (CVPR)*, 2017, pp. 4700–4708.

[12] P. Rajpurkar, J. Irvin, R. L. Ball, K. Zhu, B. Yang, H. Mehta, T. Duan, D. Ding, A. Bagul, C. P. Langlotz, B. N. Patel, K. W. Yeom, K. Shpanskaya, F. G. Blankenberg, J. Seekins, T. J. Amrhein, D. A. Mong, S. S. Halabi, E. J. Zucker, A. Y. Ng, and M. P. Lungren, "CheXNeXt: Deep learning approaches for multi-label chest radiograph classification," vol. 1, no. 4, 2018, p. e182694.

[13] Z. Yuan, Y. Yan, M. Sonber, and T. Yang, "Large-scale robust deep AUC maximization: A new surrogate loss and empirical studies on medical image classification," in *Proceedings of the IEEE/CVF International Conference on Computer Vision (ICCV)*, 2021, pp. 3040–3049.

[14] A. E. W. Johnson, L. Bulgarelli, L. Shen, A. Gayles, A. Shammout, S. Horng, T. J. Pollard, S. Hao, B. Moody, B. Gow, L.-w. H. Lehman, L. A. Celi, and R. G. Mark, "MIMIC-IV, a freely accessible electronic health record dataset," *Scientific Data*, vol. 10, no. 1, p. 1, 2023.

[15] A. E. W. Johnson, T. J. Pollard, S. J. Berkowitz, N. R. Greenbaum, M. P. Lungren, C.-y. Deng, R. G. Mark, and S. Horng, "MIMIC-CXR-JPG, a large publicly available database of labeled chest radiographs," *arXiv preprint arXiv:1901.07042*, 2019.

[16] R. Bigolin Lanfredi, M. Zhang, W. F. Auffermann, J. Chan, P.-A. T. Duber, V. Dwyer, N. Murthy, M. Y. Shai, A. Sodickson, S. P. Bhatt, and T. Defined, "REFLACX, a dataset of reports and eye-tracking data for localization of abnormalities in chest x-rays," *Scientific Data*, vol. 9, no. 1, p. 350, 2022.

[17] J. Deng, W. Dong, R. Socher, L.-J. Li, K. Li, and L. Fei-Fei, "ImageNet: A large-scale hierarchical image database," *Proceedings of the IEEE Conference on Computer Vision and Pattern Recognition (CVPR)*, pp. 248–255, 2009.

[18] D. P. Kingma and J. Ba, "Adam: A method for stochastic optimization," *Proceedings of the International Conference on Learning Representations (ICLR)*, 2015.