4/18/2019 1:32:55 PM

Mr. Radhe Shyam Mittal

HR = 87 mS

B.P = 118/76 mmHg

SpO2 = 98 (RA)

18/4/19

Rate	84	. Age not entered, assumed to be 50 years old for purpose of ECG interpretation
		. Sinus rhythm.....normal P axis, V-rate 50- 99
PR	130	. Multiple ventricular premature complexes.....V complexes w/ short R-R intervls
QRSD	87	. Abnormal R-wave progression, late transition.....QRS area<0 in V5/V6
QT	316	. Inferior infarct, old.....Q >35mS, II III aVF
QTc	374	. Abnrm T, consider ischemia, anterolateral lds.....T <-0.20mV, I aVL V2-V6

--AXIS--

P	57
QRS	-42
T	122

12 Lead; Standard Placement

- ABNORMAL ECG -

Unconfirmed Diagnosis

MR. RADHE SHYAM MITTAL
PRN : 113258 Age/Sex 58 Yrs / Male
Visit : IP-2 Dt. : 18/04/2019 14:39
Consultant : Dr. D Gaware

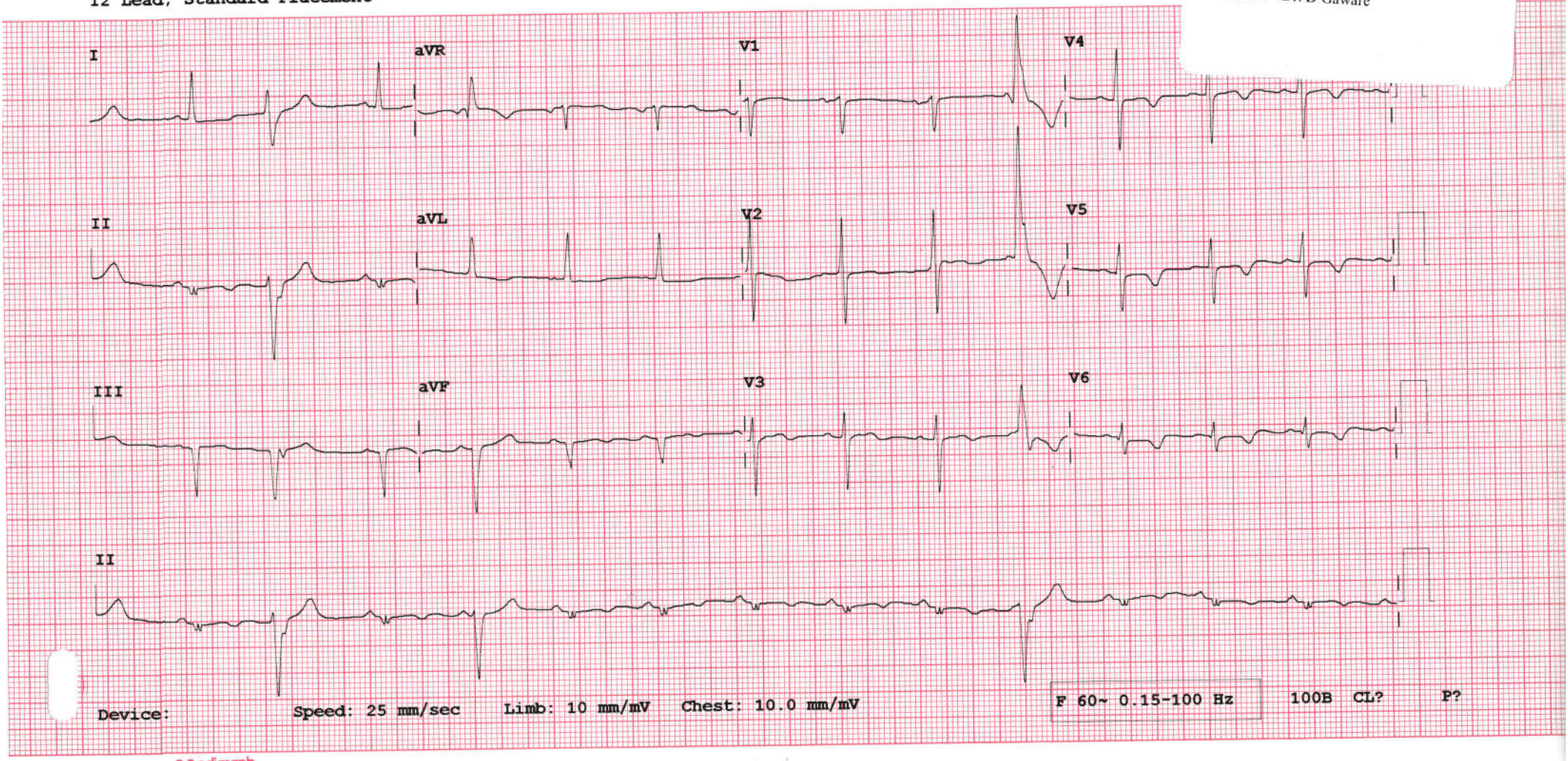

Device: Speed: 25 mm/sec Limb: 10 mm/mV Chest: 10.0 mm/mV F 60~ 0.15-100 Hz 100B CL? P?

Medigraph