MR RADHE S MITTAL 20/04/2019 10:15:41

Rate	104	. Age not entered, assumed to be 50 years old for purpose of ECG interpretation
		. Sinus tachycardia.....rate> 99
PR	141	. Abnormal R-wave progression, early transition.....QRS area>0 in V2
QRSD	89	. Inferior infarct, old.....Q >35mS, II III aVF
QT	355	. Abnrm T, consider ischemia, anterolateral lds.....T <-0.20mV, I aVL V2-V6
QTc	467	

--AXIS--

P	48
QRS	-40
T	163

12 Lead; Standard Placement

- ABNORMAL ECG -

Unconfirmed Diagnosis

MR. RADHE SHYAM MITTAL
PRN : 113258 Age/Sex 58 Yrs / Male
Visit : IP-2 Dt. : 18/04/2019 14:39
Consultant : Dr. D Gaware

20/4/19 @ 10:30 AM

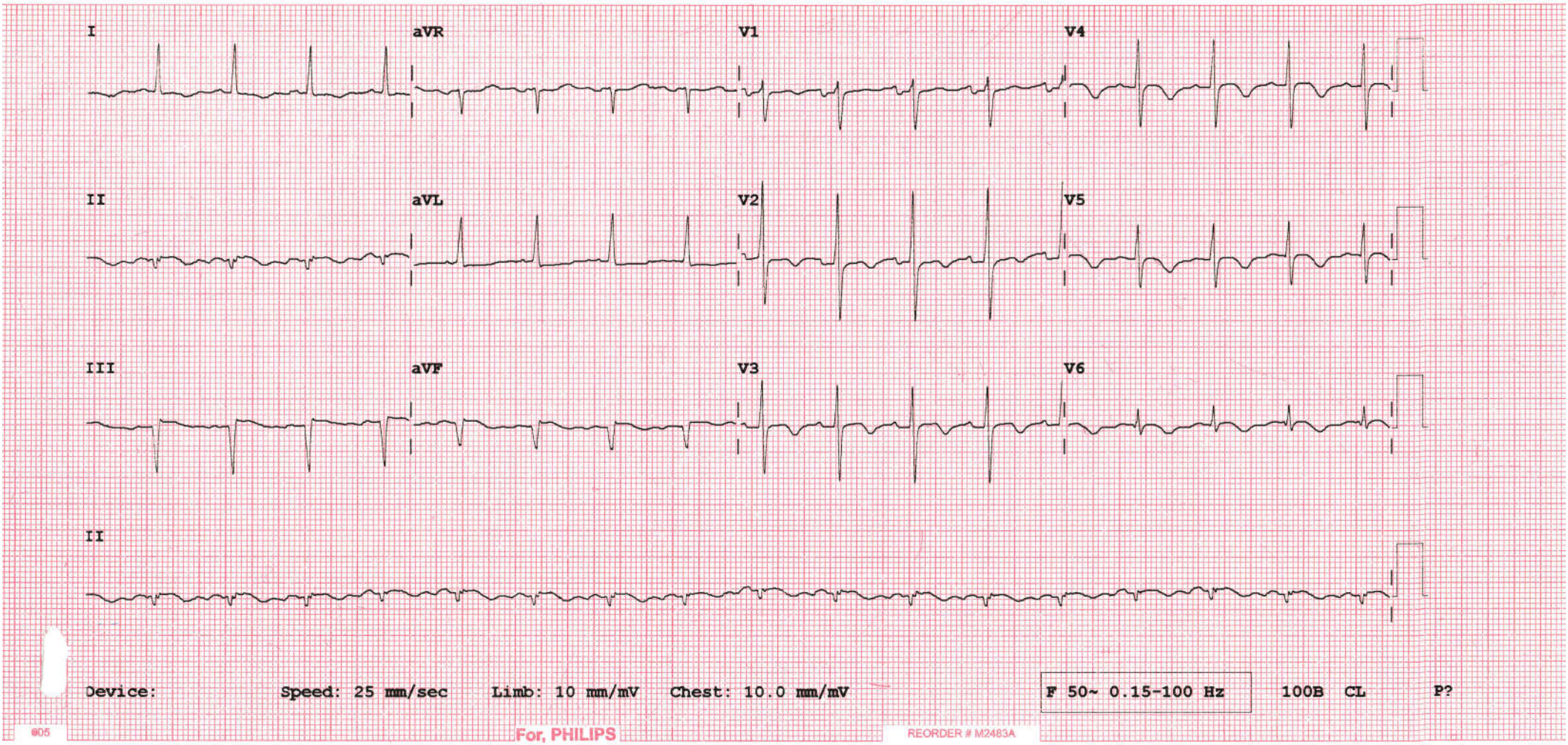

Device: Speed: 25 mm/sec Limb: 10 mm/mV Chest: 10.0 mm/mV F 50~ 0.15-100 Hz 100B CL P?

805 For, PHILIPS REORDER # M2483A