9/16/2019 6:56:21 PM

Rate	62	. Age not entered, assumed to be 50 years old for purpose of ECG interpretation
		. Sinus rhythm.....normal P axis, V-rate 50- 99
PR	162	. Abnormal R-wave progression, early transition.....QRS area>0 in V2
QRSD	95	. Inferior infarct, age indeterminate.....Q>35mS, T neg, II III aVF
QT	503	. Lateral leads are also involved.....lat Q or ST-T abnormalities
QTc	511	. Prolonged QT interval.....QTc >500mS
		. Baseline wander in lead(s) V4

--AXIS--

P	60
QRS	-24
T	-45

MR. RADHE SHYAM MITTAL
PRN : 113258 Age/Sex 59 Yrs / Male
Visit : IP-3 Dt. : 16/09/2019 19:33
Consultant : Dr. D Gaware

16/9/19

- ABNORMAL ECG -

12 Lead; Standard Placement

Unconfirmed Diagnosis

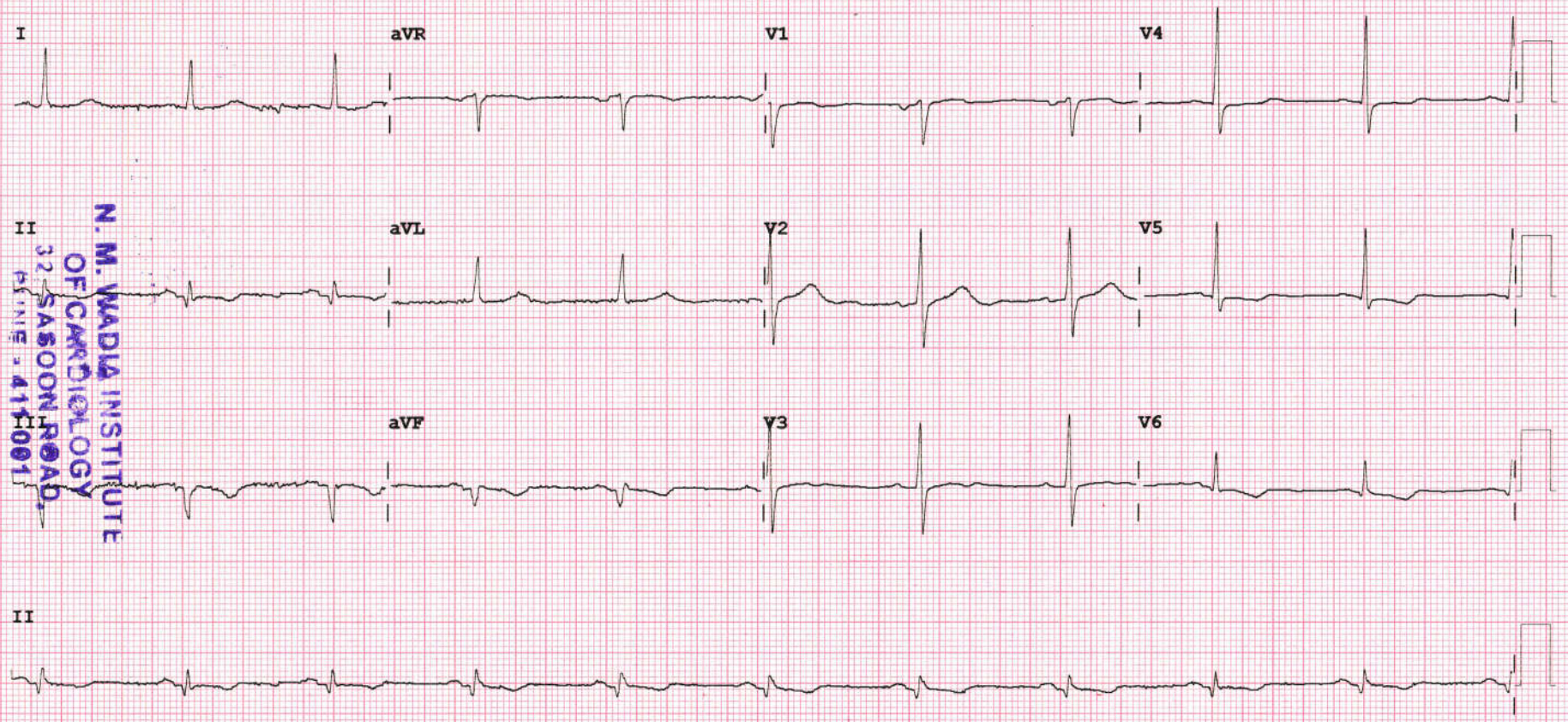

N. M. WADIA INSTITUTE OF CARDIOLOGY
32 SASOON ROAD,
PUNE - 411001

Device: Speed: 25 mm/sec Limb: 10 mm/mV Chest: 10.0 mm/mV F 60~ 0.15-100 Hz 100B CL P?

Medigraph