Avanti
SUPER SPECIALITY HOSPITAL

Patient Name: Mr. RADHE SHYAM MITTAL S/O SITA RAM MITTAL / MRN-220400294
Age / Gender: 61 Yr /Male
Address: SETHI NAGAR, Ujjain, MADHYA PRADESH
Req. Doctor: DR.GAWARE
Regn. Number: WALKIN.22-23-245

Request Date : 15-04-2022 11:42 AM

Reporting Date : 15-04-2022 12:00 PM
Report Status : Finalized

ECHO

OBSERVATION:

M-MODE &2D ECHO:-

Sclerotic aortic valve

All cardiac chambers are normal in size.

No RWMA at rest.

Normal LV systolic function LVEF 60%

Intact IAS / IVS.

No Clot / Vegetation /Effusion.

DOPPLER:

Trivial MR

IMPRESSION:

Status CAD/ Post CABG
Sclerotic aortic valve
Trivial MR
Normal LV systolic function (LVEF- 60%).

END OF REPORT

DR. SURESH BENDWAL
MD MEDICINE

AVANTI HOSPITALS UJJAIN

Hari Phatak Road , Nana Kheda , Mahakal Road , Ujjain

Name **radheshyam mittal**

Sex

Age
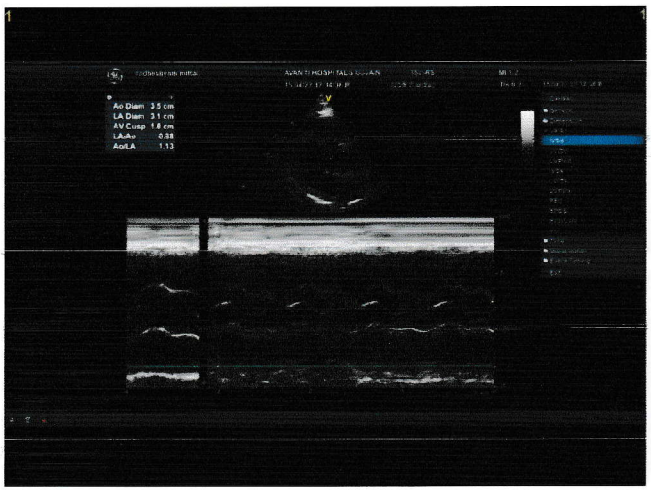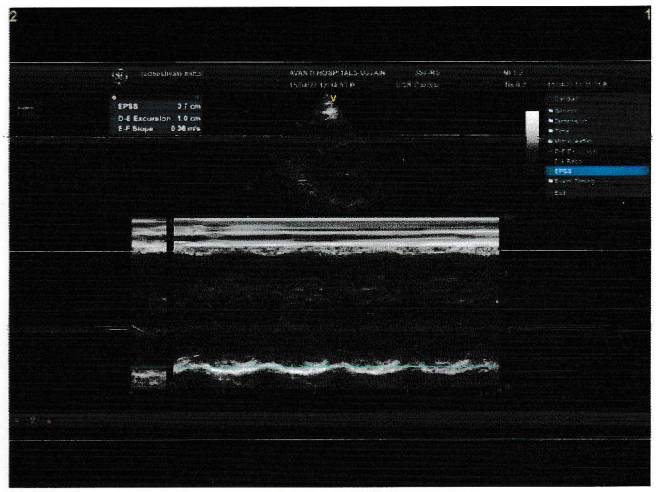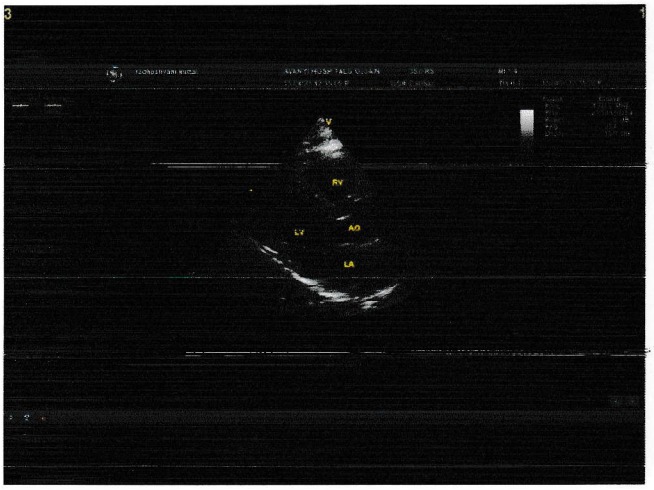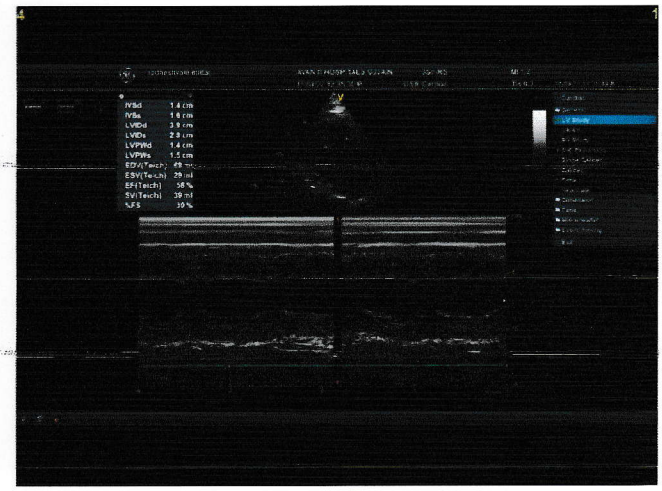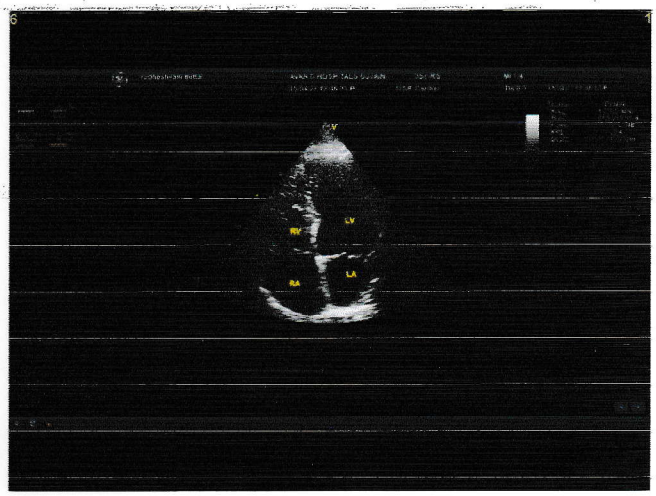
Date **15/04/2022**