NAME	RADHE SHYAM MITTAL	STUDY DATE	13-05-2025 13:11:36
REF. BY	DR. PUSHKAR GADRE	PATIENT ID	SI-S2136919
BARCODE		AGE	64Y 4M 10D

HEAD AND NECK CT AND MRI WITH CONTRAST

Clinical profile: Ulcerative lesion along lateral border of oral tongue on right side, post biopsy status.MR before and after injection of IV contrast and plain non-contrast bone CT of neck has been performed.
Susceptibility artefacts from metallic dental implants are noted.
10cc of Gadoteric acid was administered at a rate of 2ml/sec. No life-threatening contrast reaction was observed after intravenous contrast administration.

There is a large lobulated heterogeneously enhancing mass with scattered non-enhancing necrotic foci involving the oral tongue and base of tongue on the right side.
It measures 5.3 x 3.5 cm in maximum AP and transverse dimensions with a superoinferior extent of approximately 4.7 cm.
It extends across the midline to involve the oral tongue on left side (for approximately 3.6 mm) as well as extends posteriorly beyond the base tongue to involve the right glosso tonsillar sulcus and the right palatine tonsil. The right half of the soft palate also appears bulky and shows enhancement.
Inferiorly the mass has infiltrated the sublingual space and invades floor of mouth with involvement of upper component of root of tongue (genioglossus muscles / lingual septum). The mass also involves the right hyoglossus and styloglossus /palatoglossus muscles.

Outlines of the right mylohyoid muscle are indistinct and mass seems to be extending into the right submandibular space along the medial cortex of the right mandibular body.
Extension is also noted to the adjacent right gingivolabial and gingivobuccal sulcus.
The skull base and nasopharynx appear clear.

There are multiple bilateral level IA, IB and level II nodes noted on both sides, larger and more in number on the right side. The right sided level IB and level II nodes ranging in size from 14-18.5 mm and show necrotic areas. No signs of extranodal extension are seen on this study.The level IB and II nodes on the right side also appear rounded with loss of fatty hilum.

NAME	**RADHE SHYAM MITTAL**	STUDY DATE	**13-05-2025 13:11:36**
REF. BY	**DR. PUSHKAR GADRE**	PATIENT ID	**SI-S2136919**
BARCODE		AGE	**64Y 4M 10D**

Bilateral smaller discrete Level IA (6-7.5 mms), IB (10-12.7 mms) level II (12-13.5 mms.) lymph nodes are seen.

There is a diffuse abnormal signal and post-contrast enhancement noted within the body of mandible on right side however, the corticall margins of the mandible are intact and the medullary cavity appears intact.

Hypopharynx and larynx appear intrinsically normal.

Deep neck spaces are normal.

Sphenoid sinus shows mucosal thickening with mottled densities.

Vertebral bodies look normal.

Impression:

Large heterogeneously enhancing partially necrotic lobulated mass involving oral tongue on the right side with locally infiltrative features as described above,extending to floor of mouth, right submandibular space and across the midline.
Extension to the right sided oropharyngeal structures is also seen as mentioned above with involvement of the right sided gingivolabial and gingivobuccal sulcus.
Changes in the right mandible appear to be more on account of odontogenic pathology / peritumoural oedema rather than involvement by the mass - however, this would need confirmation with HPE.
Findings are indicative of a neoplastic pathology.
Bilateral multilevel cervical lymphadenopathy is noted as described above. The right-sided larger necrotic level IB and level II nodes are suggestive of metastasis.
Associated smaller discrete bilateral level IA, IB and lower cervical nodes are also seen which will need followup.

NAME	RADHE SHYAM MITTAL	STUDY DATE	13-05-2025 13:11:36
REF. BY	DR. PUSHKAR GADRE	PATIENT ID	SI-S2136919
BARCODE		AGE	64Y 4M 10D

Suggest: Biopsy correlation.
USG guided FNA of the cervical lymph nodes if clinically indicated and followup .

Dr.Sanjay Vaid
MD

The above report was created using voice recognition technology. Although efforts are made to correct all errors prior to signing, please notify us immediately at our Reception Desk numbers if any dictation errors are noted. The errors will be rectified at the earliest.

NAME	***RADHE SHYAM MITTAL***	*STUDY DATE*	***13-05-2025 13:11:36***
REF. BY	***DR. PUSHKAR GADRE***	*PATIENT ID*	***SI-S2136919***
BARCODE		*AGE*	***64Y 4M 10D***

Images are not for diagnostic purpose *Patient Id: SI-S2136919* *Name: RADHE SHYAM MITTAL*

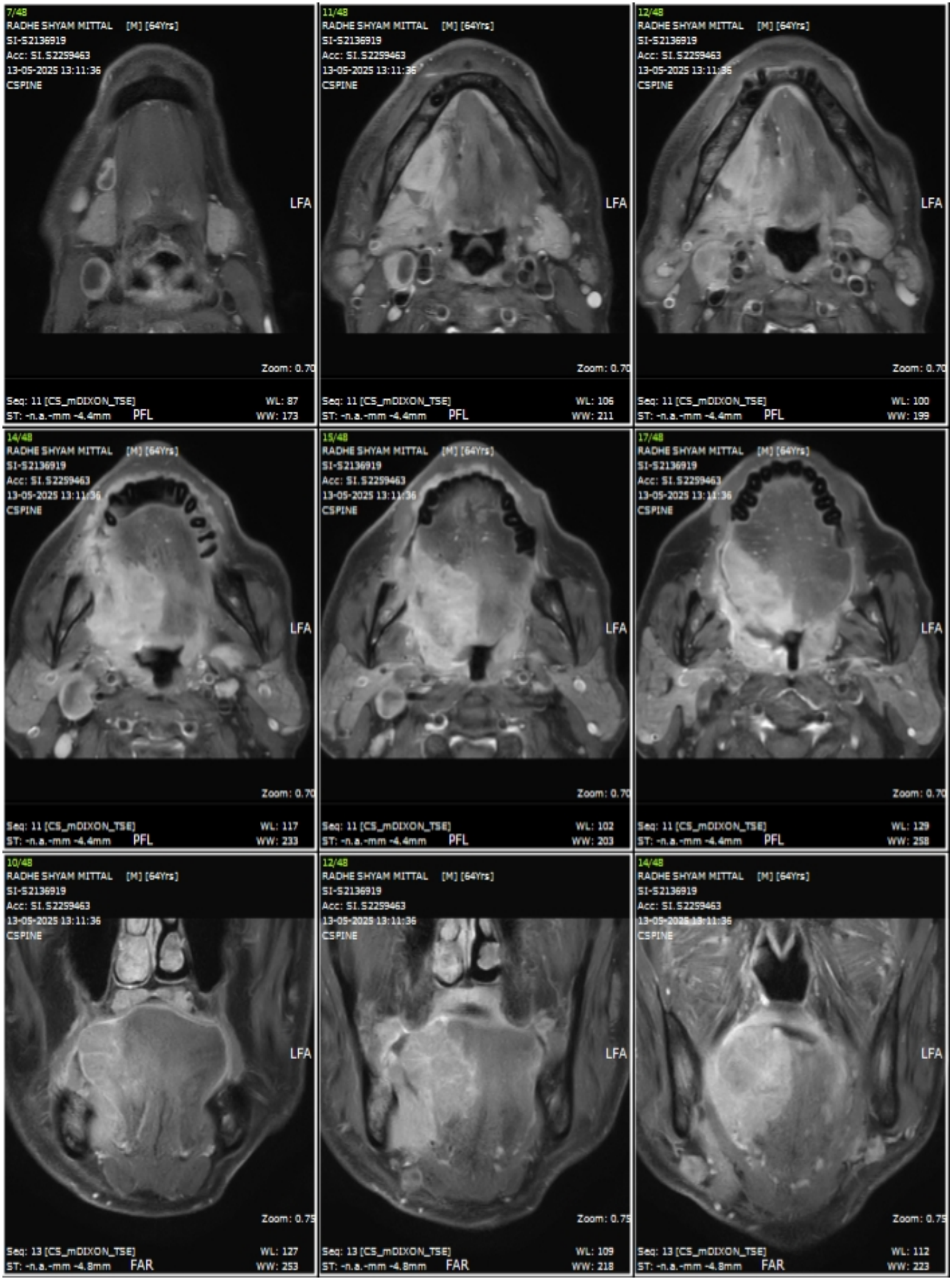

Images are not for diagnostic purpose *Patient Id: SI-S2136919* *Name: RADHE SHYAM MITTAL*
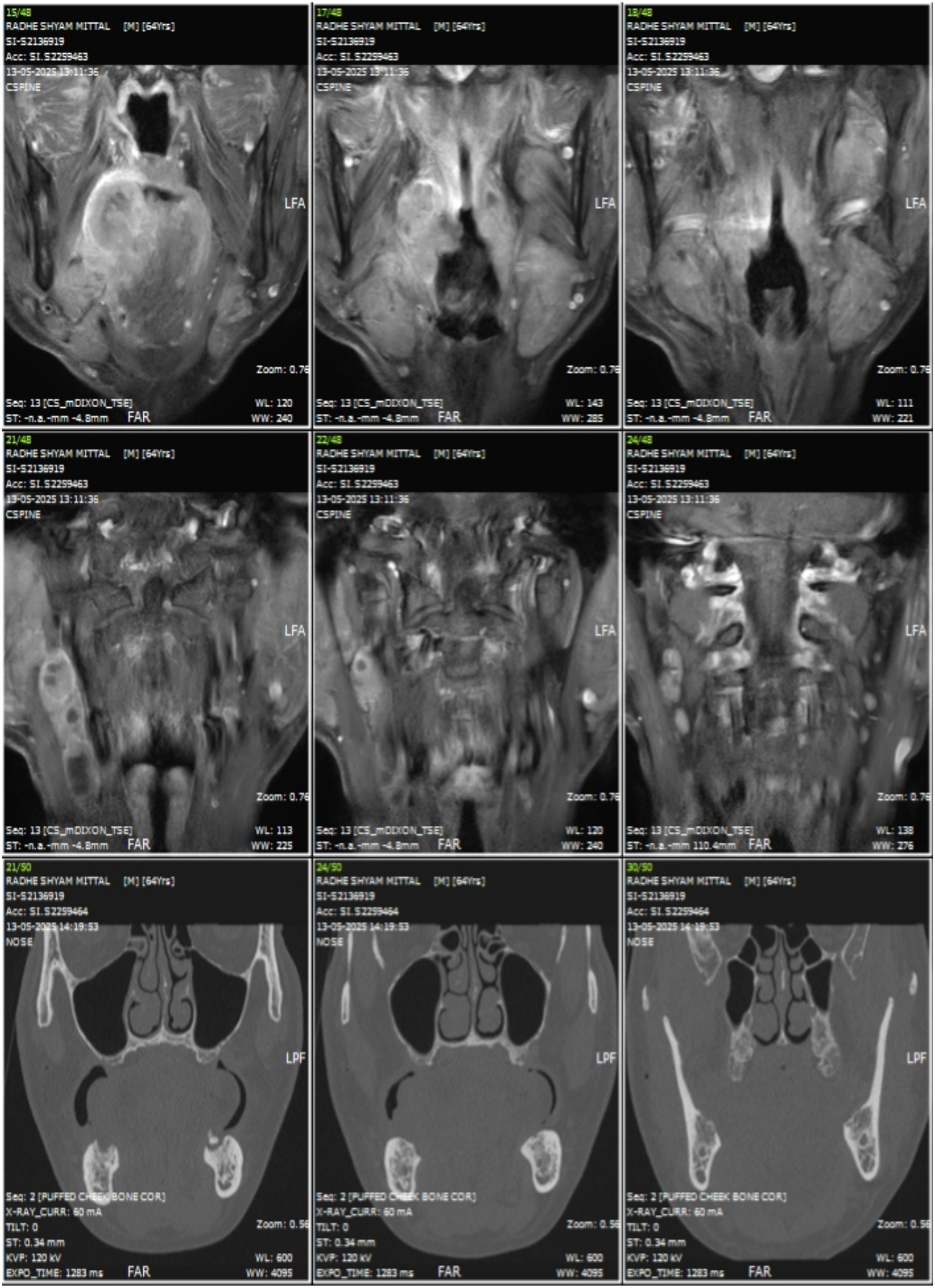
Images are not for diagnostic purpose *Patient Id: SI-S2136919* *Name: RADHE SHYAM MITTAL*