Ultrasound Atlas of Rheumatic Diseases

Hand

Healthy Subject
RA
SpA
Crystal-related
Other Diseases

Hand

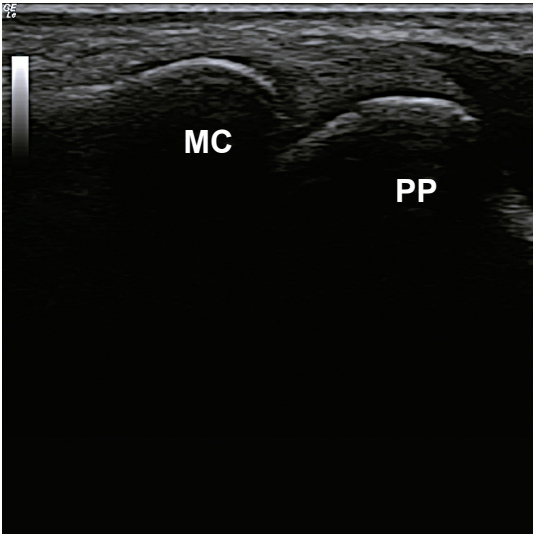

Healthy Subject

2nd MCP joint

Dorsal longitudinal scan

MC = metacarpal
PP = proximal phalanx

Chang, Chi-Ching

Grey scale US using a Envisor (Philips, the Netherland) with a multi-frequency linear transducer (7~12 MHz)

Hand

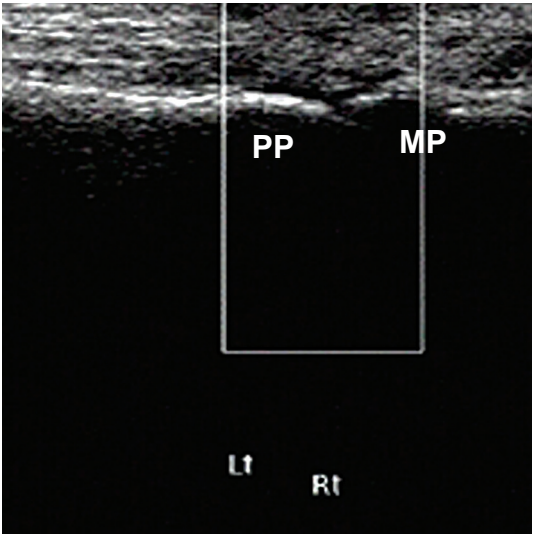

Healthy Subject

Hand (PIP joint)

Dorsal longitudinal scan

PP = proximal phalanx
MP = middle phalanx

Chang, Chi-Ching

Grey scale US using a Envisor (Philips, the Netherland) with a multi-frequency linear transducer (7~12 MHz)

Hand

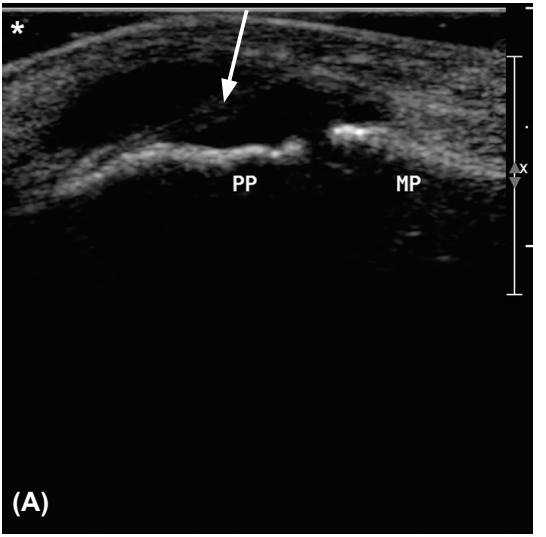

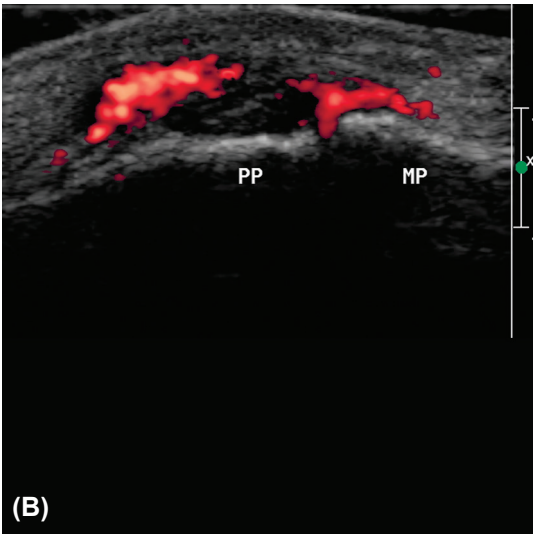

RA

Dorsal longitudinal scan (1 o'clock position) of PIP joint (A) and Power Doppler image (B).

(A) Marked widening of PIP joint with synovial memebrane proliferation (arrow).

(B) Power Doppler scan reveals confluent Doppler signals that occupy about half of the joint cavity.
PP = proximal phalanx
MP = middle phalanx
* = the anechoic jelly between the probe and skin of patient.

Chen, Hsin-Hua
Grey scale US using a Philip iU22 with a linear probe (7-15 MHz)

Hand

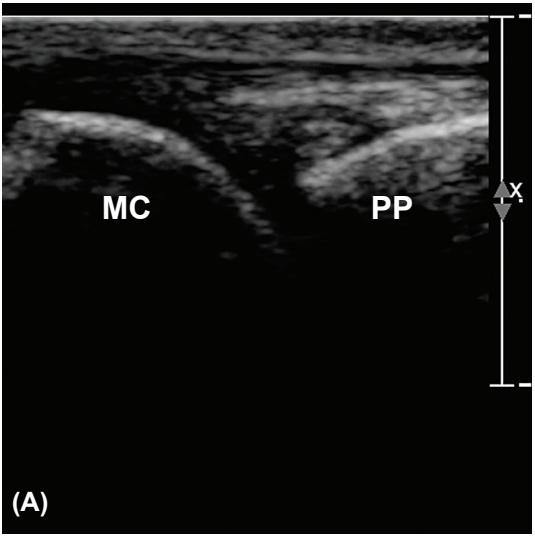

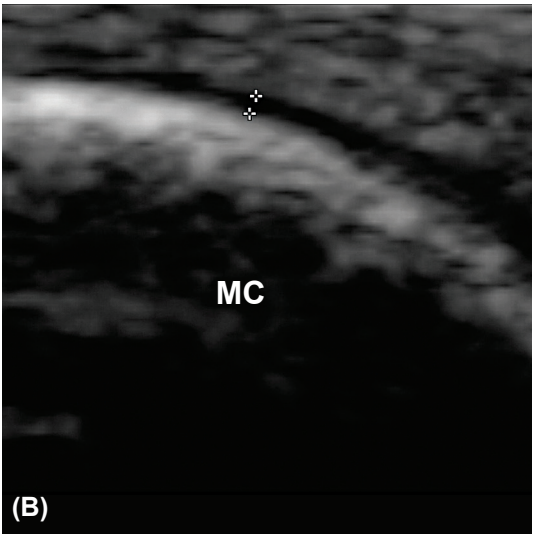

RA

MCP joint

Dorsal longitudinal scan (A) and amplified image for measuring cartilage thickness (0.016cm) on maximal flexion (B).

Widening of 2nd MCP joint capsule with mild synovial membrane proliferation and minimal effusion. Measurement of cartilage thickness was performed with full-flexion of MCP joint over metacarpal bone. The normal range in women is more than 0.03cm.
MC = metacarpal
PP = proximal phalanx

Chen, Hsin-Hua
Grey scale US using a Philip iU22 with a volumetric probe (4D, 5-13MHz)

Hand

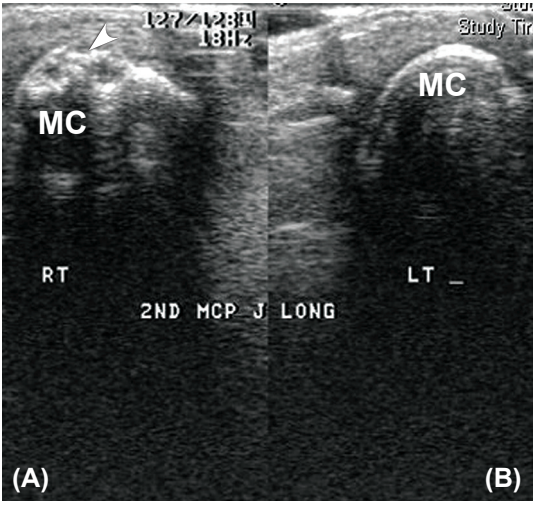

Tsai, Wen-Pin
Aloka 5500

RA

Right 2nd MCP joint

Dorsal longitudinal scan

Bony erosion(arrow head) change over right 2nd metacarpal head (A) RT : abnormal, (B) LT : normal
MC = metacarpal

Hand

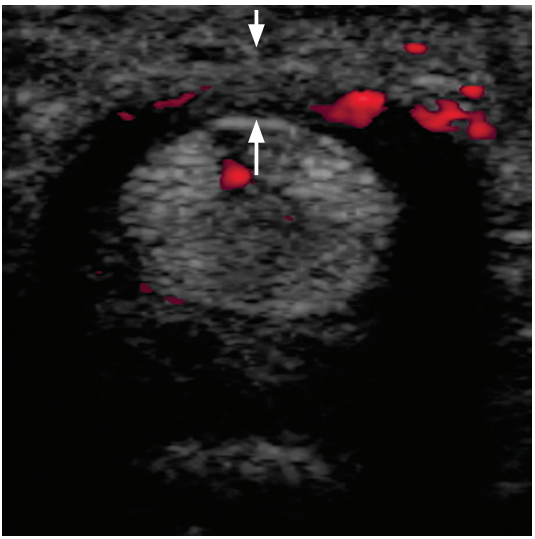

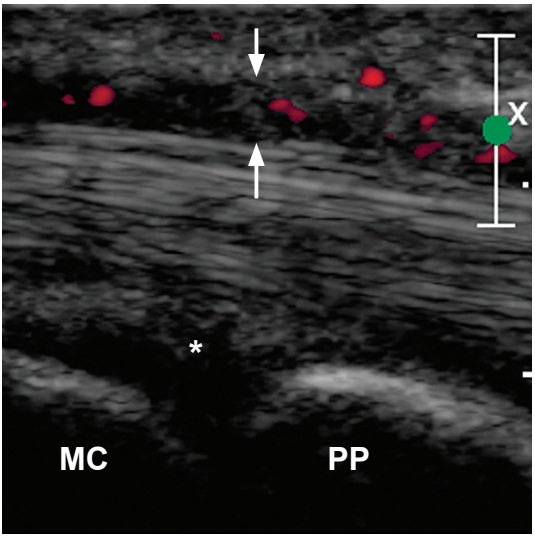

SpA

Psoriatic Arthritis

Rt 2nd MCP joint and flexor tendon

Volar Transverse (A) and longitudinal (B) scan of Right 2nd MCP

Thickening of tendon sheath (arrows) with some DoPPler signals. Minimal widening (*) of right 2rd MCP joint capsule without intraarticular DoPPler signal.

MC = metacarpal

PP = proximal phalanx

Chen, Hsin-Hua

Power Doppler US using a Philip iU22 with a linear probe (7-12MHz)

Hand

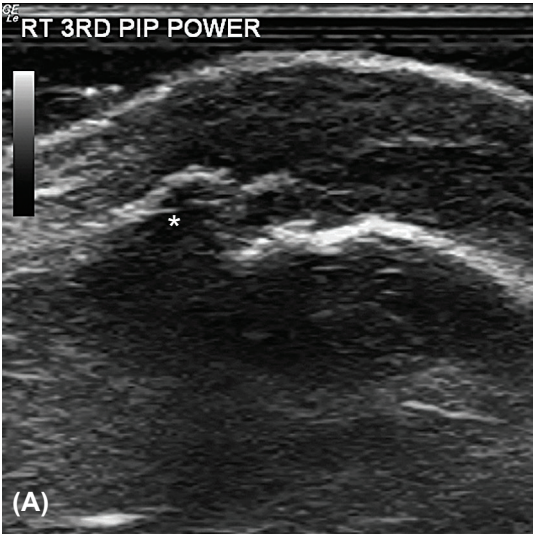

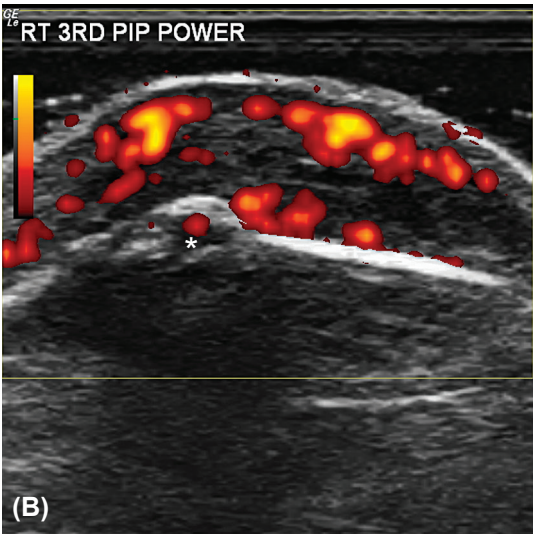

SpA

Psoriatic Arthritis

Longitudinal scan of 3rd proximal interphalangeal joint

(A) Marked swelling of overlying tendon complex on PIP joint and joint erosion.(*)

(B) Power Doppler scan also showed extended inflammation along tendon and entheseal area.

Kuo, Chang-Fu

Grey scale US using a Logiq 9 (General Electrics Medical Systems,Milwaukee,WI) with a volumetric probe (4D16L), with power doppler

Hand

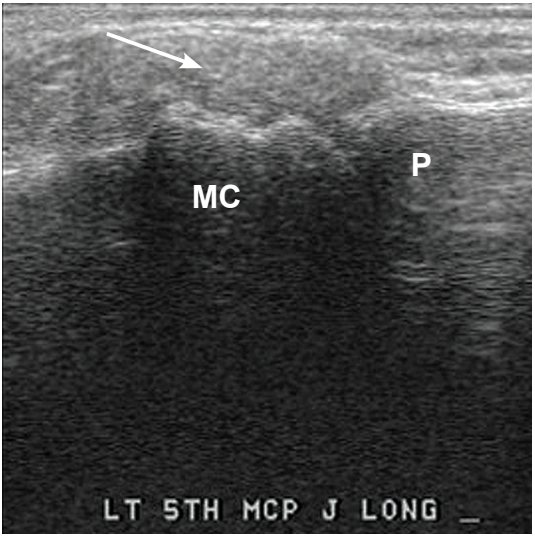

Crystal-related

Tophaceous Gout

Dorsal longitudinal scan of Left 5th MCP joint

Tophi(arrow) deposition adjacent to MCP joint.
MC = metacarpal
P = phalange

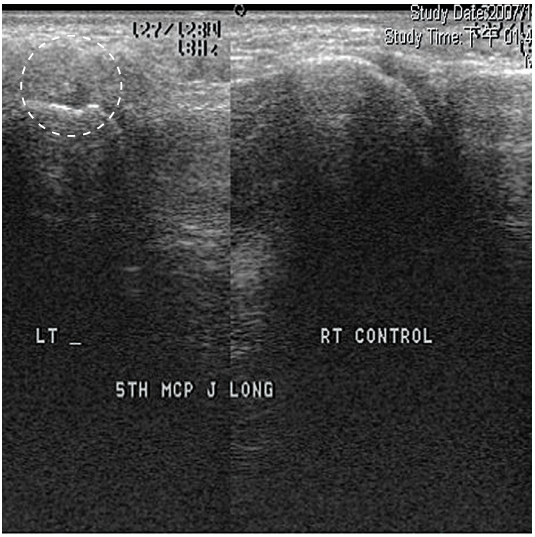

Tophi deposition adjacent to MCP joint.
MC = metacarpal
P = phalange
LT = abnormal
RT = normal

Tsai, Wen-Pin
Aloka 5500

Hand

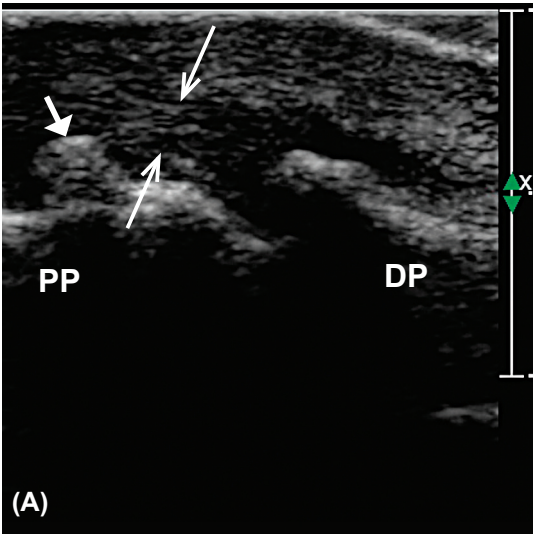

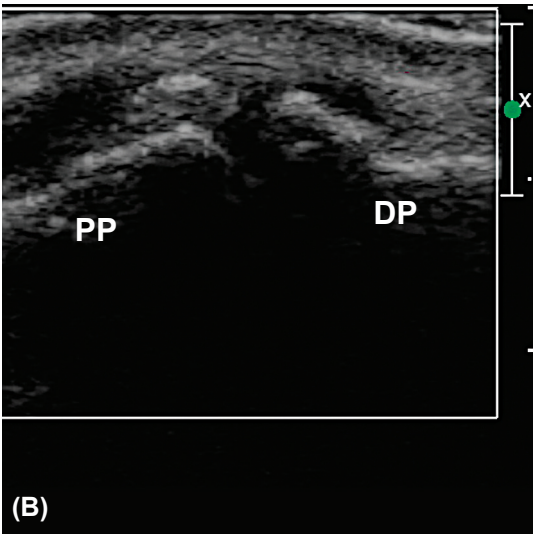

Crystal-related

Limited PSS

Dorsal longitudinal scan of distended PIP joint (A) and Power Doppler US of mild flexed PIP joint (B).

(A) Note a hyperechoic lesion with acoustic shadow in the deep part of extensor tendon (arrows).

(B) Note the hyperechoic lesion moves with the tendon when the PIP mild flexed. PDUS shows no Doppler signals in the tendon and joint cavity. The above findings suggest a calcified lesion in the extensor tendon, which might be related to PSS.

PP = proximal phalanx
DP = distal phalanx

Chen, Hsin-Hua

Grey scale and power Doppler US using a Philip iU22 with a umetric probe (4D, 5-13MHz)

Hand

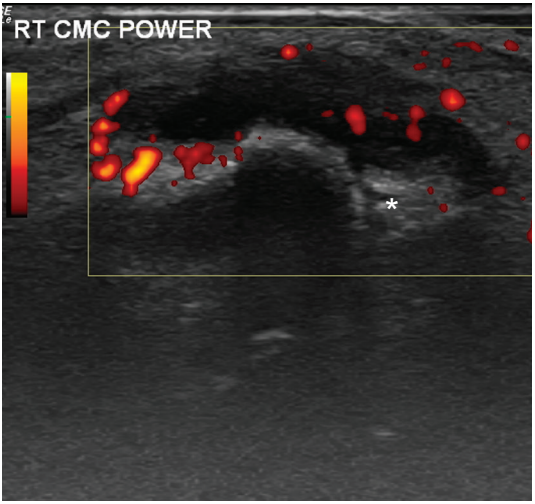

Crystal-related

Gouty Arthritis

Transverse dorsal scan of Carpometocarpal joint

Gouty arthritis, CMC joint. Extensive fluid collection with high vascularity. Some hyperechoic spots(*) were suspected to be tophi. Fluid analysis revealed MSU crystals.

Kuo, Chang-Fu

Grey scale US using a Logiq 9 (General Electrics Medical Systems,Milwaukee,WI) with a volumetric probe (4D16L), with power doppler

Hand

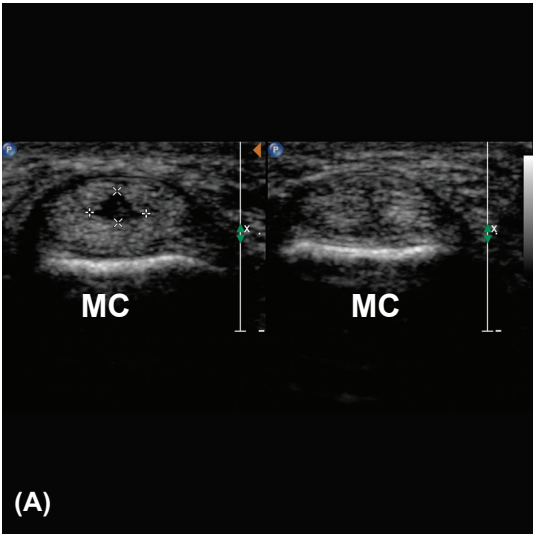

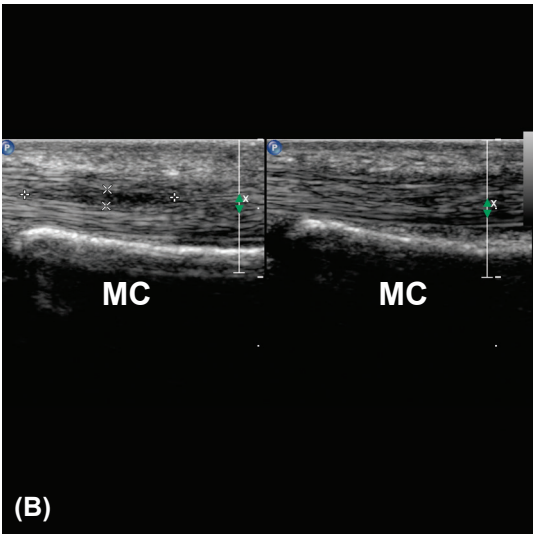

Chen, Hsin-Hua

Grey scale US using a Philip iU22 with a linear array probe (7-15MHz)

Other Diseases

Tendon Tear

Volar transverse scan (A) and longitudinal scan of 3rd MCP (B).

(A) Transverse scan of digital flexor tendon shows a hypoechoic lesion in the deep part of the superficial flexor tendon in left side US image. Normal contralateral flexor tendon is shown in right side of US image.

(B) Longitudinal scan shows the corresponding focal partial tear.

MC = metacarpal

Hand

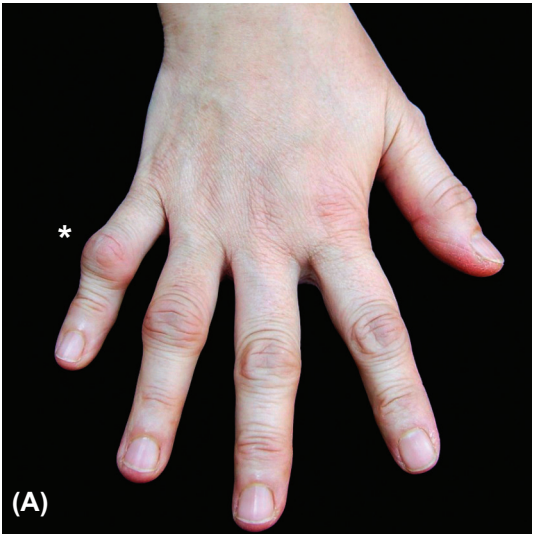

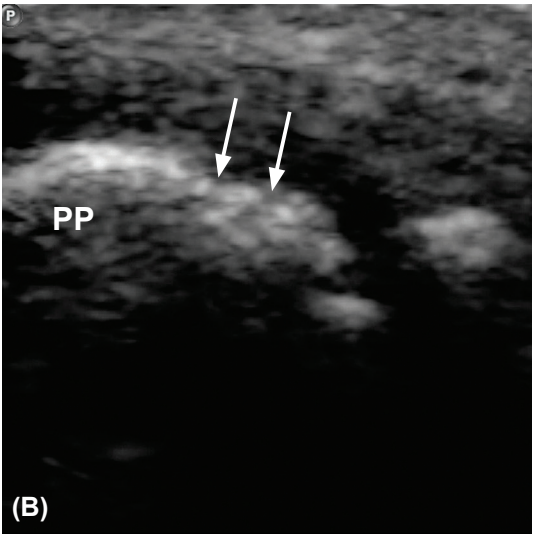

Chen, Hsin-Hua
Grey scale US using a Logiq 5 (General Electrics)

Other Diseases

RAPUS

Gross picture of right hand of a patient with RAPUS (A) and dorsal longitudinal scan with 4th PIP full flexion posture (B).

(A) Deformed 5th PIP joint (*).

(B) Longitudinal scan performed over 4th PIP joint with maximal flexion posture shows a focal bony erosion over proximal phalanx periarticular region with loss of anechoic overlying hyaline cartilage (arrows).

PP = proximal phalanx

Hand

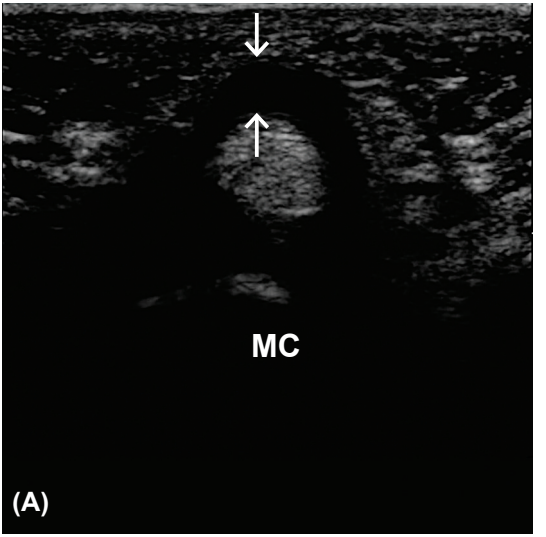

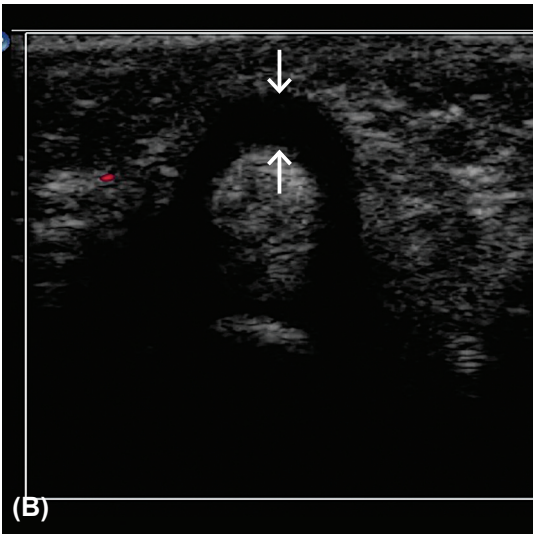

Chen, Hsin-Hua

Power Doppler US using a Philip iU22 with a linear probe (7-12MHz)

Other Diseases

Flexor Tenosynovitis (Degenerative)

Rt 3rd MCP joint and flexor tendon

Volar Transverse with Gray scale (A) and Power Doppler (B) images

Gray scale image shows marked widening of tendon sheath (arrows). No Doppler signal is found in the tendon sheath in power Doppler image, suggesting a degenerative process.

MC = metacarpal

Hand

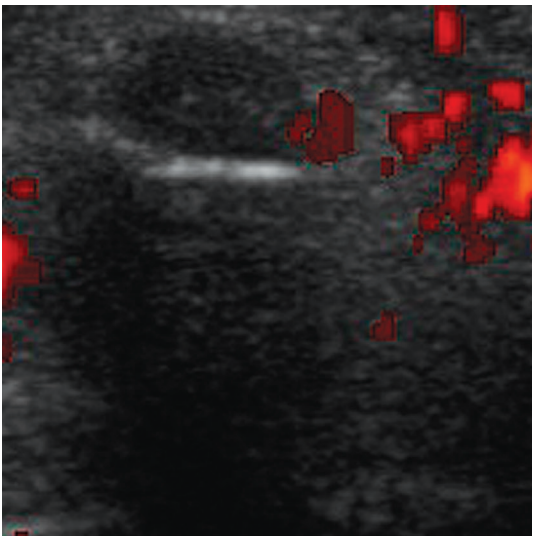

Chen, Ying-Chou
Power Doppler Ultrasonography using CGM OPUS 5000

Other Diseases

Primary Sjogren's Syndrome, Extensor Tenosynovitis

Right 3rd metacarpophalangeal joints

Transverse images obtained with a 7.5 MHz transducer over the dorsal aspect of the 3rd metacarpophalangeal joints

Power Doppler signals in more than half the synovium of the metacarpophalangeal joints.

Hand

Other Diseases

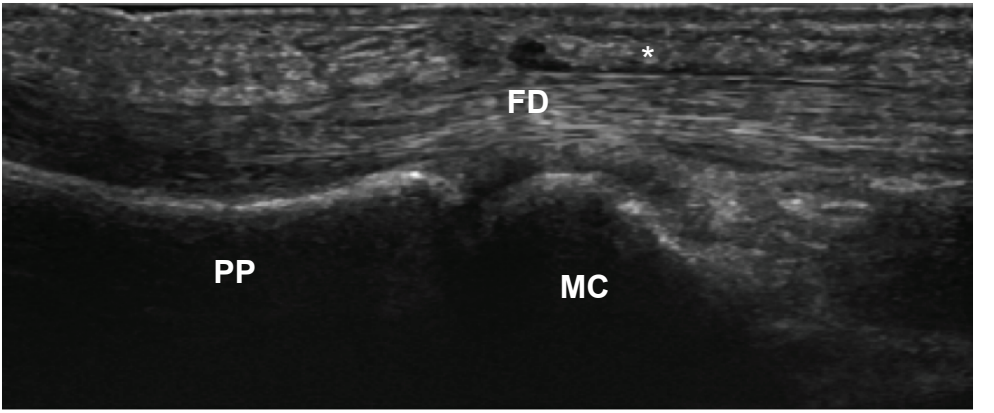

Lai, Kuo-Lung

Gray scale US using a GE E9 (General Electrics) with a linear probe (15MHz)

Trigger finger

Longitudinal scan

Trigger finger. Longitudinal US scan at volar aspect of MCP showed A1 pulley (*) thickening. FD: flexor digitorum tendon, MC: metacarpal head, PP: proximal phalanx.

Hand

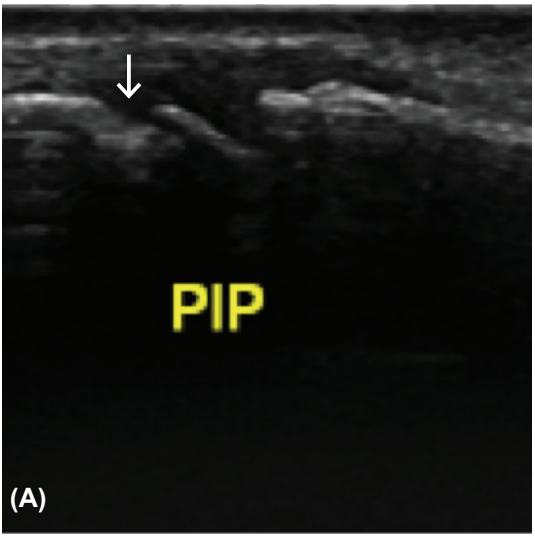

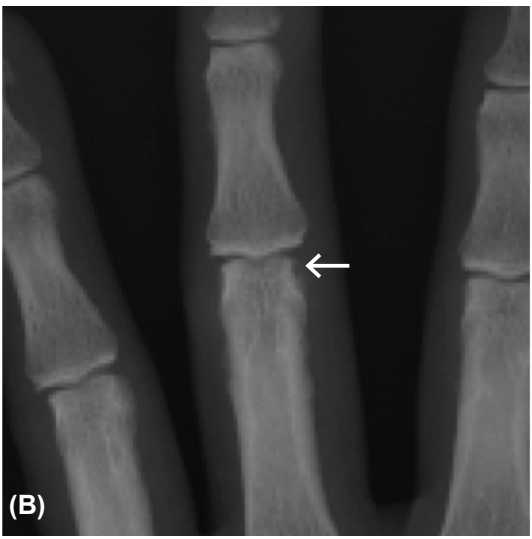

Other diseases

Erosive OA

Longitudinal scan of PIP joint

(A) Longitudinal US scan at dorsolateral side of 3rd PIP joint showed a bone erosion (arrow) at proximal phalanx head.

(B) X-ray showed joint space narrowing, tiny spur and a bone erosion (arrow) at the 3rd PIP joint.

Lai, Kuo-Lung

Gray scale US using a GE E9 (General Electrics) with a linear probe (15MHz)

Hand

Other Diseases

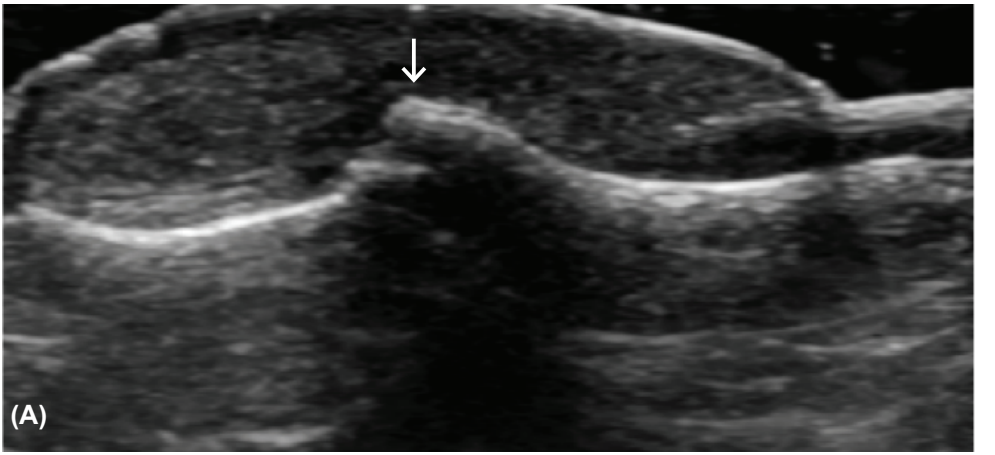

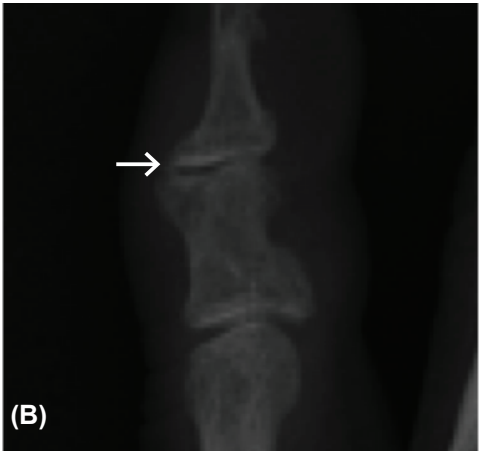

Heberden's node (DIP OA)

Longitudinal scan of DIP joint

Heberden's node (DIP OA). (A) Longitudinal US scan at dorsal side of 5th DIP joint showed bony protruding (arrow) (B) X-ray showed joint space loss and spurs (arrow) at the 5th DIP joint.

Lai, Kuo-Lung

Gray scale US using a GE E9 (General Electrics) with a linear probe (15MHz)

Hand

Other Diseases

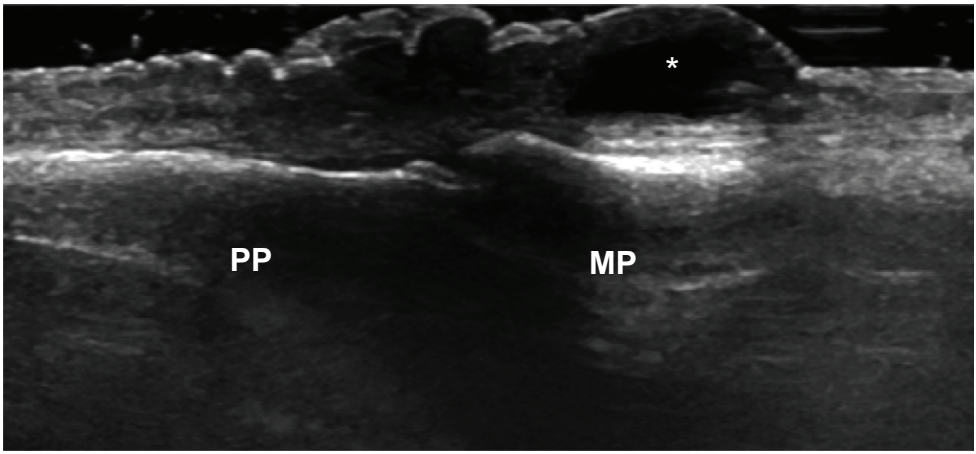

Lai, Kuo-Lung

Gray scale US using a GE E9 (General Electrics) with a linear probe (15MHz)

Ganglion cyst

Longitudinal scan

Ganglion cyst. Longitudinal US scan at the dorsum of PIP joint sowed an anechoic cyst (*) with posterior enhancement at the extensor tendon. PP: proximal phalanx, MP: middle phalanx.

Memo