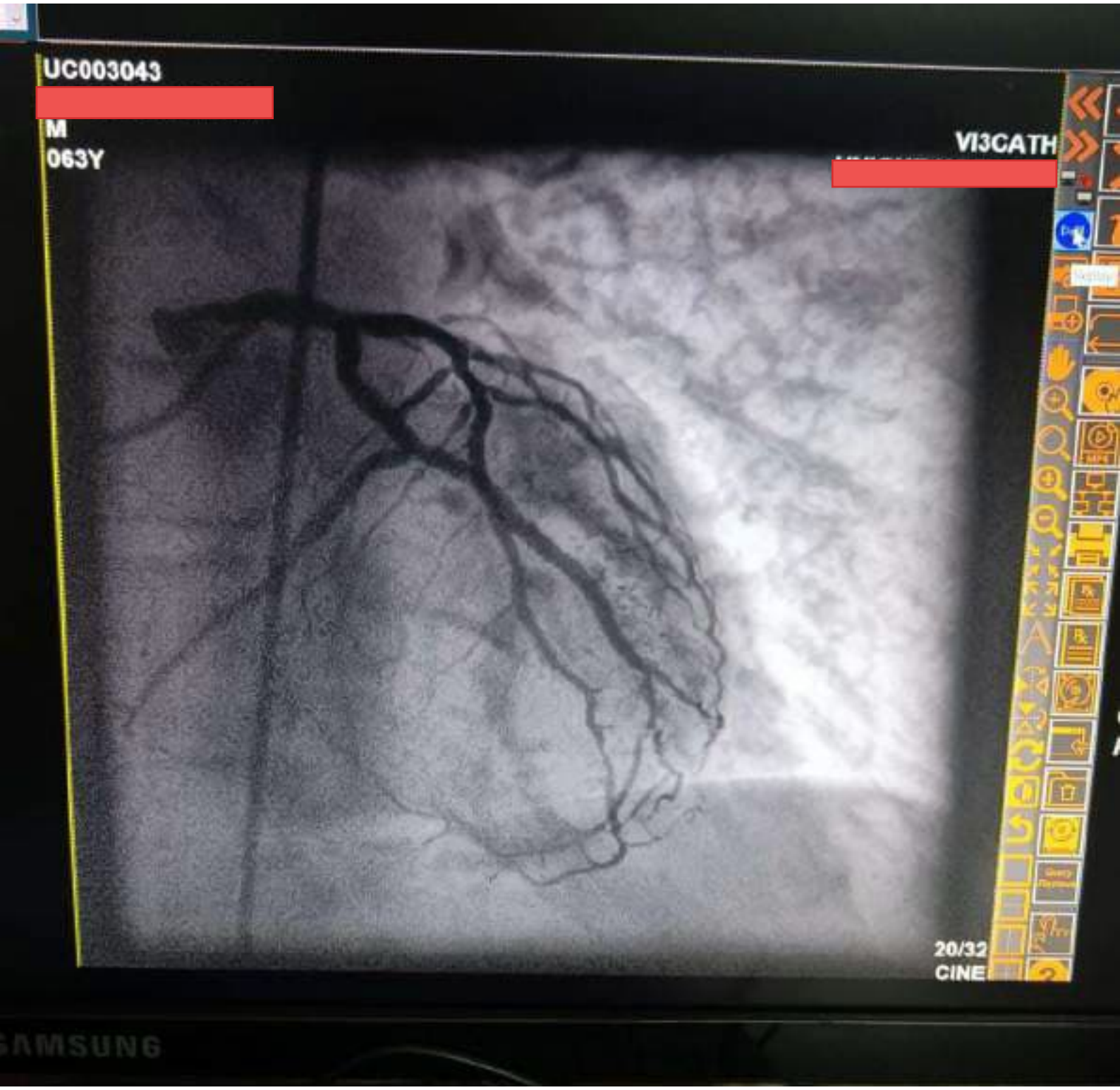
UC003043
[redacted]
M
063Y
VI3CATH
[redacted]
20/32
CINE
SAMSUNG

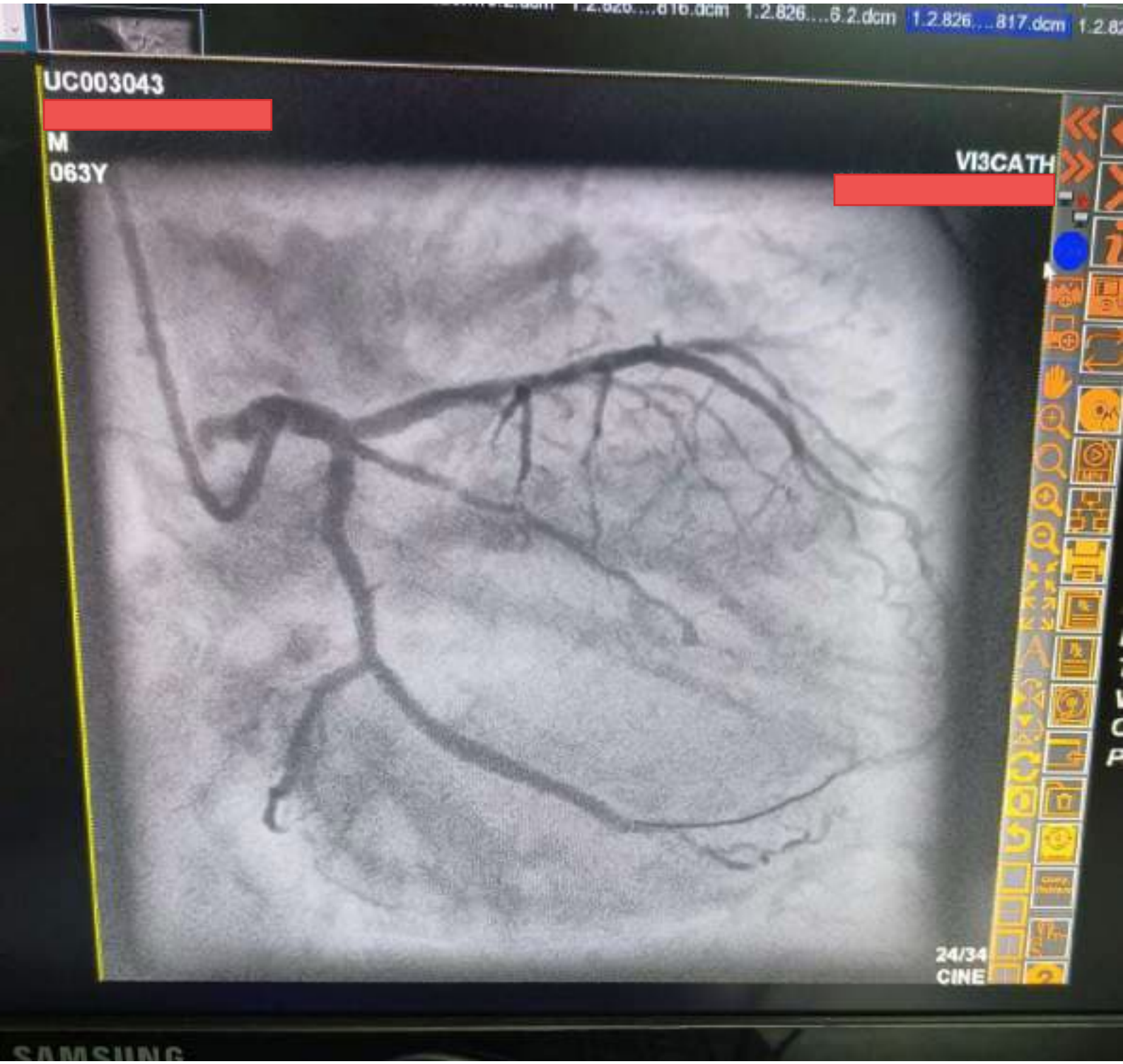
1.2.826....816.dcm
1.2.826....6.2.dcm
1.2.826....817.dcm
UC003043
M
063Y
VI3CATH
24/34
CINE
SAMSUNG

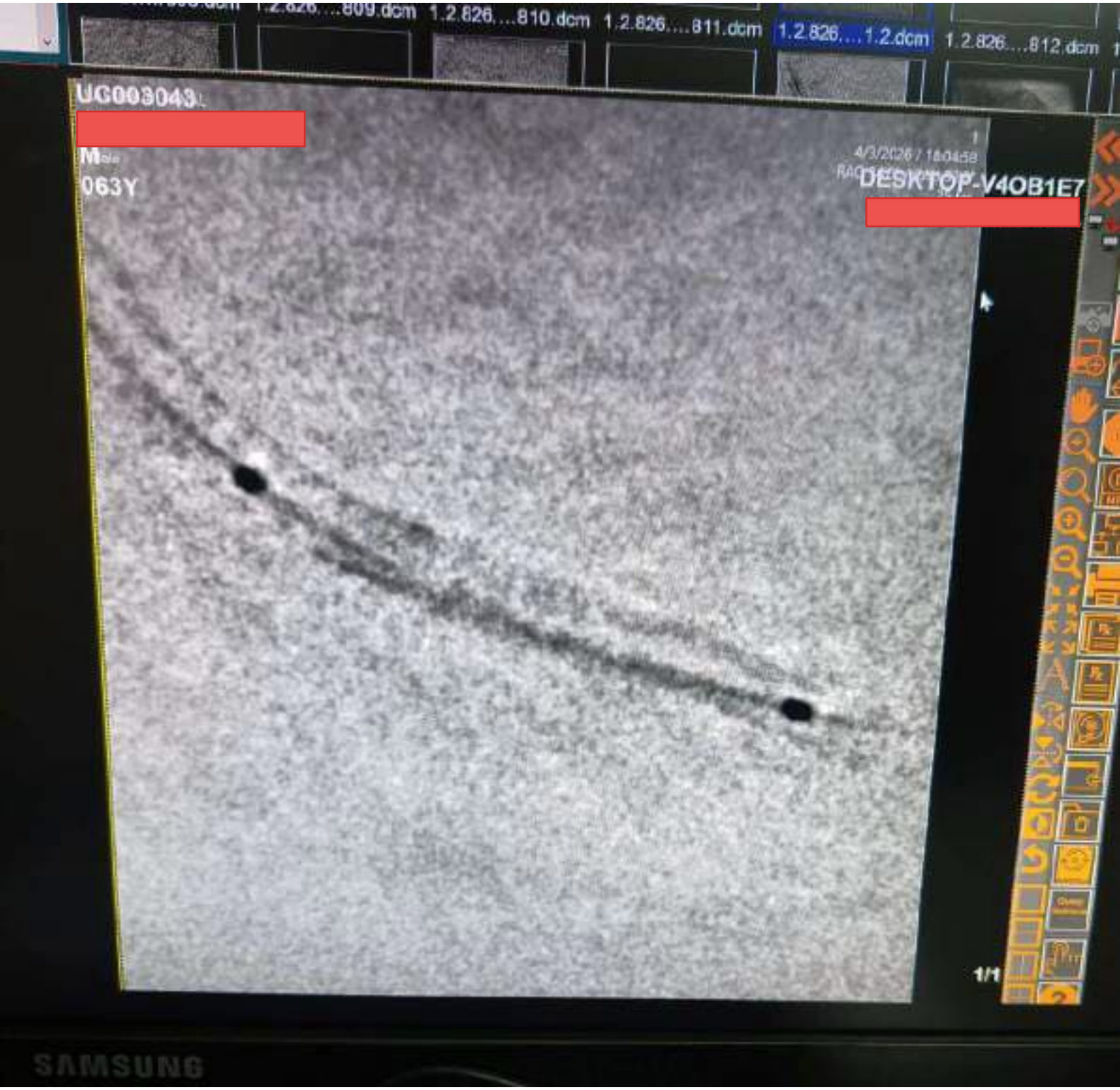
1.2.826....809.dcm
1.2.826....810.dcm
1.2.826....811.dcm
1.2.826....1.2.dcm
1.2.826....812.dcm
UG003043
[redacted]
M
063Y
4/3/2026 / 18:04:58
DESKTOP-V4OB1E7
[redacted]
1/1
SAMSUNG

UC003043
[redacted]
M
063Y
VI3CATH
[redacted]
8/29
CINE
SAMSUNG

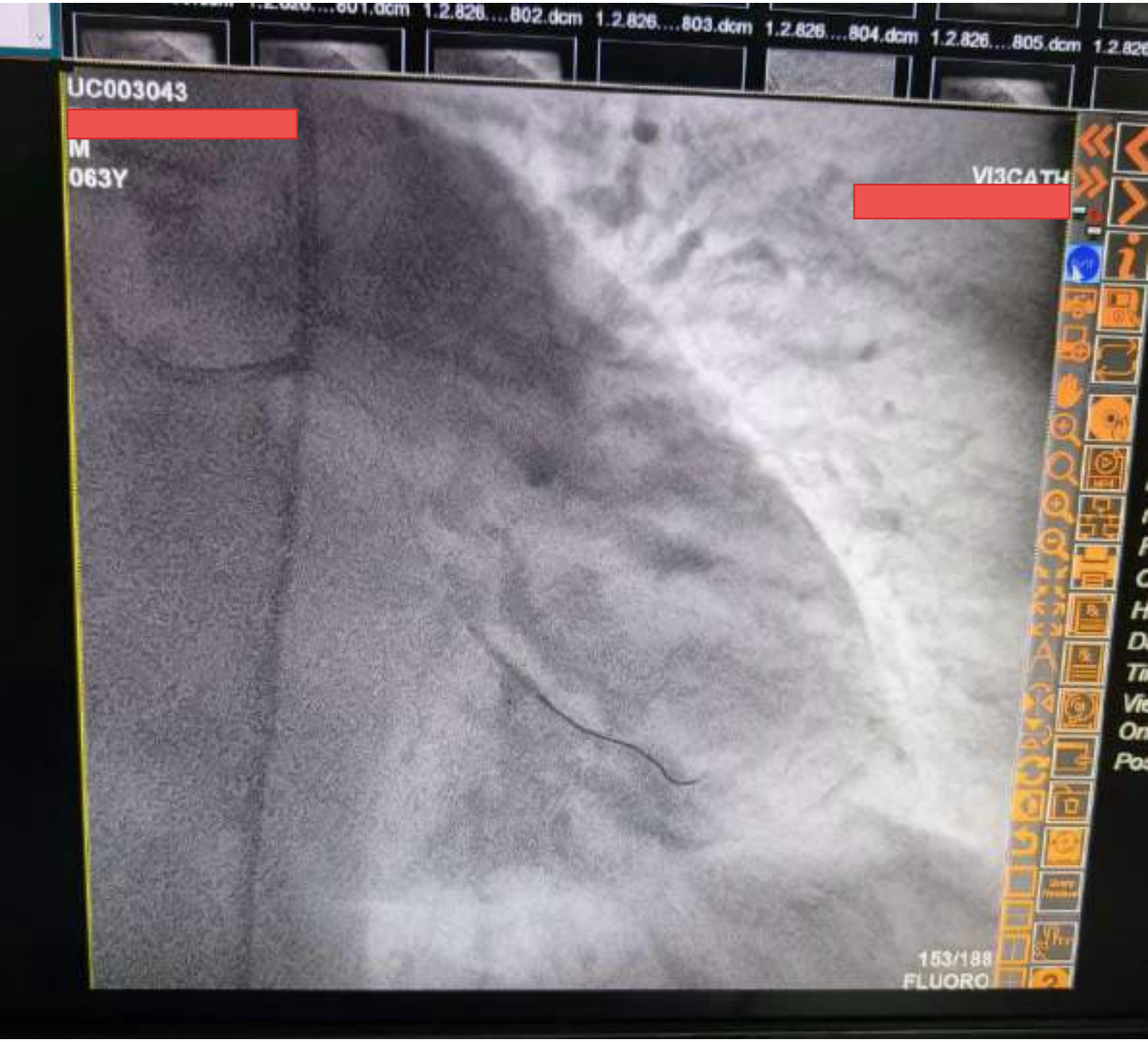
1.2.826....802.dcm
1.2.826....803.dcm
1.2.826....804.dcm
1.2.826....805.dcm
UC003043
[redacted]
M
063Y
VI3CATH
[redacted]
153/188
FLUORO

[redacted] (Gami)

[redacted]

The Complete Cardiovascular Care

Report of Coronary Angiography

[redacted]

M.D. (Medicine)
DNB (Cardiology)

Ex. Cardiologist : Sal Hospital, Ahmedabad
Ex. Physician : Lions Hospital, Palanpur

[redacted]

Name [redacted] Age : 63 Sex : Male

Done by Dr. [redacted] I.P. No. UI - 2234 MRD No. :

CATH No. UC - 3043 Date : 03/04/2026

RFR

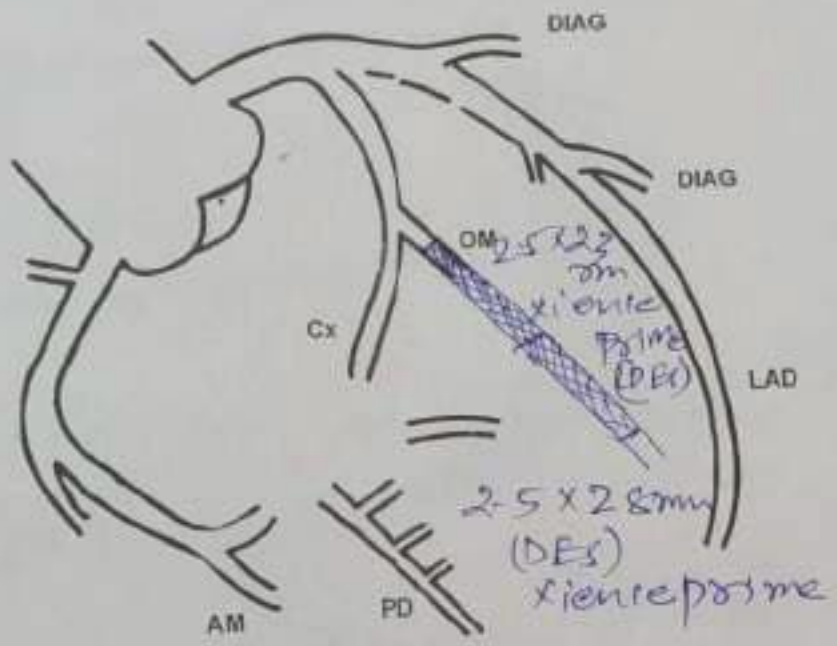

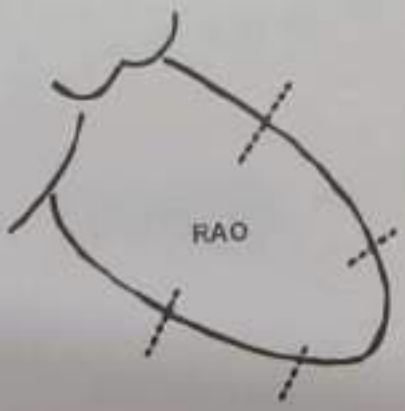

D - ACS : NSTEMI
CAG : SVD

Comments :
· PCI (2 DES) to OM, done

[redacted]

Cardiologist

[redacted]

RX

XIENCE PRIME™

Everolimus Eluting Coronary Stent System

2.5 mm	28 mm	143 cm

UDI

	2026-12-06
REF 105.1707-28	LOT 312.1441



FLUSHING TOOL

ATM	kPa
8 (NOM)	811
9	910
10	1010
11	1110
12	1210
13	1317
14	1419
15	1520
16	1621
17	1723
18 (RBP)	1824
19	1925
20	2027
21	2128
22	2229

POST DILATATION LIMIT 3.25 mm

Abbott Medical
3200 Lakeside Drive
Santa Clara, CA 95054 USA
TEL: (800) 227-9902
FAX: (800) 6U-6574
Outside USA TEL: +1 951-914-4069
Outside USA FAX: +1 951-914-0531

Product of Ireland

EN REP
Abbott Vascular International BVBA
Park Lane, Culliganlaan 2B
1831 Diegem, BELGIUM
TEL: + 32 2 714 14 11
FAX: + 32 2 714 14 12

EC REP
Abbott Vascular Netherlands BV
Argonautweg 1, 6422 PH
Heerlen
The Netherlands
TEL: +31-(0)45-5435700

7440-49-4

STERILE EO

MD CE 2797

2023-12-06

WPL2120663-12 (2023-19-17)

* Indicates a trademark of the Abbott group of companies

UC003043
M
063Y
VI3CATH
20/48
FLUORO

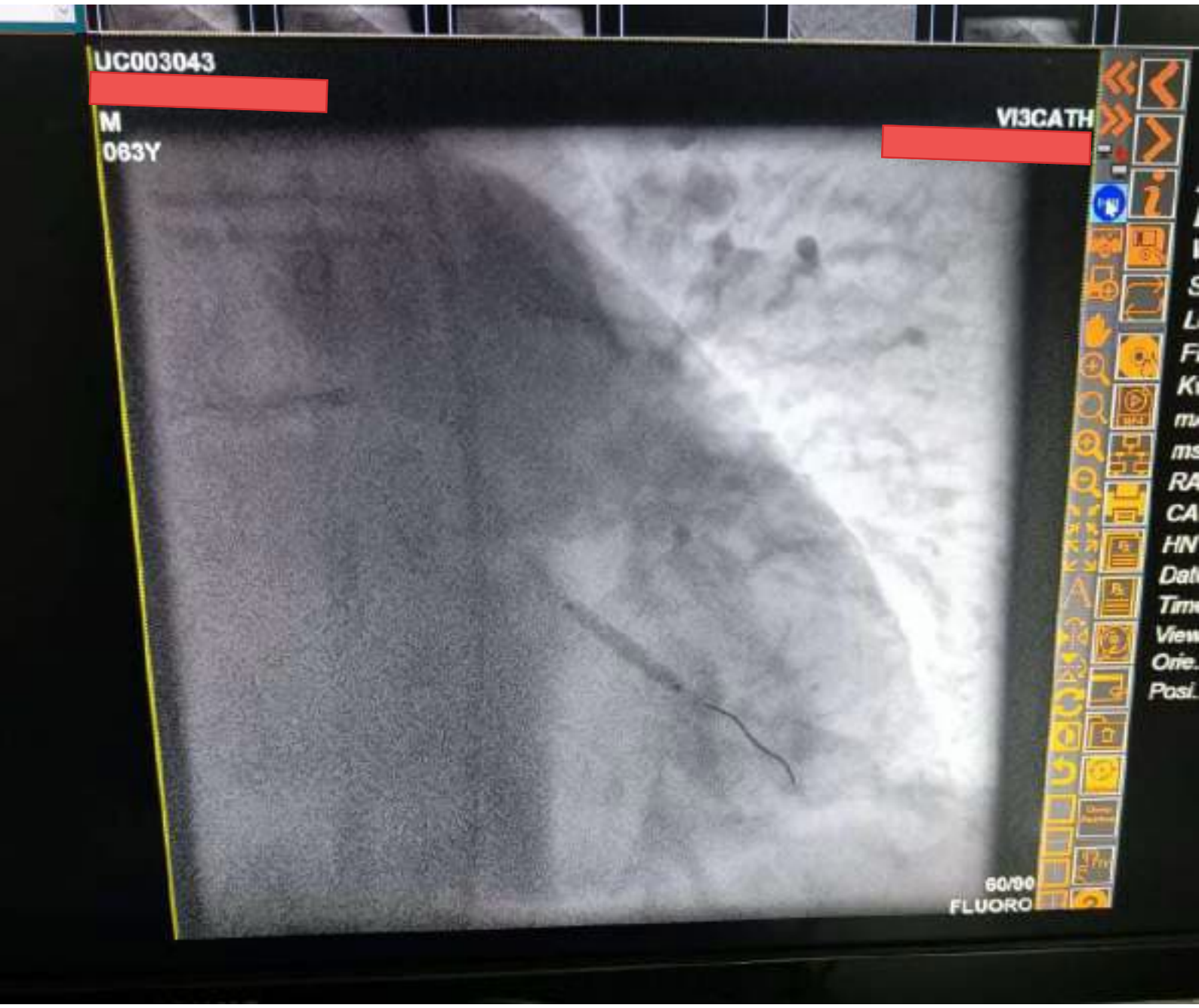
UC003043
[redacted]
M
063Y
VI3CATH
[redacted]
60/90
FLUORO

Abbott

Abbott

RX

XIENCE PRIME™

Everolimus Eluting Coronary Stent System

ATM	kPa
8 (NOM)	811
9	912
10	1013
11	1115
12	1216
13	1317
14	1419
15	1520
16	1621
17	1723
18 (RBP)	1824
19	1926
20	2027
21	2129
22	2229

POST DILATATION LIMIT 1.35 mm

2.5 mm | 23 mm | 143 cm

UDI

2027-03-12

REF 1011707-23 LOT 4032141

Abbott Medical
3200 Lakeside Drive
Santa Clara, CA 95054 USA
TEL: (800) 227-9902
FAX: (800) 601-8074
Outside USA TEL: +1 951-914-4999
Outside USA FAX: +1 951-914-2021

Product of Ireland

EC REP

Abbott Vascular International BVBA
Park Lane, Culliganlaan 2B
1831 Diegem, BELGIUM
TEL: + 32 2 714 14 11
FAX: + 32 2 714 14 12

EC REP

Abbott Vascular Netherlands BV
Argonautenweg 1, 6422 PH
Heerlen
The Netherlands
TEL: +31 (0)45-5405700

FLUSHING TOOL

vascular.abbott.com

1440-46-4

NI

109 µg Everolimus
100 µg/cm²

STERILE EO

MD

CE 2797

2024-03-13

™ indicates a trademark of the Abbott group of companies

WPL2130660-11 (2023-10-17)

[redacted]

The Complete Cardiovascular Care

[redacted]

M.D. (Medicine)
DNB (Cardiology)
Ex. Cardiologist : Sal Hospital, Ahmedabad
Ex. Physician : Lions Hospital, Palanpur
Reg. No. G-27764

Date :

PTCA REPORT

NAME : [redacted]

AGE / SEX: 63 Y / M

IPD NO : 2234

CATH NO :UC- 3043

PROCEDURE PTCA : PCI (2 DES) TO OM 1

DATE : 03 / 04 /2026

ROUTE – RIGHT RADIAL ROUTE

DYE : OMNI PAQUE

PTCA : PCI (2 DES) TO OM 1

GUIDE CATHETER : 6F 3.5 EBU

GUIDE WIRE :RUNTHROUGH

PRE - DILATATION : 2.5 *15 MM AT 15 ATM FOR 20 SEC

STENT : : 2.5 *23 MM XIENCE PRIME AT 12 ATM FOR 20 SEC (OVER LAPED)

: 2.5 *28 MM XIENCE PRIME AT 12 ATM FOR 20 SEC

POST DILATATION : 3 .0 * 15 MM PIPIT NC AT 15 ATM FOR 20 SEC .

The Complete Cardiovascular Care

GOOD END RESULT TIMI – 3 FLOW

There is 5%-6% chances of stent thrombosis / re-stenosis in first year and 1%-2% thereafter.

[redacted]

Monday to Saturday : 10-00 am to 6-00 pm

[redacted]

• For Emergency Mo. [redacted]

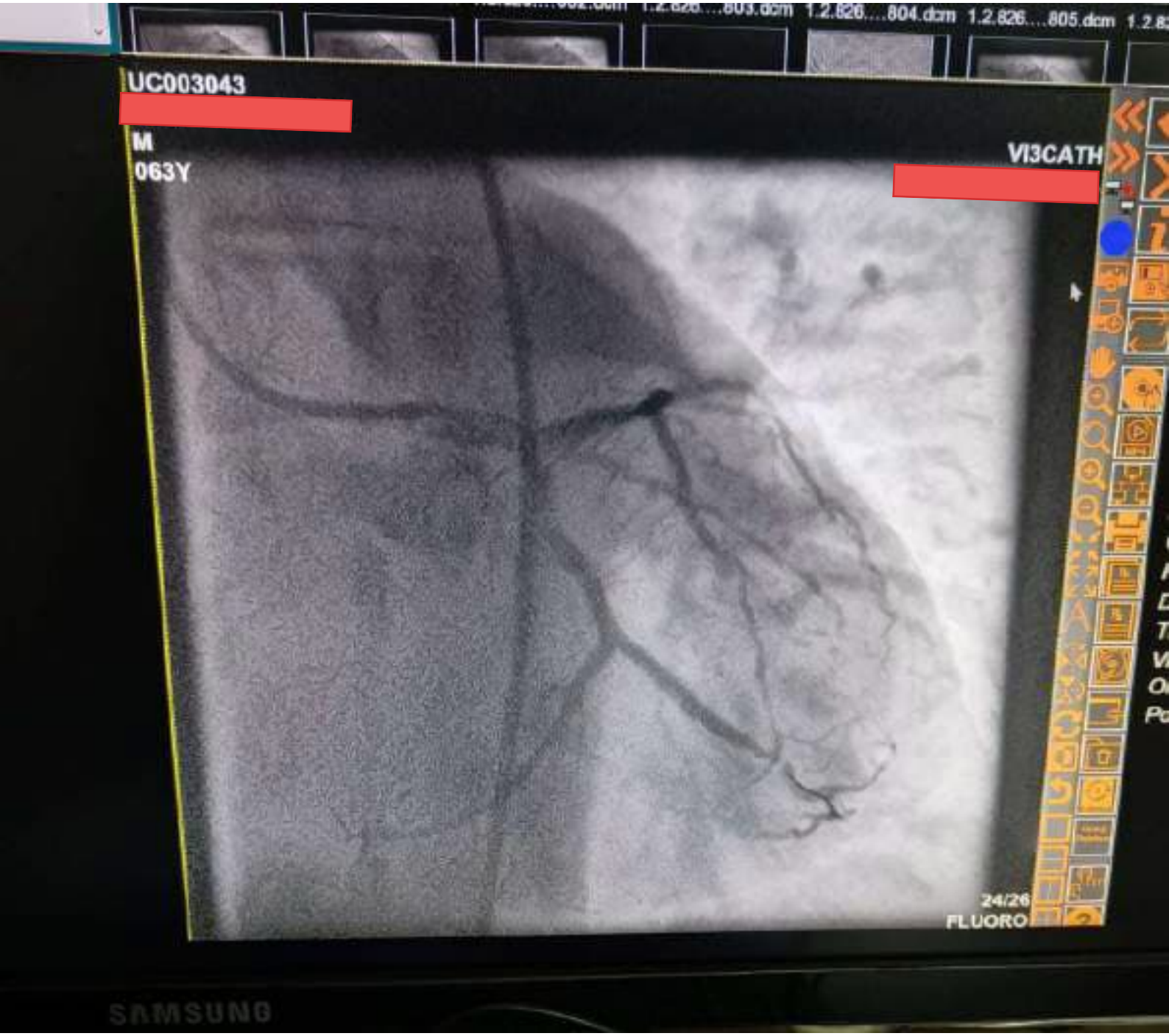
1.2.826....804.dcm
1.2.826....805.dcm
UC003043
M
063Y
VI3CATH
24/26
FLUORO
SAMSUNG

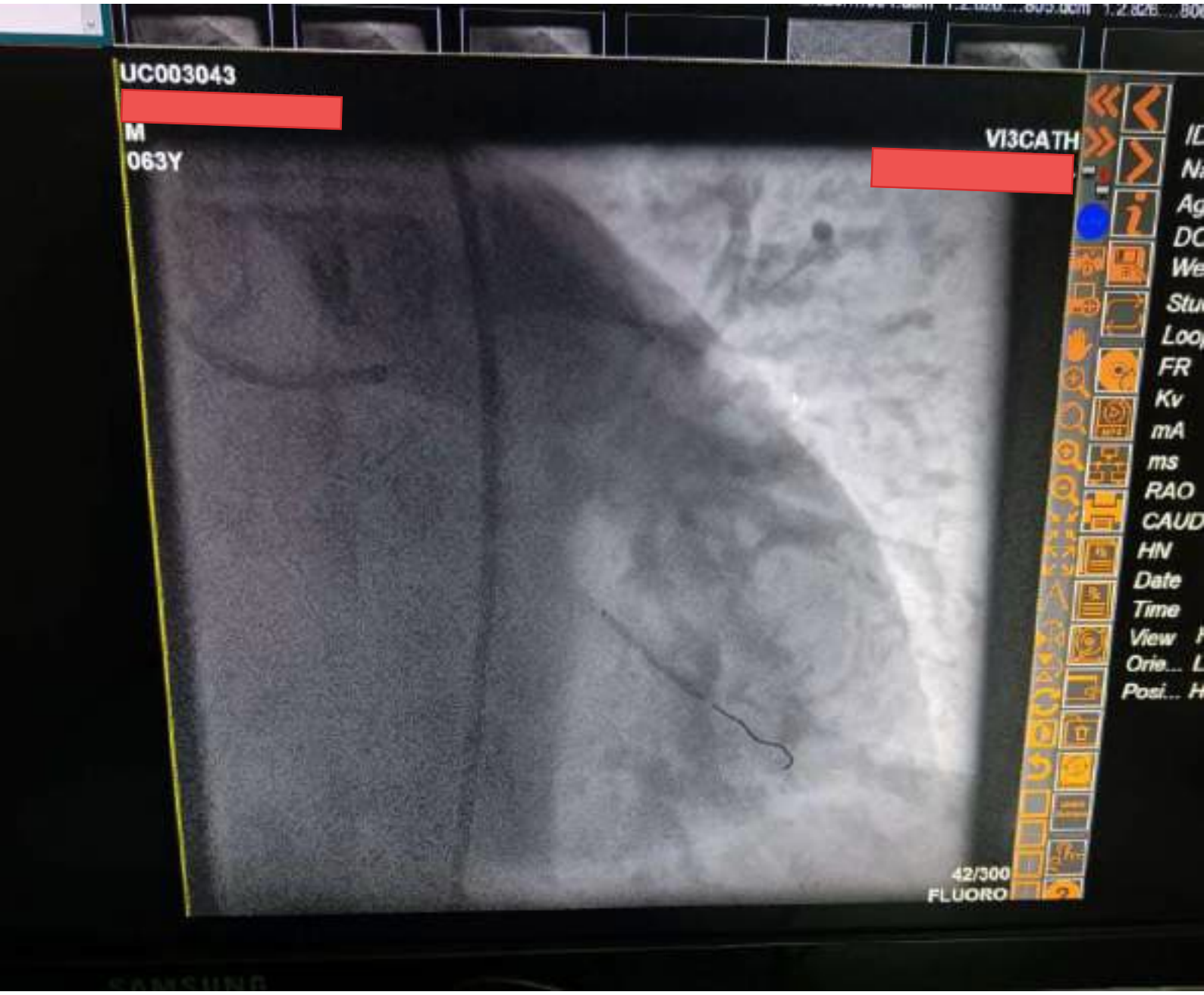
UC003043
[redacted]
M
063Y
VI3CATH
[redacted]
42/300
FLUORO
ID
Na
Ag
DO
We
Stu
Loo
FR
Kv
mA
ms
RAO
CAUD
HN
Date
Time
View
Orie...
Posi...

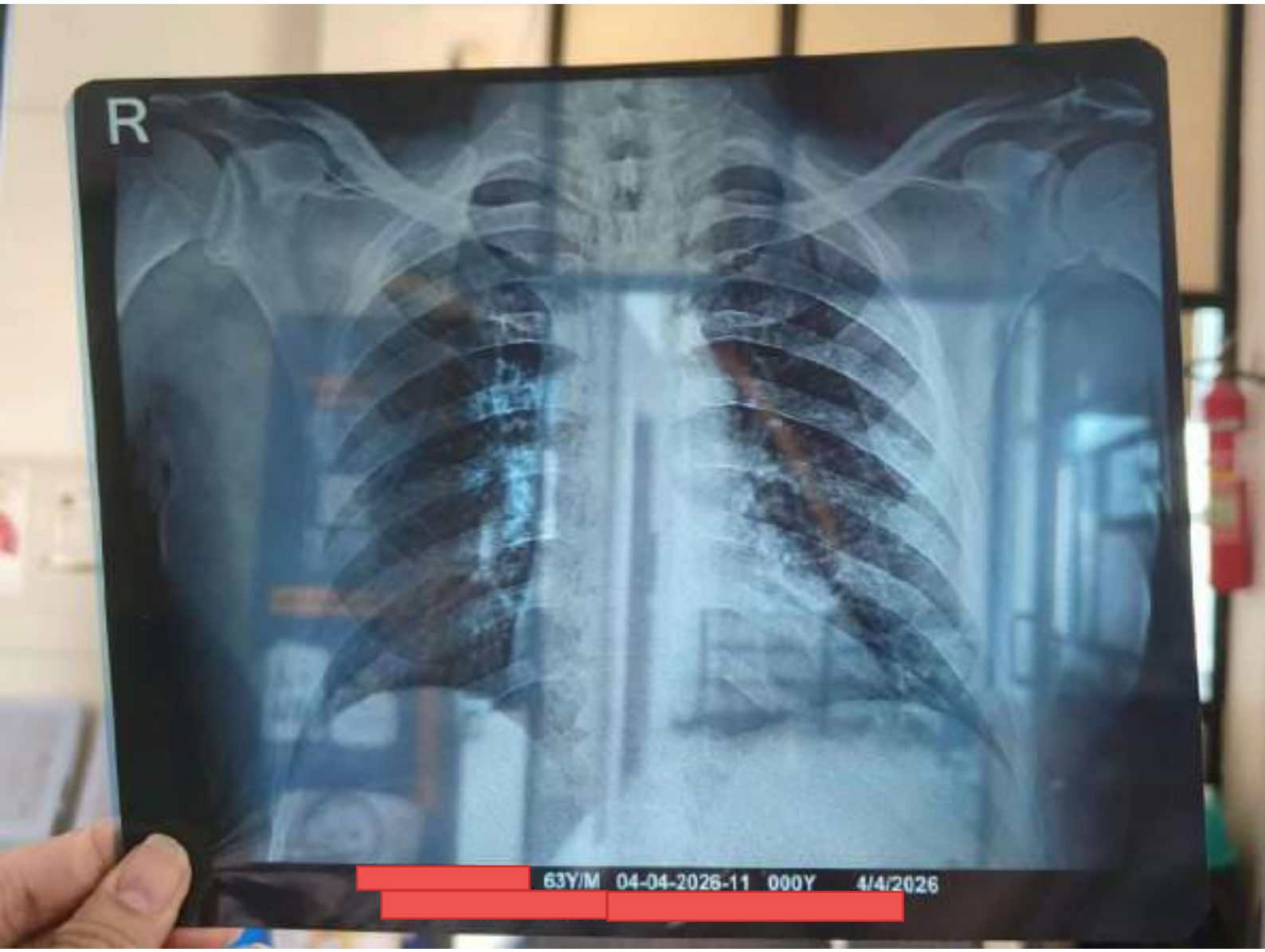
R
[redacted] 63Y/M 04-04-2026-11 000Y 4/4/2026
[redacted]

RX

XIENCE PRIME™

2.5 mm x 23 mm

(01) 0 8717648 12347 4

(17) 270312 (10) 4032141 (91) 5060

	2027-03-12
REF	1011707-23
LOT	4032141

2024-03-13

RX

XIENCE PRIME™

2.5 mm x 28 mm

(01) 0 8717648 12348 1

(17) 261205 (10) 3121441 (91) 5481

	2026-12-05
REF	1011707-28
LOT	3121441

2023-12-06

Monday to Saturday : 10-00 am to

[redacted]

[redacted]

PATIENT NAME: [redacted]
REF BY: [redacted] **MD DNB CARDIO**
DATE: 04/04/2026

X-RAY CHEST A/P VIEW

- No pneumothorax.
- Both lung fields show prominent bronchovascular markings.
- No collapse, consolidation cavity or mass lesion seen.
- No active Koch's lesion seen.
- Cardiac shadow normal.
- Both hila appear normal.
- Both domes normal.
- Both costophrenic angles clear.
- Bony ribs under vision no displaced fracture

SUGGEST: clinical correlation.
Thanks for reference.

[redacted]

M.D. RE[redacted]-17187

[redacted]

[redacted]

M.D.
Consultant Radiologist & Sonologist
Ex. Asst. Professor, Civil Hosp. A'bad

[redacted]

Subject to Palanpur Jurisdiction Only | Not Valid for any Medico Legal Purpose