[redacted]

[redacted]

DEPARTMENT OF CARDIOLOGY

IPD. No. : 07362
Patient Name : [redacted]
Procedure Date : 31/03/2026
Consultant/Operator : [redacted]

UHID NO: 35549
Age/Sex: 47Y/M

CATH ID: 1916

CORONARY ANGIOPLASTY REPORT

Hemodynamic Status :
Pressure : 140/70mm of Hg
Approach : Right Radial Approach

HR : 64 bpm

SPO_2 : 99%

Diagnosis : CAD-ACS-IWMI, MODERATE LV DYSFUNCTION
CAG-SVD

Lesion : LCX mid 90% stenosis.

Hardware Used:
Guiding Catheter; 6F EBU 3.5
PTCA wire: Fielder FC
Balloon : Zee Pro SC 2.50x10mm & Zee Pro NC 3.0x10mm
stent: Racer CC Plus 3.0x21mm

translumina
Racer CC PLUS
REF RRPP 3021
LOT RPAGG121124
SN RPAGG12713
Mfg. dt 2024-11
Use by 2027-10
∅ 3.00 mm
21 mm

Procedure: Adhoc PTCA to LCX
Left main Coronary artery engaged with 6F- EBU 3.5 guiding catheter. Lesion crossed with Fielder FC Wire. lesion was pre dilated with Zee Pro SC 2.50x10mm balloon at 12atms pressure. Lesion was stented with Racer CC Plus 3.0x21mm stent at 10atms pressure. Stent was Post dilated with Zee Pro NC 3.0x10mm Balloons at 14 atms pressure. Good end result with TIMI III flow achieved.

CONCLUSION : Successful Adhoc PTCA to LCX done with 1DES.

Important note:-
1. Never stop medicines without written advice of doctor.
2. Consult doctor if chest pain/ Breathing difficulty/any other symptoms.
3. Do regular follow up.
4. Stents carry an inherent 5 % risk of restenosis.

[redacted]

MD(PULMED), DrNB(Cardiology)
Consultant Interventional Cardiologist

[redacted]

[redacted]

[redacted]

Patient is our Priority

[redacted]

IPD. No.
Patient Name : [redacted]
Procedure Date : 31/03/2026
Consultant/Operator : DR. [redacted]

UHID NO: 35549
Age/Sex: 47Y/M

CATH ID: 1916

CORONARY ANGIOGRAM

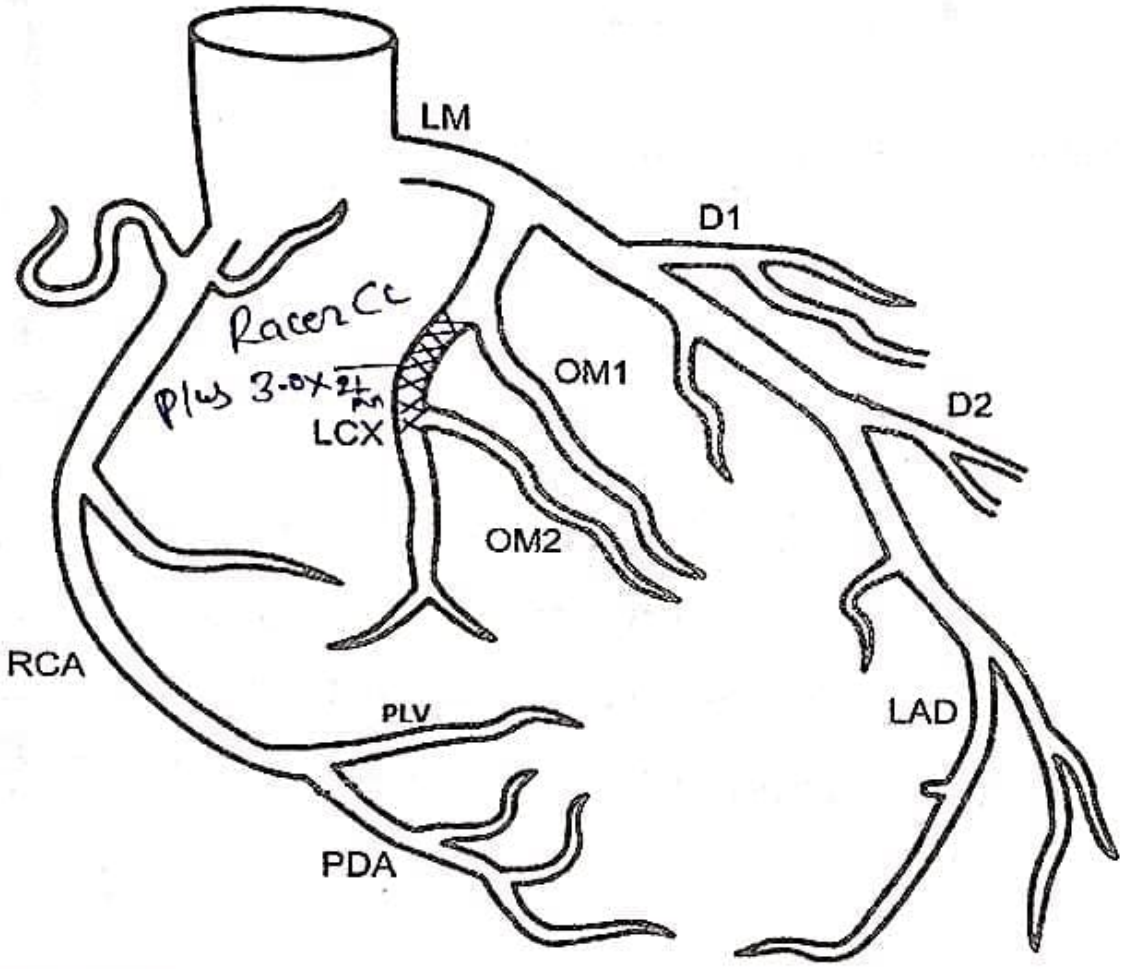

CONCLUSION : Successful Adhoc PTCA to LCX done with 1DES.

[redacted]

[redacted]

MD(PUL.MED), DrNB(Cardiology)
Consultant Interventional Cardiologist

[redacted]

Patient is our Priority

OPERATION NOTE

IPD. No.	: 07362	UHID NO: 35549
Patient Name	: [redacted]	Age/Sex: 47Y/M
Procedure Date	: 31/03/2026	
Consultant/Operator	: DR. [redacted]	CATH ID: 1916

Aortic Pressure : 140/70 mmHg Route/Access: R-R

OT Time : 7:30PM to 9:05PM

LESION:- LCX-Mid 90% Stenosis.

Hardware Used: EBU 3-5-6F

PTCA WIRE :- Fielder FC

PRE DILATION:- Zee Pro SC 2.50 X 10 mm

STENT:- Racer CC Plus 3.0 X 21mm

POST DILATION: Zee Pro NC - 3.0 X 10 mm

CONCLUSION: Successful Adhoc PTCA To LCX Done ELDES. TIMI III flow achieved

ADVICE: Medical Management.

[redacted]

[redacted]

MD(PUL MED), DrNB(Cardiology)
Consultant Interventional Cardiologist