[redacted]
+91 [redacted]
+91 [redacted]
[redacted]

DEPARTMENT OF CARDIOLOGY

IPD. No.	: 07362	UHID NO: 35549
Patient Name	: [redacted]	Age/Sex: 47Y/M
Procedure Date	: 31/03/2026	
Consultant/Operator	: [redacted]	CATH ID: 1915

CORONARY ANGIOGRAPHY REPORT

Hemodynamic Status :

Pressure : 140/70mm of Hg HR : 64 bpm SPo_2 : 99%

Approach : Right Radial Approach

LMCA : Normal.

LAD : Type III vessel, mid myocardial bridge +.
Diagonal are normal.

LCX : Dominant, mid 90% stenosis (lesion length= 3.0x21mm).
Oms are normal.
LPDA & LPLV are normal.

RCA : Non-Dominant, normal.

CONCLUSION : **CAD-ACS-IWMI, MODERATE LV DYSFUNCTION**
CAG-SVD

ADVISE : **ADHOC PTCA TO LCX WITH 1DES.**

[redacted]

[redacted]
MD(PULMED), DrNB(Cardiology)
Consultant Interventional Cardiologist

[redacted]

[redacted]

IPD. No. : 07362
Patient Name : [redacted]
Procedure Date : 31/03/2026
Consultant/Operator : [redacted]

UHID NO: 35549
Age/Sex: 47Y/M

CATH ID: 1915

CORONARY ANGIOGRAM

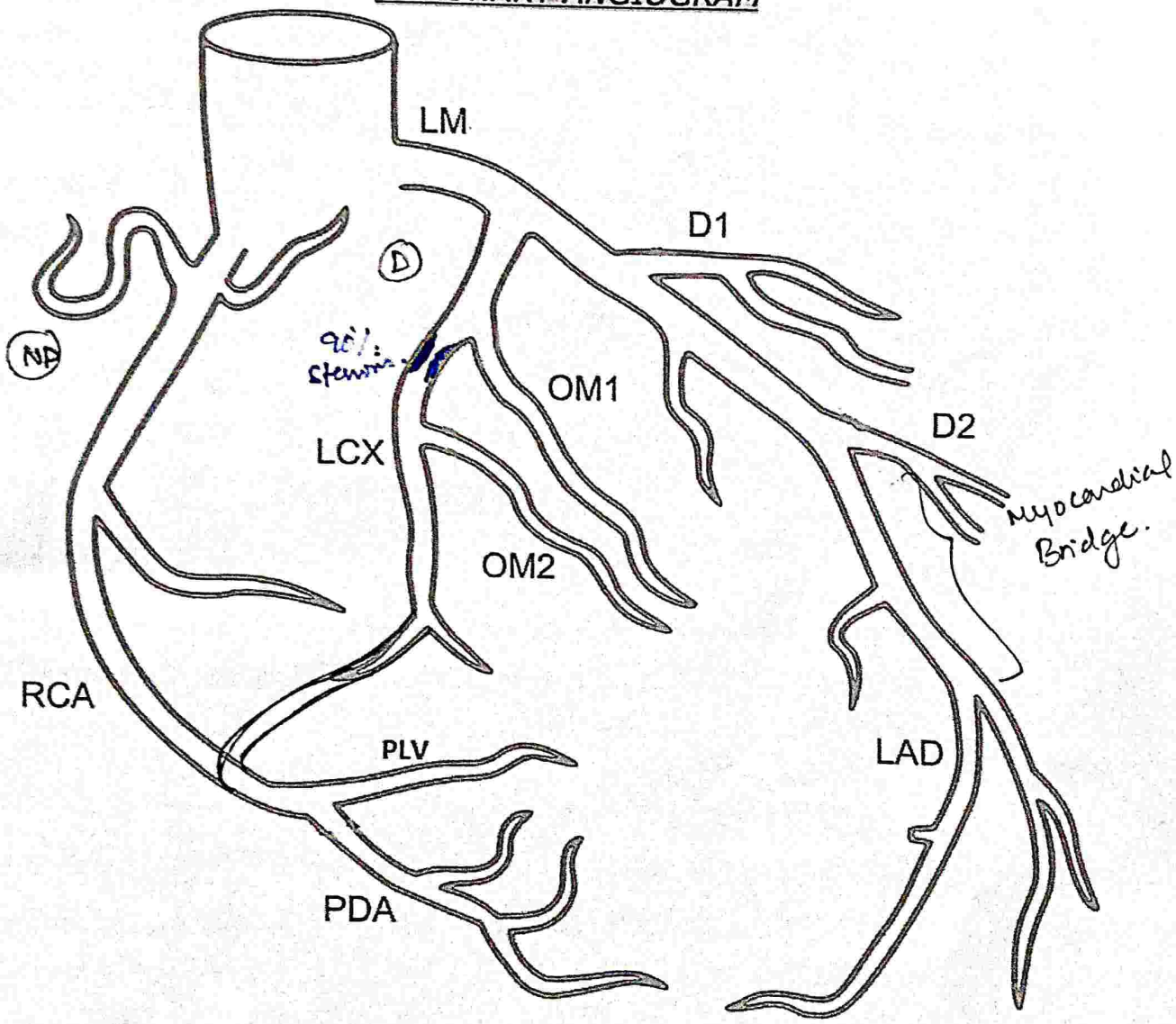

CONCLUSION: SVD

ADVICE: PTCA TO LCx.

[redacted]

MD(PU
Consultant [redacted]

[redacted]

Patient is our Priority

OPERATION NOTE

IPD. No.	: 07362	UHID NO: 35549
Patient Name	: [redacted]	Age/Sex: 47Y/M
Procedure Date	: 31/03/2026	
Consultant/Operator	: [redacted]	CATH ID: 1915

Aortic Pressure : 140/70 mmHg Route/Access: R-R

Catheter Used: Tig. SF

CINE CORONARY STATUS

Dominance:- Left

LMCA: Normal

LAD: Type III Vessel, Normal.

D1: (N) D2: (N)

LCX: Dominant, Mid 90% Stenosis.

OM1: (N) OM2: (N)

RCA: Non-Dominant, Normal

Left PDA: (N) Left PLV: (N)

CONCLUSION: CAD-ACS-IWMI, Moderate LV Dysfunction.
CAU- SVD

ADVICE: Adhoc PTCA to LCX with 1 DES.

[redacted]

[redacted]

MD(PUL. MED), DrNB(Cardiology)
Consultant Interventional Cardiologist