PCI REPORT

Name	:	**Age**	: 74 years
Sex	: Male	**Date**	: 03/04/2026
Ref By	:		

PTCA to RCA (OT Notes)

Procedure done under local anesthesia
Total Heparin used: 6000 U

Route: Rt Femoral

JR was cannulated with 6F JR 3.5 guiding catheter and diagnostic shoots taken in various views showed RCA lesion.

1) The Lesion was crossed with Rinato wire and predilatation done with 2.5X12 mm predilatation ballon at 18atms for 20 secs

2) Supra Explorer 3.0X48 mm stent (DES) was then deployed in Mid RCA at 16 atms for 30 secs and check shoots repeated .

3) Overlapping Supra Explorer 3.5X20 mm stent (DES) was then deployed at 16 atms for 20 secs

4) Post dilatation was done with 3.5 x 12 mm N.C. balloon at 20 atms for 10 secs

5) There was no dissection. An adequate deployed stent with distal TIMI III flow was seen.

No peri-procedural complications

Sahajanand Medical Technologies Limited
SUPRA EXPLORER
3.00 mm x 48 mm
REF FGTX300048
SN (21)P25TXAEGS300048085
LOT (10)P25TXAEGAB
B (17)2027-04

Sahajanand Medical Technologies Limited
SUPRA EXPLORER
3.50 mm x 20 mm
REF FGTX350020
SN (21)S25TXAYOS350020081
LOT (10)S25TXAYOAB
B (17)2027-09

Scanned with OKEN Scanner

Scanned with OKEN Scanner

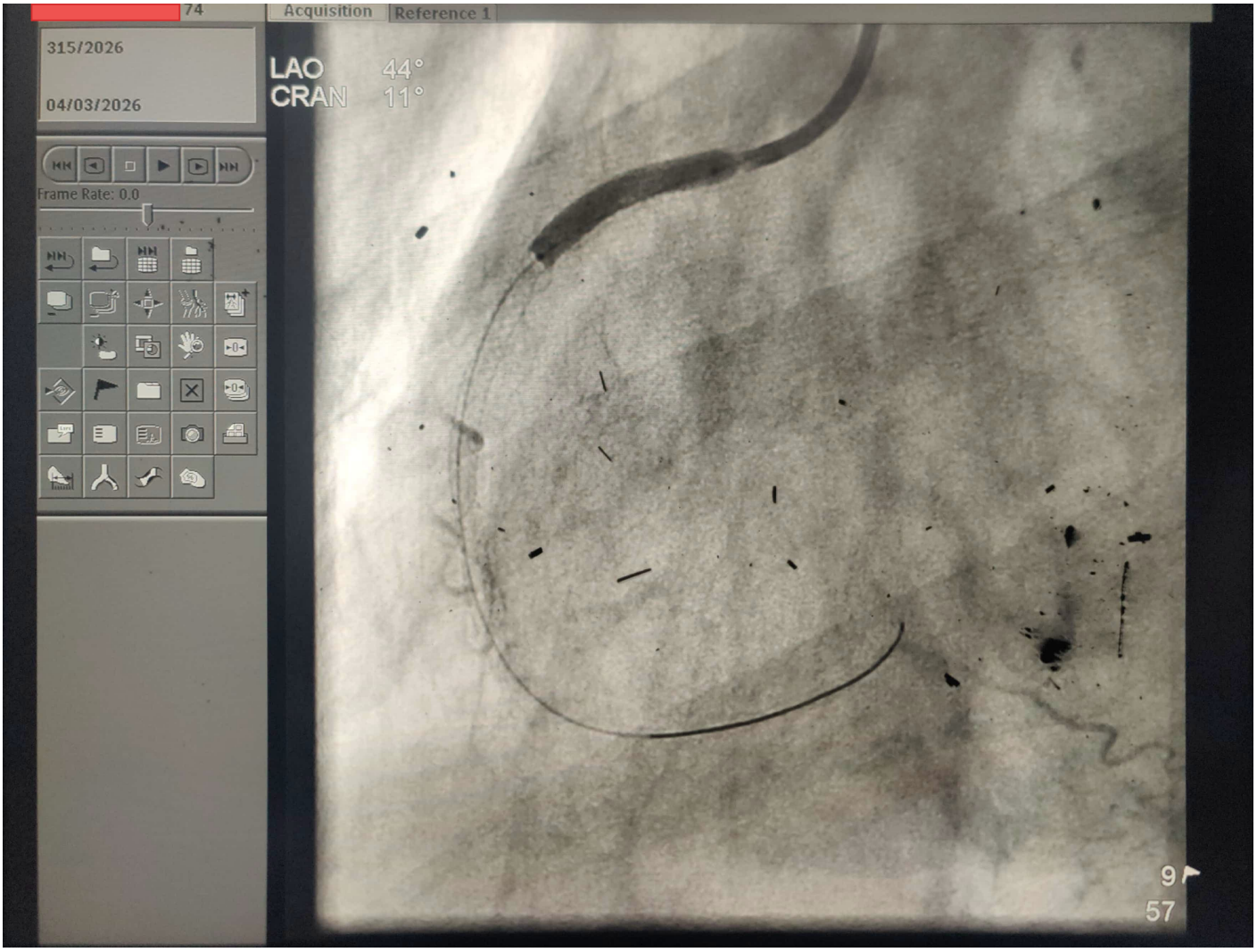

Scanned with OKEN Scanner