[redacted]

CORONARY ANGIOGRAPHY REPORT

Patient Name	: [redacted]	Age/Sex	: 75Yrs / M
Cath ID No.	: SSVH/268/26	Pt. Reg. No.	: D-37/2026
Ref. Dr.	: [redacted]	Date	: 01/04/2026

LCA	RCA
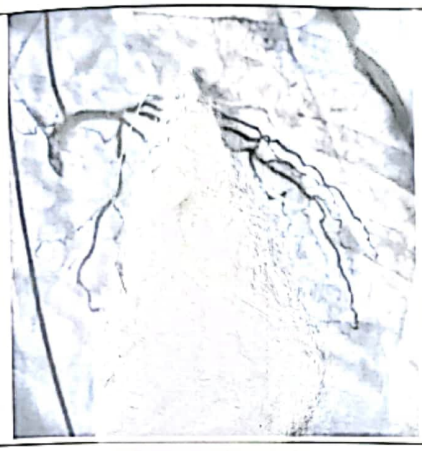	

HISTORY	:	Chest Pain.
LMCA	:	Normal.
LAD	:	Osteoproximal 50% stenosis.
DIAGONAL	:	Small caliber, but long vessel.
RI	:	Mid segment has 50% stenosis in small caliber long vessel.
LCx	:	Non-Dominant & Normal.
OM	:	Normal.
RCA	:	Dominant & has long segment 85-90% stenosis involving proximal to mid segments. Rest normal.
PDA / PLV	:	Normal.
IMPRESSION	:	Critical stenosis of RCA.
ADVICE	:	PTCA + Stents (2) in RCA.

[redacted]

[redacted]

DNB (Medicine), DNB (Cardiology)

[redacted]

[redacted]

Scanned with OKEN Scanner

Scanned with OKEN Scanner