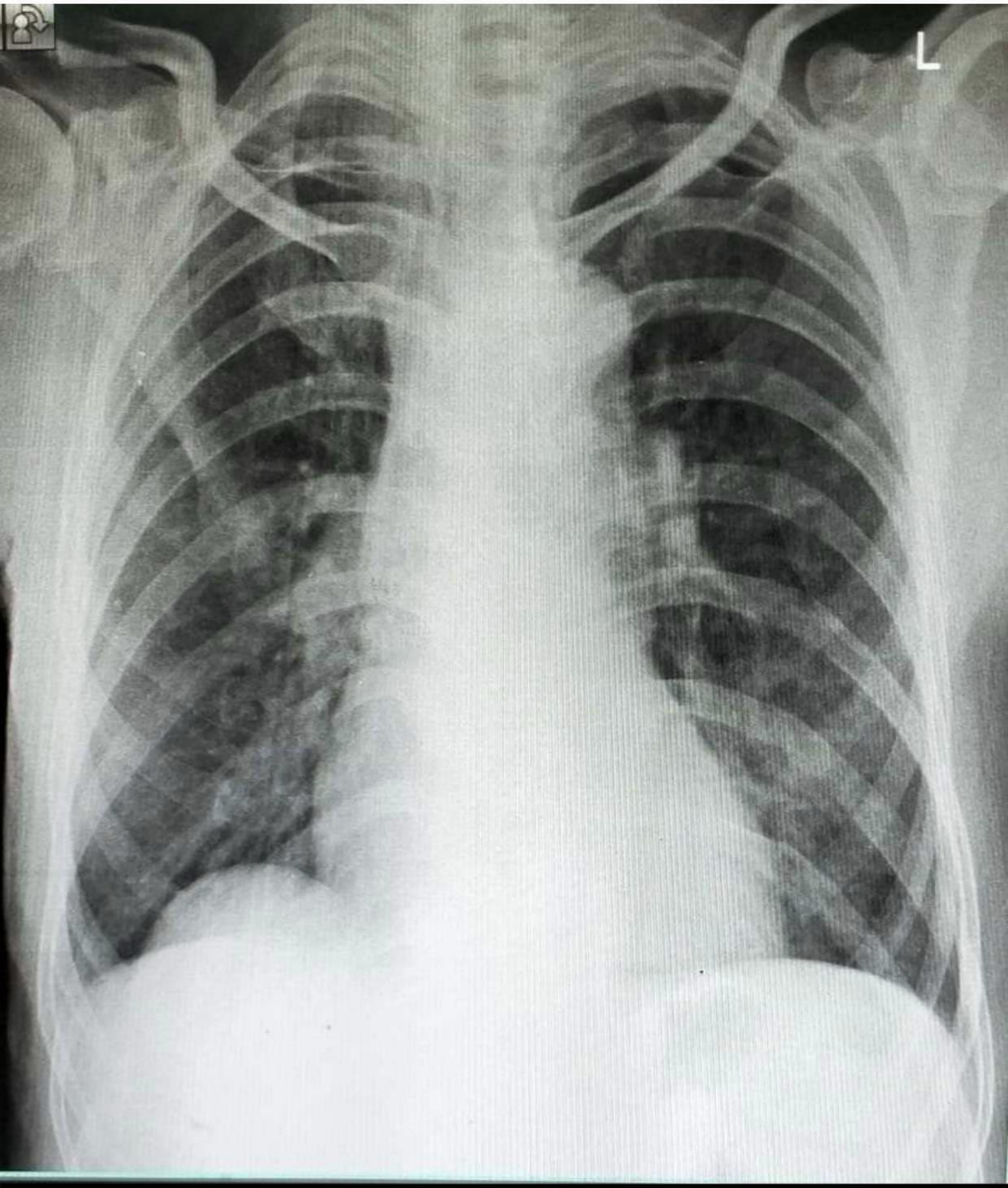

PT NAME - [redacted] AGE/SEX - 58Y/F CHEST PA DATE - 24/03/2026

Patient Name:	[redacted]	Referring Physician:	
Age / Sex:	58Y/F	Study Date:	24/03/2026

DIGITAL RADIOGRAPH CHEST PA VIEW

Report:

Bilateral hila are prominent -likely nodal/vascular.

Prominent of broncho-vascular marking and hila-bronchitis.

Both domes of diaphragm and CP angles are normal.

No evidence of mediastinal shift is seen.

Cardiac size is normal.

Bony cage appear normal.

soft tissue appear normal.

Ad- clinical correlation further evaluation.

[redacted]

M.D. Radiodiagnosis
Reg. No.- 39917

The science of radiology is based upon interpretation of shadows of normal and abnormal tissue. This is neither complete nor accurate; hence, findings should always be interpreted in to the light of clinico-pathological correlation. This is a professional opinion, not a diagnosis. Not meant for medico legal purposes.