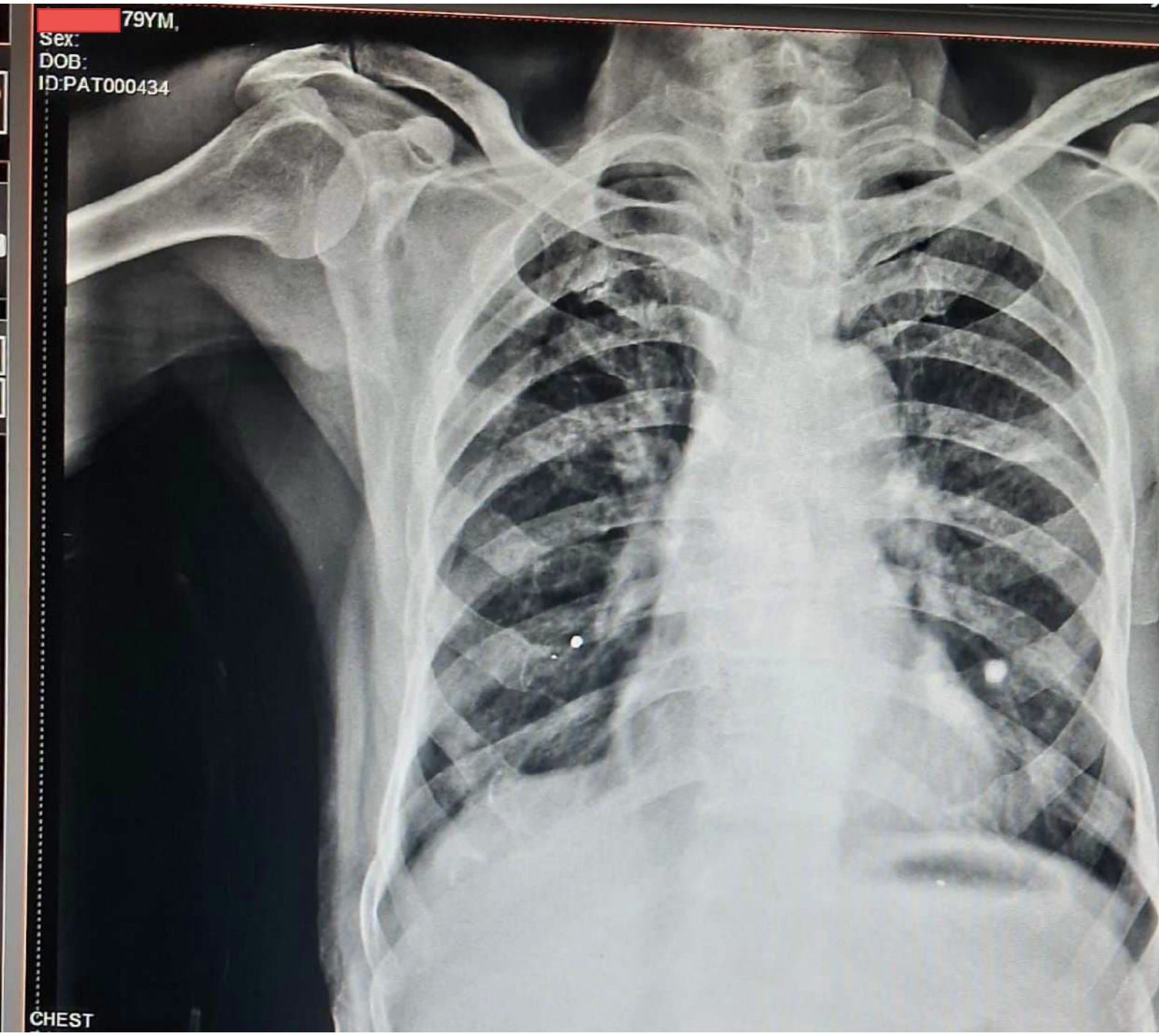
[redacted] 79YM,
Sex:
DOB:
ID:PAT000434
CHEST

[redacted]

X-RAY CHEST (PA VIEW)

Patient name:- [redacted] Age:- 79y

Date:- 27/03/2026 Sex:- male

Findings:-

- **Bilateral lung fields shows increase in vascular markings with patchy opacities seen in right upper lobe.**
- **Bilateral lung appear hyperinflated.**
- **Trachea slightly shifted towards left**
- Cardiac size are within normal limits.
- Mediastinum contours appears maintained and right side diaphragm appears slightly elevated.

Impression:-

- Above features suggestive of bronchitis likely allergic/infective ?copd

Clinical correlation suggested

[redacted]

Signature

TIMING: 8.00 AM TO 8.00 PM FOR HOME COLLECTION-DIAL Mob.: 9795819823, 8604505116

24 घण्टे अल्ट्रासाउण्ड सुविधा उपलब्ध

[redacted]

सुविधाये : सभी प्रकार के पैथोलॉजिकल जाँचे ● हॉरमोन्स ● ग्लाइकोसाइलेटेड हीमोग्लोबिन (Hb 1c) ● स्पेशल टेस्ट

Clinical correlation is essential for final diagnosis, in case of disparity test must be repeated. this report is not valid for medicalegal purpose.