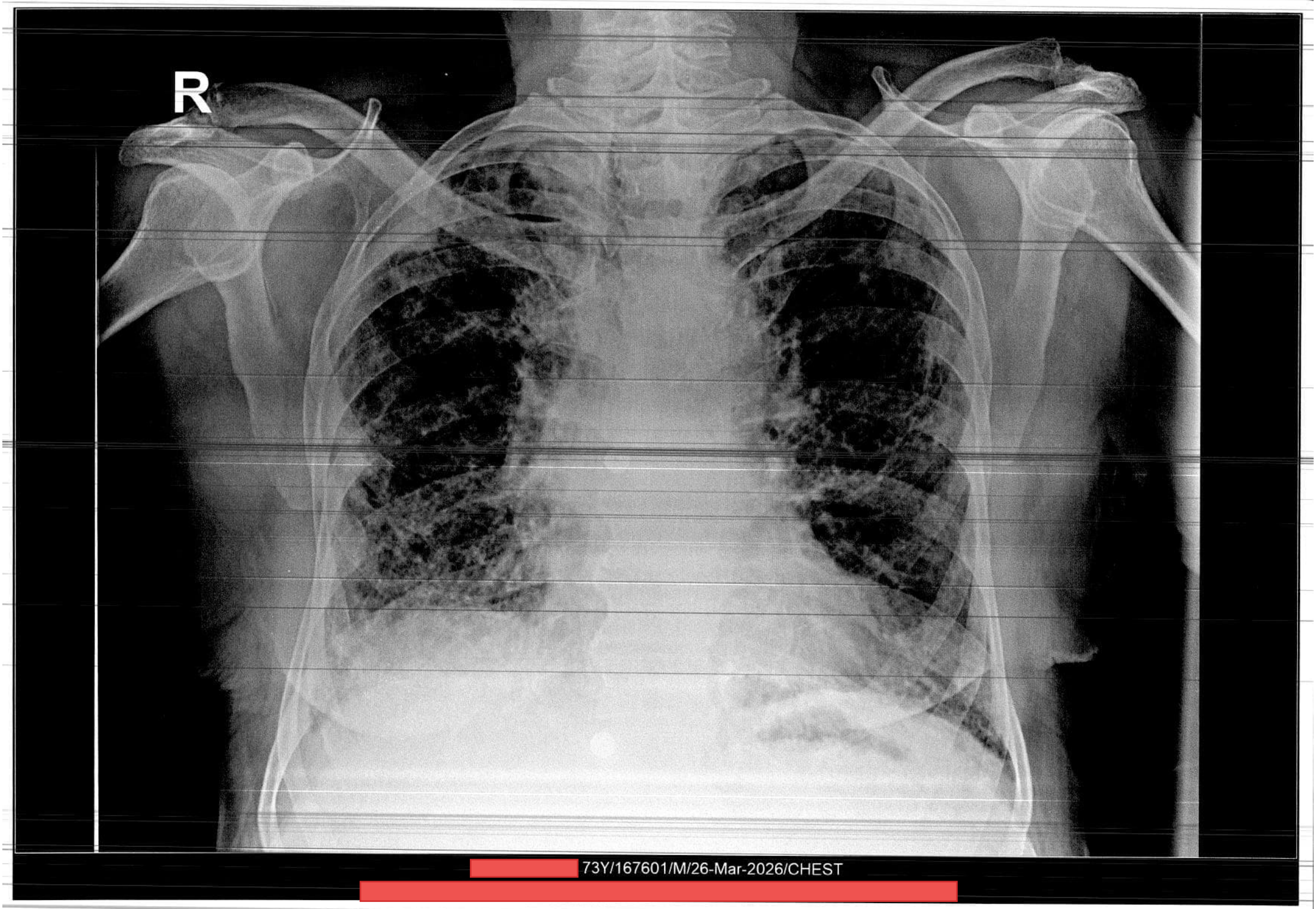
R
[redacted] 73Y/167601/M/26-Mar-2026/CHEST
[redacted]

Reg. No.

Patient Name :

Age/Sex :72Y/M

Date :26/03/2026

Patient UHID : 177601

X Ray CHEST PA VIEW

REPORT

Trachea is central.

Cardiac size appears within normal limits.

Bilateral lung fields show patchy air-space opacities, more prominent in the lower zones, especially on the left side.

Costophrenic angles appear clear.

No obvious pneumothorax seen.

Visualized bony thorax appears intact.

Impression: B/L Pnemonitis.
Advised -clinical correlation.

Radiologist: