Department of Radiology & Imaging

NAME : [redacted]
PATIENT ID : 010611714
ORDER NO. : 506311
REFERRED BY: [redacted]

AGE : 37 Years
SEX : F
DATE : 18-Feb-2026

ABDOMINAL AND PELVIS SONOGRAPHY

B-mode real time USG done.

Liver is normal in size and shape and show normal homogenous echopattern.

No intrahepatic focal or diffuse lesion seen.

Gall bladder is minimally distended with multiple calculi within (8-10) largest measures 14-15 mm.

C.B.D. and portal vein are of normal calibre.

(Rt) kidney measures 9.0 x 3.7 cm. (Lt) kidney measures 10.9 x 4.4 cm.

Both kidneys show normal cortical echogenicity.

No calculus, hydronephrosis or S.O.L. seen on either side.

Spleen, Pancreas and major abdominal vessles are normal.

No ascites, adenopathy or collection seen. Urinary bladder is normal.

Uterus is normal in size, shape and show normal midline endometrial echo.

Both ovaries are normal. No adnexal mass. No free fluid in P.O.D.

Bowel loops appear normal.

OPINION: GALL BLADDER IS MINIMALLY DISTENDED WITH MULTIPLE CALCULI WITHIN (8-10) LARGEST MEASURES 14-15 MM.

SUGGESTED : CLINICAL CORRELATION.

[redacted]

Dr. [redacted]
MBBS, DNB (Radiology)
Reg. [redacted]
FMF UK Certified
FMF ID 316532
Consultant Radiologist

[redacted]

[redacted]

Department of Radiology & Imaging

Patient ID 010611714
Referred By GS Unit 3 - [redacted]

Patient Name [redacted]
Age/Sex 37 Years/F

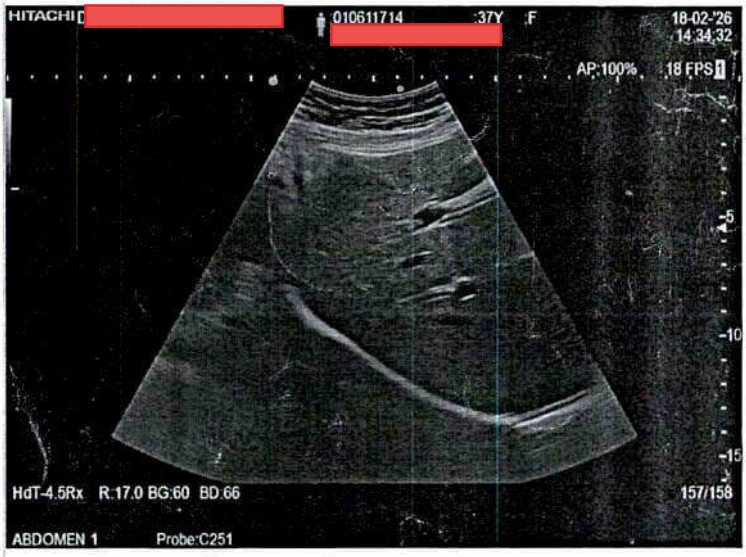

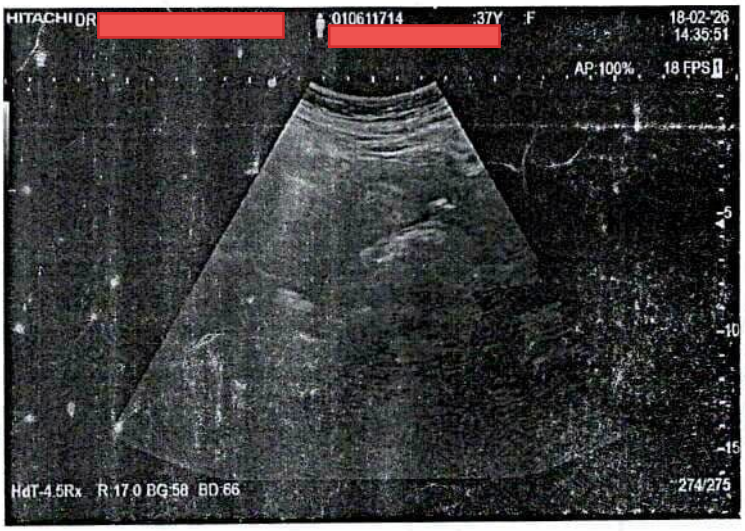

Department of Radiology & Imaging

Patient ID 010611714
Referred By GS Unit 3 - [redacted]
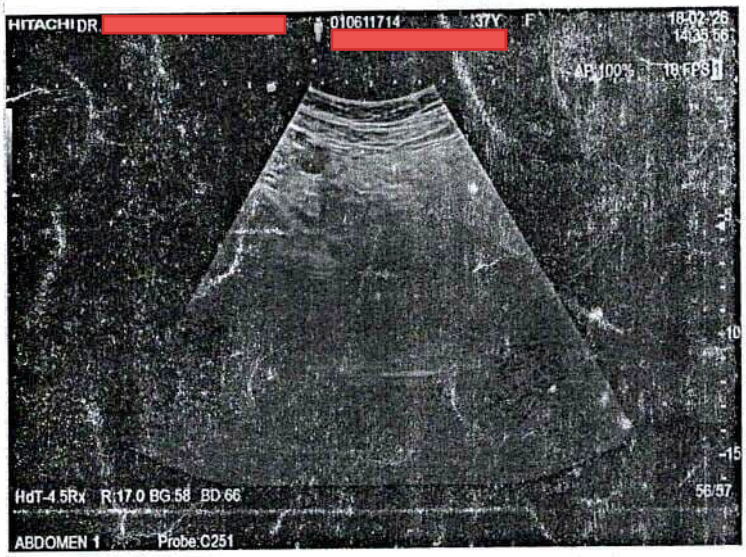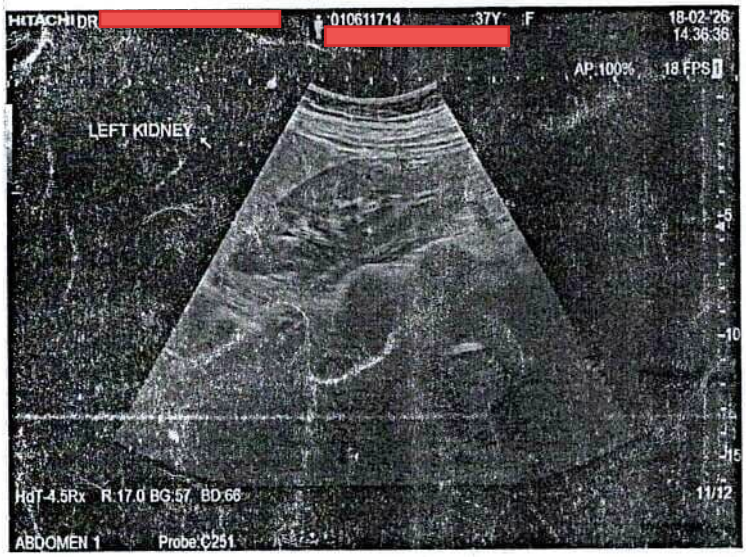
Patient Name [redacted]
Age/Sex 37 Years/F