[redacted] Hospital Reg. No.-[redacted] [redacted] Ph.:[redacted]

[redacted]

[redacted]

PT'S NAME: [redacted] **AGE/SEX:71Y/F**

REF BY Dr. [redacted] **DATE:11/03/2026**

LIVER: Liver is normal in size & Parenchymal echotexture homogenous.
Intrahepatic billiary radicals are not dilated.
No mass lesion seen.

G.B: A calculus size 16.5mm seen in the lumen of GB with acoustic shadowing.
Wall thickened 3.2mm. No mass lesion seen

CBD: Normal in caliber.

PANCREAS: No calcification, no mass lesion seen. MPD not dilated

SPLEEN: Normal in size with normal echotexture.

RT.KIDNEY: Size & echotexture normal.
No calculus, no mass lesion seen.
RT ureter is not dilated.

LT.KIDNEY: Size & echotexture normal.
No calculus, no mass lesion seen.
LT Ureter is not dilated.

U.B.: Normal wall. No calculus. No mass seen.

UTERUS: Atrophied.
Both ovaries are not visualized.

OPINION: CHOLECYSTITIS WITH CHOLELETHIASIS.

[redacted]

(S[redacted]IST)

[redacted]

अत्याधुनिक मशीनों द्वारा उपलब्ध सुविधाएं :

Pathology, Ultrasound, Digital X-Ray, Electrolyte & All Special Test

Timing : 8:30 am. to 7:30 pm.

[redacted]

Not for Medicolegal Purpose

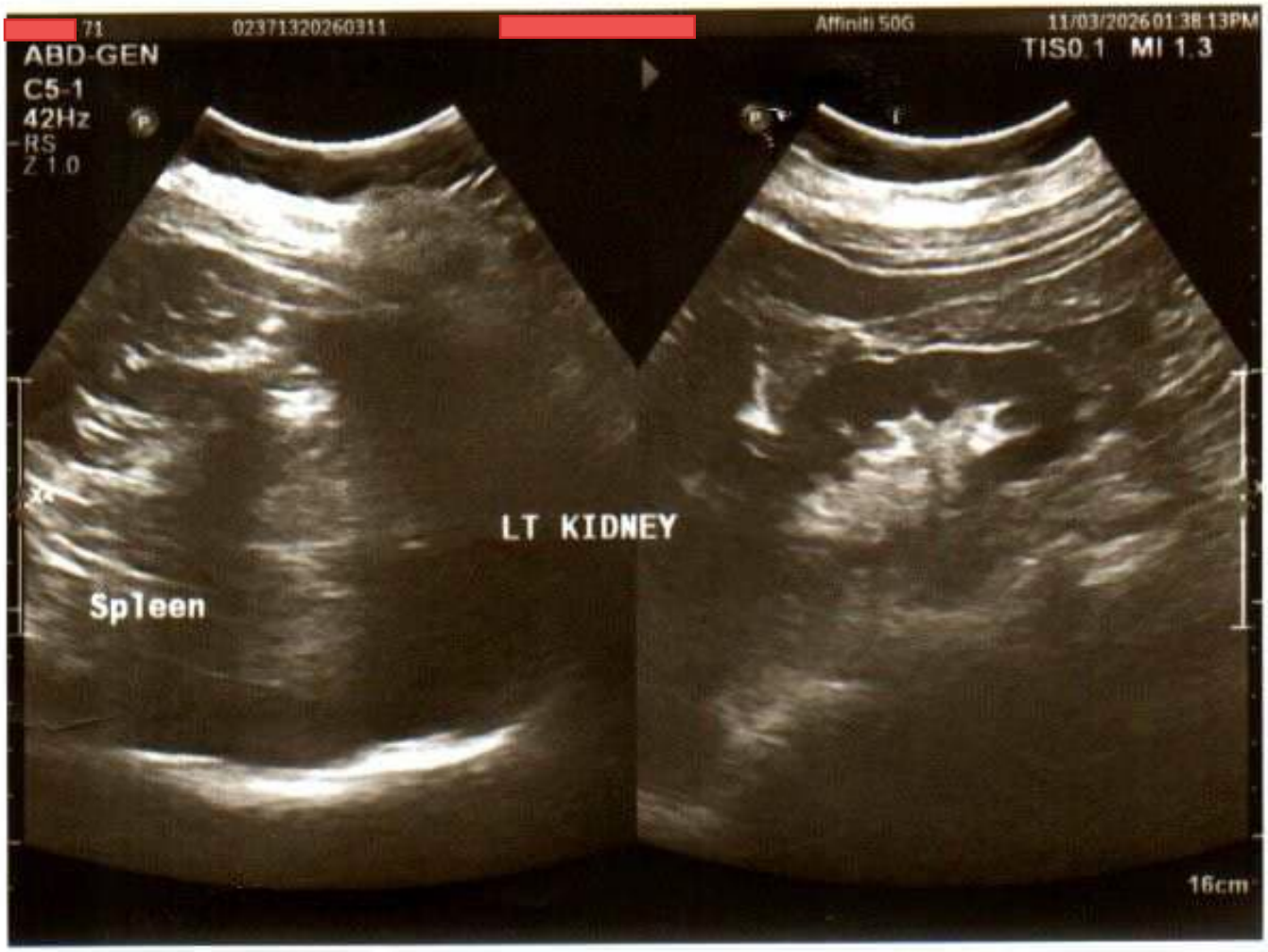
71
02371320260311
Affiniti 50G
11/03/2026 01:38:13PM
ABD-GEN
C5-1
42Hz
RS
Z 1.0
TIS0.1 MI 1.3
LT KIDNEY
Spleen
16cm

71
02371320260311
Affiniti 50G
11/03/2026 01:38:04PM
ABD-GEN
C5-1
42Hz
RS
Z 1.0
TIS0.1 MI 1.3
RT KIDNEY
CBD
16cm

71
02371320260311
Affiniti 50G
11/03/2026 01:37:54PM
TIS0.1 MI 1.3
ABD-GEN
C5-1
42Hz
RS
Z 1.0
X4
Pancreas
GB CAL
Dist 1.65 cm
16cm

71
02371320260311
Affiniti 50G
11/03/2026 01:37:34PM
TIS0.1 MI 1.3
ABD-GEN
C5-1
42Hz
RS
Z 1.0
X4
UTERUS
Liver
16cm