ECUBE
19.03.2026 01:41:16 PM
Abdomen
2D HAR
100%
Frq 4.4
Gn 33
DR 74
FR 50
16.0
Rt Kidney
Lt Kidney

ECUBE
19.03.2026 01:40:46 PM
20260319_133757
Admin
C1-6CT
MI 1.20
TIS 0.2

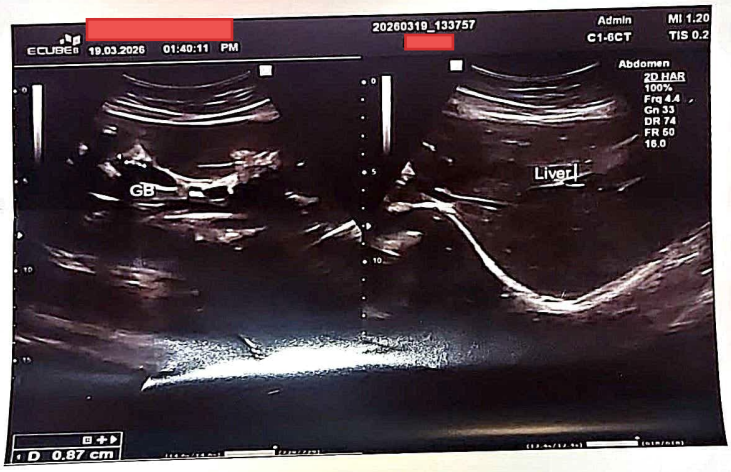
ECUBE
19.03.2026 01:40:11 PM
20260319_133757
Admin
C1-6CT
MI 1.20
TIS 0.2
Abdomen
2D HAR
100%
Frq 4.4
Gn 33
DR 74
FR 50
16.0
GB
Liver
D 0.87 cm

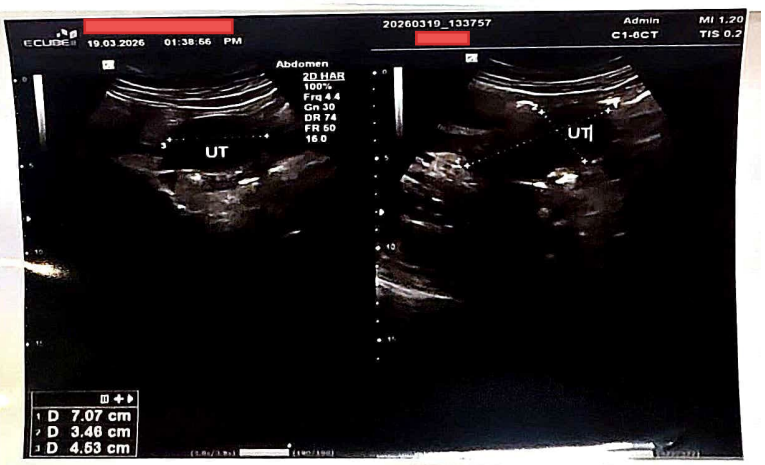
ECUBE
19.03.2026 01:38:56 PM
20260319_133757
Admin
C1-6CT
MI 1.20
TIS 0.2
Abdomen
2D HAR
100%
Frq 4.4
Gn 30
DR 74
FR 50
16.0
UT
UT
D 7.07 cm
D 3.46 cm
D 4.53 cm

Reg. No. :

Date :_____

Patient Name: **Age/Sex:-29Y/F**

Ref by: - Dr. **Date:- 19/03/2026**

FEMALE ULTRASONOGRAPHY REPORT

Liver: Normal in shape, size and normal echo pattern.
IHBR not dilated Portal vein not dilated. No mass / cyst seen.

Gall bladder: Normal in shape, size. Wall thickness appears normal.
Peri-cholecystic area appears normal. **Multiple hard echodence shadow largest one (approx 8.7mm) seen in lumen & neck.**

CBD: Not dilated.

Spleen: Normal in shape size and echo pattern. No mass / cyst seen.
Splenic vessels not dilated.

Pancreas: Normal in shape and echo pattern. No mass / cyst seen.
Pancreatic ducts not dilated.

RT. Kidney : Normal in shape & size and location.
Corticomedullary differentiation is well distinct. Calyces not dilated.
No hydronephrosis or renal calculus seen in both the kidneys.

LT. Kidney : Normal in shape & size and location.
Corticomedullary differentiation is well distinct. Calyces not dilated.
No hydronephrosis or renal calculus seen in both the kidneys.

U. Bladder: **Is partially filled.**

Uterus: Normal in **size (70x34x45mm)** Echo texture of myometrium is homogenous.
Cavity empty. Endometrial thickness appears normal.

Ovaries: Normal.
Adenexas: Normal.
POD: No free fluid seen.
Lymph nodes: Not seen.
Ascetic Fluid: No free fluid seen inside the peritoneal cavity.
Others: Excessive gas filled bowel loops seen in all over abdomen.

INFERENCE: **Cholelithiasis.**

USG has its own limitations, please correlate clinically
Not for medico-legal use

Mob.
E-mail :