[redacted]

[redacted]

SCAN & LAB PVT. LTD.

Name:Mrs[redacted]	Registered ON :10-03-2026 09:00:43	Ref By :Dr.[redacted]
Age :24Years	Reg No :133375	Ref. Lab/Hosp:
Sex :Female	LAB No :[redacted]	Sample Type :

USG WHOLE ABDOMEN

Liver is normal in size, shape & echotexture. Intra hepatic biliary radicals are not dilated and biliary confluence is patent. No focal or diffuse lesion seen. IVC and hepatic veins are normal. Portal vein is normal in size.

Gall bladder is distended showing a calculus of size 6.6 mm is seen in GB lumen. Wall thickness is normal. No pericholecystic collection seen. CBD is normal in diameter. Lumen is anechoic.

Pancreas is normal in size. Margins are regular. Parenchyma shows normal echotexture. Pancreatic duct is not dilated. No focal area of altered echogenicity or calcification is seen.

Spleen is normal in size, shape and echotexture. No focal or diffuse mass lesion seen. No collaterals are seen.

Kidneys are normal in size, shape and echotexture. Corticomedullary differentiation is maintained. Pelvicalyceal system is not dilated. No obvious calculus or mass lesion seen. Ureters are not dilated.

Urinary Bladder is distended. Wall thickness is normal. No calculus or mass seen.

Uterus is normal in size, shape and echotexture. No obvious focal lesion seen. Endometrial thickness is normal. Cervix appears normal.
Adnexa: Both ovaries are normal in size, shape and echotexture. No obvious mass lesion seen.

There is no free fluid in peritoneal cavity.
There is no significant retroperitoneal or mesenteric lymphadenopathy.
No obvious bowel wall thickening seen.

कृपया पुरानी रिपोर्ट व डाक्टर का पर्चा [illegible] अवश्य लायें

IMPRESSION:-

- **Cholelithiasis.**

Adv- Clinical correlation & follow-up.

[redacted]

[redacted]

MD RADIODIAGNOSIS

[redacted]

Above impression is not the final diagnosis. Please correlte clinico-pathologically. In case of any discrepancy, please send patient for review (free), The report and films are not valid for medico-legal or juridical purpose,

[redacted]

Patient

Patient ID [redacted]

Study

Date 10/03/2026

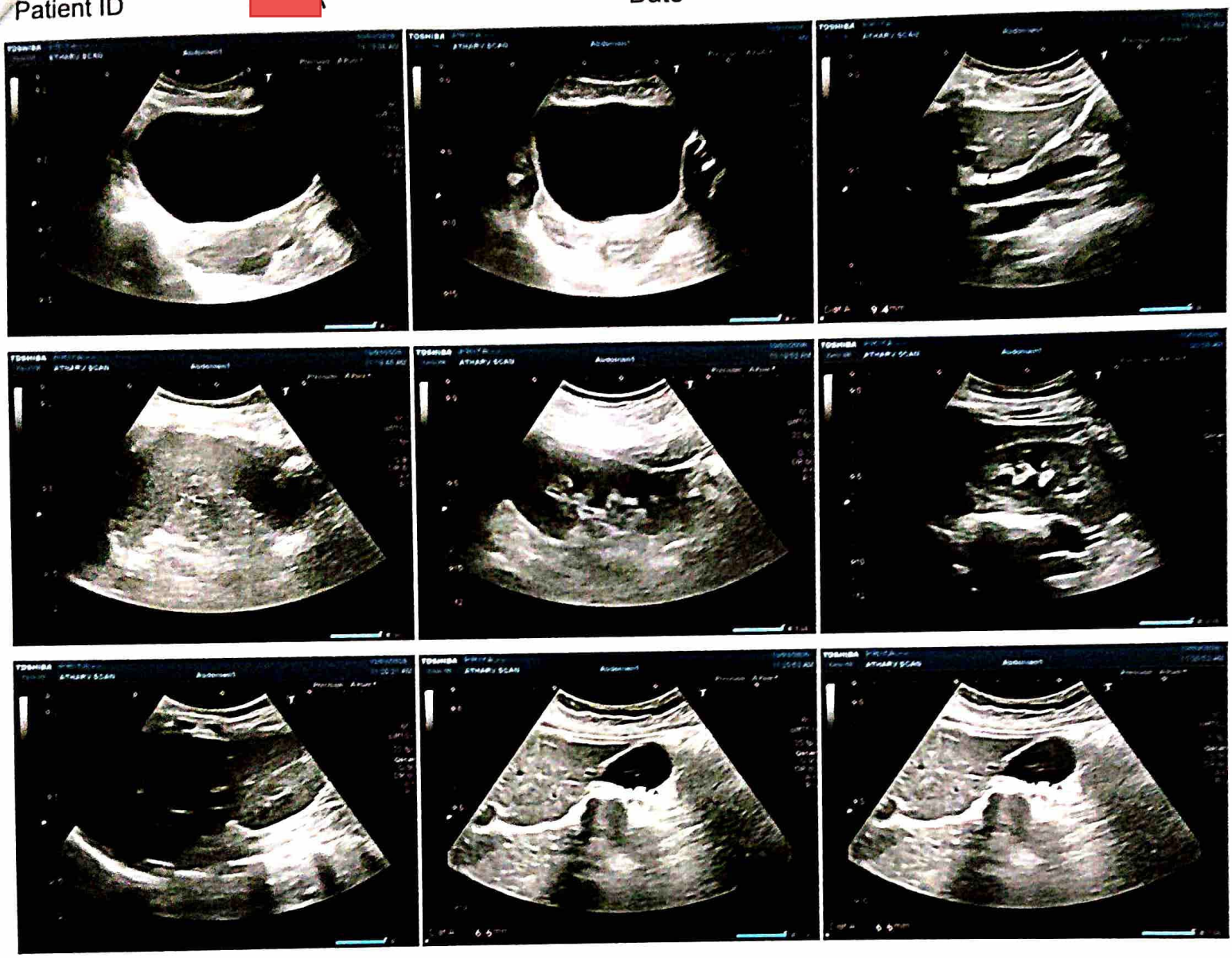

Printed Date : 10/03/2026 11:21:55 AM