[redacted]

[redacted]

PATENT NAME:- [redacted] **AGE:- 36** **SEX:- FEMALE**

REF. BY DR.:- SELF. **DATE:- 19-03-2026**

ULTRASOUND WHOLE ABDOMEN

NO EVIDENCE OF ASCITIS,PARAORTIC LYMPHNODES&PLEURAL EFFUSION.

* LIVER

Liver is normal in shape, size &echo pattern. No mass lesion is seen.
Intrahepaticbiliary channels are of normal caliber.Echo texture& echo pattern of liver is normal.

* GB

GB is normal in shape, size & contour. No mass or calculus is seen.
CBD is of normal caliber.

* PANCREAS

Spleen is normal in shape, size & echopattern. Splenic vein is normal in size.

* SPLEEN

Pancreas is normal in shape, size &echopattern. No mass lesion is seen.
Pancreatic duct is normal.

* RIGHT KIDNEY

Rt kidney is normal in shape, size &ech.opattern.No mass lesionor calculus is seen. Pelvicalyceal system is normal.Cortico-medullary differentiation is intact.

* LEFT KIDNEY

Lt kidney is normal in shape, size &ech.opattern. No mass lesion is seen. **Multiple Echogenic foci of largest size measuring abou 26X15mm** seen in upper and mid Pole of Left Kidney.
Pelvicalyceal system is normal.Cortico-medullary differentiation is intact.

* UB

UB is normal in shape, size & wall thickness.
No mass or calculus is seen.

* UTERUS

Post Menopausal Atrophied Uterus.
No significant amount of fluid is seen in cul-de-sac.

* OVARIES

Both ovaries are normal is shape, size &contour . No T-O mass.

IMPRESSION:-

LEFT RENAL CALCULI.

[redacted]

***This is the provisional Diagnosis please co-relate with your clinical findings & futher investigaions. Not for Medico legal use**

[redacted]

EQUIPPED WITH : CT Scan Ge/Linux (Multiple Slice), Twin Semi Automated biochemical Analyzer & Digital X-Ray 300 MA, ECG

NAME OF PATIENT :	[redacted]	AGE/ SEX:	36Year/female
REFERRED BY:	DR.	DATE:	24-03-2026
INVESTIGATION:	IVP		

IVP

PLAIN X-RAY KUB:-

A.R.O. shadow of size **26X14mm** is seen on **Left side of abdomen.**

B/L psoas shadows are normal.

IVP:-

Right kidney &Ureter:-

There are good excretory functions, Nephrogram and pyelogram phases are normal, No filling defect seen.

Right ureter is normal in caliber.

Left kidney &Ureter:-

There are delayed excretory functions. There is increasingly dense nephrogram and pyelogram phases.

PCS are dilated. R.O. shadow is seen area of PUJ.

Left ureter is not opacified.

Urinary bladder:-

UB is dilated with smooth walls. No filling defect seen .

Post void urine volume is insignificant.

IMP:-

Left Side calculus with delayed renal excretory function.

Normal renal excretory function on right side.

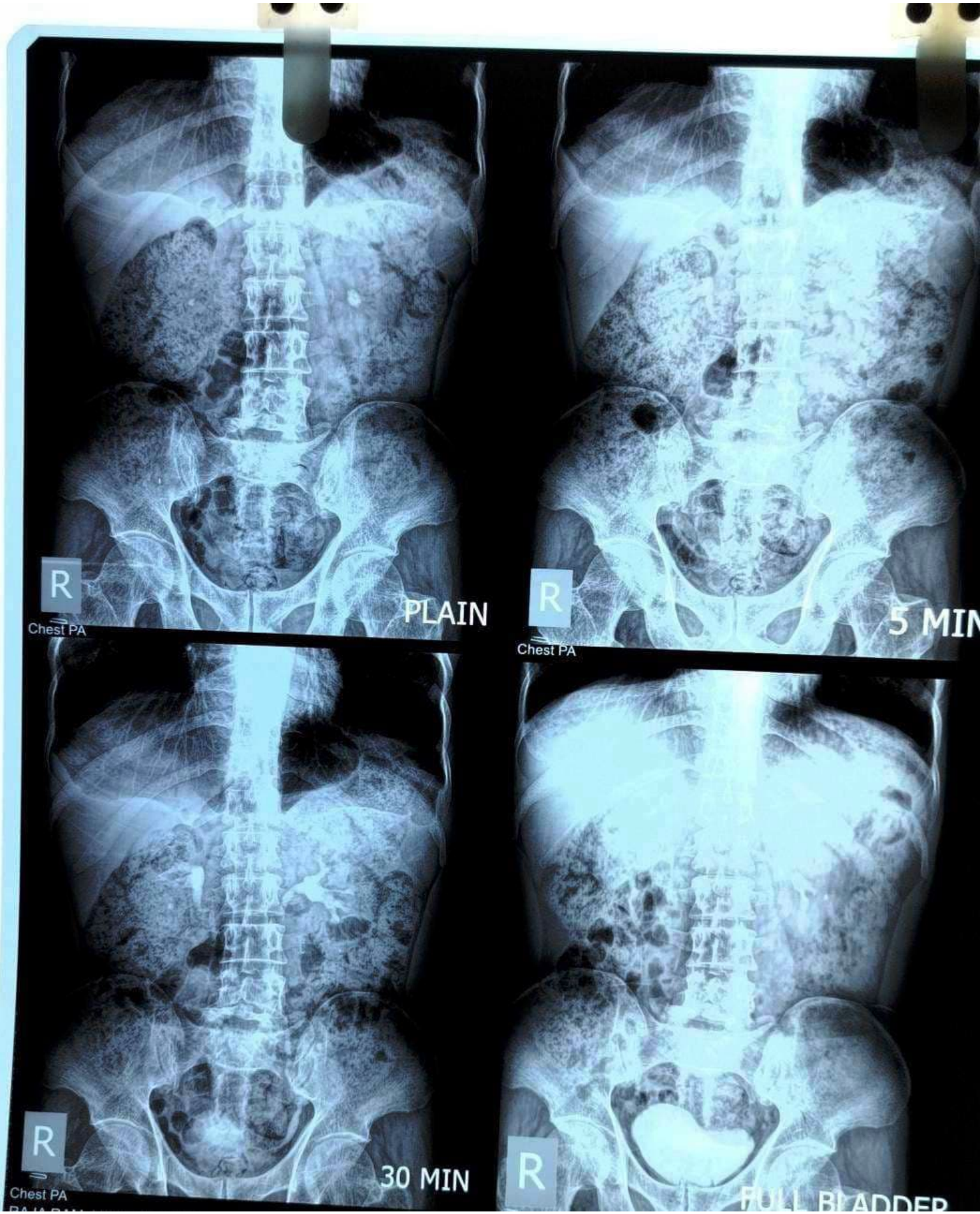
R
Chest PA
PLAIN
R
Chest PA
5 MIN
R
Chest PA
30 MIN
R
FULL BLADDER