Name	[redacted]	**Date**	**31/03/2026**
Ref. By	[redacted]	**Age / Sex**	**25 Yrs. Male**

INTRAVENOUS UROGRAPHY

PLAIN X-RAY : Shows normal psoas and kidney shadows.

A radio-opaque calculus is seen in right renal area at the level of L2 vertebral body measuring 3.1mm
Few faint radio-opaque calculi are seen in left renal area at the level of L1 and L2 vertebral bodies with largest measuring 3.4mm.
A radio-opaque calculi are seen in left paravertebral area at the level of L2-L3 vertebral bodies measuring 6.7mm with DJ stent is seen in situ on left side.
Visualized spine appears normal.

INTRA-VENOUS UROGRAPHY :

IVU done with inj. Omnipaque 300mg/ml x50ml IV.
Both kidneys are normally sited and are of normal size and shape. Kidneys measure 102x50mm and 100x50mm or right and left sides respectively.
There is normal excretion of contrast on both sides.

Right kidney:
Pelvicalyceal system is normal on right side. **A radio-opaque calculus in right renal area is seen to lie inferior calyx s/o right renal calculus.** Right ureter is normal in course and calibre. There is no hold up of contrast on right side.

Left kidney:
Few faint radio-opaque calculi seen in left renal area are seen to lie in left middle and inferior calyces. A radio-opaque calculus noted in left paravertebral location are seen to lie in left upper ureter with DJ stent is seen in situ on left side.

Urinary bladder shows smooth outline. No filling defect or calculus is identified in bladder. No significant residual urine is seen after micturition.

IMPRESSION : IVU study reveals:
* **Right renal calculus**
* **Left renal calculi and left upper ureteric calculus with Dj stent seen in situ on left side.**
* **Normal excretion of contrast in bilateral kidney.**

ADV: Clinical correlation and further evaluation with nuclear medicine scan.

[redacted]

Reported by : [redacted]

2603310030

[redacted]
MBBS. MD (RADIODIAGNOSIS)
Consultant Radiologist

This is a professional opinion and not a final diagnosis. All investigations have some limitations and views expressed here are based on imaging features noted during examination. For further confirmation of diagnosis and clinico-pathological investigations/further imaging and non imaging investigations like CT, MRI, PET-CT, TVS USG, Doppler, Endoscopy etc. will be required. Re examination and second opinion are strongly suggested if imaging findings do not correlate with clinical findings and surgical patients. Please ask for a correction, if you notice any typing errors in the report. Your feedback will be appreciated.

Facilities • एम.आर.आई. (3Tesla MRI) • सी.टी. स्कैन (64 Slice CT Scan) • डिजिटल एक्स-रे (Digital X-Ray) • डिजिटल ओ.पी.जी. (Digital O.P.G.) • सोनो मैमोग्राफी (Sono Mammography) • पैथोलॉजी (Pathology) अल्ट्रासाउण्ड (3D, 4D, Color Doppler, TVS), Anomaly Scan, • High Frequency अल्ट्रासाउण्ड (Breast, Neck, MSK Etc.) • USG Guided Investigation-FNAC, Biopsy, Tapping etc. • सभी प्रकार के उच्च क्वालिटी के डिजिटल एक्स-रे (Latest 300mA Digital X-Ray Machine) • स्पेशल जाँचे जैसे - IVP, HSG, Barium Studies Etc.
• सभी प्रकार की आँखों की बिमारियों की जाँच तथा उपचार उपलब्ध है। • आयुष्मान योजना द्वारा आँखों के ऑपरेशन की निःशुल्क सुविधा • Not valid for medico legal purposes

** IMAGE DIAGNOSTICS CT & MRI CENTRE **

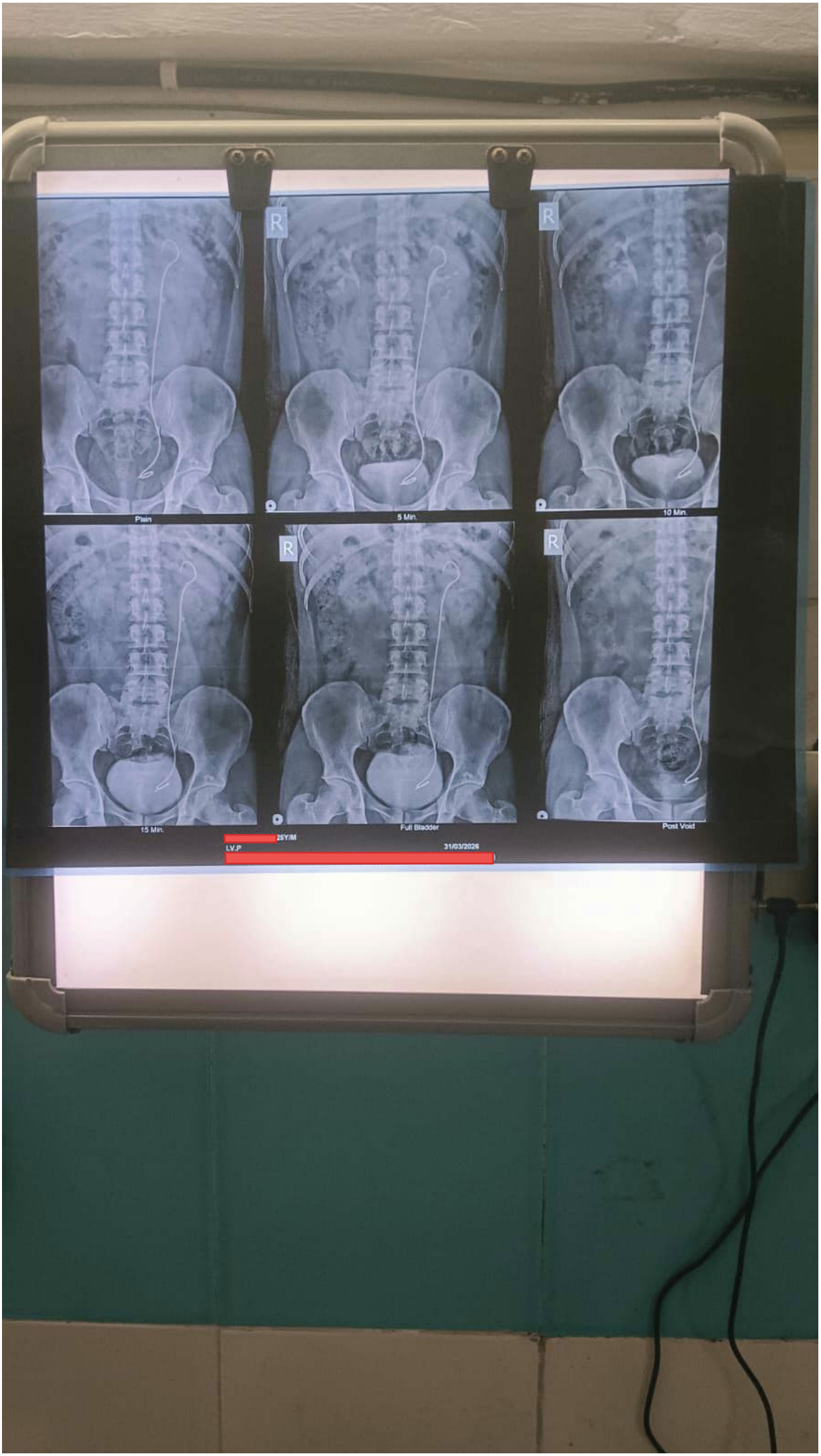
R
R
Plain
5 Min.
10 Min.
R
R
15 Min.
Full Bladder
Post Void
[redacted] 25Y/M
LV.P
31/03/2026
[redacted]