[redacted]

- MRI
- MULTI SLICE CT SCAN
- ULTRASOUND
- DIGITAL X-RAY
- PATHOLOGY
- OPG
- ECG

E-mail [redacted]

PATENT NAME:-	Mrs. [redacted]	AGE: -32	SEX:FEMALE
REF.BY:-	Dr. SELF.	DATE:-	21/03/2026

X-RAY IVP STUDY

A radiopaque shadow seen in RightRenalmeasuring **27X15mm**.

Renal and psas shadows are partially obscured by bowel gases.

SKIAGRAM INTRAVENOUS PYELOGRAPHY:-

5 mts after contrast injection early exposure skiagram shows good nephrographic effect on both side Size shape and location of both kidneys are normal.

No e/o right hydronephrosis seen. No c/o left hydronephrosis.

Bilateral ureters appear normal in caliber.

Contrast filled urinary bladder is clearly outlined margins are regular. No filling defect or indentation seen.

Post voiding skiagram shows no residual contrast .Noother abnormality seen.

IMPRESSION:-RIGHT RENAL CALCULUS .

ADVICE UROGRAM FOR BETTER EVALUATION.

Please correlatc clinically.

[redacted]

(Radiologist) [redacted]
MD RADIODIAGNOSIS

(Radiologist) [redacted]
MD RADIODIAGNOSIS

(Radiologist) [redacted]
DMRD (EX. SR.) K.G.M.U. LUCKNOW

Note: If any Discrepancies between radiolgical finding/ diagnosis & clinical diagnosis is there, then review within 3 day, free of cost

Review Immediately for any typing mistake

Not for medico legal purpose

Thanks for the referral with regards

सभी सुविधाएं - एक छत, एक जगह आराम

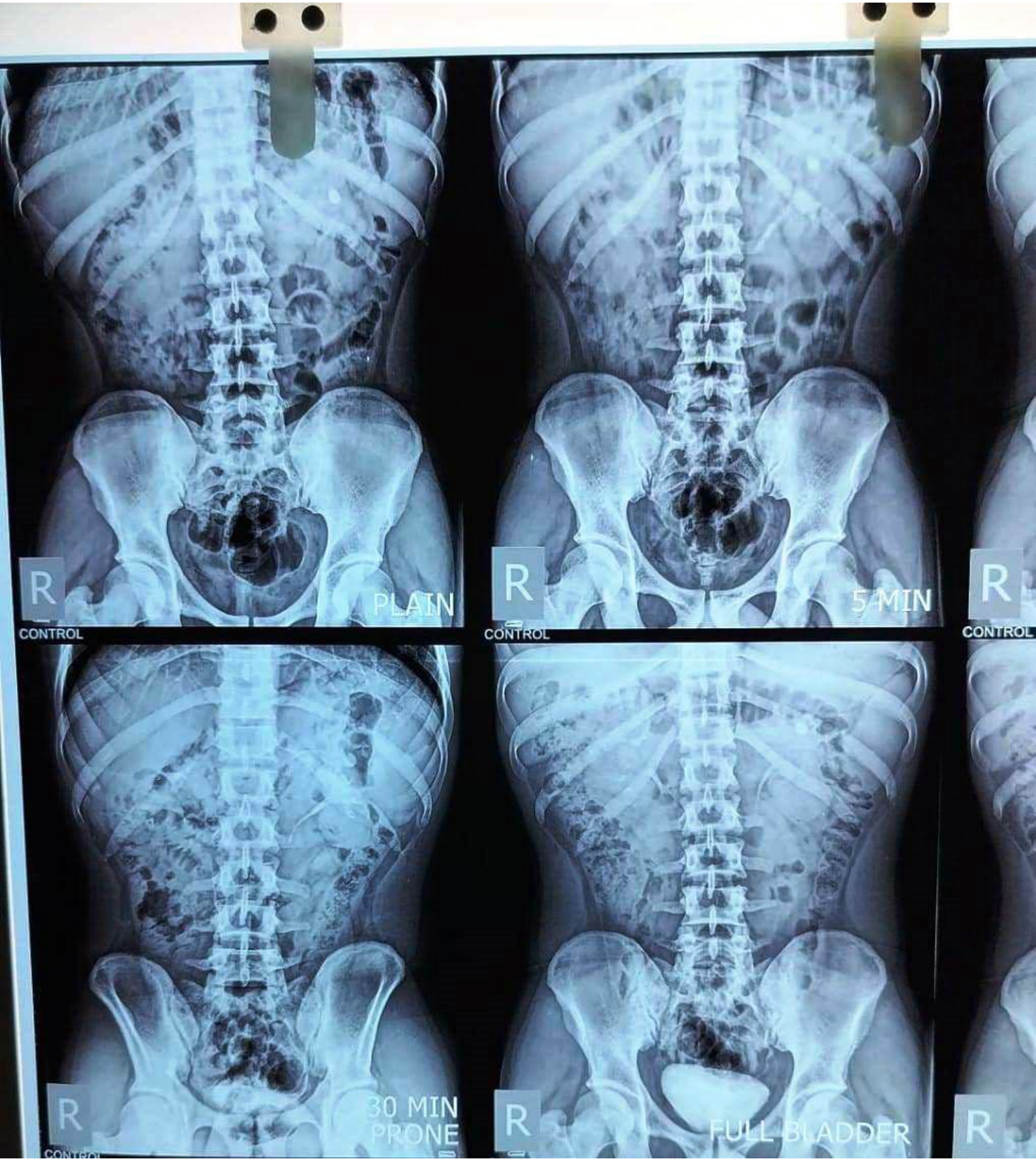
R
PLAIN
CONTROL
R
5 MIN
CONTROL
R
CONTROL
R
30 MIN
PRONE
R
FULL BLADDER
R