[redacted]

NAME OF PATIENT :	[redacted]	AGE/ SEX:	29/Year/male
REFERRED BY:	DR.	DATE:	22-03-2026
INVESTIGATION:	IVP		

IVP

PLAIN X-RAY KUB:-

A.R.O. shadow of size **26X15**mm is seen on **Right side of abdomen.**

B/L psoas shadows are normal.

IVP:-

Right kidney &Ureter:-

There are good excretory functions, Nephrogram and pyelogram phases are normal,

PCS are dilated. R.O. shadow is seen area of PUJ.

Right ureter is normal in caliber.

Left kidney &Ureter:-

There are delayed excretory functions. There is increasingly dense nephrogram and pyelogram phases.

Left ureter is not opacified.

Urinary bladder:-

UB is dilated with smooth walls. No filling defect seen .

Post void urine volume is insignificant.

IMP:-

Right side calculus with delayed renal excretory function.

Normal renal excretory function on right side.

[redacted]

PATENT NAME:- [redacted] **AGE:- 29 SEX:- MALE**

REF. BY DR.:- SELF. DATE:- 18-03-2026

ULTRASOUND WHOLE ABDOMEN

NO EVIDENCE OF ASCITIS,PARAORTIC LYMPHNODES&PLEURAL EFFUSION.

* LIVER

Liver is normal in shape, size &echo pattern. No mass lesion is seen.
Intrahepaticbiliary channels are of normal caliber.
Echo texture& echo pattern of liver is normal.

* GB

GB is normal in shape, size & contour. No mass or calculus is seen.
CBD is of normal caliber.

* PANCREAS

Pancreas is normal in shape, size &echopattern. No mass lesion is seen.
Pancreatic duct is normal.

* SPLEEN

Spleen is normal in shape, size &echopattern. Splenic vein is normal in size.

* RIGHT KIDNEY

Rt kidney is normal in shape, size &ech.opattern. No mass lesion is seen. **Multiple Echogenic foci of largest size measuring about 26X16mm** seen in upper and mid Pole of Rigl Kidney.Pelvicalyceal system is normal.Cortico-medullary differentiation is intact.

* LEFT KIDNEY

Lt kidney is normal in shape, size &ech.opattern.No mass lesion or calculus is seen. Pelvicalyce system is normal.Cortico-medullary differentiation is intact.

* UB

UB is normal in shape, size & wall thickness.
No mass or calculus is seen.

* PROSTATE

Prostate is normal is shape, size &echopattern. No mass lesion is seen.
Capsule is intact. No evidence of Calcification.
Both seminal vesicles are normal in shape, size &echopattern.

IMPRESSION:-

RIGHT RENAL CALCULI.

[redacted]

***This is the provisional Diagnosis please co-relate with your clinical findings & futher investigaions. Not for Medico legal use**

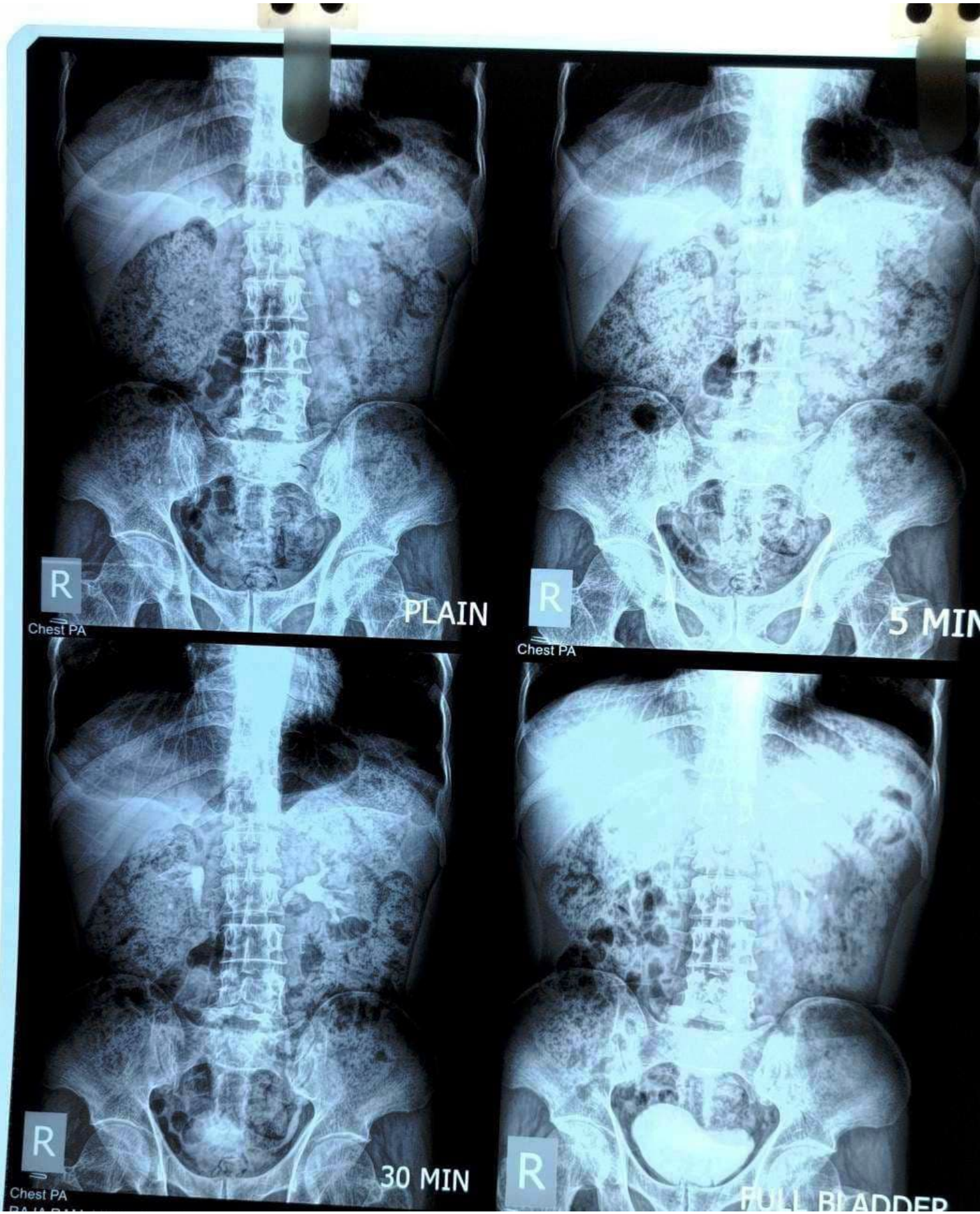
R
Chest PA
PLAIN
R
Chest PA
5 MIN
R
Chest PA
30 MIN
R
FULL BLADDER