[redacted]

X-RAY'S REPORT

Patient Name:	[redacted]	Patient ID:	2026040310
Sex:	F	Study:	IVP
Age:	38 Years	Referring Physician:	[redacted]
Study Date:	04-04-2026	Modality:	

IVP

- **Plain X-Ray KUB – Large abnormal radio-opaque calculus approx. (17&14 mm) seen in KUB region.**
- 60 ml of I V contrast given under aseptic precautions and films taken at 05,10,15 min, with full & empty bladder. Procedure was uneventful.
- **STUDY SHOWS:-**
- **KIDNEYS**: Both kidney show normal excretion of contrast and normal in size, shape and position. Both Pelvicalyceal system is dilated with maintained cupping of calyces and no obvious filling defect or irregularity. **Abnormal shadow overlapping with both side renal pelvis leading to hydronephrosis with a large radio opaque calculus shadow is seen in line of right renal at the level of L3 approx (17 mm) seen. And some radio opaque calculus shadows are seen in line of left renal at the level of L3 approx (14 mm) seen.**
- **URETERS:- Right upper ureter is mild dilated . And delayed excretion on the left ureter.**
- **URINARY BLADDER:** It is distended and normally opacified by contrast. No obvious irregularity of wall / filling defect seen.
- ***Bowel gas pattern is normal.***
- **IMPRESSION:**
- **BOTH SIDE RENAL PELVIS CALCULUS AND HYDROURETERONEPHROSIS WITH NORMAL FUNCTIONING OF BOTH KIDNEYS.**

AD:- further investigation of NCCT KUB Kindly Review with clinical findings.

[redacted]

[redacted]

(MD Radio diagnosis)

PLEASE CALL ON: 8960072344FOR more details about patient.(only doctors)

The science of radiology is based upon interpretation of shadows of normal and abnormal tissue. This is neither complete nor accurate; hence, findings should always be interpreted in to the light of clinico-pathological correlation. **THIS IS A PROFESSIONAL OPINION, NOT A DIAGNOSIS. NOT MEANT FOR MEDICO LEGAL**

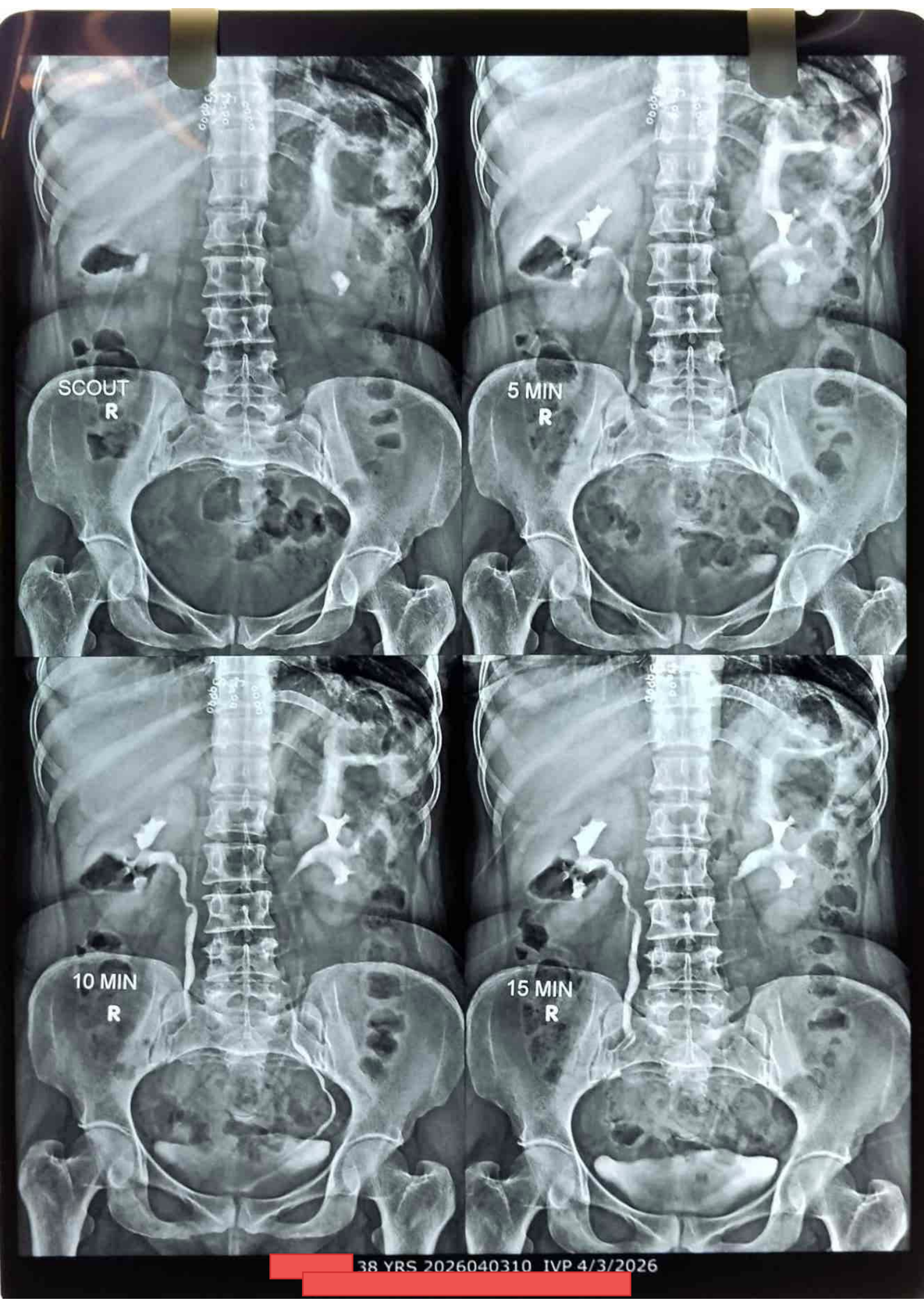
SCOUT
R
5 MIN
R
10 MIN
R
15 MIN
R
[redacted] 38 YRS 2026040310 IVP 4/3/2026
[redacted]

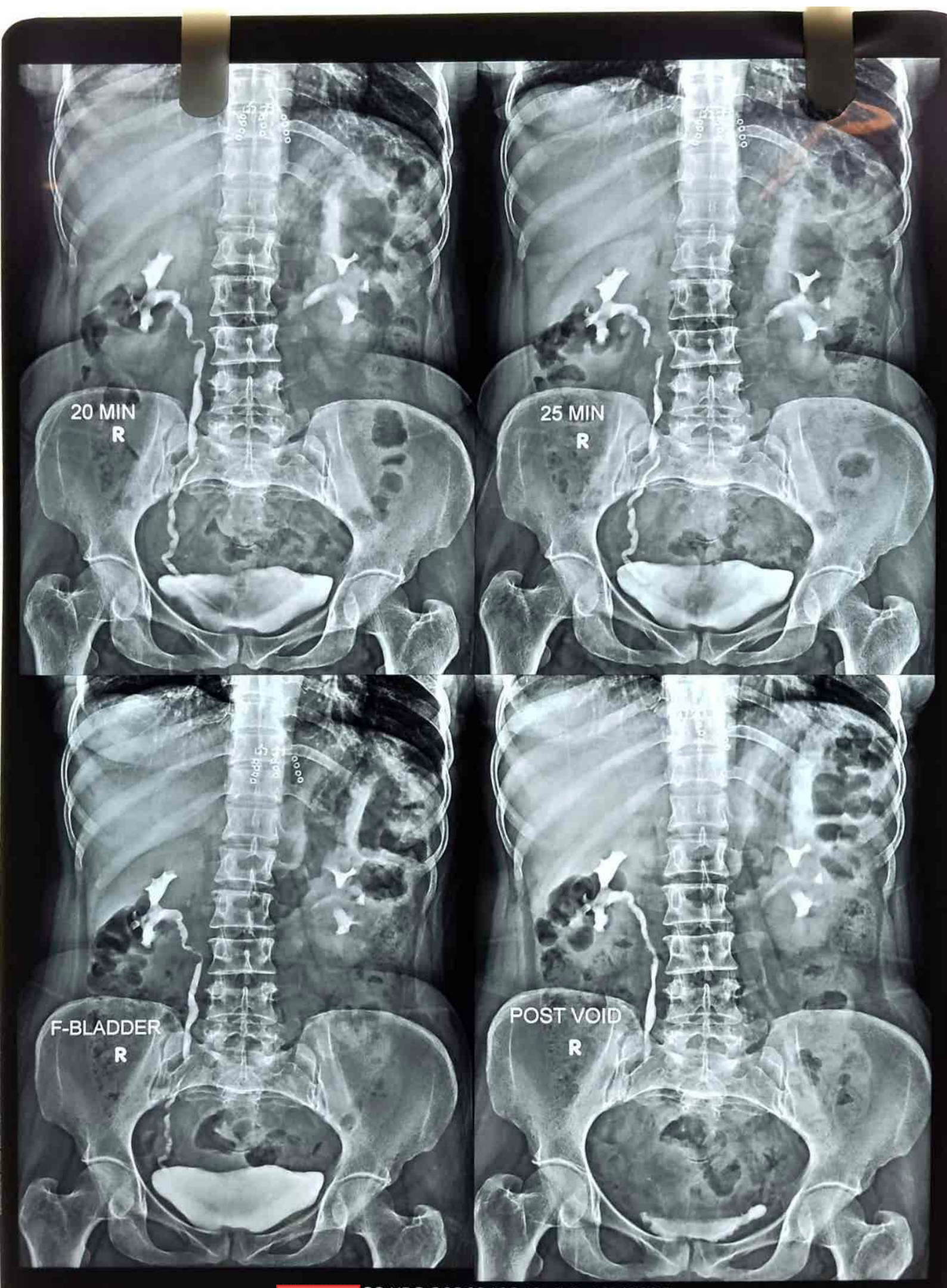

[redacted] 38 YRS 2026040310 IVP 4/3/2026 [redacted]