STANDARDS

FOR DATA COLLECTION FROM HUMAN SKELETAL REMAINS

Proceedings of a Seminar at The Field Museum of Natural History
Organized by Jonathan Haas

Volume Editors: Jane E. Buikstra and Douglas H. Ubelaker

Assistant Editor: David Aftandilian

Contributions by:
D. Aftandilian, J. E. Buikstra, M. Finnegan,
J. Haas, D. A. Kice, C. R. Nichol, D. W. Owsley,
J. C. Rose, M. J. Schoeninger, G. R. Scott,
C. G. Turner II, D. H. Ubelaker, P. L. Walker, and E. Weidl

ARKANSAS ARCHEOLOGICAL SURVEY RESEARCH SERIES NO. 44
1994

Arkansas Archeological Survey
Fayetteville, Arkansas
©1994
Third Printing 1997

Library of Congress Cataloging in Publication Data

Standards for data collections from human skeletal remains:
proceedings of a seminar at the Field Museum of Natural History, organized by Jonathan Haas / volume editors, Jane E. Buikstra and Douglas H. Ubelaker, assistant editor, David Aftandilian; contributions by D. Aftandilian . . . [et al.].
p. cm. —(Arkansas Archeological survey research series; no. 44)
Includes bibliographical references and index.
ISBN 1-56349-075-7 (acid-free paper); $25.00
1. Indians of North America—Anthropometry—Handbooks, manuals, etc.—Congresses. 2. Anthropometry—Handbooks, manuals, etc.—Congresses. 3. Human skeleton—Classification—Handbooks, manuals, etc.—Congresses. 4. Human remains (Archaeology)—Classification—Handbooks, manuals, etc.—Congresses. 5. Indians of North America—Antiquities—Law and legislation—Congresses. I. Haas, Jonathan, 1949- . II. Buikstra, Jane E. III. Ubelaker, Douglas H. IV. Aftandilian, David. V. Field Museum of Natural History. VI Series.
E98.A55S88 1994 94-36389
572'.897—dc20 CIP

Abstract:

For human remains that are likely to be repatriated or otherwise made unavailable for future research, an exhaustive and thorough data collection protocol (standardization of minimal amounts of information that should be recorded) was developed, reviewed, and tested by specialists. Procedures include inventory, sexing and aging, dental collection and study, measurement, nonmetric traits, postmortem changes, paleopathology, cultural modifications, and conservation of samples. Twenty-nine easy-to-use data recording forms are attached.

Series Editor: Hester A. Davis
Production Editor: Mary Lynn Kennedy
Production (Bioarcheology) Assistants: Lela Donat, Victoria Dianne Green, Melissa L. Jones, Jerome C. Rose, Angela Tiné
Proofreaders: Melissa Memory, Annie Moerbe, Nese Nemec
Offset Printers: Western Newspaper Company, Indianapolis

Karen Cruse

CONTENTS

ABSTRACT ii
LIST OF FIGURES AND TABLES v
ACKNOWLEDGMENTS vi
1 THE NEED FOR DATA RECORDING STANDARDS 1
2 RATIONALE AND SCORING PROCEDURES FOR SKELETAL INVENTORY 5
CODING RELATIVELY COMPLETE SKELETONS 6
CODING COMMINGLED OR INCOMPLETE REMAINS 9
RECORDING IMAGES: PHOTOGRAPHY, RADIOGRAPHY, CASTING, AND SKETCHES 10
3 DOCUMENTATION OF SEX DIFFERENCES AND AGE CHANGES IN ADULTS 15
SEX DETERMINATION 16
DOCUMENTATION OF AGE CHANGES 21
4 IMMATURE REMAINS: MATURATION AND MEASUREMENT 39
AGE-AT-DEATH 40
MEASUREMENTS 44
5 DENTAL DATA COLLECTION I: INVENTORY, PATHOLOGY, AND CULTURAL MODIFICATIONS 47
DENTAL INVENTORY 47
OCCLUSAL SURFACE WEAR 49
ENAMEL MICROWEAR 53
DENTAL CARIES 54
ABSCESSES 55
DENTAL CALCULUS 56
ENAMEL DEFECTS: HYPOPLASIAS AND OPACITIES 56
PREMORTEM DENTAL MODIFICATIONS 58
DENTAL SAMPLES 58
6 DENTAL DATA COLLECTION II: DENTAL MORPHOLOGY, MEASUREMENTS OF THE SECONDARY DENTITION 61
DENTAL MEASUREMENTS 61
DENTAL MORPHOLOGY 63
7 MEASUREMENT OF ADULT REMAINS 69
8 NONMETRIC SKELETAL TRAITS 85
9 POSTMORTEM CHANGES: HUMAN TAPHONOMY 95
TYPES OF ALTERATION 95
RECORDING TAPHONOMIC CHANGES 105
10 PALEOPATHOLOGY 107
THE IMPORTANCE OF STANDARD TERMINOLOGY, STANDARDLY APPLIED 108
OBSERVATIONAL STRATEGIES 108
DATA COLLECTION PROTOCOL 123
CONCLUDING STATEMENT 159

11 CULTURAL MODIFICATIONS OF THE LIVING: TREPANATION AND ARTIFICIAL CRANIAL DEFORMATION 159
TREPANATION (TREPHINATION) 159
ARTIFICIAL CRANIAL DEFORMATION 160
12 BIOCHEMICAL AND MICROSTRUCTURAL TECHNIQUES: CONSERVATION OF DENTAL, SKELETAL SAMPLES 164
ESTIMATING ANTIQUITY 165
ESTIMATING CHRONOLOGICAL AGE 165
HEALTH STATUS 168
DIET 168
GENETIC RELATIONSHIPS 170
ASPECTS OF BEHAVIOR 170
MIGRATION PATTERNS 172
CLIMATE 172
CHANGES INDUCED BY HEAT 173
SUMMARY OF SAMPLES AND CURATION REQUIREMENTS 173
13 CONCLUDING STATEMENT 175

APPENDICES
I. GLOSSARY OF TERMS 177
II. INTRA- AND INTER-OBSERVER ERROR 183

REFERENCES CITED 185
INDEX 203
ATTACHMENTS after 206
1 Inventory Recording Form for Complete Skeletons
2 Inventory Recording Form for Commingled Remains and Isolated Bones
3 Adult Skeleton Recording Form: Anterior and Posterior Views
4 Adult Skeleton Recording Form: Right and Left Lateral Views
5 Juvenile Skeleton Visual Recording Form: Child and Fetus Anterior Views
6 Skull Recording Form: Anterior and Posterior Views
7 Skull Recording Form: Right and Left Lateral Views
8 Skull Recording Form: Superior and Basilar Views
9 Postcranial Bones Visual Recording Form: Right and Left Views of Os Coxae, Scapula, Clavicle
10 Postcranial Bones Visual Recording Form: Right and Left Views of Femur, Tibia, Fibula
11 Adult Sex/Age Recording Form
12 Immature Remains Recording Form: Bone Union and Epiphyseal Closure
13 Immature Measurements Recording Form
14 Dental Inventory Visual Recording Chart: Permanent and Deciduous Dentition
15 Supernumerary Teeth and Abscesses Visual Recording Form: Maxillary and Mandibular Dentition
16 Dental Inventory Recording Form: Permanent Teeth
17 Dental Inventory Recording Form: Deciduous Teeth
18 Enamel Defects (Hypoplasias and Opacities) Recording Form: Permanent and Deciduous Teeth
19 Premortem Dental Modifications Recording Form
20 Dental Measurements and Morphology Recording Form
21 Cranial and Postcranial Measurement Recording Form: Adult Remains
22 Primary Nonmetric Traits Recording Form
23 Taphonomy Recording Form I: Burned Bone
24 Taphonomy Recording Form II: Weathering, Discoloration, Polish, Cutmarks, Gnawing, and Other
25 Paleopathology Recording Form I: Shape, Size, Bone Loss, Formation, Fractures, and Porotic Hyperostosis
26 Paleopathology Recording Form II: Vertebral Pathology, Arthritis, and Miscellaneous
27 Trepanation Recording Form
28 Cranial Deformation Recording Form
29 Checklist for Skeletal and Dental Samples

FIGURES

1. Sex differences in the subpubic region 17
2. Sex differences in the greater sciatic notch 18
3. Scoring system for preauricular sulcus 19
4. Scoring system for sexually dimorphic cranial features 20
5. Pubic symphyseal face for Todd and Suchey-Brooks scoring 21
6. Todd Pubic symphysis phases 22
7. Suchey-Brooks standards for female pubic symphysis 23
8. Suchey-Brooks standards for male pubic symphysis 24
9. Ilium regions used in auricular surface age determination 24
10. Auricular surfaces for use in age determination 26-32
11. Location of sites to be used to record ectocranial 33
12. Stages of ectocranial suture closure 34-35
13. Postcranial developmental phases and chronological age 37
14. Chronological age and ectocranial suture scores 38
15. Location of epiphyses 40
16. Stages of epiphyseal union for the proximal femur 41
17. Primary ossification centers of the os coxae 41
18. Primary ossification centers of the vertebrae 42
19. Primary ossification centers of the occipital 42
20. Relationship of epiphyseal union and fusion of primary ossification centers to chronological age 43
21. Measurements of immature human remains 45-46
22. Visual recording chart for permanent dentition 48
23. Stages of formation for teeth 50
24. Sequence of formation of American Indian teeth 51
25. Surface wear scoring system for teeth 52
26. Scott system for scoring surface wear in molars 53
27. Abscess of a second mandibular molar 55
28. Variations in degree of dental calculus formation 56
29. Two incisors coated with ammonium chloride 57
30. Premortem dental modifications 59-60
31. Measurement of diameters on posterior teeth 62
32. Measurement of diameters on anterior teeth 62
33. Measurement of crown height 63
34. Anatomical landmarks of the skull, anterior view 71
35. Anatomical landmarks of the skull, lateral view 72
36. Anatomical landmarks of the skull, basilar view 73
37. Cranial measurements in the sagittal plane 74
38. Maximum cranial breadth and bizygomatic diameter 74
39. Cranial measurements, basilar view 75
40. Cranial measurements, anterior view 75
41. Measurements of the orbital region 76
42. Frontal, parietal, and occipital chord measurements 76
43. Foramen magnum length and breadth 77
44. Mastoid length 77
45. Measurements of the mandible, anterior view 78
46. Measurements of the mandible, lateral view 78
47. Measurements of the clavicle 79
48. Measurements of the scapula 79
49. Measurements of the humerus 80
50. Measurements of the radius 80
51. Measurements of the ulna 81
52. Measurements of the sacrum 81
53. Measurements of the os coxae 82
54. Measurements of the femur 83
55. Measurements of the tibia 83
56. Measurements of the fibula 84
57. Measurements of the calcaneus 84
58. Frontal cranial vault, nonmetric traits 87
59. Superior and lateral cranial vault, nonmetric traits 88
60. Posterior and basilar cranial vault, nonmetric traits 89
61. Basilar cranial vault, nonmetric traits 90
62. Lateral cranial vault, nonmetric traits 91
63. Lateral and posterior bridging of the atlas. 92
64. Accessory transverse foramen 92
65. Various degrees of expression of the septal aperture 92
66. Cremated bone, illustrating degrees of burning 96
67. Example of surface erosion due to roots 97
68. Bone weathering stages 99
69. Carnivore tooth marks 100
70. Bones presenting evidence of rodent gnawing 101
71. Cutmarks 102
72. Examples of perimortem and postmortem breakage 103-104
73. Perimortem anvil abrasions 104
74. Impact of "normal" modeling due to growth 109
75. Pacchionian depressions on parietal bones 110
76. "Normal" vessel tracks for basivertebral veins 110-111
77. Vessel tracks of well-remodeled periostitis 111
78. Sample sketch of abnormal bone remodeling 112
79. Shape abnormalities, angulation and bowing 124
80. Illustration of modeling during growth 125
81. Several examples of abnormal bone shapes 125-126
82. Fusiform expansion of tibia due to infectious process 126
83. Kyphosis (abnormal anterior curvature) 127
84. Ankylosis (abnormal fusion) in spine, T12 to sacrum 128
85. Spinal abnormalities 129-130
86. Hydrocephalic skull 131
87. Achondroplasia 131-132
88. Variation in margin form for resorptive lesions 133
89. Skeletal lesions, keyed to pathology codes 133
90. Examples of osteoporotic bone loss 134
91. Sagittal sections of partial spines 135
92. Abnormal bone formations, woven and sclerotic 136
93. "Sunburst" and "cauliflower"effects on cranium 137
94. Various forms of bony shell formations 138
95. Cloacae (sinus tracks or canals) 139
96. Abnormal matrix formation, as in Paget's Disease 140-141
97. Myositis ossificans on the linea aspera of the left femur 142
98. Joint fusion, right metatarsal and proximal phalanx 142
99. Button osteoma on the frontal bone 143

100. Stellate scars (caries sicca) 143
101. Involucrum and sequestrum (arrow) in a left tibia 144
102. Types of fractures 144-145
103. Trauma induced by weapons, entry and exit 146-148
104. Non-union of a midshaft fracture of a left radius 148
105. Examples of traumatic and congenital dislocations 149-150
106. Coding system for porotic hyperostosis 151-153
107. Schmorl's nodes on vertebral bodies 154
108. Osteophyte vs. syndesmophyte formations 154
109. Partial and complete sacral spina bifida 155
110. Examples of spondylolysis 156
111. Bony osteoarthritis 157-158
112. Surface osteophytes 158
113. Example of partially healed trepanation 159
114. Common methods for trepanation 160
115. Examples of deformed skulls and deforming devices 161
116. Bilobate expansion in cranial deformation 161
117. Major forms of North American cranial deformation 162
118. Sketch of deformed skull, recording cranial deformation 163
119. Photomicrograph of bone section 166
120. Location of bone sections for cross-sectional geometry 171
121. Axes of bone sections for cross-sectional geometry 171

TABLES

1. Summary of inventory procedures for relatively complete skeletons 7
2. Inventory categories for recording the dentition 49
3. Supplemental list of postcranial measurements 70
4. Supplemental list of nonmetric traits 93-94
5. Bone weathering stages 98
6. Paleopathology skeletal code 114-115
7. Dental and skeletal samples 174

ACKNOWLEDGMENTS

Although space limitations prevent us from mentioning the individual contributions of all who participated in bringing this volume to completion, we do want to highlight the special efforts of the following people: Jerome C. Rose, for facilitating publication; Phillip Walker, who could be depended on for support and insightful comments at all times; Lisa Hoshower, for sustained assistance during the critical early stages of revision and rewriting; Diane Houdek, for her excellent and timely photography; Erica Jones, for editorial assistance; John Verano, for photography; and David Hunt, for preparing specimens for photography.

We also extend our sincere gratitude to the staff of the Arkansas Archeological Survey for the quality and intensity of their editorial effort. Especially crucial were the contributions of Victoria Diane Green, who provided indispensable technical help throughout the manuscript production, and Lela Donat and Angela Tiné for their gracious and expeditious advice. To all who labored at the editorial offices of the Survey, we are deeply appreciative of your successes in producing an excellent, affordable product.

CHAPTER 1

THE NEED FOR DATA RECORDING STANDARDS OF HUMAN SKELETAL REMAINS

From the scientific study of our ancestors we gain significant, often unique, knowledge about the history of humankind. Fossils are investigated to define the timing and evolutionary pathways taken by the earliest members of our species. In more recent contexts, the study of human tissues from archaeological sites permits important insights concerning health, diet, genetic relationships, microevolution, and population characteristics such as mean age-at-death and sex ratios. While much of this research has focused upon historical questions, contemporary issues are also addressed. Inherited skeletal features, for example, are now being used to resolve conflicting land claims by indigenous peoples. Similarly, evidence of bone and tooth pathology has been important in medical evaluations of inherited predispositions for certain diseases, such as diabetes and anemia. Nutritional assessments of traditional diets have also benefited from long term perspectives developed through chemical studies of ancient bones. These varied investigations of ancestral remains are the subject matter of physical anthropology.

Recent years have witnessed profound changes in the field of physical anthropology. Today's skeletal biologists, utilizing new tools such as high-speed computers, CT scans, and chemical analyses, pursue research problems thought impossible to investigate a decade ago. Traditional measurements and observations are employed in new ways to assess population relationships, growth and development, and biomechanics. Chemical approaches include elemental and isotopic analyses that provide detailed information concerning subsistence, nutrition, disease patterns, and even ages of infant weaning. Paleopathological diagnoses have become more exact, and therefore enable far-reaching inferences concerning the impact of culture change upon health, the history of disease, and the dynamics of disease experience in broad cultural contexts. While specialties and techniques grow increasingly complex, aspects of our research have become more synthetic and interdisciplinary. General patterns and processes are being identified that broadly characterize past populations, their experiences, and ways of life.

Academic interest in human skeletal biology, paleopathology, and related research foci such as paleonutrition and paleodemography has grown markedly in recent years. The *American Journal of Physical Anthropology* now publishes more articles on these topics than any other aspect of physical anthropology. The excitement and challenge of research in human skeletal biology is attracting increasing numbers of students who investigate ancient, historic, and contemporary human groups throughout the world. Until recently, scientists studying human skeletal biology in North America often conducted their research on Native American remains recovered from archaeological sites.

Many Native Americans argue that since contemporary Native Americans have ancestral relationships to certain skeletal remains, the disposition of these remains should be controlled by descendent groups. This sentiment was expressed in Iowa as early as 1971 (Anderson et al. 1978), when conflict arose over archaeological excavations of Native American skeletons. Concern spread throughout the Native American community, culminating in numerous state laws restricting the excavation and analysis of human remains in the United States (Ubelaker and Grant 1989).

On November 28, 1989, President Bush approved Public Law 101-185, the National Museum of the American Indian Act, directing the Smithsonian Institution in Washington, D.C., to carefully inventory its collections of human remains and to determine which remains are directly ancestral to existing tribes. Such tribes would then determine the fate of specified collections. Funds were appropriated to cover the cost of the actions mandated by this law.

The President approved Public Law 101-601, the Native American "Graves Protection and Repatriation Act," on November 16, 1990. This law directs all museums and laboratories within the United States (other than the Smithsonian) to evaluate their human skeletal collections. Museums and other institutions must inventory all human remains, determine those which can be ancestrally linked to existing tribes, communicate that information to the affected tribes, and then follow the wishes of the tribes regarding those collections.

Clearly, both these new laws pose monumental challenges to the scientific community and to institutions holding collections of skeletal remains. Institutions with large collections face significant logistical problems simply to complete the inventories specified by the legislation. Assessments must then be made of linkages with existing tribes, bringing together evidence from archaeological records, archival sources, oral histories, as well as from the bones and their archaeological contexts. Even small museums are expected to command expertise from archaeological, ethnohistoric, physical anthropological, and archival specialists. The magnitude of the affected collections has yet to be determined, although the impact will no doubt be significant.

Many archaeologists and physical anthropologists, while sympathetic to concerns of Native Americans, are deeply concerned with the loss of knowledge that may result from these developments. Just as scientific research techniques are offering new avenues for investigating nutrition, genetic relatedness, and health, access to skeletal collections is diminishing. Not only will important tissues not be available to future generations of scholars with newly developed technologies, but important scientific investigative principles, based on replicability of results, may also be precluded by reburial (Buikstra and Gordon 1981).

Also of concern are the collections that are being transferred and buried today without scientific study or with only limited analysis by qualified physical anthropologists. In cases where human bones with ambiguous or no information available on their original interment context are encountered in museum or laboratory collections, studying the bones themselves according to standardized scientific methods provides the only means of determining the genetic affiliation of the bones, i.e., whether the bones represent the remains of Native Americans or other cultural groups. Without proper study by trained professionals, remains ancestral to other cultural groups might mistakenly be returned to Native Americans, or remains ancestral to one Native American tribe might be returned to another tribe. An associated complication is the fact that administrators responsible for collections, who wish to act responsibly, are uncertain about *who* is qualified to study remains and *what standards* they should employ. To be avoided are situations in which undertrained students or marginal scholars "study" collections but actually produce little usable data.

Although the primary stimulus for this volume has been concerns voiced by Native Americans — and more recently, African-Americans — within the United States, similar issues have been raised by various ethnic groups within other countries, including Australia, Canada, and Israel. The volatile repatriation issue has the potential to spread to other countries as well. While such political developments cannot be controlled by the scientific community, we are extremely concerned that scientists act decisively to counter the loss of unique and important information. Just as in modern autopsies, standardized data from skeletal remains should be recorded before they become unavailable for study.

The immediate impact of the repatriation issue is to focus attention upon techniques for studying large numbers of skeletal remains efficiently and effectively. The need to gain the maximum amount of information from skeletons that will soon be unavailable creates an unusual challenge to the discipline of physical anthropology — demanding broad, problem-oriented data collection and creative, futuristic thought.

As yet there are no accepted standards for data collection from remains scheduled for repatriation. Data collection protocols currently vary among researchers, thus limiting possibilities for comparing, for example,

health across groups under different subsistence regimes. Although eighteenth-, nineteenth- and early twentieth-century physical anthropologists such as Blumenbach, Morton, Hrdlicka, Martin, and Hooton stressed the development of standard measurements and handbooks, recent emphases upon problem-orientation have encouraged individualized data collection strategies. A great deal of new knowledge about subjects unrealized in earlier studies has emerged, ranging from occupational stresses among Eskimos to factors favoring the development of tuberculosis in the Americas. As a result of such specialized research foci, however, data collection protocols have become highly variable and tailored to specific topics. Although equally as rigorous as the work of earlier scholars, researchers today — having exponentially increased the classes of data that one might collect — find it exceedingly difficult to compare their own data sets with those of other workers.

The lack of standardization in data collection became the central topic for discussion at the business meeting of the fifteenth annual gathering of the Paleopathology Association held in Kansas City, Missouri, on March 22, 1988. Those in attendance stressed the need for minimal standards in data collection because they feared that many collections were being lost with little or no scientific study.

At this meeting, Dr. Jerome Rose of the University of Arkansas described his review of published accounts for archaeologically recovered human remains from the region under the jurisdiction of the Southwestern Division of the United States Army Corps of Engineers. Rose reported that few published data sets were directly comparable and that no single report offered comprehensive data. Predictably, Rose was nominated to chair a committee charged with assessing the problem of data comparability and recommending new steps to take toward standardization. A volunteer committee of Susan C. Anton, Jane Buikstra, Leslie E. Eisenberg, John B. Gregg, Ellis Nieberger, Bruce Rothschild, and Roberts Woods worked with Rose in this effort. The report of this committee, published by the Paleopathology Association (Rose et al. 1991), is the cornerstone of the present initiative.

During 1989, while the Paleopathology Association's Committee was deliberating, the Field Museum of Natural History in Chicago was negotiating with the Blackfeet tribe concerning the Museum's collection of Blackfeet remains. Following discussions with us (Buikstra and Ubelaker), Field Museum Vice President for Collections and Research Jonathan Haas received support from the National Science Foundation to conduct an intensive seminar/workshop charged with developing standards for collection of osteological data. Working with Haas to organize this effort, we invited colleagues who not only were eminent scholars, but who could also speak with authority concerning specific, varied subtopics within skeletal biology. Representation from all major training programs was also sought. Such diversity carried the risk of major disagreements emerging within the group, but it also suggested that our results should be broadly accepted if consensus could be reached.

Workshop participants were responsible for topics generally compatible with current research expertise and publication records. These topical "assignments" were somewhat arbitrary, in that most participants were familiar with a number of subjects. Each participant was asked to prepare for group discussion a set of procedures for data collection in relationship to the assigned topic. The individual participants and their topics were as follows: George Armelagos, bone pathology; Jane Buikstra, nonmetric variation; Douglas Owsley, inventory and osteometric analysis; Jerome Rose, dental inventory, pathology, and cultural modifications; Lewis Sadler, computer imagery and illustration; Margaret Schoeninger, bone histology and chemistry; Christy Turner, dental metrics and morphology, taphonomy, and cranial deformation (the latter two shared with others); Douglas Ubelaker, subadult development; and Phillip Walker, adult aging and sexing. Jonathan Haas served as moderator/facilitator, and John Yellen attended, representing the National Science Foundation.

Despite relatively short notice, participants each arrived at the January 25-26, 1991, meeting well prepared. Following brief introductory remarks, each participant was asked to summarize recommendations concerning his or her assigned topic. Group discussion ensued. The difficult nature of our endeavor quickly emerged. We all wanted to cover our fields as thoroughly as possible, recognizing the need not only to accommodate existing research interests but also those likely to emerge in the future. The possibilities for data collection within each topical focus appeared nearly endless.

Those in the group with experience in data gathering from threatened collections cautioned that our protocol had to be selective so that it could be implemented within a reasonable time. Procedures that were too extensive, time-consuming, complicated, and difficult, would not be acceptable.

The workshop sessions were productive. Each participant obviously had worked hard to evaluate the current literature while also directing attention to the needs of future scholars. Suggestions were presented thoughtfully and consensus emerged, facilitated by Jonathan Haas when minor points received undue attention. Early in the meeting, we agreed that our published report should specify two data collection protocols: (1) the necessary minimum data set to be collected on all threatened remains; and (2) a broader protocol that could be followed if time and resources permitted.

We departed Chicago with a goal of producing final manuscripts by the April, 1991, meeting of the American Association of Physical Anthropologists in Milwaukee, Wisconsin. During our April meeting we resolved ambiguous issues and charged each participant to produce a final contribution in timely fashion. This volume is a result of that effort.

The final set of recommendations presented here is slightly modified from those generated at the NSF seminars. While most topics were well covered through individual assignments, the diversity of orientations and writing styles produced documents that required further editorial review. It was agreed that chapter authors would be collectively recognized and that the editors should rewrite and restructure the volume so that it would become an integrated set of recommendations that flowed logically and were presented in the same expository style. At this point the section on bone pathology became the collective responsibility of Buikstra, Ubelaker, and Owsley, with able assistance from Don Ortner. In addition to the topical chapters, a glossary and recommendations for determining intra- and inter-observer error have been added as appendices.

We recognize that the standards presented here are only a limited set of those necessary to meet the needs of contemporary and future researchers. If, however, these data are collected in systematic fashion from all repatriated remains, we will have learned a great deal concerning the lifeways of ancient peoples. Demography, health, interment procedures, diet, and genetic relationships will all be amenable to scientific study. In addition, we will have done our best to ensure that Native American remains ancestral to a given tribe, and not to a different tribe or to another cultural group entirely, will be returned to that tribe. We therefore recommend these standards to all institutions facing the imminent loss of skeletal remains, with the certainty that the knowledge gained will contribute to our appreciation of human history.

CHAPTER 2

RATIONALE AND SCORING PROCEDURES FOR SKELETAL INVENTORY

The initial step in recording skeletal remains is the creation of an inventory that serves both as a fundamentally important description of materials and as a basis for comparative statistical analyses. For a variety of reasons, most archaeologically recovered interments will not contain all bones from the human skeleton. Mortuary rituals may have involved corpse exposure and selective burial of body parts. Erosive forces, including soil acidity, root activity, and disturbance by burrowing animals, often destroy buried remains. Incomplete archaeological recovery and inappropriate curation procedures may also reduce the number of bones present in a collection.

The inventory is an important analytical tool for many forms of bioarchaeological research. Unusual bone frequencies may offer unique insight into mortuary rituals, while quality of preservation will affect investigations of heritage and health. Essential to comparative analyses is the ability to generate accurate frequencies for skeletal attributes such as nonmetric traits, bone fractures, trepanations, and lesions indicative of infectious disease. These frequencies *must* reflect accurate counts of both attribute presence *and* absence. The total number of observations and a count of individuals in the sample are unlikely to be identical due to the many cultural, taphonomic, archaeological, and curatorial factors that limit bone recovery and preservation. A count of healed fractures of the left humerus, for example, is relatively meaningless unless the number of left humeri that could be observed is also reported. Collecting both bone counts and completeness assessments for each skeleton in a format suitable for a computer data base is, therefore, critical to the inventory process.

Archaeologically recovered skeletal series may include relatively complete skeletons, commingled remains, and isolated bones. We have designed slightly different inventory procedures and recording forms for relatively complete skeletons (Attachment 1) and for commingled and incomplete remains, including isolated bones (Attachment 2). The Inventory Recording Form for Complete Skeletons (Attachment 1) is suitable for burial features which contain skeletons readily identified as individuals, even though more than one set of remains may have been placed in the feature. When bodies have been cremated as part of the mortuary ritual, a significant portion of the skeletal series may show the effect of burning. Any evidence of burning should be noted on the Recording Form for Burned Bone, as described in Chapter 9.

An archaeological sample may, of course, include interments that fall into each of these categories and thus require the use of both types of recording forms for a specific site or skeletal series. An articulated skeleton may, for example, have been included within a burial feature otherwise composed of commingled materials. Similarly, it is not unusual for crematory basins containing multiple, fragmented remains to occur in burial mounds largely composed of unburned, individual interments.

During the inventory process, the observer may wish to systematically screen for other attributes, such as pathology or postmortem change. If recording of these other attributes is to occur later, these bones should be tagged or otherwise identified as the inventory proceeds.

A complete, mature human skeleton contains 206 bones which have normally developed from 806 distinctive ossification centers. Our goal has been to develop an inventory process that will focus upon the bones and centers of ossification that are most important in skeletal biological research. While all bones will be

identified and recorded, bones from certain body regions such as the hands, feet, and thorax will be reported as counts rather than as individual elements. Permanent and deciduous teeth should be inventoried according to the procedures presented in Chapter 5.

The inventory forms presented as Attachments 1 and 2 can accommodate both juvenile and adult remains. For example, the space allocated for assessing vertebral centrum or body completeness is suitable for recording both immature and mature skeletons. Similarly, the condition of either epiphyses or articular ends of long bones can be recorded on the same inventory form. All skeletons—fetal, juvenile, and adult— should be inventoried.

In addition to reporting presence and completeness of remains on the inventory forms, we recommend that each skeleton, including isolated bones, be systematically photographed and radiographed. Assemblages of commingled remains should also be photographed. All dentitions should be cast and photographed. Standards and methods for photography and radiography are presented in the final section of this chapter, as are techniques for casting dentitions and suggestions for enhancing the quality of dental photography. We also recommend that observers use sketches to record the location of postmortem features such as cutmarks and evidence of carnivore gnawing (described in Chapter 9). Unusual or extreme conditions of any type, including abnormal bone remodeling due to disease (Chapter 10), trepanation, or cranial deformation (Chapter 11) should be recorded by indicating the location, extent, and texture of the anomaly (see the appropriate chapters below for recommended recordation procedures). We have provided a number of skeleton and individual bone outlines (Attachments 3-15) to facilitate recording this information.

CODING RELATIVELY COMPLETE SKELETONS

We begin by presenting the inventory procedure for relatively complete skeletons. To facilitate the inventory process, as well as other aspects of recording, the skeleton should, if possible, be placed in anatomical position on a flat surface in a well-lighted area. A separate Inventory Form for Complete Remains (Attachment 1) should be used to code each skeleton.

The inventory process recommended here emphasizes structures that have high information value for the variety of topics accessible through the study of archaeologically recovered human skeletons: genetic relationships, health, cultural practices, and demography. Completeness scores are designed to reflect details required for these investigations. For example, an articular region with a minor amount of postmortem erosion should be scored as complete, since studies of pathology are unlikely to be affected by this minor example of imperfect preservation. Similarly, a relatively large, heavily eroded femur segment should be scored as poorly preserved, reflecting its minimal information value. Thus, a bone (or designated section) will be considered complete when the majority of the element is present and available for observation of diagnostic features. Complete bones are coded as "1," while a code of "2" or partial indicates a reduced potential for attribute observation. Badly eroded or very incomplete materials are coded as "3," poor. Bones which are present but unobservable, as may be the case for materials recorded *in situ*, should be noted in the section for comments which is located at the end of the inventory form. Missing elements are recorded by leaving the space blank. This format is followed for the inventory of most bones, as noted below and summarized in Table 1.

SKULL

Cranial elements are coded as "1" (complete) if at least 75% of each bone is present. A code of "2" indicates that between 25% and 75% of the element has been preserved. When represented by fragments comprising less than 25% of the whole bone, cranial elements should be coded as "3" (poorly preserved). A blank space is used to report missing bones. It should be noted that the temporomandibular joint surfaces are recorded as structures distinct from the remainder of the temporal bones, using the same blank,1-3 coding system.

On the Inventory Recording Form for Complete Remains (Attachment 1), space has been provided to record left and right sides of all cranial bones. Even though some of these bones (frontal, occipital, sphenoid, mandible) normally fuse in the adult, we recommend recording each side of the fused bone separately. This will provide a better overall picture of the preservation of the skull, and will be especially useful in explaining why certain observations (e.g., of bilateral nonmetric traits; see Chapter 8) could only be made on one side of the skull.

Table 1
SUMMARY OF INVENTORY PROCEDURES FOR RELATIVELY COMPLETE SKELETONS

Cranial and Postcranial Bones other than Cervical Vertebrae 3-6; Thoracic Vertebrae 1-9; Ribs 3-10; Carpals, Metacarpals; Tarsals (except Talus and Calcaneus); Hand and Foot Phalanges. Limb long bone diaphyses should be divided into proximal, middle, and distal thirds. Each of these sections and the epiphyses (or articular surfaces) should be recorded separately.

blank = missing
1 = >75% present = complete
2 = 25% - 75% present = partial
3 = <25% present = poor

Cervical Vertebrae 3-6; Thoracic Vertebrae 1-9 ; Ribs 3-10. Record bodies (or centra) separately from neural arches. Record the total number of observable units, reporting C3-C6; T1-9; left and right ribs 3-10 separately. Then report the total count of complete units, according to the following standards:

Bodies/Centra: Complete = >75% present
Neural Arches: Complete = at least two articular facets observable
Ribs: Complete = head and neck present

Carpals, Metacarpals, Tarsals (other than Talus and Calcaneus); Metatarsals; Hand and Foot Phalanges. Score counts of each of these bone types, separating left and right elements (other than phalanges). Report first the number of bones present, followed by a count of the number of complete (>75% present) specimens.

Fragments not assigned to one of the above categories. Sort the bones into one of the following bone groups and report either by count or weight: skull, limb long bones, vertebrae, hand/foot, clavicle/scapula, os coxae, miscellaneous postcranial, and unidentifiable.

Postcranial Bones Other Than Limb Long Bones

Postcranial bones are coded in much the same manner as the skull. The clavicle, manubrium and body of the sternum, sacrum, patella, talus, and calcaneus are coded as complete when at least 75% of each bone is present. Partial presence ("2") is recorded for bones 25-75% complete. If less than 25% is present, the appropriate code is "3," with a blank used to indicate missing elements.

For the scapulae, vertebrae, ribs, and os coxae, the same percentages are used, but there are additional provisions. The glenoid fossae of the scapulae, for example, are coded separately, as are other articular (joint) surfaces (see *Limb Long Bones* below).

Centra[1] (or bodies) and neural arches of the vertebrae are recorded as distinctive observational units. At least 75% of a body (or centrum) must be present and observable for a code of "1" (complete). Since the primary areas of interest in the neural arch are the superior and inferior articular surfaces, at least two articular surfaces must be observable for a code of "1" (complete). If fewer than two articular facets are observable, the neural arch should be considered partially represented (code "2"). The scoring system for the third through sixth cervical vertebrae (C3-C6) and the first through ninth thoracic vertebrae (T1-T9) asks the observer to report separately a count for total numbers of neural arches and bodies (centra). Additional columns request counts for the number of *complete* neural arches and bodies. The difference between the number present and the number complete indicates the number of partial neural arches and bodies in the specified section of the vertebral column.

Ribs 1, 11, and 12 are reported separately. Ribs 3-10 are grouped, separated by side, and then recorded first as a count of number present and secondly as number complete. To be recorded as complete, the head and neck of a rib must be present and observable; otherwise, it is coded as partial.

The three primary units (ilium, ischium, and pubis) of the os coxae are reported as complete (code "1") when at least 75% of each is present. The acetabulum and the auricular surfaces (the articular surfaces) are coded separately.

Counts of carpals, metacarpals, tarsals (other than the talus and calcaneus, which are recorded separately), metatarsals, hand phalanges, and foot phalanges are reported in terms of total present and number complete. At least 75% of each bone must be present and observable for it to be reported as complete. Carpals, metacarpals, tarsals (other than the talus and calcaneus), and metatarsals should be separated by side, if possible. Space is also provided for recording unsided hand and foot bones, including phalanges.

Limb Long Bones

The format for scoring long bones is especially detailed. Three sections of each diaphysis (shaft), representing the proximal, middle, and distal thirds are reported separately. At least 75% of each unit must be present for the section to be considered complete, and coded as "1." Representation between 25% and 75% is recorded as "2." If less than 25% is present, the section is coded as "3" (poorly preserved). Leaving the space blank is used to indicate the complete absence of an observational unit. Experience with similar coding schemes has indicated that these percentages are appropriate thresholds for recording information from long bone sections.

Coding for the proximal and distal articular surfaces or epiphyses also follows the general postcranial coding format. At least 75% of the articular surface must be present for a code of "1" (complete). Between 25-75% representation is reported as "2," and <25% as "3." Absence is reported as a blank.

Other Fragments

Fragments that cannot be assigned to the above categories should be grouped into one of the following clusters and reported either as fragment counts or weights: skull, limb long bones, vertebrae, hand/foot, clavicle/scapula, os coxae, miscellaneous postcranial, and unidentifiable. If the number of fragments is small, notations in the Attachment 1 Comments Section should be sufficient. If large numbers of fragments are present, Attachment 2 should be used (see next section).

[1] For convenience, "centrum" and "epiphysis" are used in the inventory form. Centrum should be considered equivalent to "body" in the mature vertebra. Similarly, epiphysis and articular region (or surface) should be considered equivalent.

CODING COMMINGLED OR INCOMPLETE REMAINS

Basic Procedures

The procedure for recording commingled remains is slightly modified from that for individual skeletons. First the bones from each archaeological context should be sorted by the inventory-based units defined above. Bones recorded individually, such as parietals and femurs, should be sorted by element and by side. Bones recorded in clusters, such as left and right ribs, hand and foot phalanges, third through sixth cervical vertebrae, should be grouped together. These elements should then be inventoried on the Inventory Recording Form for Commingled Remains and Isolated Bones (Attachment 2). Elements are recorded by entering the name of the bone, side, segment (i.e., proximal epiphysis, distal 1/3 of diaphysis), relative completeness, MNI (minimum number of individuals), and Count/Wt (weight), thus requesting the same level of detail as reported for relatively complete skeletons.

The new entries are MNI and Count/Wt. MNI refers to the minimum number of individuals represented by the elements reported on this line. For example, if five complete left temporals are recorded on a line, the MNI would be "5". Count/Wt is used to report highly fragmented materials grouped into the following categories: skull, limb long bones, vertebrae, hand/foot, clavicle/scapula, os coxae, miscellaneous postcranial, and unidentifiable.

Space is also provided for age-at-death and sex estimates, which should be based upon methods described in Chapter 3, 4, 5, and 6. In commingled contexts, the observer frequently can only distinguish immature from mature materials; more rarely can infants, children, adolescents and adults of various ages be identified. Under the heading, age, counts for the most precise estimates possible should be entered. If chronological age estimates more restrictive than the following categories can be made, they should be recorded. Otherwise, whenever possible, these categories should be used:

#F = #Fetal (<birth)
#I = #Infants (b - 3 years)
#C = # Children (3 - 12 years)
#AO = # Adolescents (12-20 years
#YAd = # Young Adults (20-35 years)
#MAd = # Middle Adults (35-50 years)
#OAd = # Old Adults (50+ years)

In other cases, it will only be possible to distinguish juvenile **(#J)** from adult **(#Ad)** remains. Elements from adults may also provide a basis for sex diagnosis. Sex estimates should be recorded as

#M
#M?
#F
#F?
or "?"

depending upon degree of certainty, as discussed in Chapter 3.

The observer may choose to enter information for bones (or segments) in identical states of preservation on a single line, or s/he may wish to list all observations for specific elements on one line. If multiple states of preservation are reported, then it is important that the information coded in the age/sex columns follow the order presented for completeness. For example, the sequence Temporal / Left / (blank) / 1, 1, 2 / 3 / 1J, 2Ad / 1?, 1M, 1M? reports three left temporals, including one complete element from a juvenile, another complete specimen from a male adult, and a third piece which is incompletely represented and is perhaps from a male.

Cremations (and Other Burials Containing Highly Fragmented Bones)

Burned remains may include relatively complete, individual skeletons or they may be composed of highly fragmented and/or commingled materials. Isolated, relatively complete skeletons should first be inventoried according to procedures outlined above for unburned individual remains. Degree and pattern of burning should then be recorded following the methods outlined in Chapter 9. An appropriate method for photographing cremated remains is provided in the following section of this chapter.

Cremations frequently include materials that are both highly fragmented and commingled. In these instances, bone identifications should first be recorded according to the format for commingled materials (above), supplemented by information on color, texture, and warping, as described in Chapter 9. When sorting fragmented materials, it may be helpful to create sorting blocks within a large grid drawn on paper or cardboard. Depending on degree of fragmentation, the blocks may represent individual bones, as in the individual inventory, or bone clusters: skull, limb long bones, vertebrae, hand/foot, clavicle/scapula, os coxae, miscellaneous postcranial, and unidentifiable. Within each category, juvenile fragments should be isolated from adult remains and sex diagnoses made on appropriate materials. Bone identification, completeness, age, and sex information should be recorded on the Inventory Form for Commingled Remains (Attachment 2). Counts or weights within each category, subdivided by color, texture, and evidence of warping should then be entered on the Coding Form for Burned Bone presented in Chapter 9.

RECORDING IMAGES: PHOTOGRAPHY, RADIOGRAPHY, CASTING, AND SKETCHES

Methods for reproducing skeletal images are developing rapidly. Techniques such as CT scans hold promise for establishing three-dimensional reproductions of skeletal structure sufficient for accurate osteometry. Computer-aided archives of images are also possible (Vannier and Conroy 1989a, 1989b). While these methods hold great promise, factors of cost and equipment accessibility have led us to recommend more traditional approaches to data and image recording: photography, radiography, casting, and sketches.

Some laboratories report positive results through videotaping an overview of the remains, accompanied by a verbal description of observations, such as the criteria used for estimating age and sex, and examples of anomalies or pathology. If a videotape is created, provisions must be made to renew the film each 7-10 years, or the record will be lost.

Photography

What to Photograph

Systematic black-and-white photographs should be taken as a primary visual archive. When stored under cool (<70 degrees Fahrenheit) and relatively dry (ca. 30% humidity), black-and-white negatives should be stable for an indefinite period. Depending upon the film and use, color transparencies must be renewed periodically (every 10-20 years). We therefore recommend that black-and-white film comprise the primary archive, as described below. Color slides should be taken of features that may be used in oral presentations or that may be difficult to fully represent in black and white. Recurrent and unusual pathology (#5 below) and cultural modifications (#6), for example, should be subject both to black-and-white and color photography.

As a first priority, we recommend that each of the following be photographed:

1. All complete crania: from anterior, lateral, superior, and basilar aspects. Care should be taken to orient each cranium such that the plane of the film is in the coronal (facial or anterior view), sagittal (lateral view), and transverse (superior and basilar views) planes. In the lateral view, the Frankfurt plane should be oriented horizontally.

2. Dentitions: closeups of dental arcade or individual teeth from buccal/labial, lingual, and occlusal aspects. Special techniques for photographing teeth are discussed below.

3. All structures observed for estimation of sex: subpubic region of the os coxae, including detail of pubic element; greater sciatic notch (os coxae). If the skull is insufficiently complete for photography described under "1" above, portions used for sex diagnosis should be photographed.

4. All structures used for estimating maturational status. In adults, both auricular surfaces and pubic symphyseal faces of the os coxae should be photographed. If not recorded under "1" above, palatine and cranial sutures should also be represented. For juveniles, special care should be taken to record maturational status of the dentition. Since diaphyseal lengths will be measured, these need not be photographed systematically. Examples of partially fused or recently fused epiphyses should be recorded.

5. All unique forms of pathology and representative examples of recurrent pathology.

6. All unique examples of cultural modifications of bones and teeth, such as trepanations, inlays, or filed teeth. Representative examples of cutmarks and taphonomic changes should also be recorded. If the standard photographs indicated in "1" and "2" are insufficient to fully capture dental modifications and cranial deformation, then additional photographs should be taken.

7. Mass burials with intentional breakage should be photographed in their entirety. This provides a record of bone reduction that cannot otherwise be easily recorded by numerical scoring of bone size and breakage patterns.

Photographic Equipment and Technique for Unburned Bones

(after White and Folkens 1991: 294-300; 427-429)

Most osteological photography is conducted with 35 mm single lens reflex cameras.[2] While a 55 mm lens with a macro close-up capability provides satisfactory results, White and Folkens (1991: 295) recommend a 105 mm with macro. The systematic, archival photographs described above should be made with black-and-white films, such as Kodak TMAX 100™, Plus-X Pan™, or Ilford FP4™ (ISO 80 to 125). Color transparencies for publication in color or slide presentations should be made of representative examples of recurrent pathologies and cultural modifications. Kodachrome™ (ISO 64) is suitable for most color work, unless low lighting conditions exist. Color films should be appropriate for the available light source, as indicated in film packaging and standard photography texts. Incandescent and fluorescent lighting produce undesirable color distortions.

Normally an electronic flash or photo lamps (quartz halogen or tungsten) are required for recording bones in laboratory settings. When using color film, placing bones on a black velvet background will enhance color accuracy and eliminate shadows. For black-and-white photography, bones placed on a nonglare glass suspended above the base of a copy stand provides good results. A light box may also be used, establishing the exposure features with the lights off, and turning them on prior to taking the photograph. An 18% gray card, commercially available, and held in front of the lens when setting exposure features, is also useful. Whether relying on automatic features of the camera or establishing settings oneself, it is important to expose and develop an "experimental" roll of film (both b/w and color) early in the recording process to ensure that appropriate technique is being followed.

Each photograph should contain a metric scale and a card identifying the context for the specimen. Care should also be taken to create a complete log of photographs, which should be stored with the negatives and transparencies. Original archival photographs and transparencies should never be lent. Instead copies should be made for publications or presentations.

Photographic Techniques for Cremated Remains

Color variation in cremations that consist of many small bone fragments can be recorded efficiently by photographing them on a light box or other backlit surface with gray scale and color separation guides included

[2]If a medium format (6 x 6 cm format) camera is available, this will produce sharper images (see White and Folkens 1991: 295).

in the image. Small guides suitable for this type of photography can be obtained from:

Graphics Imaging Systems Division
Eastman Kodak Company
Rochester, New York 14650
(ask for Publication NO. Q-13)

When taking the photographs, turn off the backlighting and adjust the top- lighting so that there is even illumination over the surface of the light box. After determining the proper exposure, turn the backlight on and take the photograph. To maximize the value of such images for digital image analysis, make certain that the intensity of the backlighting is greater (1.5-2 f-stops) than that of the toplighting. This will allow the background to be clearly distinguished from the bones being photographed. It is also important to make a calibration photograph to record your lighting setup. To do this, take a photograph of the light box without any object on it, turning the backlight off and the toplights on. This photograph can be used by image analysis systems to compensate for uneven illumination.

Photographic Equipment and Technique for Teeth

All teeth should be photographed from buccal/labial, lingual, and occlusal aspects. The translucent nature of the tooth crown may require special preparation of enamel surfaces for high quality results. While a coating device designed for SEM work can be used to cover the surface with carbon, a technically simpler alternative is granular ammonium chloride. The procedure renders the enamel surface opaque and creates a matte appearance. Here we describe the method appropriate to isolated teeth, which can also be modified for intact dentitions.

Approximately 15 grams of granular ammonium chloride should be heated for nearly five minutes in a test tube held by tongs over a Bunsen burner until it begins to smoke. As the powder solidifies, move the test tube so that the flame approaches the mouth of the tube. Each tooth, held by tweezers or mounted with clay on a glass microscope slide, should be passed through the smoke column until it is evenly coated. if the smoke is applied too thickly, the surface layer will flake away from the enamel and obscure detail. Roughly 40 teeth can be coated with 15 grams of ammonium chloride. After coating, special care must be taken during transport to keep the dusted crowns from contacting other surfaces and becoming damaged. Photography should follow soon after treatment, as the ammonium chloride will absorb moisture from the air and become transparent within a few hours. Oblique lighting will produce black-and-white photographs with fine surface detail. This procedure should not be used for color photography or for teeth whose discoloration indicates an abnormal condition such as fluorosis or a cultural practice such as tobacco use.

RADIOGRAPHY

We recommend that standard radiographs be taken of each skeleton in order to survey remains for hidden abnormalities and to document bony reaction near grossly visible lesions. As a minimal requirement, the following radiographs should be taken of each skeleton. Posterior-anterior positioning, placing the bone as close as possible to the film, is recommended.

1. Cranium: Two views:posterior- anterior and lateral. Cranium should be oriented as for photography, with coronal and sagittal planes parallel to the plane of the film; 24 x 30 cm film is suitable for cranial radiographs.

2. Mandible: Views should maximize exposure of the dentition. An intact mandible will require a minimum of three views: one from each side and a posterior-anterior exposure. Radiographs of immature mandibles and maxillae should be taken from angles optimal for visualising dental development.

3. Long Bones: All long bones should be radiographed, anterior aspect toward film. Multiple bones of the same density can be placed on the same film, recognizing that the least distortion is achieved from exposure to the central ray. The largest commercially available film, 35" x 43" will normally be large enough for long bones, although the femur usually must be positioned obliquely.

4. All bones that show abnormal conditions: Multiple views should be recorded in order to fully document the condition. Bones should be positioned to minimize overlap between multiple lesions and between lesions and other skeletal structures.

If facilities for radiography do not already exist within your laboratory, assistance should be solicited from radiology departments within medical schools or hospitals. Standard medical techniques can readily be adapted to skeletal remains, with the technique depending upon the equipment, the film, and bone density. A film to tube distance of 48" is recommended. Although adequate results can be obtained from standard medical radiographic film, some researchers have reported superior resolution when mammography film-screen combinations and techniques adapted to dry bone are used. A centimeter scale and density step wedge should appear in all exposures, as should identifying numbers for each skeleton. Documentation concerning technique and film type should become part of the permanent record for the collection, curated along with the x-rays.

Dental Casts

Casting the dentition of human skeletons provides a permanent record that can be used for subsequent observations of dental morphology, occlusion, caries, and other dental lesions. We recommend that all teeth, including both the primary and secondary dentitions, be cast in dental stone. High resolution casting for recording hypoplasias and microwear using vinyl polysiloxane impression material is described in Chapter 5 and can be used for casting the full dentition. The polysiloxane method is, however, very expensive and is not necessary to provide the level of detail required for observing morphological variation.

An alternative technique which is relatively inexpensive requires the use of Alginate, dental stone, and dental impression trays such as those standardly used in clinical dentistry. A disadvantage to the Alginate method is that only one cast can be made from a single mold, whereas multiple casts can be created from the polysiloxanes (or other latex materials). It is also necessary to use the molds within a few hours of taking the impressions.[3]

Alginate, dental stone, and plastic impression trays can be purchased from any dental supply company, while all other necessary materials such as mixing bowls and spatulas are generally available. Purchasing a casting vibrator from a dental supply company is recommended, since it will improve the quality of the casts and simplify production.

Maxillae and mandibles should be checked for loose teeth and fragmented bone, and repaired with Duco™ cement. The teeth and alveolus should then be soaked in water for two to five minutes and drained. Select a suitably sized impression tray which allows three to five millimeters of space between the teeth and the side of the tray. Mix the Alginate according to directions, completely fill the tray with the Alginate mixture, and immediately press the tray onto the dental arch. Remove the tray and Alginate mold from the teeth, rinse the mold with water, and inspect for quality. If the mold appears to represent the dentition satisfactorily, then the casting material should be prepared by mixing the laboratory stone powder with the amount of water specified in the directions. Place the tray with the Alginate mold on the vibrator and spoon in a small quantity of the laboratory stone mixture, allowing the stone to flow into the occlusal cusp depressions. Slowly add more stone until the mold is filled. Build up the stone to make a base for the cast and place on a flat surface, occlusal side up, until all heat is dissipated from the cast. When the cast has cooled or "cured," remove the Alginate mold, inspect the cast for air bubbles, and repeat the procedures if not satisfactory. When adequately padded to prevent mechanical damage, the dental casts can be stored indefinitely.

[3]This discussion has benefited from the information conveyed by Ginger Ridgway, San Diego Museum of Man during the dental casting workshop she presented to the Paleopathology Association during April, 1991.

SKETCHES

As Attachments 3-10 we present outlines of adult and juvenile skeletons, six views of the skull, and renderings of selected postcranial bones. These attachments should be copied and used as the basis for sketches of such features as extreme examples of pathology or unusual anomalies. The locations of other bone modifications, such as cutmarks, trepanations, and evidence of gnawing by carnivores or rodents, can also be recorded on these images. Whenever they are used, the sketches should be attached to the appropriate data recording form.

CHAPTER 3

DOCUMENTATION OF SEX DIFFERENCES AND AGE CHANGES IN ADULTS

Accurate age and sex estimates in human skeletal remains are basic to studies of past adaptations and demographic histories. Age and gender-based differences in diet, disease, activity patterns, and mortuary practices are all accessible through investigations of human skeletal materials. Skeletal studies can also provide temporal perspectives on human demography that are available from no other source.

The goal of this section is to develop standards for recording skeletal features known to vary by age and sex among adult humans. While the observer has the option of providing an estimate of age and sex at the close of the exercise, the principal goal is developing a descriptive data base. Researchers may choose to weigh the importance of specific structures differently, both now and in the future, as new knowledge about skeletal sexual dimorphism and maturation becomes available. We therefore emphasize accurate description rather than the summary age or sex statements. This emphasis is reflected in the composition of Attachment 11, a recording form for attributes reflecting adult age and sexual dimorphism.

In developing recommended standards for age estimates we recognize that there are several commonly used techniques for linking observed maturation stages (biological age) with chronological age. For example, in the case of recording age-related structures of the pubic symphysis, two frequently used methods are recommended: Todd and Suchey-Brooks. By contrast, in developing standards for evaluating degree of cranial suture closure, we have combined and simplified several recording systems in an effort to maximize information and efficiency. Researchers using multivariate approaches to estimate age-at-death will doubtless wish to combine the data presented in this chapter with other age-associated changes, such as dental attrition, tooth loss, arthritic changes, and radiographic evidence (see Chapters 5 and 10). Histological techniques that focus upon age changes within teeth and long bones also facilitate age estimates. Chapter 12 includes materials appropriate for histological estimates of age within the suite of recommended samples to be selected for permanent curation.

Comprehensive reports of sex ratios should combine the morphological information defined in this chapter with analyses of cranial and postcranial measurements. Many of the metric data requested in Chapter 7 are known to reflect sexual dimorphism.

The standards developed here have been selected for their value in age and sex assessments of archaeologically recovered materials. Additional methods, although accurate for estimating age and sex in forensic cases, are frequently inappropriate for most archaeological collections. For example, age-related morphological changes at the sternal extremity of the fourth rib (Loth and Iscan 1989), useful when that rib is well preserved, are usually not helpful in archaeological materials which are fragmented and incomplete. As indicated in Chapter 12, however, we do recommend that a rib be retained, so that it can be observed when the promising sternal extremity technique is refined in a manner more suitable for archaeological collections. An extensive summary of techniques useful in estimating age in well preserved skeletons can be found in Krogman and Iscan (1986); Ubelaker (1989a, 1989b), and Zimmerman and Angel (1986). Techniques popular in Europe are summarized by Acsádi and Nemeskéri (1970), Ferembach et al. (1980), and Knussman (1988).

SEX DETERMINATION

Within any human population, adult male and female skeletons differ in both general shape and size. Estimates of sex should therefore be based both upon measurements of dimorphic dimensions, such as the maximum diameter of the femur head or maximum facial breadth (bizygomatic diameter), and observations of morphological features known to differ between males and females. Measurements appropriate to the development of standards for estimating sex are included in Chapter 7.

Any attempt to develop standards for estimating sex in human skeletal remains must recognize that patterns of sexual dimorphism vary among human groups. Therefore, the application of metric standards developed from populations remote in time and space from the study sample is to be avoided. Similarly, patterns of morphological features, other than a limited number noted for the os coxae, are typically population-specific. Estimates of sex therefore can be difficult if the observer is not familiar with the overall pattern of variability within the population from which the sample is drawn.

Within all human groups, growth changes during adolescence lead to distinctive differences in the male and female os coxae. The female pelvic outlet is expanded relative to its height while male growth trajectories generally follow a preadolescent pattern (Coleman 1969). Therefore, adolescent hip bones presenting typically female features can confidently be diagnosed as female. A male pattern observed in an adolescent os coxae should be considered inconclusive, however, because the remains may represent a female whose pelvic dimensions have not yet assumed adult proportions. Conversely, male skulls may retain a gracile, female appearance during adolescence. Adolescent skulls presenting male characteristics may therefore be more confidently diagnosed as male than may the more ambiguous gracile cranium. The use of cranial features is additionally complicated by age-related changes in dimorphism during adulthood. For both males and females, there is a tendency for the skull to exhibit an increasingly "masculine" morphology with increasing age (White and Folkens 1991; Meindl et al. 1985). As yet there are no standards for diagnosing sex in juvenile materials considered acceptable by most osteologists (Saunders 1992).

The following discussion emphasizes dimorphic features of the os coxae and the skull. More extensive discussion of male and female skeletal sex differences may be found in Bass (1987); Buikstra and Meilke (1985), Krogman and Iscan (1986); Phenice (1969), Ubelaker (1989a, 1989b); White and Folkens (1991).

Os Coxae Morphology

The hip bones present the most reliable indicators of sex in the human skeleton. In this exercise we have chosen to emphasize attributes of the subpubic region (Phenice 1969), the form of the greater sciatic notch, and the presence of a preauricular sulcus. A cast series that usefully illustrates examples of the three subpubic features emphasized here is available from France Casting, Dr. Diane L. France, 20102 Buckhorn Road, Bellvue, CO 80512.

Attributes of the subpubic region should be scored as:

blank = Unobservable
1 = Female
2 = Ambiguous
3 = Male

ventral arc
subpubic cavity
ischiopubic ramus ridge

The structures to be recorded for the subpubic region include the ventral arc, the subpubic concavity, and the ischiopubic ramus ridge. These structures are illustrated in Figure 1. Females present positive expressions of these attributes. According to Phenice (1969), the ventral arc is the most reliable indicator; the ischiopubic ramus ridge, the least.

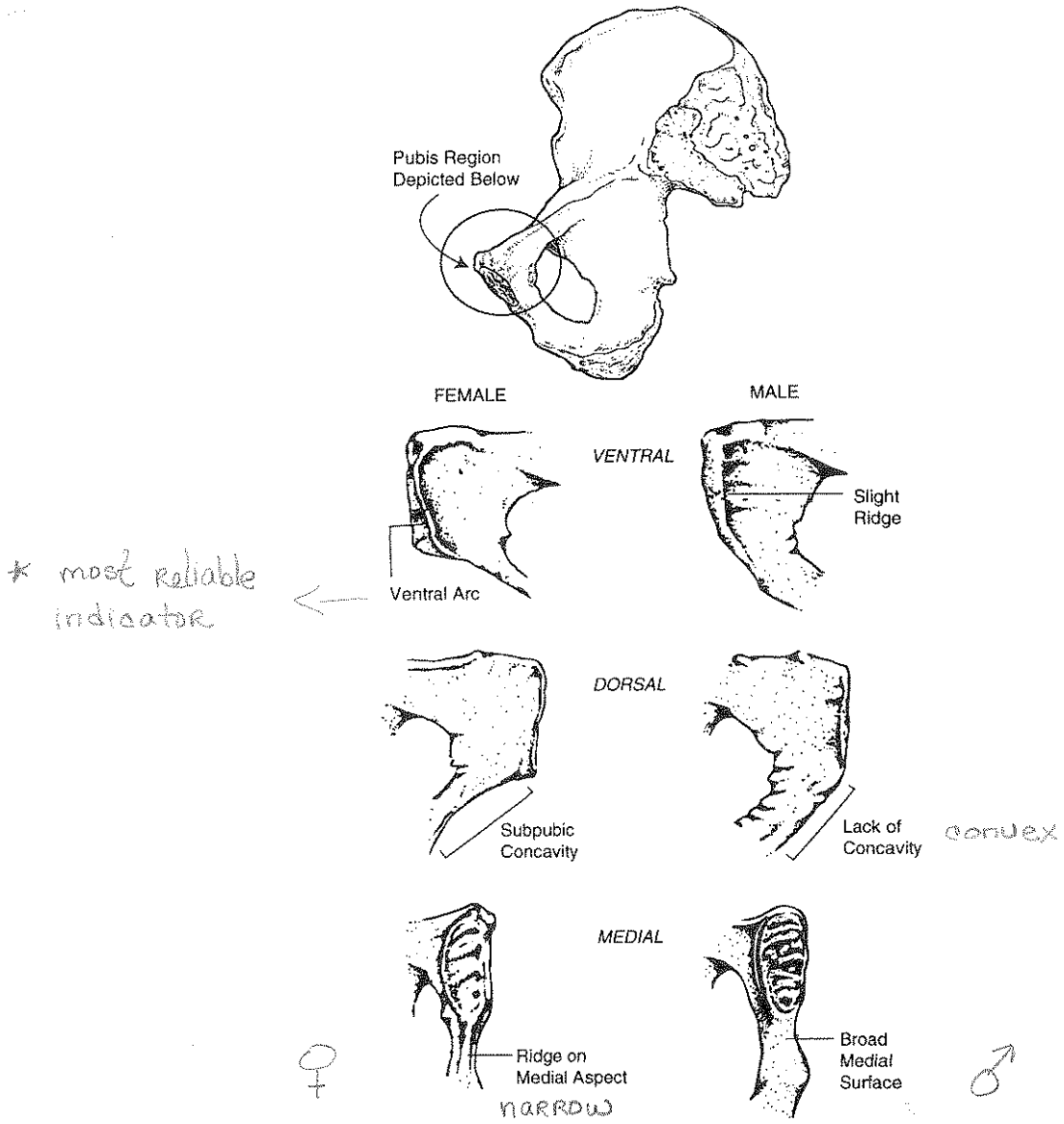

Figure 1. Sex differences in the subpubic region: Phenice's technique for sex determination. Drawing by Zbigniew Jastrzebski (after Buikstra and Mielke 1985; Phenice 1969).

Ventral Arc: The ventral arc (ventral arch ridge) is a slightly elevated ridge of bone across the ventral surface of the pubis (Figure 1: top). To facilitate scoring this feature, the pubis should be oriented with the ventral surface directly facing the observer.

Subpubic Concavity: This feature is found on the ischiopubic ramus lateral to the symphyseal face. In females the inferior border of the ramus is concave, in males it tends to be convex. This observation should be made while viewing the dorsal surface of the bone (Figure 1: middle).

Ischiopubic Ramus Ridge: The medial surface of the ischiopubic ramus immediately below the symphysis forms a narrow, crestlike ridge in females. This structure is broad and flat in males (Figure 1: bottom).

The ***Greater Sciatic Notch*** tends to be broad in females and narrow in males. The shape of the greater sciatic notch is, however, not as reliable an indicator of sex as the conformation of the subpubic region due to a number of factors, including the tendency for the notch to narrow in females suffering from osteomalacia. Figure 2 should be used in recording greater sciatic notch form. The best results will be obtained by holding the os coxae about six inches above the diagram so that the greater sciatic notch has the same orientation as the outlines, aligning the straight anterior portion of the notch that terminates at the ischial spine with the right side of the diagram. While holding the bone in this manner, move it to determine the closest match. Ignore any exostoses that may be present near the preauricular sulcus and the inferior posterior iliac spine. Configurations more extreme than "1" and "5" should be scored as "1" and "5" respectively. The illustration numbered "1" in Figure 2 presents typical female morphology, while the higher numbers show masculine conformations.

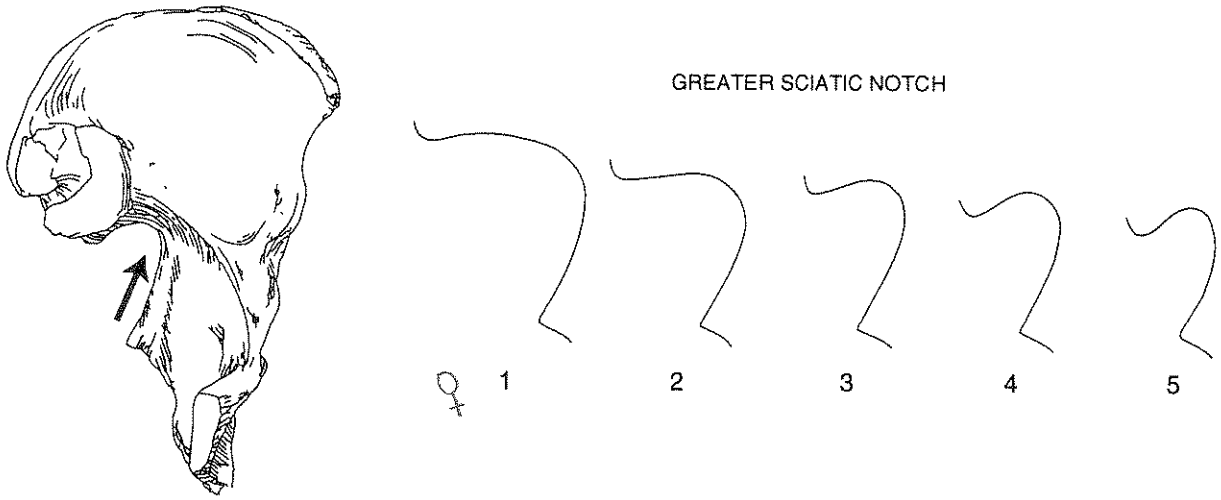

Figure 2. Sex differences in the greater sciatic notch. Drawing by P. Walker.

In addition to these features, the ***Preauricular Sulcus*** is thought to appear more commonly in females than in males. Figure 3 represents variation in preauricular sulcus form. Four positive expressions (2-4 below), as well as absence (1), should be recorded.

0 = (not illustrated) Absence of preauricular sulcus. The surface of the ilium along the inferior edge of the auricular surface and continuing into the greater sciatic notch is generally smooth. In some specimens, this surface may be roughened slightly where ligaments attach during life.

1 = The preauricular sulcus is wide, typically exceeding 0.5 cm, and deep. The walls of the sulcus are transected by bony ridges that make the sulcus appear as if it is composed of a series of lobes. The preauricular sulcus typically extends along the entire length of the inferior auricular surface, often undercutting it.

2 = The preauricular sulcus is wide (usually greater than 0.5 cm) but shallow. The base of the groove is slightly irregular, but bony ridges, if present, are not as marked as in Variant 1. The sulcus usually extends along the entire length of the inferior auricular surface.

3 = The preauricular sulcus is well defined but narrow, less than 0.5 cm deep. Its walls are either undulating or smooth. The sulcus extends along the entire length of the inferior auricular surface. A sharp, narrow bony ridge is typically present on the inferior edge of the preauricular sulcus, and it frequently extends along the entire inferior edge of the groove.

4 = The preauricular sulcus is a narrow (less than 0.5 cm), shallow, and smooth-walled depression. It lies below only the posterior part of the auricular surface. A sharp, bony ridge may be found on the inferior edge of the sulcus; if present, it does not extend the entire length of the sulcus.

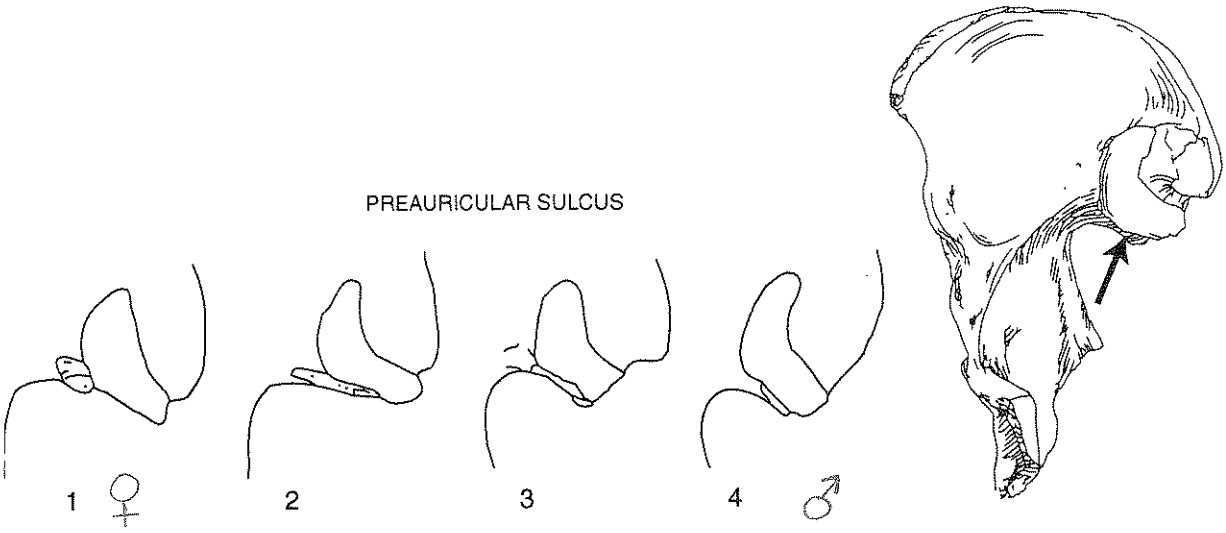

Figure 3. Scoring system for preauricular sulcus. Drawing by P. Walker (after Milner 1992).

Cranial Morphology

Although males tend to have larger, more robust skulls than females, estimating sex based on cranial features can be a challenging process. Populations vary markedly in this respect. For some groups, cranial morphology provides a reliable basis for sex determination; for others, it does not. While the measurements reported in Chapter 7 summarize dimensional elements of dimorphism, there are other attributes of size, shape, and robusticity that should be recorded in order to develop an estimate of sex based on cranial features. We have chosen to emphasize five aspects of skull morphology, as illustrated in Figure 4: robusticity of the nuchal crest, size of the mastoid process, sharpness of the supraorbital margin, prominence of glabella, and projection of the mental eminence. In all cases, a five-point scale is used, with the more gracile, feminine features at the lower end of the range.

In recording these features, optimal results are obtained by holding the cranium (or mandible) at arm's length a few inches above the appropriate portion of Figure 4, oriented so that the features observed can be directly compared with those illustrated. Move the bone from diagram to diagram until the closest match is obtained. Score each trait independently, ignoring other features. Specific procedures for each of the traits are listed below. The most extreme forms of each feature are defined here, with intermediate grades illustrated visually in Figure 4.

Nuchal Crest: View the lateral profile of the occipital and compare it with the diagrams. Feel the surface of the occipital with your hand and note any surface rugosity, ignoring the contour of the underlying bone. Focus upon the rugosity attendant to attachment of nuchal musculature. In the case of minimal expression (score = "1"), the external surface of the occipital is smooth with no bony projections visible when the lateral profile is viewed. Maximal expression (score = "5") defines a massive nuchal crest that projects a considerable distance from the bone and forms a well-defined bony ledge or "hook."

Mastoid Process: Score this feature by comparing its size with that of surrounding structures such as the external auditory meatus and the zygomatic process of the temporal bone. Mastoid processes vary considerably in their proportions. The most important variable to consider in scoring this trait is the volume of the mastoid process, not its length. Minimal expression ("1") is a very small mastoid process that projects only a small distance below the inferior margins of the external auditory meatus and the digastric groove. A massive mastoid process with lengths and widths several times that of the external auditory meatus should be scored as "5."

Supraorbital Margin: Begin by holding your finger against the margin of the orbit at the lateral aspect of the supraorbital foramen. Then hold the edge of the orbit between your fingers to determine its thickness. Look at each of the diagrams to determine which it seems to match most closely. In an

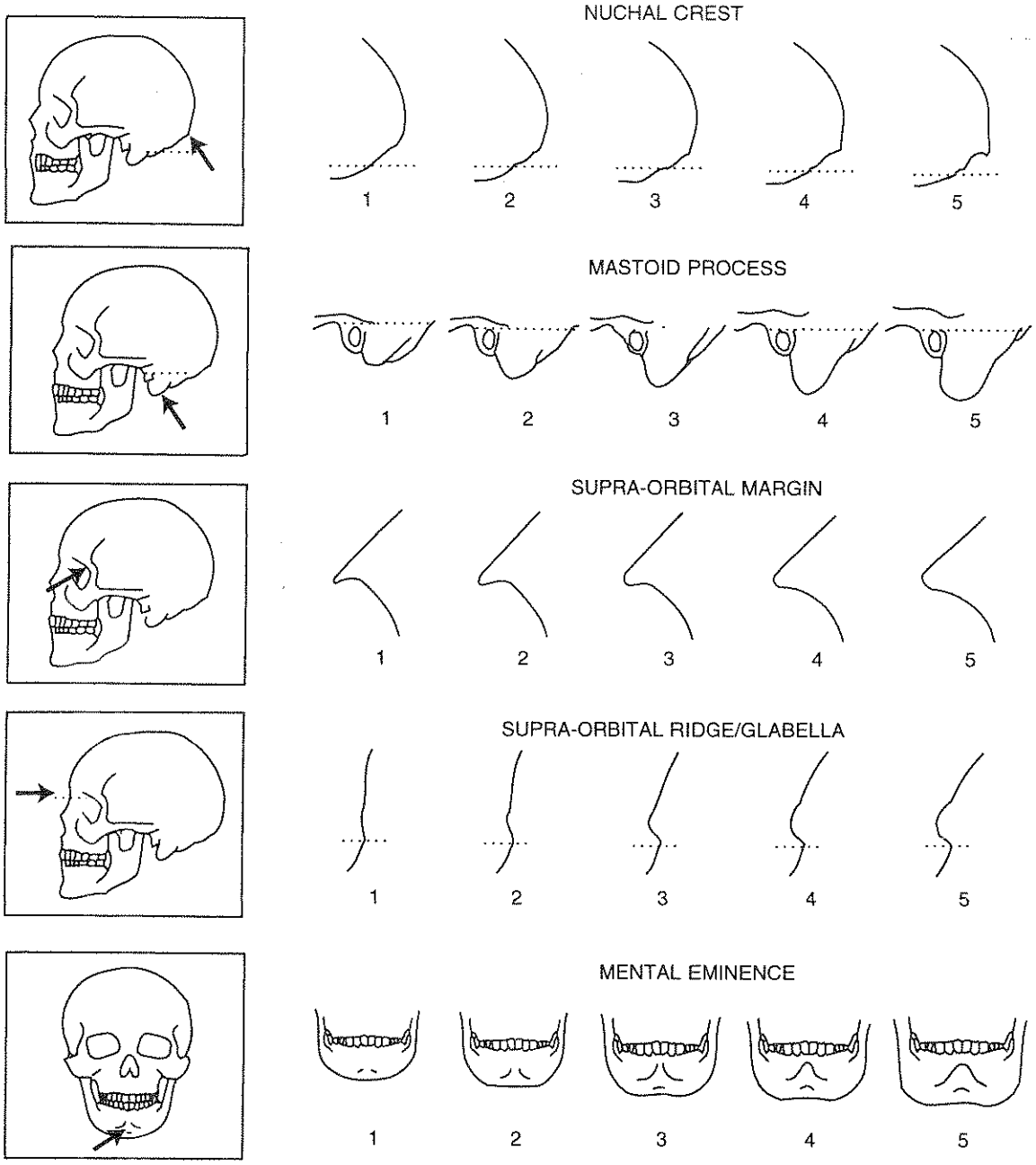

Figure 4. Scoring system for sexually dimorphic cranial features (after Acsadi and Nemeskeri 1970, Figure 16).

example of minimal expression ("1"), the border should feel extremely sharp, like the edge of a slightly dulled knife. A thick, rounded margin with a curvature approximating a pencil should be scored as "5."

Prominence of Glabella: Viewing the cranium from the side, compare the profile of the supraorbital region with the diagrams. In a minimal prominence of glabella/supraorbital ridges ("1") the contour of the frontal is smooth, with little or no projection at the midline. Maximal expression involves a massive glabellar prominence, forming a rounded, loaf-shaped projection that is frequently associated with well-developed supraorbital ridges.

Mental Eminence: Hold the mandible between the thumbs and index fingers with thumbs on either side of the mental eminence. Move the thumbs medially until they delimit the lateral borders of the mental eminence. In examples of minimal expression ("1"), there is little or no projection of the mental eminence above the surrounding bone. By contrast, a massive mental eminence that occupies most of the anterior portion of the mandible is scored as "5."

Estimated Sex

Record estimates for the os coxae and the skull separately based on your overall assessment of all sexually dimorphic structures. Assign each individual to one of the following:

0 = ***undetermined sex.*** Insufficient data are available for sex determination.
1 = ***female.*** There is little doubt that the structures represent a female.
2 = ***probable female.*** The structures are more likely female than male.
3 = ***ambiguous sex.*** Sexually diagnostic features are ambiguous.
4 = ***probable male.*** The structures are most likely male than female.
5 = ***male.*** There is little doubt that the structures represent a male.

DOCUMENTATION OF AGE CHANGES

The age-related changes discussed in this section are limited to those that occur in the pubic symphysis, the auricular surface of the ilium, and the cranial sutures. Both the Todd and the Suchey-Brooks systems are used for recording changes of the symphyseal face. Developmental stages for each of these four methods should be reported, according to the phases listed in the following sections.

Several late fusing skeletal elements, such as the epiphysis of the clavicle, the iliac crest of the os coxae, and the basioccipital synchondrosis are also useful for distinguishing young adults from older individuals. Chapter 4, which focuses upon subadult maturation and measurement, discusses procedures for scoring these attributes. Other forms of age-related changes, including dental wear, premortem tooth loss, and osteoarthritis, will be discussed in Chapters 5 and 10.

Pubic Symphysis

Morphological changes of the pubic symphyseal face are considered to be among the most reliable criteria for estimating age-at-death in adult human remains. To apply any of the standards commonly used to develop age estimates, attention must be paid to proper orientation of the pubis and to recognition of certain key features: ridge-and-furrow system, dorsal margin, dorsal platform, ventral rampart, ossific nodules, rim, and delimited extremities. With the dorsal aspect to the left and the superior extremity up, the composite symphyseal face presented in Figure 5 illustrates the proper orientation of the pubic symphyseal face for observation of these attributes. In addition to scoring each pubic symphysis according to the Todd (1921a, 1921b) and the Suchey-Brooks (Brooks and Suchey 1990; Suchey and Katz 1986) standards, photographs should be taken of each symphyseal face. Right and left sides should be scored separately.

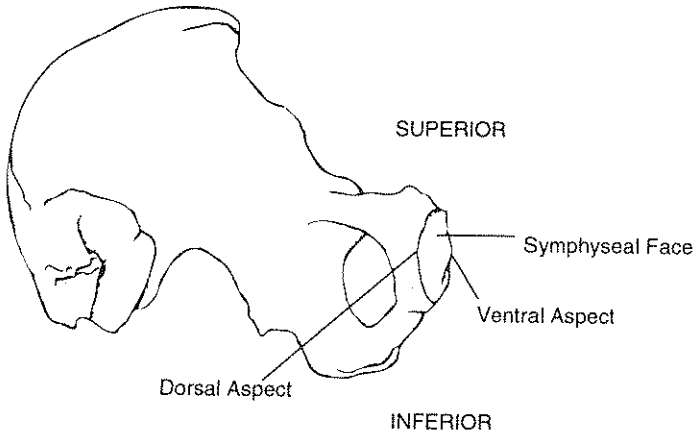

Figure 5. Pubic symphyseal face indicating orientation and key structures for Todd and Suchey-Brooks scoring methods (after Ubelaker 1989a, Figure 68b).

Todd Pubic Symphysis Scoring System

Representative symphyseal faces are presented in Figure 6 and discussed below. For further details, the observer should consult Todd (1921a, 1921b).

Phase 1. Symphyseal face rugged, traversed by horizontal ridges separated by well-marked grooves, there being no distinction in size between the upper and lower ridges. None of the following structures are present: nodules fusing with the surface, a delimiting margin, or definition of extremities. (Age, 18-19)

Phase 2. Symphyseal surface still rugged. Horizontal grooves are becoming filled near their dorsal limit with new, finely textured bone. Bony nodules may be present, fusing with upper symphyseal face. Dorsal delimiting margin begins to develop. No delimitation of the extremities. Ventral bevel commences. (Age, 20-21)

Phase 3. Symphyseal face shows progressive obliteration of ridge and furrow system. Commencing formation of a dorsal platform. Bony nodules may be present. Definition of dorsal margin, with sharp lipping. Ventral bevel more pronounced. Extremities not delimited. (Age, 22-24)

Phase 4. Great increase of ventral beveled area. Corresponding diminution of ridge and furrow formation. Complete definition of dorsal margin through the formation of the dorsal platform. Commencing delimitation of lower extremity. (Age, 25-26)

Phase 5. Little change in symphyseal face and dorsal platform. Margin more clearly defined and more sharply lipped. Lower extremity better defined. Upper extremity forming with or without the intervention of a bony nodule. (Age, 27-30)

Phase 6. Increasing definition of extremities. Development and practical completion of ventral rampart. Retention of some granular appearance of symphyseal face indicating that activity has not yet ceased. Failure of ventral aspect of pubis adjacent to ventral rampart to become transformed into a compact surface. The rampart may therefore be somewhat undermined. Retention of the pectinate outline of the dorsal margin and slight ridge and furrow system. No lipping of ventral margin and no increased lipping of dorsal margin. (Age, 30-35)

Phase 7. Face and ventral aspect change from granular to fine-grained or dense bone. Slight changes in symphyseal face and marked changes in ventral aspect from diminishing activity. No formation of symphyseal rim. No ossification of tendinous and ligamentous attachments. (Age, 35-39)

Phase 8. Symphyseal face and ventral aspect of pubic bone generally smooth and inactive. Oval outline complete. Extremities clearly defined. No distinct "rim" to symphyseal face. No marked lipping of ventral or dorsal margin. Development of ossification in tendinous and ligamentous attachments especially those of sacro-tuberous ligament and gracilis muscle. (Age, 40-45)

Phase 9. Symphyseal face presents a more or less marked rim. Dorsal margin uniformly lipped; ventral margin irregularly lipped. (Age, 45-49)

Phase 10. Ventral margin eroded at a greater or lesser extent of its length, continuing somewhat onto the symphyseal face. Rarefaction of face and irregular ossification. Disfigurement increases with age. (Age, 50+)

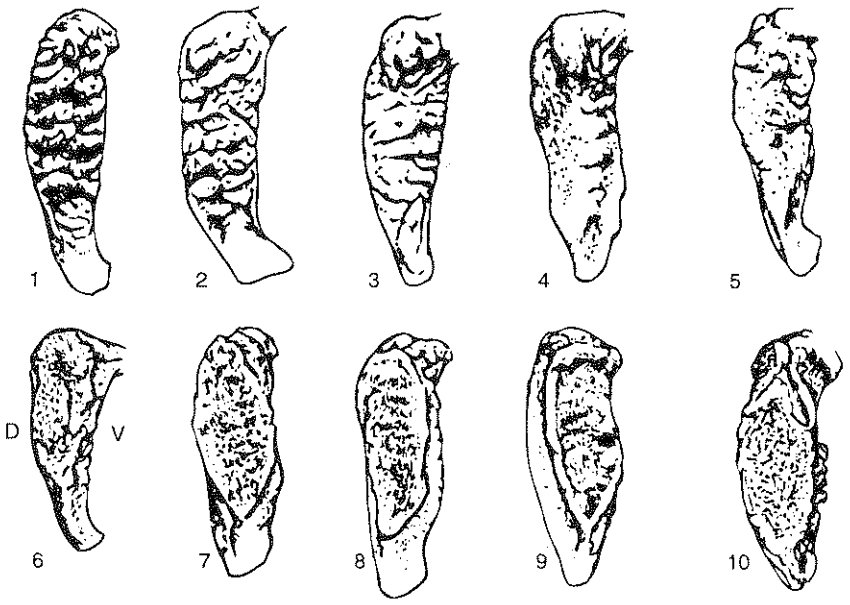

Figure 6. Todd pubic symphysis faces. D = dorsal; V = ventral. Drawing by Zbigniew Jastrzebski (after McKern and Stewart 1957).

Suchey-Brooks Pubic Symphysis Scoring System

The following descriptions define the Suchey-Brooks system for estimating age-at-death, based upon morphology of the pubic symphysis (Brooks and Suchey 1990; Suchey and Katz 1986). While the descriptions can be applied to symphyseal faces from either males or females, visual matches for females should be made in reference to Figure 7. Standards suitable for males are presented in Figure 8. Cast series which further enhance the information presented here are available from Dr. Diane France, at the address noted earlier in this chapter.

Phase 1. Symphyseal face has a billowing surface composed of ridges and furrows which includes the pubic tubercle. The horizontal ridges are well-marked. Ventral beveling may be commencing. Although ossific nodules may occur on the upper extremity, a key feature of this phase is the lack of delimitation for either extremity (upper or lower).

Phase 2. Symphyseal face may still show ridge development. Lower and upper extremities show early stages of delimitation, with or without ossific nodules. Ventral rampart may begin formation as extension from either or both extremities.

Phase 3. Symphyseal face shows lower extremity and ventral rampart in process of completion. Fusing ossific nodules may form upper extremity and extend along ventral border. Symphyseal face may either be smooth or retain distinct ridges. Dorsal plateau is complete. No lipping of symphyseal dorsal margin or bony ligamentous outgrowths.

Phase 4. Symphyseal face is generally fine-grained, although remnants of ridge and furrow system may remain. Oval outline usually complete at this stage, though a hiatus may occur in upper aspect of ventral circumference. Pubic tubercle is fully separated from the symphyseal face through definition of upper extremity. Symphyseal face may have a distinct rim. Ventrally, bony ligamentous outgrowths may occur in inferior portion of pubic bone adjacent to symphyseal face. Slight lipping may appear on dorsal border.

Phase 5. Slight depression of the face relative to a completed rim. Moderate lipping is usually found on the dorsal border with prominent ligamentous outgrowths on the ventral border. Little or no rim erosion, though breakdown possible on superior aspect of ventral border.

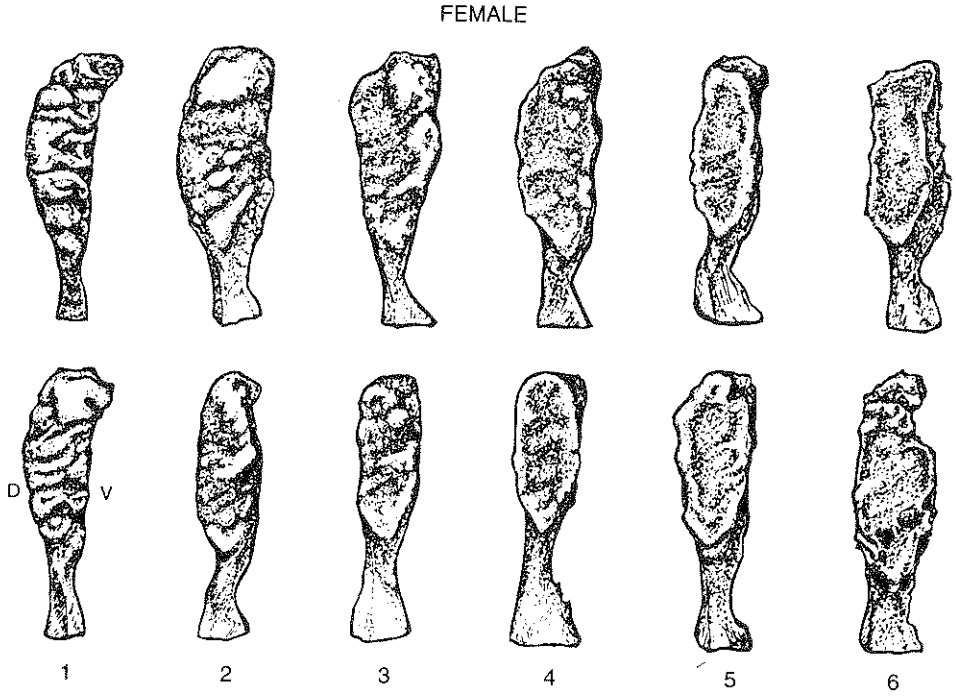

Figure 7. Suchey-Brooks standards for changes in the topography of the female pubic symphysis. D = dorsal; V = ventral. Drawing by Zbigniew Jastrzebski (after Brooks and Suchey 1990).

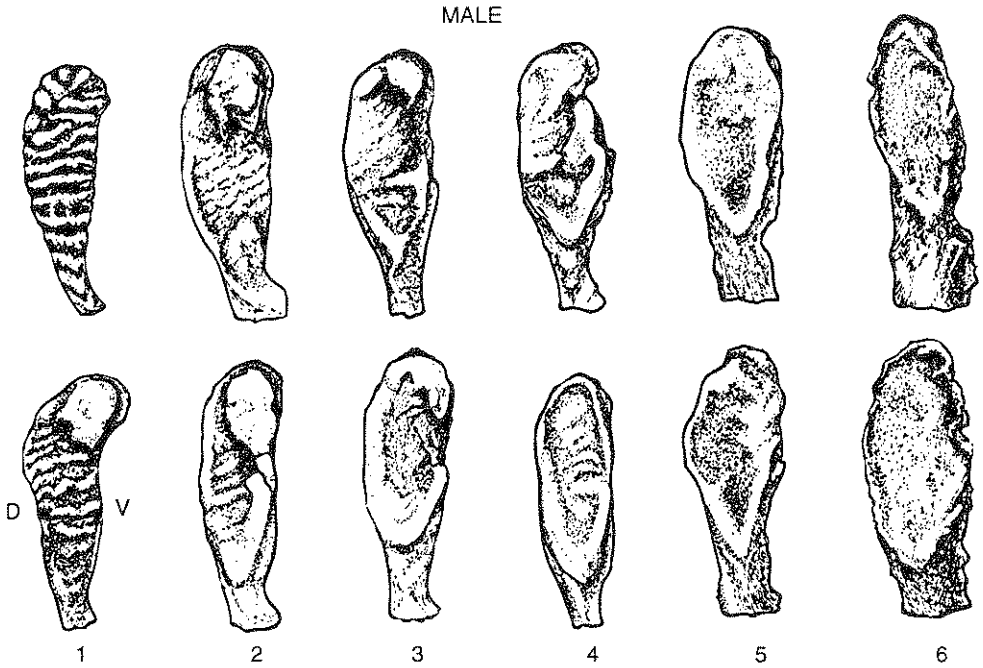

Figure 8. Suchey-Brooks standards for changes in the topography of the male pubic symphysis. D = dorsal; V = ventral. Drawing by Zbigniew Jastrzebski (after Brooks and Suchey 1990).

Phase 6. Symphyseal face shows ongoing depression as rim erodes. Ventral ligamentous attachments are marked. Pubic tubercle may appear as a separate bony knob. Face may be pitted or porous, giving an appearance of disfigurement as the ongoing process of erratic ossification proceeds. Crenelations may occur, with the shape of the face often irregular.

Auricular Surface

The auricular surface of the os coxae exhibits systematic age-related changes which are more complex and difficult to score than those of the pubic symphysis. The auricular surface, however, is more frequently preserved than the pubis in many archaeological collections (Lovejoy et al. 1985; Meindl and Lovejoy 1989: 140), and therefore provides a useful way to document age-related changes in cases where the pubic symphysis is not preserved.

Figure 9 illustrates the features used to record age changes of the auricular surface. These features are defined below, along with other terms important to the auricular surface technique. Our definitions follow Ubelaker (1989a: 81).

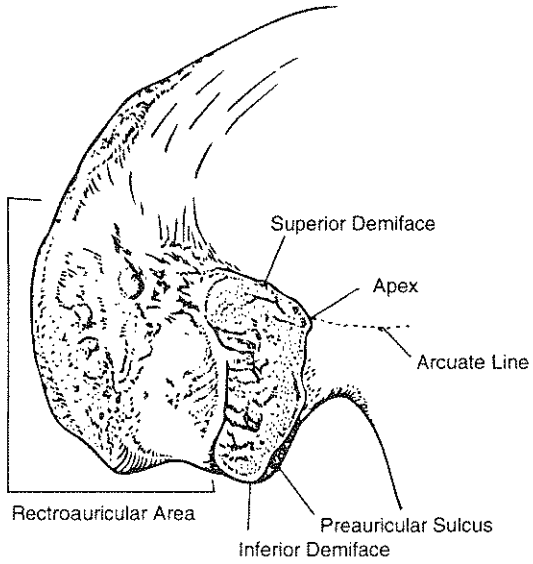

Figure 9. Regions of the ilium used in auricular surface age determination. Drawing by Zbigniew Jastrzebski (after Meindl and Lovejoy 1989:141).

Apex: Portion of the auricular surface that articulates with the posterior aspect of the arcuate line.
Superior Demiface: Portion of the auricular area above the apex.
Inferior Demiface: Portion of the auricular area below the apex.
Retroarticular Area: Region between the auricular surface and the posterior inferior iliac spine.
Billowing: Transverse ridging.
Granularity: Appearance of the articular surface. A heavily "grained" appearance, for example, resembles fine sandpaper.
Density: Compactness. Subchondral bone that appears smooth and not granular.
Porosity: Perforations ranging from barely visible to 10 mm in diameter.

Each auricular surface should be assigned to one of the eight phases described below, recording the right and left sides separately. Further details concerning these standards are presented in the publications that defined the technique (Lovejoy et al. 1985; Meindl and Lovejoy 1989: 165). Photographs of auricular surfaces from individuals of various estimated ages are provided in Figure 10, along with captions describing the criteria used to assign an age to each auricular surface. Associations between specific changes and chronological age are treated in more detail in Bedford et al. (1989).

Phase 1. Transverse billowing and very fine granularity. Articular surface displays fine granular texture and marked transverse organization. There is no porosity, retroauricular or apical activity. The surface appears youthful because of broad and well-organized billows, which impart the definitive transverse organization. Raised transverse billows are well-defined and cover most of the surface. Any subchondral defects are smooth-edged and rounded. (Age, 20-24)

Phase 2. Reduction of billowing but retention of youthful appearance. Changes from the previous phase are not marked and are mostly reflected in slight to moderate loss of billowing, with replacement by striae. There is no apical activity, porosity, or retroauricular activity. The surface still appears youthful owing to marked transverse organization. Granulation is slightly more coarse. (Age, 25-29)

Phase 3. General loss of billowing, replacement by striae, and distinct coarsening of granularity. Both demifaces are largely quiescent with some loss of transverse organization. Billowing is much reduced and replaced by striae. The surface is more coarsely and recognizably granular than in the previous phase, with no significant changes at apex. Small areas of microporosity may appear. Slight retroauricular activity may occasionally be present. In general, coarse granulation supersedes and replaces billowing. Note smoothing of surface by replacement of billows with fine striae, but distinct retention of slight billowing. Loss of transverse organization and coarsening of granularity is evident. (Age, 30-34)

Phase 4. Uniform, coarse granularity. Both faces are coarsely and uniformly granulated, with marked reduction of both billowing and striae, but striae may still be present. Transverse organization is present but poorly defined. There is some activity in the retroauricular area, but this is usually slight. Minimal changes are seen at the apex, microporosity is slight, and there is no macroporosity. (Age, 35-39)

Phase 5. Transition from coarse granularity to dense surface. No billowing is seen. Striae may be present but are very vague. The face is still partially (coarsely) granular and there is a marked loss of transverse organization. Partial densification of the surface with commensurate loss of granularity. Slight to moderate activity in the retroauricular area. Occasional macroporosity is seen, but this is not typical. Slight changes are usually present at the apex. Some increase in macroporosity, depending on degree of densification. (Age, 40-44)

Phase 6. Completion of densification with complete loss of granularity. Significant loss of granulation is seen in most specimens, with replacement by dense bone. No billows or striae are present. Changes at apex are slight to moderate but are almost always present. There is a distinct tendency for the surface to become dense. No transverse organization is evident. Most or all of the microporosity is lost to densification. There is increased irregularity of margins with moderate retroauricular activity and little or no macroporosity. (Age, 45-49)

Phase 7. Dense irregular surface of rugged topography and moderate to marked activity in periauricular areas. This is a further elaboration of the previous morphology, in which marked surface irregularity becomes the paramount feature. Topography, however, shows no transverse or other form of organization. Moderate granulation is only occasionally retained. The inferior face generally is lipped at the inferior terminus. Apical changes are almost invariable and may be marked. Increasing irregularity of margins is seen. Macroporosity is present in some cases. Retroauricular activity is moderate to marked in most cases. (Age, 50-59)

Phase 8. Breakdown with marginal lipping, macroporosity, increased irregularity, and marked activity in periauricular areas. The paramount feature is a nongranular, irregular surface, with distinct signs of subchondral destruction. No transverse organization is seen and there is a distinct absence of any youthful criteria. Macroporosity is present in about one-third of all cases. Apical activity is usually marked but it is not requisite. Margins become dramatically irregular and lipped, with typical degenerative joint change. Retroauricular area becomes well defined with profuse osteophytes of low to moderate relief. There is clear destruction of subchondral bone, absence of transverse organization, and increased irregularity. (Age, 60+)

a

Age 19

P - Marked billowing over surface
P - Cortical bone on surface has fine-grained texture
D - Smooth-edged youthful defects near apex
S - No retroauricular activity
S - No apical activity
Specimen #T854

b

Age 24

P - Transverse organization prominent, especially on inferior demiface, but less than typical overall. Residual billowing at inferior margin
P - Fine granularity evident over most of surface. Some slight coarse granularity in apical region
D - Postmortem damage has worn cortical bone in places.
S - No retroauricular activity
S - No significant apical activity
Specimen #T1243

KEY: P = Primary aging characteristic; S = Secondary aging characteristic;
D = Descriptive statement, not an aging criterion

Figure 10a-b. Photographs of auricular surfaces for use in age determination. Courtesy of C. O. Lovejoy, R. S. Meindl, M. E. Bedford, K. F. Russell, Department of Anthropology and Biomedical Sciences Program, Kent State University.

c

Age 27

P - Moderate transverse organization on inferior demiface
P - Billowing evident over inferior and part of superior demifaces
P - Coarse granularity evident inferiorly (making surface texture slightly older than T1243).
S - No retroauricular activity
S - No apical activity
Specimen #T1312

d

Age 31

P - Striae strong on inferior demiface
P - Significant transverse organization is evident especially on inferior demiface. Loss of transverse organization superiorly
P - Uniform coarse granularity on superior demiface. Mostly fine granularity on inferior demiface
S - Very slight retroauricular activity
S - No apical activity
Specimen #T1139

KEY: P = Primary aging characteristic; S = Secondary aging characteristic;
D = Descriptive statement, not an aging criterion

Figure 10c-d. Photographs of auricular surfaces for use in age determination. Courtesy of C. O. Lovejoy, R. S. Meindl, M. E. Bedford, K. F. Russell, Department of Anthropology and Biomedical Sciences Program, Kent State University.

e

Age 35

P- Striae still abundant but weak transverse organization and complete boss of billowing
P - Uniform coarse granularity dominates entire surface
S - Slight retroauriclar activity
S - No apical activity
Specimen #T1313

f

Age 39

P - Few striae remain on inferior demiface
P - Very little transverse organization except at apex
P - Uniform coarse granularity over entire surface
S - Slight retroauricular activity
S - Minimal apical activity
Specimen #T1319

KEY: P = Primary aging characteristic; S = Secondary aging characteristic;
D = Descriptive statement, not an aging criterion

Figure 10e-f. Photographs of auricular surfaces for use in age determination. Courtesy of C. O. Lovejoy, R. S. Meindl, M. E. Bedford, K. F. Russell, Department of Anthropology and Biomedical Sciences Program, Kent State University.

g

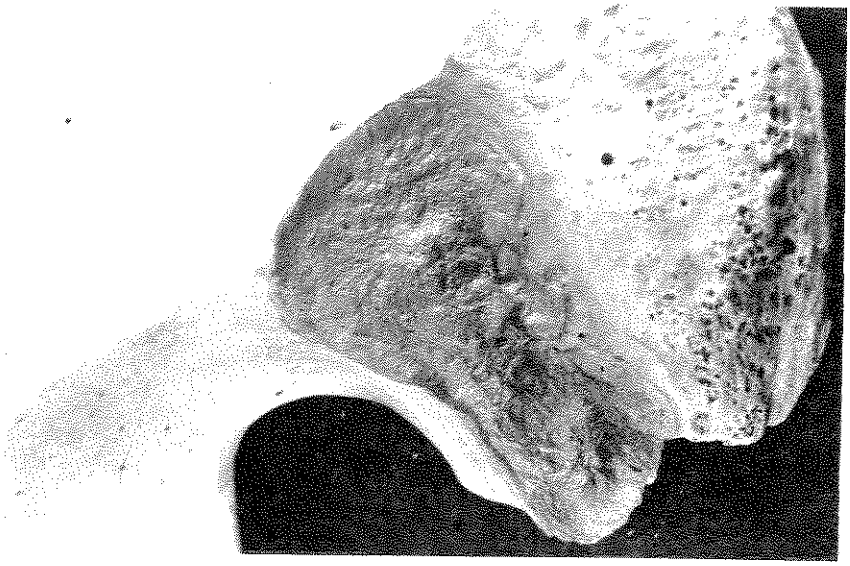

Age 42

P - No transverse organizaton
P - Coarse granularity over most of surface
P - Densification appearing (e.g. posterior margin of surface)
S - Possible microporosity present
S - Slight to moderate retroauricular activity
S - Minimal apical activity
Specimen #T1431

h

Age 44

P - Vague residual transverse organization on inferior demiface but otherwise complete loss of this feature
P - Coarse granularity being replaced by densification around rim and in islands on surface
S - Some microporosity evident on inferior demiface
S - Slight retroauricular activity
S - Moderate to strong apical changes
Specimen #T1476

KEY: P = Primary aging characteristic; S = Secondary aging characteristic;
D = Descriptive statement, not an aging criterion

Figure 10g-h. Photographs of auricular surfaces for use in age determination. Courtesy of C. O. Lovejoy, R. S. Meindl, M. E. Bedford, K. F. Russell, Department of Anthropology and Biomedical Sciences Program, Kent State University.

i

Age 50
- P - All transverse organization absent
- P - Dense bone covers surface, but some residual granularity evident
- S - Microporosity at various points over surface
- S - Macroporosity present, especially on posterior aspect of inferior demiface
- S - Slight to moderate retroauricular activity
- S - Slight apical activity
- Specimen #T1422

j

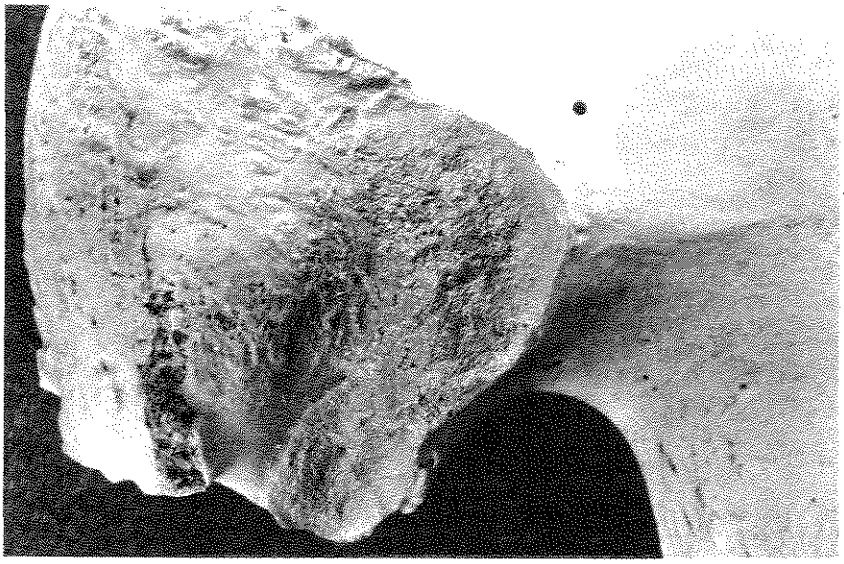

Age 51
- P - No transverse organization
- P - Surface covered with dense bone interspersed with residual rough granularity
- D - Postmortem damage on posterior part of superior demiface
- S - Moderate retroauricular activity
- S - Minimal apical activity
- Specimen #T1132

KEY: P = Primary aging characteristic; S = Secondary aging characteristic;
D = Descriptive statement, not an aging criterion

Figure 10i-j. Photographs of auricular surfaces for use in age determination. Courtesy of C. O. Lovejoy, R. S. Meindl, M. E. Bedford, K. F. Russell, Department of Anthropology and Biomedical Sciences Program, Kent State University.

k

Age 54

P - No transverse organization
P - Dense bone covering entire surface
P - Surface rugose and strongly irregular
S - Microporosity and macroporosity present
S - Moderate retroauricular activity
S - Moderate apical activity
Specimen #T1549L

l

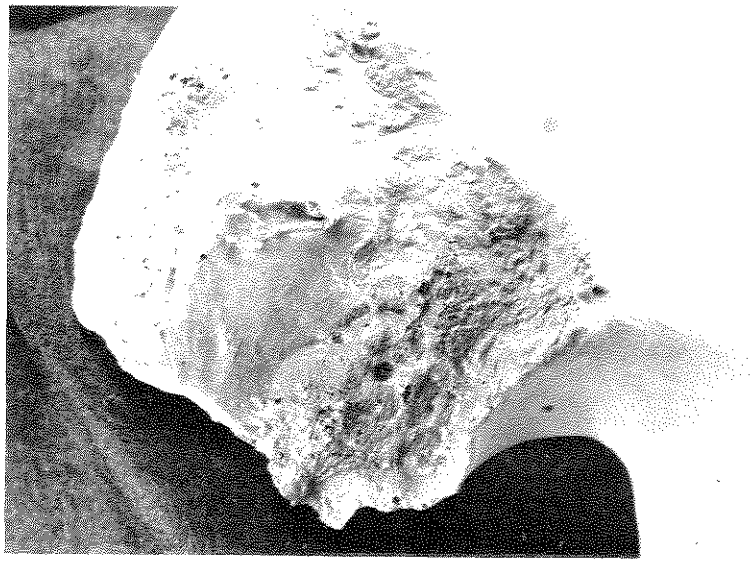

Age 59

P - No transverse organization
P - Dense bone covers entire surface except where porosity interferes
P - Rugose, irregular surface
S - Microporosity and macroporosity are evident on inferior demiface
S - Moderate retroauricular activity
S - Slight apical activity
Specimen #T1549R

KEY: P = Primary aging characteristic; S = Secondary aging characteristic;
D = Descriptive statement, not an aging criterion

Figure 10k-l. Photographs of auricular surfaces for use in age determination. Courtesy of C. O. Lovejoy, R. S. Meindl, M. E. Bedford, K. F. Russell, Department of Anthropology and Biomedical Sciences Program, Kent State University.

m

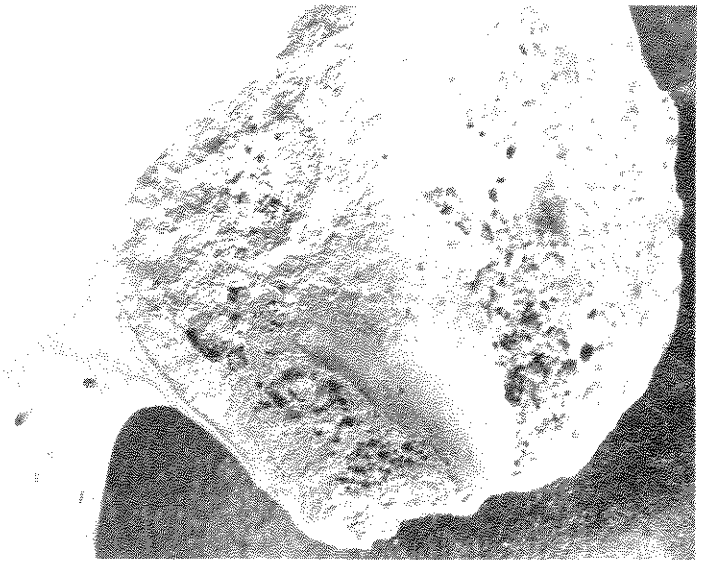

Age 63
P - No transverse organization
P - Strongly irregular surface
P - Dense bone with marked subchondral destruction on inferior demiface
S - Macroporosity present
S - Moderate retroauricular activity
S - Slight apical activity (less than expected for this age)
S - Marginal breakdown evident posteriorly
D - Some postmortem damage
Specimen #T1852

KEY: P = Primary aging characteristic; S = Secondary aging characteristic;
D = Descriptive statement, not an aging criterion

Figure 10m. Photographs of auricular surfaces for use in age determination. Courtesy of C. O. Lovejoy, R. S. Meindl, M. E. Bedford, K. F. Russell, Department of Anthropology and Biomedical Sciences Program, Kent State University.

Cranial Suture Closure

Although cranial sutures generally close (fuse) with increasing age, there is considerable variability in closure rates. Such variation reduces the value of suture closure patterns for age estimation (Masset 1989). Information on suture closure is, however, useful when other criteria are not available or when used in conjunction with other attributes (Acsádi and Nemeskéri 1970; Meindl and Lovejoy 1985).

Degree of suture closure should be recorded for 10 ectocranial, 4 palatal, and 3 endocranial locations (Figure 11). This technique is a composite of methods developed by several researchers, eg. Baker (1984); Mann et al (1987); Meindl and Lovejoy (1985); Todd and Lyon (1924, 1925a, 1925b, 1925c). Degree of closure for all suture segments should be recorded according to the following stages (Meindl and Lovejoy 1985: 58), which are illustrated in Figure 12.

blank = Unobservable

0 = Open. There is no evidence of any ectocranial closure at the site.

1= Minimal Closure. Some closure has occurred. Score is assigned to any minimal to moderate closure, i.e. from a single bony bridge across the suture to about 50% synostosis at the site.

2 = Significant Closure. There is a marked degree of closure but some portion of the site is still not completely fused.

3 = Complete Obliteration. The site is completely fused.

Ectocranial sutures are scored at a 1 cm length of suture surrounding the following points, as illustrated in Figure 11a. Use the left side of the skull in instances of bilateral segments.

1. Midlambdoid. Midpoint of left half of the lambdoid suture (pars intermedia).

2. Lambda. At lambda (pars lambdica) of lambdoid and sagittal sutures.

3. Obelion. At obelion (pars obelica) of the sagittal suture.

4. Anterior Sagittal. Point on the sagittal suture 1/3 distance from bregma to lambda (at juncture of parts bregmatica and pars verticis).

5. Bregma. At bregma (pars bregmatica of the coronal and sagittal sutures).

6. Midcoronal. Midpoint of left coronal suture (within pars complicata).

7. Pterion. At pterion, within the region of the upper portion of the left greater wing of the sphenoid, usually at the point at which the parietosphenoid suture meets the frontal bone.

8. Sphenofrontal. Midpoint of the left spheno-frontal suture.

9. Inferior Sphenotemporal. Point of intersection between the left sphenotemporal suture and a line connecting both articular tubercles of the temporo-mandibular joint.

10. Superior Sphenotemporal. Point on the left sphenotemporal suture lying 2 cm below juncture with the parietal bone.

Sutures of the hard palate should be scored across their entire length. The left incisive suture should be scored rather than the right, if both segments are observable. Figure 11b illustrates the location of each suture segment.

11. Incisive Suture. Separates maxilla (with canines, premolars and molars) from premaxilla (incisors only).

12. Anterior Median Palatine Suture. Score entire length on paired maxillae between incisive foramen and palatine bone.

13. Posterior Median Palatine Suture. Score entire length on paired palatine bones.

14. Transverse Palatine Suture. Score entire length between maxillae and palatine bones.

Endocranial sutures should be scored across the following segments. If the skull is complete, anterior sutures can be observed indirectly by use of a small flashlight and a dental mirror. Locations are indicated in Figure 11c.

15. Sagittal. Full sagittal suture

16. Left Lambdoid. Pars lambdica and pars intermedia of the left lambdoid suture.

17. Left Coronal. Pars bregmatica and pars complicata of the left coronal suture.

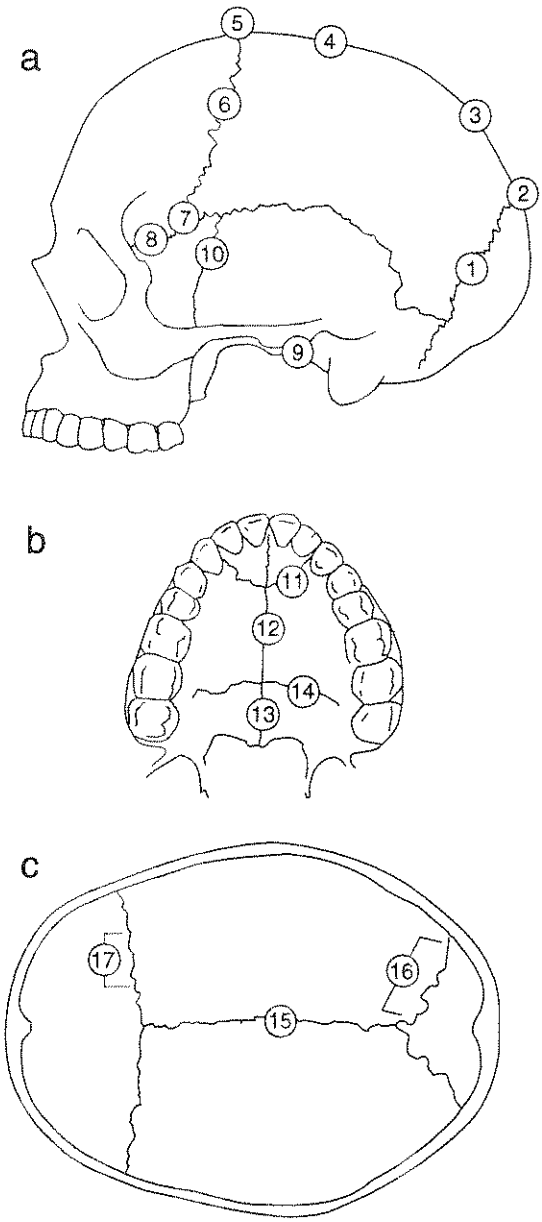

Figure 11. Location of sites to be used to record ectocranial (a; 1-11), palatal (b; 12-14), and endocranial (c; 15-17) suture closure. Drawing by P. Walker (after Mann et al. 1987; Meindl and Lovejoy 1985: 59; Todd and Lyon 1924, 1925a-c).

a



b

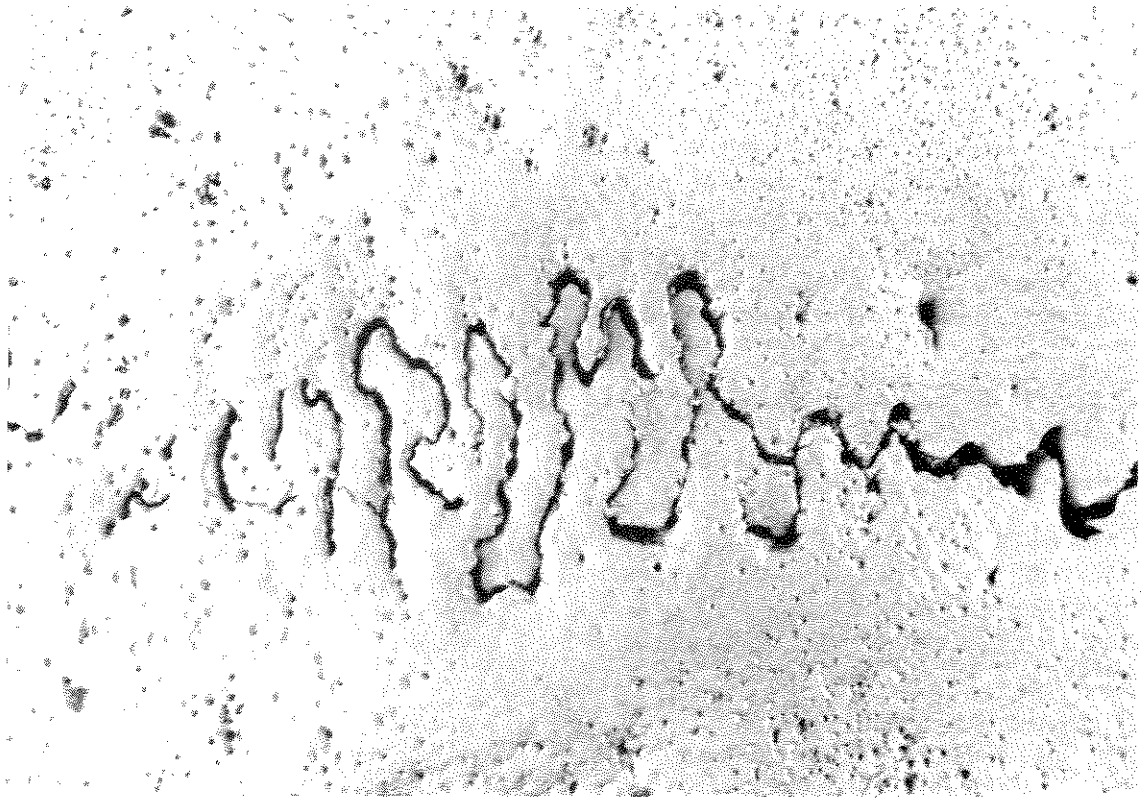

Figure 12a-b. Stages of ectocranial suture closure; a) Open: score = 0; b) Minimal closure: score = 1. Courtesy of P. L. Walker.

c

d

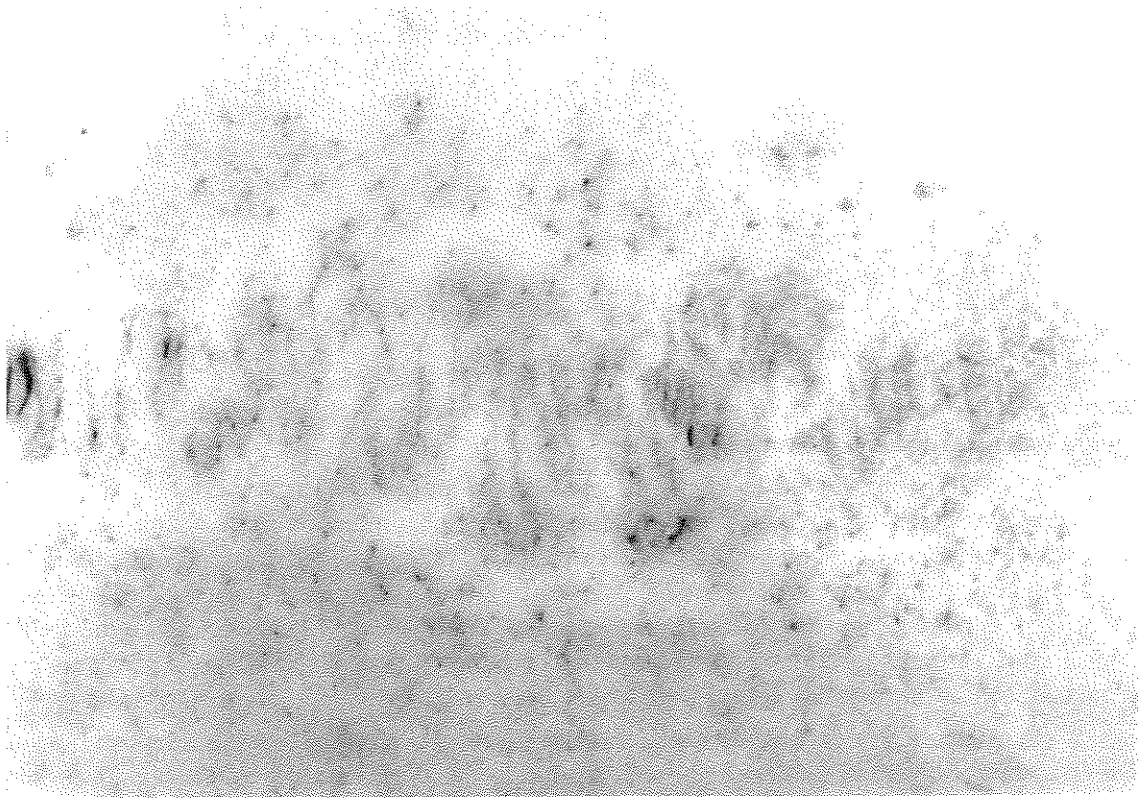

Figure 12c-d. Stages of ectocranial suture closure. c) Significant closure: score = 2; d) Complete obliteration: score = 3. Courtesy of P. L. Walker.

ESTIMATED AGE

In the space provided in Attachment 11, based upon your overall assessment of available data, assign each adult individual to one of the following age classes.

Young Adult (20-34 years)
Middle Adult (35-49 years)
Old Adult (50+ years)

The reasons for your assignment should be described under the heading "Comments." Experienced workers may also wish to indicate a probable age-at-death in years and the basis for this assessment.

In developing an age estimate, Figures 13 and 14 may prove helpful. Figure 13 illustrates the association between the developmental phases of the os coxae described in this chapter and chronological age. A similar procedure is used in Figure 14 to associate composite ectocranial suture scores and chronological age for the cranial vault and the lateral-anterior regions, as defined by Meindl and Lovejoy (1985). Composite scores are reached by summing scores for five "vault" sites and five "lateral-anterior" sites. Both systems include observations at the midcoronal suture and at pterion. If scores are not available for all sites used to obtain a composite score, a composite score cannot be determined.

Vault Sites	Lateral-Anterior Sites
midlambdoid	**pterion**
lambda	**midcoronal**
obelion	**sphenofrontal**
anterior sagittal	**inferior sphenotemporal**
bregma	**superior sphenotemporal**

Composite scores can therefore theoretically range between 0 and 21 for the vault system and 0 and 15 for the lateral-anterior system. The following composite scores are associated with the "S" designations in Figure 14. Predictions for completely open sutures are not possible with this method. Individuals whose sutures are fully closed fall into the older adult category.

VAULT		LATERAL-ANTERIOR	
Composite Score	**"S"**	**Composite Score**	**"S"**
1-2	**S1**	**1**	**S1**
3-6	**S2**	**2**	**S2**
7-11	**S3**	**3-5**	**S3**
12-15	**S4**	**6**	**S4**
16-18	**S5**	**7-8**	**S5**
19-20	**S6**	**9-10**	**S6**
		11-14	**S7**

According to Lovejoy and Meindl (1985), the lateral-anterior region proved to be a better predictor of chronological age than the vault sites.

While not represented in Figure 14, endocranial and palate sutures can also serve as a basis for estimating age. By young adulthood, the incisive (IN) suture has already closed, with activity evident within the transverse palatine (TP) and posterior median palatine (PMP) segments. Closures of IN, TP, and PMP, with the anterior median palatine (AMP) remaining at least partially open, are characteristic of middle adulthood. Complete fusion is typical of older adults (Mann et al. 1987). Endocranial suture closures for the coronal, sagittal, and lambdoid sutures begin during young adulthood. Advanced but incomplete closure stages are characteristic of middle adults, while fully fused sutures are typically found in older adults (Krogman and Iscan 1986).

In ambiguous cases, more weight should be given to postcranial features than cranial suture scores. Observers may also wish to consider epiphyseal union (Chapter 4), dental attrition (Chapter 5), arthritis (Chapter 10), ossification of cartilage, tendons, and ligaments (Chapter 10), as well as microscopically observable age-related changes (Chapter 12). The basis for assignment of estimated ages and age ranges should be fully described in the "Comments" section of Attachment 11.

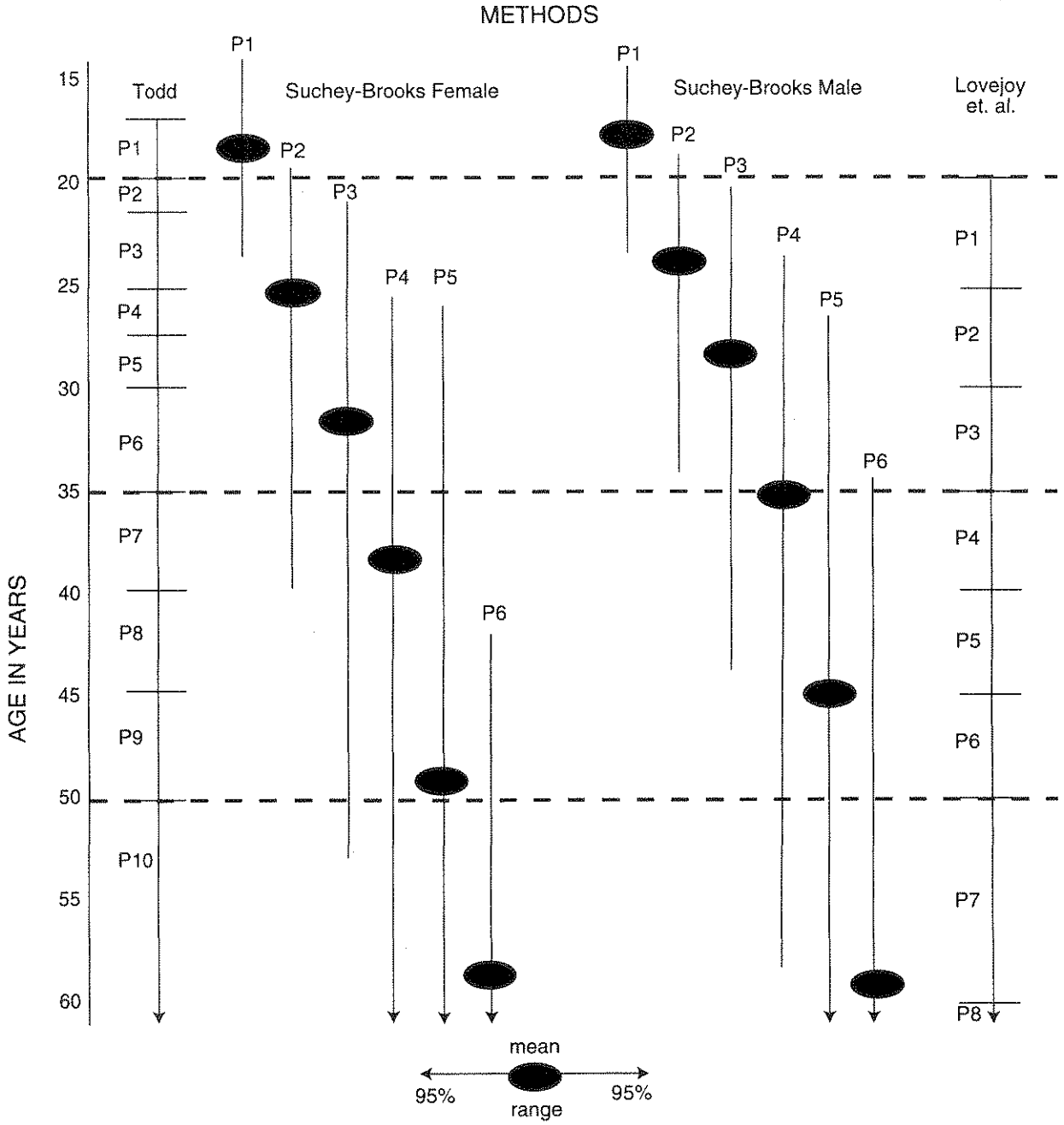

Figure 13. Association between postcranial developmental phases and chronological age (after Todd 1921a, 1921b); Brooks and Suchey 1990; and Lovejoy et al. 1985). Suchey-Brooks Method: Bars denote the 95% range for each estimate, with an oval used to represent the mean. Arrows mean that the phase includes individuals in excess of 60 years of age.

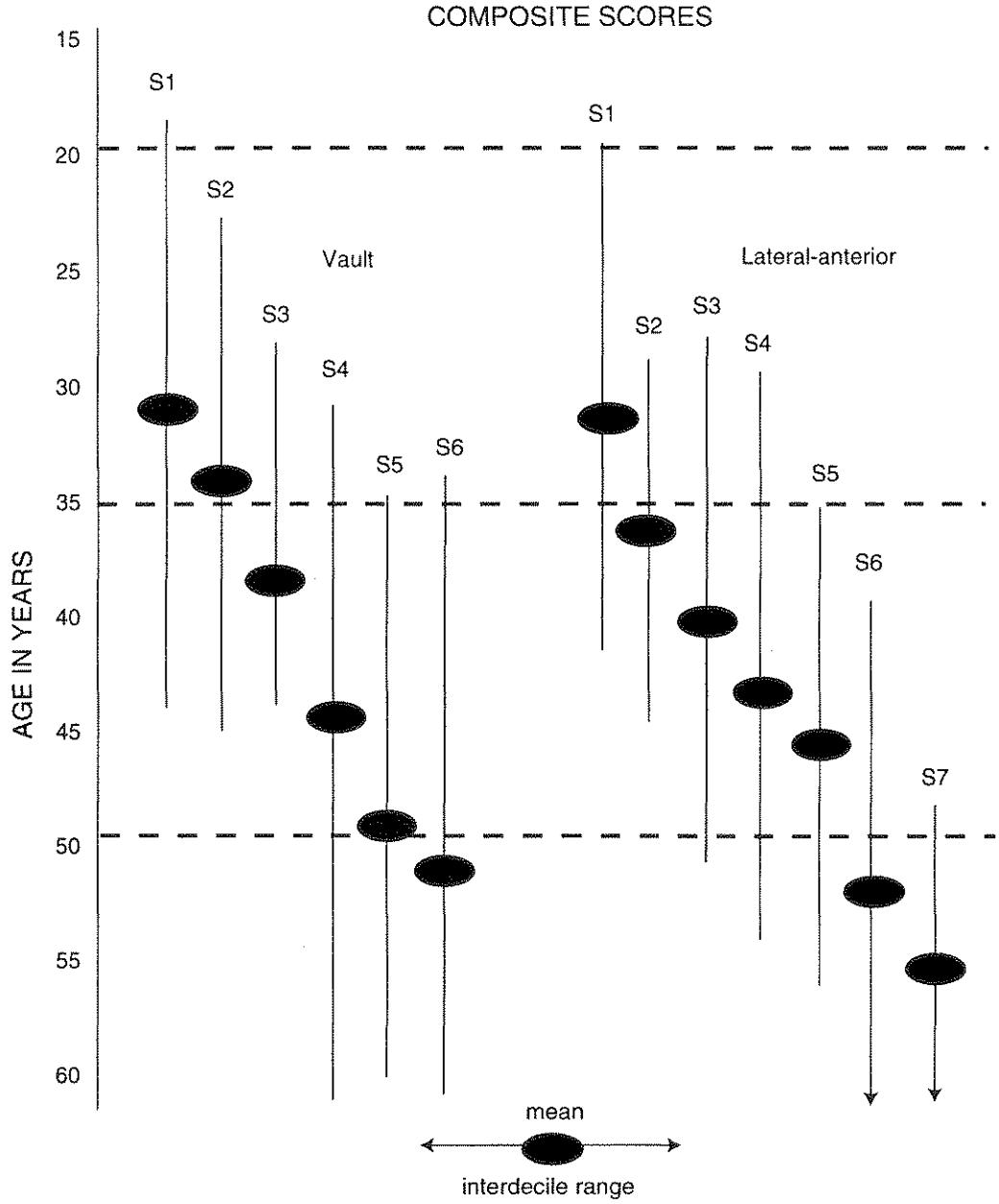

Figure 14. Association between chronological age and ectocranial suture composite scores for the cranial vault and the lateral-anterior region (after Meindl and Lovejoy 1985). The bars denote the interdecile range, with the mean indicated by an oval. Arrows mean that the stage includes individuals in excess of 60 years of age.

CHAPTER 4

IMMATURE REMAINS: MATURATION AND MEASUREMENT

The study of immature human remains holds excellent potential for addressing a range of issues important to our understanding of human history. Subsistence strategies, diet, disease experience, weaning patterns, and inherited conditions often influence maturing teeth and bones in a manner that reflects ancient lifeways. Investigations of juvenile skeletons and dentitions are therefore critical to many aspects of bioarchaeological research, including demographic reconstructions, comparative growth and maturation studies, disease diagnoses, and nutritional evaluations.

Most data collected from immature remains document the various maturational systems operating during growth and development. Dental calcification and eruption (see Chapter 5), development and fusion of epiphyses, and unification of primary ossification centers within the vertebrae and pelvis are examples of distinctive maturational systems. It is important that data characterizing each of these systems be collected independently so that future comparative research may refine assessments of physiological (developmental) age and thus strengthen estimates of chronological age at death.

Accurate chronological age estimates are critical to demographic analyses and investigations of the many processes that influence growth and maturation, including limiting factors such as poor nutrition and ill health. Since skeletal growth and maturation in relationship to dental development is used today in living populations to evaluate health status, the application of comparable standards to archaeological samples permits studies of long term trends in nutritional adequacy and quality of life. Recent research concerning the impact of agricultural intensification upon health well illustrates the importance of perspectives developed from the study of immature remains (Cohen and Armelagos 1984).

Observations of typical human mortality patterns suggest that large numbers of young juveniles should be present in any archeological sample. Representation is, however, limited by factors such as burial customs, preservation, recovery techniques, and curation methods. In many cases only the most durable bones and teeth survive. The data set to be collected from immature remains therefore has been selected both for the quality of information gained and the probability that the bones identified here will be recovered from the archaeological record. If sufficient time and resources are available, the list should be expanded to include size and epiphyseal union status of all individual ribs (head and tubercle union), all recognizable hand and foot bones, and all vertebrae. Additional measurements of immature bones are described in Fazekas and Kosa (1978).

AGE-AT-DEATH

Union of Epiphyses

For each epiphysis of the postcranial skeleton indicated in Attachment 12 and illustrated in Figure 15, classify the union of the epiphysis and diaphysis according to the following system. Bilateral elements should

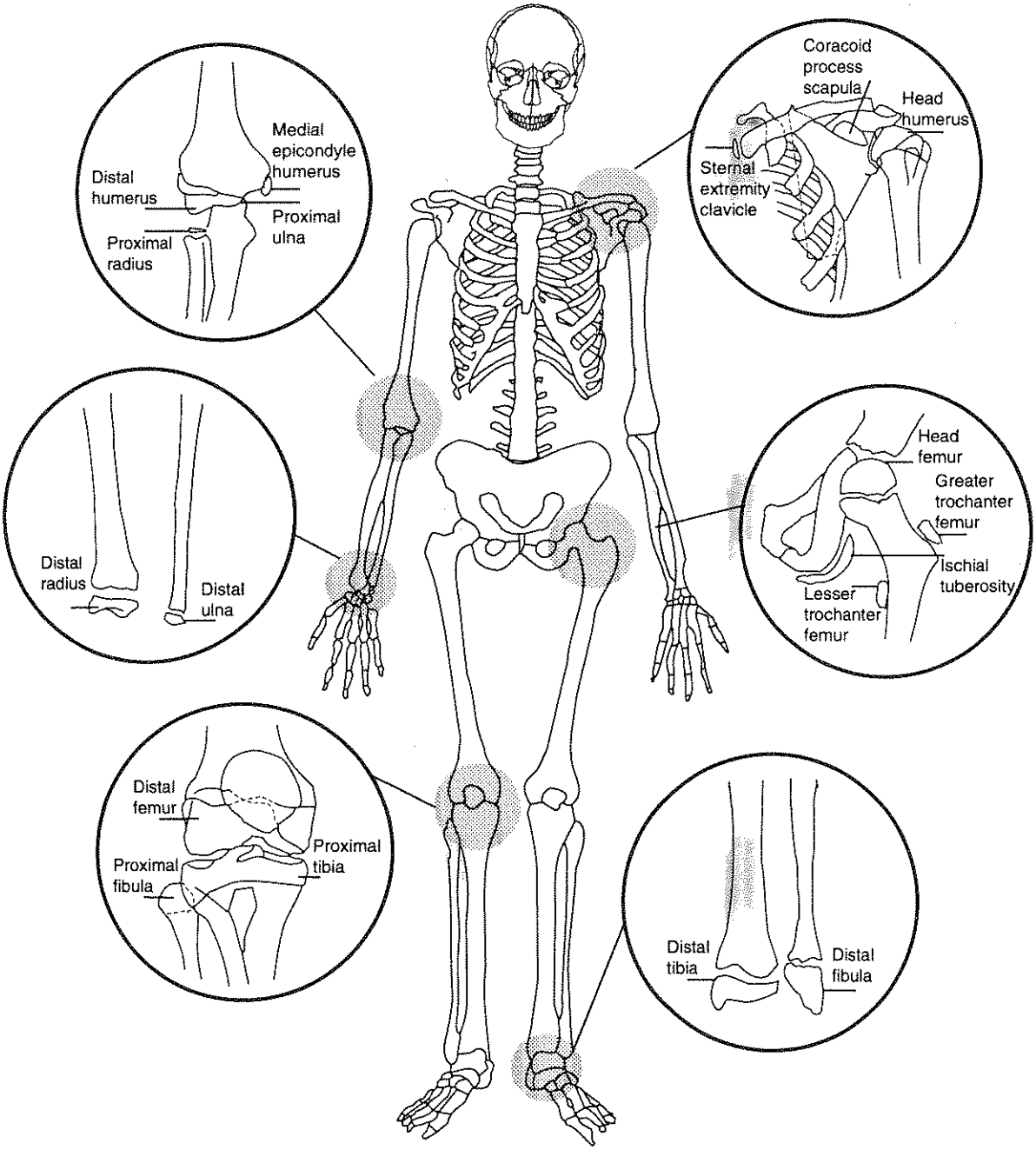

Figure 15. Location of epiphyses.

both be recorded, as indicated in the recording form (Attachment 12). Figure 16 illustrates these stages of union for the proximal femur.

blank = unobservable
0 = open: epiphysis and diaphysis completely separate; no bony union
1 = partial union: some union has occurred
2 = complete union: all visible aspects of the epiphysis are united.

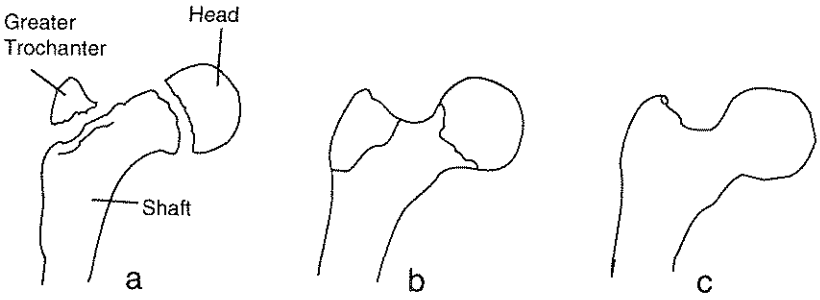

Figure 16. Examples of stages of epiphyseal union for the proximal femur (after Ubelaker 1989a, Figure 85). a) Shaft and epiphyses completely separate; b) Shaft and epiphyses united, but their junction clearly defined by a line; c) Union complete, with obliteration of lines of junction.

Union of Primary Ossification Centers

Fusion between primary ossification centers of the pelvis, the vertebrae, and the occipital should be scored according to the same standards (blank, 0, 1, 2) used for the union of epiphyses. Space is allocated in Attachment 12 for recording these primary fusions.

In forming the mature os coxae, the ischium and pubis fuse together first, uniting the ascending ramus of the ischium with the descending ramus of the pubis (Figure 17). The ischium-pubis is then united with the ilium at the acetabulum.

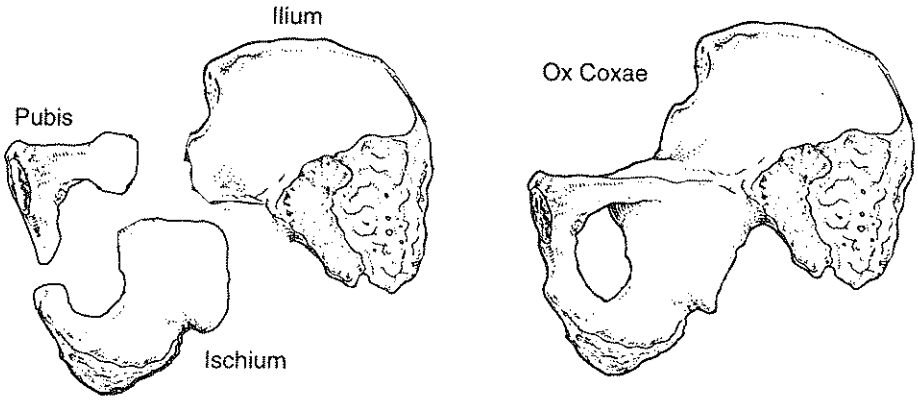

Figure 17. Primary ossification centers of the os coxae, external view (after Steele and Bramblett 1988, Figure 9.10).

Among the vertebrae, the halves of the neural arch fuse prior to union with the centra (Figure 18). Within the vertebral column, score the most advanced stage of union within each segment for cervical, thoracic, and lumbar vertebrae. If, for example, three cervical vertebrae are incompletely united, while one is completely fused, the appropriate score would be "2," complete union. Degree of fusion between each sacral segment should be recorded, e.g., S1-S2, S2-S3.

As illustrated in Figure 19, the occipital includes two lateral parts, a squamous portion, and a basilar part. The two lateral parts fuse first to the squama, followed by fusion with the basilar part. Much later, as an individual nears adulthood, the basilar portion of occipital fuses to the sphenoid at the spheno-occipital synchondrosis. Each of these points of fusion should be recorded. If fusion of the lateral parts is asymmetrical, record the most advanced stage of fusion.

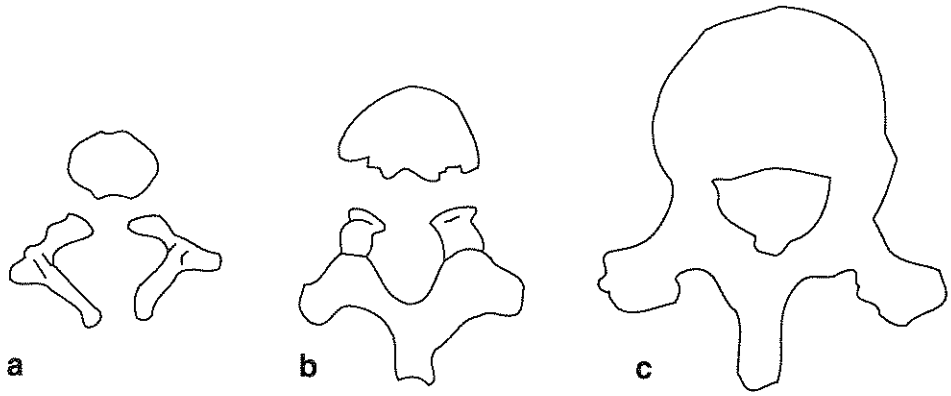

Figure 18. Primary ossification centers of the vertebrae (after Steele and Bramblett 1988, Figure 5.17). a) Neural arches and centrum separate; b) Neural arches fused but separate from centrum; c) All primary centers fused.

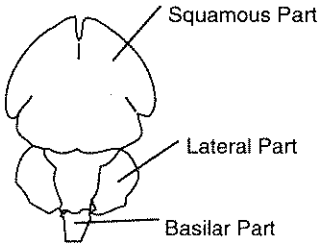

Figure 19. Primary ossification centers of the occipital (after Brothwell 1981, Figure 2.14).

At the close of your evaluation of epiphyseal and primary ossification center fusion, we ask that you estimate age-at-death within five-year intervals. Figure 20 includes a graphic representation of the relationship between these fusions and chronological age which can be used to develop this estimate. Most of the bars represent age ranges of active fusion for males only, due to the lack of systematic data for females. In general, females tend to mature one to two years earlier than males, which should be taken into consideration if the observed remains are judged to be female. If sex is unknown, then the probable age range should be extended

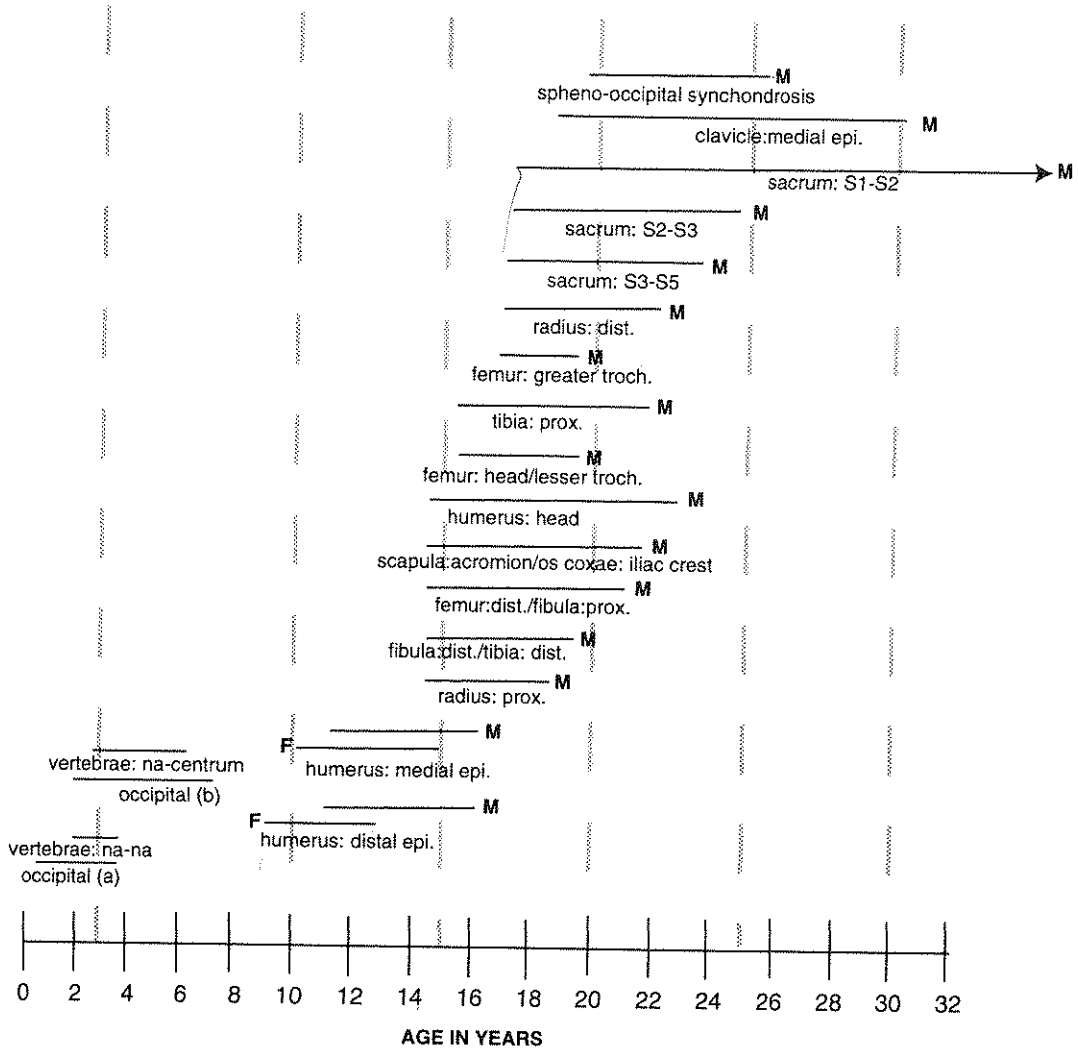

Figure 20. Relationship of epiphyseal union and fusion of primary ossification centers to chronological age (after Krogman and Iscan 1986; McKern and Stewart 1957; Redfield 1970; Suchey et al. 1984; Ubelaker 1989a, 1989b). Bars indicate period during which union/fusion is occurring. Most bars reflect data for males ("M"), while those for females are indicated by the letter "F."

to include one to two years at the lower (female) end of the range. Given that postcranial maturation is highly variable, the associations in the diagram may not precisely represent the pattern you are observing. Possible mixing of remains from two or more individuals must, however, be considered in examples departing markedly from the sequence illustrated in Figure 20, e.g., a femur in late stages of fusion associated with a humerus lacking epiphyses.

You should indicate the rationale for your estimate in the "Comments" section of the recording form (Attachment 12). Broader or more restricted age ranges can also be indicated and should be justified. We recognize that other workers may wish to integrate this information with that for other maturational features presented in this chapter and in Chapter 5. The estimate on Attachment 12, however, should be based exclusively on epiphyseal and ossification center fusion.

Dental Development

Dental development should be recorded during the dental inventory process (see Chapter 5). The standards adopted there follow those of Moorees, Fanning, and Hunt (1963a, 1963b).

MEASUREMENTS

Measurements used to describe adult remains are frequently not suitable for juvenile skeletons due to the absence of structures and landmarks usually present in mature bones. The most appropriate standards for observing young infants and fetal materials have been developed by Fazekas and Kosa (1978). In modified form, the Fazekas and Kosa (1978) method is followed here, as illustrated in Figure 21. A recording form appropriate for immature measurements is included as Attachment 13. Since many of the cranial measurements require identification of landmarks that become ambiguous by the end of the first year of life, the list described in Table 1 should be applied to fetal and young infant (<1 year) materials only. If any of the deciduous incisor teeth are fully erupted with the roots virtually complete, you will probably have trouble identifying landmarks for the measurements listed in Table 1. When sufficiently complete, crania and mandibles from older juveniles should be measured according to the standards recommended for adults (see Chapter 7).

Most postcranial measurements listed in Figure 21 do not, however, suffer limitations similar to those for the skull and are therefore suitable for all immature materials (<18 years). When either the distal or the proximal long bone epiphysis is fused, the bone should be measured according to these standards. The recorder should estimate the diaphysis terminus and place an asterisk by the entry on the recording form (to indicate that the measurement was estimated). If both epiphyses are fused, then the bone should be considered "adult" for measurement purposes and recorded according to the standards developed in Chapter 7.

The instruments necessary for the measurements defined here include sliding calipers and an osteometric board. All measurements should be recorded to the nearest millimeter and taken on the left side in the case of bilateral measurements. The right side may be substituted if the left is not measurable, with an "R" placed in parentheses next to the measurement. If bones are fragmented or distorted, measurements should not be taken. Dimensions should, however, be estimated in situations of minor erosion or reconstruction and identified by an asterisk "*" on the recording form.

Recommendations for determinations of intra- and inter-observer error appear in Appendix II.

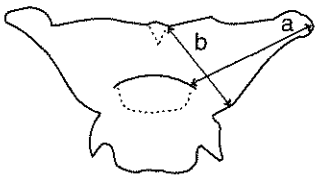

1. Lesser Wing of the Sphenoid

(a) Length: Distance from the lateral tip of the lesser wing to the midline of the synchondrosis intersphenoidalis. In very young fetuses measure the distance between the tip and the medial end of the lesser wing.

(b) Width: Greatest width of the lesser wing measured across the optic canal.

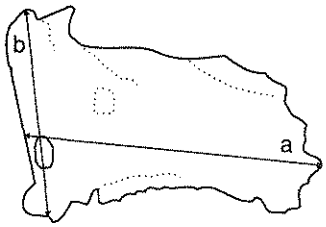

2. Greater Wing of the Sphenoid

(a) Length: Greatest distance between the medial pterygoid plate and the lateral tip of the greater wing.

(b) Width: Greatest distance between the sphenoidal spine and the anterior end of the pterygoid plate.

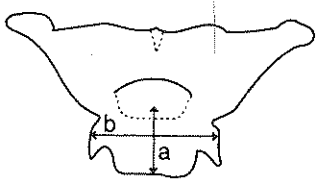

3. Body of the Sphenoid

(a) Length: Distance measured in the midline, between the synchondrosis intersphenoidalis and synchondrosis spheno-occipitalis.

(b) Width: Greatest distance measured transversely in the plane of the middle part of the hypophyseal fossa.

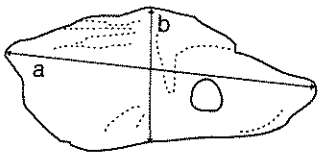

4. Petrous and Mastoid Portions of the Temporal Bone

(a) Length: Greatest distance between the apex of the petrous part and the superior posterior end of the mastoid part.

(b) Width: Greatest distance measured in the vertical plane of the posterior surface of the petrous bone.

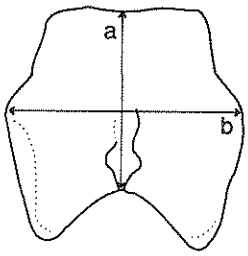

5. Basilar Part of the Occipital

(a) Length: Minimum distance measured in the sagittal plane between foramen magnum and the synchondrosis spheno-occipitalis.

(b) Width: Greatest distance perpendicular to length (a).

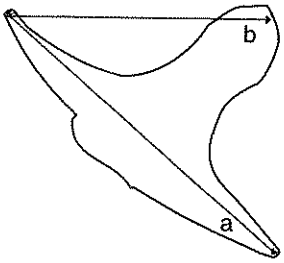

6. Zygomatic Bone

(a) Length: Distance between the anterior end of the infraorbital margin (marginal process) and the posterior end of the temporal process.

(b) Width: Distance between the anterior end of the infraorbital margin (marginal process) and the frontosphenoidal process.

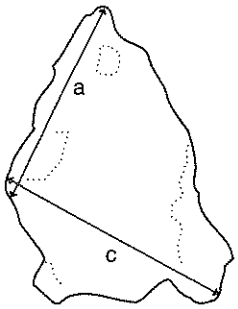

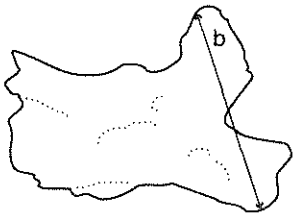

7. Maxilla

(a) Length: Distance between the anterior nasal process and posterior border of palatal process in sagittal plane.

(b) Height: Distance measured in the vertical plane between the alveolar part and the frontal process.

(c) Width: Distance between the posterior end of the palatal process (intermaxillary suture) and the end of the zygomatic process.

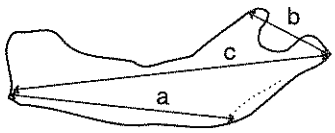

8. Mandible

(a) Length of the Body: Distance from the tuberculum mentale to the angle.

(b) Width of the Arc: Distance between the coronoid and the condyloid processes.

(c) Full Length of Half Mandible: Distance between the tuberculum mentale and the articular condyle.

Figure 21. Cranial measurements for young juveniles (fetal to 12 months). Numbers 1 through 8 correlate with those on Recording Form Attachment 13. Continued overleaf. Drawings by Zbigniew Jastrzebski (after Fazekas and Kosa 1978, pp. 43-51).



9. Clavicle

(a) Length: Maximum distance between the sternal and acromial ends.
(b) Diameter: Maximum diameter at midshaft.

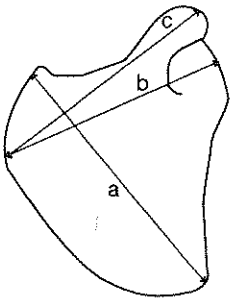

10. Scapula

(a) Length (height): Distance between the medial and inferior angles of the scapula.
(b) Width: Distance between the margin of the glenoid fossa and the medial end of the spine.
(c) Length of the Spine: Distance between the medial end of the spine and the tip of the acromion.

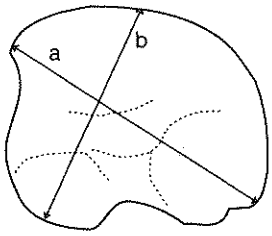

11. Ilium

(a) Length: Distance between the anterior superior and posterior superior spines.
(b) Width*: Distance between the middle point of iliac crest and farthest point on acetabular extremity.

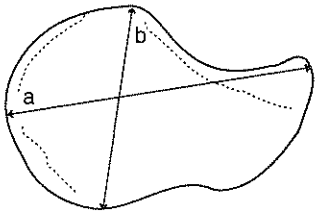

12. Ischium

(a) Length: Greatest distance between the acetabular extremity and the most ventral portion of the ischial tuberosity.
(b) Width*: Greatest distance of acetabular portion.

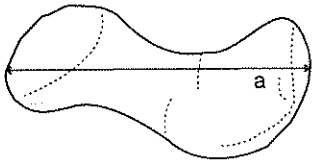

13. Pubis

(a) Length: Greatest distance between the symphyseal end and acetabular portion.

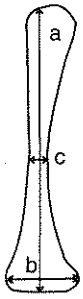

14. Humerus

(a) Length: Maximum length of diaphysis.
(b) Width: Maximum width of distal extremity.
(c) Diameter: Maximum diameter at midshaft.

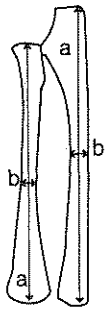

15. Ulna

(a) Length: Maximum length of diaphysis.
(b) Diameter: Maximum diameter at midshaft.

16. Radius

(a) Length: Maximum length of diaphysis.
(b) Diameter: Maximum diameter at midshaft.

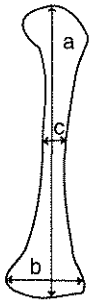

17. Femur

(a) Length: Maximum length of diaphysis.
(b) Width: Maximum width of distal extremity.
(c) Diameter: Maximum diameter at midshaft.

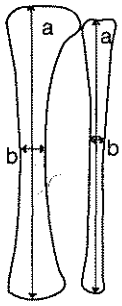

18. Tibia

(a) Length: Maximum length of diaphysis.
(b) Diameter: Maximum diameter at midshaft.

19. Fibula

(a) Length: Maximum length of diaphysis.
(b) Diameter: Maximum diameter at midshaft.

Figure 21, continued. Postcranial measurements for young juveniles (fetal to 12 months). Measurements that should only be taken on young juveniles are indicated by an asterisk. Numbers 9 through 19 correlate with those on Recording Form Attachment 13. Drawings by Zbigniew Jastrzebski (after Fazekas and Kosa 1978, pp. 43-51).

CHAPTER 5

DENTAL DATA COLLECTION I: INVENTORY, PATHOLOGY, AND CULTURAL MODIFICATIONS

Teeth are especially important for studies of ancient peoples because they reflect age-at-death, diet, heath, disease, and genetic affiliation (Kelley and Larsen 1991). Since the dentition maintains its integrity in buried contexts where bones may not be well preserved, teeth frequently are the only human tissues available for scientific inquiry. Inherited features of the dentition have therefore been highly visible in evolutionary studies, including investigations of the earliest humans (Dahlberg 1956; Gregory 1916; Hellman 1928; Scott and Turner 1988). Systems for scoring dental traits and measurements useful in studies of heritage are described in Chapter 6 (see also Turner et al. 1991).

In this chapter we describe methods for recording dental information relevant to the study of age, health, and disease. Research based upon these data complements the human skeletal studies described in other chapters of this volume. For example, dental wear is age related (see Chapter 3) and can therefore be used for estimating relative age-at-death within populations (Brothwell 1989; Lovejoy 1985; Miles 1962, 1963, 1978; Walker et al. 1991). As further discussed in Chapter 12, histological studies of various dental features, such as secondary dentin, root transparency, and cementum layers, provide additional techniques for refining the accuracy of age estimates (Burns et al. 1976; Charles, et al. 1989; Cook 1984; Gustafson 1950; Maples 1978; Maples and Rice 1979).

Since patterns of dental wear and disease are influenced by the nutritional quality and physical characteristics of food, studies of the dentition also contribute to dietary reconstructions. Microscopically visible abrasion features on dental enamel are important clues about the physical characteristics of foods (Bullington 1988; Smith 1984; Teaford 1988; Teaford and Oyen 1989), while the frequency of decay (or caries) can indicate the relative amount of sugar or carbohydrates in the diet and the amount of cooking (Larsen et al. 1991; Leigh 1925; Neuman and Poole 1974; Powell 1985; Rose et al. 1984; Turner 1979).

Unlike other calcified tissues, enamel does not remodel after it is formed. Therefore, dental defects such as linear enamel hypoplasias permanently record developmental disturbances experienced during infancy and childhood. Studies of defect location and pattern permit reconstructions of age-specific patterns of juvenile nutritional adequacy and physiological stress (Goodman and Rose 1991; Rose et al. 1985).

The methods recommended here for collecting data from human teeth represent only a limited selection of possible strategies. Our goal in creating this protocol has been to (1) maximize information recovery per unit of time; (2) minimize intra- and inter-observer error; and (3) use standard data collection procedures whenever possible.

DENTAL INVENTORY

Since any analysis of dental data requires knowledge of the presence and condition of all teeth, a detailed inventory *must* be created. We recommend that the inventory be recorded as numerical codes, supplemented by a visual format. The coding system illustrated in Attachment 14a assigns numbers 1-32 to the permanent dentition, beginning with the maxillary right third molar ("1"), continuing to the maxillary left third molar ("16"), moving to the mandibular left third molar ("17"), and concluding with the mandibular right third molar ("32"). Although the deciduous dentition (Attachment 14b) is commonly annotated by lower case letters rather than by numbers, we prefer a unified numbering system, beginning with

"51" for the maxillary right second molar, continuing to the maxillary left second molar ("60"), moving to the mandibular left second molar ("61"), and concluding with the mandibular right second molar ("70"). This numbering system facilitates data collection and computerized data entry from individuals with mixed permanent and deciduous dentitions.

While information can be recorded directly on the dental charts illustrated in Attachment 14, we recommend that the forms presented as Attachment 16 through 19 be used to more fully represent tooth presence, location of supernumerary teeth, dental attrition, pathology, and cultural modifications. Similar to recording devices employed by dentists, Attachments 14 and 15 present standard, idealized tooth drawings of occlusal, buccal (labial), and lingual surfaces. These charts can be used to amplify or enhance the data recorded in the other dental recording forms. Figure 22, an example of Attachment 14a after inventory and pathology data have been recorded, provides an example of how this form can be used as visual supplements to the numerical codes.

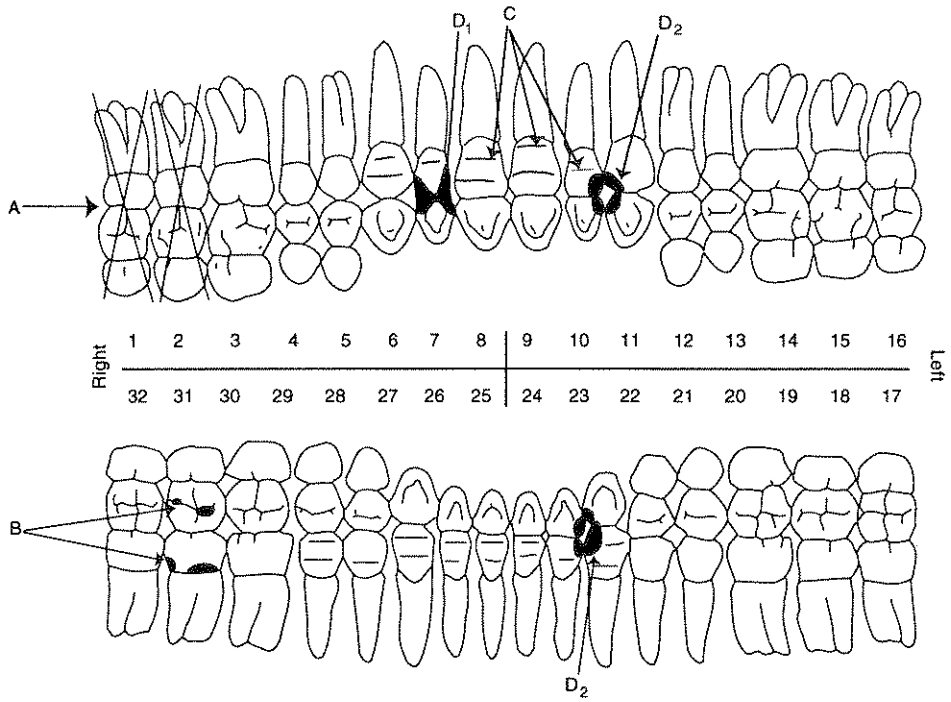

Figure 22. Example of Visual Recording Chart for Permanent Dentition (Attachment 14a) after data have been recorded. A indicates missing teeth; B reflects the location of caries (two occlusal, code = 1; one interproximal, code = 2; one cervical, code = 4); C illustrates the locations of hypoplastic bands; D provides examples of two forms of cultural modifications: D1 = filing, D2 = wear due to pipe smoking.

Inventory categories for coding the dentition on the Dental Inventory Recording Forms (Attachments 16 and 17) are presented in Table 2. These codes should be entered on the line marked "Presence." Categories 1, 2, 7, and 8 are appropriate for isolated teeth as well as relatively complete dentitions. Supporting alveolar tissues of the mandible and maxilla must be observed in recording categories 3-6. Category 8 ("present, but unobservable") should be used to describe unerupted deciduous or permanent teeth which are partially visible in crypts in the maxilla or mandible.

Teeth coded as "1" (present, but not in occlusion) should also be classified according to the formation sequence described by Moorees et al. (1963a, 1963b), as listed and illustrated in Figure 23. These codes should be entered on Attachments 16 and 17 in the appropriate box in the row marked "Development." While there are many approaches to

Table 2
Inventory Categories for Recording the Dentition

1. Present, but not in occlusion
2. Present, development completed, in occlusion
3. Missing, with no associated alveolar bone
4. Missing, with alveolus resorbing or fully resorbed: premortem loss
5. Missing, with no alveolar resorption: postmortem loss
6. Missing, congenital absence
7. Present, damage renders measurement impossible, but other observations are recorded
8. Present, but unobservable (e.g. deciduous or permanent tooth in crypt)

translating these developmental stages to chronological age, e.g., Ubelaker 1989a and Smith 1991, the Moorees, Fanning and Hunt system is the most readily applied strategy for recording tooth formation. Numbers 1-14 are used to indicate sequential stages of crown and root completion. Since many observers are familiar with the Moorees, Fanning, and Hunt system, we also list their alphanumeric symbols.

Figures 23 reproduces illustrations from Moorees et al. (1963a, 1963b) for stage of crown, root, and apex formation in deciduous mandibular canines, deciduous mandibular molars, and mandibular permanent molars. These basic models for single and multirooted teeth are easily adapted to other tooth classes—both deciduous and permanent. After assessing dental development, we ask that the observer estimate chronological age. Figure 24 provides a composite visual image of dental development stages keyed to chronological age. The observer should record on Attachments 16 and 17 the chronological age of the stage which provides the closest "fit" with the observed pattern. If the observed developmental pattern lies between two of the stages illustrated in Figure 24, chronological ages appropriate to both should be recorded as a range on Attachments 16 and 17.

The presence of supernumerary teeth should be indicated graphically on the drawings provided in Attachment 15. Attachment 15a is appropriate for the maxillary dentition, while 15b should be used to report mandibular supernumeraries. Location should be coded as:

1. In tooth row
2. Within palate or on lingual aspect of mandible
3. Within palate, mesiodens (on midline, upper arcade only)
4. External to tooth row

The observer should identify the supernumerary's location by indicating adjacent (the two nearest) teeth by code in the space provided on the recording form. Supernumerary teeth should also be listed in the space provided on the Dental Inventory Recording Forms.

Occlusal Surface Wear

An extensive literature documents the utility of dental attrition in reconstructing prehistoric diets, estimating age-at-death, and explaining incidence patterns for dental diseases such as caries and abscesses (Brothwell 1989; Lovejoy 1985; Miles 1962,1963, 1978; Murphy 1959a; Powell 1985; Smith 1984; Walker et al. 1991). Dietary reconstructions are enhanced by the fact that within a given age group more extreme attrition is associated with consumption of relatively coarser foods. For example, the significant reduction in dental wear that occurred with the introduction of agriculture in North America indicates reduced coarseness of the diet along with differences in food composition and food preparation technology (Smith 1984). Since dental wear reduces the locations available for caries development, any analysis of caries frequencies must also consider attrition rates (Powell 1985). In addition, dental attrition scores are important in the development of population-specific estimates of age-at-death (Chapter 3).

There are a number of systems available for recording occlusal surface wear. We recommend a format that has demonstrated utility in dietary reconstruction and is relatively easy to use. Only teeth from the left side of the arcade should

Ci initial cusp formation
Cco coalescence of cusps
Coc cusp outline complete
Cr. 1/2 crown 1/2 complete
Cr. 3/4 crown 3/4 complete
Cr. c crown complete
Ri initial root formation
Cl. i initial cleft formation
R 1/4 root length 1/4
R 1/2 root length 1/2
R 3/4 root length 3/4
Rc root length complete
A 1/2 apex 1/2 closed
A c apical closure complete

a. Deciduous mandibular canines

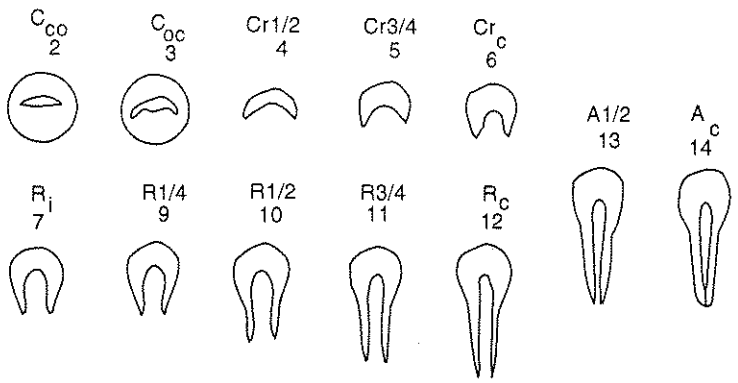

b. Deciduous mandibular molars

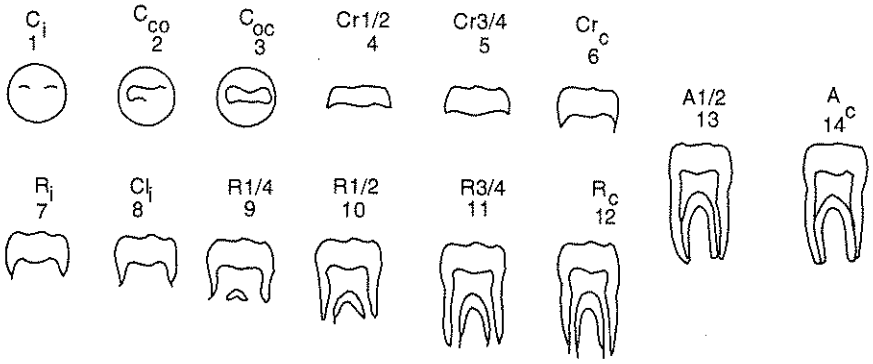

c. Permanent mandibular molars

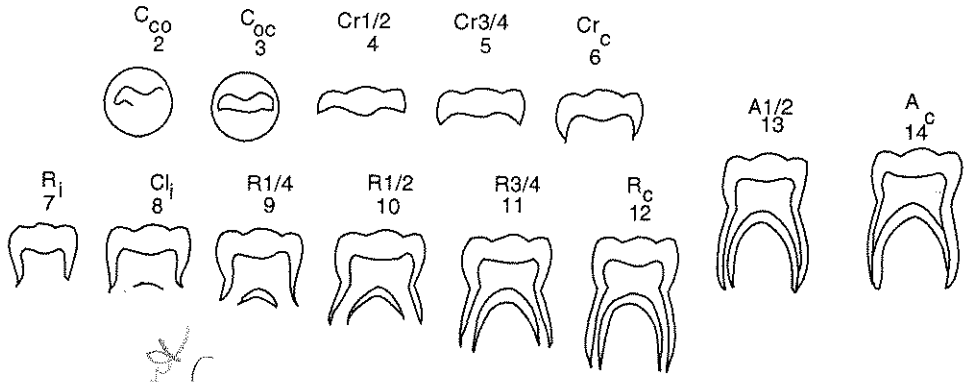

Development

Code	Stage	Code	Stage
1	Initial cusp formation	8	Initial cleft formation
2	Coalescence of cusps	9	Root length 1/4
3	Cusp outline complete	10	Root length 1/2
4	Crown 1/2 complete	11	Root length 3/4
5	Crown 3/4 complete	12	Root length complete
6	Crown complete	13	Apex 1/2 closed
7	Initial root formation	14	Apex closed

Figure 23. Stages of formation for the crown, root, and apex of a) deciduous mandibular canines; b) deciduous mandibular molars; c) permanent mandibular molars. The Moorees, Fanning, and Hunt code appears above the numerical code for each stag. Drawings by Zbigniew Jastrzebski (after Moorees et al. 1963a, Figures 1 and 2; 1963b).

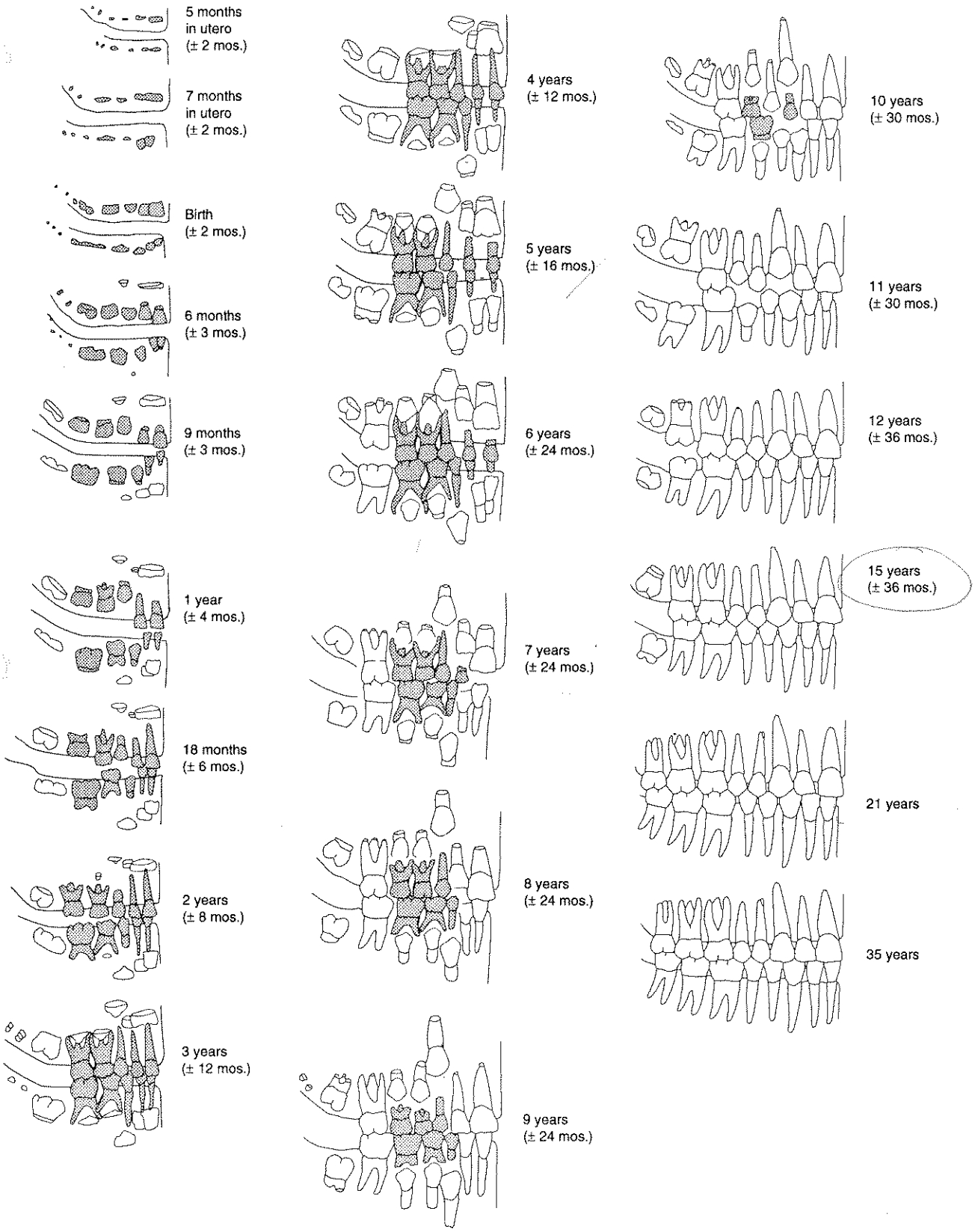

Figure 24. Sequence of formation and eruption of teeth among American Indians (after Ubelaker 1989a, Figure 71).

be recorded, with substitutions from the right if the left tooth is missing. In instances when marked asymmetry is present, the researcher should record observations for all teeth. Such asymmetries commonly arise due to dental disease, use of teeth as tools (see below), or craniofacial anomalies.

Given that most osteologists are familiar with some variant of the Murphy (1959b) system, we recommend that the Murphy system as modified by Smith (1984) be adopted for the premolars, canines, and incisors. As illustrated in Figure 25, wear is recorded along an eight point scale, based on the amount of exposed dentin. Each tooth should be matched to the drawings (Figure 25) and descriptions of the illustrated attrition stages. If a tooth is not observable, the space on the recording form should be left blank. Wear should be recorded on Attachment 16.

Since the Smith system discriminates poorly when attrition rates are moderate to low, we prefer the standards developed by Scott (1979) for molars. In the Scott system, each molar occlusal surface is divided into quadrants and the amount of observable enamel is scored on a scale between 1 and 10. Both written descriptions and the illustrations presented in Figure 26 should be used. The final score recorded for each tooth is the sum of scores for the four quadrants, thus yielding a possible range from 4 to 40. If any quadrant is not observable, then the space on the recording form for that tooth should be left blank. The antimere should then be scored, if it is sufficiently complete. Scores should be recorded in the space provided in Attachment 16.

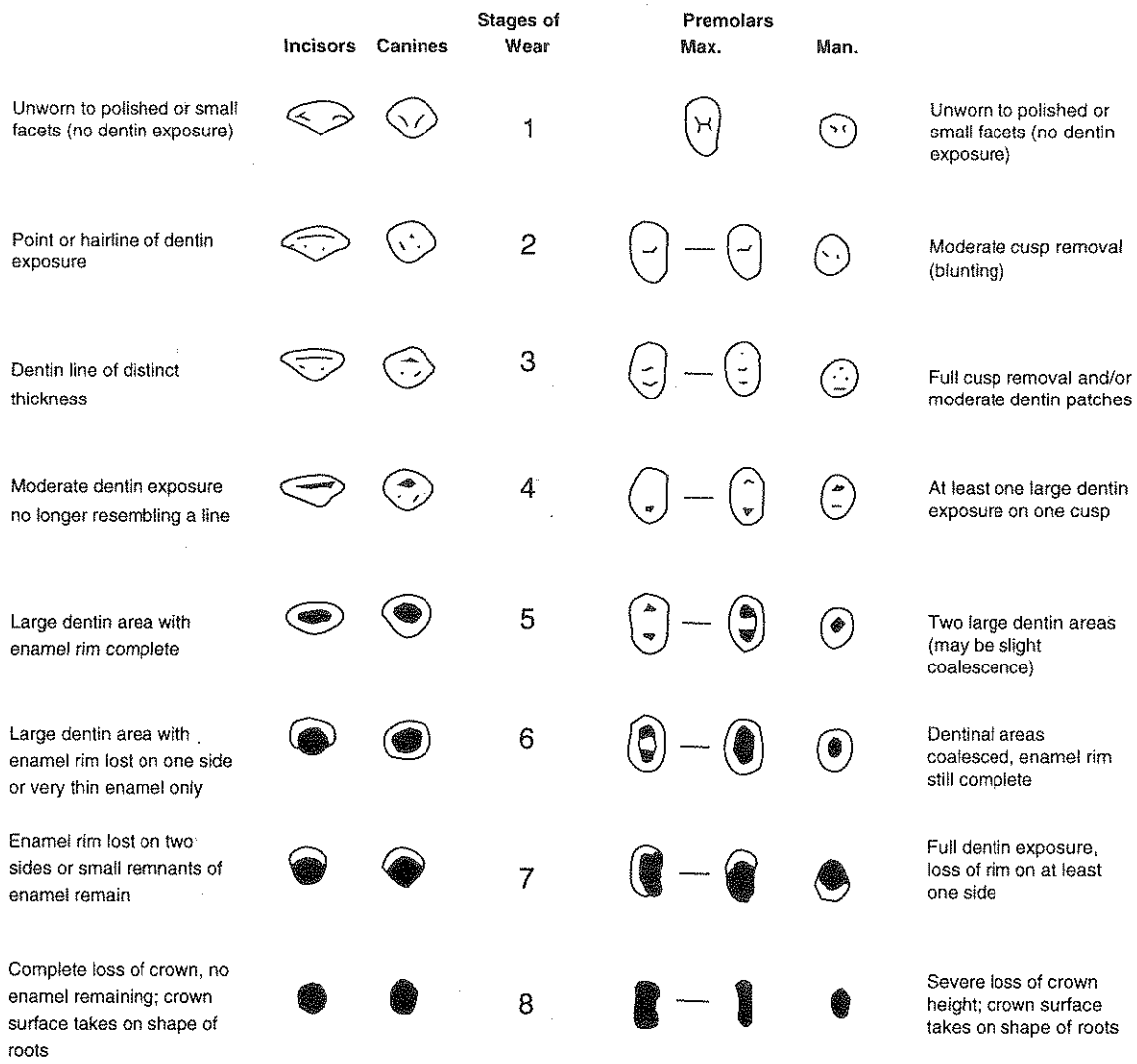

Figure 25. Surface wear scoring system for incisors, canines, and premolars. Drawings by Zbigniew Jastrzebski (after Smith 1984:45-46).

continues for molars –
Dental Anthropology
Smith
Hillson

Score	Description
0	No information available (tooth not occluding, unerupted, antemortem or postmortem loss, etc.)
1	Wear facets invisible or very small
2	Wear facets large, but large cusps still present and surface features (crenulations, noncarious pits) very evident. It is possible to have pinprick size dentine exposures or dots which should be ignored. This is a quadrant with much enamel.
3	Any cusp in the quadrant area is rounded rather than being clearly defined as in 2. The cusp is becoming obliterated but is not yet worn flat.
4	Quadrant area is worn flat (horizontal) but there is no dentine exposure other than a possible pinprick sized dot.
5	Quadrant is flat, with dentine exposure one-fourth of quadrant or less. (Be careful not to confuse noncarious pits with dentine exposure.)
6	Dentine exposure greater: more than one-fourth of quadrant area is involved, but there is still much enamel present. If the quadrant is visualized as having three sides (as in the diagram) the dentine patch is still surrounded on all three sides by a ring of enamel.
7	Enamel is found on only two sides of the quadrant.
8	Enamel on only one side (usually outer rim) but the enamel is thick to medium on this edge.
9	Enamel on only one side as in 8, but the enamel is very thin—just a strip. Part of the edge may be worn through at one or more places.
10	No enamel on any part of quadrant—dentine exposure complete. Wear is extended below the cervicoenamel junction into the root.

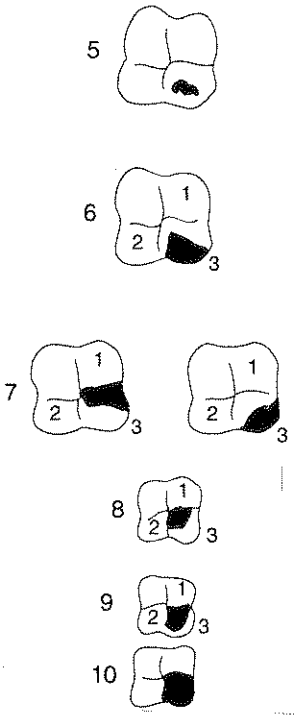

Figure 26. Scott system for scoring surface wear in molars. Drawings by Zbigniew Jastrzebski (after Scott 1979: 214).

ENAMEL MICROWEAR

Analyses of enamel microwear using scanning electron microscopy (SEM) have proven useful in dietary reconstruction (Gordon 1984a, 1984b; Rose and Harmon 1986; Teaford 1988, 1991; Teaford and Oyen 1989). SEM studies provide data on the size and quantity of dietary particles and abrasive inclusions, as well as the presence of other materials such as nut hulls, plant fibers, and acids. The short temporal life of microwear features provides opportunities for assessing dietary change and even seasonality of death. We anticipate that SEM investigations of enamel microwear will become increasingly prominent in studies of archaeological collections.

The study of enamel microwear therefore holds excellent potential for future research concerning diet and food preparation technology. As the study of enamel microwear is relatively new, however, there are presently no widely accepted data collection standards. The absence of standard protocols, coupled with the fact that quantitative analysis of microwear features is extremely time consuming, leads us to recommend against directly observing microwear during

recording. Instead, we suggest that a tooth demonstrated to be maximally informative in previous SEM studies be retained for future investigations. The second mandibular left molar is the ideal choice because it best represents microscopic features and is seldom subject to excavation and postexcavation damage. The right M_2 should be substituted if the left is not available.

Although casting is clearly a less desirable alternative than long term curation of actual teeth, high resolution casts also record details appropriate for SEM analysis. Molds can be made using light body polysiloxane impression materials such as Coltene's President™ or 3M's Express™. Super hard epoxy resins are recommended for the casts (Beynon 1987; Goodman and Rose 1990:94; Teaford and Oyen 1989). Addresses for companies selling these products are:

Light body impression materials		Super Hard Epoxy Resin
Coltene Inc. 14 Kane Industrial Dr. Hudson MA 01749	3M Dental Products Division Building 225-4S-11 3 M Center St. Paul MN 55144-1000	TAP Plastics 7176 Regional St. Dublin CA 94568

Because all dentists are familiar with molding and casting techniques, they can serve as excellent sources of advice and other forms of assistance.

We recommend the casting methods described by Beynon (1987), who also provides additional technical details and information on dimensional stability of molds and casts. Equipment and supplies required for this process include the light body impression compound, putty, the epoxy casting materials, medium weight aluminum foil, a syringe, and a mold appropriate to the size of the tooth (optional). Although the mold is not absolutely necessary, its use will minimize the amount of casting materials required. Beynon's technique, which produces a cast suitable for long term curation, is summarized below.

> The light body systems employ a putty which is used to make a base mold. The putty should be mixed according to the manufacturer's instructions. A round mound larger than the specimen should be placed on a flat surface or in a suitably sized mold. The occlusal surface of the molar to be cast should be covered by medium weight aluminum foil pressed closely against the surface. This provides a space for the light body compound. After the base compound hardens, the tooth should be removed and any compound overlapping the occlusal surface dimensions trimmed. The foil should then be removed and a thin coating of the light body compound, mixed according to manufacturer's instructions, syringed onto the tooth surface and within the base mold. The tooth should be reinserted with firm pressure into the base mold and excess compound extruded. Once hardened, the mold should be flexed and the tooth removed. The positive cast is made with an epoxy having low shrinkage properties. The epoxy should be syringed slowly into the mold to ensure entry into all small spaces and to avoid introducing bubbles which will cause surface defects in the casts. Holding the mold on a standard dental vibrator while pouring the epoxy will aid in eliminating bubbles (after Benyon 1987).

Dental Caries

Dental caries, which appear as dark eroded regions of the tooth enamel, are among the most common and the most informative dental pathologies observed in archaeological samples. An association between increased caries frequencies and the consumption of foodstuffs rich in sugar/carbohydrates makes caries analysis especially useful in dietary reconstructions (Powell 1985; Turner 1979). For example, investigations of dental health have contributed to our knowledge of agricultural intensification in late prehistory (Cohen and Armelagos 1984; Rose, Marks, and Tieszen 1991) and the impact of western diets among the Eskimo (Moorees 1957).

Caries data assume their full analytical potential when based upon records of tooth type and surface. Each tooth class demonstrates a characteristic susceptibility to caries. Incisors and canines, for example, typically present little evidence for caries, when compared to the morphologically more complex, and hence more cavity-prone, posterior teeth. Under similar dietary regimes, archaeological series disproportionately represented by anterior teeth will show relatively low caries rates when compared to collections with higher proportions of molars. It is therefore imperative that the dental inventory be conducted in such a way that teeth without caries are clearly differentiated from situations in which observations could not be made, e.g., teeth lost pre- or postmortem.

Tooth surfaces also vary in susceptibility to caries. Complex occlusal surfaces are most likely to present evidence of caries, while the smooth sides of the crown are seldom affected. Coarser diets facilitate natural cleaning and thus lower

caries rates. With age and periodontal disease, interproximal, cervical, and root caries become more common. Therefore caries must be analyzed as age-specific frequencies, and in association with information about dental attrition.

The system recommended here for reporting caries is a modification of that designed by Moore and Corbett (1971). Caries should be recorded for each of the 32 permanent and 20 deciduous teeth by tooth surface. The location of each example should also be indicated on the Visual Recording Chart (Attachments 14a and b).

0. ***No Lesion Present***
1. ***Occlusal Surface:*** all grooves, pits, cusps, dentin exposures, and the buccal and lingual grooves of the molars
2. ***Interproximal Surfaces:*** includes the mesial and distal cervical regions
3. ***Smooth Surfaces:*** buccal (labial) and lingual surfaces other than grooves
4. ***Cervical Caries:*** originates at any cemento-enamel junction (CEJ), except the interproximal regions
5. ***Root Caries:*** below the CEJ
6. ***Large Caries:*** cavities that have destroyed so much of the tooth that they cannot be assigned a surface of origin
7. ***Noncarious Pulp Exposure:*** see below

Each case of caries should be recorded by surface on Attachment 16 (permanent teeth) or 17 (deciduous teeth), using the numerical codes presented above. If more than three carious lesions are present on one tooth, use a slash or slashes to divide the boxes on the recording form in half. Then record one carious lesion in each half of the divided box(es). Because caries is age progressive, it should not be recorded by size.

Reliability in reporting dental caries increases dramatically if only those cases which have penetrated the surface enamel are reported (Moore and Corbett 1971: 157). These appear as stained, irregularly walled cavities. If doubt exists, *do not* record the observation.

Caries should be recorded following visual inspection. Rudney and coworkers (1983) report that this method produces higher inter-observer reliability than either explorer (dental probe) or radiographic techniques.

A situation which has caused confusion in a number of studies is exposure of the pulp chambers by rapid dental attrition. Exposed pulp chambers appear as large, deep round holes located in the middle of the tooth or at the cusp center in multicusped teeth. This configuration may closely resemble caries, even though exposure of the pulp chamber does not always lead to caries development or abscesses. One criterion used in identifying noncarious pulp exposures is the presence of these features in several adjacent teeth, commonly the mandibular anterior dentition. Noncarious pulp chamber exposure should be noted on the recording form as caries category "7," but should not be counted in developing caries frequency data.

Abscesses

Abscesses indicate pulp chamber inflammation following excessive attrition or dental caries. Apical abscessing may also occasionally result from enamel cracks after trauma or from spontaneous idiopathic phenomena. As illustrated in Figure 27, abscesses can be identified by the presence of a drainage channel leading from the apex of the tooth root through the alveolar bone. Apical abscess presence and location should be recorded on Attachments 16 or 17, with a "1" indicating a buccal or labial alveolar channel and a "2" denoting a lingual perforation. The location can also be recorded visually on Attachment 15. An "0" indicates absence.

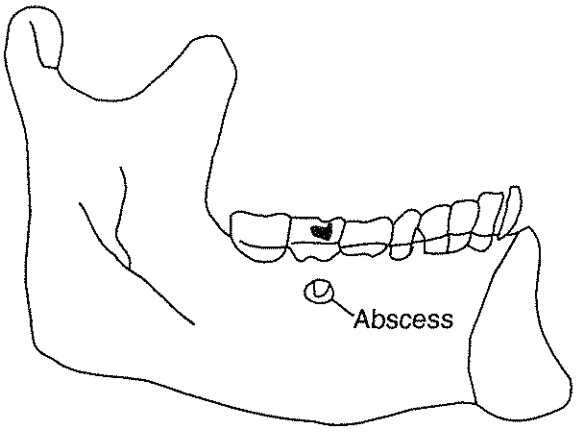

Figure 27. Abscess of a left second mandibular molar showing a lingual drainage channel from the root apex through the alveolar bone.

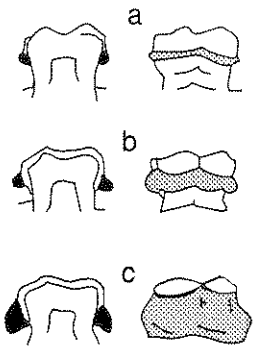

Figure 28. Illustrations of variations in degree of dental calculus formation: a) small amount (code = 1); b) moderate amount (code = 2); c) large amount (code = 3) (after Brothwell 1981, Figure 6.14b).

Dental Calculus

Calculus (calcified plaque, see Figure 28) frequently traps food remains and plant phytoliths and can therefore be useful in dietary reconstructions. Calculus samples should be removed from teeth and curated for future microscopic and chemical analyses. A dental pick can be used to remove calculus from the tooth surface without damaging the tooth or the alveolus.

Rates of calculus formation are difficult to estimate since many deposits suffer postmortem loss. Overexuberant cleaning during conservation is a particularly destructive factor.

Calculus should be reported as "0" (absent), "1" (small amount), "2" (moderate amount), "3" (large amount), or "9" (unobservable) in Attachments 16 and 17. Note whether the calculus occurred on the buccal (labial) or the lingual aspect of the tooth. Figure 28 illustrates each degree of calculus formation. The tooth (or teeth) from which calculus samples are removed should be indicated on the recording form by an "S."

Enamel Defects: Hypoplasias and Opacities

Various systemic stressors such as malnutrition and infectious disease can produce abnormal enamel during dental development. Studies of living people indicate that the form and frequency of developmental disturbances such as enamel hypoplasias and opacities reflect health status and diet quality. Since enamel formation is cumulative, a permanent record of juvenile developmental disturbances is available through the study of enamel defects. Given that dental maturation occurs according to a predictable schedule, age-specific health patterns for juveniles can be reconstructed from studies of adult dentitions (Rose et al. 1985; Goodman and Rose 1990).

Hypoplasias are deficiencies in enamel thickness which may be caused by three phenomena: systemic metabolic stress, hereditary anomalies, and localized trauma. Caused by defects in matrix secretion, hypoplasias are distinctive from enamel opacities, which reflect imperfect enamel mineralization. Enamel opacities are thought to reflect systemic stress, though upon occasion trauma may also produce enamel discoloration. Examples of both true hypoplasias and accentuated perikymata, which should not be recorded, are illustrated in Figure 29.

In studies of archaeologically recovered materials, enamel defects reflecting systemic metabolic stress should be identified and recorded. Other causes, such as hereditary anomalies and localized trauma, are relatively rare and less pertinent to reconstructions of ancient lifeways. Hereditary anomalies, while rare, are normally present as severe destructive lesions throughout the dentition. Nonsystemic factors such as local trauma or inflammation generally influence only one, or at most a few, adjacent teeth. Systemic metabolic stress commonly produces defects in multiple locations that reflect completeness of enamel crowns at the time of insult. We therefore limit our analyses to widespread, age-specific lesions.

Enamel defects should be recorded on Attachment 18, using the following key. The first five attributes describe hypoplasias, and the last two reflect boundary characteristics of hypocalcified enamel.

0. Absence
1. Linear horizontal grooves
2. Linear vertical grooves
3. Linear horizontal pits
4. Nonlinear arrays of pits
5. Single pits
6. Discrete boundary opacity
7. Diffuse boundary opacity

Hypoplastic features should be recorded by type and location. Although in recently erupted teeth location could be indicated by distance from the incisal edge or cusp tip, attrition rapidly renders this measurement impossible. We therefore recommend measuring the distance from the midpoint of the labial/buccal cemento-enamel-junction (CEJ) to the

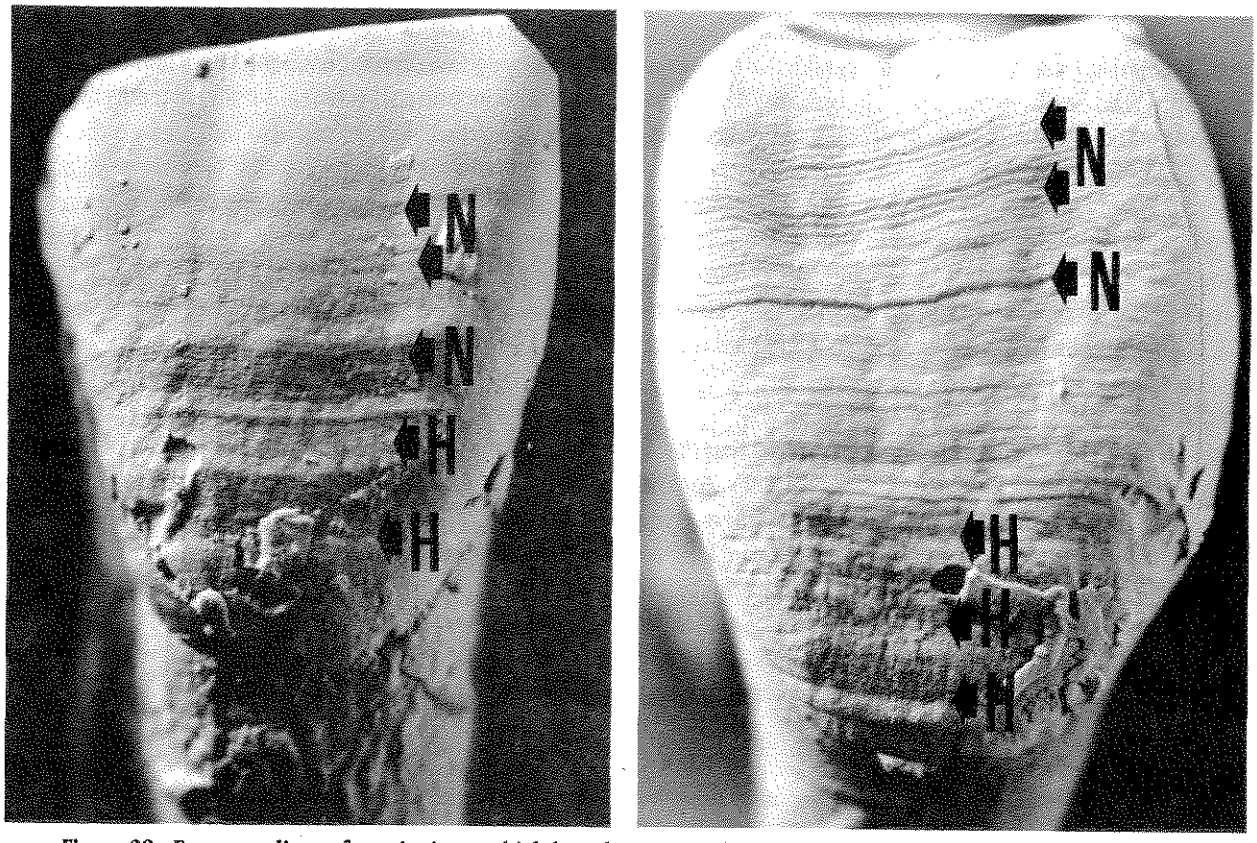

Figure 29. Epoxy replicas of two incisors which have been coated with ammonium chloride. Hypoplasias have been marked with an "H," while other features which might be mistaken for hypoplasias are marked with an "N." Hypoplasia classification has been confirmed by examining the histological structure in thin section. Photos by Lela Donat.

most occlusal portion of the hypoplasia. Through use of standard tables (Rose et al. 1985; Goodman and Rose 1990), this measurement can be converted into age of occurrence. While some researchers argue that both the width and depth of hypoplastic features carry information about duration and severity of poor health, such inferences have yet to be firmly grounded in clinical evidence. If time permits, width of the hypoplastic feature may be recorded, especially in examples of severe defects. Distance from the CEJ to the most distant (occlusal) aspect of the defect is, however, the single most important measurement. All examples of multiple distinctive bands on a single tooth should be recorded.

We also wish to underscore the importance of crown height measurements on both healthy and defective teeth, as described in the following section on dental measurement (Chapter 6). Also useful in studies of dental wear, crown height measurements provide crucial background information concerning availability of enamel surfaces for observation of dental defects.

Hypocalcifications (opacities) normally appear as either transverse bands or oval areas on the labial or buccal surfaces of the crown. They vary according to color, location, and boundary characteristics. Color should be coded according to the following standard.

1. Yellow
2. Cream/white
3. Orange
4. Brown

As noted above, boundary characteristics should be reported as either discrete ("6") or diffuse ("7"), while locations should be measured in the same manner as hypoplasias. For example, a cream/white discrete hypocalcification located 6.2 mm from the CEJ of the right central incisor would be recorded as "8:6,6.2, 2" in the appropriate boxes on Attachment 18.

When time does not permit observation of dental defects throughout the dentition, we recommend recording data from the maxillary central incisors and mandibular canines in both primary and secondary dentitions. Both antimeres (right and left) should be observed. A more informative data set would include all incisors and canines. Ideally, all teeth should be observed. The location of each defect should be recorded numerically on Attachment 18 and also indicated on the visual recording chart (Attachment 14).

Given changing levels of specificity in recording dental hypoplasias, we recommend retaining one maxillary central incisor and one mandibular canine for future scholarship . If curation is impossible, high quality casts and photographs should be made of the labial/buccal surfaces of these teeth. Casting procedures outlined in the discussion of dental microwear above should be followed (Beynon 1987; Goodman and Rose 1990: 94; Teaford and Oyen 1989), accompanied by dental photography (see Chapter 2 for recommended procedures).

Premortem Dental Modifications

There are a variety of cultural behaviors that may alter dentitions. Some of these involve deliberate modifications such as filing and inlays. Others result inadvertently from habitual behaviors such as pipe smoking or use of the mouth as a third hand while working vegetal or animal fibers. Since many of these modifications are idiosyncratic, the best documentation is clear, thorough description, including discussion of the surface(s) affected, the nature of the modification, and any introduced materials. Locations should be indicated on the visual recording chart (Attachment 14). Each example should be photographed, following the procedure outlined in Chapter 2.

Premortem dental modifications should be assigned to one of the following categories and the appropriate designation entered on Attachment 19. Examples of premortem modifications are illustrated in Figure 30.

1. ***Surface Modifications: Filing*** (see Figure 30a, b, and d). Filing, commonly of the anterior teeth, may produce a variety of forms.
2. ***Surface Modifications: Drilling, with or without inlays*** (see Figure 30a and c). Circular depressions are commonly sites of inlays, which may or may not be recovered archaeologically. Microscopic verification of circular striations and introduced adhesive material ensures that this form of cultural modification is correctly identified. Both the nature of the adhesive and the inlay, if present, should be reported.
3. ***Dental Restorations and Appliances.*** The form and extent of appliances and restorations should be discussed by location and the materials used.
4. ***Dental Wear Associated with Artifact Use or Production*** (see Figure 30e). Wear or chipping patterns associated with such habitual activities as pipe smoking and fiber modification should be described by location, including surface(s) affected. Focus upon careful description of the unusual pattern rather than speculating about causative agents. Note that alterations in this category can include grooves produced by pulling thin strings or thread through the teeth (Cybulski 1974; Schultz 1977), unusual chipping due to the use of teeth as tools (Turner and Cadien 1969), and interproximal grooves resulting from habitual use of toothpicks (Ubelaker et al. 1969; Frayer and Russell1987). In recording interproximal grooves, it is important to note their relationship to any carious lesions and evidence for periodontal disease in the adjacent alveolus.
5. ***Tooth Ablation.*** Intentional removal of teeth as a cultural practice. Often difficult to distinguish from accidental premortem loss. Symmetrical loss in several individuals strengthens an argument for ablation.

Dental Samples

For the study of dental pathology and wear, we recommend that at least six teeth be retained for future analyses:

1. Central Maxillary Incisor
2. Both Mandibular Canines
3. Mandibular 1st and 2nd Premolar
4. Mandibular Second Molar

Maxillary incisors and mandibular canines are important in studies of dental hypoplasias, while the mandibular second molar provides the basis for studies of microwear. As discussed in Chapter 12, anterior teeth such as canines and premolars are important for histological estimates of age-at-death (using modifications of the Gustafson technique). The study of growth layer groups within the cementum of lower premolar roots also holds excellent promise for estimates of age-at-death.

a

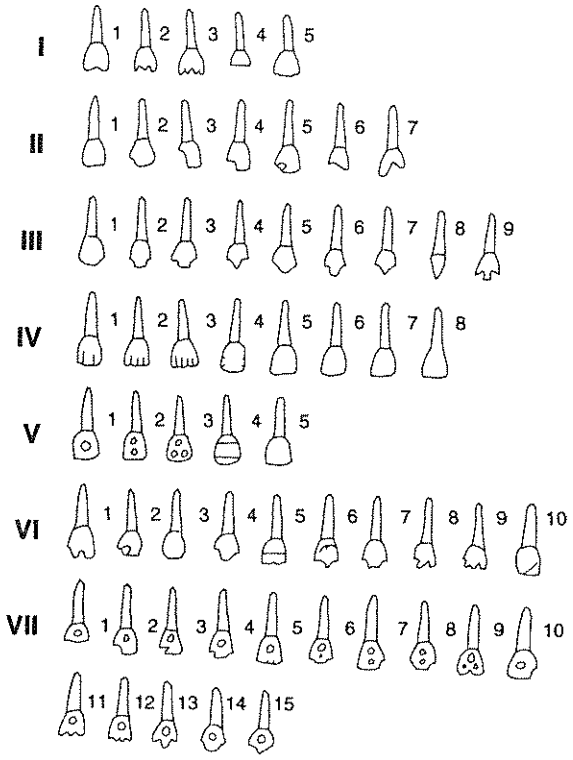

I -III. Modification of the edge

IV-V. Modification of outer (labial) surface

VI-VII. Modification of both the edge and labial surface

b

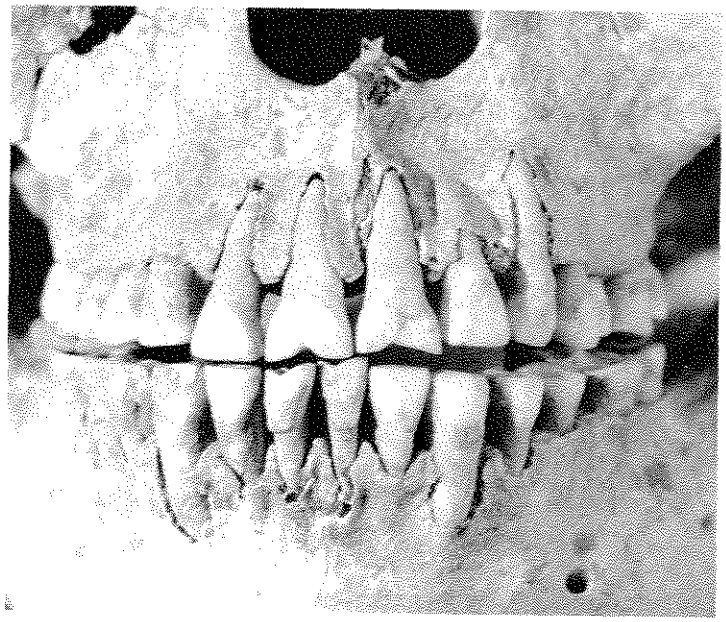

c

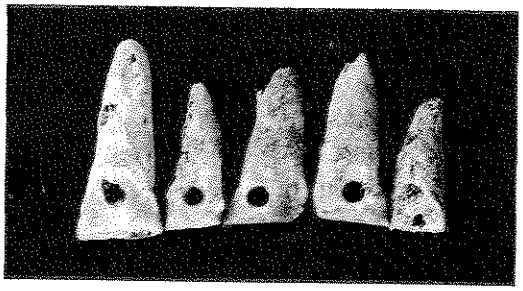

Figure 30a-c. Premortem dental modifications. a) Classification of types of dental mutilation employed for ornamental effect in precolumbian America. b) Filing of upper and lower central incisors; c) Perforations for inlay. Photos, previously published in Ubelaker 1989a as Figures 93 and 110. Courtesy of D. H. Ubelaker and Taraxacum Press.

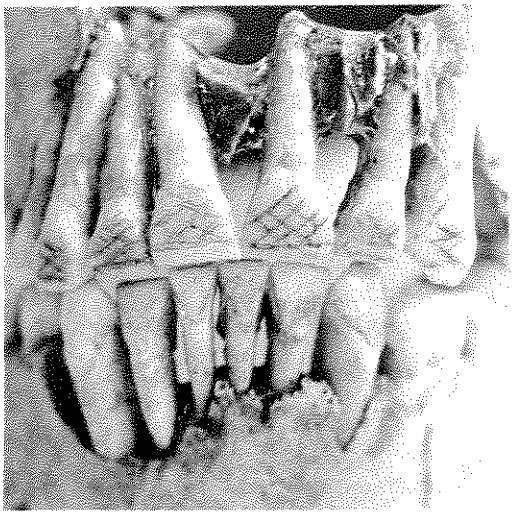

d

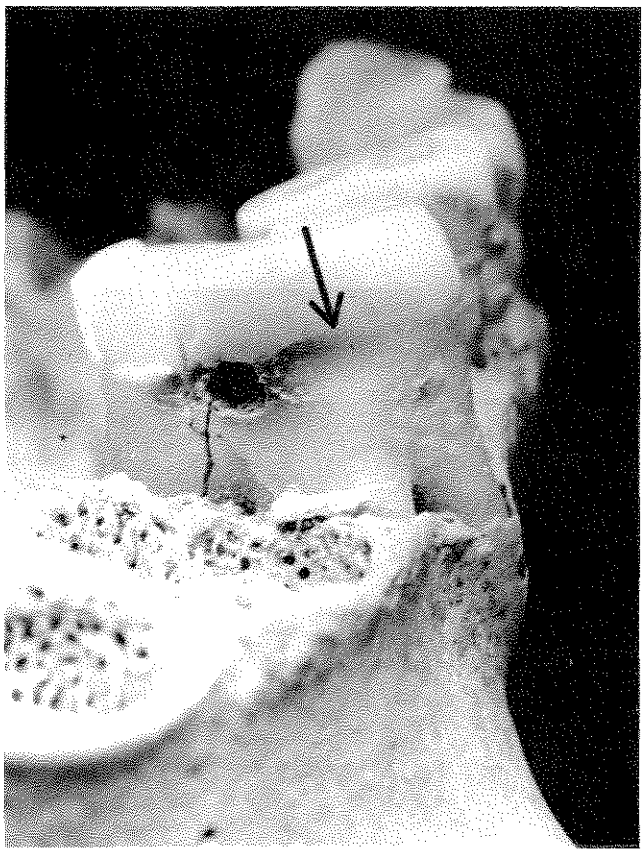

e

Figure 30d-e. Premortem dental modifications. d) Crosshatch (decoration); e) Interproximal grooving on a mandibular molar. Previously published in Ubelaker 1989a as Figures 111-112. Courtesy of D. H. Ubelaker and Taraxacum Press.

CHAPTER 6

DENTAL DATA COLLECTION II: DENTAL MORPHOLOGY AND MEASUREMENTS OF THE SECONDARY DENTITION

Observations of tooth shape and size convey information about genetic relatedness and are therefore important for studies of heritage at worldwide, continental, regional, and community levels. Early migrations from Asia into the Americas have been charted through studies of dental morphology (Turner 1989). Within geographic regions, dental measurements and morphological features have been used to examine population replacement as an explanation for culture change among Archaic and Woodland populations from eastern North America (Sciulli 1979; Sciulli and Granby 1989). In addition, the durability of teeth has made them a key data source for comparative study of fossil and recent humans. Further discussion of dental features in comparative and evolutionary perspectives can be found in Kelley and Larsen (1991) and Scott and Turner (1988).

Inherited tooth form must also be considered when evaluating dental health and the impact of food preparation techniques. Complex enamel surfaces, for example, provide ideal environments for the development of caries. Shovel-shaped incisors are well suited for withstanding the typical biomechanical stresses of tool use and mastication in Arctic populations following traditional subsistence strategies. The robust lingual ridges characteristic of shoveling, however, serve as food traps and thus became a cariogenic liability following the introduction of refined sugars by European explorers and immigrants (Mayhall 1976). An evolutionary tendency for dental reduction in *Homo sapiens* has also been noted and linked to food preparation technology (Brace et al. 1991).

In this chapter we discuss methods for observing key morphological features of the dentition and for recording standard measurements. Given the importance of teeth in bioarchaeological studies, we also recommend that all dentitions — both primary and secondary — be cast in dental stone, as discussed in Chapter 2. Recommendations for determinations of intra- and inter-observer error appear in Appendix II.

DENTAL MEASUREMENTS

Tooth measurements provide important information about heritage and evolutionary trends in craniofacial morphology. In addition, measurements such as crown height serve as essential baseline data for studies of dental pathology. The measurement techniques recommended here follow Mayhall (1992) and Moorees (1957).

Dimensions should be recorded for all teeth from the left side of the arcade. The antimere may be substituted when the left tooth is not observable. Measurements should be determined using a dial or digital caliper accurate to .01 mm. Accuracy is enhanced when caliper blades are ground to form sharp points.

When possible, three measurements should be taken: mesiodistal diameter (crown length), buccolingual or faciolingual diameter (crown width), and crown height. Mesial refers to the anterior aspect of any tooth, with the point between the two central incisors being the most anterior within the dental arcade. Distal refers to the

mesiodistal diameter
buccolingual / faciolingual
crown height

point most distant from the midline. Buccal refers to the tooth surface next to the cheek, while lingual refers to the aspect nearest the tongue. In all examples, these terms refer to teeth in proper anatomical position, not teeth that are subject to rotation or crowding.

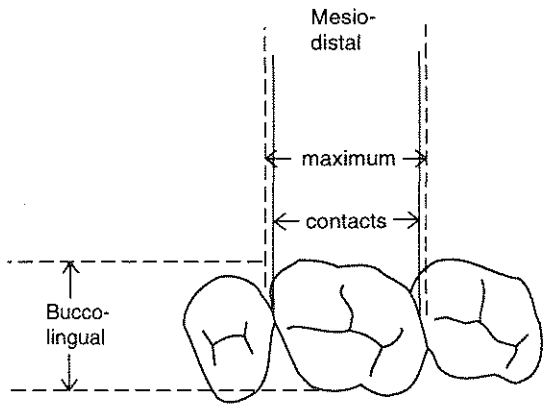

Figure 31. Measurement of mesiodistal and buccolingual (faciolingual) diameters on posterior teeth. Two mesiodistal methods are illustrated (after Mayhall 1992, Figure 1).

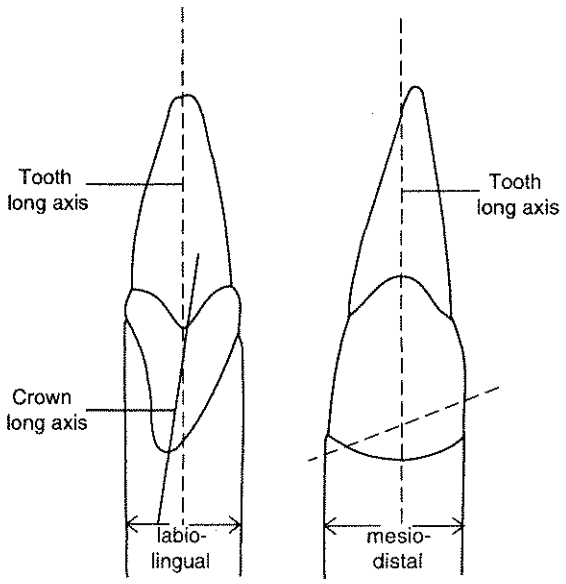

Figure 32. Measurement of mesiodistal and labiolingual (faciolingual) diameters on anterior teeth. Note that the long axis of the crown is not the same as the long axis of the tooth (after Mayhall 1992, Figure 2).

Mesiodistal diameters are most commonly taken in two ways: 1) between interproximal contact points (or areas) parallel to the occlusal surface, or 2) as the maximum width of the tooth crown in the mesiodistal plane. Both measurements are indicated in Figure 31 for the posterior dentition. The two definitions produce identical measurements in anterior teeth (see Figure 31). While either method can be used, we recommend the second technique because the first is limited to teeth showing minimal interproximal wear and is ambiguous under conditions of malocclusion. Given that many North American archaeological samples show evidence of severe dental wear by early adulthood, the second method holds greater potential for data capture. Measurements should not be recorded for dimensions likely to be affected by dental wear or pathology. The recorder should report which of the two techniques for mesiodistal measurement was used.

Buccolingual (faciolingual) diameters are defined as the widest diameter of the tooth, measured perpendicular to the mesiodistal plane. As illustrated in Figure 32, care must be taken in the anterior dentition to ensure that the axis of measurement is truly parallel to the long axis of the tooth, not the crown. On molars this is usually about half the distance between the cemento-enamel junction (CEJ) and the occlusal surface.

Crown height is measured from the occlusal surface to the CEJ on incisors, canines, and premolars (Figure 33b). In molars, by convention, crown height is defined as the distance between the tip of the mesiobuccal cusp to the CEJ, measured along a line parallel to the long axis of the tooth (Figure 33a).

A form suitable for recording dental measurements is presented as Attachment 20. Teeth from the left side of both the upper and lower arcades should be recorded, with antimeres substituted in the case of missing data. Estimated measurements should be indicated by an asterisk.

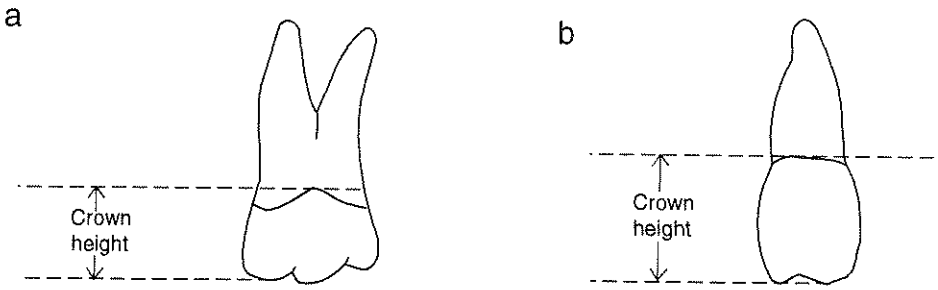

Figure 33. Measurement of crown height: a) Posterior teeth; b) Anterior teeth (after Rogers 1984, Figure 27).

Dental Morphology

Beginning with Hrdlicka's (1920) classic work on incisor shoveling, physical anthropologists have sought to systematically describe variations in dental morphology. To facilitate the development of accurate, replicable standards, graded cast series were developed by Dahlberg (1956) for the permanent dentition and by Hanihara (1961) for deciduous teeth. More recently Turner and colleagues (1991) have created a set of standards illustrated in cast series for an expanded list of dental features. The primary set of observations recommended for recording is a subset of the Turner et al. (1991) list and includes their recommended gradations. If time permits, observers should include the full Turner—Arizona State University Dental Anthropology Laboratory (ASU) listing. The goal of the ASU system is to present replicable, graded distinctions by defining a set of variants which are commonly observed within archaeological samples, have low sexual dimorphism, and are readily observable. The subset presented in this chapter focuses upon variation observed in incisors and and molars, since we believe that these teeth are most easily recognized when removed from alveoli — as is the case in many archaeologically derived museum collections. We have also selected traits that minimize intra- and inter-observer error (Nichol and Turner 1986).

Whether observers are planning to proceed with the primary list described here or to follow the more extensive observational sequence of Turner et al. (1991), we urge acquisition of the ASU series of dental casts which provide a three-dimensional reference for the grades of expression discussed below. The casts serve as standard reference plaques and are of immense utility in either scoring regime. The cast series can be obtained at cost from:

Dr. Christy G. Turner II
Department of Anthropology
Arizona State University
Tempe, AZ 85287-2402

The following discussion includes the name of the trait, the teeth to be observed, a definition or locational comment, the name(s) of the developers, key references, identification of the reference plaque (if any), scoring categories, and additional comments. This information is reprinted from Turner et al. (1991).[1] A sample recording form for dental morphology appears as Attachment 20.

[1]Our appreciation is expressed to Wiley-Liss for permission to reprint sections of Turner et al. (1991).

WINGING

UPPER CENTRAL INCISORS Rotation of the upper central incisors was initially discussed by Enoki and Dahlberg (1958), with the followed procedures modified by Turner (1970). No reference plaque. Scoring is as follows:

1. Bilateral Winging: Central incisors are rotated mesiolingually, giving a V-shaped appearance when viewed from the occlusal surface. When the angle formed is greater than 20 degrees, it is classed as 1A; when less than 20 degrees, 1B.
2. Unilateral Winging: Only one of the incisors is rotated.
3. Straight: Both teeth form a straight labial surface or follow the curvature of the dental arcade.
4. Counter Winging: One or both teeth are rotated distolingually.

SHOVELING

UPPER INCISORS Scaling of lingual marginal ridges was first proposed by Hrdlicka (1920), a plaque was developed by Dahlberg (1956), and an expanded classification system developed by Scott (1973). Plaques: ASU Shovel UI1; Shovel UI2. Scoring:

0. None: Lingual surface is essentially flat.
1. Faint: Very slight elevations of mesial and distal aspects of lingual surface can be seen and palpated.
2. Trace: Elevations are easily seen.
3. Semishovel: Stronger ridging is present and there is a tendency for ridge convergence at the cingulum.
4. Semishovel: Convergence and ridging are stronger than in grade 3.
5. Shovel: Strong development of ridges, which almost are in contact at the cingulum.
6. Marked Shovel: Strongest development. Mesial and distal lingual ridges are sometimes in contact at the cingulum.
7. Barrel (UI2 only): Expression exceeds grade 6.

DOUBLE SHOVELING

UPPER INCISORS The presence of labial marginal ridges as a standard reference was developed by Dahlberg (1956) and modified by Turner and Laidler-Dowda in 1979. Reference plaque: ASU UI1 double shovel. Scoring:

0. None: Labial surface is smooth.
1. Faint: Mesial and distal ridging can be seen in strong contrasting light. Distal ridge may be absent in this and stronger grades.
2. Trace: Ridging is more easily seen and palpated.
3. Semi-Double Shovel: Ridging can be readily palpated.
4. Double Shovel: Ridging is pronounced on at least one-half of the total crown height.
5. Pronounced Double Shovel: Ridging is very prominent and may occur from the occlusal surface to the CEJ.
6. Extreme Double Shovel: Very pronounced ridging.

PEG-SHAPED INCISORS

UPPER LATERAL INCISOR Defined by various workers as a tooth which is very reduced in size and lacking normal crown morphology, being peg shaped instead. No reference plaque. Scoring:

0. Normal-sized incisor.
1. Incisor reduced in size, but having normal crown form.
2. Peg-shaped incisor as defined above.

UPPER PREMOLAR ROOT NUMBER

UPPER FIRST PREMOLAR The upper premolars are usually single rooted. When two roots are present there is normally a buccal and a lingual root. Three roots result from the bifurcation of the buccal root. When multiple roots occur, they are usually on the first premolar. Procedure defined by Turner (1967, 1981). No reference plaque. Root number can often be scored when teeth are missing by simply counting the number of complete sockets. Scoring:

1. One root. Tip may be bifid for less than 1/3 of its length.
2. Two roots. Separate roots must be greater than one-quarter to one-third of the total root length.
3. Three roots. Length defined as in grade 2.

HYPOCONE

UPPER MOLARS Distolingual cusp or cusp 4. Absence and severely reduced forms of this cusp are more common on M1 and M2 than the same forms of the metacone. Plaque developed by Larson (1978) and modified by Turner and Scott in 1975. Reference plaque: ASU UM hypocone. Scoring:

0. No hypocone. Site is smooth.
1. Faint ridging present.
2. Faint cuspule present.
3. Small cusp present
3.5 Moderate-sized cusp present.
4. Large cusp present.
5. Very large cusp present.

CUSP 5 (METACONULE)

UPPER MOLARS A fifth cusp, the metaconule, may occasionally be present in the distal fovea of the upper molars between the metacone and hypocone. This trait has been discussed and scaled by Harris (1977) and Harris and Bailit (1980). Plaque developed by Turner and Warner in 1977. Reference plaque: ASU UM cusp 5. Scoring:

0. Site of cusp 5 is smooth, with only a single distal groove separating cusps 3 and 4.
1. Faint cuspule present.
2. Trace cuspule present.
3. Small cuspule present
4. Small cusp present.
5. Medium-sized cusp present.

CARABELLI'S TRAIT

UPPER MOLARS Occurs on the lingual surface of the mesiolingual cusp (cusp 1). Plaque developed by Dahlberg (1956). Reference Plaque: Zoller Lab UM Carabelli cusp. Scoring:

0. Mesiolingual aspect of cusp 1 is smooth.
1. Groove present.
2. Pit present.
3. A small Y-shaped depression is present.
4. A large Y-shaped depression is present.
5. A small cusp without a free apex occurs. The distal border of the cusp does not contact the lingual groove separating cusps 1 and 4.
6. A medium-sized cusp with an attached apex making contact with the medial lingual groove is present.
7. A large free cusp is present.

ENAMEL EXTENSIONS

UPPER MOLARS Projections of the enamel border in an apical direction. First scored and classified by Pedersen (1949), with minor modification here. No reference plaque. Scoring:

0. Enamel border is straight, or, rarely, curved toward the crown. Score any extension *not* attached to the crown as absent.
1. A faint, approximately 1.0 mm long extension projecting toward and along the root.
2. A medium-sized, approximately 2.0 mm long extension.
3. A lengthy extension, generally >4.0 mm in length. It may extend all the way to the root bifurcation.

LOWER PREMOLAR ROOT NUMBER (TOMES' ROOT)

LOWER FIRST PREMOLAR Tomes (1923) was the first to draw attention to this condition, which is defined as the presence of deeply grooved mesial roots. As is now known, this anomaly is part of a morphogenetic continuum from a single to a double-rooted tooth. Standardized variation scale developed by Turner and Stephen Herzog in 1979. Reference plaque: ASU LP1 Root Form. Tomes' (1923) original observation would be equivalent to grades 3 and 4 of this classification. Scoring:

0. Developmental grooving is absent or, if present, shallow with rounded rather than V-shaped indentation.
1. Developmental groove is present and has a shallow V-shaped cross-section.
2. Developmental groove is present and has a moderately deep V-shaped cross-section.
3. Developmental groove is present, V shaped, and deep.
4. Developmental grooving is deeply invaginated on both the mesial and distal borders.
5. Two free roots are present. They are separate for at least one-quarter to one-third of the total root length.

GROOVE PATTERN

LOWER MOLARS Well defined studies of the molar groove pattern began with Gregory (1916), were expanded by Hellman (1928), and culminate in the three class system developed by Jorgensen (1955). No reference plaque. Determinations should be aided by use of a 10x hand lens. Scoring:

Y. Cusps 2 and 3 are in contact.
+. Cusps 1, 2, 3, and 4 are in contact.
X. Cusps 1 and 4 are in contact.

CUSP NUMBER

LOWER MOLARS The pioneering work on molar cusp number was by Gregory (1916), only slightly modified here. No reference plaque. Scoring:

4. Cusps 1 (protoconid); 2 (metaconid); 3 (hypoconid); and 4 (entoconid) are present.
5. Cusp 5 (hypoconulid) is also present.
6. Cusp 6 (entoconulid) is also present.

PROTOSTYLID

LOWER MOLARS A paramolar cusp found on the buccal surface of cusp 1. Standard developed by Dahlberg (1956). Reference plaque: Zoller Lab LM protostylid. Scoring:

0. No expression of any sort. Buccal surface is smooth.
1. A pit occurs in the buccal groove.
2. Buccal groove is curved distally.
3. A faint secondary groove extends mesially from the buccal groove.
4. Secondary groove is slightly more pronounced.
5. Secondary groove is stronger and can easily be seen.
6. Secondary groove extends across most of the buccal surface of cusp 1. This is considered a weak or small cusp.
7. A cusp with a free apex occurs.

CUSP 5

LOWER MOLARS Cusp 5 or the hypoconulid occurs on the distal occlusal aspect of the lower molars. It should be recorded only in the absence of Cusp 6 (see below). Standard developed by Turner and Warner in 1977. Reference plaque: ASU LM cusp 5. Scoring:

0. Absence. Molar has only 4 cusps.
1. Cusp 5 is present and very small.
2. Cusp 5 is small.
3. Cusp 5 is medium sized.
4. Cusp 5 is large.
5. Cusp 5 is very large.

CUSP 6

LOWER MOLARS Cusp 6, the entoconulid or tuberculum sextum, occurs in the distal fovea of the lower molars lingual to cusp 5. It is scored by size relative to cusp 5. Standard developed by Turner (1970). Reference plaque ASU LM cusp 6. Scoring:

0. Cusp 6 is absent.
1. Cusp 6 is much smaller than cusp 5.
2. Cusp 6 is smaller than cusp 5.
3. Cusp 6 is equal in size to cusp 5.
4. Cusp 6 is larger than cusp 5.
5. Cusp 6 is much larger than cusp 5.

CUSP 7

LOWER MOLARS Cusp 7, the metaconulid or tuberculum intermedium, occurs in the lingual groove between cusps 2 and 4. Standard developed by Turner (1970). Reference plaque: ASU LM cusp 7. Scoring:

0. No occurrence of cusp 7.
1. Faint cusp is present. Two weak lingual grooves are present instead of one.
1A. A faint tipless cusp 7 occurs displaced as a bulge on the lingual surface of cusp 2.
2. Cusp 7 is small.
3. Cusp 7 is medium sized.
4. Cusp 7 is large.

LOWER MOLAR ROOT NUMBER

LOWER MOLARS 1-3 Roots, as standardized by Turner (1967). No reference plaque.

One Root: root tip may be bifurcated. If tips are free for more than one-fourth to one-third of the total root length, score as two roots.

Two Roots: Two separate roots exist for at least one-fourth to one-third the total root length.

Three Roots: A third (supernumerary) root is present on the distolingual aspect.

UT Databank
UT Fordisc
Manual

CHAPTER 7

MEASUREMENT OF ADULT REMAINS

Measurement has been an important part of skeletal biology since the earliest osteological analyses (Blumenbach 1776, 1786; Morton 1839). Cranial and postcranial measurements have typically been used to describe individuals and to compare groups. Before 1960, comparisons were usually based on single measurements evaluated independently or on indices that combined two dimensions as an indicator of shape. The recent availability of computers has facilitated the use of multivariate statistics and encouraged the development of increasingly sophisticated research designs.

Population variation in skeletal morphology is the result of genetic and environmental differences among groups. Since heritability studies have demonstrated that genes greatly influence cranial shape, it is generally assumed that groups with similar craniofacial morphology are more closely related than groups that display greater differences in cranial form. A number of studies have examined patterns of cranial variation at worldwide, regional, ethnic, or intragroup levels (e.g., Corrucini 1972; Droessler 1981; Heathcote 1986; Howells 1973, 1989; Jantz 1974; Jantz et al. 1978; Key 1983; Key and Jantz 1981, 1990; Owsley et al. 1981, 1982; Pietrusewsky 1990; Rightmire 1970; Rothhammer and Silva 1990; Sciulli 1990). Microevolutionary processes, such as natural selection and gene flow, are reflected in these data, as are differences attributable to secular change (Jantz 1973; Jantz and Moore-Jansen 1988).

Multivariate analyses using statistical procedures such as Mahalanobis's D^2, discriminant functions, and canonical analyses are now commonly employed to evaluate temporal and geographical variation in skeletal morphology. Craniometric data have been used to address questions of taxonomy, functional morphology, and cultural-historical relationships. Identification of ancestry is important both in forensic contexts (Gill and Rhine 1990), and in bioarchaeological research on skeletal remains from historic sites (Jantz and Owsley 1994). Accurate identification of tribal affiliation is a major requirement in the repatriation process.

Although the skull has been the focus of most quantitative studies, postcranial measurements represent another important source of information. Genes influence postcranial dimensions, as do age, sex, behavior, and nutrition. Dimensions of long bones have, for example, proved useful in estimates of stature, age, sex, and even activity patterns (DiBennardo and Taylor 1983; Bridges 1985; Frayer 1980; Ruff et al. 1984; Krogman and Iscan 1986; Iscan and Cotton 1990; Trotter and Gleser 1958; Ubelaker 1989a; Van Gerven 1972a, 1972b; Zobeck 1983).

In this chapter, we present two lists of measurements. The first set is the minimum standard required for documentation of all collections, which was developed initially as part of the National Forensic Data Base (Moore-Jansen et al. 1994). This set of measurements was selected because it includes dimensions commonly used by osteologists to define genetic, sex, and age differences in both recent and ancient human groups. Data collected through use of these standards should therefore be useful to skeletal biologists, bioarchaeologists, and forensic anthropologists.

Measurement landmarks, techniques, and instrumentation appropriate for the 24 cranial, 10 mandibular, and 44 postcranial measurements that comprise this primary data set are illustrated in Figures 34-57. A data collection recording form appropriate for the primary list is included as Attachment 21. Definitions of

landmarks, measurement techniques, and instrumentation are based on Martin [1957, as translated in Moore-Jansen et al. 1994], with additional notes on landmarks from Bass (1987) and White and Folkens (1991). Further details concerning osteometry can be found in Bass (1987); Hrdlicka (1952); Montagu (1960); Olivier (1969), and White and Folkens (1991).

Basic instruments generally available in most skeletal biology laboratories can be used to take these measurements: spreading and sliding calipers, a mandibulometer, metal tape, and an osteometric board. If available, a craniophore should be used to establish the Frankfort horizontal plane which serves as a reference for Measurement 24: Mastoid Length. All measurements should be recorded to the nearest millimeter and taken on the left side in the case of bilateral measurements. The right side may be substituted if the left is not measurable, with an "R" placed in parentheses next to the measurement. If bones are fragmented or distorted, measurements should not be taken. Dimensions should, however, be estimated in situations of minor erosion or reconstruction and identified by an asterisk "*" on the recording form.

A second, supplemental list of postcranial measurements is also presented here, recommended for those whose resources permit such full documentation. This list appears in Table 3, along with references which provide details concerning landmarks and measurement methods.

Several additional, less commonly used measurements have proven useful for specific research problems, e.g., Gill (1984); Howells (1973); Key and Jantz (1981). Observers are therefore encouraged to become familiar with previous osteometric studies that would form a suitable comparative database for their study sample. Measurements reported in such works should be added to the primary list presented here. When such measurements are added, it is important that landmarks be defined precisely and that full documentation be included in final reports.

Recommendations for determinations of intra- and inter-observer error appear in Appendix II.

Table 3
Supplemental List of Postcranial Measurements

Measurement	Code	Source
1. Scapula: spine length	(SLS)	Bass 1987: 117, #3
2. Scapula: supraspinous length	(SSL)	Bass 1987: 117, #4
3. Scapula: infraspinous length	(ISL)	Bass 1987: 118, #5
4. Scapula: glenoid cavity breadth	(GCB)	Zobeck 1983: 133, #39
5. Scapula: glenoid cavity height	(GCH)	Zobeck 1983: 133, #40
6. Scapula: glenoid to inferior angle	(GIL)	Zobeck 1983: 133, #41
7. Sternum: manubrium length	(MML)	Bass 1987: 112, Fig. 64
8. Sternum: body (mesosternum) length	(MSL)	Bass 1987: 112, Fig. 64
9. Sternum: sternebra 1 width	(S1W)	Bass 1987: 112, Fig. 64
10. Sternum: sternebra 3 width	(S3W)	Bass 1987: 112, Fig. 64
11. Humerus: proximal epiphysis breadth	(BUE)	Zobeck 1983: 129, #2
12. Humerus: least circumference shaft	(LCS)	Bass 1987: 148, #5
13. Radius: maximum head diameter	(RDH)	Zobeck 1983: 131, #17
14. Radius: neck circumference	(MCS)	Zobeck 1983: 133, #46
15. Ulna: maximum breadth olecranon	(BOP)	Zobeck 1983: 131, #18
16. Ulna: minimum breadth olecranon	(MBO)	Zobeck 1983: 131, #19
17. Ulna: maximum width olecranon	(WOP)	Zobeck 1983: 131, #20
18. Ulna: olecranon-radial notch	(ORL)	Zobeck 1983: 131, #21
19. Ulna: olecranon-coronoid length	(OCL)	Zobeck 1983: 131, #22
20. Femur: trochanteric length	(FTL)	Zobeck 1983: 130, #7
21. Femur: a-p diameter lateral condyle	(APL)	Zobeck 1983: 132, #29
22. Femur: a-p diameter medial condyle	(APM)	Zobeck 1983: 132, #30
23. Femur: bicondylar breadth	(BCB)	Zobeck 1983: 133, #44
24. Femur: minimum vertical diameter neck	(VDN)	Zobeck 1983: 133, #48
25. Tibia: position of nutrient foramen	(CFL)	Zobeck 1983: 132, #33

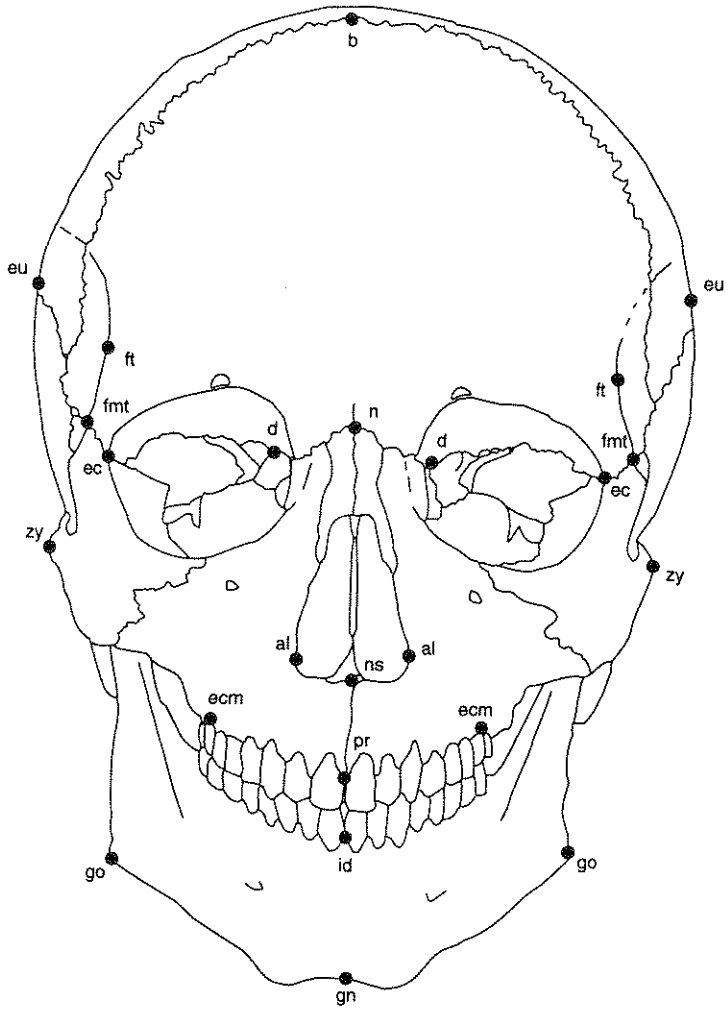

ALARE **(al)**: Instrumentally determined as the most lateral points on the nasal aperture in a transverse plane. (Paired)

BREGMA **(b)**: The ectocranial midline point where the coronal and sagittal sutures intersect.

DACRYON **(d)**: The point on the medial border of the orbit at which the frontal, lacrimal, and maxilla intersect: dacryon lies at the intersection of the lacrimo-maxillary suture and the frontal bone. There is often a small foramen at this point. (Paired)

ECTOCONCHION **(ec)**: The intersection of the most anterior surface of the lateral border of the orbit and a line bisecting the orbit along its long axis. To mark ectoconchion, move a toothpick or other thin straight instrument up and down, keeping it parallel to the superior orbital border, until you divide the eye orbit into two equal halves. Mark the point on the anterior margin with a pencil. (Paired)

EURYON **(eu)**: Instrumentally determined ectocranial points on opposite sides of the skull that form the termini of the line of greatest cranial breadth. (Paired)

FRONTOMALARE TEMPORALE **(fmt)**: The most laterally positioned point on the fronto-malar (fronto-zygomatic) suture. (Paired)

FRONTOTEMPORALE **(ft)**: The point where the temporal line reaches its most anteromedial position on the frontal. (Paired)

GNATHION **(gn)**: The most inferior midline point on the mandible.

GONION **(go)**: A point along the rounded posteroinferior corner of the mandible between the ramus and the body. To determine the point, imagine extending the posterior ramus border and the inferior corpus border to form an obtuse angle. The line bisecting this angle meets the curved gonial edge at gonion. (Paired)

INFRADENTALE **(id)**: The midline point at the superior tip of the septum between the mandibular central incisors.

NASION **(n)**: The point of intersection between the frontonasal suture and the midsagittal plane.

NASOSPINALE **(ns)**: The point where a line drawn between the inferiormost points of the nasal (piriform) aperture crosses the midsagittal plane. Note that this point is not necessarily located at the tip of the nasal spine.

PROSTHION **(pr)**: The most anterior point in the midline on the alveolar processes of the maxillae.

ZYGION **(zy)**: Instrumentally determined as the most lateral point on the zygomatic arch. (Paired)

Figure 34. Anatomical landmarks of the skull, anterior view (after Moore-Jansen et al. 1994).

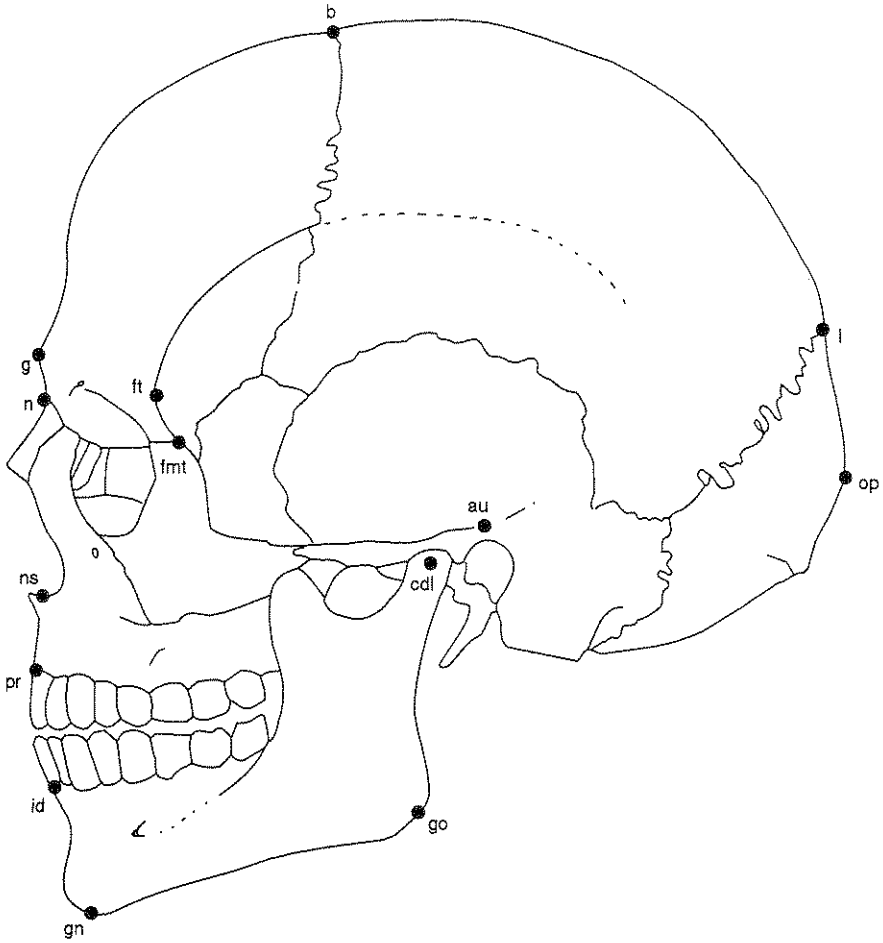

AURICULARE **(au)**: Not a standard landmark as defined here. Instead it is defined as a point on the lateral aspect of the root of the zygomatic process at the deepest incurvature, wherever it may be. (Paired)

BREGMA **(b)**: The ectocranial midline point where the coronal and sagittal sutures intersect.

CONDYLION LATERALE **(cdl)**: The most lateral point on the mandibular condyle. (Paired)

FRONTOMALARE TEMPORALE **(fmt)**: The most laterally positioned point on the fronto-malar (fronto-zygomatic) suture. (Paired)

FRONTOTEMPORALE **(ft)**: The point where the temporal line reaches its most anteromedial position on the frontal. (Paired)

GLABELLA **(g)**: The most anterior midline point on the frontal bone, usually above the frontonasal suture.

GNATHION **(gn)**: The most inferior midline point on the mandible.

GONION **(go)**: A point along the rounded posteroinferior corner of the mandible between the ramus and the body. To determine the point, imagine extending the posterior ramus border and the inferior corpus border to form an obtuse angle. The line bisecting this angle meets the curved gonial edge at gonion. (Paired)

INFRADENTALE **(id)**: The midline point at the superior tip of the septum between the mandibular central incisors.

LAMBDA **(l)**: The ectocranial midline point where the sagittal and lambdoidal sutures intersect. If location of this point is rendered difficult by the presence of wormian bones, locate the point where projections of the sagittal and lambdoid sutures would meet.

NASION **(n)**: The point of intersection between the frontonasal suture and the midsagittal plane.

NASOSPINALE **(ns)**: The point where a line drawn between the inferiormost points of the nasal (piriform) aperture crosses the midsagittal plane. Note that this point is not necessarily located at the tip of the nasal spine.

OPISTHOCRANION **(op)**: Instrumentally determined most posterior point of the skull not on the external occipital protuberance.

PROSTHION **(pr)**: The most anterior point in the midline on the alveolar processes of the maxillae.

Figure 35. Anatomical landmarks of the skull, lateral view (after Moore-Jansen et al. 1994).

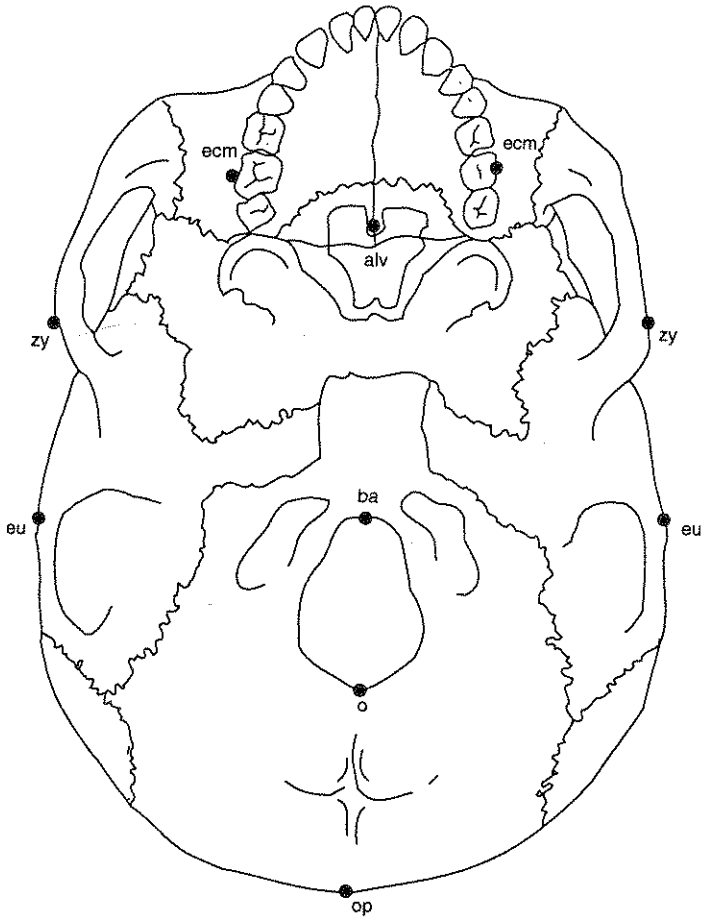

ALVEOLON **(alv)**: The point on the hard palate where a line drawn through the most posterior points of the alveolar ridges crosses the midline.

BASION **(ba)**: The midline point on the anterior margin of the foramen magnum. For cranial height measurements, the point is placed on the anteroinferior portion of the foramen's rim. For basinasal and basiprosthion measurements, the point is located on the most posterior point on the foramen's anterior rim and is sometimes distinguished as endobasion.

ECTOMOLARE **(ecm)**: The most lateral point on the outer surface of the alveolar borders of the maxilla, often opposite the middle of the second molar tooth. (Paired)

EURYON **(eu)**: Instrumentally determined ectocranial points on opposite sides of the skull that form the termini of the line of greatest cranial breadth. (Paired)

OPISTHION **(o)**: The midline point at the posterior margin of the foramen magnum.

OPISTHOCRANION **(op)**: Instrumentally determined most posterior point of the skull not on the external occipital protuberance.

ZYGION **(zy)**: Instrumentally determined as the most lateral point on the zygomatic arch. (Paired)

Figure 36. Anatomical landmarks of the skull, basilar view

DEFINITIONS OF CRANIAL AND POSTCRANIAL MEASUREMENTS

1. ***Maximum Cranial Length (g-op):*** distance between glabella (g) and opisthocranion (op) in the midsagittal plane, measured in a straight line. *Instrument:* spreading caliper. *Comment:* Place skull on side, holding one end of caliper at glabella and extending caliper until maximum diameter at posterior aspect of skull is obtained (Figure 37).

2. ***Maximum Cranial Breadth (eu-eu):*** maximum width of skull perpendicular to midsagittal plane wherever it is located, with the exception of the inferior temporal lines and the area immediately surrounding them. *Instrument:* spreading caliper (Figure 38).

3. ***Bizygomatic Diameter (zy-zy):*** direct distance between most lateral points on the zygomatic arches (zy-zy). *Instrument:* spreading or sliding caliper. (Figure 38).

4. ***Basion-Bregma Height (ba-b):*** direct distance from the lowest point on the anterior margin of foramen magnum (ba), to bregma (b). *Instrument:* spreading caliper (Figure 37).

5. ***Cranial Base Length (ba-n):*** direct distance from nasion (n) to basion (ba). *Instrument:* spreading caliper (Figure 37).

6. ***Basion-Prosthion Length (ba-pr):*** direct distance from basion (ba) to prosthion (pr). *Instrument:* spreading or sliding caliper (Figure 37).

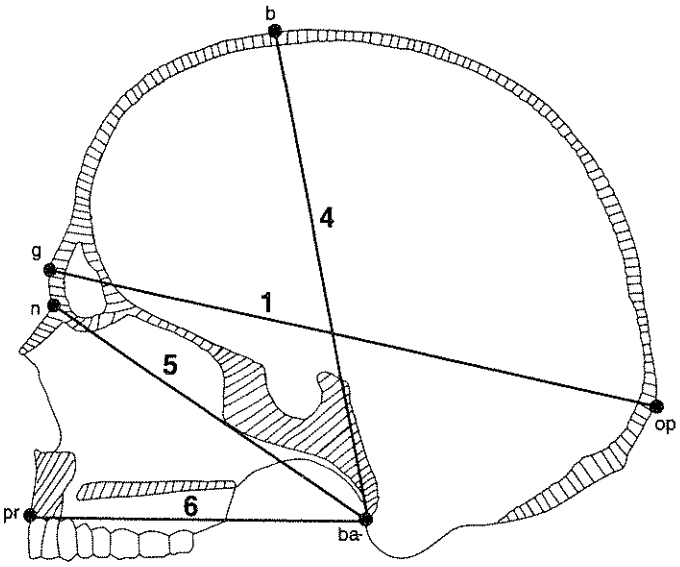

Figure 37. Cranial measurements in the sagittal plane (after Moore-Jansen et al. 1994).

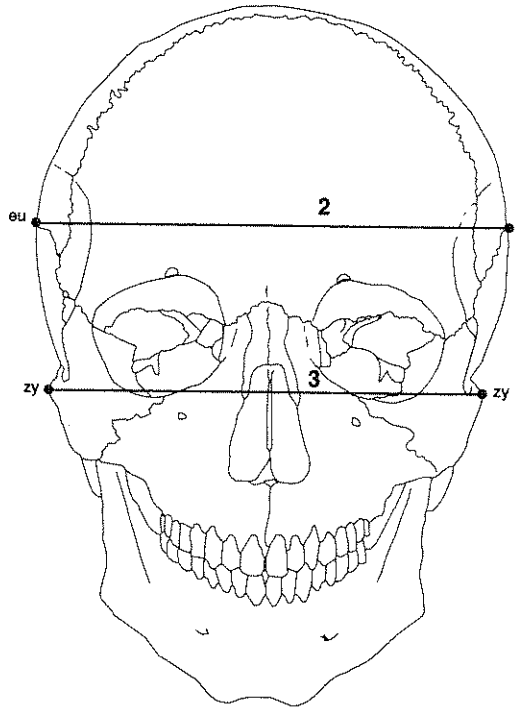

Figure 38. Maximum cranial breadth and bizygomatic diameter (after Moore-Jansen et al. 1994).

7. ***Maxillo-Alveolar Breadth (ecm-ecm):*** maximum breadth across the alveolar borders of the maxilla measured on the lateral surfaces at the location of the second maxillary molars (ecm). *Instrument:* spreading caliper. *Comment:* The points of measurement (ecm) are customarily *not* found on the alveolar processes, but are located on the bony segment above the second maxillary molars (Figure 39).

8. ***Maxillo-Alveolar Length (pr-alv):*** direct distance from prosthion (pr) to alveolon (alv). *Instrument:* spreading or sliding caliper. *Comment:* Sliding caliper applicable only if incisor teeth have been lost. Position skull with basilar portion facing up. Apply a thin wire, wooden rod, rubber band, or other similar device to the posterior borders of the alveolar arch and measure the distance from prosthion to the middle of the wire/band (on midsagittal plane) (Figure 39).

9. ***Biauricular Breadth (au-au):*** least exterior breadth across the roots of the zygomatic processes (au), wherever found. *Instrument:* sliding caliper. *Comment:* With the skull resting on the occiput and with the base toward the observer, measure to the outside of the roots of the zygomatic processes at their deepest incurvature, generally slightly anterior to the external auditory meatus, with the sharp points of the caliper. This measurement makes no reference to standard landmarks of the ear region (Figure 39).

10. ***Upper Facial Height (n-pr):*** direct distance from nasion (n) to prosthion (pr). *Instrument:* sliding caliper. *Comment:* This measurement may be estimated under conditions of minor alveolar resorption. It should not be taken if resorption is great (Figure 40).

11. ***Minimum Frontal Breadth (ft-ft):*** direct distance between the two frontotemporale (ft). *Instrument:* sliding caliper. (Figure 40).

12. ***Upper Facial Breadth (fmt-fmt):*** direct distance between the two external points on the frontomalar suture (fmt) *Instrument:* sliding caliper (Figure 40).

13. ***Nasal Height (n-ns):*** direct distance from nasion (n) to the midpoint of a line connecting the lowest points of the inferior margin of the nasal notches (ns). *Instrument:* sliding caliper (Figure 40).

14. ***Nasal Breadth (al-al):*** maximum breadth of the nasal aperture (al-al). *Instrument:* sliding caliper. *Comment:* Be certain measurement is perpendicular to the midsagittal plane (Figure 40).

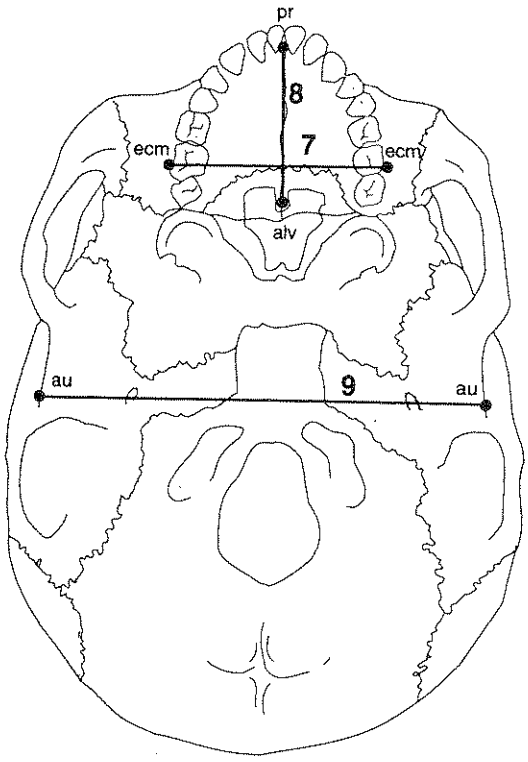

Figure 39. Cranial measurements, basilar view (after Moore-Jansen et al. 1994).

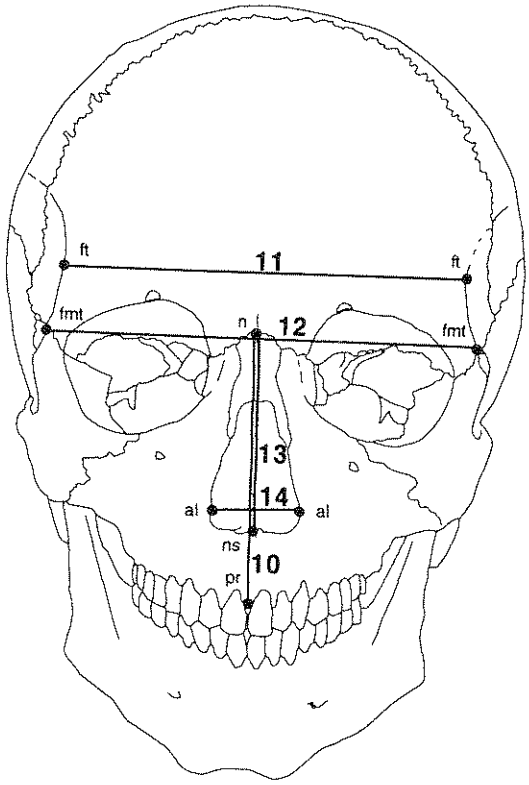

Figure 40. Cranial measurements, anterior view (after Moore-Jansen et al. 1994).

15. ***Orbital Breadth (d-ec):*** laterally sloping distance from dacryon (d) to ectoconchion (ec). *Instrument:* sliding caliper. *Comment:* for standardization and practical reasons, measure the left orbit. Measure the right orbit if the left is damaged, and record the side measured on the recording form (Figure 41).

16. ***Orbital Height:*** direct distance between the superior and inferior orbital margins. *Instrument:* sliding caliper. *Comment:* measurement is taken perpendicular to orbital breadth and similarly bisects the orbit. Avoid notches on either orbital border (Figure 41).

17. ***Biorbital Breadth (ec-ec):*** direct distance between right and left ectoconchion (ec). *Instrument:* sliding caliper. *Comment:* This measurement may be difficult if the anterior lateral orbital margins are sharp (Figure 41).

18. ***Interorbital Breadth (d-d):*** direct distance between right and left dacryon (d). *Instrument:* sliding caliper. (Figure 41).

19. ***Frontal Chord (n-b):*** direct distance from nasion (n) to bregma (b) taken in the midsagittal plane. *Instrument:* sliding caliper (Figure 42).

20. ***Parietal Chord (b-l):*** direct distance from bregma (b) to lambda (l) taken in the midsagittal plane. *Instrument:* sliding caliper (Figure 42).

21. ***Occipital Chord (l-o):*** direct distance from lambda (l) to opisthion (o) taken in the midsagittal plane (Figure 42).

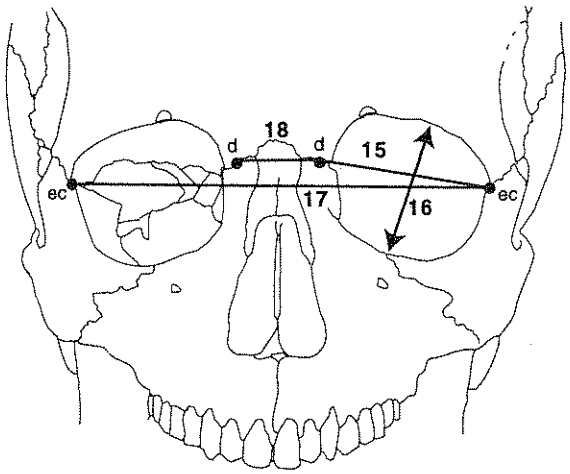

Figure 41. Measurements of the orbital region (after Moore-Jansen et al. 1994).

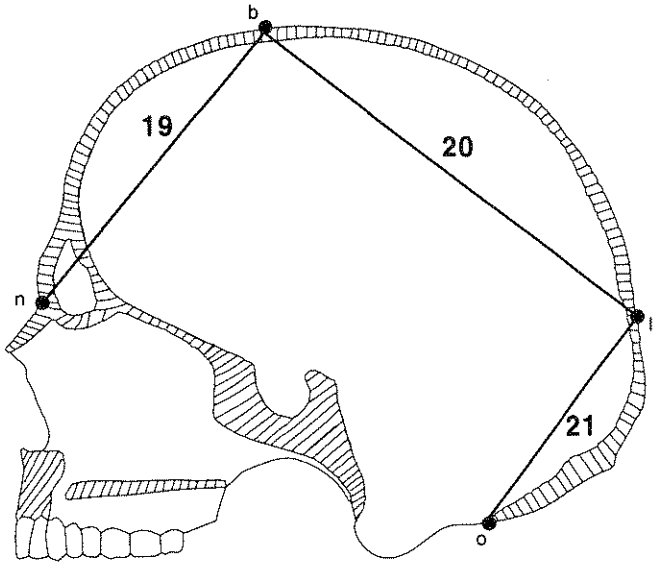

Figure 42. Frontal, parietal, and occipital chord measurements (after Moore-Jansen et al. 1994).

22. *Foramen Magnum Length (ba-o):* direct distance from basion (ba) to opisthion (o). *Instrument:* sliding caliper. *Comment:* tips of caliper should rest precisely on opposing edges of the border of foramen magnum. (Figure 43).

23. *Foramen Magnum Breadth:* distance between the lateral margins of foramen magnum at the points of greatest lateral curvature. *Instrument:* sliding caliper (Figure 43).

24. *Mastoid Length:* vertical projection of the mastoid process below and perpendicular to the eye-ear (Frankfort) plane. *Instrument:* sliding caliper (and craniophore). *Comment:* Rest skull on its right side and apply the calibrated bar of the caliper just behind the mastoid process, with the fixed flat arm tangent to the upper border of the external auditory meatus and pointing to the lower border of the orbit. Slide the measuring arm until it is level with the tip of the mastoid process. If craniophore is available, this should be used to establish the ear-eye (Frankfort) plane (Figure 44).

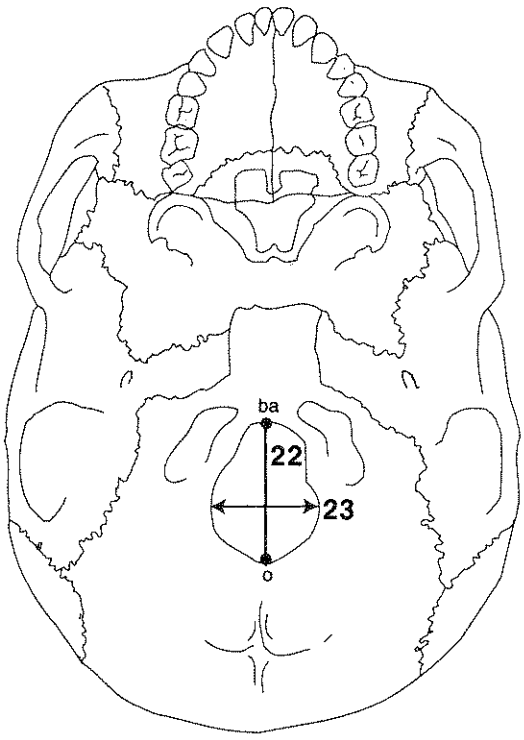

Figure 43. Foramen magnum length and breadth (after Moore-Jansen et al. 1994).

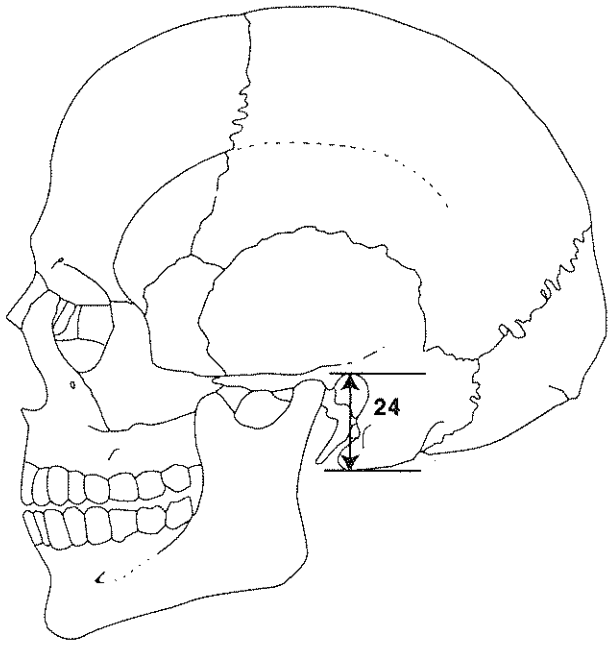

Figure 44. Mastoid length (after Moore-Jansen et al. 1994).

25. ***Chin Height (id-gn):*** direct distance from infradentale (id) to gnathion (gn). *Instrument:* sliding caliper. *Comment:* id may be estimated in slightly eroded specimens by reference to alveolus adjacent to lateral incisors. If alveolus is markedly eroded, specimen should not be measured (Figure 45).

26. ***Height of the Mandibular Body:*** direct distance from the alveolar process to the inferior border of the mandible perpendicular to the base at the level of the mental foramen. *Instrument:* sliding caliper (Figure 46).

27. ***Breadth of the Mandibular Body:*** maximum breadth measured in the region of the mental foramen perpendicular to the long axis of the mandibular body. *Instrument:* sliding caliper (Figure 45).

28. ***Bigonial Width (go-go):*** direct distance between right and left gonion (go). *Instrument:* sliding caliper. *Comment:* Place the blunt points of the caliper to the most prominent external points at the mandibular angles (Figure 45).

29. ***Bicondylar Breadth (cdl-cdl):*** direct distance between the most lateral points on the two condyles (cdl). *Instrument:* sliding caliper (Figure 45).

30. ***Minimum Ramus Breadth:*** least breadth of the mandibular ramus measured perpendicular to the height of the ramus. *Instrument:* sliding caliper (Figure 46).

31. ***Maximum Ramus Breadth:*** distance between the most anterior point on the mandibular ramus and a line connecting the most posterior point on the condyle and the angle of the jaw. *Instrument:* sliding caliper (Figure 46).

32. ***Maximum Ramus Height:*** direct distance from the highest point on the mandibular condyle to gonion (go). *Instrument:* sliding caliper or mandibulometer (Figure 46).

33. ***Mandibular Length:*** distance of the anterior margin of the chin from a center point on the projected straight line placed along the posterior border of the two mandibular angles. *Instrument:* mandibulometer. *Comment:* Apply movable board of the mandibulometer to the posterior borders of the mandibular rami and the fixed board against the most anterior point of the chin. Mandible may be stabilized by gently applying pressure (one or two fingers) to the left second molar (Figure 46).

34. ***Mandibular Angle:*** angle formed by the inferior border of the corpus and the posterior border of the ramus. *Instrument:* mandibulometer. *Comment:* Mandible may be stabilized by gently applying pressure (one or two fingers) to the left second molar (Figure 46).

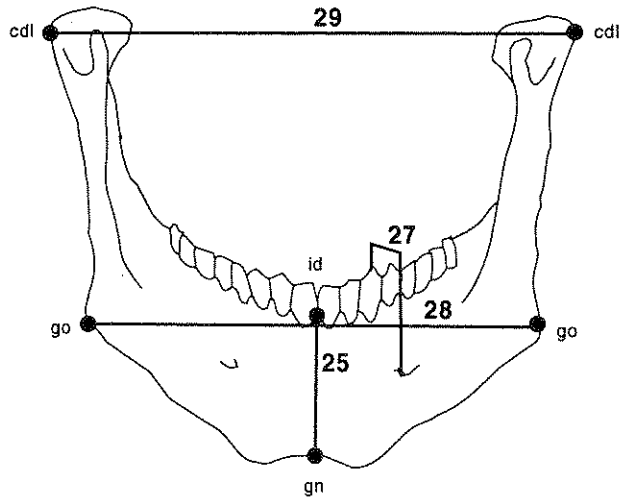

Figure 45. Measurements of the mandible, anterior view (after Moore-Jansen et al. 1994).

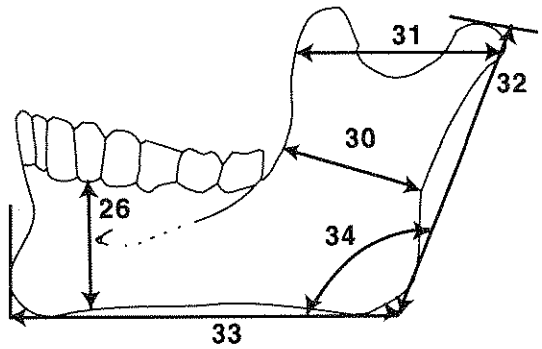

Figure 46. Measurements of the mandible, lateral view (after Moore-Jansen et al. 1994).

35. ***Clavicle: Maximum Length:*** maximum distance between the most extreme ends of the clavicle. *Instrument:* osteometric board (Figure 47).

36. ***Clavicle: Sagittal (Anterior-Posterior) Diameter at Midshaft:*** distance from the anterior to the posterior surface at midshaft. *Instrument:* sliding caliper. *Comment:* determine the midpoint of the diaphysis on the osteometric board and mark it with a pencil. Then determine sagittal diameter (Figure 47).

37. ***Clavicle: Vertical (Superior-Inferior) Diameter at Midshaft:*** distance from the superior to the inferior surface at midshaft. *Instrument:* sliding caliper. *Comment:* taken perpendicular to sagittal diameter (Figure 47).

38. ***Scapula: Height (Anatomical Breadth):*** direct distance from the most superior point of the cranial angle to the most inferior point on the caudal angle. *Instrument:* sliding caliper (Figure 48).

39. ***Scapula: Breadth (Anatomical Length):*** distance from the midpoint on the dorsal border of the glenoid fossa to midway between the two ridges of the scapular spine on the vertebral border. *Instrument:* spreading caliper. *Comment:* project a line through the obtuse angle of a triangle formed by the vertebral border and the two ridges of the spine, dividing it into two equal halves. The medial measuring point is located where this line intersects the vertebral border (Figure 48).

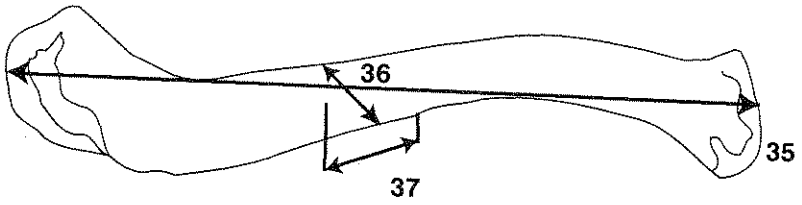

Figure 47. Measurements of the left clavicle, superior view (after Moore-Jansen et al. 1994).

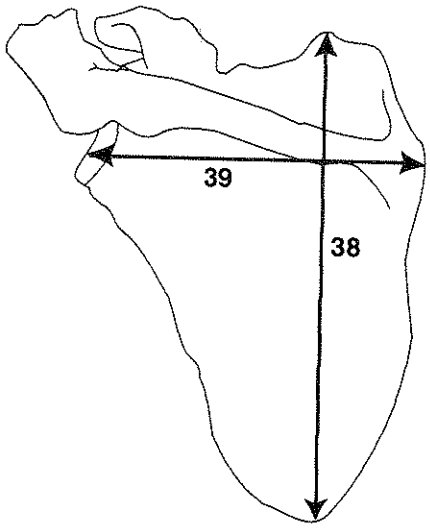

Figure 48. Measurements of the left scapula, dorsal view (after Moore-Jansen et al. 1994).

40. ***Humerus: Maximum Length:*** direct distance from the most superior point on the head of the humerus to the most inferior point on the trochlea. Humerus shaft should be positioned parallel to the long axis of the osteometric board. *Instrument:* osteometric board (Figure 49).

41. ***Humerus: Epicondylar Breadth:*** distance of the most laterally protruding point on the lateral epicondyle from the corresponding projection of the medial epicondyle. *Instrument:* osteometric board. *Comment:* Place the bone with its posterior surface resting on the osteometric board. Put the medial epicondyle against the vertical endboard and apply the movable upright to the lateral epicondyle (Figure 49).

42. ***Humerus: Vertical Diameter of Head:*** direct distance between the most superior and inferior points on the border of the articular surface. *Instrument:* sliding caliper (Figure 49).

43. ***Humerus: Maximum Diameter at Midshaft:*** maximum diameter at midshaft. *Instrument:* sliding caliper. *Comment:* determine the midpoint of the diaphysis on the osteometric board and mark with a pencil. Record maximum diameter wherever it occurs (Figure 49).

44. ***Humerus: Minimum Diameter at Midshaft:*** minimum diameter of midshaft. *Instrument:* sliding caliper. *Comment:* determine the midpoint of the diaphysis on the osteometric board and mark with a pencil. Record minimum diameter wherever it occurs (Figure 50).

45. ***Radius: Maximum Length:*** distance from the most proximally positioned point on the head of radius to the tip of the styloid process without regard for the long axis of the bone. *Instrument:* osteometric board (Figure 50).

46. ***Radius: Anterior-Posterior (Sagittal) Diameter at Midshaft :*** distance between anterior and posterior surfaces at midshaft. *Instrument:* sliding caliper. *Comment:* determine the midpoint of the diaphysis on the osteometric board and mark with a pencil. Measure sagittal diameter at that point. This measurement is almost always less than the medial-lateral diameter (Figure 50).

47. ***Radius: Medial-Lateral (Transverse) Diameter at Midshaft:*** distance between medial and lateral surfaces at midshaft. *Instrument:* sliding caliper. *Comment:* perpendicular to anterior-posterior diameter (Figure 50).

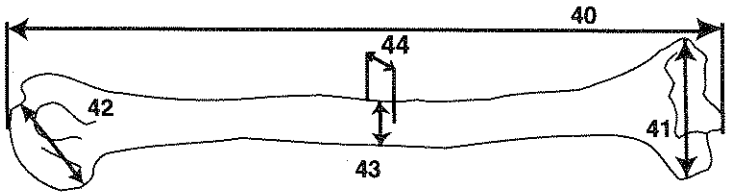

Figure 49. Measurements of the left humerus, anterior view (after Moore-Jansen et al. 1994).

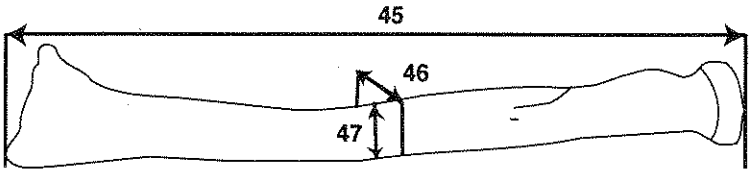

Figure 50. Measurements of the left radius, anterior view (after Moore-Jansen et al. 1994).

48. ***Ulna: Maximum Length:*** distance from the most superior point on the olecranon to the most inferior point on the styloid process. *Instrument:* osteometric board (Figure 51).

49. ***Ulna: Anterior-Posterior (Dorso-Volar) Diameter:*** maximum diameter of the diaphysis at the level of greatest crest development in anterior-posterior (dorso-volar) plane. *Instrument:* sliding caliper (Figure 51).

50. ***Ulna: Medial-Lateral (Transverse) Diameter:*** distance between medial and lateral surfaces at the level of greatest crest development. Instrument: sliding caliper. *Comment:* taken perpendicular to anterior-posterior diameter (Figure 51).

51. ***Ulna: Physiological Length:*** distance between the most distal (inferior) point on the surface of the coronoid process and the most distal point on the inferior surface of the distal head of the ulna. *Instrument:* spreading caliper. *Comment:* do not include the styloid process or the groove between the styloid process and the distal surface of the head. Be certain that the proximal point is at the deepest concavity of the coronoid process (Figure 51).

52. ***Ulna: Minimum Circumference:*** least circumference near the distal end of the bone. *Instrument:* metal tape (Figure 51).

53. ***Sacrum: Anterior Length:*** distance from a point on the promontory positioned in the midsagittal plane to a point on the anterior border of the tip of the sacrum measured in the midsagittal plane. *Instrument:* sliding caliper. *Comment:* place the pointed tips of the caliper on the promontory and the antero-inferior border of the fifth sacral vertebra. If a sacrum exhibits more than five segments, note this on the recording form, and then measure all true sacral units (Figure 52).

54. ***Sacrum: Anterior Superior Breadth:*** maximum transverse breadth of the sacrum at the level of the anterior projection of the auricular surface. *Instrument:* sliding caliper (Figure 52).

55. ***Sacrum: Maximum Transverse Diameter of Base:*** direct distance between the two most laterally projecting points on the sacral base measured perpendicular to the midsagittal plane. *Instrument:* sliding caliper (Figure 52).

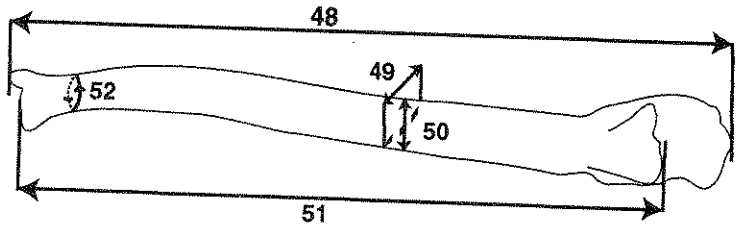

Figure 51 Measurements of the left ulna, anterior view (after Moore-Jansen et al. 1994).

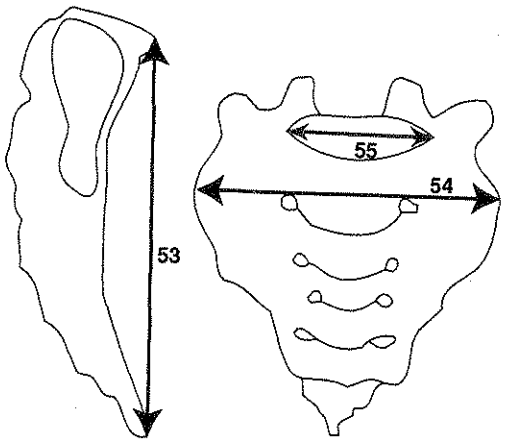

Figure 52. Measurements of the sacrum (after Moore-Jansen et al. 1994).

56. ***Os Coxae: Height:*** distance from the most superior point on the iliac crest to the most inferior point on the ischial tuberosity. *Instrument:* spreading caliper or osteometric board (Figure 53).

57. ***Os Coxae: Iliac Breadth:*** distance from the anterior-superior iliac spine to the posterior-superior iliac spine. *Instrument:* spreading caliper (Figure 53).

58. ***Os Coxae: Pubis Length:*** distance from the point in the acetabulum where the three elements of the os coxae meet to the upper end of the pubic symphysis. *Instrument:* sliding caliper. *Comment:* the measuring point in the acetabulum may be identified in the adult by (1) an irregularity which is frequently visible, both on the acetabular and pelvic surfaces; (2) a change in thickness which may be seen by holding the bone up to a light; (3) a notch often present in the border of the articular surface in the acetabulum. In measuring the pubis, care should be taken to hold the caliper parallel to the long axis of the bone (Figure 53).

59. ***Os Coxae: Ischium Length:*** distance from the point in the acetabulum where the three elements meet to the point in which the axis of the ischium crosses the ischial tuberosity. *Instrument:* sliding caliper. *Comment:* ischium length should be measured approximately perpendicular to pubis length (after Schultz 1930) (Figure 53).

60. ***Femur: Maximum Length:*** distance from the most superior point on the head of the femur to the most inferior point on the distal condyles. *Instrument:* osteometric board. *Comment:* Place the medial condyle against the vertical endboard while applying the movable upright to the femoral head (Figure 54).

61. ***Femur: Bicondylar Length:*** distance from the most superior point on the head to a plane drawn along the inferior surfaces of the distal condyles. *Instrument:* osteometric board. *Comment:* Place both distal condyles against the vertical endboard while applying the movable upright to the femoral head (Figure 54).

62. ***Femur: Epicondylar Breadth:*** distance between the two most laterally projecting points on the epicondyles. *Instrument:* osteometric board (Figure 54).

63. ***Femur: Maximum Head Diameter:*** the maximum diameter of the femur head, wherever it occurs. *Instrument:* sliding caliper (Figure 54).

64. ***Femur: Anterior-Posterior (Sagittal) Subtrochanteric Diameter:*** distance between anterior and posterior surfaces at the proximal end of the diaphysis, measured perpendicular to the medial-lateral diameter. *Instrument:* sliding caliper. *Comment:* be certain that the two subtrochanteric diameters are recorded perpendicular to one another. Gluteal lines and/or tuberosities should be avoided (Figure 54).

65. ***Femur: Medial-Lateral (Transverse)Subtrochanteric Diameter:*** distance between medial and lateral surfaces of the proximal end of the diaphysis at the point of its greatest lateral expansion below the base of the lesser trochanter. *Instrument:* sliding caliper. *Comment:* be certain that the two subtrochanteric diameters are recorded perpendicular to one another (Figure 54).

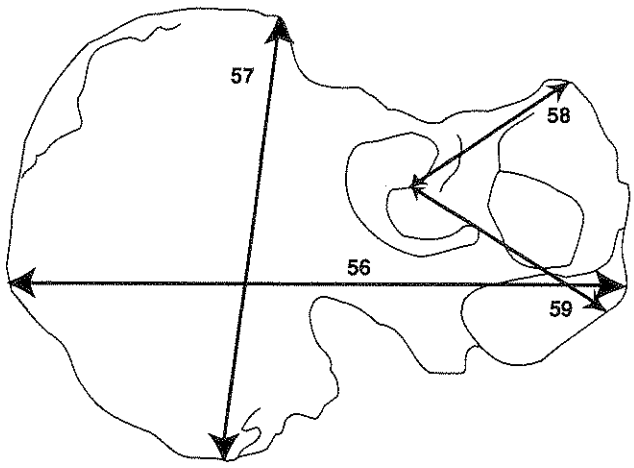

Figure 53. Measurements of the os coxae (after Moore-Jansen et al. 1994).

66. ***Femur: Anterior-Posterior (Sagittal) Midshaft Diameter:*** distance between anterior and posterior surfaces measured approximately at the midpoint of the diaphysis, at the highest elevation of linea aspera. *Instrument:* sliding caliper. Comment: The sagittal diameter should be measured perpendicular to the anterior bone surface (Figure 54).

67. ***Femur: Medial-Lateral (Transverse) Midshaft Diameter:*** distance between the medial and lateral surfaces at midshaft, measured perpendicular to the anterior-posterior diameter (#66). *Instrument:* sliding caliper (Figure 54).

68. ***Femur: Midshaft Circumference:*** circumference measured at the level of the midshaft diameters (#66 and 67). If the linea aspera exhibits a strong projection which is not evenly expressed across a large portion of the diaphysis, then this measurement is recorded approximately 10 mm above the midshaft. *Instrument:* metal tape (Figure 54).

69. ***Tibia: Length:*** distance from the superior articular surface of the lateral condyle to the tip of the medial malleolus. *Instrument:* osteometric board. *Comment:* place the tibia on the board, resting on its posterior surface with the longitudinal axis parallel to the instrument. Place the lip of the medial malleolus on the vertical endboard and press the movable upright against the proximal articular surface of the lateral condyle(Figure 55).

70. ***Tibia: Maximum Proximal Epiphyseal Breadth:*** maximum distance between the two most laterally projecting points on the medial and lateral condyles of the proximal articular region (epiphysis). Tibia diaphysis should parallel the upright of the osteometric board. *Instrument:* osteometric board (Figure 55).

71 ***Tibia: Maximum Distal Epiphyseal Breadth:*** maximum distance between the two most laterally projecting points on the medial malleolus and the lateral surface of the distal articular region (epiphysis). *Instrument:* osteometric board (Figure 55).

72. ***Tibia: Maximum Diameter at the Nutrient Foramen:*** distance between the anterior crest and the posterior surface at the level of the nutrient foramen. *Instrument:* sliding caliper (Figure 55).

73. ***Tibia: Medial-Lateral (Transverse) Diameter at the Nutrient Foramen:*** straight line distance of the medial margin from the interosseous crest at the level of the nutrient foramen. *Instrument:* sliding caliper (Figure 55).

74. ***Tibia: Circumference at the Nutrient Foramen:*** circumference measured at the level of the nutrient foramen. *Instrument:* metal tape (Figure 55).

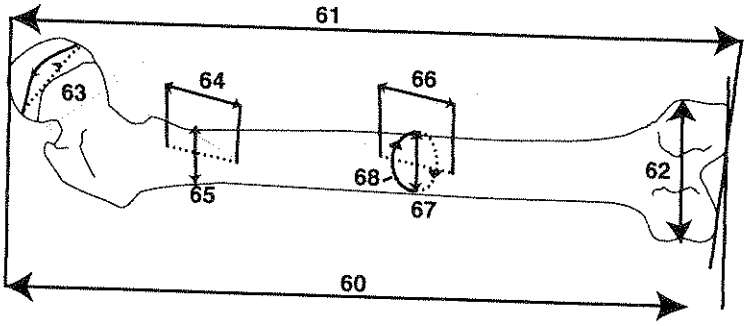

Figure 54. Measurements of the left femur, posterior view (after Moore-Jansen et al. 1994).

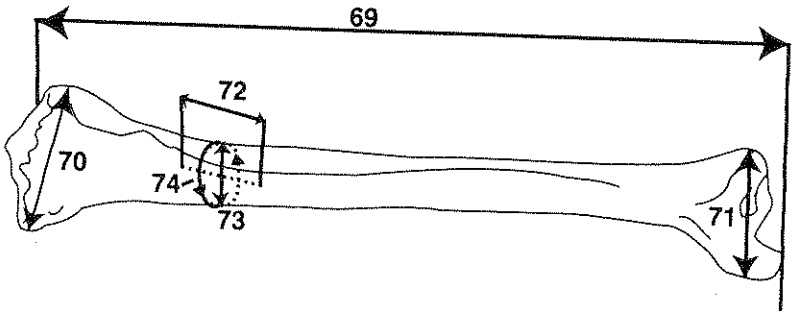

Figure 55. Measurements of the left tibia, anterior view (after Moore-Jansen et al. 1994).

75. ***Fibula: Maximum Length:*** maximum distance between the most superior point on the fibula head and the most inferior point on the lateral malleolus. *Instrument:* osteometric board (Figure 56).

76. ***Fibula: Maximum Diameter at Midshaft:*** maximum diameter at midshaft. *Instrument:* sliding caliper. *Comment:* maximum diameter is most commonly located between the anterior and lateral crests. Find the midpoint of the diaphysis using the osteometric board and mark with a pencil. Place the diaphysis of the bone between the two branches of the caliper while turning the bone to obtain the maximum diameter (Figure 56).

77. ***Calcaneus: Maximum Length:*** distance between the most posteriorly projecting point on the tuberosity and the most anterior point on the superior margin of the articular facet for the cuboid measured in the sagittal plane and projected onto the underlying surface. *Instrument:* sliding caliper. *Comment:* measurement is taken in the sagittal plane and projected onto the underlying surface (Figure 57).

78. ***Calcaneus: Middle Breadth:*** distance between the most laterally projecting point on the dorsal articular facet and the most medial point on the sustentaculum tali. *Instrument:* sliding caliper. *Comment:* the two measuring points lie at neither the same height nor in a plane perpendicular to the sagittal plane. Accordingly, the measurement is projected in both dimensions. Span the calcaneus from behind with the square branches of the caliper so that the ruler is positioned in a flat and transverse plane across the bone (Figure 57).

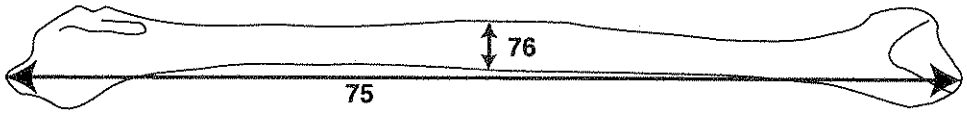

Figure 56. Measurements of the left fibula, lateral view (after Moore-Jansen et al. 1994).

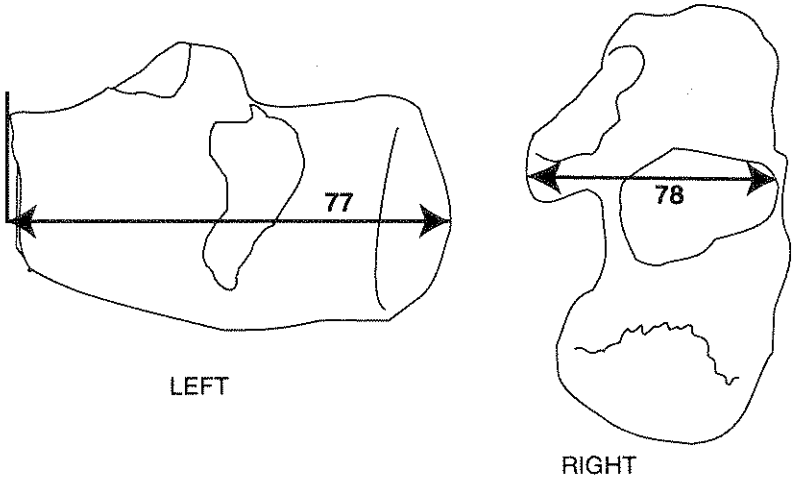

Figure 57. Measurements of the calcaneus (after Moore-Jansen et al. 1994).

TABLE 11.6

Measurements of the Calcaneus and Talus Utilized in Discriminant Function Computations Listed in Table 11.7

Calcaneus

1. Maximum length: from most posterior point of the tuberosity to the most anterior-superior point of the cuboidal facet
2. Minimum width: minimum horizontal width through the body taken anterior to the tuberosity and posterior to the posterior facet for the talus
3. Body height: from most inferior point of the tuberosity to the most superior point of the posterior facet of the calcaneus
4. Load arm length: from the most posterior point of the posterior articular surface for the talus to the most anterior-superior point of the cuboidal facet
5. Load arm width: from the most lateral point of the posterior articular surface to the most medial point of the sustentaculum tali

Talus

1. Maximum length: from the sulcus for the flexor hallucis longus muscle at the posterior aspect of the talus to the most anterior point on the articular surface for the navicular
2. Width of the talus: from the most lateral point of the articular surface for the lateral malleolus to the opposite point of the articular surface for the tibia
3. Body height: taken by placing the talus on a flat surface and then determining the most superior point of the articular surface for the tibia. The superior point is usually along the medial rim of the tibial facet.
4. Maximum length of the trochlea for the tibia: taken in an anterior-posterior plane
5. Maximum width of the trochlea: taken perpendicular to the projected line for the maximum length of the trochlea

APPLICATIONS

Gender

Bunning (1964) was the first to note sexual variations of the bones of the foot. Based upon a sample of 183 adult males, 63 adult females, and 64 fetuses from Nigeria, Bunning documented that calcanea with two anterior superior facets occurred in 57.7 percent of the males and 80.2 percent of the females. Although this difference is significant at the 0.05 level of confidence, it has marginal value as an aid in estimating the sex of unknown individuals because of the high incidence in both sexes of calcanea with double anterior facets.

More recently Steele (1976) developed a series of discriminant functions to distinguish the sex of individuals based upon measurements of the talus and calcaneus. The sample utilized for this study consisted of 58 white males, 60 black males, 58 white females, and 63 black females from the Terry collection. The measurements utilized are listed in table 11.6, illustrated in figure 11.16; discriminant function results are presented in table 11.7. A discriminant function score is the sum of the values produced by multiplying selected measurements by their respective constants. If a score is greater than the sectioning point given for a discriminant function, then the individual is probably male. If the score is less than the section point, then the individual is probably female.

In addition to developing the discriminant functions, Steele determined that 82 percent of the individuals in the study sample could be identified from the maximum length of the talus alone, assuming that all specimens greater than 52 mm were males and those smaller were females. Both the maximum length of the talus and the discriminant functions developed for the Terry collection were shown to accurately estimate the gender of unknown individuals from other populations if the sectioning point was adjusted for that population.

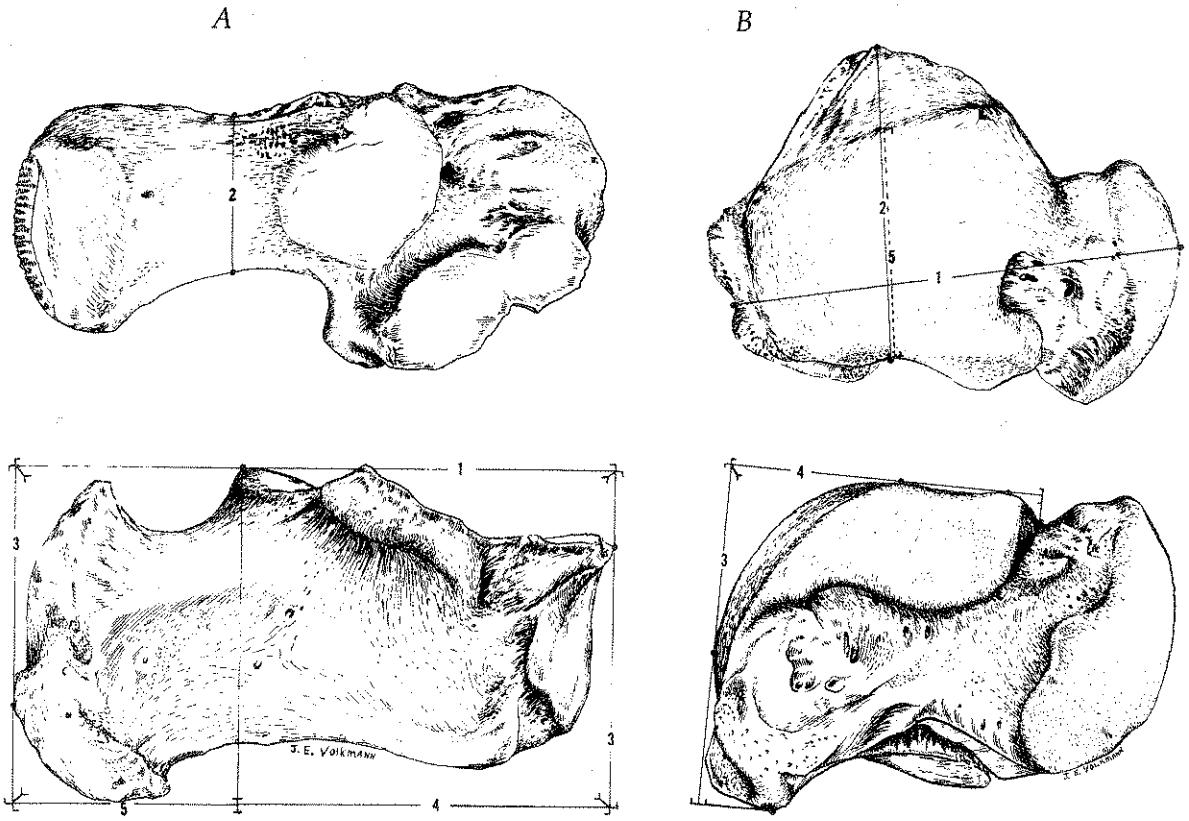

FIGURE 11.16

Calcaneus (A) and Talus (B) Measurements Used to Determine the Gender of Individuals

Numbers correspond to descriptions of measurements listed in table 11.6.

CHAPTER 8

NONMETRIC SKELETAL TRAITS

The nonmetric traits, also termed discrete traits (Rightmire 1972), discreta (Rösing 1982), discontinuous traits (Ossenberg 1969), epigenetic traits (Berry and Searle 1963), minor variants (Berry and Searle 1963), and quasicontinuous traits (Grüneberg 1952), have been recorded in skeletal material since the time of Blumenbach (1776). For much of this period, nonmetric features were described in detail but they seldom served as a basis for population comparison, even though their utility in phylogenetic study had been recognized by Wood Jones in 1931. Family studies of these traits follow a tradition begun nearly a century ago (Shepherd 1893; Symmers 1895).

Commonly observed traits normally take one of four forms: ossicles or small bones that occur within cranial sutures, abnormal proliferative ossifications such as bony spurs or bridges, ossification failure leading to defects such as the septal aperture of the humerus or the tympanic dihiscence of the external auditory meatus, and variation in foramen number and location. Features associated with ossification failure may be termed hypostotic traits, while hyperostotic traits involve abnormal bone formation (Ossenberg 1970).

The significance of nonmetric traits in contemporary studies of ancient skeletal remains is based on the knowledge that these variants show familial inheritance in *H. sapiens* (Torgersen 1951a, 1951b, 1963; Selby et al. 1955; Saunders and Popovich 1978), laboratory mice (Grüneberg, 1952, 1954, 1955; Deol et al. 1957; Grewal 1962; Self and Leamy 1978), rabbits (Sawin and Hamlet 1972), and rhesus macaques (Cheverud 1982; Cheverud and Buikstra 1981a, 1981b, 1982). Heritability estimates for human skeletal remains from mortuary contexts has also been reported (Lane 1977; Sjøvold 1984).

In North America, two key investigations have encouraged enthusiasm for the use of nonmetric traits as markers of biological distance in skeletal series: Laughlin and Jørgensen (1956) and Lane and Sublett (1972). Although studies of biological distance have in general become less prominent than paleopathology and forensic anthropology in recent years (Buikstra et al. 1990), nonmetric traits have continued to enjoy visibility in the work of European scholars, as illustrated by the detailed treatment recently published by Hauser and De Stefano (1989). The Hauser and De Stefano volume, which exhaustively treats nonmetric variants of the skull, should be carefully read by anyone seriously considering biological distance study.

As noted by many researchers, an advantage of nonmetric traits is the fact that they may be recorded in fragmentary, incomplete, and poorly preserved materials. Although questions of intra- and inter-observer error must be considered (Corruccini 1974; Conner 1984; Konigsberg 1987; also, see Appendix II), nonmetric traits can be recorded with ease and efficiency, compared to the more elaborate procedures required in mensuration.

Analyses of biological distance must treat thorny problems such as asymmetry, age/sex associations and inter-trait correlations, which appear to be population-specific. While researchers do not agree on analytical procedures for dealing with such issues, it *is* possible to develop a data collection protocol that will be sufficiently flexible to accommodate various forms of statistical manipulation. This chapter will develop a suitable scoring procedure for those traits determined to be most useful in skeletal series recovered from North American mortuary sites. Three points are significant in this regard.

1. Researchers must record positive occurrences, absences, and instances in which observations could not be made. Reports of counts without knowledge of the number of times observations could be made are not useful.
2. Bilateral traits must be scored on both sides of each individual in the sample.
3. Although in some instances traits are scored dichotomously (presence vs. absence), certain features must be considered against a graded scale. While an argument can be made for dichotomous scoring of all traits, based on the need for scoring consistency, it is clear that nonmetric traits reflect the additive effect of multiple genes (Grüneberg 1963; Saunders and Popovich 1978). Thus, nonmetric traits may be considered threshold characters, according to Falconer's (1965, 1967) model, as described by Hauser and De Stefano (1989:5-8). Therefore multistage scoring provides significantly more information about the genome than dichotomous scoring (Hauser and De Stefano 1989).

The next section identifies the nonmetric traits considered to be of primary importance and includes information concerning location and scoring strategy for each variant. Figures are also provided to illustrate these traits. *Both adult and juvenile materials should be coded.* Attachment 22 includes data recording standards. Table 4 identifies a further, more extensive listing of cranial and postcranial nonmetric traits which can be used to supplement the primary features. Some of the traits in Table 4 were not included in the list of primary traits due to their rarity in most North American populations. However, if such traits are found to occur frequently in the specific population being studied, then those traits should be scored along with the primary traits.

Certain anomalies sometimes considered to be nonmetric traits, such as spondylolysis, are considered in other chapters. Spondylolysis, for example, is recorded as a spinal pathology (Chapter 10). Additional information concerning these and other nonmetric variants appears in Anderson (1964); El-Najjar and McWilliams (1978); Finnegan (1974); Finnegan and Faust (1974); Hauser and De Stefano (1989); Saunders (1978); Winder (1981).

Recommendations for determinations of intra- and inter-observer error are given in Appendix II.

Nonmetric Traits of Primary Importance

1. ***Metopic Suture:*** Located on midline of the frontal bone, from bregma to nasion. Persistence of sutura interfrontalis,which usually closes by the eighth year. Suture may be completely retained or may only extend a short distance from nasion (Figure 58).

2. ***Supraorbital Structures:*** Notches and/or foramina may be present at the supraorbital margin of the frontal bone. All foramina must present openings on both orbital and external surfaces to be scored as present. Foramina on the superior, horizontal aspects of the margin are considered supraorbital, while those located at the confluence of the vertical (medial) and horizontal aspects of the orbit are considered supratrochlear. Only supraorbital structures will be considered primary nonmetric traits (Figure 58). vessels → direction variable

3. ***Infraorbital Suture:*** Located on the orbital and facial surfaces, though presence on the facial surface only will be scored. A complete suture extends from the orbital margin to the infraorbital foramen. Partial and complete sutures will be distinguished (Figure 58).

4. ***Multiple Infraorbital Foramina:*** Foramina situated on the external anterior surface of the maxilla below the infraorbital margin, above the canine fossa. Probing with a bristle or other flexible fiber may be necessary to demonstrate that the foramina extend into a canal that opens on the orbital floor. Divisions observable within the infraorbital canal will be scored as distinct from true multiple foramina (Figure 58).

5. ***Zygomatico-facial Foramina:*** Foramina located on facial surface of zygomatic (malar) bone. Both size and number should be recorded (Figure 58).

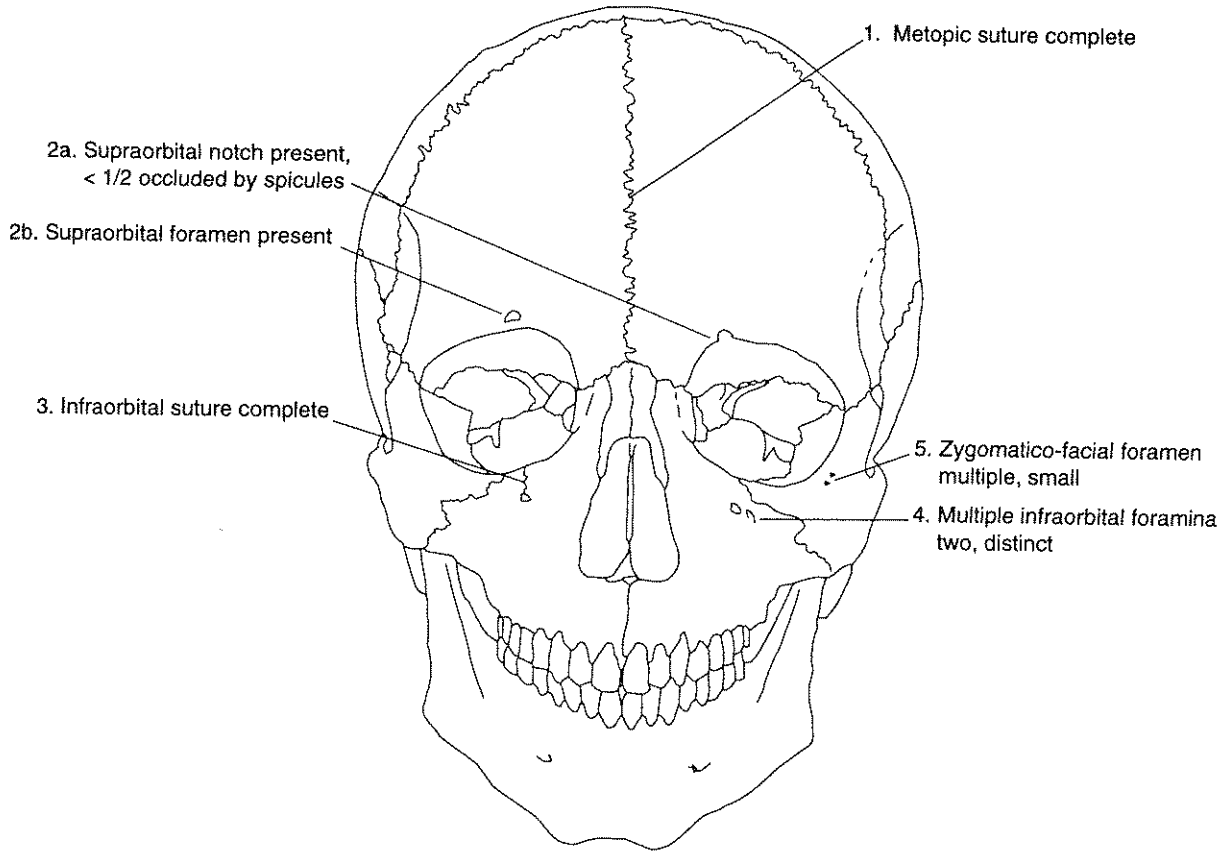

Figure 58. Frontal view of cranial vault illustrating locations of metopic suture, supraorbital notch, supraorbital foramen, infraorbital suture, zygomatico-facial foramina, and infraorbital foramina.

6. ***Parietal (Obelionic) Foramen:*** Located on the parietal bone, within or near the suture at obelion. Foramen should lead into canal extending to and perforating the internal table. Foramina existing only on the internal table should not be scored (Figure 59).

7. ***Sutural Bones:*** Ossicles located at specific points in the cranial vault. Should be true separate ossifications and not part of a complicated suture. Adjacent sutures should be visible for occurrence to be scored (Figure 59).
   a. *Epipteric Bone:* Located at the junction of the frontal, parietal, temporal, and sphenoid bones.
   b. *Coronal Ossicle:* Located within coronal suture.
   c. *Bregmatic Bone:* Located at junction of paired parietals and frontal, formed within anterior fontanelle.
   d. *Sagittal Ossicle:* Located within sagittal suture.
   e. *Apical Bone:* Located at lambda, within posterior fontanelle.
   f. *Lambdoid Ossicle:* Located within lambdoid suture.
   g. *Asterionic Bone:* Located at junction of occipital, parietal, and temporal bones.
   h. *Ossicle in Occipito-Mastoid Suture:* Located in suture between temporal and occipital bones.
   i. *Parietal Notch Bone:* Ossicle located within parietal notch, between squamous portion of temporal and parietal.

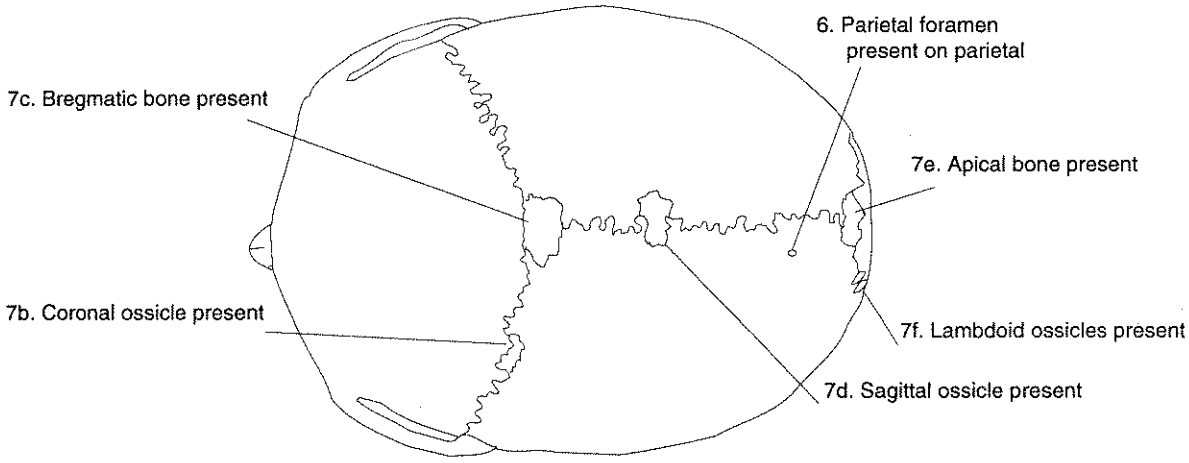

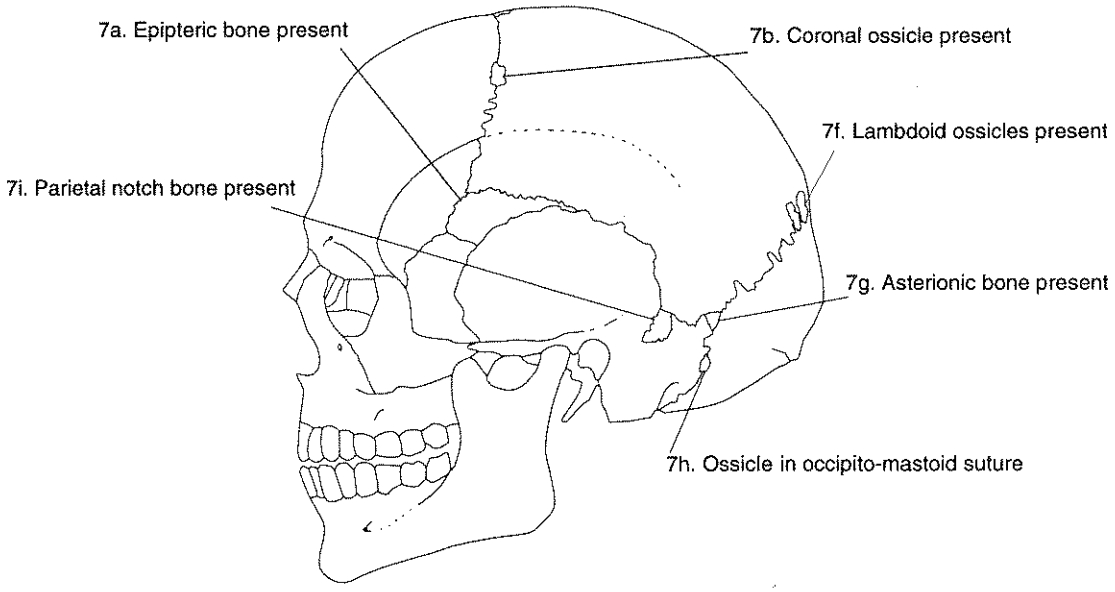

Figure 59. Superior and lateral aspect of cranial vault illustrating locations of parietal foramina and the sutural bones.

8. ***Inca Bone:*** Failure of fusion of the primary ossification centers of the squamous portion of the occipital bone. Most commonly a transverse suture (sutura Mendoza) divides the squamous portion at the point of the highest nuchal line. It is important to distinguish the Inca bone from the presence of an ossicle at lambda, which is smaller and centered in the posterior fontanelle (Figure 60).

9. ***Condylar Canal:*** Canal opening within the condylar fossa, posterior to the occipital condyles. An open or "patent" canal is directed antero-medially, ending in a foramen located on the superior aspect of the pars lateralis, within the cranial cavity, or within the jugular notch (Figure 60).

10. ***Divided Hypoglossal Canal:*** The hypoglossal canal is located superior to the occipital condyle, normally at an angle perpendicular to the main axis of the condyle. The hypoglossal canal can be divided by spines located within the canal or on the internal aspect adjacent to foramen magnum. Both the location of the spines and the completeness of the bridge they form should be recorded (Figure 60).

11. ***Direction of Flexure for Superior Sagittal Sulcus:*** The superior sagittal sulcus most commonly flexes right. Variations include left flexure and bifurcation (Figure 60).

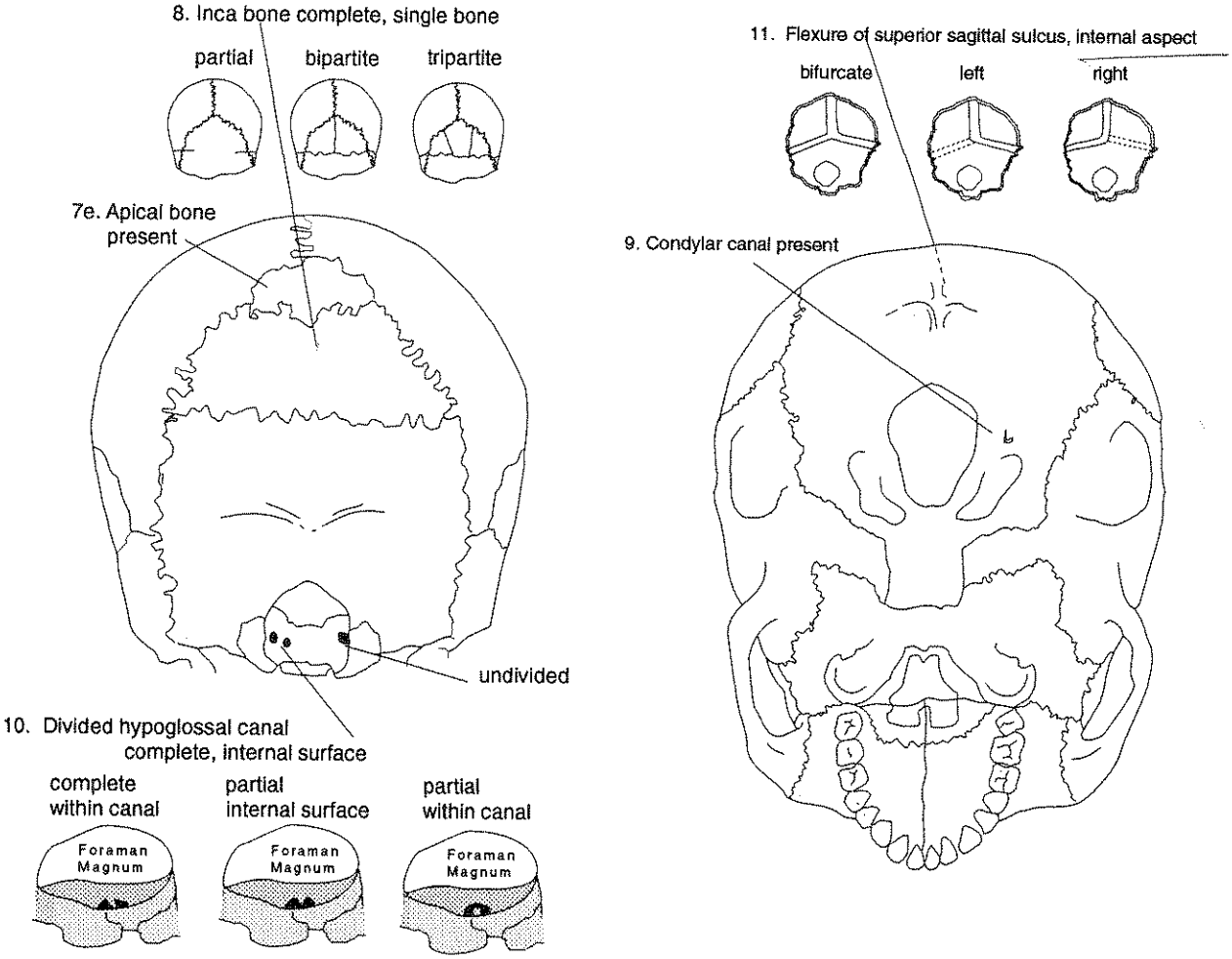

Figure 60. Posterior and basilar aspects of cranial vault illustrating locations of the inca bone, condylar canal, divided hypoglossal canal (original drawing by Betsy Krug), and the flexure of superior sagittal sulcus.

12. Foramen Ovale Incomplete: Foramen ovale (sphenoid bone) open to foramen lacerum (Figure 61).

13. Foramen Spinosum Incomplete: Foramen spinosum (sphenoid bone) open to foramen lacerum (Figure 61).

14. Pterygo-spinous Bridge or Spur: Bony bridge due to fusion of lateral lamina between lateral pterygoid plate of sphenoid and spina angularis. Incomplete bridge (spur) should be distinguished from full ossification (Figure 61).

15. Pterygo-alar Bridge or Spur: Bony bridge due to fusion of lateral lamina between lateral pterygoid plate of sphenoid and inferior surface of the greater wing. Incomplete bridge (spur) should be distinguished from full ossification. (Figure 61).

16. Tympanic Dihiscence: Incomplete closure of tympanic plate of the temporal bone. The defect occurs on the anterior aspect, posterior to the mandibular fossa. Small foramina should be distinguished from extensive ossification failures (Figure 61).

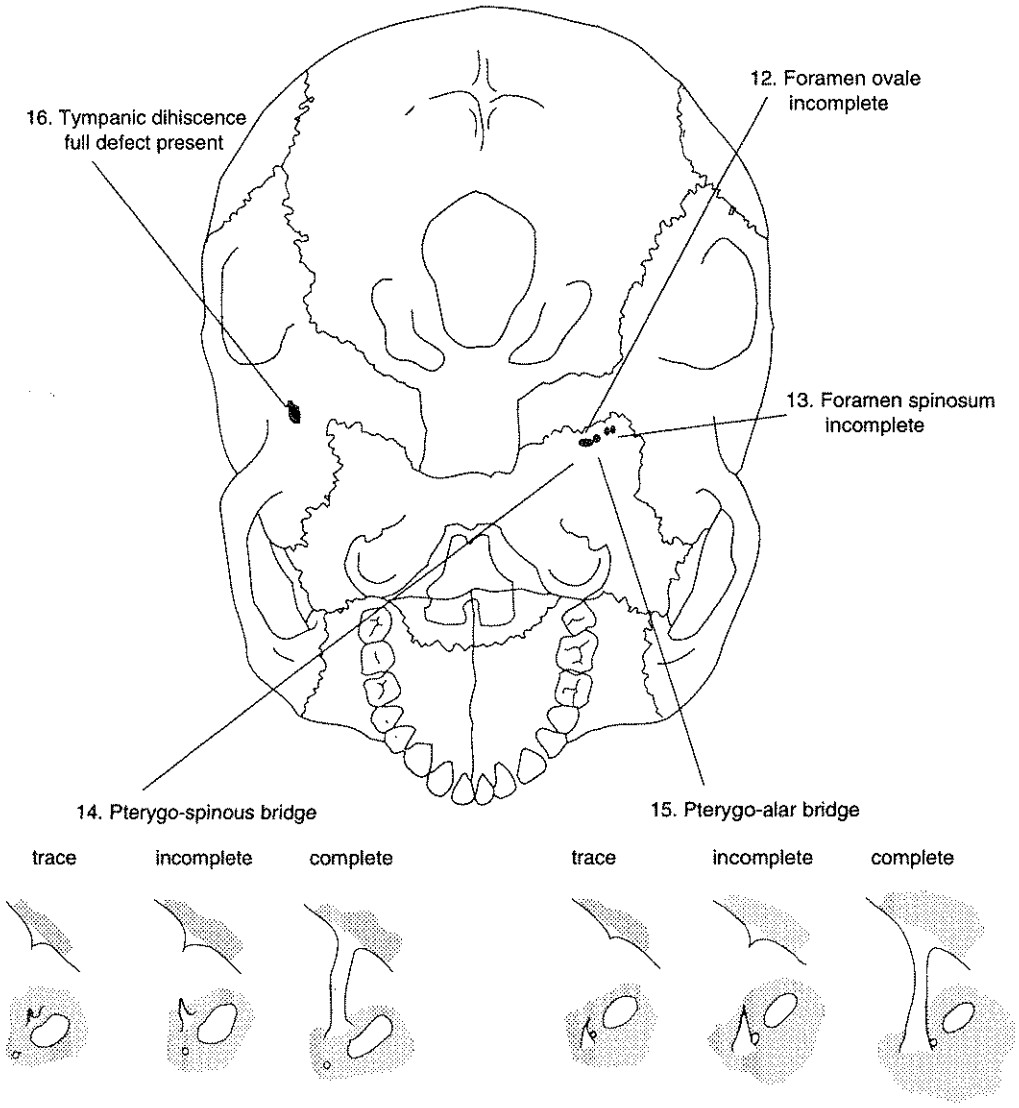

Figure 61. Basilar aspect of cranial vault illustrating locations of foramen ovale incomplete, foramen spinosum incomplete, pterygo-spinous bridge and spur, pterygo-alar bridge and spur, and tympanic dihiscence.

17. ***Auditory Exostosis (Torus):*** Bony nodule developed within internal auditory meatus. Degree of canal occlusion should be estimated (Figure 62).

18. ***Mastoid Foramen:*** Foramen located posterior to the mastoid process, usually on the temporal bone, but occasionally on the occipital or within the occipito-mastoid suture. Both location and number should be reported (Figure 62).

19. ***Mental Foramen Number:*** Foramina located on the external aspect of the mandibular corpus inferior to P_3. The most frequent variant is double foramina (Figure 62).

20. ***Mandibular Torus:*** Bony ridge or series of nodules that develop on the lingual aspect of the lower jaw near the premolars and canines. Do not confuse with robust mylohyoid line (Figure 62).

21. ***Mylohyoid Bridge:*** Bony bridge over the mylohyoid canal of the mandible, either in region of mandibular foramen or approximately in the center of the groove. Both location and degree of bridge formation should be recorded (Figure 62).

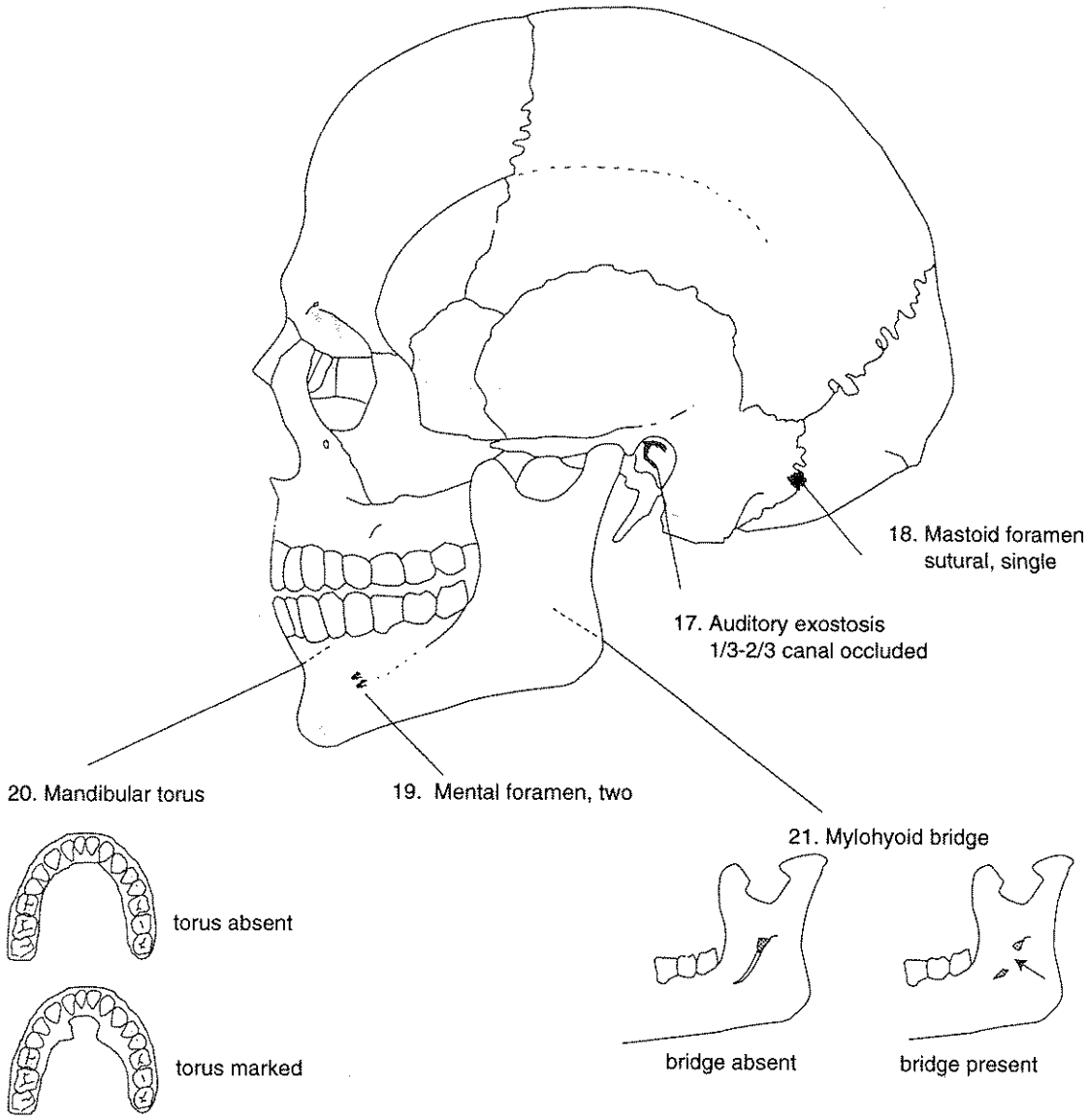

Figure 62. Lateral aspect of cranial vault illustrating locations of auditory exostosis, mastoid foramen, mental foramen, mandibular torus, and mylohyoid bridge.

22. *Atlas Bridging:* Location and degree of expression are scored (Figure 63).
Lateral Bridge: Bony spicules unite the lateral aspect of the superior articular facet of C1 with the lateral mass.
Posterior Bridge: Bony spicules unite the posterior aspect of the superior articular facet of C1 with the posterior arch.

23. *Accessory Transverse Foramina in Seventh Cervical Vertebra:* Bony spicules may divide transverse foramina. Division may be partial or complete (Figure 64).

24. *Septal Aperture:* Perforation between the olecranon fossa and coronoid fossa of distal humerus. Degree of expression is reported (Figure 65).

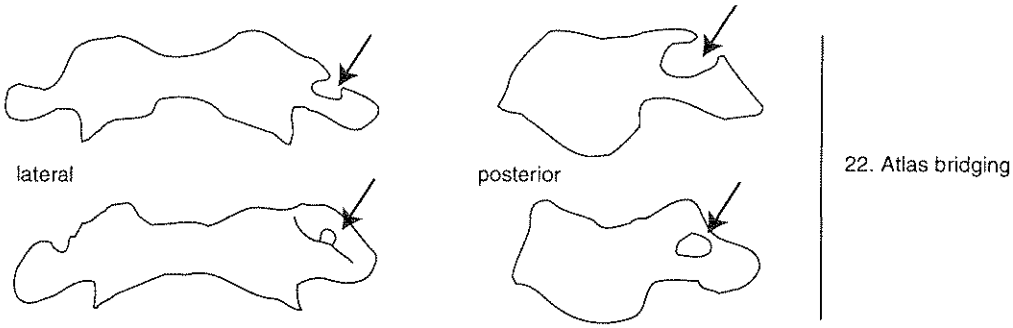

Figure 63. Lateral and posterior bridging of the atlas. Both partial (top) and complete (bottom) bridging are illustrated (after Hauser and DeStefano 1989, Figure 17).

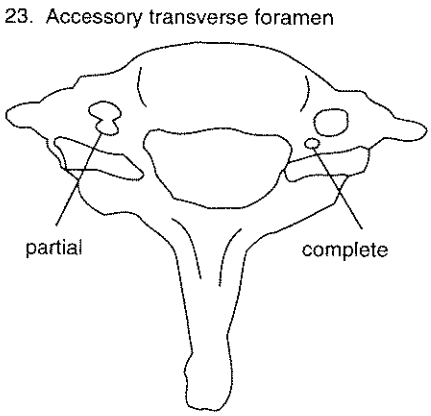

Figure 64. Accessory transverse foramen in the seventh cervical vertebra, illustrating complete (right) and partial (left) expressions (after Saunders 1978, Plate 35).

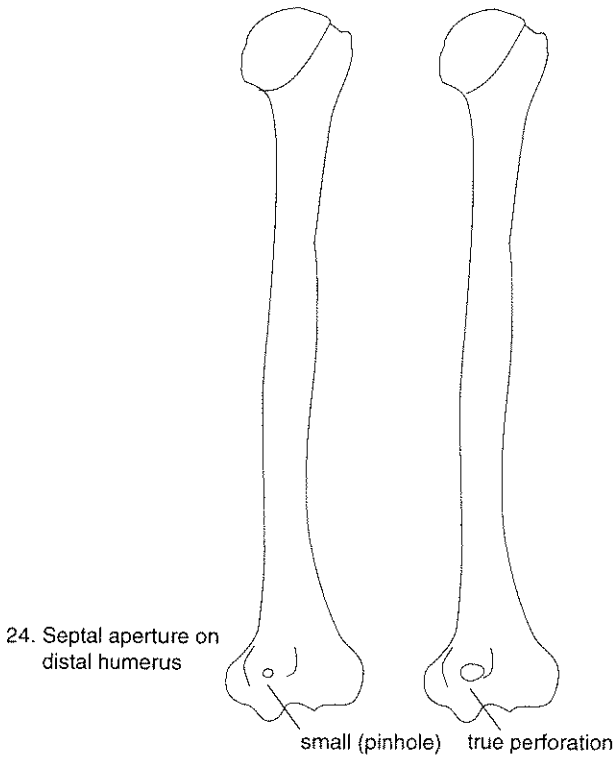

Figure 65. Two degrees of expression of the septal aperture (after Saunders 1978, Plate 8f).

PRIMARY NONMETRIC TRAITS RECORDING FORM

Site Name/Number _____/_____ Observer _____

Feature/Burial Number _____/_____ Date _____

Burial/Skeleton Number _____/_____

Present Location of Collection _____

	L	M	R
1. Metopic Suture:			
0 = absent			
1 = partial		___	
2 = complete			
9 = unobservable			
2. Supraorbital Structures			
a. **Supraorbital notch:**	___		___
0 = absent			
1 = present, < 1/2 occluded by spicules			
2 = present, > 1/2 occluded by spicules			
3 = present, degree of occlusion unknown			
4= multiple notches			
9 = unobservable			
b. **Supraorbital foramen:**	___		___
0 = absent			
1 = present			
2 = multiple foramina			
9 = unobservable			
3. Infraorbital Suture:	___		___
0 = absent			
1 = partial			
2 = complete			
9 = unobservable			
4. Multiple Infraorbital Foramina:	___		___
0 = absent			
1 = internal division only			
2 = two distinct foramina			
3 = more than two distinct foramina			
9 = unobservable			
5. Zygomatico-facial Foramina:	___		___
0 = absent			
1 = 1 large			
2 = 1 large plus smaller f.			
3 = 2 large			
4 = 2 large plus smaller f.			
5 = 1 small			
6 = multiple small			
9 = unobservable			
6. Parietal Foramen:	___		___
0 = absent			
1 = present, on parietal			
2 = present, sutural			
9 = unobservable			

	L	M	R
7. Sutural Bones			
0 = absent			
1 = present			
9 = unobservable			
a. epipteric bone:	___		___
b. coronal ossicle:	___		___
c. bregmatic bone:		___	
d. sagittal ossicle:		___	
e. apical bone:		___	
f. lambdoid ossicle:	___		___
g. asterionic bone:	___		___
h ossicle in occipito-mastoid suture:	___		___
i. parietal notch bone:	___		___
8. Inca Bone		___	
0 = absent			
1 = complete, single bone			
2 = bipartite			
3 = tripartite			
4 = partial			
9 = unobservable			
9. Condylar Canal:	___		___
0 = not patent			
1 = patent			
9 = unobservable			
10. Divided Hypoglossal Canal:	___		___
0 = absent			
1 = partial, internal surface			
2 = partial, within canal			
3 = complete, internal surface			
4 = complete, within canal			
9 = unobservable			
11. Flexure of Superior Sagittal Sulcus		___	
1 = Right			
2 = Left			
3 = Bifurcate			
9 = Unobservable			
12. Foramen Ovale Incomplete:	___		___
0 = absent			
1 = partial formation			
2 = no definition of foramen			
9 = unobservable			

Series/Burial/Skeleton_____

Observer/Date _____

	L	M	R
13. Foramen Spinosum Incomplete: 0 = absent 1 = partial formation 2 = no definition of foramen 9 = unobservable	___		___
14. Pterygo-spinous Bridge: 0 = absent 1 = trace (spicule only) 2 = partial bridge 3 = complete bridge 9 = unobservable	___		___
15. Pterygo-alar Bridge: 0 = absent 1 = trace (spicule only) 2 = partial bridge 3 = complete bridge 9 = unobservable	___		___
16. Tympanic Dihiscence: 0 = absent 1 = foramen only 2 = full defect present 9 = unobservable	___		___
17. Auditory Exostosis: 0 = absent 1 = <1/3 canal occluded 2 = 1/3-2/3 canal occluded 3 = >2/3 canal occluded 9 = unobservable	___		___
18. Mastoid Foramen a. **Location:** 0 = absent 1 = temporal 2 = sutural 3 = occipital 4 = both sutural and temporal 5 = both occipital and temporal 9 = unobservable	___		___
b. **Number:** 0 = absent 1 = 1 2 = 2 3 = more than 2 9 = unobservable	___		___
19. Mental Foramen: 0 = absent 1 = 1 2 = 2 3 = >2 9 = unobservable	___		___

	L	M	R
20. Mandibular Torus: 0 = absent 1 = trace (can palpate but not see) 2 = moderate: elevation between 2-5 mm. 3 = marked: elevation greater than 5 mm. 9 = unobservable	___		___
21. Mylohyoid Bridge a. **Location:** 0 = absent 1 = near mandibular foramen 2 = center of groove 3 = both bridges described in 1) and 2), with hiatus 4 = both bridges described in 1) and 2), no hiatus 9 = unobservable	___		___
b. **Degree:** 0 = absent 1 = partial 2 = complete 9 = unobservable	___		___
22. Atlas Bridging a. **Lateral Bridging:** 0 = absent 1 = partial 2 = complete 9 = unobservable	___		___
b. **Posterior Bridging:** 0 = absent 1 = partial 2 = complete 9 = unobservable	___		___
23. Accessory Transverse Foramina: —in 7th Cervical Vertebra ~~0 = absent~~ 1 = partial 2 = complete 9 = unobservable	___		___
24. Septal Aperture: 0 = absent 1 = small foramen (pinhole) only 2 = true perforation 9 = unobservable	___		___

Table 4
Supplemental List of Nonmetric Traits

The references cited for each trait provide further description and population-based information. These sources have been chosen to minimize the number of books/periodicals an observer would need to consult for photographs and scoring schemes. These references are, therefore, not necessarily those that originally defined a given feature.

1. CRANIAL

Frontal Grooves: Single or paired grooves of variable depth and width which ascend obliquely from the supraorbital region to the temporal line (Hauser and De Stefano 1989).

Ethmoidal Foramina: Variation in number and location of anterior and posterior ethmoidal foramina (Hauser and De Stefano 1989).

Supratrochlear Notch or Foramen: Located on superior aspect of medial wall of orbit (Hauser and De Stefano 1989).

Trochlear Spine: Located behind and slightly below the medial end of the supraorbital margin, about 1 cm above the fronto-lacrimal suture (Hauser and De Stefano 1989).

Double (Occipital) Condylar Facet: Size, shape, and orientation of occipital condyles vary (Hauser and De Stefano 1989: 116).

Paracondylar Process: Process located lateral to the occipital condyle, medial to the mastoid process, and posterior to the jugular fossa (Hauser and De Stefano 1989).

Bridging of Jugular Foramen: Location and completeness of division can vary (Hauser and De Stefano 1989).

Pharyngeal Tubercle: Tubercle located anterior to foramen magnum, on the inferior aspect of the basilar occipital (Hauser and De Stefano 1989).

Clinoid Bridges or Spurs: Bridges or spurs uniting (1) the anterior and middle clinoid processes of the sphenoid; (2) the anterior and posterior clinoid processes; and/or (3) the middle and posterior clinoid processes (Hauser and De Stefano 1989).

Accessory Lesser Palatine Foramina: Small foramina located posterior to the palatine foramina, on the horizontal processes of the palatine bones (Hauser and De Stefano 1989).

Palatine Torus: Bony outgrowth along the midline of the hard palate (Hauser and De Stefano 1989; Turner et al. 1991).

Maxillary Torus: Thickening of lingual margin of alveolar process in molar region of maxilla (Hauser and De Stefano 1989)

Rocker Mandible: Curvature of the inferior surface of the horizontal ramus of the mandible (Turner et al 1991).

Suprameatal Pit or Spine: Pit or spine located immediately superior and posterior to the external auditory meatus (Hauser and De Stefano 1989).

Divided Parietal Bone: Parietal bone is divided by either a horizontal or a vertical suture (Hauser and De Stefano 1989).

Os Japonicum: Suture dividing the zygomatic (malar) into two parts. Suture is usually horizontal (Hauser and De Stefano 1989).

Marginal Tubercle: Projection on temporal border of the frontal process of the zygomatic (malar) (Hauser and De Stefano 1989).

2. POSTCRANIAL

Retroarticular Bridge: Bony bridge or spur extending posteriorly from the posterior border of transverse process to the posterior arch of the first cervical vertebra (Saunders 1978).

Accessory Transverse Foramen in Cervical Vertebrae 3-6: As in the seventh cervical (see Table 1), transverse foramina may be bifurcate at the level of C3-C6 (Saunders 1978).

Cranial or Caudal Shift in Vertebral Numbers: Transitional vertebrae become morphologically identical to adjacent segment, most commonly in lumbo-sacral region. Partial or complete shifts can occur. As a result, an individual may have, for example, four lumbar and six sacral vertebrae instead of the normal five lumbar and five sacral (Saunders 1978).

Accessory Sacroiliac Articulation: Accessory articulation producing articular surfaces inferior to sacroiliac articulation (Finnegan 1978; Saunders 1978).

Suprascapular Foramen or Notch Form: Suprascapular ligament ossifies to form partial or complete bridge closing suprascapular notch (Finnegan 1978; Saunders 1978; Winder 1981).

Accessory Acromial Articular Facet: Facet located on the antero-inferior surface of acromion; articulates with humerus (Finnegan 1978; Saunders 1978; Winder 1981).

Unfused Acromial Epiphysis: Persistence of separate ossification center beyond 25 years (Saunders 1978).

Glenoid Fossa Extension: Oval extension of humeral articular facet at the posterior-superior aspect of the glenoid fossa (Saunders 1978).

Circumflex Sulcus: Groove of variable size and depth located on the posterolateral border of the scapula (Finnegan 1978; Saunders 1978; Winder 1981).

Sternal Foramen: Ossification defect producing aperture in body of sternum (Saunders 1978; Winder 1981).

Supratrochlear Spur: Process arising from medial supracondylar ridge 5-7 cm above the medial condyle of the humerus (Finnegan 1978; Saunders 1978; Winder 1981).

Trochlear Notch Form: Two discrete facets formed on articular surface of trochlear process of ulna (Saunders 1978; Winder 1981).

Allen's Fossa: Depression located on anterior superior margin of femoral neck near articular surface of the head. Underlying trabeculae may be exposed (Finnegan 1978).

Poirier's Facet or Extension: Extension of articular facet from head onto anterior superior aspect of femoral neck (Finnegan 1978; Saunders 1978).

Third Trochanter: Tuberosity located at the superior aspect of the gluteal crest of the femur (Finnegan 1978; Saunders 1978).

Vastus Notch: Varies from a facet to a smooth or sharp-edged notch at the superolateral aspect of the patella (Finnegan 1978).

"Squatting Facets," Distal Tibia: Extensions of distal articular surface onto the anterior aspect of metaphysis (Finnegan 1978; Saunders 1978).

"Squatting Facets," Talus: Extensions of articular facets analogous to those of the tibia, located on the superior surface anterior to the articular facet for the tibia (Finnegan 1978; Saunders 1978).

Shape of Talar Articular Surfaces (Calcaneus): A variety of forms and associations for the talar (superior) articular surfaces includes: three discrete facets; anterior and middle facets joined (usually forming an hourglass shape); all three facets joined (Finnegan 1978; Saunders 1978).

CHAPTER 9

POSTMORTEM CHANGES: HUMAN TAPHONOMY

A variety of perimortem events and postmortem processes can be inferred through the study of bone color, surface details, and shape. Cremation, scalping, and the creation of amulets from ancestral remains are but a few examples of the many cultural behaviors that are reflected in ancient skeletal samples. Chemical, biological, and physical aspects of the depositional environment also leave diagnostic signatures on archaeologically recovered bone. Among the most common of these agents are erosive soil conditions and rodent or carnivore gnawing. Such changes may reveal important information concerning perimortem events and mortuary rituals. Corpses exposed on or above the ground prior to burial may, for example, show evidence of carnivore or insect activity, as well as bone color and texture changes.

It is sometimes difficult to distinguish postmortem changes from those that occurred before death. Oval depressions that result from insect activity and soil acidity have frequently been confused with the effects of diseases that cause abnormal bone resorption. Studies of ancient disease must therefore begin by eliminating postdepositional "pseudopathologies" from the diagnostic process.

Systematic observations of bone condition also serve as today's baseline against which future examinations can evaluate the long-term efficacy of alternative preservation strategies. Evaluations of bone condition are also useful in assessing the impact of various depositional environments upon osseous tissues.

In subsequent sections we discuss a variety of ways in which bone may be altered following death, with emphasis upon the changes most commonly observed in North American materials. Our initial presentation describes typical changes in color, surface texture, and shape, and links these altered states with specific causal factors such as heat, exposure to sunlight, and gnawing by animals. The data collection protocol emphasizes observations that reflect culturally significant behaviors.

This approach borrows many concepts from the subdiscipline of taphonomy (Efremov 1940), which is defined as the investigation of processes that affect an organism from its death until the point at which study commences (Behrensmeyer and Hill 1980; Gifford 1981; White and Folkens 1991). Although taphonomy is normally considered a subfield of paleontology, its principles are clearly relevant to archaeological investigations of human remains (Turner and Morris 1970; Turner 1983; Turner and Turner 1990, 1992).

TYPES OF ALTERATION

Color

Fresh, untreated bone has an ivory color. A variety of agents, including grave inclusions, mortuary rituals, and depositional environments may cause discoloration. Exposure to heat, whether accidental or as part of an interment procedure, causes systematic color changes that provide information about the heat source and its intensity. Temperature can be estimated from the fact that bone burned at relatively low temperatures assumes a brown or black ("smoked') quality, while at higher temperatures bone becomes blue-gray or white. The brown/black coloration may occur at temperatures as low as 200-300 degrees centigrade. At 800 degrees centigrade, "calcined" white to blue-gray coloration appears (Buikstra and Swegle 1989; Shipman et al. 1984; Van Vark 1980).

Patterning of heat-induced color changes may also provide information about condition of cadavers at the time of burning. Joint surfaces and bones located within thick soft tissues will be shielded from the effects of fire when bodies are burned in an articulated, fleshed state. These "shielded" surfaces will show a less severe degree of burning than unshielded portions of the skeleton. Disarticulated or defleshed elements will present a more uniform burning pattern (Buikstra and Swegle 1989). Examples of bone burned under varying conditions are presented in Figure 66.

Metal objects interred with remains can cause bone stains. Most common in North American materials is a green discoloration due to contact with copper.

Bone often changes color in response to the presence of bacteria, plants, and soil minerals that are present in the depositional environment. Most of these agents will darken bone to tan, red-brown, grey or nearly black. In contrast, exposure to the bleaching effects of sunlight will cause bone to assume a chalky, off-white color.

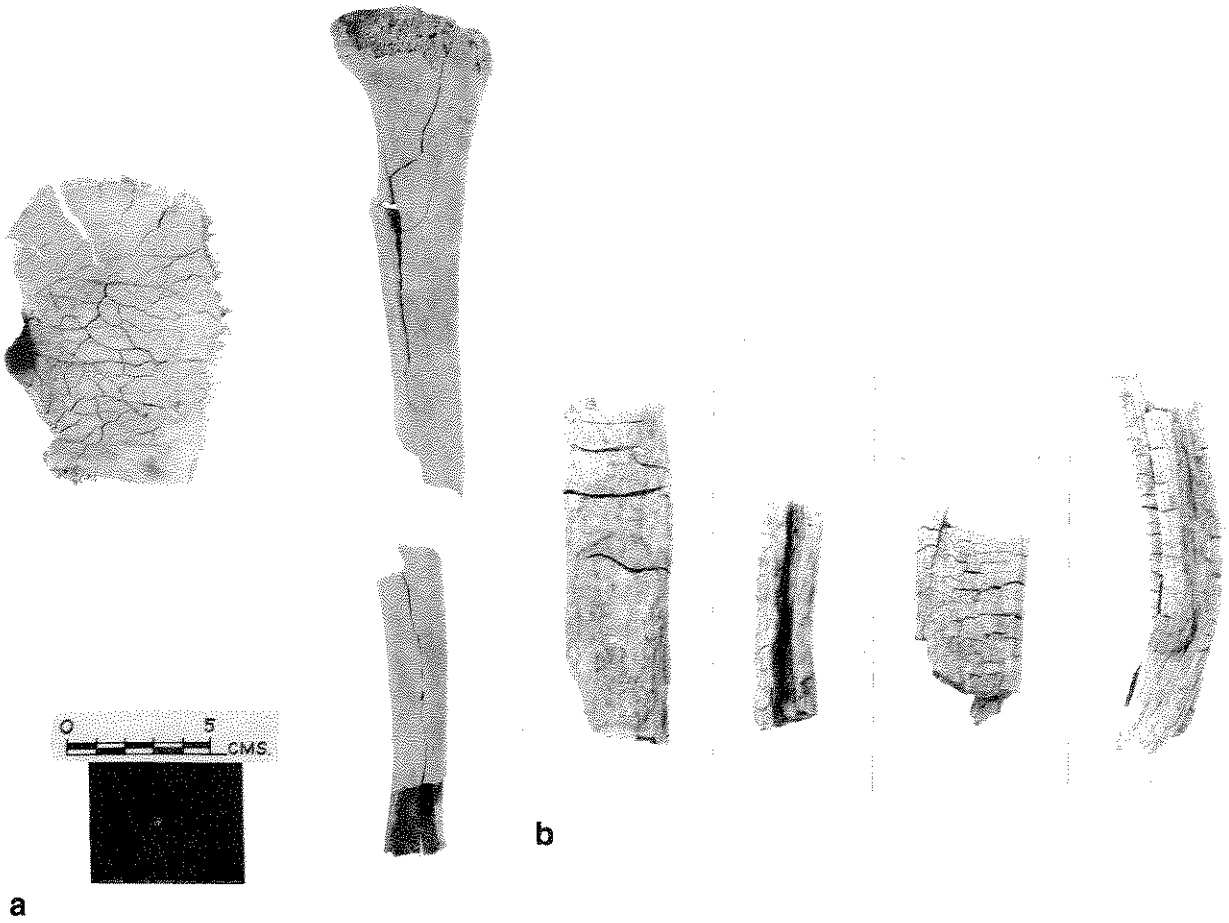

Figure 66a-b. Cremated bone, illustrating various degrees and patterns of burning. a) Cremated bones showing cracking, checking, and splitting, indicating that they were dry when burned. b) Cremated bones with transverse and longitudinal checking and splitting and marked warping, indicating that they were "green" or covered with flesh when burned. Previously published as Figures 52 and 53 in Ubelaker (1989a). Courtesy of D. H. Ubelaker and Taraxacum Press.

Surface Changes

Bone surface texture may be altered by heat, plant roots, insects, worms, soil/sediment characteristics, scavengers, and human activity. In order to fully appreciate the nature of surface changes, the observer is encouraged to use a magnifying lens or low-powered dissecting microscope under bright light.

When bones are exposed to heat sufficient to induce calcination, external surfaces are likely to split and crack. If bone containing a significant organic component is burned, surfaces are likely to assume a "checked" appearance due to cracks both perpendicular and parallel to the main axis of the specimen. Such evidence of "green" burning contrasts with bones burned after the organic component has been depleted. As illustrated in Figure 66, the resultant "dry" burning pattern typically presents less extensive surface modification, primarily shallow cracks parallel to the main axis (i.e., bone will be split longitudinally). Observations of modern crematories and experimental studies have confirmed this distinction (Baby 1954; Binford 1963; Buikstra and Swegle 1989).

Plant roots in contact with bone can etch dendritic patterns reminiscent of vessel tracks. These root tracks may become discolored through acidic decalcification (Figure 67). Such grooves should not be misinterpreted as evidence for pathology or cultural activities (White and Folkens 1991).

The effects of insect infestation, along with the impact of other animals such as worms and other burrowing microfauna, commonly produce bone changes that may mimic abnormal bone resorption. Examples of such "pseudopathologies" are well known from many world areas (Buikstra, Baker, and Cook 1993; Ortner and Putschar 1985; Wells 1967). Each possible resorptive disease focus must be carefully observed for evidence

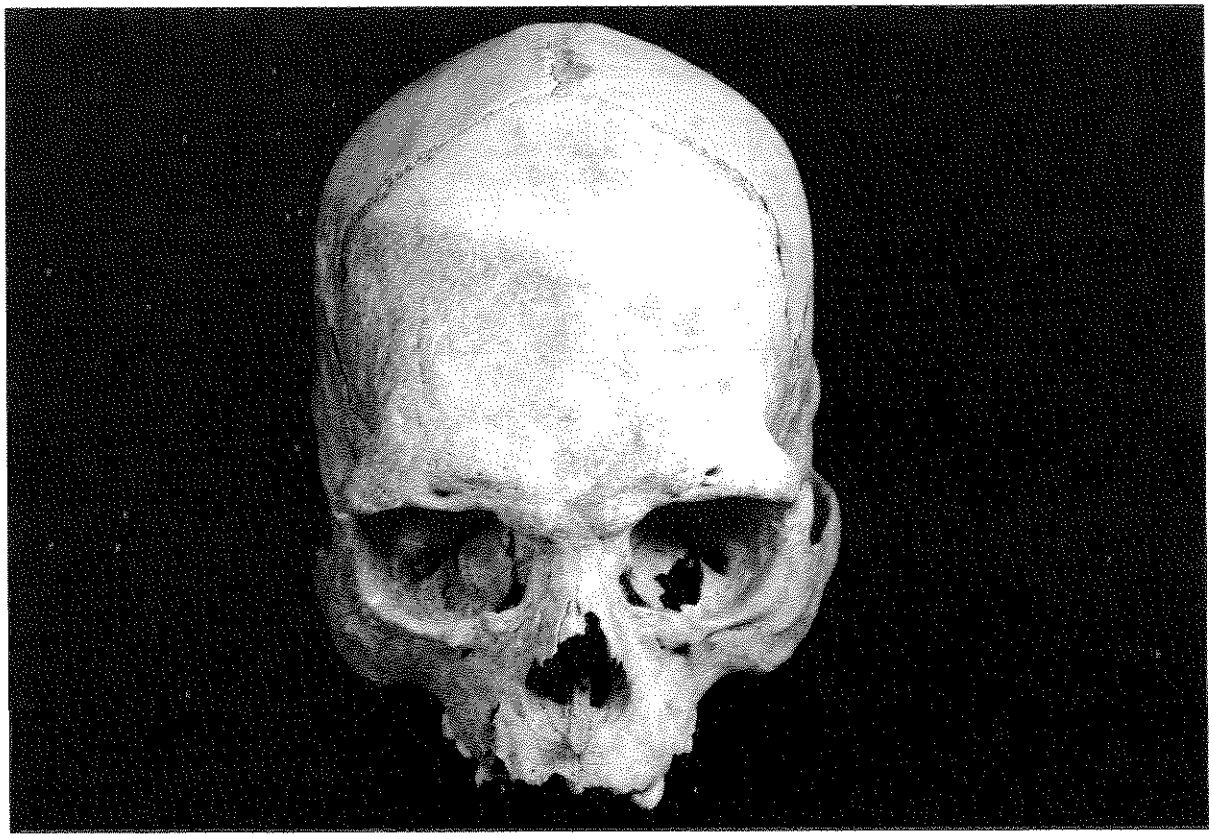

Figure 67. Example of surface erosion due to roots on left frontal. Specimen from Chiribaya Alta, Peru. Photo by Diane Houdek.

of bony response during life. When this key marker is absent, a diagnosis of "pseudopathology" must be considered.

Bone exposed upon the ground surface will weather according to a defined sequence, beginning with superficial cracking and ending in splintering (Table 5 and Figure 68; Behrensmeyer 1978). Although the rate and patterning taken by such changes will reflect local conditions, the sequence is relatively stable and thus provides a standardized means of characterizing weathering changes. These stages are important in defining past depositional environments. Such evaluations also establish a contemporary baseline against which future workers can evaluate the efficacy of alternative preservation regimes.

Table 5
BONE WEATHERING STAGES
After Behrensmeyer (1978). Slightly modified for collections context.

Stage 0: Bone surface shows no sign of cracking or flaking due to weathering.

Stage 1: Bone shows cracking, normally parallel to the fiber structure (e.g. longitudinal in long bones). Articular surfaces may show mosaic cracking.

Stage 2: Outermost concentric thin layers of bone show flaking, usually associated with cracks, in that the bone edges along the cracks tend to separate and flake first. Long thin flakes, with one or more sides still attached to the bone, are common in the initial part of Stage 2. Deeper and more extensive flaking follows, until most of the outermost bone is gone. Crack edges are usually angular in cross section.

Stage 3: Bone surface is characterized by patches of rough, homogeneously weathered compact bone, resulting in a fibrous texture. In these patches, all the external, concentric layers of bone have been removed. Gradually the patches extend to cover the entire bone surface. Weathering does not penetrate deeper than 1.0-1.5 mm at this stage, and bone fibers are still firmly attached to each other. Crack edges usually are rounded in cross section.

Stage 4: The bone surface is coarsely fibrous and rough in texture; large and small splinters occur and may be loose enough to fall away from the bone if it is moved. Weathering penetrates into inner cavities. Cracks are open and have splintered or rounded edges.

Stage 5: Bone is falling apart, with large splinters. Bone easily broken by moving. Original bone shape may be difficult to determine. Cancellous bone usually exposed, when present, and may outlast all traces of the former more compact, outer parts of the bones.

Tooth marks of both carnivores and herbivores (primarily rodents), are commonly observed on human remains. Carnivores typically attack the trabecular ends of long bones where diagnostic patterns of pitting, scoring, and puncturing can be observed (Figure 69). Ribs are also subject to carnivore gnawing (White and Folkens 1991).

Rodents, such as mice, groundhogs, and porcupines produce pairs of parallel, square-bottomed grooves, frequently located at sites of bony prominences such as the lateral margin of the orbit and the iliac crest (Figure 70). These patterned and regular incisions should not be confused with the effects of human activity (White and Folkens 1991).

Cutmarks may provide evidence of scalping or corpse preparation during the course of a mortuary ritual. Cutmarks produced during defleshing and dismemberment often cluster around specific anatomical features, such as points of attachment for tendons and ligaments. The type of tool used to remove flesh can be inferred through examination of a cross section of the cut. V-shaped cross sections are associated with stone flakes or metal knives. Bifacially flaked tools usually produce broad, shallow outlines. Cuts and scratches introduced

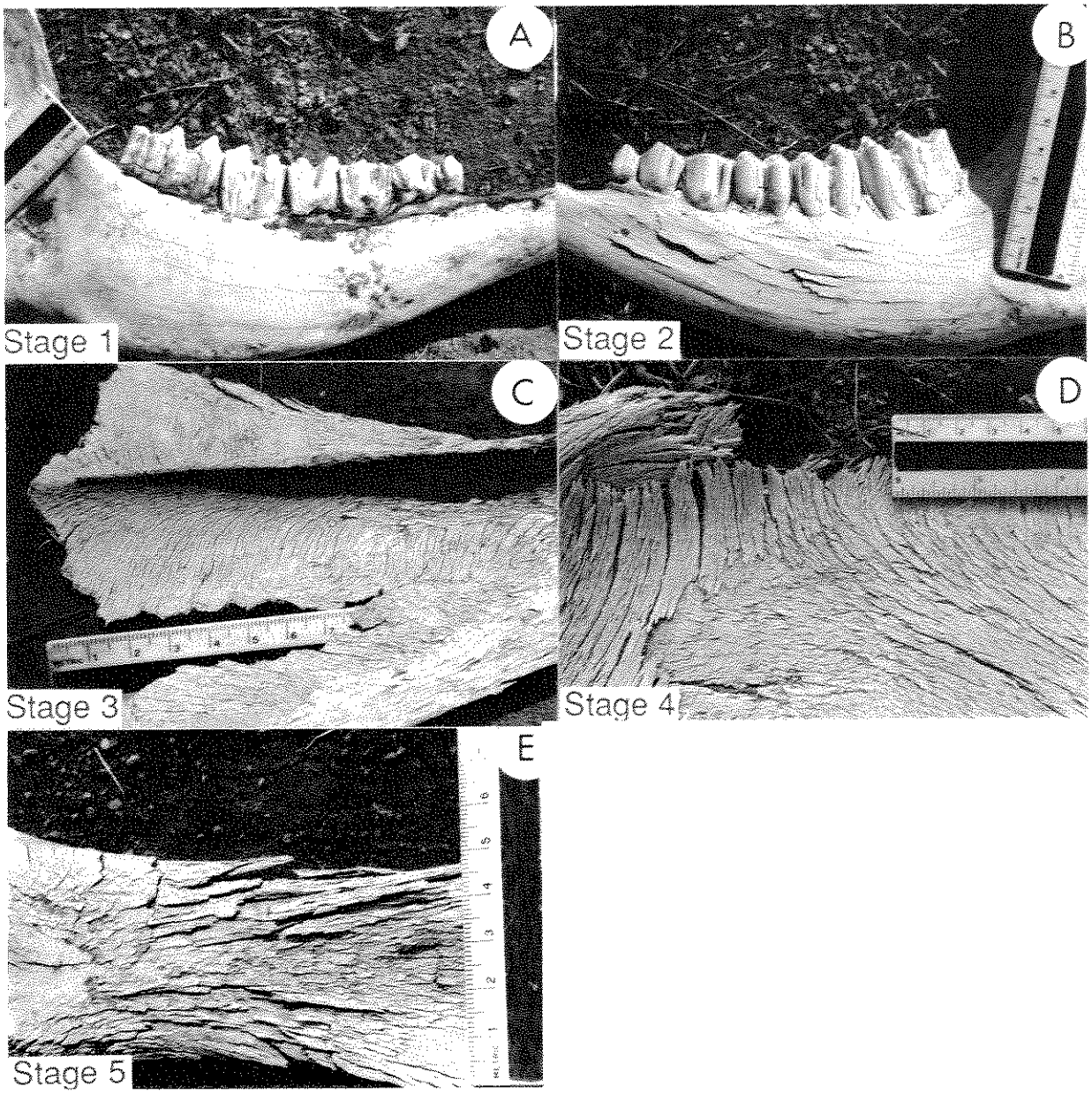

Figure 68. Bone weathering stages. A) Stage 1: cow mandible showing initial cracking parallel to bone fiber structure; B) Stage 2: opposite side of same cow mandible showing flaking of outer bone layers; C) Stage 3: bovid scapula showing fibrous, rough texture and remnants of surface bone near lower right border; D) Stage 4: part of scapula showing deep cracking and coarse, layered fiber structure; E) Stage 5: scapula blade showing final stages of deep cracking and splitting. Previously published as Figure 2 in Behrensmeyer (1978). Courtesy of K. Behrensmeyer.

during excavation or curation can be distinguished from perimortem or immediately postmortem events by inspecting the color of the bone at the base of the cut. Modern marks will be light in color, while evidence of more ancient behaviors will be stained by the depositional environment and thus match the remainder of the bone. Several examples of cutmarks are illustrated in Figure 71. Included are cutmarks of the postcranial skeleton associated with dismemberment and modifications of the cranial vault suggestive of scalping.

a

b

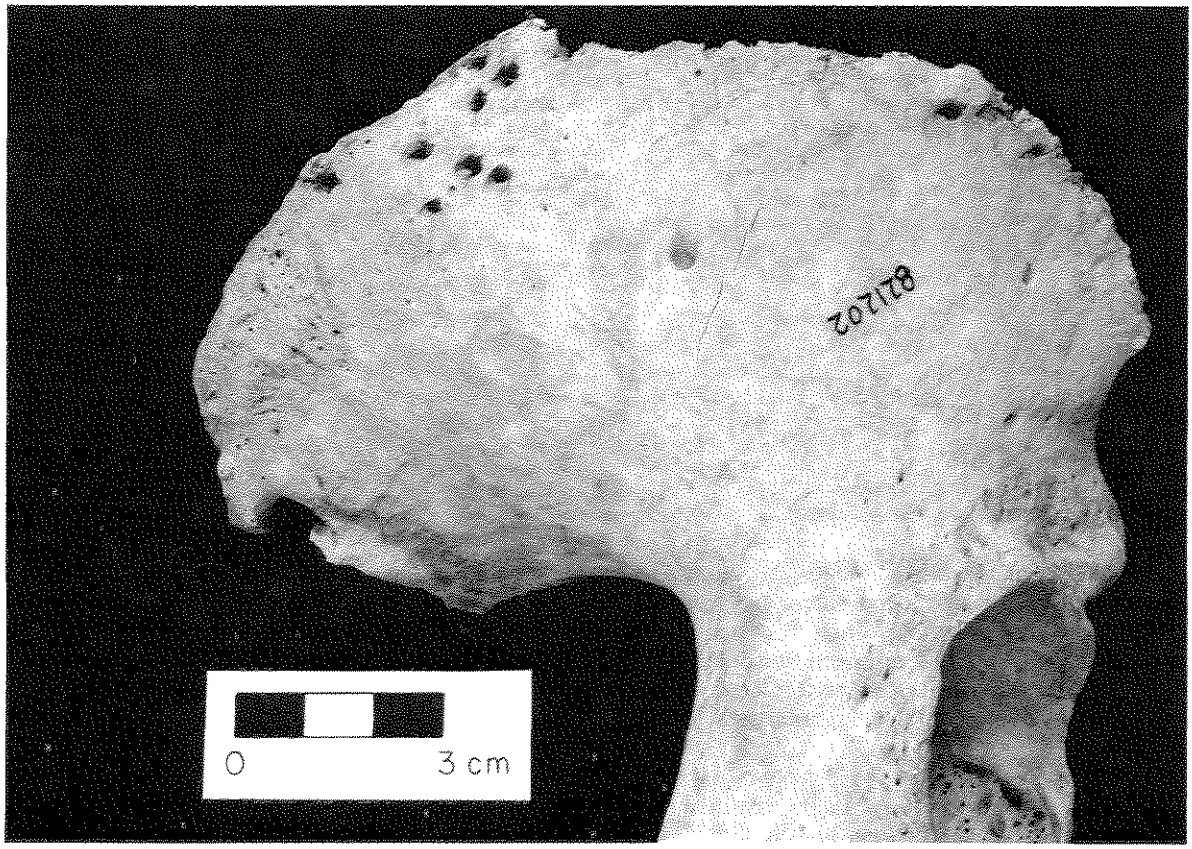

Figure 69a-b. Carnivore tooth marks. a) Small carnivore (dog or coyote) tooth puncture marks on two distal fibulae. Specimens from Room 59 mass burial, Wupatki Ruin, northeast Arizona. Courtesy of C.G. Turner II. b) Carnivore tooth puncture marks on a right ilium. Specimen from Burial 200, Norris Farms 36, central Illinois. Previously published as Figure 4 in *American Antiquity* 56(1991):581-603. Courtesy of G. R. Milner and the Society for American Archaeology.

a

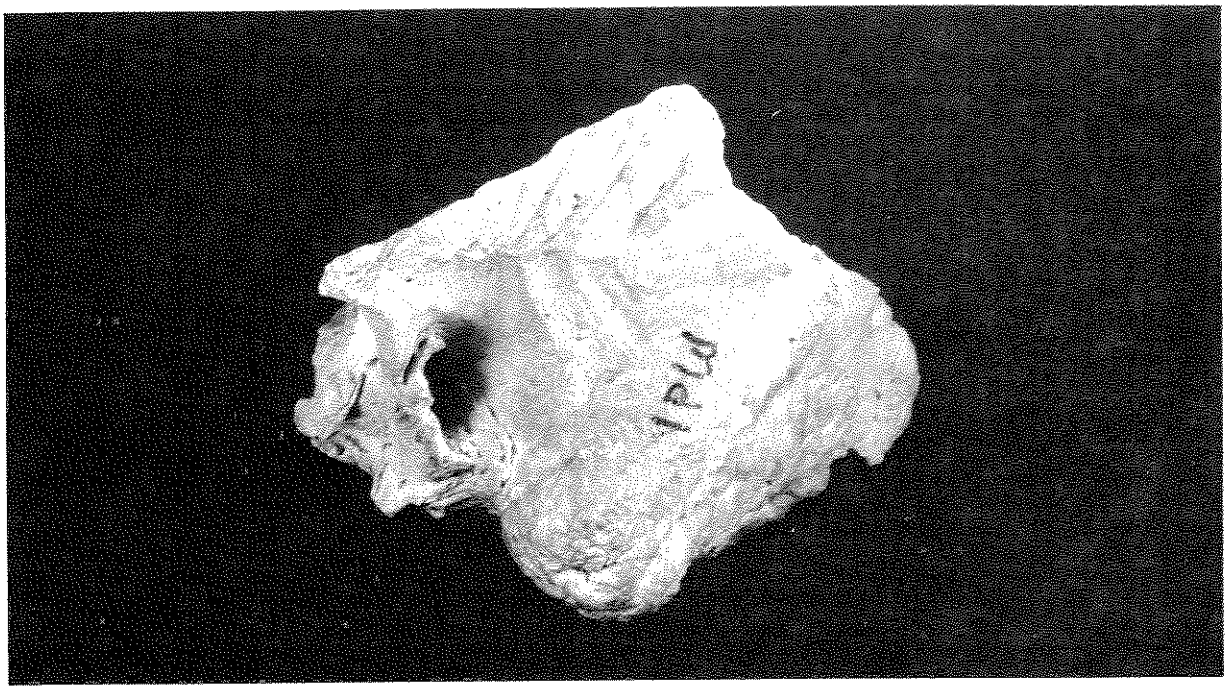

b

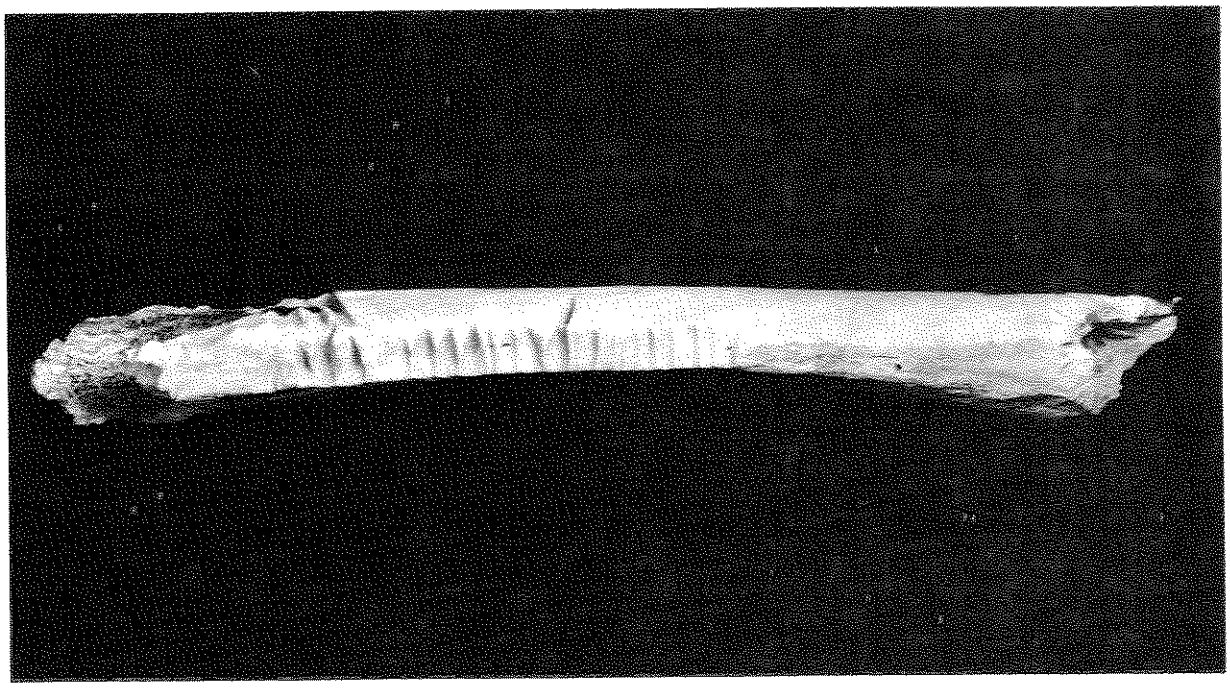

Figure 70a-b. Bones presenting evidence of rodent gnawing. a) Rodent gnaw marks on suprameatal crest, left temporal bone. Specimen from Collins Mound 1, southern Illinois. b) Rodent gnaw marks on linea aspera, right femur. Specimen NPM 18D from Neville Public Museum, Wisconsin. Photos by Diane Houdek.

a



b

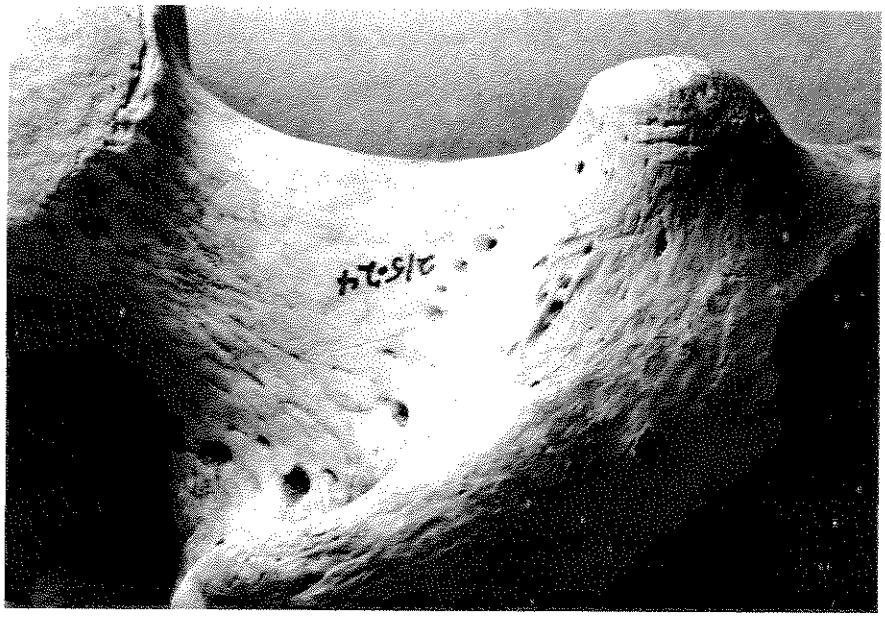

Figure 71a-b. Cutmarks. a) Cutmarks on frontal bone (probably indicative of scalping). Specimen from Burial 72, Norris Farms 36, central Illinois. Previously published as Figure 2 in *American Antiquity* 56(1991):581-603. Courtesy of G.R. Milner and the Society for American Archaeology. b) Cutmarks on posterior surface of greater trochanter and neck of a right femur. Specimen from Burnt Mesa, northwest New Mexico. Courtesy of C.G. Turner II.

Shape Changes

Various perimortem and postmortem factors may cause changes in bone shape. Soil pressure may induce deformation, which is often especially severe in juvenile crania. Even relatively subtle effects may affect metric observations. Similarly, bone burned "green" at temperatures sufficient to induce calcination commonly becomes warped and may shrink.

Dehydration, salt accumulation, heat, scavengers, ground or ice pressure, and trampling are but a few of the factors that may cause bones to break. While these sources of fragmentation may not be of central interest to skeletal biologists, it *is* important to distinguish between these "natural" agents and breakage caused by humans near the time of death. While spiral fractures (see Chapter 10) can result from either human or nonhuman forces, they *are* indicative of premortem or perimortem events. Breaks occurring long after death, in tissues of low collagen content, typically have squared edges at right angles to the bone surface (Figure 72b), while perimortem fractures tend to form oblique angles (Figure 72a).

The use of tools to break bones is another sign of human activity. Hammer-anvil abrasions, for example, produce faint clusters of parallel scratches that occur when a bone slips when impacted by a hammerstone or other heavy implement that crushes it against an anvil (Figure 73). Conchoidal impact dents and projectile impressions are also clear evidence of human activity.

a

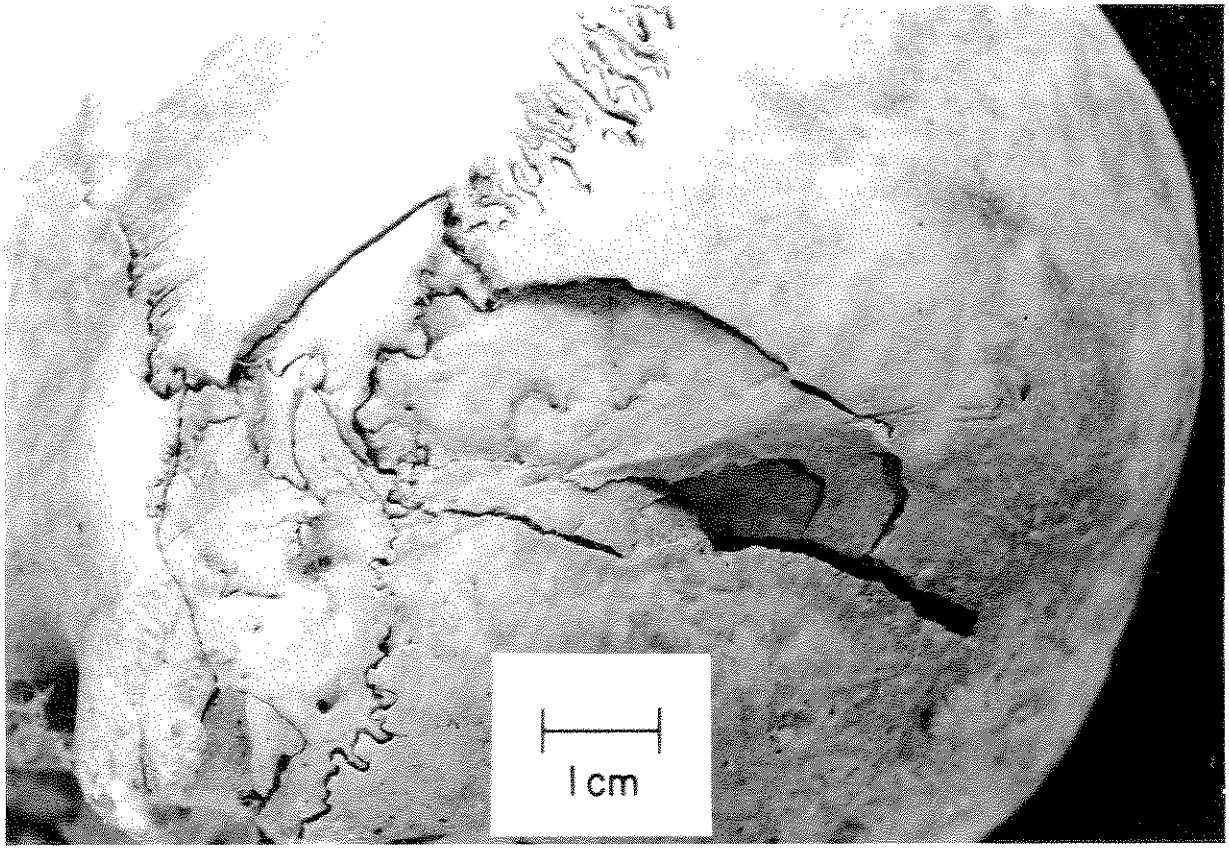

Figure 72a. Perimortem depressed cranial fracture just posterior to asterion on the left side of the occipital bone. Specimen from Burial 239-242, Norris Farms 36, central Illinois. Previously published as Figure 1 in *American Antiquity* 56(1991):581-603. Courtesy of G.R. Milner and the Society for American Archaeology.

b

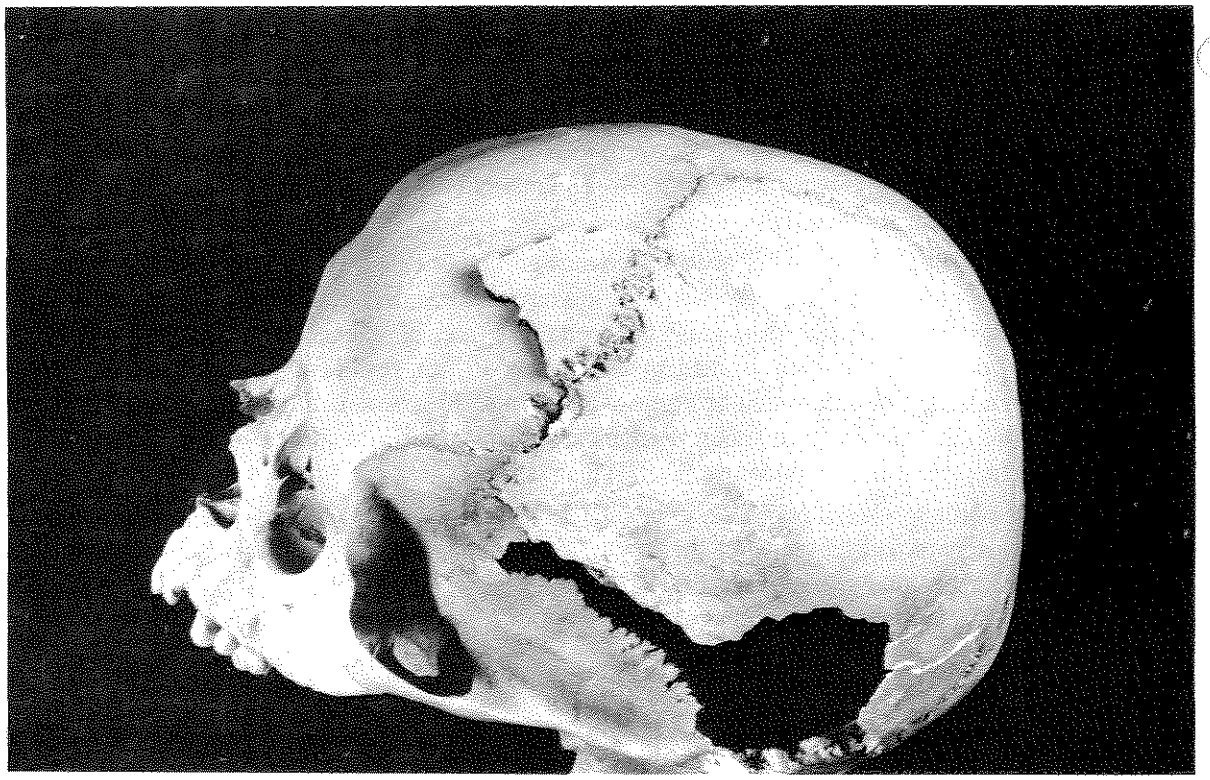

Figure 72b. Postmortem breakage of the left side of the frontal bone adjacent to the coronal suture. Note the sharp edges of the break, and that the broken bone was forced outward from the cranium. Other postmortem breakage of the cranium is visible toward the bottom of the photograph. Specimen from University of Chicago miscellaneous collections. Photograph by Diane Houdek.

Figure 73. Perimortem anvil abrasions (and burning) on a femur fragment. Specimen from Burnt Mesa, northwest New Mexico. Courtesy of C.G. Turner II.

Bones may be defleshed and then retained for a period of time, either as complete elements or in modified forms that may be worn as ornaments or used as tools. Skulls and long bones are most commonly decorated by painting and incising, or are modified into masks, pendants, or other forms of ornamentation. Tools such as awls, flutes and cups have also been fashioned from human bones. Postmortem breakage near the foramen magnum or on both sides of the cranial vault, accompanied by signs of weathering, may be evidence that a skull has been placed on a stake or a skull rack.

RECORDING TAPHONOMIC CHANGES

Recording procedures for taphonomic changes focus upon features which enhance interpretations of human behaviors, such as mortuary rituals and violence. Certain other postmortem changes are also important, since they may limit the accuracy of other observations. Deformation due to soil pressure may, for example, render skeletal measurements imprecise. This concern for measurement accuracy is addressed in Chapters 4, 6, and 7, in which we request that the observer identify measurements that have been estimated from incomplete materials or may have been affected by warping. Observation of sometimes subtle taphonomic features, such as cutmarks, requires careful scrutiny of all bone surfaces, under adequate lighting and magnification. A low-powered stereomicroscope and a 75 watt reflector floodlamp is recommended.

Precision in recording *color* should be maintained through the use of Munsell Soil or Plant Tissue Color Charts. Evidence of stains, burning, or "bleaching" due to exposure to sunlight should include Munsell evaluations both for the taphonomically altered bone and for "normal" bone adjacent to the altered section. (The observer need not record chroma, hue, and value for "normal" remains.) Standard Munsell Soil Charts will include colors appropriate for bones altered by heat and sunlight. Painted surfaces or those modified by contact with metals may require acquisition of charts for green or purple hues, either by adding the Soil Chart for gley soils or by purchase of the Munsell Plant Tissue Color Charts. Munsell Charts, including instructions for use, may be purchased from either of the following sources.

Munsell Color
MacBeth Division, Kollmorgen Instruments Corp.
2441 North Calvert Street
Baltimore, Maryland 21218

Forestry Supplies, Inc.
205 W. Rankin St.
P.O. Box 8397
Jackson, Mississippi 39284-8397
Ph: 1-800-647-5368
Fx :1-800-543-4203

Evidence of *burning* should be coded by color, surface texture, warping, and patterning. As noted in Chapter 2, the most efficient recording strategy is for evidence of burning to be recorded in association with the inventory process through the used of the Burned Bone Recording Form (Attachment 23). Color should be reported as ***T***an, ***B***lack (including dark brown), or ***W***hite (including blue-gray). Heat-altered bone normally presents Munsell chroma of "/0," with the threshold between smoked and calcined remains at a value of approximately "4.5/." If more than one color appears on a single bone, list all appropriate colors and percentage of bone(s) affected. When reporting poorly preserved or highly fragmented materials, weights may be substituted for percentages. A technique for photographically recording color variation in cremated materials is described in Chapter 2.

Surface texture of cremated remains should be reported as ***L*** (longitudinally split); ***T*** (transverse and longitudinal checking); and ***C*** (curved cracks). Indicate presence by recording all appropriate codes. Similarly, report deformed (warped) bones as ***Y*** (Present) or ***N*** (Not Present). Observations of surfaces shielded by articular areas or by dense soft tissues should also be recorded as ***Y*** (Present) or ***N*** (Not Present). Space for further description and interpretation is available on the Burned Bone Recording Form (Attachment 23).

Weathering changes should be coded according to the Behrensmeyer categories listed in Table 5. The most advanced stage for a given element should be recorded on Attachment 24. When evaluating a large series

of specimens, the observer may choose to report weathering for selected elements, e.g, all left tibiae and frontal bones.

Other taphonomic changes should be reported and described by location on drawings of skeletons and/or individual bones. Examples of suitable drawings are presented in Chapter 2 as Attachments 3-10. The location of *discolored areas,* such as green stains due to associated copper items, should be indicated on a skeleton drawing, photographed, and described through the use of Munsell Charts. Similarly, regions impacted by *carnivore or herbivore gnawing* should be indicated on a drawing. Because carnivore gnawing frequently indicates access to remains relatively soon after death, it is also advisable to photograph evidence of carnivore activity. Evidence for *cultural modifications* that have created tools, ornaments, or displays such as skull racks should be carefully documented through drawings, photographs, and descriptions. All bone fragments should be examined closely for evidence of *polish.*

Premortem and perimortem fractures, wounds, and abrasions are recorded in Chapter 10, Paleopathology. The documentation of *cutmarks* requires meticulous examination of each bone, with appropriate lighting and magnification. The location of cuts or cut clusters should be indicated on bone drawings, and supplemented by descriptions which include estimates of cut numbers, average (or range) of cut length(s), and cut outline. An effective technique for recording cut outline involves creating replicas of representative marks. Replicas can be made according to the following technique:

> Clean the modified area with water, or with an appropriate solvent if the bone has been treated with a preservative. Cover the region with a 3-4 mm thick layer of a silicone-based, dental impression material. After the impression material has set, draw an arrow on the back of the mold to indicate its orientation. An epoxy positive can be made from the mold for long term curation. Be certain to mark the cast to indicate its orientation relative to the original bone. The silicon impression provides a negative of the tool mark that can be sectioned and mounted on a glass microscope slide for analysis of shape.

The Taphonomic Changes Recording Form (Attachment 24) is designed for recording evidence of weathering, discoloration, polishing, cutmarks, rodent or carnivore gnawing, and artifact production. Each entry should begin by specifying the type of alteration, the affected bone, the location of the modification on the bone, and the number of photographs and drawings. Space is then allocated for other information, such as number of cutmarks and the appropriate Munsell designation for metal-staining. The following should be recorded for each type of taphonomic change.

> ***Weathering:*** (1) Bone identification, (2) photographs of representative samples, (3) degree of weathering (see Table 5).
>
> ***Discoloration:*** (1) Bone identification, (2) location (append drawing and photograph), (3) color of discolored bone and "normal" adjacent bone (use Munsell Charts).
>
> ***Polish:*** (1) Bone identification, (2) location (append drawing and photograph).
>
> ***Cutmarks:*** (1) Bone identification, (2) location (append drawing and photograph), (3) number of cuts, (4) average cut length, (5) range of cut lengths, (6) sketch and cast (optional but recommended) of representative cut(s).
>
> ***Evidence of Rodent and Carnivore Gnawing:*** (1) Bone identification, (2) location (append drawing and photograph), (3) number of paired grooves or incisions. Evidence of rodent and carnivore gnawing should be recorded separately.
>
> ***Other Forms of Cultural Modification Including the Creation of Artifacts:*** (1) Bone identification, (2) shape (append drawing and photograph).

Additional space on the form should be used to further describe the entry. Multiple types of taphonomic change in the same skeleton can be entered on the same recording form.

CHAPTER 10

PALEOPATHOLOGY

One of the most challenging aspects of skeletal biological study is the investigation of ancient health and disease. Although not all illnesses leave skeletal signatures, the study of abnormal bone can provide important information concerning an individual's health status. When a representative population sample is available, analysis of skeletal pathology can provide estimates of *community* health and thus facilitate investigations of disease patterning in comparative perspective. Similarly, information concerning the origin and evolution of certain diseases is uniquely available through the investigation of ancient remains.

During the last quarter-century, anthropologists have focused upon the use of population-based data to measure health relative to other cultural and environmental factors including the development of agriculture (Cohen and Armelagos 1984), occupational stresses (Bridges 1989a, 1989b, 1991; Kennedy 1989, Merbs 1983), the consequences of the Columbian encounter upon Native Americans (Larsen 1984, 1990; Verano and Ubelaker 1992; Walker et al. 1989), and the impact of emancipation upon African-Americans (Rose 1985). Evidence of healed and perimortem trauma has facilitated interpretations of alliance formation, raiding, and warfare among ancient and modern groups. Anthropologists also use paleopathology as a vehicle for investigating the history of diseases such as tuberculosis, the treponematoses (yaws, endemic syphilis, and venereal syphilis), leprosy, and rheumatoid arthritis (Baker and Armelagos 1988; Buikstra 1981; Cook 1976; Grmek 1989; Hackett 1967; Hudson 1965; Møller-Christensen 1967; Ortner and Putschar 1985; Powell 1988; Rothschild et al. 1988, 1990; Steinbock 1976).

The study of specific diseases in human skeletal samples places greater emphasis upon differential diagnosis than does the comparative analysis of population health. To develop general, population-based characterizations of health and disease, all instances of bone inflammation, for example, may be considered together, with relatively minor emphasis upon causation. Other nonspecific forms of nutritional and/or disease stress, such as the linear enamel hypoplasias discussed in Chapter 5, and rates of stature attainment available from the long bone measurements described in Chapter 7 are also used in this form of study. By contrast, differential diagnoses of specific diseases require precise details of abnormal bone lesions, compared and contrasted with a suite of alternatives defined through modern clinical experience. Data collection from skeletal remains in danger of reburial must fulfill the requirements of both approaches.

The goal of the following data collection protocol is not to lead the observer to a specific disease diagnosis, but rather to encourage data collection sufficient for future scholarship concerning both the origins and evolution of specific conditions and comparative studies of population health. Several useful texts that focus upon paleopathology have facilitated this difficult task: Ortner and Putschar (1985); Steinbock (1976); and Mann and Murphy (1990). This work has also benefited greatly from a series of workshops organized by Bruce Ragsdale and Donald Ortner as part of the annual meeting program for the Paleopathology Association. The workshop in 1992 emphasized issues of standard terminology, a matter of central concern. The following protocol draws most heavily upon the content of these workshops and the Ortner and Putschar (1985)

volume. Recent historical treatments of American paleopathology may be found in Buikstra and Cook (1980) and Ubelaker (1982).

THE IMPORTANCE OF STANDARD TERMINOLOGY, STANDARDLY APPLIED

Ortner and Putschar (1985: 36) list three essential elements for recording skeletal pathology: "(1) an unambiguous terminology; (2) precise identification of the locations and distribution of abnormal bone; and (3) a descriptive summary of the morphology of abnormal bone." Clear, consistently applied terminology is considered an essential, fundamental requirement. Those of us who have attempted to examine disease patterning using published accounts quickly realize that investigations may easily be compromised by the use of non-standard terminology. Even simple and seemingly obvious descriptors such as "narrow," "large," and "coarse" are applied differently by different researchers. To counter the use of ambiguous terms and to define useful terms precisely, we include a glossary of some adjectives and nouns commonly used in contemporary studies of paleopathology (see Appendix I).

Observational Strategies

A critical step in recording pathological conditions is the recognition of true bone abnormalities, as opposed to the normal range of variation in healthy individuals. The recorder must, therefore, develop an appreciation for the morphology of normal bone—both immature and mature—and learn to recognize artifacts of postmortem alterations (see Chapter 9).

Features commonly misinterpreted as pathological include metaphyseal changes in growing individuals, Pacchionian depressions, and vessel impressions. As illustrated in Figure 74, it is normal for juvenile metaphyses to present porosity and evidence of remodeling, especially during periods of rapid growth. Although extreme metaphyseal porosity and exposure of trabecular bone is considered pathological, most examples encountered in skeletons fall within the "normal" range. Figure 75, the internal aspect of a cranial vault from an elderly adult, shows numerous circumscribed depressions termed "Pacchionian" or "Arachnoid" depressions, which are normal anatomical features. Such irregularities are formed as the internal table of the cranial vault develops to conform to related structures of the brain and its surrounding tissues. Figure 76a illustrates a bilateral linear depression on the frontal bone which reflects the path taken by a superficial vessel, a normal variation rather than a pathological condition. Similarly, the foramen for the basivertebral vein (Figure 76b), on the dorsal aspect of the vertebral body or centrum, should not be confused with abnormal conditions. Sequelae of pathological change are also frequently overinterpreted. For example, linear grooves frequently observed on raised areas of long bone surfaces are vessel impressions around which pathological bone has remodeled and are commonly misinterpreted as cutmarks or evidence of postmortem change (Figure 77). Other examples of postmortem, postdepositional changes such as rodent gnawing and root impressions are illustrated in Chapter 9.

Each pathological condition should be photographed and radiographed (see Chapter 2). When illustrating certain forms of abnormality, e.g., unusual growth patterns in juvenile long bones, it may prove useful to photograph the abnormal example with a normal element from an individual of roughly the same age and sex (if known). In addition to radiographs and photographs, we also recommend including illustrations of the areas affected by each pathological condition. A series of blank drawings of bones provided in Chapter 2 (Attachments 3-10) may be copied to serve as a basis for such illustrations. When supplementing the standard coding forms in this manner, the observer should provide a key which conforms to the standard terminology recommended here. Figure 78 is an example of a supplemental sketch. (Computerized images will soon replace the coding sheets. Until that time, we recommend the use of the blank drawings presented in Chapter 2.)

The pathology coding procedure described here is closely integrated with the inventory process. The observer can easily identify and record forms of pathology as the inventory proceeds. Alternatively, the pathology coding forms may be completed later. To develop the most efficient recording strategy that will also minimize

a

b

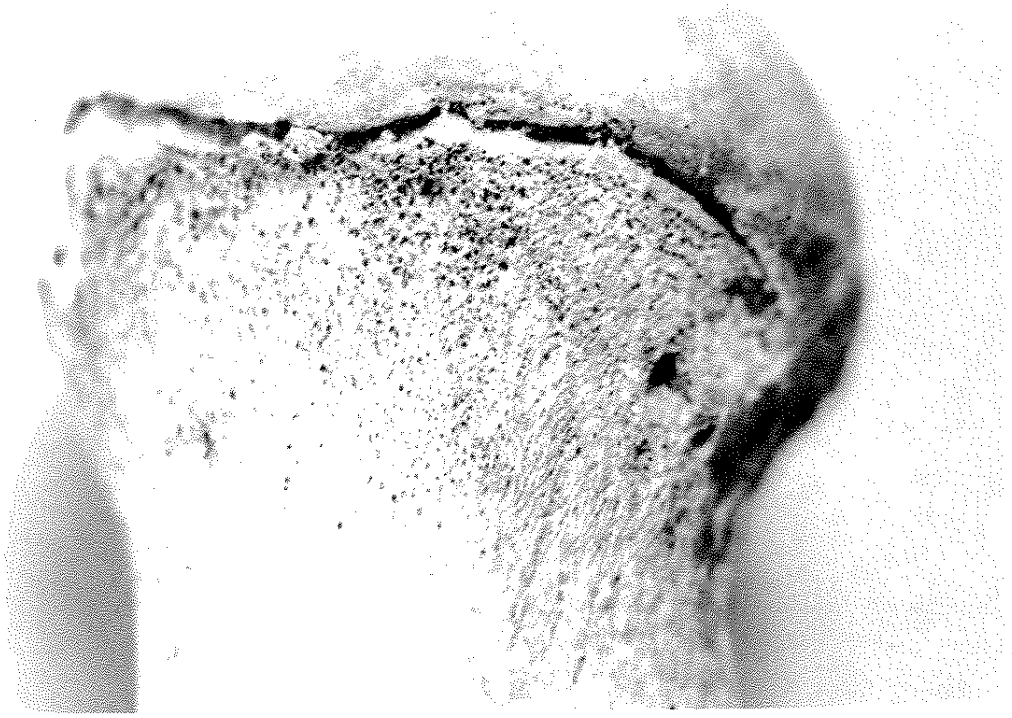

Figure 74. Impact of "normal" modeling due to growth. a) Porosity associated with normal remodeling in the metaphyseal area of an immature long bone. b) Porosity associated with normal remodeling in the femoral neck area. Photos by D.H. Ubelaker.

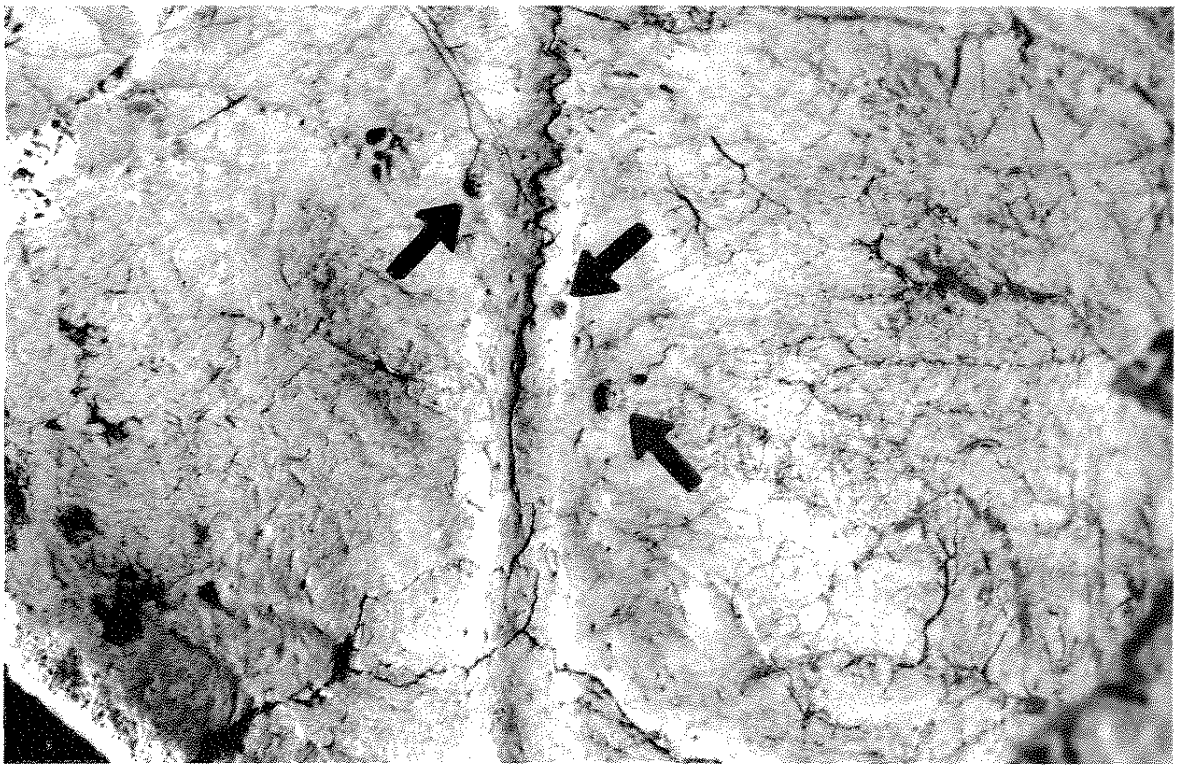

Figure 75. Pacchionian depressions (arrows) on internal surface of parietal bones, in the region of the superior sagittal sulcus. Specimen Ld °1-76. Photo by Diane Houdek.

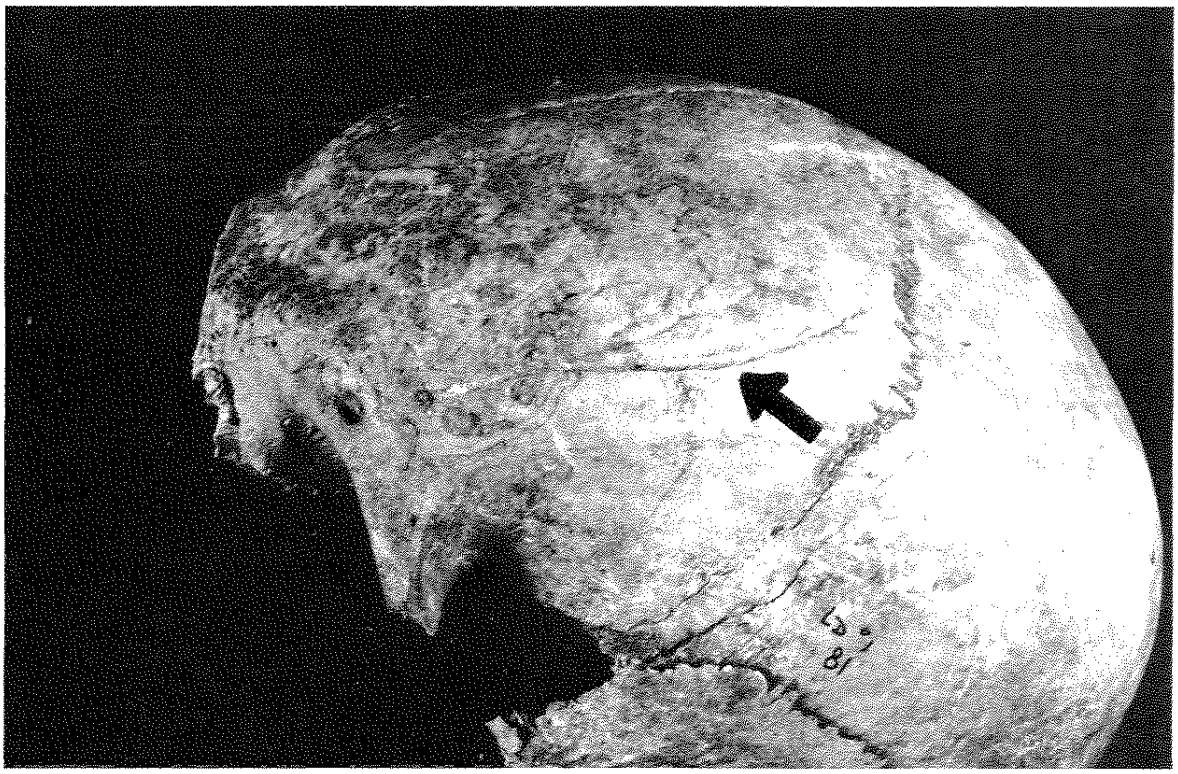

Figure 76a. "Normal" vessel tracks on frontal bone, extending up from the supraorbital foramen and roughly paralleling the temporal line, left lateral view. Specimen Ld °1-81. Photo by Diane Houdek.

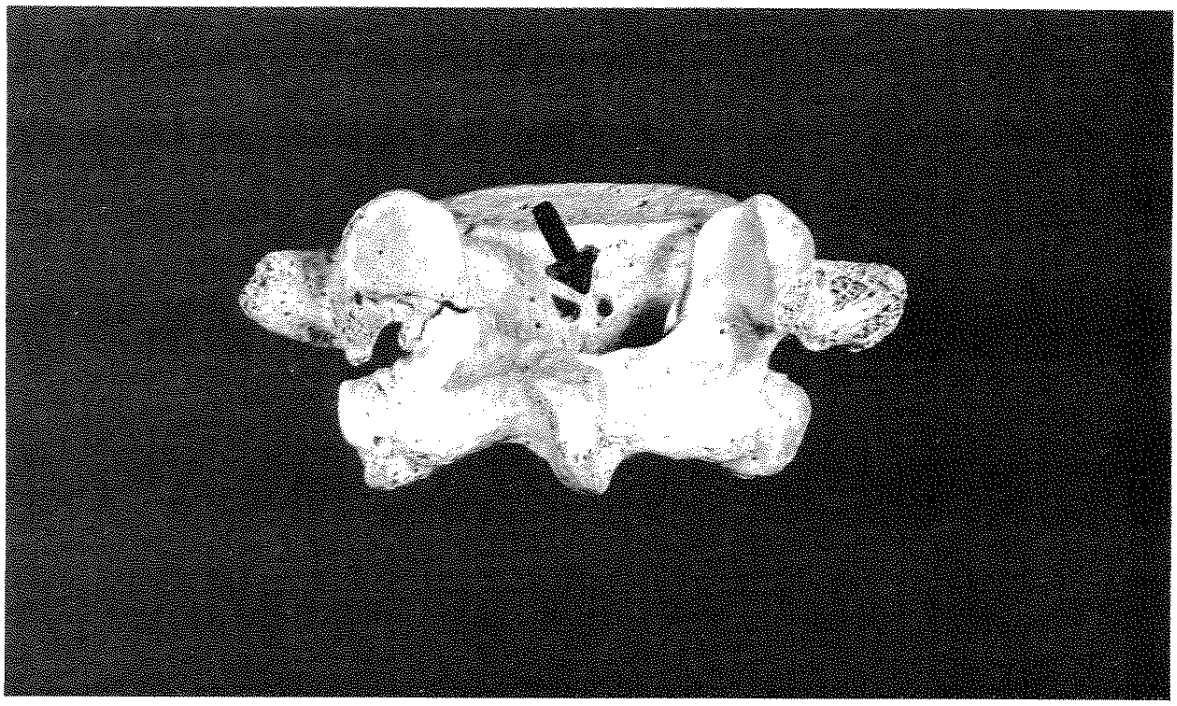

Figure 76b. Foramina for basivertebral veins (arrow) on L5, posterior view. Specimen 51 from Japanese collections, University of Chicago. Photo by Diane Houdek.

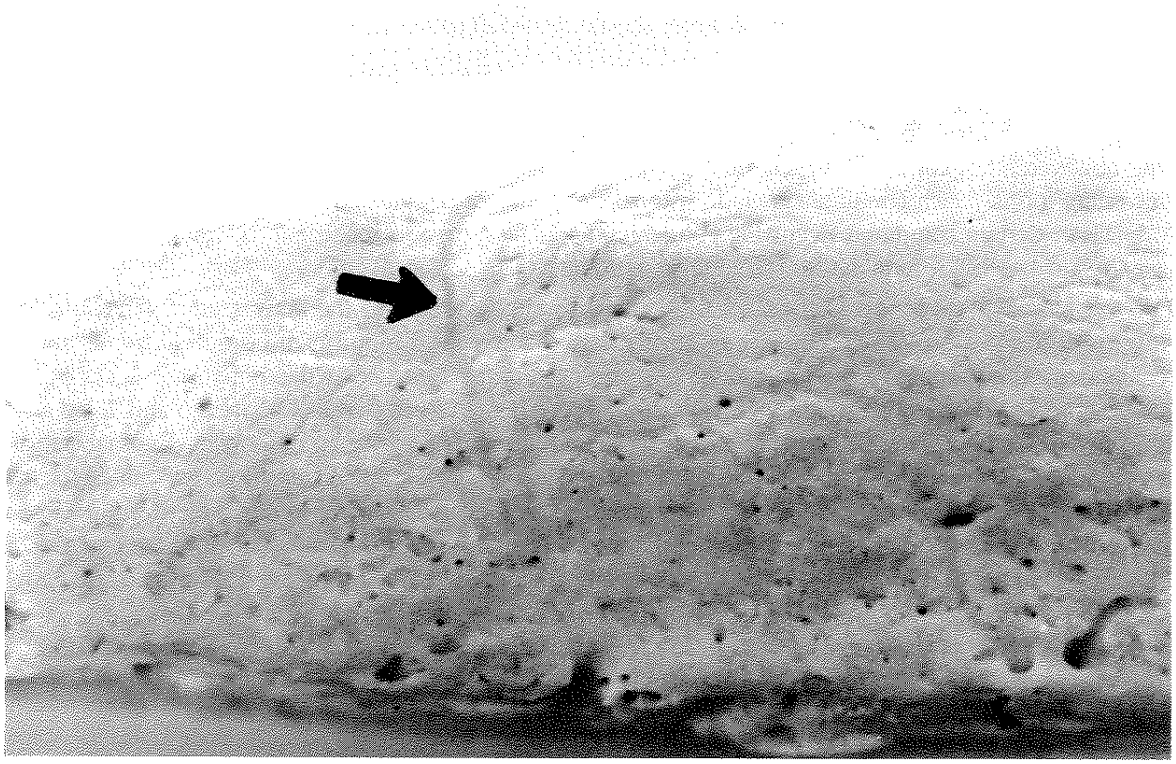

Figure 77. Detail of vessel tracks associated with well remodeled periostitis on thickened long bone cortex of 46-year-old male of European ancestry from the Huntington Collection, Smithsonian Institution, NMNH 320316. Photo by D.H. Ubelaker.

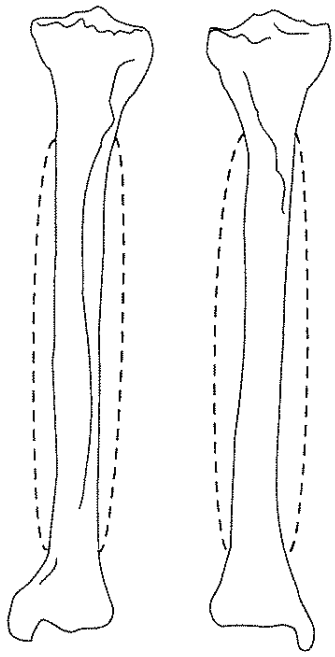

Figure 78. Sample sketch of abnormal bone remodeling of the left tibia. Fusiform expansion of the entire diaphysis is illustrated from anterior and posterior views. Pathology codes 1.3.3, 1.4.2.

inter- and intra-observer error, a single observer should record all pathology or specific forms of pathology over a short period of time.

Most of the information requested concerning pathology requires the observer to recognize the presence of abnormal bone loss or bone formation and report these processes in a standardized format. There are, however, a few conditions which are especially informative and therefore require their own section on the recording forms. Such conditions include osteoarthritis, fractures, and porotic hyperostosis (including cribra orbitalia). Certain commonly occurring congenital anomalies are also recorded, for example, spina bifida is reported in a special section devoted to vertebral pathology.

Although most aspects of pathological change will key directly to the bony segments recorded in the inventory form, there are certain observations that require consideration of complete bones and bone complexes. Observations of abnormal *shape* and *size* fall into this category. While dimensional data illustrating unusual size or proportions will be available through metric data recorded in Chapters 6 and 7, we ask that evidence for hydrocephaly, acromegaly, dwarfism, and localized deformities be described. Unusual cranial and long bone shapes should also be reported. Recommended long bone shape observations are limited to changes that may reflect nutritional deficiencies, healed fractures, or congenital anomalies. Premature suture closure or craniosynostosis (craniostenosis), a condition that frequently leads to unusual dimensions or asymmetries of the skull, is recorded for the major sutures of the cranium. Abnormal spinal curvature should also be reported.

DATA COLLECTION PROTOCOL

For purposes of data collection, observations of pathological bone conditions have been formally grouped into nine categories: (1) Abnormalities of Shape; (2) Abnormalities of Size; (3) Bone Loss; (4) Abnormal Bone Formation; (5) Fractures and Dislocations; (6) Porotic Hyperostosis/Cribra Orbitalia; (7) Vertebral Pathology; (8) Arthritis; and (9) Miscellaneous Conditions.

Each of the pathology recording sequences requires the initial identification of the affected unit. Three digit codes should be entered from the Bone Key (Table 6). An affected frontal bone, for example, would be coded 2.0.1, and when coding for spina bifida, the sacrum would be identified as 3.4.0. Several entries require codes for side, bone segment, and aspect.

When identifying pathological bone sections, the observer should record the full affected unit. Thus, while arthritis always reflects changes at articular surfaces (1) or (5), instances of abnormal bone loss or bone proliferation may, for example, be localized within the central portion of a diaphysis (3), may include the proximal 2/3 of the diaphysis (6), or may extend across the full shaft (8). Observers should not include unaffected sections in their observations by, for example, coding for the full diaphysis when reporting a condition localized within the proximal metaphyseal area.

Each observation, as listed on the Skeletal Pathology Code Key (Table 6) is uniquely identified by the second and third digits. For example, in recording sclerotic, lamellar reaction on the periosteal surface of the full left tibia diaphysis, the coding sequence would be: 4 (Category: abnormal bone formation); **4**.3.3 (Bone: tibia); 2 (Side: left); 8 (Section: total diaphysis); **4**.1.2 (Observation: sclerotic reaction). If both sides were affected in an identical manner, "3" would replace "2".

1.0.0 Abnormality of Shape

The observer may identify either one or two bones plus side and then provide two observations of pathology (Attachment 25). Given that abnormalities of shape frequently involve more than one bone or bone pair, two bone pairs may be coded within each. When coding information concerning abnormalities of shape within the spinal column, either kyphosis or scoliosis, the observer should use the first bone entry to code the superior vertebra of the affected sequence and the second entry to code for the most inferior unit. The presence of multiple opportunities to enter descriptive information permits the observer to record the type of spinal abnormality, the form, and the presence of ankylosis, as **1**.7.1/8.1/9.2 as angular kyphosis associated with ankylosis. The following discussion focuses upon identifying specific shape abnormalities.

Long Bones

In this category overall shape differences for long bones are recorded on Attachment 25. *Bowing* (**1**.1.0) refers to smooth, gradual curvature, as opposed to *angulated* (**1**.2.0) changes that are commonly the results of (healed) fractures (Figure 79). Bowing frequently results from deficiency diseases, such as rickets or scurvy, and is basically a response to the effects of gravity in structurally unsound bone. Bowing and angulation can occur in both mature and immature individuals.

Some differences in shape tend to occur in growing individuals, while others are typical of adults. As illustrated in Figure 80, during maturation healthy immature bones grow through resorption of the external cortex near the metaphysis and deposition of tissue endosteally. If the external resorption process fails, the overall appearance will be one of a constricted central portion of the diaphysis with unusually wide proximal and distal ends. *Flaring metaphyses* (**1**.3.1) are thus developmental disorders which can either begin near the center of bone or develop distally. The proportion of the bone presenting this form of abnormal remodeling provides information about the age of onset and duration of the condition (Figure 81a and b).

Alternatively, both adults and children may present *uniformly wide* (**1**.3.2) tubular long bone outlines, commonly due to the presence of a chronic infectious process. Overall abnormal widths may be associated with bowing or with an otherwise normal outline. In adults, infectious disease (frequently in association with sequential microtrauma) commonly produces *fusiform* or spindle-shaped (**1**.3.3) expansion of diaphyses, which may encircle the bone or may predominate on one surface, such as the antero-medial aspect of the tibia (Figure 82). The presence of other unusual shapes should be recorded as **1**.3.4 and should be described in narrative form. The observer's degree of certainty in identifying the abnormal shape should be coded as either **1**.4.1 (very slight or barely discernible) or **1**.4.2 (clearly present).

Table 6
Skeletal Pathology Code Key

Side

1. Right
2. Left
3. Both Sides

Section

1. Proximal Epiphysis/ Articular Surface
2. Proximal 1/3 of Diaphysis
3. Middle 1/3 of Diaphysis
4. Distal 1/3 of Diaphysis
5. Distal Epiphysis/ Articular Surface
6. Proximal 2/3 Diaphysis
7. Distal 2/3 Diaphysis
8. Total Diaphysis
9. Both Prox. and Distal Articular Surfaces

Aspect

1. Superior Surface
2. Inferior Surface
3. Both Superior and Inferior Surfaces
4. Medial
5. Lateral
6. Both Medial and Lateral Surfaces
7. Posterior (Dorsal)
8. Anterior (Ventral)
9. Circumferential

Bone

2.0.0 Skull
- 2.0.1 Frontal
- 2.0.2 Parietal
- 2.0.3 Occipital
- 2.0.4 Temporal
- 2.0.5 Zygomatic
- 2.0.6 Maxilla
- 2.0.7 Mandible
- 2.0.8 Palatine
- 2.0.9 Sphenoid
- 2.1.0 Nasal
- 2.1.1 Hyoid

3.0.0 Vertebrae
- 3.1.0 Cervical vertebrae
  - 3.1.1 CI (atlas)
  - 3.1.2 C2 (axis)
  - 3.1.3 C3-6
  - 3.1.4 C7
- 3.2.0 Thoracic vertebrae
  - 3.2.1 T1-9
  - 3.2.2 T10
  - 3.2.3 T11
  - 3.2.4 T12
- 3.3.0 Lumbar vertebrae
  - 3.3.1 L1
  - 3.3.2 L2
  - 3.3.3 L3
  - 3.3.4 L4
  - 3.3.5 L5
- 3.4.0 Sacrum
- 3.5.0 Coccyx
- 3.6.0 Ribs
  - 3.6.1 First rib
  - 3.6.2 Second Rib
  - 3.6.3 Ribs 3-10
  - 3.6.4 Rib11
  - 3.6.5 Rib 12
- 3.7.0 Sternum
  - 3.7.1 Manubrium
  - 3.7.2 Body (gladiolus)

4.0.1 Clavicle
- 4.0.2 Scapula
- 4.0.3 Glenoid fossa
- 4.1.0 Upper limb
  - 4.1.1 Humerus
  - 4.1.2 Radius
  - 4.1.3 Ulna
  - 4.1.4 Carpals
  - 4.1.5 Metacarpals
  - 4.1.6 Hand phalanges
- 4.2.0 Os coxae
  - 4.2.1 Ilium
  - 4.2.2 Ischium
  - 4.2.3 Pubis
  - 4.2.4 Acetabulum
- 4.3.0 Lower Limb
  - 4.3.1 Femur
  - 4.3.2 Patella
  - 4.3.3 Tibia
  - 4.3.4 Fibula
  - 4.3.5 Tarsals
  - 4.3.6 Metatarsals
  - 4.3.7 Foot phalanges

Pathology

1.0.0 General Abnormality of SHAPE: LONG BONE
- 1.1.0 Bowed (abnormal curvature)
- 1.2.0 Angulated
- 1.3.0 External Outline Altered
  - 1.3.1 Flaring Metaphyses
  - 1.3.2 Uniformly abnormally wide
  - 1.3.3 Fusiform (spindle) shape
  - 1.3.4 Other (see narrative)
- 1.4.0 Degree of Shape Abnormality
  - 1.4.1 Barely discernible
  - 1.4.2 Clearly discernible

1.0.0 Abnormality of SHAPE: SKULL
- 1.5.0 Craniosynostosis, suture
  - 1.5.1 Metopic
  - 1.5.2 Coronal
  - 1.5.3 Sagittal
  - 1.5.4 Lambdoid
  - 1.5.5 Other (see narrative)
- 1.6.0 Craniosynostosis, completeness
  - 1.6.1 Partial
  - 1.6.2 Complete

1.0.0 Abnormality of SHAPE: SPINAL COLUMN
- 1.7.0 Type
  - 1.7.1 Kyphosis (ant.-post)
  - 1.7.2 Scoliosis, left
  - 1.7.3 Scoliosis, right
- 1.8.0 Form
  - 1.8.1 Angular
  - 1.8.2 Gradual change in body height
- 1.9.0 Ankylosis
  - 1.9.1 Absent
  - 1.9.2 Present

2.0.0 Abnormality of SIZE
- 2.1.0 Hydrocephaly present
- 2.2.0 Size Reduction
  - 2.2.1 Achondroplastic dwarfism
  - 2.2.2 Proportional dwarfism
  - 2.2.3 Bone (or region) specific reduction
- 2.3.0 Acromegaly

3.0.0 Abnormal BONE LOSS
- 3.1.0 Location
  - 3.1.1 Periosteal or subchondral surface, external table
  - 3.1.2 Cortex, trabeculae, or diploë
  - 3.1.3 Endosteal surface, internal table
  - 3.1.4 Mixed: 3.1.1 + 3.1.2
  - 3.1.5 Mixed: 3.1.2 + 3.1.3
  - 3.1.6 Mixed: all three locations involved
- 3.2.0 Extent of involvement: % of unit affected
  - 3.2.1 <1/3
  - 3.2.2 1/3-2/3
  - 3.2.3 >2/3
- 3.3.0 Focal Bone Loss (well organized): Number of foci
  - 3.3.1 Unifocal
  - 3.3.2 Multifocal: 2 foci
  - 3.3.3 Multifocal: 3-5 foci
  - 3.3.4 Multifocal: 6-10 foci
  - 3.3.5 Multifocal: 10+ foci
- 3.4.0 Focal Bone Loss: Size
  - 3.4.1 <1 cm
  - 3.4.2 1-5 cm
  - 3.4.3 >5
  - 3.4.4 Mixed 3.4.1 + 3.4.2
  - 3.4.5 Mixed 3.4.1 +3.4.3
  - 3.4.6 Mixed 3.4.2 + 3.4.3
  - 3.4.7 Mixed 3.4.1 + 3.4.2 + 3.4.3
- 3.5.0 Focal Bone Loss: Bony Response
  - 3.5.1 Circumscription, sclerotic reaction
  - 3.5.2 Boundaries well defined, but no sclerosis
  - 3.5.3 Margins not sharply defined
  - 3.5.4 Mixed 3.5.1 +3.5.2
  - 3.5.5 Mixed 3.5.2 + 3.5.3
  - 3.5.6 Mixed 3.5.1 + 3.5.2 + 3.5.3
  - 3.5.7 Mixed 3.5.1 + 3.5.3
- 3.6.0 Diffuse (osteoporotic; irregular and poorly organized)
  - 3.6.1 With cortical thinning associated
  - 3.6.2 Without cortical thinning associated
- 3.7.0 Structural Collapse Associated

Table 6 , continued

4.0.0 Abnormal BONE FORMATION
- 4.1.0 Periosteal Surface: Lamellar Reaction
  - 4.1.1 Reactive woven bone (fiberbone) present
  - 4.1.2 Sclerotic reaction
  - 4.1.3 Both woven and sclerotic reaction evident
- 4.2.0 Cortex Intact, spicules perpendicular to surface
  - 4.2.1 Sunburst effect
  - 4.2.2 Cauliflower appearance
- 4.3.0 Cortex Perforated
  - 4.3.1 By expansive, shell-type reaction
  - 4.3.2 Due to cloacae (sinus tracks) - from medullary cavity
- 4.4.0 Endosteal Surface
  - 4.4.1 Lamellae visible
  - 4.4.2 Medullary cavity narrowed with no visible lamellae
- 4.5.0 Abnormal Matrix
  - 4.5.1 Deposition of woven, immature bone
  - 4.5.2 Cancellous expansion
  - 4.5.3 Trabecular coarsening
- 4.6.0 Extent of Involvement; % of Unit Affected
  - 4.6.1 <1/3
  - 4.6.2 1/3-2/3
  - 4.6.3 >2/3
- 4.7.0 Ossified connective tissue
  - 4.7.1 Myositis ossificans (omit if with fracture, see 5.49)
  - 4.7.2 Enthesopathy
  - 4.7.3 Joint fusion
- 4.8.0 Specific structures
  - 4.8.1 Button osteoma(s)
  - 4.8.2 Stellate scars
  - 4.8.3 Sequestrum
  - 4.8.4 Involucrum
  - 4.8.5 Both 4.8.3 and 4.8.4

5.0.0 FRACTURES AND DISLOCATIONS
- 5.1.0 Type of fracture (indicate all)
  - 5.1.1 Complete
  - 5.1.2 Partial (greenstick)
  - 5.1.3 Simple
  - 5.1.4 Comminuted
  - 5.1.5 Spiral
  - 5.1.6 Compression
  - 5.1.7 Depressed, outer table only
  - 5.1.8 Depressed, outer and inner tables
  - 5.1.9 Pathological
- 5.2.0 Shape characteristics (indicate all)
  - 5.2.1 Blunt round
  - 5.2.2 Blunt oval
  - 5.2.3 Edged (bladed)
  - 5.2.4 Projectile entry
  - 5.2.5 Projectile exit
  - 5.2.6 Projectile embedded
  - 5.2.7 Radiating
  - 5.2.8 Amputation
- 5.3.0 Perimortem fracture (no observable remodeling)
  - 5.3.1 Clearly the result of perimortem trauma
  - 5.3.2 Ambiguous, possibly postmortem trauma
- 5.4.0 Fracture sequelae (indicate all)
  - 5.4.1 Callus formation, woven bone only
  - 5.4.2 Callus formation; sclerotic reaction
  - 5.4.3 Healing/obliteration of cranial fracture
  - 5.4.4 Nonunion
  - 5.4.5 Tissue necrosis
  - 5.4.6 Infection
  - 5.4.7 Traumatic arthritis
  - 5.4.8 Joint fusion
  - 5.4.9 Traumatic myositis ossificans
- 5.5.0 Type of dislocation
  - 5.5.1 Traumatic
  - 5.5.2 Congenital
  - 5.5.3 Cause ambiguous

6.0.0 POROTIC HYPEROSTOSIS (frontal, parietal, occipital bones)
- 6.1.0 Degree
  - 6.1.1 Barely discernible
  - 6.1.2 Porosity only
  - 6.1.3 Porosity with coalescence of foramina, no thickening
  - 6.1.4 Coalescing foramina with increased thickness
- 6.2.0 Location
  - 6.2.1 Orbits
  - 6.2.2 Adjacent to sutures
  - 6.2.3 Near bosses or within squamous portion of occipital
  - 6.2.4 Both adjacent to suture and within orbits
  - 6.2.5 Both adjacent to suture and near bosses/in squamous
- 6.3.0 Activity
  - 6.3.1 Active at time of death
  - 6.3.2 Healed
  - 6.3.3 Mixed reaction: evidence of healing + active lesions

7.0.0 VERTEBRAL PATHOLOGY
- 7.1.0 Schmorl's nodes
  - 7.1.1 Barely discernible
  - 7.1.2 Moderate expression
  - 7.1.3 Marked expression
- 7.2.0 Osteophytes, degree (indicate maximum expression)
  - 7.2.1 Barely discernible
  - 7.2.2 Elevated ring
  - 7.2.3 Curved spicules
  - 7.2.4 Fusion present
- 7.3.0 Syndesmo/Enthesophytes, degree (maximum expression)
  - 7.3.1 Barely discernible
  - 7.3.2 Elevated ring
  - 7.3.3 Curved spicules
  - 7.3.4 Fusion present
- 7.4.0 Spina bifida
  - 7.4.1 Partial
  - 7.4.2 Complete
- 7.5.0 Spondylolysis
  - 7.5.1 Complete fracture, no healing
  - 7.5.2 Healing evident
  - 7.5.3 Spondylolysthesis

8.0.0 ARTHRITIS
- 8.1.0 Lipping, degree
  - 8.1.1 Barely discernible
  - 8.1.2 Sharp ridge, sometime curled with spicules
  - 8.1.3 Extensive spicule formation
  - 8.1.4 Ankylosis
- 8.2.0 Lipping, extent of circumference affected
  - 8.2.1 <1/3
  - 8.2.2 1/3-2/3
  - 8.2.3 > 2/3
- 8.3.0 Surface porosity, degree
  - 8.3.1 Pinpoint
  - 8.3.2 Coalesced
  - 8.3.3 Both pinpoint and coalesced
- 8.4.0 Porosity, extent of surface affected
  - 8.4.1 <1/3
  - 8.4.2 1/3-2/3
  - 8.4.3 >2/3
- 8.5.0 Eburnation, degree
  - 8.5.1 Barely discernible
  - 8.5.2 Polish only
  - 8.5.3 Polish with groove(s)
- 8.6.0 Eburnation, extent of surface affected
  - 8.6.1 <1/3
  - 8.6.2 1/3-2/3
  - 8.6.3 >2/3
- 8.7.0 Surface osteophytes, degree
  - 8.7.1 Barely discernible
  - 8.7.2 Clearly present
- 8.8.0 Periarticular resorptive foci, degree
  - 8.8.1 Barely discernible
  - 8.8.2 Clearly present
- 8.9.0 Periarticular resorptive foci extent of circumference
  - 8.9.1 <1/3
  - 8.9.2 1/3-2/3
  - 8.9.3 >2/3

Any clearly identified shape change should be coded **1**.4.2. Further gradations of degree should be evident in radiographs and photographs and need not encumber the coding form (Such distinctions, commonly coded as "mild," "moderate" and "extreme," are notoriously subjective and difficult to standardize across observers.).

Skull

Craniosynostosis (craniostenosis, premature suture closure) can change the shape of the skull markedly, depending upon the sutures involved and the age of onset (Ortner and Putschar 1985: 352). Specific types of craniosynostosis include scaphocephaly (premature closure of the sagittal suture); trigonocephaly (early closure of the metopic suture); and plagiocephaly (partial closure of the coronal or lambdoid suture, leading to asymmetry). On Attachment 25, premature suture closure is coded for the metopic (**1**.5.1.); coronal (**1**.5.2), sagittal (**1**.5.3); and lambdoid (**1**.5.4) sutures. Other examples of craniosynostosis should be discussed and their presence recorded as **1**.5.5. The presence of plagiocephaly due to asymmetrical closure of the lambdoid or coronal suture should be indicated as either a "1" or "2" in the column coding for "side," while a "3" should be entered for symmetrical closure. Craniosynostosis arrested (*incomplete*) at the time of death should be indicated as a second observation, **1**.6.1, while *complete* fusion is entered as **1**.6.2.

Spinal Column

The normal spinal curves may deviate either through abnormal anterior or lateral curvature. If more than a single unit is involved in abnormal curvature, the superior vertebra should be indicated in the first space available for bone identification and the most inferior abnormal unit within the second space.

Abnormal anterior curvature or *kyphosis* (**1**.7.1; Figure 83) frequently results from either focal bone loss, compression fractures, or gradual loss of anterior body height within a region. Kyphotic change due to focal bone loss may be followed by bone formation which may lead to fusion *(ankylosis;* Figure 84), a condition that should be coded as **1**.9.2 (ankylosis present). As illustrated in Figure 85, compression fractures normally involve only a single unit, while gradual loss of height frequently affects several vertebrae.

Lateral deviation or *scoliosis* may result from the congenital presence of hemivertebrae (Figure 85) or from other forms of asymmetrical bone loss which lead to the development of wedge-shaped vertebrae. It is not unusual for two (compensating) examples of scoliotic change to be present in a single individual. The observer is requested to identify the direction of curvature as either left (**1**.7.2) or right (**1**.7.3) in the first space reserved for pathology observation. The form of the curvature and ankylosis should be coded in succeeding spaces.

2.0.0 **Abnormality of Size**

Hydrocephaly (**2**.1.0) is a congenital condition that leads to abnormal enlargement of the calvarium, with thinning of the neurocranial bones and ossicles within sutures (Figure 86). Occasionally normal immature crania are mistakenly termed hydrocephalous, since normal brain growth in infants and children produces a calvarium that is disproportionately large compared to the face. Hydrocephaly also occurs in other mammals and can produce distorted crania that mimic the human condition (Ubelaker et al. 1991). Care should therefore be taken in diagnosing this rare condition. If an example of hydrocephaly is encountered, we recommend that the specimen be thoroughly documented by measurement, photography, and radiography. Emphasis should be placed on describing the extent of parietal thinning and the presence of extrasutural bones. For criteria useful in diagnosing this condition, see Richards and Anton (1991).

Achondroplasia (**2**.2.1) is the most common form of dwarfism, resulting from developmental failure of bones formed in cartilage (Figure 87a and b). Characteristically, the face and cranial base are disproportionately small relative to the cranial vault. Long bones are short compared to their breadth, and the limbs are short

relative to the trunk. Other even more rare forms of dwarfism tend to involve proportional reduction in size of all bones, unlike the disproportionate reduction of certain bones seen in achondroplasia.

The resumption of growth in adulthood is known as *acromegaly* (**2**.3.0). Typically, bone is added at articular regions and along periosteal surfaces. Normal prominences, such as the chin, and joints, such as the temporomandibular articulation, become exaggerated through this process. Sinuses are enlarged and the cranial vault is thickened.

Achondroplasia, acromegaly, and related growth disorders are very rare in skeletal samples. If they are encountered, they should be described in detail with complete measurements, photographs, and radiographs.

3.0.0 Abnormal Bone Loss

The observer should first indicate the location of abnormal bone loss on Attachment 25, according to the following format.

3.1.1 Periosteal (outer cortical surface), external table

3.1.2 Cortex (excluding outer surface), or diploë

3.1.3 Endosteal surface, trabeculae, internal table

3.1.4 Mixed: **3**.1.1 + **3**.1.2

3.1.5 Mixed: **3**.1.2 + **3**.1.3

3.1.6 Mixed: All three locations involved

The *extent* of involvement should be measured in terms of the visible, observable structure. If less than 1/3 of the observable unit is affected, **3**.2.1 should be entered. For 1/3 to 2/3 of the unit affected, the code is **3**.2.2; for more than 2/3, **3**.2.3. If the bone is incomplete, *do not* attempt to infer pathological changes that might have been present if the bone were complete.

Abnormal bone loss may be either *focal* or *diffuse*. *Focal* changes are clearly visible, although size and marginal definition may vary. In recording focal lesions, observers are asked to identify the number of resorptive foci individually if the total count is below 10. Unifocal involvement is coded as **3**.3.1, while multifocal expressions are reported according to the following format:

3.3.2 Multifocal: 2 foci

3.3.3 Multifocal: 3-5 foci

3.3.4 Multifocal: 6-10 foci

3.3.5 Multifocal: 10+ foci

Lesion size should also be recorded, utilizing all categories that apply.

3.4.1: <1 cm

3.4.2: 1-5 cm

3.4.3: >5 cm

3.4.4: Mixed 3.4.1 + 3.4.2

3.4.5: Mixed 3.4.1 + 3.4.3

3.4.6: Mixed 3.4.2 + 3.4.3

3.4.7. Mixed 3.4.1 + 3.4.2 + 3.4.3

As illustrated in Figures 88 and 89a and b, marginal definition can vary. Here we recognize three categories: (1) clearly defined emargination with obvious evidence of sclerotic reaction; (2) sharply defined margins without obvious sclerotic reaction; and (3) poorly defined margins. As the degree of circumscription is related to the speed with which the disease process is proceeding, this category is very important. Both "pure" and mixed reactions can be coded using the following format:

3.5.1 Circumscription, sclerotic reaction

3.5.2 Boundaries well defined, but no sclerosis

3.5.3 Margins not sharply defined

3.5.4 Mixed 3.5.1 + 3.5.2

3.5.5 Mixed 3.5.2 + 3.5.3

3.5.6 Mixed 3.5.1 + 3.5.2 + 3.5.3

Diffuse or osteoporotic bone loss can result in multiple sites of resorption, which can vary in size and areal extent. These sites are illustrated in Figure 90. Common expressions of osteoporotic change seen in the cranial vault and orbits are termed porotic hyperostosis and should be recorded according to procedures indicated in Section 6.0. Similarly, diffuse reactions on articular surfaces should be coded in Section 8.0 Arthritis. (Do not code osteoarthritic changes and porotic hyperostosis under Bone Loss). True osteoporosis is frequently associated with *trabecular coarsening,* as illustrated in Figure 91. Trabecular coarsening is a mixed reaction, involving both resorption and deposition, and will be recorded under 4.0 Abnormal Bone Formation.

An imbalance of bone formation and resorption can lead to *cortical thinning* in long bones. This condition can be inferred visually, although direct measurement is preferred. If long bones such as the femur are being sectioned during the collection of samples for chemical (or other) analyses, direct measurement of cortical thickness at midshaft should be recorded. We ask that cortical thinning be evaluated visually in association with diffuse bone loss. If both diffuse bone loss and cortical thinning are observed, **3**.6.1 should be reported. Diffuse bone loss without cortical thinning is recorded as **3**.6.2.

Structural collapse as a result of bone loss should be recorded (**3**.7.0). This will commonly occur within the spinal column, either as a result of osteoporosis, trauma, or focal resorption due to infectious disease.

4.0.0 Abnormal Bone Formation

On Attachment 25, at least five observations may be included for a single type of abnormal bone formation. In this way, the type of abnormal formation can be reported, along with information concerning the proportion of the unit affected and the presence of specific structures such as stellate scars. Proliferative changes specific to vertebral bodies, such as osteophytes and syndesmophytes, should be recorded under 7.0, while lipping in association with arthritis should be coded under 8.0 (Attachment 26).

Most abnormal bone formations will be grossly observable as either *lamellae* (**4**.10) or *vertical spicules* (**4**.20) added to intact external surfaces. These structures may be relatively recent additions of woven bone, indicating a process active near the time of death. Alternatively, the formations may have been subject to remodeling, which produces a sclerotic reaction indicative of a healing phase or a chronic disease process. To correctly evaluate recency and rapidity, it is important to distinguish lamellae of *woven bone* (fiberbone) (**4**.1.1) from *sclerotic* additions (**4**.1.2) that have become integrated with the cortex. Reactions including both woven and sclerotic bone may also be present and should be coded as *mixed* (**4**.1.3). Figure 92a and b and 93 a and b illustrate these reactions on both cranial and postcranial bones.

Perpendicular spicules added rapidly to the periosteal surface will produce a *"sunburst"* effect that should be reported as **4**.2.1 (Figure 93a). Spicules added more slowly assume the appearance of a *"cauliflower,"* as illustrated in Figure 93b. This more chronic reaction is coded as **4**.2.2.

Occasionally, periosteal surfaces will not be intact, due to processes originating within the bone. As a result, the cortex may be perforated and an elevated *"shell"* produced (Figure 94). Alternatively, *cloacae,* also termed sinus tracks or canals, may be present, usually indicating a site of infection deep within the bone. As illustrated in Figure 95, cloacae are typically smooth-walled canals extending into the bone and associated with additional evidence of pathological remodeling. Shell-type reactions should be recorded as **4**.3.1, while the presence of sinus tracks is reported as **4**.3.2.

The *endosteal* surface, if visible, may present evidence of reactive bone which narrows the medullary cavity. In some instances distinctive lamellae may be discerned (**4**.4.1). Lamellae are not visible upon all occasions. Narrowing without observable lamellae should be recorded as **4**.4.2.

Abnormal matrix formation may present evidence of *immature, woven bone,* replacing normal cortical structures (**4**.5.1). Typically bones thicken but become structurally unsound, as in the case of Paget's disease (Figure 96a-d). Another example of abnormal matrix formation is the expansion of cancellous bone that can result in obvious *thickening* of elements such as the bodies of the ribs, the sternum, and the bones of the calvarium (**4**.5.2). It is important to distinguish between this form of abnormal matrix formation and the integration of externally generated lamellar bone in the creation of abnormal structures. Another form of abnormal remodeling of cancellous tissue produces *coarsened trabeculae* (see Figure 91), usually through a combination of resorption and addition. Trabecular coarsening should be recorded as **4**.5.3.

For all of the abnormal bone formations discussed so far, the extent of involvement should be recorded only in terms of the structures actually observed, as for abnormal bone loss (see above). If less than 1/3 of the observable unit is affected, **4**.6.1 should be entered. If 1/3 to 2/3 of the unit is affected, enter the code **4**.6.2; if more than 2/3 of the unit is involved, enter **4**.6.3.

Other examples of structures which result from abnormal bone formation include ossification of connective tissue. Often of traumatic origin, *myositis ossificans* (**4**.7.1; Figure 97) refers to the formation of bone within muscle tissue (If a fracture is evident, myositis ossificans should be coded under **5**.4.9 rather than in this section.). *Enthesophytes*, also called osteophytes, are projections or spicules of bone at sites of tendinous or ligamentous attachment (see Figure 112). The presence of enthesophytes should be coded as (**4**.7.2). Abnormal bone formation can also lead to *joint fusion* (Figure 98), which should be recorded as (**4**.7.3).

A common form of benign bony tumor is the *button osteoma* (Figure 99), a small (<2 cm) dense, smooth, circular raised area typically observed on the cranial vault. Also seen on the cranial vault, *stellate scars,* or "caries sicca," are mixed reactions consisting of a central focal destructive area surrounded by bone formation which frequently becomes sclerotic and reflects a chronic condition (Figure 100). Caries sicca is considered to be pathognomonic of tertiary syphilis (Hackett 1976). The presence of button osteomata should be coded as **4**.8.1; stellate scars as **4**.8.2.

Involucra and *sequestra* typically occur as a result of disease processes affecting long bones, as illustrated in Figure 101. A sequestrum (**4**.8.3) is an isolated piece of dead bone, commonly resulting from trauma. If the periosteum remains intact, a new sheath of bone may be produced, surrounding the sequestrum. The new bone sheath is termed an involucrum, which should be reported as **4**.8.4. If both a sequestrum and an involucrum are present, the code is **4**.8.5.

5.0.0 Fractures and Dislocations

Since several characteristics are typically required to describe the nature of a fracture, 11 observational spaces are available on Attachment 25. The observer is asked to report each appropriate attribute within section **5**.1.0 (Type of Fracture). Thus, a complete, simple fracture in an individual presenting evidence of abnormal bone loss would be entered as 1.1 (1st observation: complete); and 1.3 (2nd observation: simple). Sequelae, such as mature callus formation (4.2) should also be recorded.

Depending upon the bone involved, the age of the individual, and the nature of the stress, a variety of patterns may result from trauma (Figure 102a-e). A break in a long bone may be *complete* (**5**.1.1) or *partial* (**5**.1.2). Partial or "greenstick" fractures typically occur as a result of bending stresses in juveniles. Adult ribs are also a frequent site of greenstick fractures. *Simple* (**5**.1.3) fractures break the bone into two distinct segments, while *comminuted* (**5**.1.4) fractures produce additional bone fragments. *Spiral* (**5**.1.5) fractures, commonly the result of twisting forces, course obliquely through the bone. Osteoporotic, aged adults most commonly suffer *compression* (**5**.1.6) fractures of the vertebrae (see Figure 85). Compression of the cranial vault typically results in *depressed* fractures. Depressed fractures involving the outer table only should be coded as **5**.1.7; depressed

fractures involving both the outer and the inner tables should be coded as **5**.1.8. Fractures that follow other bone-weakening illnesses are termed *pathologic* (**5**.1.9).

When fractures result from the use of weapons, the nature of the insult may be determined from the shape of the fracture (Figure 103). The terms *blunt round* (**5**.2.1) and *blunt oval* (**5**.2.2) describe depressed fractures, usually of the cranium. *Edged* or *bladed fractures* (**5**.2.3) refer to sharp force trauma, e.g., knives and axes.

Projectile entry (**5**.2.4) and exit (**5**.2.5) sites usually can be identified by greater bone loss or beveling on the side that follows the path of the projectile (Figure 103c, e). Thus a cranium with a gunshot wound usually would display greater bone loss on the endocranial surface of the entry site and the ectocranial surface of the exit site. Fragments will usually be displaced in the direction the projectile is traveling. Embedded projectiles should be coded as **5**.2.6. Amputations (**5**.2.8) are identified by a missing segment, indications of healing, and evidence of bone loss.

If the fracture is clearly ancient, *without signs of healing,* then it may have occurred near the time of death. Recent breaks may be distinguished from ancient trauma by observing the surfaces of the broken fragments. If the broken edges are stained the same color as the external bone surfaces, then ancient, perimortem trauma may be suspected. Light-colored edges are more likely the result of excavation or curation damage. A clear example of perimortem trauma should be coded as **5**.3.1; a more ambiguous example **5**.3.2. See Figure 72 in Chapter 9 for examples of perimortem and postmortem breakage patterns.

Callus formation typically accompanies fracture healing. A recently formed callus will be composed of *woven bone* (**5**.4.1), while *sclerotic* (**5**.4.2), integrated bone formation is indicative of an episode earlier in the lifetime of the individual (see Figure 92a and b for illustrations of woven versus sclerotic bone). Similarly, evidence of healing may be evident in association with cranial trauma, uniting sections of a depressed fracture or obliterating the stellate pattern commonly associated with projectile (arrow or bullet) wounds (**5**.4.3). A failure of the healing process may result in *nonunion* (**5**.4.4), leading to a "false joint" or pseudoarthrosis (Figure 104). Nonunion is most common in distal limb segments, especially the forearm. *Tissue necrosis*, or death of bone in that area (**5**.4.5), may result from trauma. Infection (**5**.4.6) may ensue, as may *arthritic* (**5**.4.7) changes. Arthritic changes may result directly from joint disorganization due to a traumatic event or may develop later, as a more chronic expression of the unusual stresses promoted by dysfunctional limbs (or other structures). Overuse of other body segments may also result in arthritis in joints far removed from the site of original trauma. Trauma can also lead to *joint fusion* (**5**.4.8) or *myositis ossificans* (**5**.4.9), which have been discussed above in section **4**.7.0.

Dislocations (**5**.5.0) may result from *trauma* (**5**.5.1), although unusual joint formations may also be *congenital* (**5**.5.2). The hip is the most common site of congenital malformations (dysplasias) which may be confused with traumatic dislocations. Typically, the dysplastic hip will display an unusually shallow acetabulum, while the acetabulum of the traumatically dislocated joint will appear relatively normal. Long-standing dislocations may undergo remodeling sufficient to obscure the ultimate cause. If the observer cannot discern the dislocation's ultimate cause, **5**.5.3 should be entered for the appropriate bone on Attachment 25. Examples of traumatic and congenital hip dislocations are illustrated in Figure 105a-d.

6.0.0 Porotic Hyperostosis

Porosity of the cranial vault and/or orbits is thought by many to represent an anemic response, resulting from hypertrophy of blood-forming tissue within the cranial vault. While rare hereditary anemias occur in Old World collections, most instances of porotic hyperostosis viewed in North American Indian remains are the result of nutritional deficiencies, infectious disease, and/or parasitism. Inherited hemolytic anemias, such as sickle-cell or thalassemia, may be present in remains of individuals of African-American or Mediterranean heritage.

Typically, porotic hyperostosis occurs on the orbital surface of the frontal bone or adjacent to the lambdoid, sagittal, or occasionally, the coronal sutures. In extreme cases, more central regions of the frontal, parietal, and occipital bones may be involved. When identifying porotic hyperostosis, it is important to distinguish between

cancellous hypertrophy ("hair-on-end" pattern) and lamellar expansion ("onion-skin" pattern). Occasionally this distinction will require sectioning (or radiography) of the affected tissue. In this way, the "hair-on-end" pattern characteristic of porotic hyperostosis can easily be differentiated from lamellar bone production.

Various degrees of expression for porotic hyperostosis can be identified. The recording system recommended here is adapted from Stuart-Macadam (1985) and should be used for the frontal, parietal, and occipital bones. As illustrated in Figure 106a-c, we distinguish between very indistinct porosity (**6**.1.1), true porosity (**6**.1.2), coalescing pores (**6**.1.3), and coalescing pores in association with expansive changes (**6**.1.4). When varying degrees of expression are present, the most extreme should be coded.

Locational distinctions should be made between porosity occurring only within the orbits of the frontal bone (cribra orbitalia, **6**.2.1) and hyperostotic changes of the cranial vault. Within the cranial vault, porosity may be localized near the lambdoid, sagittal, and (more rarely) coronal sutures (**6**.2.2), or it may appear more centrally near the frontal and/or parietal bosses or within the squamous portion of the occipital bone (**6**.2.3). If both the orbits and the sutural region of the frontal bone are affected, the appropriate code is **6**.2.4. When both the bosses/squamous portions of the parietal or occipital bones present evidence of porotic hyperostotic changes, the appropriate code is **6**.2.5. The sharp edges and woven bone of active lesions (**6**.3.1) should be distinguished from remodeled, sclerotic changes (**6**.3.2). Mixed reactions are also possible and should be coded as **6**.3.3.

7.0.0 Vertebral Pathology

Certain conditions of the spinal column require special consideration. Among these are age-related structures, such as Schmorl's nodes (or depressions) and osteophytic expansions of the vertebral bodies. (Degenerative changes of the vertebral bodies should be coded here. Osteoarthritic changes of the true diarthrodial joints located on the neural arches should be considered in reference to 8.0 Arthritis.) The congenital anomaly called spina bifida is also discussed here, as is the congenital anomaly/fracture spondylolysis. For each of these conditions score the maximum expression apparent for each skeletal unit designated in the inventory (Attachment 26).

Pathological changes in the vertebrae produced by other conditions, such as tuberculosis, should not be recorded in this section. They should be coded under the more general pathological changes. For instance, the abnormal bone loss frequently associated with tuberculosis should be recorded under Bone Loss.

Schmorl's nodes (7.1.0) occur as a result of intervertebral disk pressure on the superior or inferior surfaces of the vertebral bodies. As illustrated in Figure 107, Schmorl's nodes are commonly associated with other forms of degenerative change, such as the formation of bony spurs or *osteophytes* (7.2.0) extending from the vertebral bodies. The initial horizontal orientation of osteophytes distinguishes them from *syndesmophytes* (endesmophytes) and enthesophytes, 7.3.0), which are oriented vertically. As illustrated in Figure 108, syndesmophytes form within the margins of intervertebral disks and commonly present a "flowing" pattern; vertebral enthesophytyes form first within the anterior and posterior longitudinal ligaments and also show a "flowing" pattern. Osteophytosis, on the other hand, tends to produce "shelflike" protrusions and irregular or undulating fusion. Syndesmophytes are characteristic of such conditions as ankylosing spondylitis, and enthesophytes are characteristic of conditions such as diffuse idiopathic skeletal hyperostosis (DISH disease). Osteophyte formation represents age and activity-related degeneration. In recording osteophyte or syndesmophyte/enthesophyte formation, we ask that observers indicate the maximum expression within the anatomical units defined on the inventory. These should be scored according to the following standards.

OSTEOPHYTES, DEGREE (indicate maximum expression)

7.2.1 Barely discernible

7.2.2 Elevated ring

7.2.3 Curved spicules

7.2.4 Fusion present

SYNDESMOPHYTES/ENTHESOPHYTES, DEGREE (indicate maximum expression)

7.3.1 Barely discernible

7.3.2 Elevated ring

7.3.3 Extended spicules

7.3.4 Fusion present

As illustrated in Figure 109a, under normal circumstances, the neural arches of the fifth (or fourth and fifth) sacral unit do not fuse, forming a structure called the sacral hiatus. Nonfusion of neural arches for sacral units superior to S4 should be considered an expression of spina bifida, a congenital condition that can be clearly visualized following age six after which the neural arches of S1-S3 (or S4) should be fused. Partial/Incomplete fusion (spina bifida occulta,7.4.1) should be reported in instances of ossification failures above S4 that do not extend throughout all sacral units. If all sacral laminae have failed to fuse, the condition should be scored as "complete" (7.4.2) (Figure 109b). Instances of spina bifida do occur on other vertebrae, but this happens so rarely that we do not include them in the coding system. Instead we recommend describing the affected vertebra(e) on a separate page to be included with the pathology code forms in the final report.

Separation of a vertebra across the pars interarticularis or, more rarely, across the pedicles (see Figure 110a-c) is called *spondylolysis.* The separation may be either unilateral or bilateral. Separation with no evidence of healing should be scored as 7.5.1. Occasionally, a fracture line will be present, with evidence of healing (7.5.2). If the fracture is bilateral, the two separated vertebral segments may have moved apart during life. Bilateral separation *(spondylolisthesis,* 7.5.3), primarily through forward movement of the body and anterior portion of the neural arch, is evidenced by the development of osteophytes which indicate the displaced position of the anterior vertebral segment. Eburnation (see **8**.5.0 below) can also provide evidence for spondylolisthesis. The fifth lumbar vertebra is the most common site of spondylolysis, though more superior units may be affected.

8.0.0 **ARTHRITIS**

Typical features of osteoarthritis (degenerative joint disease) include *lipping* (bony spur or osteophytic development) marginal to the articular surface, *porosity* of the surface, and *eburnation.* Eburnation is the bone-on-bone polish that develops following cartilage degeneration. Grades of each type of change are illustrated in Figure 111a-c. The observer is asked to determine the extent of the joint surface (porosity, eburnation) or joint periphery (lipping) affected and to indicate the maximum expression of the arthritic change. For all features of arthritis, record the maximum expression observed within each group defined on the inventory (Attachment 26). The following standards are to be applied.

LIPPING, DEGREE

8.1.1 Barely discernible

8.1.2 Sharp ridge, sometime curled with spicules

8.1.3 Extensive spicule formation

8.1.4 Ankylosis

LIPPING, EXTENT OF CIRCUMFERENCE AFFECTED BY MOST SEVERE EXPRESSION

8.2.1 <1/3

8.2.2 1/3-2/3

8.2.3 >2/3

SURFACE POROSITY, DEGREE

8.3.1 Pinpoint

8.3.2 Coalesced

8.3.3 Both pinpoint and coalesced present

POROSITY, EXTENT OF SURFACE AFFECTED

8.4.1 <1/3

8.4.2 1/3-2/3

8.4.3 >2/3

EBURNATION, DEGREE

8.5.1 Barely discernible

8.5.2 Polish only

8.5.3 Polish with groove(s)

EBURNATION, EXTENT OF SURFACE AFFECTED

8.6.1 <1/3

8.6.2 1/3-2/3

8.6.3 >2/3

Surface osteophytes reflect the addition of compact bone to joint surfaces, as illustrated in Figure 112. We ask that the observer indicate whether surface osteophytes are barely discernible (**8**.7.1) or clearly present (**8**.7.2).

Periarticular resorptive foci, when present, should also be recorded as either barely discernible (**8**.8.1) or clearly present (**8**.8.2). In addition, the extent of the circumference affected by the periarticular resorptive foci should be recorded as less than 1/3 (**8**.9.1), 1/3 to 2/3 (**8**.9.2), or greater than 2/3 (**8**.9.3).

Periarticular resorptive foci, when present, should also be recorded as either barely discernible (**8**.8.1) or clearly present (**8**.8.2). In addition, the extent of the circumference affected by the periarticular resorptive foci should be recorded as less than 1/3 (**8**.9.1), 1/3 to 2/3 (**8**.9.2), or greater than 2/3 (**8**.9.3).

CONCLUDING STATEMENT

In this chapter we have attempted to provide standards for data collection on pathological collections that in our collective experience provide insight into past disease conditions, their diagnosis, and their impact on human communities. Any decision to restrict data collection or to record less information than suggested here will greatly hamper future interpretations of health and disease for the populations represented by these collections. At the same time, we recognize that the procedures recommended here are only minimal. As time and resources permit, these standards should be augmented by additional strategies developed by the investigator through his/her experience or reading of the scientific literature.

a

b

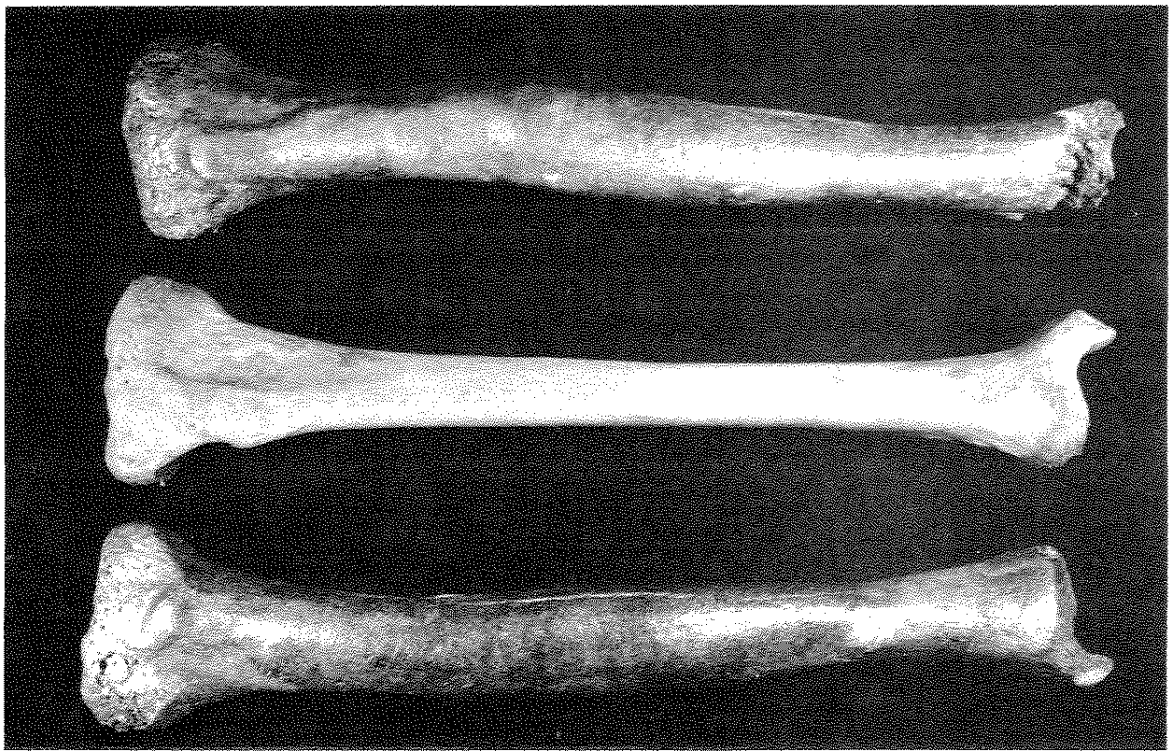

Figure 79a-b. Shape abnormalities, including both angulation (sharp curvature) and bowing (gradual curvature).
a) Angulated right 2nd metacarpal (top), compared with normal bone (bottom). Specimen Ray °3-38.
b) Abnormally bowed tibiae (top and bottom) compared to normal right tibia (middle). Specimens Peisker M-2 TB B2 (top and bottom) and 51 (middle) from Japanese collections, University of Chicago. Photos by Diane Houdek.

INDEX

References to figures are printed in boldface following text entries..

Abscesses, dental, 55, **55**
Achondroplasia, 116-117, **131-132**
Acromegaly, 117
Age-at-death determination
  adult, 21-38
    amino acid racemization, 169
    auricular surface scoring system, 24-32, **24, 26-32**
    cranial suture closure, 32-36, **34-35, 38**
    pubic symphysis scoring systems, 15, **21-24**
    sternal extremity of ribs 2-7, 168-169
  immature, 39-46
    epiphyseal union, 40-41, **40, 41, 43**
    union of primary ossification centers, 42-43, **41, 42, 43**
  See also, Dental formation, histology, and morphology
Amino acid racemization, 167
Amputation, 120
Angulation, 113, **124**
Ankylosis, 116, **128**
Arthritis, 122-123, **157-158**
Auricular surface scoring system, 24-32, **24, 26-32**
Bone formation, abnormal. 85, 97, 107-112, 118-119
  See also under specific type of abnormality.
Bone loss, abnormal, 117-118, 119
  See also under specific type of abnormality.
Bowing, 113, **124**
Burned bone, 5, 105, **96**
  inventory, 5, 10
  photography, 11-12
  taphonomy, 105
Button osteoma, 119, **143**
Calculus, dental, 55-56, **56**
Carbon ratios, stable isotope, 169-170
Caries
  dental, 54-55
  sicca, 119, **143**
Casts, dental, 13, 54, 63
Cementum annulation, 174
Checking, 96, 105, **96**
Cloacae, 118, **138, 139**
Color of remains
  and cremation, 10, 11, 95-96, 105, 173
  in cutmarks, 99
  green, from copper, 106
  in teeth, 57
  in trauma healing, 120
Commingled remains, inventory, 5-6, 9-10
Cortical thinning, 118
Cranial deformation
  artificial, 160-163, **161, 162**
  pathologic shape changes, 116-117, **124-127**
Cranial landmarks, 44-45, 69-77, **45, 71-77**
Craniostenosis (craniosynostosis), 116
Cremation
  inventory, 5, 10
  photographs of, 11-12
  taphonomy, 105, **96**
Cribra orbitalia, 121
Cross-sectional geometry, 170-172, 174, **171**
Cultural modification of remains, 11,
  dental, 58, **59, 60**
  taphonomic, 106
  trepanation, 159-163, **159, 160**
Cutmarks, 98-99, **102**
Dental
  abscesses, 55, **55**
  calculus, 56, **56**
  caries, 54-55
  casts, 13, 54, 63
  enamel defects
    hypoplasias, 13, 56-58, **57**
    opacities, 56-57
  enamel microwear, 53-54, **52, 53**
  eruption patterns, 48-54, **50, 51**
  histology, 167
  cementum annulation, 174
  Gustafson method, 58, 167
  inventory, 47-49, **48**
  measurements, 61-62, **62, 63**
  modifications, premortem, 58, **59-60**
  morphology, 63-68
  samples, 58, 173-174
  tooth formation, 48-51, **50, 51**
  wear
    artifact-induced, 58, **60**
    micro-, enamel, 53-54, **52, 53**
    occlusal surface, 49, 52, **52, 53**

Diet
stable isotope analyses, 169-170
trace element analyses, 169
Dislocations, 120, **149-150**
D/L amino acid ratios, 167-168, 173
DNA analysis. 170, 174
Dwarfism, 116-117, **131, 132**
Eburnation, arthritic, 122, 123, **158**
Enamel
defects
hypoplasias, 13, 56-58, 107, **57**
opacities, 56-57
microwear, 53-54, **52, 53**
occlusal surface wear, 49, 52, **52, 53**
Endesmophytes. *See* Syndesmophytes.
Enthesophytes, 119, 121
Epigenetic traits. *See* Nonmetric traits.
Epiphyseal union, 40-41, **40, 41, 43**
Eruption patterns, dental, 48-54, **50, 51**
Fiberbone. *See* Woven bone.
Flared metaphyses, 113, **126**
Flattening, cranial, 160-163, **161, 162, 163**
Fractures, 119-120, **129, 144, 145**
Fusiform expansion, 113, **112, 126**
Glabella
definition, 72
sex determination, 19, 20, **20**
Gnawing, animal, 95, 98, 106, **100, 101**
Greater sciatic notch, 11, 18, **18**
Gustafson method, 58, 167
Hemivertebrae, 116, **129**
Histological techniques, 165-168
See also under specific technique.
Histomorphometry, bone, 164, 165-166, 168
Hydrocephaly, 116, **131**
Hypoplasia, enamel, 13, 56-58, 107, **57**
Immature remains
age at death determination
epiphyseal union, 40-41, **40, 43**
union of primary ossification centers, 41-43, **42, 43**
inventory, 6-9
measurements
cranial, 44, **45**
postcranial, 44, **46**
nonmetric traits, 87-94
Innominate. *See* Os coxae.
Insect infestation, 95, 97
Inter-observer error, 183-184
Intra-observer error, 183-184
Inventory
commingled remains, 9-10
complete skeletons, 5-8
limb long bones, 8
other postcranial bones, 8
skull, 6, 7
cremated remains, 10

dental, 47-49, **48**
immature remains, 44-46, **45, 46**
incomplete remains, 8-9
Involucra, 119, **144**
Ischiopubic ramus ridge, 16-17, **17**
Joint fusion, 119, **142**
Juveniles. *See* Immature remains.
Kyphosis, 116, **127**
Lamellar expansion, 120, 121
Landmarks, cranial, 44, 45, 71-78, **45, 71-78**
Lead, 172
Lipping, arthritic. 122, **157**
Mastoid process
measurement, 70, **77**
sex determination, 19, **20**
Measurements
adult, 69-70
cranial, 71-78, **71-78**
postcranial, 79-84, **79-84**
dental, 61-63, **62, 63**
immature
cranial, 44, **45**
postcranial, 44, **46**
Mental eminence, 19, **20**
Myositis ossificans, 119, **142**
Nonmetric traits, 85-94, **87-92**
Nuchal crest, 19, **20**
Opacity, enamel, 56-57
Os coxae, inventory 7, 8, 9, 11
age at death determination, 21, 24, 36, 41, **41**
sex determination, 16-18, **17-19**
measurement, 82, **82**
Osteoarthritis, 122, **157, 158**
Osteon frequencies, 165, **166**
Osteophytes, 119, 121, 122, 123, **154, 158**
Osteoporosis, 118, **134, 135**
Oxygen ratios, 172
Pacchionian depressions, 108, **110**
Paget's disease, **140**
Pathology Coding Sheet, 114-115
Photography, 10-12

Polish, 106, 122, 123, **158**
Porosity
arthritic, 122, 123, **158**
on auricular surface, 25
normal, in juveniles, 108, **109**
porotic hyperostosis, 120-121, **151-153**
Porotic hyperostosis, 120-121, **151-153**
Postmortem changes
dental, 54, 56
pathology, 103, 105, 108
taphonomy, 95-106.
See also under specific changes.
Preauricular sulcus, 16, 18, **19**
Primary ossification centers, 41-43, **41, 42, 43**
Pseudarthrosis, 120, **148**
Pubic symphysis scoring systems
Suchey-Brooks, 23-24, **23-24**
Todd, 22, **22**
Radiocarbon dating, 164, 165, 169
Radiography, 12-13
Ribs 2-7, sternal extremity, 15, 165, 166
Rootmarks, 97, **97**
Samples
dental, 58, 173-174
other, 165-167, 168-174
Scalping, 98, 99, **102**
Scanning electron microscopy, 173
Schmorl's nodes, 121, **154**
Sciatic notch, greater. *See* Greater sciatic notch.
Sclerosis, 117-118, **133, 136, 137**
Scoliosis, 116, **130**
SEM. *See* Scanning electron microscopy.
Sequestra, 119, **144**
Sex determination
os coxae, 16-18, **17-19**
skull, 16, 19-21, **20**
Shape abnormalities, 113, 116
pathology, 116-117, **124, 125, 126**
taphonomy, 103-105, **103, 104**
See also under specific type of abnormality.
Size abnormalities, 116-117.
See also under specific type of abnormality.
Skull
age at death determination, 36, **37, 38**
inventory 6-7
landmarks, 44, 45, 71-73, **71-73**
measurements 74-78, **74-78**
postmortem breakage (on racks), 105,
sex determination, 16, 19-21, **20**
Spina bifida, 122, **155**
Splitting, 97, 105, **96, 99**
Spondylolisthesis, 122
Spondylolysis, 122, **156**
Stable isotope analysis
carbon ratios, 169-170
oxygen ratios, 172
strontium ratios, 172
Staining
on bone breaks, 120
dental, 55
by deposits, 99
from exposure to sun, 105
metal, 96, 106
Stellate scars, 119, **143**
Strontium ratios
to barium, 169
to calcium, 169
Subpubic concavity, 17, **17**
Suchey-Brooks pubic symphysis scoring system, 23-24, **23-24**
Sulcus, preauricular. *See* Preauricular sulcus.
Surface wear, occlusal, 49, 52, **52-53**
Supernumerary teeth, mentioned, 48, 49, 68
Supraorbital margin
nonmetrics, 87, 93, **87**
sex determination, 19-20, **20**
Suture closure, cranial, 32-33, 36, 116, **33-35**
Syndesmophytes, 121, **154**
Taphonomy
color, 95-96
cultural modification, 105-106, **96**
shape changes, 103-104
surface changes, 97-98
burning, 96, 97, 105, **96**
cutmarks, 98, 99, 105, 106, **102**
insect infestation, 95, 97
rootmarks, 97, **97**
toothmarks, 98, 106, **100, 101**
weathering, 98, 105-106, **99**
Teeth. *See* Dental.
Todd pubic symphysis scoring system. 22, **22**
Tooth formation, 48-51, **50, 51**
Toothmarks
carnivore, 6, 8 , 106, **100**
rodent, 6, 98, 106, **101**
Trabecular coarsening, 118, **135**
Trace element analysis
barium/strontium ratios, 169
lead, 172
strontium/calcium ratios, 169
strontium concentrations, 169

Trauma, by weapons, 120, **146, 147**
Trepanation, 159-160, **160**
Trephination. *See* Trepanation.
Ventral arc, os coxae, 16, **17**
Vertebral pathology, 121-122, **154**
See also under specific pathological condition.
Vessel tracks, 108, **110, 111**
Warping, 105
Weaning age, 1, 39
Wear patterns, dental, 52-60, **52, 53, 59, 60**
Weathering. 98, 105-106, **99**
Woven bone, 118, 119, 120, **136, 137, 140, 141**
X-ray diffraction, 173
XRD. *See* X-ray diffraction.

APPENDIX I

GLOSSARY OF TERMS

The following sources provided the basis for most of the definitions in this glossary: Critchley (1978) *Butterworth's Medical Dictionary,* 2nd ed.; Hensyl (1990) *Stedman's Medical Dictionary,* 25th ed.; O'Toole (1992) *Miller-Keane Encyclopedia and Dictionary of Medicine, Nursing, & Allied Health,* 5th ed. Additional sources included: Bates and Jackson (1987) *Glossary of Geology,* 3rd ed.; Lawrence (1989) *Henderson's Dictionary of Biological Terms,* 10th ed.; Steele and Bramblett (1988) *Anatomy and Biology of the Human Skeleton.*

Ablation - removal of a part of the body, e.g. a tooth.

Abscess - a pus-forming inflammation of the tissues around the tip of the root of a tooth. With prolonged infection, the alveolar bone surrounding the root will be resorbed.

Alveolar bone - alveolar process; the part of the maxilla and/or mandible that surrounds and supports the teeth.

Alveolar resorption - removal of alveolar bone, resulting in a decrease in the height of the maxilla and/or mandible, usually as a normal consequence of the aging process.

Alveolus - pl. **alveoli**; a tooth socket; one of the holes in the tooth-bearing alveolar process of the maxilla or mandible into which each tooth fits and is attached by its root.

Angular - forming an angle; sharply bent.

Angulated - placed or forced into an abnormal angle or bend.

Ankylosis - complete immobility of a joint, resulting from pathological changes in that joint or of the structures associated with it.

Anterior - opposite of posterior; ventral; the front surface of the body or a part thereof. Often used to indicate the position of one structure relative to another, e.g. the sternum is anterior to the thoracic vertebrae.

Antimere - one of the halves of a bilaterally symmetrical structure; especially used of teeth, e.g. the antimere of the left maxillary canine is the right maxillary canine.

Apatite - a type of calcium phosphate which forms part of the inorganic (mineral) component of bone matrix and teeth. Two subclasses of apatite are flouroapatite and hydroxyapatite.

Articular - relating to the normal anatomical points of contact between adjacent bones, i.e. joints.

Atrophy - adj. **atrophic**; a decrease in size of a normally developed organ or tissue; wasting.

Attrition - see **Dental attrition.**

Basilar - referring to or part of the base of a surface, structure, or bone.

Basioccipital synchondrosis - sphenooccipital synchondrosis; the joint between the anterior surface of the basilar part of the occipital bone and the posterior surface of the body of the sphenoid bone.

Bevel - a surface having a sloped or slanting edge.

Biological distance - 'biodistance'; measurement of population divergence based on phenotypic traits. Skeletal biological distance studies examine variation in bone or tooth shape and form in order to define patterns that are thought to reflect genetic relatedness within or between past populations.

Bowed - characterized by smooth, gradual curvature.

Buccal - pertaining to, adjacent to, or in the direction of the cheek.

Calculus - see **Dental calculus.**

Calvaria - pl. **calvariae**; the upper, domelike roof of the skull, consisting of the superior parts of the frontal, parietal, and occipital bones.

Cancellous bone - osseous tissue which consists of a network of rods, plates, or tubes (the trabeculae), with the spaces between the trabeculae filled with marrow, characteristically located in the epiphyses of long bones.

Caries - decay of bones or teeth resulting in the softening, discoloration, and destruction of the original material.

Cavitation - the formation of a cavity or cavities in an organ or tissue (e.g. teeth), usually as the result of a disease.

CEJ - cemento-enamel junction; the line of contact between the enamel and cementum of a tooth.

Cementum - the calcified tissue that immediately surrounds the dentin of the root and neck of a tooth, and which assists in holding the tooth in its socket (alveolus).

Centrum - the body of a vertebra, exclusive of the bases of the neural arches (pedicles).

Circumferential - encircling; relating to a circumference or a perimeter.

Coalesce - to grow together, fuse; to unite into one body or mass.

Collagen - a fibrous structural protein which forms the white fibers of bone, cartilage, and all other connective tissues.

Commingled - bone assemblages containing the remains of several individuals, which are frequently fragmented and incomplete.

Compact bone - dense osseous tissue. Forms the cortex of all bones, and consists largely of concentric lamellar osteons and interstitial lamellae.

Condyle - a rounded articular surface located at the distal end of certain long bones (e.g. the femoral condyles, which articulate with the tibia).

Congenital - existing at birth, referring to certain hereditary mental or physical traits, anomalies, malformations, diseases, etc.

Continuous variables - variables which can (but do not necessarily) take on an infinite number of values within a given interval, e.g. long bone length.

Cortical bone - compact bone found on the outer surface of a bone, between the endosteum and periosteum.

Craniosynostosis - craniostosis; premature ossification of the skull and obliteration of the cranial sutures. The particular sutures involved determine the resultant shape of the malformed head.

Cranium - pl. **crania**; a skull without its mandible.

C-T - computed tomography; a newer term for computerized axial tomography (CAT); a radiological imaging technique that uses computer processing to generate an image or "scan" of the tissue density in a "slice" as thin as 1 to 10 mm through a person or object; allows reconstruction of cross-sectional anatomy in several planes.

Deciduous dentition - primary dentition, 'milk teeth,' 'baby teeth'; in humans, the 20 teeth which are present before the permanent teeth erupt, after which point they are shed.

Demography - the study of vital statistics, e.g. fertility and mortality, within populations.

Dental attrition - dental wear; the natural process of wearing down the biting (occlusal) surfaces of the teeth by chewing abrasive foods.

Dental calculus - tartar; a hard, stonelike concretion, varying in color from creamy yellow to brown or black, that forms on the teeth through the calcification of dental plaque.

Dentin - dentine, dentinum; a calcified tissue containing about 20% organic matrix (mostly collagen) and 70% inorganic matter (mostly hydroxyapatite). It forms the mass of the tooth surrounding the pulp, and is covered with enamel on the crown and cementum in the root of the tooth. **Primary dentin** is dentin which develops until the formation of the root of the tooth is completed; **secondary dentin** is dentin which forms after the formation of the tooth's root is complete.

Diachronic - considering events or changes as they happen or develop over time.

Diagenesis - adj. **diagenetic**; all the chemical, physical, and biologic changes undergone by a bone after its initial deposition, exclusive of surface alteration (weathering).

Diaphysis - the shaft of a long bone, as distinguished from the extremities (epiphyses) or outgrowths (apophyses).

Diffuse - widespread, dispersed; not definitely limited or localized.

Diploe - spongy (cancellous) bone located between the outer and inner compact layers (tables) of the flat cranial bones.

Discontinuous variables - categorical or discrete variables; variables which consist only of a finite number of values within a given interval, e.g. nonmetric traits, which are usually scored as present, partially present, or absent. Note that discontinuous variables may actually represent an underlying morphological continuum, but if they are scored as discrete classes (such as present/absent), they are considered discontinuous variables.

Distal - opposite of proximal; situated away from the center of the body, remote from the point of attachment or origin. Often used to refer to a structure that is farther from the trunk (main part of the body) than another, e.g. the hand is distal to the forearm.

DNA - deoxyribonucleic acid; the acid found in cell nuclei that forms the basic structure of the genes.

Eburnation - smooth, polished appearance of exposed subchondral bone caused by bone-on-bone contact at articular surfaces as a result of degenerative joint disease.

Ectocranial - relating or belonging to the external surface of the flat cranial bones.

Enamel hypocalcification - deficient or defective enamel maturation caused by local, systemic, or hereditary factors, and characterized by low mineral content.

Enamel hypoplasia - deficient or defective enamel matrix deposition, but with normal mineralization. Results in the 'lines of growth arrest' visible to the naked eye on teeth, usually the incisors.

Endocranial - relating or belonging to the internal surface of the flat cranial bones.

Endosteum - adj. **endosteal**; the membranous layer of highly vascular connective tissue lining the medullary cavity of a bone.

Enthesophytes - projections or spicules of bone at sites of tendinous or ligamentous attachment.

Epicondyle - a projection from a long bone located above or upon the distal articular surfaces (the condyles).

Epiphysis - a secondary bone-forming center attached to a bone and separated from it by cartilage, commonly located at the ends of long bones, on the margins of certain flat bones, and at some major tubercles and processes. After a certain period of development, which differs for each epiphysis, it fuses to the main bone, and no further growth occurs at that point.

Erosion - any superficial destructive process; a wearing away of the external surface of a bone.

Exophytic - referring to a lesion or tumor that grows outward from the surface of a bone.

Exostosis - a benign new growth protruding from the surface of a bone and characteristically capped by cartilage. Occurs most often on long bones, but may also be found on flat bones. Usually forms in response to chronic irritation, as from infection, trauma, or osteoarthritis.

Focal - limited to one area or part of an organ or of the body; localized.

Foramen - a natural opening into, or perforation through, a bone.

Fracture - structural failure (breaking) of bone or cartilage.

Frankfort horizontal plane - eye-ear or auriculo-infraorbital plane, infraorbitomeatal plane; a standard craniometric reference plane which passes through the lower margins of the orbits (the orbitale) and the upper margins of the external acoustic meatuses (the porion).

Fusiform - spindle-shaped; tapering at both ends.

Gingival regression - receding of the soft tissues (gums) from around the teeth.

Gracile - slight or slender, delicate, thin.

Granulation - adj. **granular**; formation into grains or granules (small discrete masses which resemble grains), or one of the individual granules making up the larger mass.

Groove - sometimes used synonymously with 'sulcus'; an elongated, usually shallow depression, hollow or furrow.

Haversian system - see **Osteon.**

Heritability - a statistical term used to denote the proportion of phenotypic variance that is caused by variance in genotypes.

Histology - microanatomy; the science concerned with the minute structure of cells, tissues, and organs in relation to their function.

Histomorphometry - the quantitative measurement and characterization of microscopical images using a computer.

Hydroxyapatite - see **Apatite.**

Hyperplasia - increase in the number of cells of a tissue or organ, excluding tumor formation.

Hypertrophy - increase in bulk (volume) of a tissue or organ as the result of an increase in the function of that tissue. May be restricted to denote greater bulk through increase in size, but not number, of cells of the affected tissue element.

Inferior - opposite of superior; situated lower down (nearer the soles of the feet) in relation to a specific structure or reference point, situated below or directly downward. Often used to describe the position of one structure relative to another, e.g. the mouth is inferior to the nose.

Inner table of skull - the inner of the two layers of compact bone that enclose the diploe of the skull.

Interment - burial.

Inter-observer error - error associated with variation in precision (self-similarity) among data recorded by two or more observers who studied identical material.

Interproximal - lying between adjacent surfaces. In dentistry, referring to the spaces between adjacent teeth.

Intra-observer error - error associated with variation in precision (self-similarity) among data recorded by one observer from the same set of material in two or more separate study sessions.

Isotope - adj. **isotopic**; a chemical element having the same atomic number as another (i.e. the same number of protons in the nucleus), but having a different atomic mass (i.e. a different number of neutrons in the nucleus).

Juxta-articular - close to or adjoining an articular surface.

Kyphosis - also called 'hunchback'; a deformity of the spine characterized by extensive forward curvature (flexion), especially in the thoracic region.

Labial - towards the lips; related or belonging to the lips.

Lamella - pl. **lamellae**; a thin sheet or layer. In compact bone, lamellae are arranged in a circular (concentric) fashion around a central Haversian canal.

Lateral - towards the side of the body; farther from the midline or mid-sagittal plane.

Lesion - a broad term referring to any pathological or traumatic discontinuity of tissue or loss of function of a part, including wounds, sores, ulcers, tumors, and any other tissue damage; one of the individual points or patches of a multifocal disease.

Lingual - next to or towards the tongue; pertaining to the tongue.

Lipping - the formation of an overgrowth of bone which projects beyond the margin of the affected articular surface, as in osteoarthritis.

Lobulated - divided into small lobes or subdivisions of lobes, which are often separated from one another by connective tissue or fissures.

Long bones - collective term for the bones of the arms and legs. Specifically, the humerus, radius, ulna, femur, tibia, and fibula.

Lysis - adj. **lytic**; disintegration or dissolution of tissue.

Malocclusion - the lack of occlusion, or the abnormal occlusion, existing between the teeth of the upper and lower jaws.

Marrow space - a space between the trabeculae of cancellous bone, filled with a highly cellular connective tissue called 'marrow' which manufactures red blood cells.

Medial - mesial; nearer the midline or mid-sagittal plane of the body.

Medullary cavity - marrow-filled cavity inside a long bone.

Mesiodens - a supernumerary tooth located in the midline of the anterior maxillae, between the maxillary central incisor teeth.

Metaphysis - the wider portion of the shaft (diaphysis) of a long bone adjacent to the epiphysis; growth zone between the epiphysis and diaphysis during development of a bone.

Midline - the imaginary line that divides the body into symmetrical halves.

Mid-sagittal plane - median plane; the vertical plane that divides the body along its midline into symmetrical halves.

MIS - minimum information sequence.

MNI - minimum number of individuals.

Neurocranium - composed of those bones which enclose and protect the brain, as distinguished from the bones of the face.

Non-metric trait - dichotomous, discontinuous, epigenetic traits; non-pathological variations of skeletal tissues that can be better classified as present or absent (or as a point on a morphological gradient, e.g. small to large) rather than quantified by a measurement.

Occlusal - relating to the chewing surfaces (i.e. the crowns) of the premolar and molar teeth, and the contacting surfaces of the incisors and canines; also refers to a position toward the hypothetical plane passing between the maxillary and mandibular teeth when the upper and lower jaws are brought together.

Occlusion - the contact between upper and lower teeth that occurs when the jaws close.

Ossicle - ossiculum; a small bone.

Ossification by the epiphyseal plate - the conversion of tissue to bone at the epiphysis.

Osteomalacia - softening of the bones, resulting from impaired mineralization, caused by a vitamin D deficiency in adults. A similar condition in children is called rickets.

Osteometry - the branch of anthropometry which deals with the size and measurement of bones.

Osteon - Haversian system; the basic structural unit of compact bone, composed of a central, vascular canal (Haversian canal) and the concentric osseous lamellae which surround it.

Osteophyte - small abnormal bony outgrowth or protuberance, normally located in areas where ligaments attach to bone.

Outer table of skull - the outer of the two layers of compact bone that enclose the diploe of the skull.

Pathognomic - pathognomonic; characteristic or indicative of a given disease. Denotes especially one or more typical symptoms, findings, or patterns of abnormalities specific for one disease and not found in any other condition.

PCF - paleopathology coding form.

PCR - polymerase chain reaction.

Pectinate - comb-shaped.

Penciling - adj. **penciled**; degeneration of metacarpal/metatarsal joints resulting in the formation of a pencil-like (tapered) appearance at the articular ends.

Periarticular - circumarticular; surrounding a joint.

Perikymata - the transverse ridges and grooves on the surface of tooth enamel.

Perimortem - around the time of death.

Periosteal layer - periosteum; a fibrous membrane which completely covers the surfaces of bones, except at points of tendinous and ligamentous attachment and on articular surfaces, where cartilage is substituted.

Periostitis - inflammation (reaction to trauma or certain pathological processes) of the periosteal layer of a bone.

Periostosis - abnormal bone formation on the periosteal surface of a bone.

Permanent dentition - see **Secondary dentition.**

Porosity - adj. **porous**; condition of having small openings that pass directly or indirectly through a structure.

Posterior - opposite of anterior; dorsal; directed toward or situated nearer the back surface of the body. Often used to indicate the position of one structure relative to another, e.g. the thoracic vertebrae are posterior to the sternum.

Postmortem - pertaining to or occurring during the period after the time of death.

Premortem - pertaining to or occurring during the period before the time of death.

Primary dentin - see **Dentin.**

Primary dentition - see **Deciduous dentition.**

Primary center of ossification - the first site where bone begins to form during the growth of the shaft of a long bone or the body of other bones.

Proximal - opposite of distal; nearest to the trunk (main part of the body), or to the point of origin or attachment. Often used to refer to a structure that is nearer to the trunk than another, e.g. the forearm is proximal to the hand.

Pseudarthrosis - pseudoarthrosis; a new, false joint arising between the parts of a fractured bone which have failed to unite.

Pubic symphysis - see **Symphysis.**

Punched out - resembling a perforation, with scalloped or smooth edges.

Radiograph - the recorded image of an object on X-ray film.

Reactive bone - bone in the process of being formed, lost, or otherwise modified in response to some stimulus, usually pathological.

Remodeling - adj. **remodeled**; a cyclical process by which bone maintains a dynamic steady state through sequential resorption and formation of a small amount of bone at the same site. This process is often disrupted in pathological conditions affecting the bones, resulting in either abnormal bone loss or formation.

Resorption - the process of destruction of bone by osteoclasts.

Ridge - a crest; a raised linear projection or projecting structure.

Robusticity - degree of muscularity.

Sclerotic - characterized by being abnormally hard or dense, generally as a result of pathological change.

Scoliosis - lateral deviation (curvature) in the normally straight vertical line of the spine.

Secondary center of ossification - a center of bone formation appearing later than the primary, usually in an epiphysis of a long bone.

Secondary dentin - see **Dentin.**

Secondary dentition - permanent dentition; in humans, the 32 permanent teeth, which erupt and take their places after the deciduous teeth are shed.

SEM - scanning electron microscope; a microscope which produces an image of the surface of a metal-coated specimen by scanning a beam of electrons across the surface and building an image from the electrons reflected at each point. The image has both high resolution and great depth of focus.

Sequelae - sing. **sequela**; diseases or morbid conditions resulting from or dependent upon the prior presence of a certain disease.

Sexual dimorphism - normal differences in the bodies and/or behavior of males and females that arise as a consequence of sexual maturation. In addition to the secondary sex characteristics (e.g. beard on a male), also includes morphological and size differences in bones.

Skull - cranium and mandible together.

Sphenooccipital synchondrosis - see **Basioccipital synchondrosis.**

Spicule - a sharp, needle-like body or spike.

Stellate - star-shaped, with parts radiating from a center.

Subchondral bone - bone underlying cartilage.

Sulcus - any long, narrow groove, furrow, or slight depression.

Superior - opposite of inferior; situated above or directed upward. Often used to describe the position of one structure relative to another, e.g. the nose is superior to the mouth.

Supernumerary teeth - teeth exceeding the normal human number of deciduous (20) or permanent teeth (32).

Suture - one of the interlocking lines of fusion of the separate bones which unite to form the cranium.

Symphysis - the region where two paired bones, such as the left and right pubis, join together.

Syndesmophytes - projections or spicules of bone at sites of ligamentous attachment; in particular, vertically oriented growths which form along the margins of vertebral bodies, within the annulus fibrosus of the intervertebral discs.

Taphonomy - the study of processes affecting bone after death has occurred.

Tartar - see **Calculus, dental.**

TMJ - temporo-mandibular joint; the point of articulation between the condyle of the lower jaw (mandible) and the temporal bone.

Trabecular bone - see **Cancellous bone.**

Traumatic - pertaining to or caused by a wound or injury.

Trephination - trepanation; a surgical procedure which involves cutting a hole in the cranial vault and removing the cut piece of bone.

Variance - the mean of the squares of individual deviations of a set of observations from the corresponding mean; the square of the standard deviation.

Weathering - the destructive process or group of processes by which materials exposed to atmospheric agents at or near the Earth's surface are changed in color, texture, composition, firmness, or form, with little or no transport of the loosened or altered material.

Wedging - reduction or degeneration of one side of a bone, such that a wedge-shape results.

Wormian bone - sutural bone; a small, irregularly shaped accessory bone (ossicle) which forms in one of the sutures between adjacent cranial bones.

Woven bone - primary bone, 'fiberbone'; fibrous, or non-lamellar, bone which usually consists of an irregular network of intermingled trabeculae. Found wherever bone is being rapidly formed, e.g. in immature bone and fracture callus.

XRD - x-ray diffraction; a technique for determining the three-dimensional structures of crystallizable molecules from analysis of the diffraction patterns of x-rays passed through the molecules.

APPENDIX II:
INTRA- AND INTER-OBSERVER ERROR*

As emphasized throughout this volume, the repatriation issue presents many challenges to the scientific study of human skeletal remains. Too often overlooked in this context is the question of standardization and replicability of results. These issues are especially acute in reburial projects, since the remains will not be available for re-study by future researchers (Buikstra and Gordon 1981).

One widely accepted method for assessing replicability involves conducting statistical evaluations of intra- and inter-observer error. Intra-observer error studies concentrate on the replicability of results by a single individual. Following a time interval, an observer re-scores a sub-sample of the study series and then statistically compares the two sets of observations. In an inter-observer error study, the focus is on the replicability of results across multiple researchers. Two or more individuals record data from the same remains and then compare their results statistically.

Ideally, *all* observations should be subject to evaluations of intra- and/or inter-observer error. Minimally, we recommend that observations of dental measurements and morphology (Chapter 6), all measurements of immature and mature remains (Chapters 4 and 7), and the non-metric traits described in Chapter 8 be subject to replicability studies. If a single observer collects all of an information category, assessment of intra-observer error is sufficient. When several individuals contribute to the data set, both intra- and inter-observer error should be assessed.

The sub-sample of remains used in replicability studies should be selected randomly, either through the use of a random numbers table or a computer program. Most standard statistical texts include a table of random numbers and instructions for its use, e.g. Blalock (1979: 554-7); Rohlf and Sokal (1981: 71-5). Programs for generating random numbers are also available in many standard statistical packages, e.g. SYSTAT (Wilkinson 1990). Although recommendations concerning the size of sub-samples to be used in error studies vary, we suggest that at least 30 individuals be re-measured in an error analysis for measurements (continuous data). A minimum sub-sample of n = 30 will also be sufficient for error analyses of morphological and nonmetric traits (discontinuous data), provided that trait frequencies are relatively high. In cases of low trait frequency, more individuals should be re-scored. If the sample is very large, and a sub-sample of 30 would constitute less than 10-20% of the total population, enough additional individuals should be added to the error analysis so that the subsample consists of 10-20% of the total population.**

Although few studies focus exclusively on intra- and inter-observer error, several recent publications provide both appropriate statistical procedures for error analyses and examples of how to interpret results. Yezerinac et al. (1992) recommend the use of model II ANOVAs for intra-observer error analyses involving

* The authors wish to thank Lyle Konigsberg for his assistance in preparing this appendix.

** Determining the appropriate sample size is essential for any statistical study. Such a decision normally depends on an estimate of the population variance of the measurements or nonmetric traits to be included in the study. Researchers interested in more detailed discussions of how to select an appropriate sample size than could be provided here should consult Sokal and Rohlf 1981: 262-4; Yezerinac et al. 1992: 476; Zar 1984: 110-2, 153.

measurements (continuous data); Zar (1984: 206-13) and Sokal and Rohlf (1981: 205-7, 208-20) provide more detailed discussions of model II ANOVAs. Inter-observer error analyses of measurements should use paired-sample t tests; assuming that the paired t tests are not significant, the intraclass correlations provide information on replicability (see Sokal and Rohlf 1981: 215; Zar 1984: 150-3, 323-5).

Discontinuous data can be classified as ordinal or non-ordinal. Ordinal discontinuous (categorical) data discussed in this volume include sex (M, M?, ?, F?, F), degree of expression of morphological traits (e.g. small, medium, large), and degree of severity of pathology (e.g. slight, moderate, severe)—data which are part of a morphological continuum, but are separated into discrete classes for purposes of analysis. Agresti (1988) provides procedures for replicability analyses of ordinal categorical data. For error analyses involving non-ordinal discontinuous data (e.g. presence/absence of nonmetric traits), Zar suggests using the phi coefficient (1984: 321-3).

Both the data collection sheets and the results of all error analyses should be curated along with other paper records for the collection.

REFERENCES CITED

Acsádi, G. and J. Nemeskéri
1970 *History of Human Life Span and Mortality*. Akadémiai Kiadó, Budapest.

Adams, J.C.
1983. *Outline of Fractures Including Joint Injuries*, 8th ed. Churchill Livingstone, Edinburgh.

Agresti, A.
1988 A Model for Agreement between Ratings on an Ordinal Scale. *Biometrics* 39:505-510.

Alexanderson, V.
1970 Tandmorfologisk Variation hos Eskimoer og Andre Mongoloide Populationer. *Tanlaegbladet* 74:87-602.

Allison, M. J., E. Gerszten, J. Munizaga, C. Santoro, and G. Focacci
1981 La Práctica de la Deformación Craneana entre los Pueblos Andinos Precolombinos. *Chungara* 7:238-260.

Anderson, J. E.
1964 *The People of Fairty: An Osteological Analysis of an Iroquois Ossuary*. Bulletin No. 193. National Museum of Canada, Ottawa, Ontario.

Anderson, D. D., M. Finnegan, J. Hottop, and A. Fisher
1978 The Lewis Central School Site (13PW5): A Resolution of Ideological Conflicts at an Archaic Ossuary in Western Iowa. *Plains Anthropologist* 23:193-219.

Anton, S. C.
1989 Intentional Cranial Vault Deformation and Induced Changes of the Cranial Base and Face. *American Journal of Physical Anthropology* 79:253-267.

Ardito, G. and M. Fanelli
1975 I Caratteri Epigenetical del Cranio in Due Gruppi di Antichi Egizi; Osservazioni del Metodo. *Archivio per l'Antropologia e la Etnologia* 105:169-181.

Aswad, D. W.
1984 Determination of D- and L-Aspartate in Amino Acid Mixtures by High-Performance Liquid Chromatography after Derivatization with a Chiral Adduct of o-Phthaldialdehyde. *Analytical Biochemistry* 137:405-409.

Aufderheide, A. C.
1989 Chemical Analysis of Skeletal Remains. In *Reconstruction of Life from the Skeleton*, edited by M. Y. Iscan and K. A. R. Kennedy, pp. 237-260. Alan R. Liss, New York.

Aufderheide, A. C., F. D. Nieman, L. E. J. Wittmers, and G. Rapp
1981 Lead in Bone II: Skeletal Lead Content as an Indicator of Lifetime Ingestion and Social Correlates in an Archaeological Population. *American Journal of Physical Anthropology* 55:285-291.

Baby, R. S.
1954 Hopewell Cremation Practices. *The Ohio Historical Society Papers in Archaeology* 1:1-7.

Bada, J. L.
1984 In Vivo Racemization in Mammalian Proteins. *Methods in Enzymology* 106:98-115.

Bada, J. L., B. Herrmann, I. L. Payan, and E. H. Mann
1989 Amino Acid Racemization in Bone and the Boiling of the German Emperor Lothar 1. *Applied Geochemistry* 4:001-003.

Baker, B. J. and G. J. Armelagos
1988 The Origin and Antiquity of Syphilis: Paleopathological Diagnosis and Interpretation. *Current Anthropology* 29:703-737.

Baker, R. K.
1984 *The Relationship of Cranial Suture Closure and Age Analyzed in a Modern Multi-Racial Sample of Males and Females*. M.A. thesis, Dept. of Anthropology, California State University, Fullerton.

Bang, G.
1989 Age Changes in Teeth: Developmental and Regressive. In *Age Markers in the Human Skeleton*, edited by M. Y. Iscan, pp. 211-235. Charles C. Thomas, Springfield, Illinois..

Banki, Z.
1981 Dorsal und Ventrale Okzipitalwirbelformen. *Fortschritte auf dem Gediete der Roentgenstrahlen und der Nuklearmedizin* 135:322-325.

Baron, R., A. Vignery, L. Neff, A. Silverglate, and A.Santa Maria
1983 Processing of Uncalcified Bone Specimens for Histomorphometry. In *Bone Histomorphometry: Techniques and Interpretation*, edited by R. R. Recker, pp. 13-36. CRC Press, Boca Raton.

Bass, W. M.
1987 *Human Osteology: A Laboratory and Field Manual*. 3rd ed. Missouri Archaeological Society, Columbia, Missouri.

Bates, R. L. and J. A. Jackson (editors)
1987 *Glossary of Geology*. 3rd ed. American Geological Institute, Alexandria, Virginia.

Bedford, M. E., K. Russell, and C. O. Lovejoy
1989 The Utility of the Auricular Surface Aging Technique. Poster presented at the 58th Annual Meeting of the American Association of Physical Anthropologists, San Diego.

Behrensmeyer, A. K.
1978 Taphonomic and Ecologic Information from Bone Weathering. *Paleobiology* 4:150-162.

Behrensmeyer, A. K. and A. P. Hill (editors)
1980 *Fossils in the Making: Vertebrate Taphonomy and Paleoecology*. Prehistoric Archeology and Ecology Series. University of Chicago Press, Chicago.

Bennett, K. A.
1965 The Etiology and Genetics of Wormian Bones. *American Journal of Physical Anthropology* 32:463-464.

Berry, A. C.
1975 Factors Affecting the Incidence of Non-Metrical Skeletal Variants. *Journal of Anatomy* 120:519-535.

Berry, A.C. and R. J. Berry
1967 Epigenetic Variation in the Human Cranium. *Journal of Anatomy* 101:361-379.

Berry, R. J. and A. G. Searl
1963 Epigenetic Polymorphism of the Rodent Skeleton. *Proceedings. Zoological Society of London* 140:557-615.

Beynon, A. D.
1987 Replication Technique for Studying Microstructure in Fossil Enamel. *Scanning Microscopy* 1:663-669.

Biggerstaff, R. H.
1969 The Basal Area of Posterior Tooth Crown Components: The Assessment of within Tooth Variations of Premolars and Molars. *American Journal of Physical Anthropology* 31:163-170.

Billy, G.
1955 Recherche sur les Trous Parietaux. *Bulletins et Memoires. Society d'Anthropologie de Paris* 6:147-158.

Binford, L. R.
1963 An Analysis of Cremations from Three Michigan Sites. In L. R. Binford: *An Archaeological Perspective*, pp. 373-382. Seminar Press, New York.

Birkby, W. K.
1973 *Discontinuous Morphological Traits of the Skull as Population Markers in the Prehistoric Southwest*. Unpublished Ph.D. dissertation, U. of Arizona, Tuscon.

Blalock, H. M.
1979 *Social Statistics*. Revised 2nd ed. McGraw-Hill, New York.

Blumenbach, J. F.
1776 *De Generis Humani Varietate Nativa*. Dietrich, Göttingen.

1786 *Geschichte und Beschreibung der Knochen des Menschlichen Körpers*. Dietrich, Göttingen.

Bolk, L.
1916 Problems of Human Dentition. *American Journal of Anatomy* 19:91-148.

Brace, C. L., S. L. Smith, and K. D. Hunt
1991 What Big Teeth You Had Grandma! Human Tooth Size, Past and Present. In *Advances in Dental Anthropology*,edited by M. Kelley and C.S. Larsen, pp. 33-58. Wiley-Liss, New York.

Bridges, P. S.
1985 *Changes in Long Bone Structure with the Transition to Agriculture: Implications for Prehistoric Activities*. Unpublished Ph.D. dissertation, University of Michigan, Ann Arbor.

1989a Bone Cortical Area in the Evaluation of Nutrition and Activity Levels. *Human Biology* 1:785-792

1989b Changes in Activities with the Shift to Agriculture in the Southeastern United States. *Current Anthropology* 30:385-394.

1991 Skeletal Evidence of Changes in Subsistence Activities between the Archaic and Mississippian Time Periods in Northwestern Alabama. In *What Mean These Bones? Studies in Southeastern Bioarchaeology*, edited by M. L. Powell, P. S. Bridges, and A. M. W. Mires, pp. 89-101. The University of Alabama Press, Tuscaloosa and London.

Brooks, S. T. and J. M. Suchey
1990 Skeletal Age Determination Based on the Os Pubis: A Comparison of the Acsádi-Nemeskéri and Suchey-Brooks Methods. *Human Evolution* 5:227-238.

Brothwell, D. R.
1981 *Digging Up Bones*. 3rd ed. Cornell University Press, Ithaca, New York.

1989 The Relationship of Tooth Wear to Aging. In *Age Markers in the Human Skeleton*, edited by M.Y. Iscan, pp. 303-318. Charles C. Thomas, Springfield, Illinois.

Buikstra, J. E. (editor)
1981 *Prehistoric Tuberculosis in the Americas*. Scientific Papers, No. 5. Northwestern University Archaeological Program, Evanston, Illinois.

Buikstra, J. E., B. Baker, and D. C. Cook.
1993 What Diseases Plagued Ancient Egyptians? A Century of Controversy Considered. In *Biological Anthropology and the Study of Ancient Egypt*, edited by W. V. Davies and R. Walker, pp. 24-53. British Museum Press, London.

Buikstra, J. E. and D. C. Cook
1980 Paleopathology: An American Account. *Annual Review of Anthropology* 9:433-470.

Buikstra, J. E., S. R. Frankenberg, and L. W. Konigsberg
1990 Skeletal Biological Distance Studies in American Physical Anthropology: Recent Trends. *American Journal of Physical Anthropology* 82:1-7.

Buikstra, J. E. and C. C. Gordon
1981 The Study and Restudy of Human Skeletal Series: The Importance of Long Term Curation. In *The Research Potential of Anthropological Museum Collections*, edited by A.-M. Chantwell, J. B. Griffin and N. A. Rothschild. Ann. N. Y. Acad. Sci. 376: 449-465.

Buikstra, J. E. and J. H. Mielke
1985 Demography, Diet, and Health. In *The Analysis of Prehistoric Diets*, edited by R. I. Gilbert, Jr. and J. H. Mielke, pp. 359-422. Academic Press, New York.

Buikstra, J. E. and M. Swegle
1989 Bone Modification Due to Burning: Experimental Evidence. In *Bone Modification*, edited by R. Bonnichsen and M. Sorg, pp. 247-258. Center for the Study of the First Americans, Orono, Maine.

Bullington, J.
1988 *Deciduous Dental Microwear in Middle Woodland and Mississippian Populations from the Lower Illinois River Valley*. Unpublished Ph.D. dissertation, Northwestern University, Evanston, Illinois.

Burns, K. R. and W. R. Maples
1976 Estimation of Age from Individual Teeth. *Journal of Forensic Science* 21:343-356.

Burton, J. and T. D. Price
1990 The Ratio of Barium to Strontium as a Paleodietary Indicator of Consumption of Marine Resources. *Journal of Archaeological Science* 17:547-557.

Cesneys, G.
1982 Relation of Non-Metric Cranial Traits to Sex and Age in the 1st-2nd Millenia A.D. Lithuanian Craniological Materials. *Humanbiology. Budapest.* 10:19-24.

Charles, D. K., K. Condon, J. M. Cheverud, and J. E. Buikstra
1986 Cementum Annulation and Age Determination in Homo sapiens : I. Tooth Variability and Observer Error. *American Journal of Physical Anthropology* 71:311-320.

1989 Estimating Age at Death from Growth Layer Groups in Cementum. In *Age Markers in the Human Skeleton*, edited by M. Y. Iscan, pp. 277-310. Charles C. Thomas, Springfield, Illinois.

Cheverud, J. M.
1982 Phenotypic, Genetic, and Environmental Morphological Integration in the Cranium. *Evolution* 36:499-516.

Cheverud, J. M. and J. E. Buikstra
1981a Quantitiative Genetics of Skeletal Non-Metric Traits in the Rhesus Macaques on Cayo Santiago I: Single Trait Heritabilities. *American Journal of Physical Anthropology* 54:43-49.

1981b Quantitative Genetics of Skeletal Non-Metric Traits in the Rhesus Macaques on Cayo Santiago II: Phenotypic Genetic and Environmental Correlations between Traits. *American Journal of Physical Anthropology* 54:51-58.

1982 Quantitative Genetics of Skeletal Non-Metric Traits in the Rhesus Macaques on Cayo Santiago III: Relative Heritability of Skeletal Non-Metric and Metric Traits. *American Journal of Physical Anthropology* 59:151-155.

Chisholm, B. S.
1989 Variation in Diet Reconstructions Based on Stable Carbon Isotopic Evidence. In *The Chemistry of Prehistoric Human Bone*, edited by T. D. Price, pp. 10-37. Cambridge University Press, New York.

Cohen, N. N. and G. J. Armelagos (editors)
1984 *Paleopathology at the Origins of Agriculture*. Academic Press, New York.

Cole, T. M. III
1994 Size and Shape of the Femur and Tibia in Northern Plains Indians. In *Skeletal Biology in the Great Plains: Migration, Warfare, Health, and Subsistence*, edited by D. W. Owsley and R. J. Jantz, pp. 219-233. Smithsonian Press, Washington, D.C.

Coleman, W. H.
1969 Sex Differences in the Growth of the Human Bony Pelvis. *American Journal of Physical Anthropology* 31:125-151.

Collins, H. B.
1926 The Temporo-Frontal Articulation in Man. *American Journal of Physical Anthropology* 9:343-348.

Cook, D. C.
1976 *Pathological States and Disease Process in Illinois Woodland Populations: An Epidemiological Approach*. Unpublished Ph.D. dissertation, University of Chicago, Chicago.

1984 Subsistence and Health in the Lower Illinois Valley: Osteological Evidence. In *Paleopathology at the Origins of Agriculture*, edited by N. N. Cohen and G. J. Armelagos, pp. 235-269. Academic Press, Orlando, Florida.

Condon, K., D. K. Charles, J. M. Cheverud, and J. E. Buikstra
1986 Cementum Annulation and Age Determination in Homo sapiens: II. Estimates and Accuracy. *American Journal of Physical Anthropology* 71:321-330.

Conner, M. D.
1984 *Population Structure and Biological Variation in the Late Woodland of Westcentral Illinois*. Unpublished Ph.D. dissertation, University of Chicago, Chicago.

Cormie, A. B. and H. P. Schwarcz
1985 Stable Hydrogen Isotope Analysis of Bone Collagen Has Potential for Paleoclimatic Research. Abstract. Paper presented at the 20th Annual Meeeting of the Northeastern Section of the Geological Society of America, Orlando, Florida.

Corruccini, R. S.
1972 The Biological Relationships of Some Prehistoric and Historic Pueblo Populations. *American Journal of Physical Anthropology* 37:373-388.

1974 An Examination of the Meaning of Cranial Discrete Traits for Human Skeletal Biological Studies. *American Journal of Physical Anthropology* 40:425-446.

Corruccini, R. S., A. C. Aufderheide, J. S. Handler, and L. E. J. Wittmers
1987 Patterning of Skeletal Lead Content in Barbados Slaves. *Archaeometry* 29:233-239.

Cossedu, G. G., G. Floris, and G. Vona
1979 Sex and Side Differences in the Minor Non-Metrical Cranial Variants. *Journal of Human Evolution* 8:685-692.

Critchley, M. (editor in chief)
1978 *Butterworth's Medical Dictionary*. 2nd ed. Butterworths, London and Boston.

Cybulski, J.
1974 Tooth Wear and Material Culture: Precontact Patterns in the Tsimshian Area, British Columbia. *Syesis* 7:31-35.

Czarnetzki, A.
1972 Epigenetische Skelettmerkmale in Populationsvergleich II: Frequenzunterschiede Zwischen den Geschlechtern. *Zeitschrift fur Morphologie und Anthropologie* 63:341-350.

1975 On the Question of Correlation between the Size of the Epigenetic Distance and the Degree of Allopatry in Different Populations. *Journal of Human Evolution* 4:483-489.

Dahlberg, A. A.
1951 The Dentition of the American Indian. In *Papers on the Physical Anthropology of the American Indian*, edited by W. S. Laughlin, pp. 138-176. Viking Fund, New York.

1956 *Materials for the Establishment of Standards for Classification of Tooth Characteristics, Attributes, and Techniques in Morphological Studies of the Dentition*. Zoller Laboratory of Dental Anthropology, University of Chicago, Chicago.

Davida, E.
1941 Beitrage zur Persistenz der Transitorischen Nahte. *Anatomischer Anzeiger* 46:399-412.

Deol, M. S., H. Grunberg, A. G. Searle, and G. M. Truslove
1957 Genetical Differentiation Involving Morphological Characteristics in an Inbred Strain of Mice I: A British Branch of the C57BL Strain. *Journal of Morphology* 100:345-375.

De Villiers, H.
1967 *The Skull of the African Negro*. Witwatersrand University Press, Johannesburg.

DiBennardo, R. and J. V. Taylor
1983 Multiple Discriminant Function-Analysis of Sex and Race in the Postcranial Skeleton. *American Journal of Physical Anthropology* 61:305-314.

Dingwall, E. J.
1931 *Artificial Cranial Deformation*. John Bale, Sons and Danielsson, Ltd., London.

Dodo, Y.
1974 Non-Metrical Cranial Traits in the Hokkaido Ainu and the Northern Japanese of Recent Times. *Journal Anthropological Society of Nippon* 82:31-51.

1980 Appearance of Bony Bridging of the Hypoglossal Canal during the Fetal Period. *Journal Anthropological Society of Nippon* 88:229-238.

1987 Supraorbital Foramen and Hypoglossal Canal Bridging: The Two Most Suggestive Non-Metric Traits in Discriminating Major Racial Groupings of Man. *Journal Anthropological Society of Nippon* 95:19-35.

Dodo, Y. and H. Ishida
1987 Incidence of Non-Metric Cranial Variants in Several Population Samples from East Asia and North America. *Journal Anthropological Society of Nippon* 95:161-177.

Droessler, J.
1981 *Craniometry and Biological Distance: Biocultural Continuity and Change at the Late Woodland-Mississippian Interface*. Research Series No. 1.Center for American Archeology, Evanston, Illinois.

Dunbar J. B., A. E. Wolff, J. F. Volker, and P. Voller
1968 Survey of Human Periodontal Disease in Iceland. *Archives of Oral Biology* 13:387-405.

Efremov, I. A.
1940 Taphonomy: A New Branch of Paleontology. *Pan American Geologist* 74:81-93.

El-Najjar, M. Y. and K. R. McWilliams
1978 *Forensic Anthropology*. Charles C. Thomas, Springfield, Illinois.

El-Nofely, A. A. and M. Y. Iscan
1989 Assessment of Age from the Dentition in Children. In *Age Markers in the Human Skeleton*, edited by M.Y. Iscan, pp. 237-254. Charles C. Thomas, Springfield, Illinois.

Enoki, K. and A. A. Dahlberg
1958 Rotated Maxillary Central Incisors. *Orthopedics Journal Japan* 17:157-159.

Ericksen, M. F.
1973 *Age-Related Bone Remodeling in Three Aboriginal American Populations*. Unpublished Ph.D. dissertation, George Washington University, Washington D.C.

1976 Cortical Bone Loss with Age in Three Native American Populations. *American Journal of Physical Anthropology* 45:443-452.

Ericson, J. E.
1985 Strontium Isotope Characterization in the Study of Prehistoric Human Ecology. *Journal of Human Evolution* 14:503-514.

1989 Some Problems and Potentials of Strontium Isotope Analysis for Human and Animal Ecology. In *Stable Isotopes in Ecological Research*, edited by P. W. Rundel, J. R. Ehleringer, and K. A. Nagy, pp. 252-259. Ecological Studies, Volume 68. Springer-Verlag, New York.

Éry, K.
1981 *Anthropologische Analyse der Population von Tokod aus dem 5 Jahrhundert. Die Spätrömische Ferstung und das Gräberfeld von Tokod*. Akadémiai Kiadó, Budapest.

Ezzo, J. A.
1991 *Dietary Change at Grasshopper Pueblo, Arizona: The Evidence from Bone Chemistry Analysis*. Unpublished Ph.D. dissertation, University of Wisconsin, Madison.

1992a A Test of Diet versus Diagenesis at Ventana Cave, Arizona. *Journal of Archaeological Science* 19:23-37.

1992b Dietary Change and Variability at Grasshopper Pueblo, Arizona. *Journal of Anthropological Archaeology* 11:219-289.

Falconer, D. S.
1965 The Inheritance of Liability to Certain Disease, Estimated from the Incidence among Relatives. *Annals of Human Genetics* 29:51-76.

1967 The Inheritance of Liability to Certain Disease with Variable Age of Onset, with Particular Reference to Diabetes Mellitus. *Annals of Human Genetics* 31:1-20.

Fazekas, I. G. and F. Kósa
1978 *Forensic Fetal Osteology*. Akadémiai Kiadó, Budapest.

Ferembach, D., I. Schwidetzky, and M. Stoukal
1980 Recommendations for Age and Sex Diagnoses of Skeletons. *Journal of Human Evolution* 9:517-549.

Finnegan, M.
1972 *Population Definition on the Northwest Coast by Analysis of Discrete Character Variation*. Unpublished Ph.D. dissertation, University of Colorado, Boulder.

1974 Cranial and Infracranial Non-Metric Traits: Those Traits Which Are Most Important and How They May Be Handled. Abstract. *American Journal of Physical Anthropology* 41:478-479.

1978 Non-metric Variation of the Infracranial Skeleton. *Journal of Anatomy* 125:23-37.

Finnegan, M. and M. A. Faust
1974 *Bibliography of Human and Non-human Non-metric Variation*. Research Reports No. 14. Department of Anthropology, University of Massachusetts, Amherst.

1983 *Bibliography of Human and Non-human Non-metric Variation*. Supplement. Department of Anthropology, University of Massachusetts, Amherst.

Frayer, D. W.
1978 *Evolution of the Dentition in Upper Paleolithic and Mesolithic Europe*. Monographs in Anthropology No. 10. University of Kansas, Lawrence.

1980 Sexual Dimorphism and Cultural Evolution in the Late Pleistocene and Holocene of Europe. *Journal of Human Evolution* 9:399-415.

Frayer, D. W. and M. D. Russell
1987 Artificial Grooves on the Krapina Neanderthal Teeth. *American Journal of Physical Anthropology* 74:393-405.

Furuta, Y.
1982 Morphological Studies on the Mandible of Indians: The Incisura Foraminis Mandibulae and Canalis Mylohyoideus. *Okajimas Folia Anatomica Japonica* 58:1073-1102.

Gaherty, G. A.
1974 Discrete Traits, Cranial Measurements and Non-Biological Data in Africa. Abstract. *American Journal of Physical Anthropology* 40:136.

Gifford, D. P.
1981 Taphonomy and Paleoecology: A Critical Review of Archaeology's Sister Disciplines. *Advances in Archaeological Method and Theory* 4:365-438.

Gill, G. W.
1984 A Forensic Test Case for a New Method of Geographical Race Determination. In *Human Identification: Case Studies in Forensic Anthropology*, edited by T. A. Rathbun and J. E. Buikstra, pp. 329-339. Charles C. Thomas, Springfield, Illinois.

Gill, G. W. and S. Rhine (editors)
1990 *Skeletal Attribution of Race: Methods for Forensic Anthropology*. Anthropological Papers No. 4. Maxwell Museum of Anthropology, University of New Mexico, Albuquerque.

Gillespie, R.
1984 *Radiocarbon User's Handbook*. Oxford University Press, Oxford.

Goodman, A. H. and J. C. Rose
1990 Assessment of Systemic Physiological Perturbations from Dental Enamel Hypoplasias and Associated Histological Structures. *Yearbook of Physical Anthropology* 33:59-110.

Goodman, A. and J. Rose
1991 Dental Enamel Hypoplasias as Indicators of Nutritional Status. In *Advances in Dental Anthropology*, edited by M. Kelley and C. Larsen, pp. 279-294. Wiley-Liss, New York.

Goose, D. H.
1963 Dental Measurement: An Assessment of its Value in Anthropological Studies. In *Dental Anthropology*, edited by D.R. Brothwell, pp. 125-148. Symposia of the Society for the Study of Human Biology, Vol. 5. Pergamon Press, New York.

Gordon, C. C. and J. E. Buikstra
1981 Soil pH, Bone Preservation, and Sampling Bias at Mortuary Sites. *American Antiquity* 46:566-571.

Gordon, K. D.
1984a Hominoid Dental Microwear: Complications in the Use of Microwear Analysis to Detect Diet. *Journal of Dental Research* 63:1043-1046.

1984b Pitting and Bubbling Artefacts in the Surface Replicas Made with Silicone Elastomers. *Journal of Microscopy.* 134:183-188.

1988 A Review of Methodology and Quantification of Dental Microwear Analysis. *Scanning Microscopy* 2:566-571.

Green, R. F., J. M. Suchey, and D. V. Gokhale
1979 The Statistical Treatment of Correlated Bilateral Traits in the Analysis of Cranial Materials. *American Journal of Physical Anthropology* 45:61-68.

Gregg, J. B. and W. Bass
1970 Exostoses in the External Auditory Canals. *Annals of Otology, Rhinology, and Laryngology* 79:834-839.

Gregory, W. K.
1916 Studies on the Evolution of the Primates. Part 1: Cope-Osborn "Theory of Trituberculy" and the Ancestral Molar Patterns of the Primates. Part 11: Phylogeny of Recent and Extinct Anthropoids, with Special Reference to the Origin of Man. *Bulletin of the American Museum of Natural History* 35: 239-355.

Grewal, M. S.
1962 The Rate of Genetic Divergence of Sublines in the C57BL Strain of Mice. *Genetical Research* 3:226-237.

Grmek, M. D.
1989 *Diseases in the Ancient Greek World.* Johns Hopkins University Press, Baltimore.

Grüneberg, H.
1952 Genetical Studies on the Skeleton of the Mouse IV: Quasi-Continuous Variation. *Journal of Genetics* 51:95-114.

1954 Variation within Inbred Strains of Mice. *Nature* 173:674-676.

1955 Genetical Studies on the Skeleton of the Mouse XV: Relations between Major and Minor Variants. *Journal of Genetics* 53:515-535.

1963 *The Pathology of Development: A Study of Inherited Skeletal Disorders in Animals.* Blackwell, Oxford.

Guidotti, A., L. Bertelli, and A. Bastianini
1983 Variziono del Canale Ipoglosso in Crani di Feti e Neonati. *Quaderni di Anatomia Pratica* 39:1-4.

Gupta, S. and H. Polach
1985 *Radiocarbon Dating Practices at ANU.* Radiocarbon Laboratory, Research School of Pacific Studies, ANU, Canberra.

Gustafson, G.
1950 Age Determination on Teeth. *Journal of the American Dental Association* 41:45-54.

Hackett, C. J.
1967 The Human Treponematoses. In *Diseases in Antiquity*, edited by D. R. Brothwell and A. Sandison, pp. 152-169. Charles C. Thomas, Springfield.

1976 *Diagnostic Criteria of Syphilis, Yaws, and Treponarid (Treponematoses) and of Some Other Diseases in Dry Bones.* Springer-Verlag, Berlin.

Hancock, R. G. V., M. D. Grynpas, and K. P. H. Pritzker
1989 The Abuse of Bone Analyses for Archaeology Dietary Studies. *Archaeometry* 31:169-179.

Hanihara, K.
1961 Criteria for Classification of Crown Characters of the Human Deciduous Dentition. *Zinriugaku Zassi* 69:27-45.

Harris, E. F.
1977 *Anthropologic and Genetic Aspects of the Dental Morphology of Solomon Islanders, Melanesia.* Unpublished Ph.D. dissertation, Arizona State University, Tempe.

Harris, E. F. and H. L. Baillit
1980 The Metaconule: A Morphologic and Familial Analysis of a Molar Cusp in Humans. *American Journal of Physical Anthropology* 53:349-358.

Hassan, A. A., J. D. Termine, and C. V. Haynes Jr.
1977 Mineralogical Studies of Bone Apatite and Their Implications for Radiocarbon Dating. *Radiocarbon* 19:364-374.

Hauser, G. and G. F. De Stefano
1985 Variations in the Form of the Hypoglossal Canal. *American Journal of Physical Anthropology* 67:7-11.

1989 *Epigenetic Variants of the Human Skull.* Schweizerbart, Stuttgart.

Haydon, R.
1992 *Survey of Genetic Variation among the Chiribaya of the Osmore Drainage Basin, Southern Peru.* Unpublished Ph.D. dissertation, University of Chicago, Chicago.

Heathcote, G. M.
1986 *Exploratory Human Craniometry of Recent Eskaleutian Regional Groups from the Western Arctic and Subarctic of North America: A New Approach to Population Historical Reconstruction.* BAR International Series 301. British Archaeological Reports, Oxford.

Hedges, R. E. M., and I. A.
1989 The Radiocarbon Dating of Bone. *Applied Geochemistry* 4:249-253.

Hellman, M.
1928 Racial Characters in the Human Dentition. *Proceedings of the American Philosophical Society* 67:157-164.

Hensyl, W. R. (editor)
1990 *Stedman's Medical Dictionary.* 25th ed. Williams & Wilkins, Baltimore.

Holck, P.
1986 *Cremated Bones: A Medical-Anthropological Study of Archaeological Material on Cremation Burials.* Anthropologiske Skrifter 1. Anatomical Institute, University of Oslo.

Holliday, V. T. and E. Johnson
1986 Re-Evaluation of the First Radiocarbon Age for the Folsom Culture. *American Antiquity* 51:332-338.

Hooton, E. A.
1918 On Certain Eskimoid Characters in Icelandic Skulls. *American Journal of Physical Anthropology* 1:53-76.

Hori, T.
1925 Uber die Anomalien des Hinterhauptbeines. *Folia Anatomica Japonica* 3:291-312.

Howells, W. W.
1973 *Cranial Variation in Man: A Study by Multivariate Analysis of Patterns of Difference among Recent Human Populations.* Papers of the Peabody Museum 67. Peabody Museum, Harvard University, Cambridge, Mass.

1989 *Skull Shapes and the Map: Craniometric Analyses in the Dispersion of Modern Homo.* Papers of the Peabody Museum of Archaeology and Ethnology, Vol. 79. Peabody Museum, Harvard University, Cambridge, Mass.

Hrdlicka, A.
1914 *Anthropological Work in Peru in 1913, with Notes on the Pathology of the Ancient Peruvians.* Smithsonian Miscellaneous Collections, Vol. 61, No.18. Smithsonian Institution, Washington, D.C.

1920 Shovel-Shaped Teeth. *American Journal of Physical Anthropology* 3:429-465.

1924 New Data on the Teeth of Early Man and Certain Fossil European Apes. *American Journal of Physical Anthropology* 7:109-132.

1935 Ear Exostoses. *Smithsonian Miscellaneous Collections* 93:1-100. Smithsonian Institution, Washington, D.C.

1940 Mandibular and Maxillary Hyperostoses. *American Journal of Physical Anthropology* 27:1-67.

1952 [T. D. Stewart (editor)] *Practical Anthropometry.* 4th ed. Wistar Institute of Anatomy and Biology, Philadelphia.

Hudson, E. H.
1965 Treponematosis and Man's Social Evolution. *American Anthropologist* 67:885-901.

Imbelloni, J.
1937 Deformaciones Intencionales del Craneo en Sud America. *Helmintologia* 6:330-406.

Iscan, M. Y. and T. S. Cotton
1990 Osteometric Assessment of Racial Affinity from Multiple Sites in the Postcranial Skeleton. In *Skeletal Attribution of Race: Methods for Forensic Anthropology*, edited by G. W. Gill and S. Rhine, pp. 83-90. Anthropological Papers No. 4. Maxwell Museum of Anthropology, University of New Mexico, Albuquerque.

Iscan, M. and S. Loth
1986a Determination of Age from the Sternal Rib in White Males: A Test of the Phase Method. *Journal of Forensic Science* 31:122-132.

1986b Determination of Age from the Sternal Rib in White Females: A Test of the Phase Method. *Journal of Forensic Science* 31:990-999.

1986c Estimation of Age and Determination of Sex from the Sternal Rib. In *Forensic Osteology: Advances in the Identification of Human Remains*, edited by K. J. Reichs, pp. 68-89. Charles C. Thomas, Springfield, Illinois.

Jantz, R. L.
1973 Microevolutionary Change in Arikara Crania: A Multivariate Analysis. *American Journal of Physical Anthropology* 38:15-26.

1974 The Redbird Focus: Cranial Evidence in Tribal Identification. *Plains Anthropologist* 19:5-13.

Jantz, R. L. and P. H. Moore-Jansen
1988 *A Data Base for Forensic Anthropology: Structure, Context and Analysis.* Report of Investigations 47. Department of Anthropology, University of Tennessee, Knoxville.

Jantz, R. L. and D. W. Owsley
1994 White Traders in the Upper Missouri: Evidence from the Swan Creek Site. In *Skeletal Biology in the Great Plains: Migration, Warfare, Health, and Subsistence*, edited by D. W. Owsley and R. L. Jantz, pp. 189-201. Smithsonian Institution Press, Washington, D.C.

Jantz, R. L., D. W. Owsley, and P. Willey
1978 Craniometric Relationships of Central Plains Populations. In *Central Plains Tradition*, edited by D. J. Blakeslee, pp. 144-156. Report 11. Office of the Iowa State Archaeologist, Iowa City.

Jensen, B. and L. Nielsen
1968 Age Determination in the Red Fox (*Vulpes vulpes* L.) from Canine Tooth Sections. *Danish Review of Game Biology* 5:1-15.

Johanson, G.
1971 Age Determination from Human Teeth. *Odontologisk Revy* 22:1-126.

Jørgensen, K. D.
1955 The Dryopithecus Pattern in Recent Danes and Dutchmen. *Journal of Dental Research* 34:195-208.

Katz, D. and J. M. Suchey
1986 Age Determination of the Male Os Pubis. *American Journal of Physical Anthropology* 69:427-435.

1989 Race Differences in Pubic Symphyseal Aging Patterns in the Male. *American Journal of Physical Anthropology* 80:167-172.

Katzenberg, M. A.
1990 Age Differences in Stable Carbon Isotope Ratios in Prehistoric Maize Horticulturalists. Abstract. *American Journal of Physical Anthropology* 81:247.

1992 Advances in Stable Isotope Analysis of Prehistoric Bones. In *Skeletal Biology of Past Peoples: Research Methods*, edited by S. R. Saunders and M. A. Katzenberg, pp. 105-119. Wiley-Liss, New York.

Keegan, W.
1989 Stable Isotope Analysis of Prehistoric Diet. In *Reconstruction of Life from the Skeleton*, M. Y. Iscan and K. A. R. Kennedy, pp. 223-236. Alan R. Liss, New York.

Kelley, M. A. and C. S. Larsen (editors)
1991 *Advances in Dental Anthropology*.Wiley-Liss, New York.

Kennedy, K. A. R.
1989 Skeletal Markers of Occupational Stress. In *Reconstruction of Life from the Skeleton*, edited by M. Y. Iscan and K. A. R. Kennedy, pp. 129-160. Alan R. Liss, New York.

Kerley, E. R.
1965 The Microscopic Determination of Age in Human Bone. *American Journal of Physical Anthropology* 23:149-164.

Kerley, E. and D. Ubelaker
1978 Revisions in the Microscopic Method of Estimating Age at Death in Human Cortical Bone. *American Journal of Physical Anthropology* 49:545-546.

Key, P. J.
1983 *Craniometric Relationships among Plains Indians: Culture-Historical and Evolutionary Implications*. Report of Investigations No. 34. Department of Anthropology, University of Tennessee, Knoxville.

Key, P. J. and R. L. Jantz
1981 A Multivariate Analysis of Temporal Change in the Arikara Craniometrics: A Methodological Approach. *American Journal of Physical Anthropology* 55:247-259.

1990 Statistical Assessment of Population Variability: A Methodological Approach. *American Journal of Physical Anthropology* 82:53-60.

Kidder, L. and S. Stout
1986 The Intraskeletal Variability of Type II and Double Zone Osteons. Unpublished Ms.

Kilian, J.
1986 *Urcování Véku Dospel 'ych Osob Podle Chrupu* (Age Determination of Adult Individuals from the Teeth). Doktorská Disertacní Práce, Plzen.

Kilian, J. and E. Vlcek
1989 Age Determination from Teeth in the Adult. In *Age Markers in the Human Skeleton*, edited by M. Y. Iscan, pp. 255-275. Charles C. Thomas, Springfield, Illinois.

Kittel, J.
1985 Ponticulus Lateralis des Atlas. *Radiologia Diagnostica* 26:643-648.

Klodny, Y., B. Luz, and O. Navon
1983 Oxygen Isotope Variations in Phosphate of Biogenic Apatites 1: Fish Bone Apatitie — Rechecking the Rules of the Game. *Earth and Planetary Science Letters* 64:398-404.

Knussmann, R.
1988 *Anthropologie: Handbuch der Vergleichenden Biologie des Menschen*, Vol. 1, Part 1.Gustav Fischer, Stuttgart.

Konigsberg, L.
1987 *Population Genetic Models for Interpreting Prehistoric Intra-Cemetery Biological Variation*. Unpublished Ph.D. dissertation, Northwestern University, Evanston, Illinois.

Koritzer, R. T.
1977 An Anthropological Approach to the Study of Dental Pathology. In *Orofacial Growth and Development*, edited by A. A. Dahlberg and T. M. Graber, pp. 283-299. Mouton, The Hague.

Kraus, B. S. and M. Furr
1953 Lower First Premolars. *Journal of Dental Research* 32:554-564.

Krogman, W. M. and M. Y. Iscan
1986 *The Human Skeleton in Forensic Medicine*. Second Edition. Charles C. Thomas, Springfield, Illinois.

Lachmann, H.
1927 Torus Palatinus bei Degenerierten. *Zeitschrift fuer die Gesamte Neurologic und Psychiatric* 111:616-631.

Lambert, J., C. Szpunar, and J. E. Buikstra
1979 Chemical Analysis of Excavated Human Bone from Middle and Late Woodland Sites. *Archaeometry* 21:115-129.

Lambert, J. B., J. M. Weydert, S. R. Williams, and J. E. Buikstra
1990 Comparison of Methods for the Removal of Diagenetic Materials in Buried Bone. *Journal of Archaeological Science* 17:453-468.

Lambert J. B., L. Xue, and J. E. Buikstra
1991 Inorganic Analysis of Excavated Human Bone after Surface Removal. *Journal of Archaeological Science* 18:363-383.

Lane, R. A.
1977 *The Allegany Seneca: A Test of the Genetic Reliability of the Non-metric Osteological Traits for Interpopulation Analysis*. Unpublished Ph.D. dissertation, University of Texas, Austin.

Lane, R. A. and A. J. Sublett
1972 Osteology of Social Organization: Residence Pattern. *American Antiquity* 37:186-201.

Larnach, S. L. and N. W. G. Macintosh
1966 *The Craniology of the Aborigines of Coastal N.S.W.* Oceania Monographs, Sydney.

Larsen, C., R. Shavit, and M. Griffin
1991 Dental Caries Evidence for Dietary Change: An Archaeological Context. In *Advances in Dental Anthropology*, edited by M. Kelley and C. S. Larsen, pp. 179-202. Wiley-Liss, New York.

Larsen, C. S.
1984 Health and Disease in Prehistoric Georgia: Transition to Agriculture. In *Paleopathology at the Origins of Agriculture*, edited by N. N. Cohen and G. J. Armelagos, pp. 367-392. Academic Press, New York.

Larsen, C. S. (editor)
1990 *The Archaeology of Mission Santa Catalina De Guale: 2. Biocultural Interpretation of a Population in Transition*. Anthropological Papers of the American Museum of Natural History No. 68. American Museum of Natural History, New York.

Larson, M. A.
1978 *Dental Morphology of the Gran Quivera Indians*. Unpublished M.A. thesis, Arizona State University, Tempe.

Laughlin, W. S. and J. B. Jørgensen
1956 Isolate Variation in Greenlandic Eskimo Crania. *Acta Genetica et Statistica Medica* 6:3-12.

Law, I., R. Housley, N. Hammond, and E. Hedges
1991 Cuello: Resolving the Chronology through Direct Dating of Conserved and Low-Collagen Bone by AMS. *Radiocarbon* 33:303-315.

Law, I. and R. Hedges
1989 A Semi-Automated Bone Pretreatment System and the Pretreatment of Older and Contaminated Samples. *Radiocarbon* 31:247-253.

Lawrence, E. (editor)
1989 *Henderson's Dictionary of Biological Terms*. 10th ed. John Wiley & Sons, New York.

Leigh, R.
1925 Dental Pathology of Indian Tribes of Varied Environmental and Food Conditions. *American Journal of Physical Anthropology* 8:179-199.

Linc, R. and J. Fleischmann
1969 The Occurrence of Metopism in Our Present Populations and Its Relationship to Sinus Frontalis. *Anthropologie* 7:35-40.

Lisowski, F. P.
1967 Prehistoric and Early Historic Trepanation. In *Diseases in Antiquity*, edited by D. R. Brothwell and A. Sandison, pp. 651-672. Charles C. Thomas, Springfield, Illinois.

Loth, S. and M. Iscan
1987 The Effect of Racial Variation on Sex Determination from the Sternal Rib. Abstract. *American Journal of Physical Anthropology* 72:227.

1989 Morphological Assessment of Age in the Adult: The Thoracic Region. In *Age Markers in the Human Skeleton*, edited by M. Y. Iscan, pp. 105-136. Charles C. Thomas, Springfield, Illinois.

Lovejoy, C.
1985 Dental Wear in the Libben Population: Its Functional Pattern and Role in the Determination of Adult Skeletal Age at Death. *American Journal of Physical Anthropology* 68:47-56.

Lovejoy, C. O.,R. S. Meindl, T. R. Pryzbeck, and R. P. Mensforth
1985 Chronological Metamorphosis of the Auricular Surface of the Ilium: A New Method for the Determination of Age at Death. *American Journal of Physical Anthropology* 68:15-28.

Luz, B., A. B. Cormie, and H. P. Schwarcz
1990 Oxygen Isotope Variations in Phosphate of Deer Bones. *Geochimica et Cosmochimica Acta* 54:1723-1728.

McKern, T. and T. D. Stewart
1957 *Skeletal Age Changes in Young American Males, Analyzed from the Standpoint of Identification*. Technical Report EP-45. Headquarters, Quartermaster Research and Development Command, Natick, Massachusetts.

McWilliams, K. R.
1974 *Gran Quivera Pueblo and Biological Distance in the U.S. Southwest*. Unpublished Ph.D. Dissertation, University of Arizona, Tucson.

Mann, R. W., S. A. Symes, and W. M. Bass
1987 Maxillary Suture Obliteration: Aging the Human Skeleton Based on Intact or Fragmentary Maxilla. *Journal of Forensic Sciences* 32:148-157.

Mann, R. W. and S. P. Murphy
1990 *Regional Atlas of Bone Disease*. Charles C. Thomas, Springfield, Illinois.

Maples, W.
1978 An Improved Technique Using Dental Histology for Estimation of Adult Age. *Journal of Forensic Science* 23:764-770.

Maples, W. and P. Rice
1979 Some Difficulties in the Gustafson Dental Estimation. *Journal of Forensic Science* 24:168-172.

Martin, D.
1983 *Paleophysiological Aspects of Bone Remodeling in the Meroitic, X-group and Christian Populations from Sudanese Nubia*. Unpublished Ph.D. dissertation, University of Massachusetts, Amherst.

Martin, D. L. and G. J. Armelagos
1985 Skeletal Remodeling and Mineralization as Indicators of Health: An Example from Prehistoric Sudanese Nubia. *Journal of Human Evolution* 14:527-237.

Martin, D. L., A. H. Goodman, and G. J. Armelagos
1985 Skeletal Pathologies as Indicators of Quality and Quantity of Diet. In *The Analysis of Prehistoric Diets*, edited by R. J. Gilbert and J. H. Mielke, pp. 227-279. Academic Press, Orlando, Florida.

Martin R.
1957 [K Saller (editor)] *Lehrbuch der Anthropologie in Systematischer Darstellung*. Revised 3rd ed. Gustav Fischer Verlag, Stuttgart.
1979 [K Saller (editor)] *Lehrbuch der Anthropologie in Systematischer Darstellung*. Gustav Fischer Verlag, Stuttgart.

Masset, C.
1989 Age Estimation on the Basis of Cranial Sutures. In *Age Markers in the Human Skeleton*, edited by M. Y. Iscan, pp. 71-103. Charles C Thomas, Springfield, Illinois.

Masters, P. M.
1987 Preferential Preservation of Noncollagenous Protein during Bone Diagenesis: Implications for Chronometric and Stable Isotopic Measurements. *Geochimica et Cosmochimica Acta* 51:3209-3214.

Mayhall, J.
1976 *The Morphology of the Permanent Dentition of Prehistoric and Modern Central Arctic Eskimos: A Study of their Biological Relationships*. Unpublished Ph.D. dissertation, University of Chicago, Chicago.

1992 Techniques for the Study of Dental Morphology. In *Skeletal Biology of Past Peoples: Research Methods*, edited by S. R. Saunders and M. A. Katzenberg, pp. 59-78. Wiley-Liss, New York.

Meindl, R. S. and C. O. Lovejoy
1985 Ectocranial Suture Closure: A Revised Method for the Determination of Skeletal Age at Death Based on the Lateral-Anterior Sutures. *American Journal of Physical Anthropology* 68:57-66.

1989 Age Changes in the Pelvis: Implications for Paleodemography. In *Age Markers in the Human Skeleton*, edited by M. Y. Iscan, pp. 137-168. Charles C. Thomas, Springfield, Illinois.

Meindl, R. S., C. O. Lovejoy, R. M. Mensforth, and L. D. Carlos
1985 Accuracy and Direction of Error in Sexing of the Skeleton: Implications for Paleodemography. *American Journal of Physical Anthropology* 68:29-45.

Merbs, C.F.
1983 *Patterns of Activity-Induced Pathology in a Canadian Inuit Population*. National Museum of Man Mercury Series, Archaeological Survey of Canada No. 119. National Museum of Man, Ottawa.

Meyer, K.
1949 Uber den Einflub des Badens auf die Exostosenbildung im Auberen Gehogang (Klinische und Pathogenetische Untersuchungen). *Zeitschrift fuer Laryngologie, Rhinologie, Otologie, und Ihre Grenzgebiete* 28:480-492.

Miles, A.
1962 Assessment of the Ages of a Population of Anglo-Saxons from Their Dentitions. *Proceedings of the Royal Society of Medicine* 55:881-886.

1963 Dentition in the Estimation of Age. *Journal of Dental Research* 42:255-263.

1978 Teeth as an Indicator of Age in Man. In *Development, Function, and Evolution of Teeth*, edited by P. Butler and K. Joysey, pp. 455-464. Academic Press, New York.

Miller, S. C. and H. Roth
1940 Torus Palatinus: A Statistical Study. *Journal of the American Dental Association* 27:1950-1957.

Milner, G. R.
1992 Determination of Skeletal Age and Sex: A Manual Prepared for the Dickson Mounds Reburial Team. Ms. on file, Dickson Mounds Museum, Lewiston, Illinois.

Milner, G. R., E Anderson, and V G. Smith
1991 Warfare in Late Prehistoric West-Central Illinois. *American Antiquity* 56:581-603.

Møller-Christensen, V.
1967 Evidence of Leprosy in Earlier Peoples. In *Diseases in Antiquity*, edited by D. R. Brothwell and A. Sandison, pp. 295-306. Charles C. Thomas, Springfield, Illinois.

Molto, J. E.
1983 *Biological Relationships of Southern Ontario Woodland Peoples: The Evidence of Discontinuous Cranial Traits*. National Museum of Man Mercury Series, Archaeological Survey of Canada Paper 117. National Museum of Man, Ottawa.

Montagu, M. F. A.
1940 The Significance of the Variability of the Upper Lateral Incisor Teeth in Man. *Human Biology* 12:323-358.

1960 *A Handbook of Anthropometry*. Charles C. Thomas, Springfield, Illinois.

Moore, K., M. Murray, and M. J. Schoeninger
1989 Effects of Preservatives on Trace Elements and Stable Isotope Analysis of Bone. *Journal of Archaeological Science* 16:437-446.

Moore, W. J. and M. E. Corbett
1971 The Distribution of Dental Caries in Ancient British Populations 1: Anglo-Saxon period. *Caries Research* 5:151-168.

Moorees, C. F. A.
1957 *The Aleut Dentition: A Correlative Study of Dental Characteristics in an Eskimoid People*. Harvard University Press, Cambridge, Mass.

Moorees, C. F. A., E. A. Fanning, and E. E. Hunt
1963a Formation and Resorption of Three Deciduous Teeth in Children. *American Journal of Physical Anthropology* 21:205-213.

1963b Age Formation by Stages for Ten Permanent Teeth. *Journal of Dental Research* 42:1490-1502.

Moorees, C. F. A., R. H. Osbourne, and E. Wilde
1952 Torus Mandibularis: Its Occurrence in Aleut Children and Its Genetic Determinants. *American Journal of Physical Anthropology* 10:319-328.

Moore-Jansen, P. M., S.D. Ousley, and R. L. Jantz
1994 *Data Collection Procedures for Forensic Skeletal Material*. Report of Investigations No. 48. Department of Anthropology, University of Tennessee, Knoxville.

Morgan, M. E. and M. J. Schoeninger
1989 Zinc and Strontium as Dietary Indicators in a Modern Tropical Community. *American Journal of Physical Anthropology* 78:276 .

Morris, D. H.
1970 On Deflecting Wrinkles and the Dryopithecus Pattern in Human Mandibular Molars. *American Journal of Physical Anthropology* 32:97-104.

1975 Bushmen Maxillary Canine Polymorphisms. *South African Journal of Science* 71:333-335.

Morris D. H., A. A. Dahlberg, and S. Glasstone-Hughes
1978 The Uto-Aztecan Premolar: The Anthropology of a Dental Trait. In *Development, Function and Evolution of Teeth*, edited by P. M. Butler and K. A. Joysey, pp. 69-79. Academic Press, London.

Morris, N. T.
1970 The Occurrence of the Mandibular Torus at Gran Quivera. Unpublished M.A. thesis, Arizona State University, Tempe.

Morton, S. G.
1839 *Crania Americana*. Philadelphia.

Mouri, T.
1976 A Study of Non-Metrical Cranial Variants of the Modern Japanese in the Kinki District. *Journal. Anthropological Society of Nippon* 84:191-203.

Movsesjan, A. A., N. N. Mamonova, and J. C. Rychkov
1975 Programma in Metodika Issledovanija Anomalij Cerepa. *Voprosy Antropologii* 51:127-150.

Muller, H.
1977 Caracteres Non-Metriques du Squelette de la Tete chez les Populations Medievals de Thoiry (Ain, France) et de Bavois (Vaud, Suisse). *Archives Suisses d'Anthropologie Generale* 41:123-164.

Murphy, T. R.
1959a The Changing Pattern of Dentine Exposure in Human Tooth Attrition. *American Journal of Physical Anthropology* 17:167-178.

1959b Gradients of Dentine Exposure in Human Tooth Attrition. *American Journal of Physical Anthropology* 17:179-185.

Neiberger, E. J.
1978 Incidence of Torsiversion in Mandibular Third Molars. *Journal of Dental Research* 57:209-212.

Neumann, G.
1942 Types of Artificial Cranial Deformation in the Eastern United States. *American Antiquity* 7:306-310.

Neuman, H. and D. Poole
1974 Observations with Scanning and Transmission Electron Microscopy on the Structure of Human Surface Enamel. *Archives of Oral Biology* 19:1135-1143.

Nichol, C. R., and C. G. Turner II
1986 Intra- and Interobserver Concordance in Classifying Dental Morphology. *American Journal of Physical Anthropology* 69:299-315.

Nichol, C. R., C. G. Turner II, and A. A. Dahlberg
1984 Variation in the Convexity of the Human Maxillary Incisor Labial Surface. *American Journal of Physical Anthropology* 63:361-370.

Oetteking, B.
1930 Craniology of the North Pacific Coast. Jessup North Pacific Expedition. *Memoir of the American Museum of Natural History* 15:1-391.

Olivier, G.
1969 *Practical Anthropology*. Charles C. Thomas, Springfield, Illinois.

Ortner, D. J. and W. G. J. Putschar
1985 *Identification of Pathological Conditions in Human Skeletal Remains*. Smithsonian Institution Press, Washington, D.C.

Ossenberg, N. S.
1969 *Discontinuous Morphological Variation in the Human Cranium*. Unpublished Ph.D. dissertation, University of Toronto, Toronto.

1970 The Influence of Artificial Cranial Deformation on Discontinuous Morphological Traits. *American Journal of Physical Anthropology* 33:357-372.

O'Toole, M. (editor)
1992 *Miller-Keane Encyclopedia & Dictionary of Medicine, Nursing, & Allied Health*. 5th ed. W. B. Saunders Company, Philadelphia.

Owsley, D. W., S. M. Bennett, and R. L. Jantz
1982 Inter-Cemetery Morphological Variation in Arikara Crania from the Mobridge Site (39 WWM). *American Journal of Physical Anthropology* 58:179-185.

Owsley, D. W., D. F. Morey, and W. B. Turner
1981 Inferring History from Crania: Biological Distance Comparisons of Mill Creek and Early Middle Missouri Tradition Crania with Mandan and Arikara Population Samples. *Plains Anthropologist* 17:49-56.

Paabo, S.
1985 Preservation of DNA in Ancient Egyptian Mummies. *Journal of Archaeological Science* 12:411-417.

1989 Ancient DNA: Extraction, Characterization, Molecular Cloning, and Enzymatic Amplification. *Proceedings of the National Academy of Sciences* 86:6196-6200.

Pederson, P. O.
1949 The East Greenland Eskimo Dentition. *Med om Gronland* 142:1-256.

Perizonius, W. K. R.
1979 Non-Metrical Cranial Traits: Sex Difference and Age Dependence. *Journal of Human Evolution* 8:679-684.

Phenice, T.
1969 A Newly Developed Visual Method of Sexing in the Os Pubis. *American Journal of Physical Anthropology* 30:297-301.

Pietrusewsky, M.
1990 Craniofacial Variation in Australasian and Pacific Populations. *American Journal of Physical Anthropology* 82:319-340.

Piontek, J.
1979 Natural Selection and Microevolutionary Variability of Non-Metric Traits in Medieval Populations of Poland. *Studies in Physical Anthropology* 5:95-110.

Powell, M. L.
1985 The Analysis of Dental Wear and Caries for Dietary Reconstruction. In *The Analysis of Prehistoric Diet*, edited by R. I. Gilbert and J. H. Mielke, pp. 307-338. Academic Press, Orlando, Florida.

1988 *Status and Health in Prehistory: A Case Study of the Moundville Chiefdom*. Smithsonian Institution Press, Washington, D.C.

Price, T. D. (editor)
1989 *The Chemistry of Prehistoric Human Bone*. School of American Research Advanced Seminar Series. Cambridge University Press, Cambridge.

Pyo, J. and R. M. Lowman
1959 The "Ponticulus Posticus" of the First Cervical Vertebra. *Radiology* 72:850-854.

Ragsdale, B. D.
1993 Morphologic Analysis of Skeletal Lesions: Correlation of Imaging Studies and Pathologic Findings. *Advances in Pathology and Laboratory Medicine* 6:445-490.

Recker, R. R. (editor)
1983 *Bone Histomorphometry: Techniques and Interpretation*. CRC Press, Boca Raton, Florida.

Redfield, A.
1970 A New Aid to Aging Immature Skeletons: Development of the Occipital Bone. *American Journal of Physical Anthropology* 33:217-220.

Richards, G. D. and S. C. Anton
1991 Craniofacial Configuration and Postcranial Development of a Hydrocephalic Child (ca. 2500 B.C.-500 A.D.). *American Journal of Physical Anthropology* 54:185-200.

Richman, E., D. Ortner, and F. Schulter-Ellis
1979 Differences in Intracortical Bone Remodeling in Three Aboriginal American Populations: Possible Dietary Factors. *Calcified Tissue International* 28:209-214.

Riesenfeld, A.
1956 Multiple Infraorbital, Ethmoidal and Mental Foramina in the Races of Man. *American Journal of Physical Anthropology* 14:85-100.

Rightmire G. P.
1970 Bushman, Hottentot and South African Negro Crania Studied by Distance and Discrimination. *American Journal of Physical Anthropology* 33:147-168.

1972 Cranial Measurements and Discrete Traits Compared in Distance Studies of African Negro Skulls. *Human Biology* 44:263-276.

Rogan, P. K. and J. Salvo
1990 Study of Nucleic Acids Isolated from Ancient Remains. *Yearbook of Physical Anthropology* 60:359-381.

Rogers, S. L.
1984 *The Human Skull: Its Mechanics, Measurements, and Variations.* Charles C. Thomas, Springfield, IL.

Rohlf, F. J. and R. R. Sokal
1981 *Statistical Tables.* 2nd ed. W.H. Freeman & Co., San Francisco.

Romanus, T. and A. Tovi
1964 A Variation of the Atlas. *Acta Radiologica. Series One. Diagnosis* 2:289-297.

Rose, J. C. (editor)
1985 *Gone to a Better Land.* Arkansas Archaeological Survey Research Series No. 25. Arkansas Archeological Survey, Fayetteville.

Rose, J.C., S. C. Anton, A. C. Aufderheide, L. Eisenberg, J. B. Gregg, E. J. Neiburger, and B. Rothschild
1991 *Skeletal Database Committee Recommendations.* Paleopathology Association, Detroit.

Rose, J., A. Burnett, M. Nassaney, and M. Blaeuer
1984 Paleopathology and the Origins of Maize Agriculture in the Lower Mississippi Valley and Caddoan Culture Areas. In *Paleopathology at the Origins of Agriculture*, edited by M. Cohen and G. Armelagos, pp. 393-425. Academic Press, Orlando.

Rose, J., K. Condon, and A. Goodman
1985 Diet and Dentition: Developmental Disturbances. In *The Analysis of Prehistoric Diets*, edited by R. Gilbert and J. Mielke, pp. 281-305. Academic Press, Orlando.

Rose, J. and A. Harmon
1986 Enamel Microwear and Prehistoric North American Diets. Abstract. *American Journal of Physical Anthropology* 69: 257.

Rose, J. C., M. K. Marks, and L. L. Tieszen
1991 Bioarchaeology and Subsistence in the Central and Lower Portions of the Mississippi Valley. In *What Mean These Bones?*, edited by M. Powell, P. Bridges, and A. Mires, pp. 7-21. University of Alabama Press, Tuscaloosa.

Rösing, F. W.
1982 Discrete des Menschlichen Skeletts-ein Kritischer Uberblick. *Homo* 33:100-125.

Rothhammer, F. and C. Silva
1990 Craniometrical Variation among South American Prehistoric Populations: Climatic, Altitudinal, Chronological and Geographic Contributions. *American Journal of Physical Anthropology* 82:9-18.

Rothschild, B. M., K. R. Turner, and M. A. DeLuca
1988 Symmetrical Erosive Peripheral Polyarthritis in the Late Archaic Period of Alabama. *Science* 241:1498-1501.

Rothschild, B. M., R. J. Woods, and W. Ortel
1990 Rheumatoid Arthritis "in the Buff": Erosive Arthritis in Defleshed Bones. *American Journal of Physical Anthropology* 82:441-449.

Rudney, J. D., R. V. Katz, and J. W. Brand
1983 Interobserver Reliability of Methods of Paleopathological Diagnosis of Dental Caries. *American Journal of Physical Anthropology* 62:243-248.

Ruff, C.
1992 Biomechanical Analysis of Archaeological Human Skeletal Samples. In *Skeletal Biology of Past Peoples: Research Methods*, edited by S. R. Saunders and M. A. Katzenberg, pp. 37-58. Wiley-Liss, New York.

Ruff, C. B. and W. C. Hayes
1983a Cross-Sectional Geometry of Pecos Pueblo Femora and Tibiae — A Biomechanical Investigation I: Method and General Patterns of Variation. *American Journal of Physical Anthropology* 60:359-381.

1983b Cross-Sectional Geometry of Pecos Pueblo Femora and Tibiae — A Biomechanical Investigation II: Sex, Age and Side Differences. *American Journal of Physical Anthropology* 60:383-400.

Ruff, C. B., C. S. Larsen, and W. C. Hayes
1984 Structural Changes in the Femur with the Transition to Agriculture on the Georgia Coast. *American Journal of Physical Anthropology* 64:125-136.

Ruff, C. B. and C. S. Larsen
1990 Postcranial Biomechanical Adaptations to Subsistence Changes on the Georgia Coast. In *The Archaeology of Mission Santa Catalina de Guale: 2. Biocultural Intepretations of a Population in Transition*, edited by C. S. Larsen. *Anthropological Paper of the American Museum of Natural History* 68:94-120.

Ruff, C. and F. Leo
1986 Use of Computed Tomography in Skeletal Structural Research. *Yearbook of Physical Anthropology* 29:181-195.

Ruttin, E.
1933 Uber Exostosen und Hyperostosen des Auberen Gehorganges. *Acta Otolaryngolica.* 18:381-445.

Sandford, M.
1992 A Reconsideration of Trace Element Analysis in Prehistoric Bone. In *Skeletal Biology of Past Peoples: Research Methods*, edited by S. R. Saunders and M. A. Katzenberg, pp. 79-104. Wiley-Liss, New York.

Saunders, S.
1978 *The Development and Distribution of Discontinuous Morphological Variation of the Human Infracranial Skeleton.* National Museum of Man Mercury Series, Archaeological Survey of Canada, No. 81. National Museum of Man, Ottawa.

1992 Subadult Skeletons and Growth Related Studies. In *Skeletal Biology of Past Peoples: Research Methods*, edited by S. R. Saunders and M. A. Katzenberg, pp. 1-20. Wiley-Liss, New York.

Saunders, S. R. and F. Popovich
1978 A Family Study of Two Skeletal Variants: Atlas Bridging and Clinoid Bridging. *American Journal of Physical Anthropology* 49:193-203.

Sawin, P. and M. Hamlet
1972 Morphogenetic Studies of the Rabbit XLII. Growth Gradients, Epigenetic Variants, and Function. *The American Journal of Anatomy* 135:105-117.

Sawyer, D. R., M. J. Allison, R. P. Elizay, and A. Pezzia
1978 The Mylohyoid Bridge of Pre-Columbian Peruvians. *American Journal of Physical Anthropology* 48:9-16.

Scarsini, C., V. Rossi, and P. Messeri
1980 Caratteri Cranici Discontinui in Sardi de Nuoro. *Se. Sci. Anthropol.* 2:1-127.

Schoeninger, M. J.
1979 Diet and Status at Chalcatzingo: Some Empirical and Technical Aspects of Strontium Analysis. *American Journal of Physical Anthropology* 51:295-310.

1980 *Changes in Human Subsistence Activities from the Middle Paleolithic to the Neolithic Period in the Middle East*. Unpublished Ph.D. dissertation, University of Michigan, Ann Arbor.

1989a Prehistoric Human Diet. In *Chemistry of Prehistoric Human Bone*, edited by T. D. Price, pp. 38-67. Cambridge U. Press, Cambridge.

1989b Reconstructing prehistoric human diet. *Homo* 39: 78-99.

1990 Anthropology: Carbon Isotope Ratios. In *McGraw-Hill Yearbook of Science and Technology 1991*, edited by S. P. Parker, pp. 16-18. Mc Graw-Hill, New York.

Schoeninger, M. J. and K. Moore
1992 Bone Stable Isotope Studies in Archaeology. *Journal of World Prehistory* 5:247-296.

Schoeninger, M. J., K. M. Moore, M. L. Murray, and J. C. Kingston
1989 Detection of Bone Preservation in Archaeological and Fossil Samples. *Applied Geochemistry* 4:281-292.

Schultz, A. H.
1930 The Skeleton of the Trunk and Limbs of Higher Primates. *Human Biology* 2:303-438.

Schultz, P.
1977 Task Activity and Anterior Tooth Grooving in Prehistoric California Indians. *American Journal of Physical Anthropology* 46:87-91.

Schwalbe, G.
1901 Uber die Fontanella Metopica Medio-Frontalis und Ihre Bildungen. *Zeitschrift fuer Morphologie und Anthropologie* 3:93-129.

Schwarcz, H. and M. J. Schoeninger
1991 Stable Isotope Analyses in Human Nutritional Ecology. *Yearbook of Physical Anthropology*. 34:283-321.

Sciulli, P. W.
1979 Size and Morphology of the Permanent Dentition in Prehistoric Ohio Valley Amerindians. *American Journal of Physical Anthropology* 50: 615-628.

1990 Cranial Metric and Discrete Trait Variation and Biological Differentiation in the Terminal Late Archaic of Ohio: The Duff Site Cemetery. *American Journal of Physical Anthropology* 82:19-30.

Sciulli, P. W. and R. M. Granby
1989 Analysis of the Ft. Laurens, Ohio, Skeletal Sample. *American Journal of Physical Anthropology* 80:11-24.

Scott, E. C.
1979 Dental Wear Scoring Technique. *American Journal of Physical Anthropology* 51:213-218.

Scott, G. R.
1973 *Dental Morphology: A Genetic Study of American White Families and Variations in the Living Southwest Indians*. Ph.D. dissertation, Arizona State University, Tempe.

1977 Classification, Sex Dimorphism, Association, and Population Variation of the Canine Distal Accessory Ridge. *Human Biology* 49:453-469.

1980 Population Variability of Carabelli's Trait. *Human Biology* 52:63-78.

Scott, G. R. and C. G. Turner II
1988 Dental Anthropology. *Annual Review of Anthropology* 17:99-126.

Selby, S., S. M. Garn, and V. Kanareff
1955 The Incidence and Familial Nature of a Bony Bridge on the First Cervical Vertebrae. *American Journal of Physical Anthropology* 13: 129-141.

Self, S. G. and L. Leamy
1978 Heritability of Quasi-Continuous Skeletal Traits in a Random Bred Population of House Mouse. *Genetics* 88:109-120.

Shemesh, A., Y. Kolodny, and B. Luz
1983 Oxygen Isotope Variations in Phosphate of Biogenic Apatites II: Phosphorite Rocks. *Earth and Planetary Science Letters* 64:405-416.

Shepherd, F. J.
1893 Symmetrical Depressions on the Exterior Surface of the Parietal Bones. *Journal of Anatomy and Physiology* 27:501-504.

Shipman, P., G. Foster, and M. J. Schoeninger
1984 Burnt Bones and Teeth: An Experimental Study of Color, Morphology, Crystal Structure and Shrinkage. *Journal of Archaeological Science* 11:307-325.

Sillen, A. and G. J. Armelagos
1991 Introduction to the Second Advanced Seminar in Paleodietary Research. *Journal of Archaeological Science* 18:225-226.

Sillen, A. and M. Kavanagh
1982 Strontium and Paleodietary Research: A Review. *Yearbook of Physical Anthropology* 25:67-90.

Sillen, A., J. C. Sealy, and N. J. van der Merwe
1989 Chemistry and Paleodietary Research: No More Easy Answers. *American Antiquity* 54:504-512.

Sillen, A. and P. Smith
1984 Weaning Patterns Are Reflected in Strontium-Calcium Ratios of Juvenile Skeletons. *Journal of Archaeological Science* 11:237-245.

Sjøvold, T.
1984 A Report on the Heritability of Some Cranial Measurements and Non-metric Traits. In *Multivariate Statistics in Physical Anthropology*, edited by G.N. Van Vark and W.W. Howells, pp. 223-246. D. Reidel, Dordrecht, The Netherlands.

Smith, B. H.
1984 Patterns of Molar Wear in Hunter-Gatherers and Agriculturalists. *American Journal of Physical Anthropology* 63:39-56.

1991 Standards of Human Tooth Formation and Dental Age Assessment. In *Advances in Dental Anthropology*, edited by M. Kelley and C. S. Larsen, pp. 143-168. Wiley-Liss, New York.

Snow, C. E.
1948 *Indian Knoll Skeletons*. U. of Kentucky, Lexington.

Sokal, R. R. and F. J. Rohlf
1981 *Biometry*. 2nd ed. W.H. Freeman, San Francisco.

Steele, D. G. and C. A. Bramblett
1988 *The Anatomy and Biology of the Human Skeleton*. Texas A&M University Press, College Station, Texas.

Steinbock, R. T.
1976 *Paleopathological Diagnoses and Interpretation*. Charles C. Thomas, Springfield, IL.

Stewart, T.
1941 The Circular Type of Cranial Deformity in the United States. *American Journal of Physical Anthropology* 28:343-351.

1973 *The Peopling of America*. Charles Scribner's Sons, New York.

Stott, G., R. Sis, and B. Levy
1982 Cementum Annulation as an Age Criterion in Forensic Dentistry. *Journal of Dental Research* 61:814-817.

Stout S. D.
1986 The Use of Bone Histomorphometry in Skeletal Identification: The Case of Francisco Pizzarro. *Journal of Forensic Science* 31:296-300.

1989a Histomorphometric Analysis of Human Skeletal Remains. In *Reconstruction of Life from the Skeleton*, edited by M. Y. Iscan and K. A. R. Kennedy, pp. 41-52. Alan R. Liss, New York.

1989b The Use of Cortical Bone Histology to Estimate Age at Death. In *Age Markers in the Human Skeleton*, edited by M. Y. Iscan, pp. 195-207. Charles C. Thomas, Springfield, IL.

1992 Methods of Determining Age at Death Using Bone Microstructure. In *Skeletal Biology of Past Peoples: Research Methods*, edited by S. R. Saunders and M. A. Katzenberg, pp. 21-35. Wiley-Liss, New York.

Stout, S. D. and S. J. Gehlert
1980 The Relative Accuracy and Reliability of Histological Aging Methods. *Forensic Science International* 15:181-190.

Stout, S. and D. Simmons
1979 Use of Histology in Ancient Bone Research. *Yearbook of Physical Anthropology* 44:263-270.

Stuart-Macadam, P.
1985 Porotic Hyperostosis: Representative of a Childhood Condition. *American Journal of Physical Anthropology* 66:391-398.

Suchey, J. and D. Katz
1986 Skeletal Age Standards Derived from an Extensive Multiracial Sample of Modern Americans. Abstract. *American Journal of Physical Anthropology* 69:269.

Suchey, J. M., P. A. Owings, D. V Wiseley, and T. T. Noguchi
1984 Skeletal Aging of Unidentified Persons. In *Human Identification: Case Studies in Forensic Anthropology*, edited by T. A. Rathbun and J. E. Buikstra, pp. 278-297. Charles C. Thomas, Springfield, Illinois.

Suzuki, M. and T. Sakai
1960 A Familial Study of Torus Palatinus and Torus Mandibularis. *American Journal of Physical Anthropology* 18:263-272.

Symmers, W. S. C.
1895 A Skull with Enormous Parietal Foramina. *Journal of Anatomy and Physiology* 29:329-330.

Teaford, M. F.
1988 A Review of Dental Microwear and Diet in Modern Mammals. *Scanning Microscopy* 2:1149-1166.

1991 Dental Microwear: What Can It Tell Us about Diet and Dental Function? In *Advances in Dental Anthropology*, edited by M. Kelley and C. S. Larsen, pp. 341-356. Wiley-Liss, New York.

Teaford, M. F. and O. J. Oyen
1989 Live primates and Dental Replication: New Problems and New Techniques. *American Journal of Physical Anthropology* 80:73-81.

Todd, T. W.
1921a Age Changes in the Pubic Bone. I: The Male White Pubis. *American Journal of Physical Anthropology* 3:285-334.

1921b Age Changes in the Pubic Bone. III: The Pubis of the White Female. IV: The pubis of the female white-negro hybrid. *American Journal of Physical Anthropology* 4:1-70.

Todd, T. W. and Lyon, D. W. Jr.
1924 Endocranial Suture Closure, Its Progress and Age Relationship. Part I. Adult Males of White Stock. *American Journal of Physical Anthropology* 7:325-384.

1925a Cranial Suture Closure, Its Progress and Age Relationship. Part II. Ectocranial Closure in Adult Males of White Stock. *American Journal of Physical Anthropology* 8:23-45.

1925b Cranial Suture Closure: Its Progress and Age Relationship. Part III. Endocranial Closure in Adult Males of Negro Stock. *American Journal of Physical Anthropology* 8:47-71.

1925c Cranial Suture Closure: Its Progress and Age Relationship. Part IV. Ectocranial Closure in Adult Males of Negro Stock. *American Journal of Physical Anthropology* 8:149-168.

Tomes, C. S.
1923 *A Manual of Dental Anatomy, Human and Comparative*. 8th ed. H. W. Marett-Tims H. W. (editor). J. and A. Churchill, London.

Torgersen, J. H.
1951a Asymmetry and Skeletal Maturation. *Acta Radiologica* 36:521-523.

1951b Hereditary Factors in the Sutural Pattern of the Skull. *Acta Radiologica* 36:374-382.

1963 Uber Erbfaktoren fur die Asusbildung von Schadelnahten und Deren Aussageweret uber den Hominisationsablauf. *Homo* 14:16-29.

Trotter, M. and G. C. Gleser
1958 A Re-Evaluation of Estimation of Stature Based on Measurements of Stature Taken during Life and of Long Bones after Death. *American Journal of Physical Anthropology* 16:79-123.

Turner, C. G. II
1967 *The Dentition of Archaic Peoples*. Unpublished Ph.D. dissertation, University of Wisconsin, Madison.

1970 New Classification of Non-Metrical Dental Variation: Cusps 6 and 7. Paper presented at the 39th Annual Meeting of the American Association of Physical Anthropologists, Washington, D. C.

1971 Three-Rooted Mandibular First Permanent Molars and the Question of American Indian Origins. *American Journal of Physical Anthropology* 34:229-242.

1979 Dental Anthropological Indications of Agriculture among the Jomon People of Japan X: Peopling of the Pacific. *American Journal of Physical Anthropology* 51:619-636.

1981 Root Number Determination in Maxillary First Premolars for Modern Human Populations. *American Journal of Physical Anthropology* 54:59-62.

1983 Taphonomic Reconstruction of Human Violence and Cannibalism Based on Mass Burials in the American Southwest. In *Carnivores, Human Scavengers and Predators: A Question of Bone Technology*, edited by G. M. LeMoine and A. S. MacEachern, pp. 219-240. Archaeological Association of the University of Calgary, Calgary.

1989 Teeth and Prehistory in Asia. *Scientific American* 260:88-96.

Turner, C. G. II and J. D. Caiden
1969 Dental Chipping in Aleuts, Eskimos, and Indians. *American Journal of Physical Anthropology* 31:303-310.

Turner, C. G. II and L. M. C. Machado
1983 A New Dental Wear Pattern and Evidence for High Carbohydrate Consumption in a Brazilian Archaic Skeletal Population. *American Journal of Physical Anthropology* 61:125-130.

Turner, C. G. II and N. Morris
1970 A Massacre at Hopi. *American Antiquity* 35:320-331.

Turner II, C. G., C. Nichol, and G. Scott
1991 Scoring Procedures for Key Morphological Traits of the Permanent Dentition: The Arizona State University Dental Anthropology System. In *Advances in Dental Anthropology*, edited by M. Kelley and C. S. Larsen, pp. 13-31. Wiley-Liss, New York.

Turner II, C. G. and G. R. Scott
1977 Dentition of Eastern Islanders. In *Orofacial Growth and Development*, edited by A. A. Dahlberg and T. M. Graeber, pp. 229-249. Mouton, The Hague.

Turner II, C. G. and J. A. Turner
1990 Perimortem Damage to Human Skeletal Remains from Wupatki National Monument, Northern Arizona. *The Kiva* 55:187-212.

1992 The First Claim for Cannibalism in the Southwest: Walter Hough's 1901 Discovery at Canyon Butte Ruin 3, Northeastern Arizona. *American Antiquity* 57:661-682.

Tuross, N.
1989 Albumin Preservation in the Taima-Taima Mastodon Skeleton. *Applied Geochemistry* 4:255-259.

Tuross, N., A. K. Behrensmeyer, E. D. Eanes, L. W. Fisher, and P. E. Hare
1989 Molecular Preservation and Crystallographic Alterations in a Weathering Sequence of Wildebeeste Bones. *Applied Geochemistry* 4:261-270.

Tuross, N., M. Fogel, and D. W. Owsley
1994 Duration of Breast Feeding among Hunter-Gatherers and Maize Agriculturalists. *American Journal of Physical Anthropology* (submitted).

Ubelaker, D. H.
1982 The Development of American Paleopathology. In *A History of American Physical Anthropology 1930-1980*, edited by F. Spencer, pp. 337-356. Academic Press, New York.

1987 Estimating Age at Death from Immature Human Skeletons: An Overview. *Journal of Forensic Sciences* 32:1254-1263.

1989a *Human Skeletal Remains*. 2nd ed. Taraxacum Press, Washington, D. C.

1989b The Estimation of Age at Death from Immature Human Bone. In *Age Markers in the Human Skeleton*, edited by M. Y. Iscan, pp. 55-70. Charles C. Thomas, Springfield, Illinois.

Ubelaker, D. H. and L. G. Grant
1989 Human Skeletal Remains: Preservation or Reburial? *Yearbook of Physical Anthropology* 32:249-287.

Ubelaker, D. H., H. E. Berryman, T. P. Sutton, and C. E. Ray
1991 Differentiation of Hydrocephalic Calf and Human Calvariae. *Journal of Forensic Sciences* 36:801-812.

Ubelaker, D. H., T. Phenice, and W. Bass
1969 Artificial Interproximal Grooving of the Teeth in American Indians. *American Journal of Physical Anthropology* 30:145-150.

Van Gerven, D.
1972a *The Contribution of Size and Shape Variation to Patterns of Sexual Dimorphism of the Human Femur*. Unpublished Ph.D. dissertation, University of Massachusetts, Amherst.

1972b The Contribution of Size and Shape Variation to Patterns of Sexual Dimorphism of the Human Femur. *American Journal of Physical Anthropology* 7:49-60.

Vannier, M. W. and G. C. Conroy
1989a Three-Dimensional Surface Reconstruction Software System for IBM Personal Computers. *Folia Primatologica* 53:22-32.

1989b Imaging Workstations for Computer-Aided Primatology: Promises and Pitfalls. *Folia Primatologica* 53:7-21.

Van Vark, G.
1980 *Some Statistical Procedures for the Investigation of Prehistoric Human Skeletal Material*. Unpublished Ph.D. dissertation, Rijksuniversiteit de Groningen, The Netherlands.

Veechi, F.
1968 Sesso e Variazioni di Cratteri Discontinui del Cranio. *Rivista di Antropologia* 55:283-290.

Verano, J. and D. H. Ubelaker (editors)
1992 *Disease and Demography in the Americas: Changing Patterns before and after 1492*. Smithsonian Institution Press, Washington, D.C..

Vivies, E. and J. Bertranpetit
1986 Les Traits Non-Metriques et Descriptivs du Crane Deforme. *Bulletins et Memoires. Society d'Anthropologie de Paris* 14:237-248.

Vogel, J. and N. van der Merwe
1977 Isotopic Evidence for Early Maize Cultivation in New York State. *American Antiquity* 42:238-242.

Walker, P., G. Dean, and P. Shapiro
1991 Estimating Age from Tooth Wear in Archaeological Populations. In *Advances in Dental Anthropology*, edited by M. Kelley and C. S. Larsen, pp. 169-178. Wiley-Liss, New York.

Walker, P. L., J. Johnson, and P. Lambert
1988 Age and Sex Biases in the Preservation of Human Skeletal Remains. *American Journal of Physical Anthropology* 76:183-188.

Walker, P. L., P. Lambert, and M. J. De Niro
1989 The Effects of European Contact on the Health of Alta California Indians. In *Columbian Consequences*, edited by D. H. Thomas, pp. 349-364. Smithsonian Institution Press, Washington, D.C.

Walker, P. L. and J. C. Long
1977 An Experimental Study of the Morphological Characteristics of Tool Marks. *American Antiquity* 42:605-616.

Weidenreich, F.
1937 *The Dentition of Sinanthropus pekinensis: A Comparative Odontography of the Hominids*. Palaeontologia Sinica, New Series D. No. 1, Peking.

Wells, C.
1967 Pseudopathology. In *Diseases in Antiquity*, edited by D. Brothwell and A. Sandison, pp. 5-19. Charles C. Thomas, Springfield, Illinois.

White, T. and P. Folkens
1991 *Human Osteology*. Academic Press, San Francisco.

Wilkinson, L.
1990 *SYSTAT: The System for Statistics*. SYSTAT, Evanston, Illinois.

Winder, S. Snyder
1981 *Infracranial Nonmetric Variation: An Assessment of its Value for Biological Distance Analysis*. Ph.D. dissertation, Indiana University. University Microfilms, Ann Arbor.

Wolf-Heidegger, G.
1962. *Atlas of Systematic Human Anatomy.* Hafner Publishing Company, Inc., New York.

Woo, J. K.
1950 Torus Palatinus. *American Journal of Physical Anthropology* 8:81-111.

Wood Jones, F.
1931a The Non-Metrical Morphological Characters of the Skull as Criteria for Racial Diagnosis. Part I: General Discussion of the Morphological Characters Employed in Racial Diagnoses. *Journal of Anatomy* 65:179-195.

1931b The Non-Metrical Morphological Characters of the Skull as Criteria for Racial Diagnosis. Part II: The Non-Metrical Morphological Characters of the Hawaiian Skull. *Journal of Anatomy* 65:368-378.

1931c The Non-Metrical Morphological Characters of the Skull as Criteria for Racial Diagnosis. Part III: The Non-Metrical Morphological Characters of the Skulls of Prehistoric Inhabitants of Guam. *Journal of Anatomy* 65:438-445.

Yamaguchi, B., I. Sato, and Y. Dodo
1973 A Brief Note on the Supraorbital Nerve Groove on the Frontal Surface of the Human Cranium. *Bulletin of the Natural Science Museum* 16:571-579.

Yezerinac, S.M., S.C. Lougheed, and P. Handford
1992 Measurement Error and Morphometric Studies: Statistical Power and Observer Experience. *Systematic. Biology* 41:471-482.

Zar, J.H.
1984 *Biostatistical Analysis.* 2nd ed. Prentice-Hall, Englewood Cliffs, N.J.

Zhao, M. and J. L. Bada
1989 Extraterrestrial Amino Acids in Cretaceous-Tertiary Boundary Sediments at Stevns Klint, Denmark. *Nature* 339:463-465.

Zimmerman, M. R. and J. L. Angel, editors
1986 *Dating and Age Determination of Biological Materials.* Croom Helm, London.

Zobeck, T. S.
1983 *Postcraniometric Variation among the Arikara.* Unpublished Ph.D. dissertation, University of Tennessee, Knoxville.

INVENTORY RECORDING FORM FOR COMPLETE SKELETONS

Site Name/Number _____/_____ Observer _____

Feature/Burial Number _____/_____ Date _____

Burial/Skeleton Number _____/_____

Present Location of Collection _____

CRANIAL BONES AND JOINT SURFACES

	L(left)	R(right)		L	R
Frontal	____	____	Sphenoid	____	____
Parietal	____	____	Zygomatic	____	____
Occipital	____	____	Maxilla	____	____
Temporal	____	____	Palatine	____	____
TMJ	____	____	Mandible	____	____

POSTCRANIAL BONES AND JOINT SURFACES

	L	R		L	R
Clavicle	____	____	Os Coxae		
Scapula			Ilium	____	____
Body	____	____	Ischium	____	____
Glenoid f.	____	____	Pubis	____	____
Patella	____	____	Acetabulum	____	____
Sacrum	____	____	Auric. Surface	____	____

VERTEBRAE (individual)

	Centrum	Neural Arch
C1	____	____
C2	____	____
C7	____	____
T10	____	____
T11	____	____
T12	____	____
L1	____	____
L2	____	____
L3	____	____
L4	____	____
L5	____	____

VERTEBRAE (grouped)

#Present/# Complete

	Centra	Neural Arches
C3-6	____/____	____/____
T1-T9	____/____	____/____

Sternum: Manubrium ____ Body ____

RIBS (individual)

	L	R
1st	____	____
2nd	____	____
11th	____	____
12th	____	____

RIBS (grouped)

#Present/# Complete

	L	R	Unsided
3-10	____/____	____/____	____/____

Series/Burial/Skeleton_____

Observer/Date_____

LONG BONES

	Proximal Epiphysis	Diaphysis: Proximal Third	Diaphysis: Middle Third	Diaphysis: Distal Third	Distal Epiphysis
Left Humerus	____	____	____	____	____
Right Humerus	____	____	____	____	____
Left Radius	____	____	____	____	____
Right Radius	____	____	____	____	____
Left Ulna	____	____	____	____	____
Right Ulna	____	____	____	____	____
Left Femur	____	____	____	____	____
Right Femur	____	____	____	____	____
Left Tibia	____	____	____	____	____
Right Tibia	____	____	____	____	____
Left Fibula	____	____	____	____	____
Right Fibula	____	____	____	____	____

Left Talus_____

Right Talus_____

Left Calcaneus_____

Right Calcaneus_____

HAND (# Present/# Complete)

	L	R	Unsided
# Carpals	___/___	___/___	___/___
#Metacarpals	___/___	___/___	___/___
#Phalanges	___/___	___/___	___/___

FOOT (# Present/# Complete)

	L	R	Unsided
#Tarsals	___/___	___/___	___/___
#Metatarsals	___/___	___/___	___/___
#Phalanges	___/___	___/___	___/___

Comments:_____

INVENTORY RECORDING FORM FOR COMMINGLED REMAINS AND ISOLATED BONES

Site Name/Number _____/_____ Observer _____

Feature/Burial Number _____/_____ Date _____

Burial/Skeleton Number _____/_____

Present Location of Collection _____

Report all cranial bones separately. Group Cervical Vertebrae 3-6; Thoracic Vertebrae 1-9; Ribs 3-10; Carpals; Metacarpals; Tarsals (other than Talus and Calcaneus); Metatarsals; Hand and Foot Phalanges. Vertebrae other than those grouped above should be reported individually. Identify **bones** by name, indicate **L** (left); **R** (right); **B** (Both); **M** (Midline); **?** (Unsidable). Code articular regions, long bone diaphyses, and vertebrae by **segments**: **PE** (proximal epiphysis), **P1/3** (proximal third of diaphysis), **M1/3** (middle third of diaphysis), **D1/3** (distal third of diaphysis), **DE** (distal epiphysis); **B** (vertebral body or centrum), **NA** (neural arch). Otherwise, leave this category blank. Code **Completeness** according to the following:**1** = >75% present; **2** = 25% - 75% present; **3** = <25% present. MNI reflects the minimum number of individuals recorded on this line. **Count/Wt** refers to the number/weight of fragmented materials. **Age** and **Sex** determinations should be entered as counts (see text for codes).

Bone	Side	Segment	Completeness	MNI	Ct/Wt	Age	Sex

Series/Burial/Skeleton_____

Observer/Date _____

Bone	Side	Segment	Completeness	MNI	Ct/Wt	Age	Sex

ADULT SKELETON RECORDING FORM: ANTERIOR VIEW

Series/Burial/Skeleton_____

Observer/Date_____

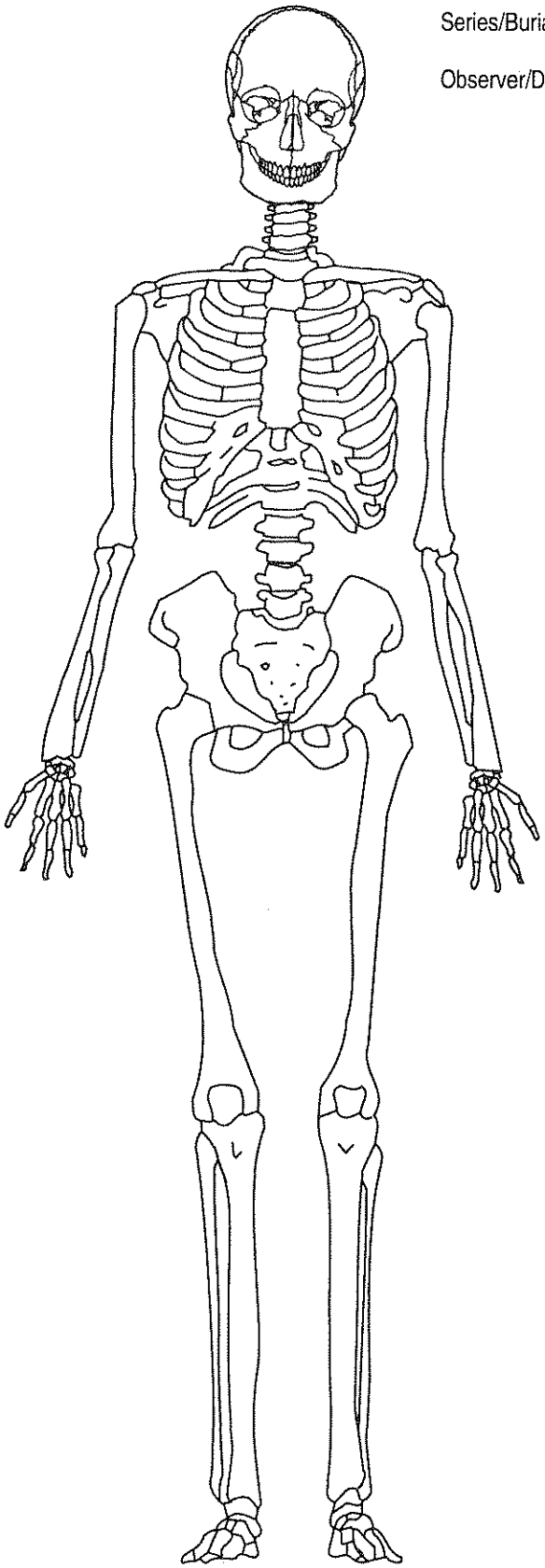

ADULT SKELETON RECORDING FORM: POSTERIOR VIEW

Series/Burial/Skeleton_____

Observer/Date_____

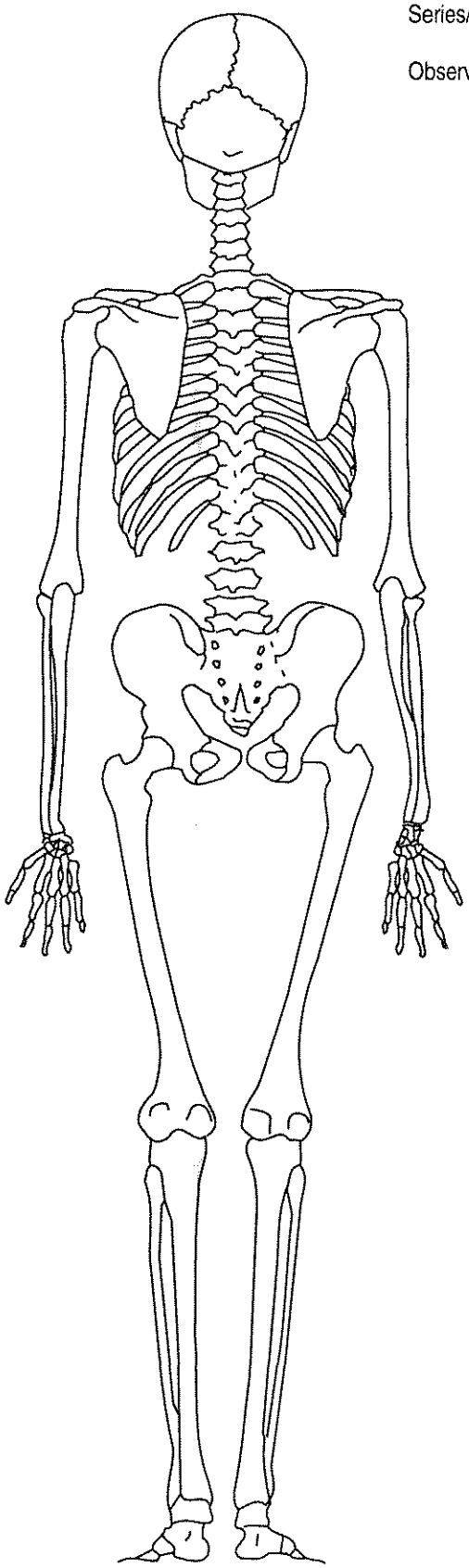

ADULT SKELETON RECORDING FORM: RIGHT LATERAL VIEW

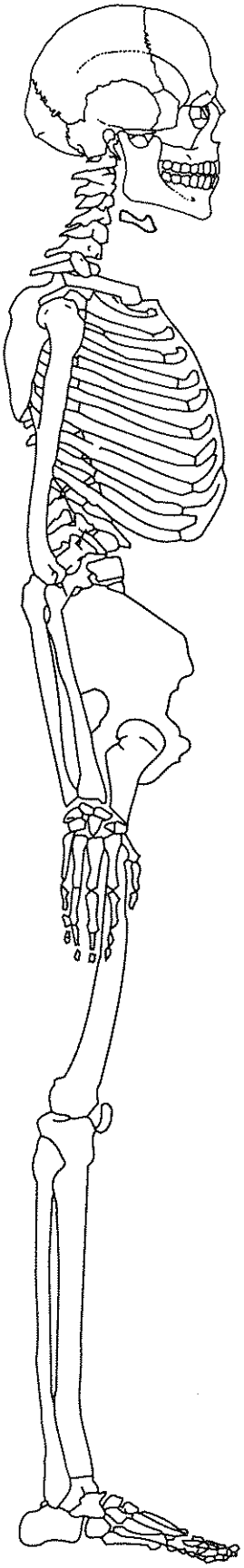

Series/Burial/Skeleton_____

Observer/Date_____

ADULT SKELETON RECORDING FORM: LEFT LATERAL VIEW

Series/Burial/Skeleton_____

Observer/Date_____

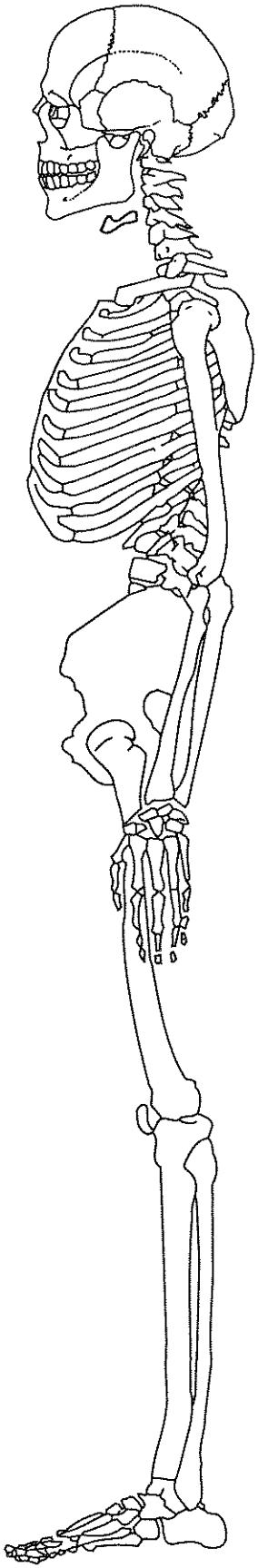

JUVENILE SKELETON VISUAL RECORDING FORM
a. CHILD ANTERIOR VIEW

Series/Burial/Skeleton_____

Observer/Date_____

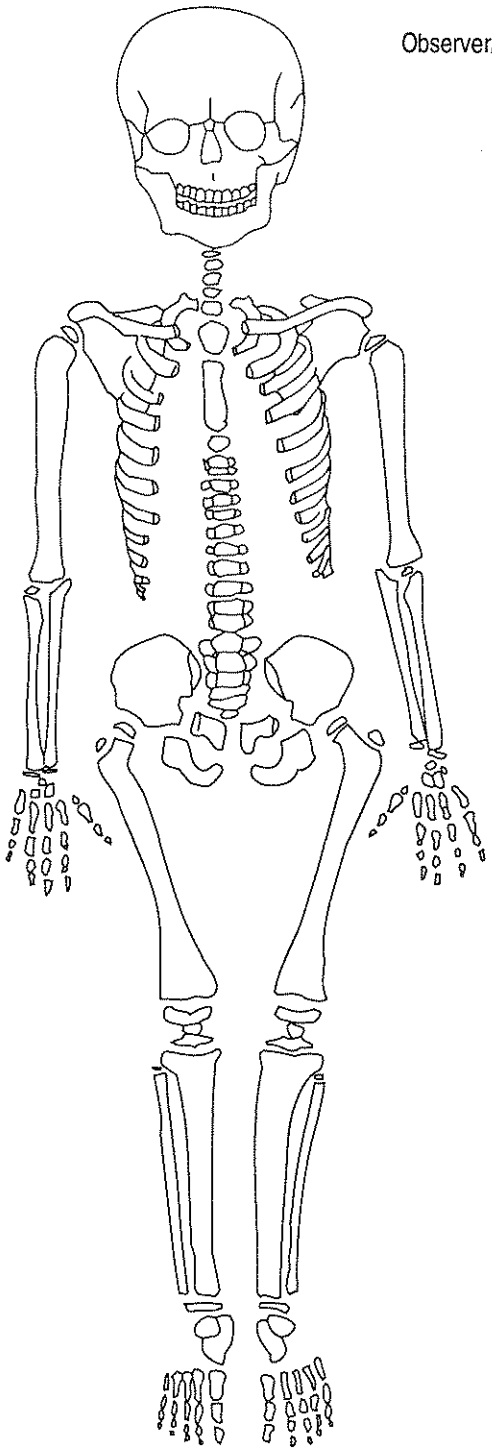

JUVENILE SKELETON VISUAL RECORDING FORM
b. FETUS (NEWBORN), ANTERIOR VIEW

Series/Burial/Skeleton_____

Observer/Date_____

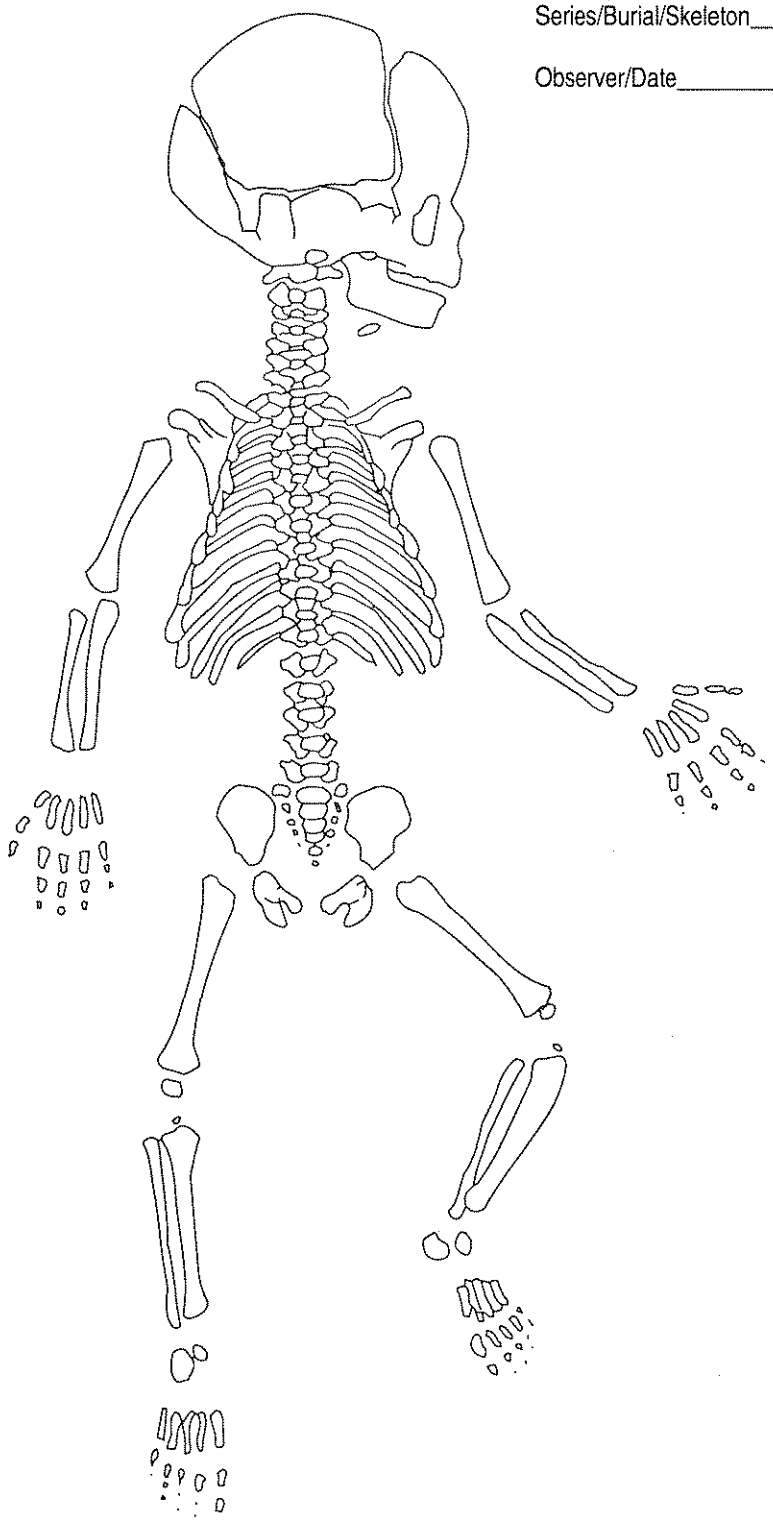

SKULL RECORDING FORM: ANTERIOR VIEW

Series/Burial/Skeleton_____

Observer/Date_____

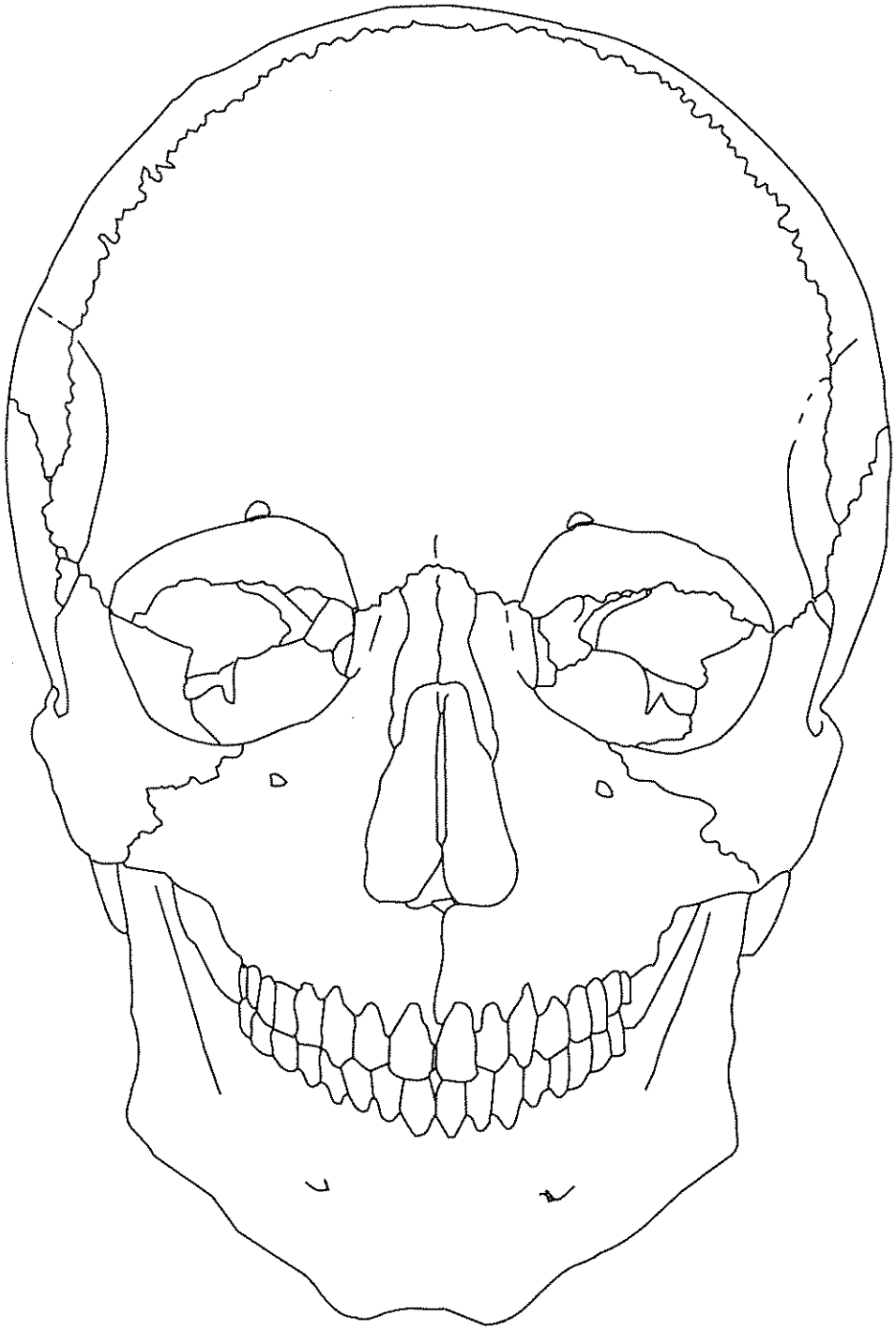

SKULL RECORDING FORM: POSTERIOR VIEW

Series/Burial/Skeleton_____

Observer/Date_____

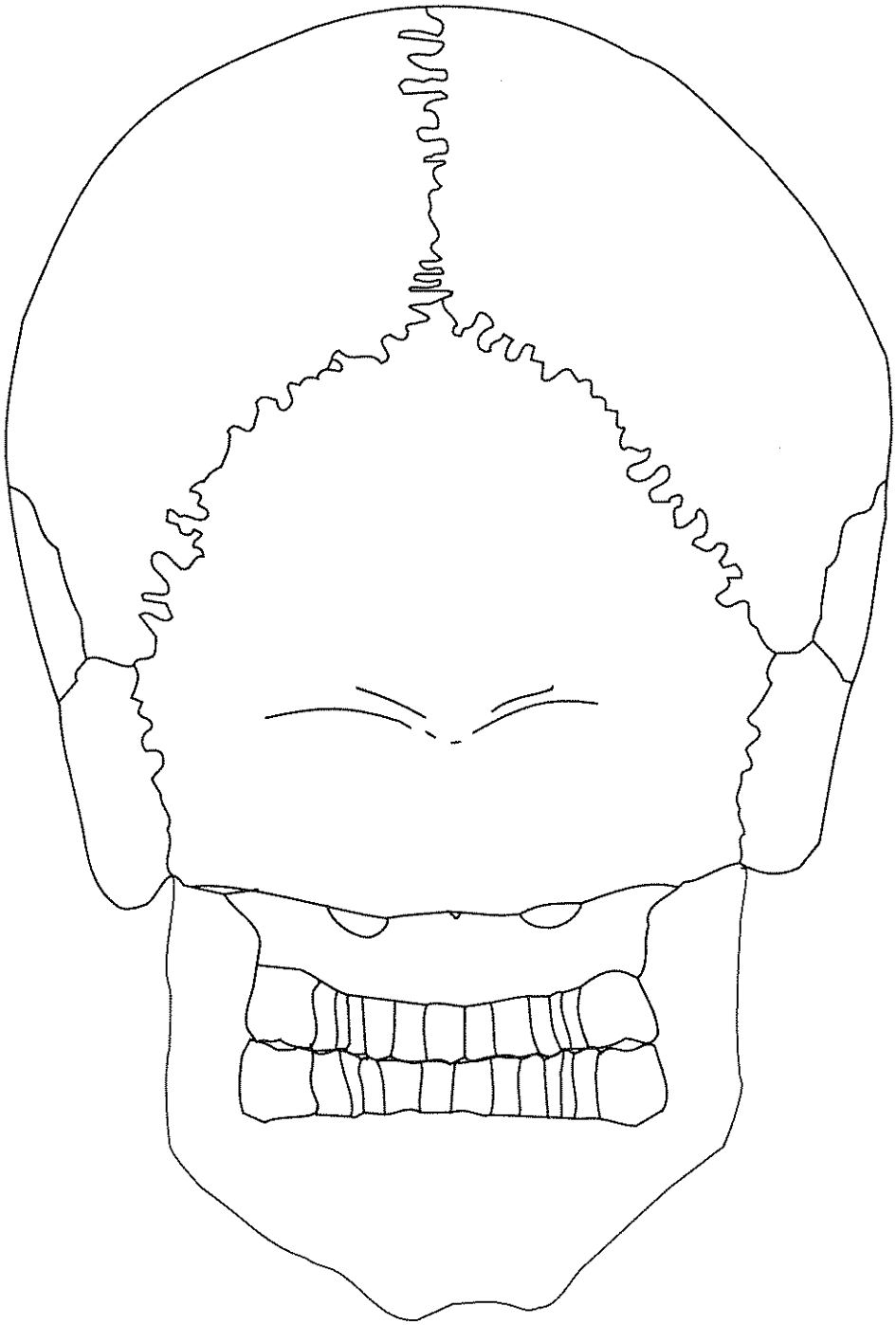

SKULL RECORDING FORM: RIGHT LATERAL VIEW

Series/Burial/Skeleton_____

Observer/Date_____

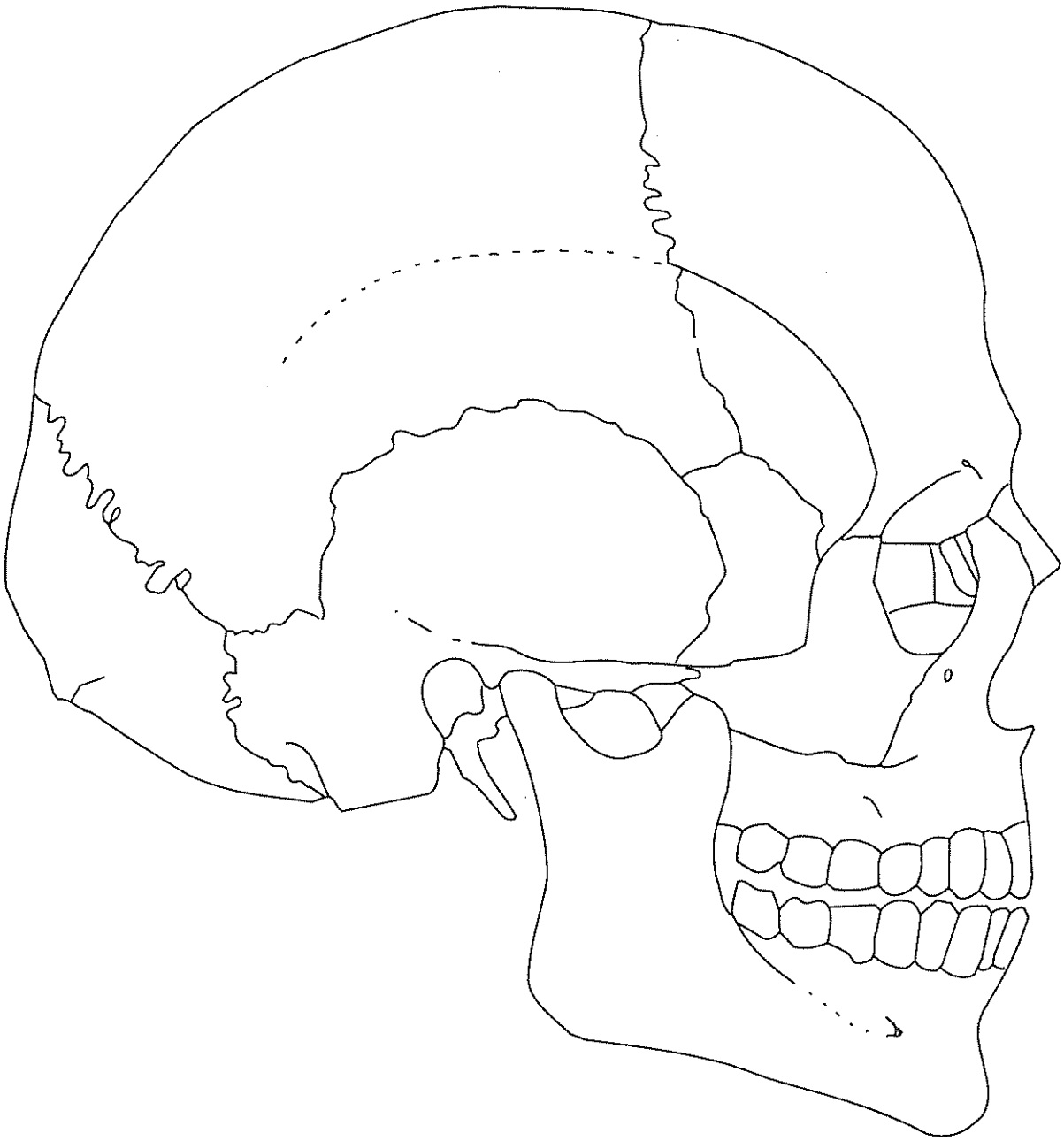

SKULL RECORDING FORM: LEFT LATERAL VIEW

Series/Burial/Skeleton_____

Observer/Date_____

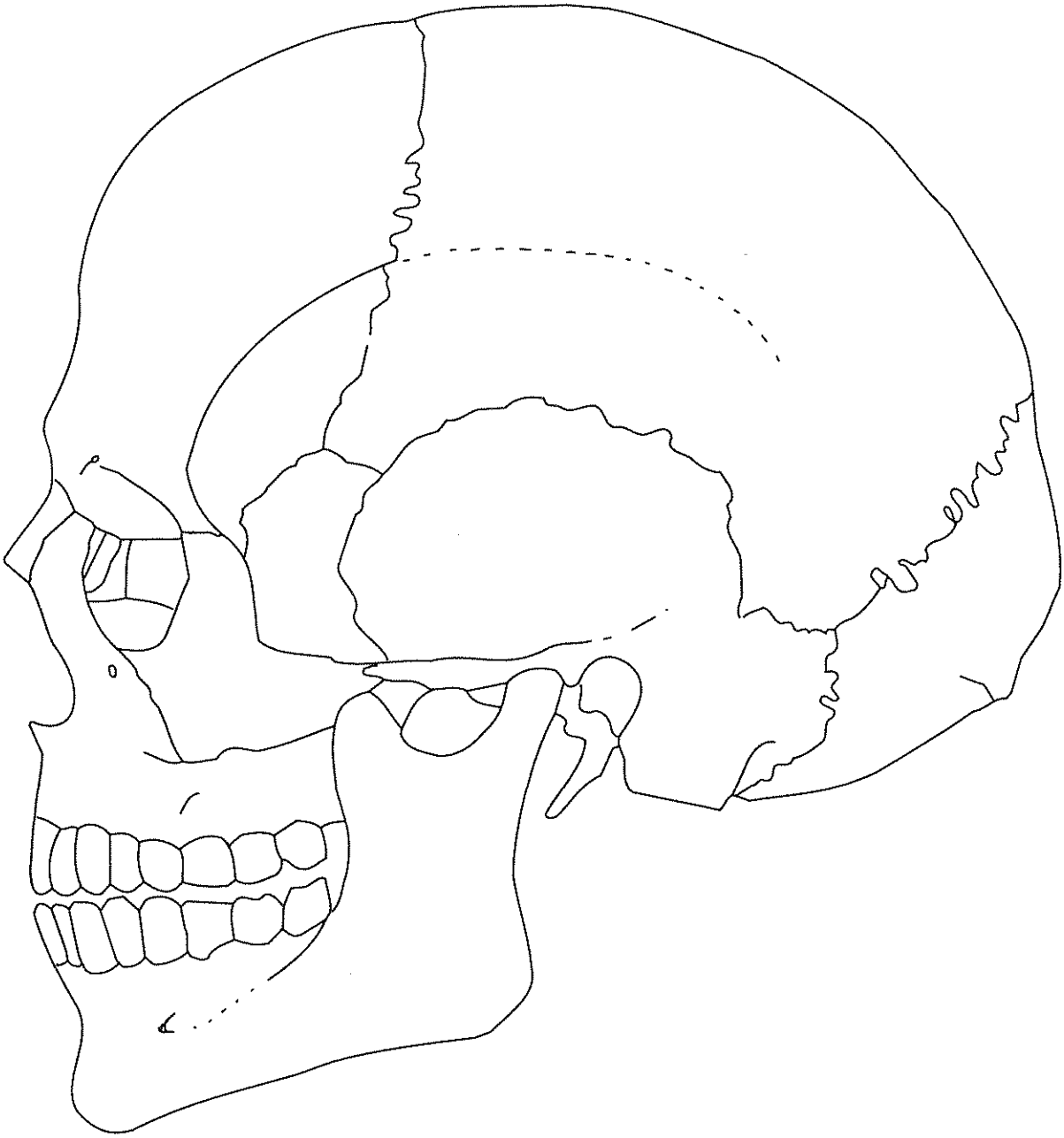

SKULL RECORDING FORM: SUPERIOR VIEW

Series/Burial/Skeleton_____

Observer/Date_____

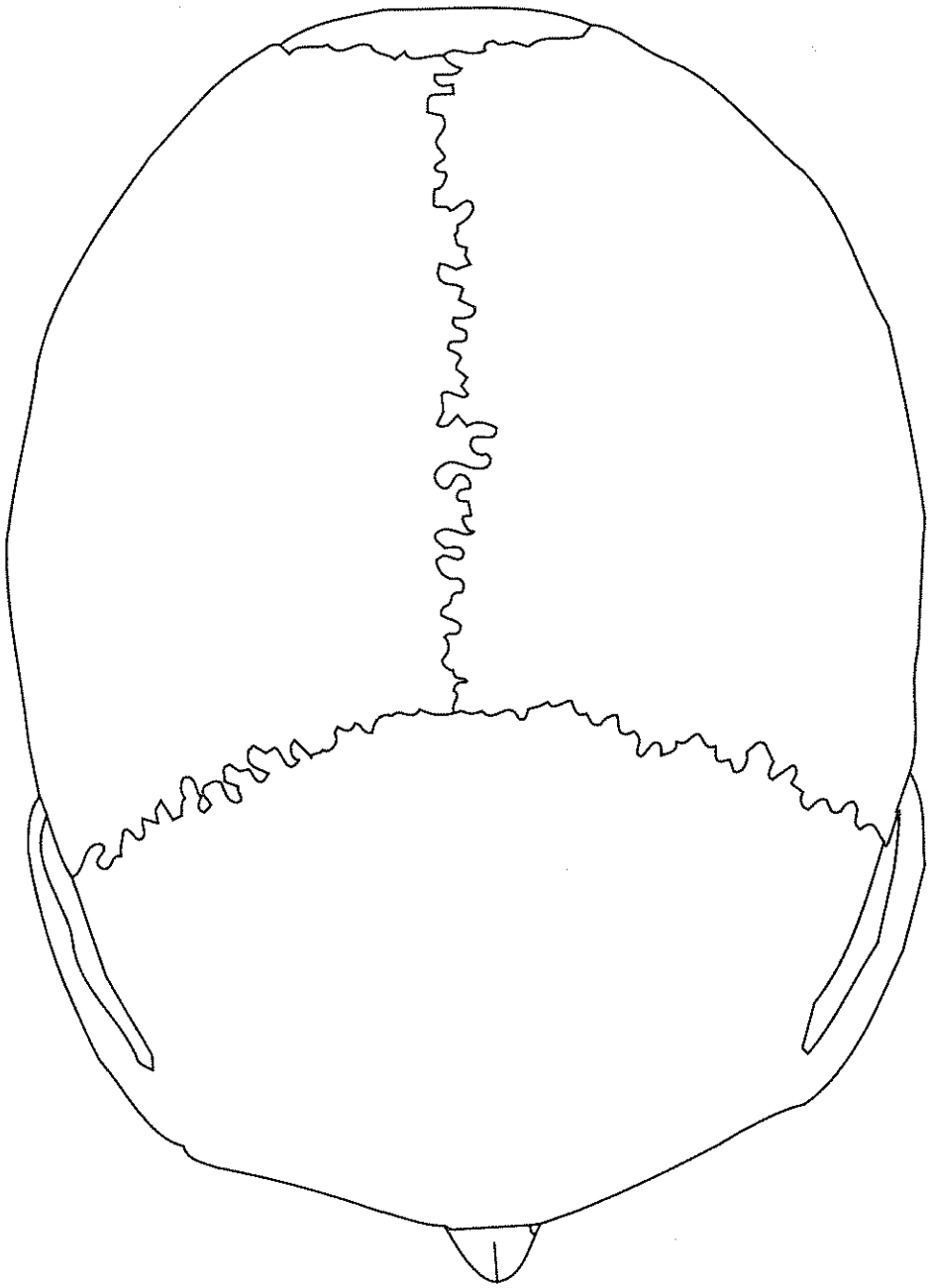

SKULL RECORDING FORM: BASILAR VIEW

Series/Burial/Skeleton_____

Observer/Date_____

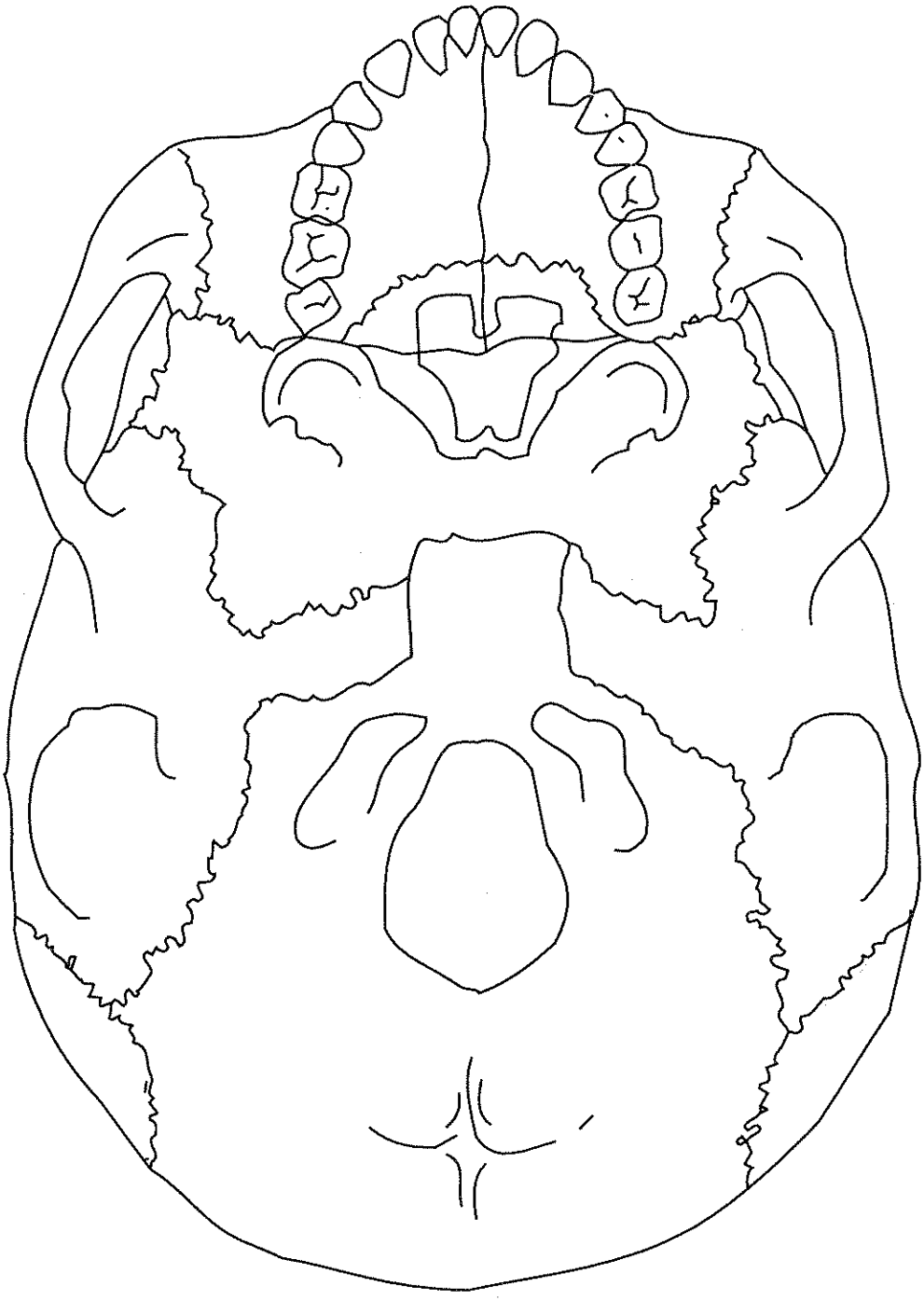

POSTCRANIAL BONES VISUAL RECORDING FORM
LEFT OS COXAE, SCAPULA, CLAVICLE

Series/Burial/Skeleton:_____

Observer/Date:_____

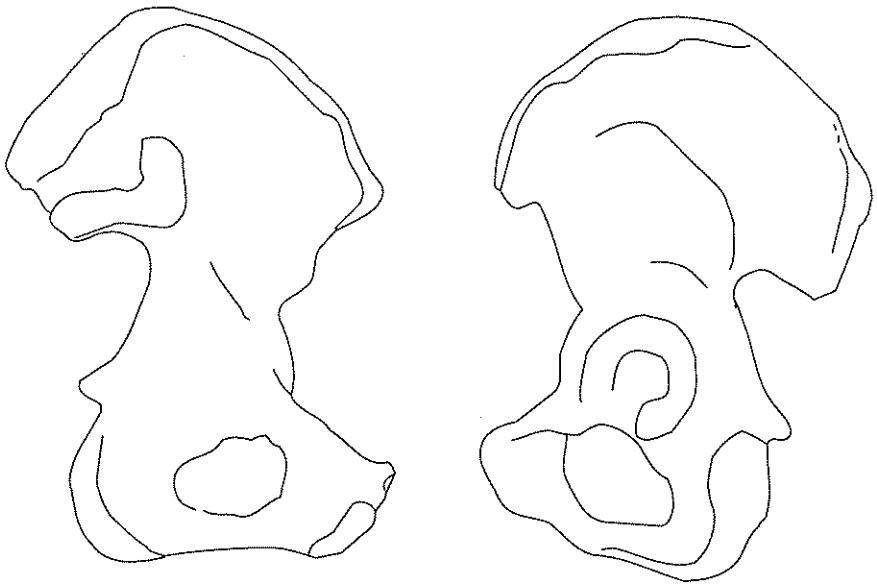

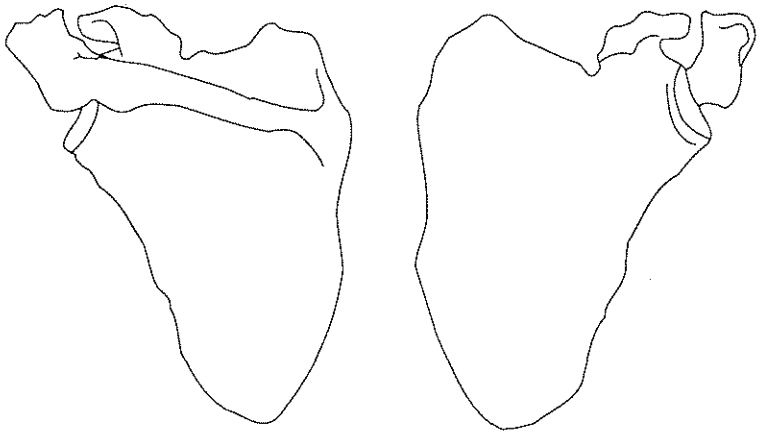

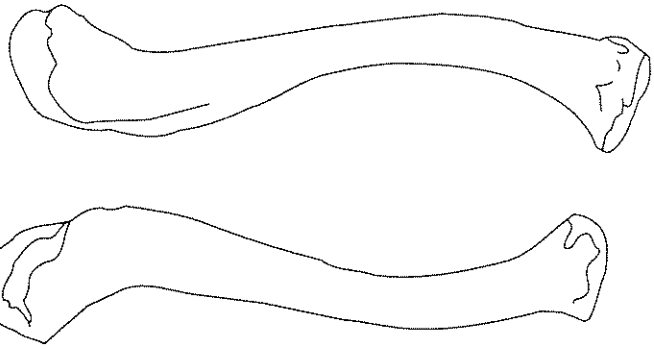

POSTCRANIAL BONES VISUAL RECORDING FORM
RIGHT OS COXAE, SCAPULA, CLAVICLE,

Series/Burial/Skeleton:_____

Observer/Date:_____

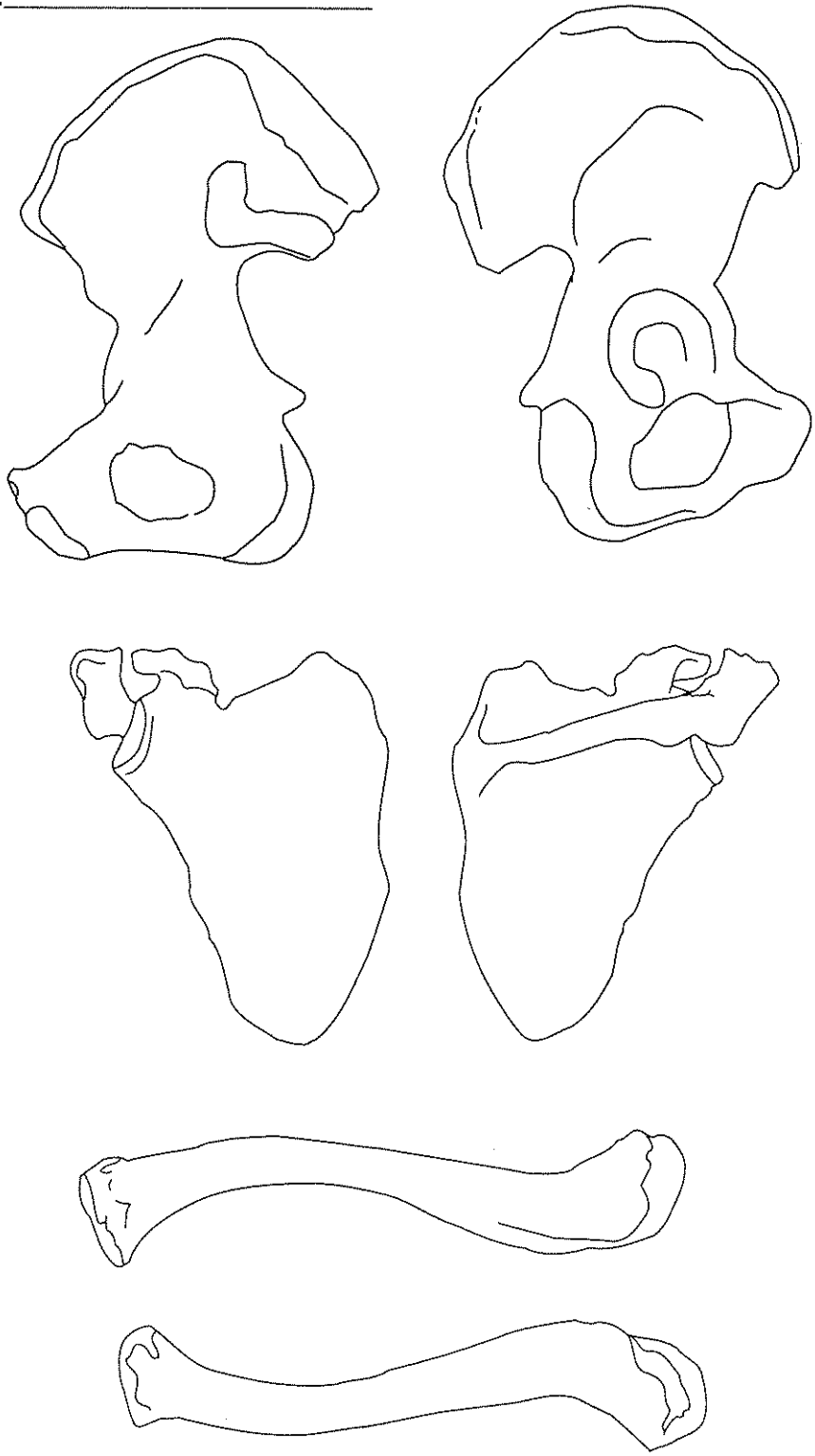

POSTCRANIAL BONES VISUAL RECORDING FORM
FEMUR, TIBIA, FIBULA

Series/Burial/Skeleton:_____

Observer/Date:_____

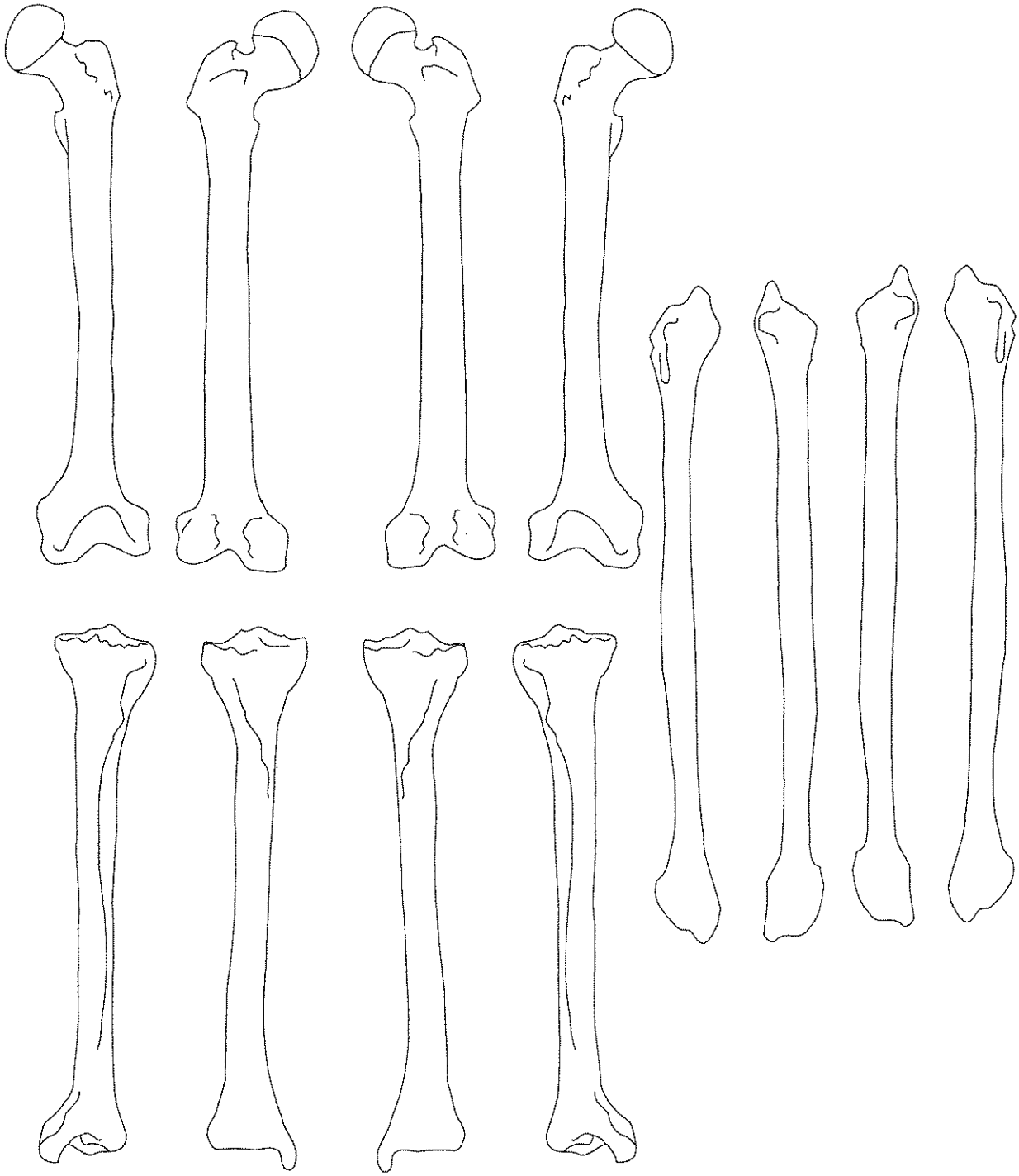

POSTCRANIAL BONES VISUAL RECORDING FORM
HUMERUS, ULNA, RADIUS

Series/Burial/Skeleton:_____

Observer/Date:_____

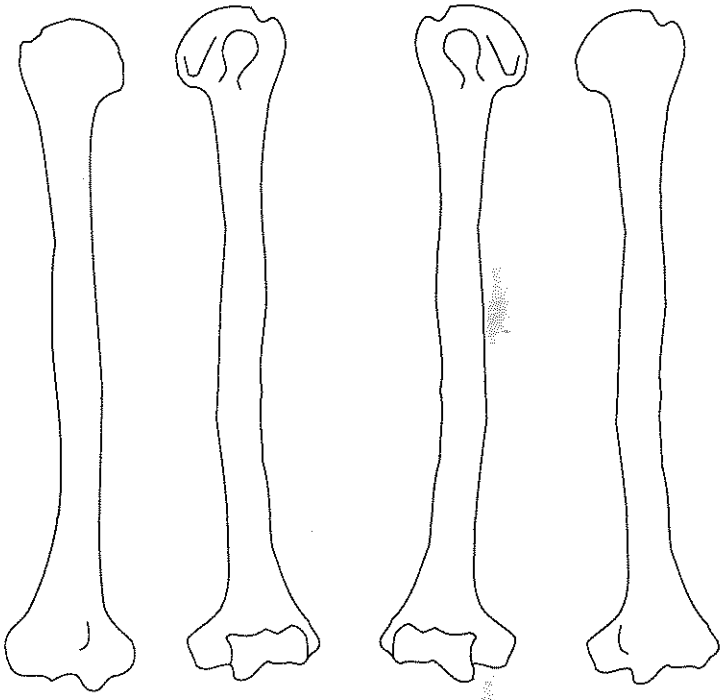

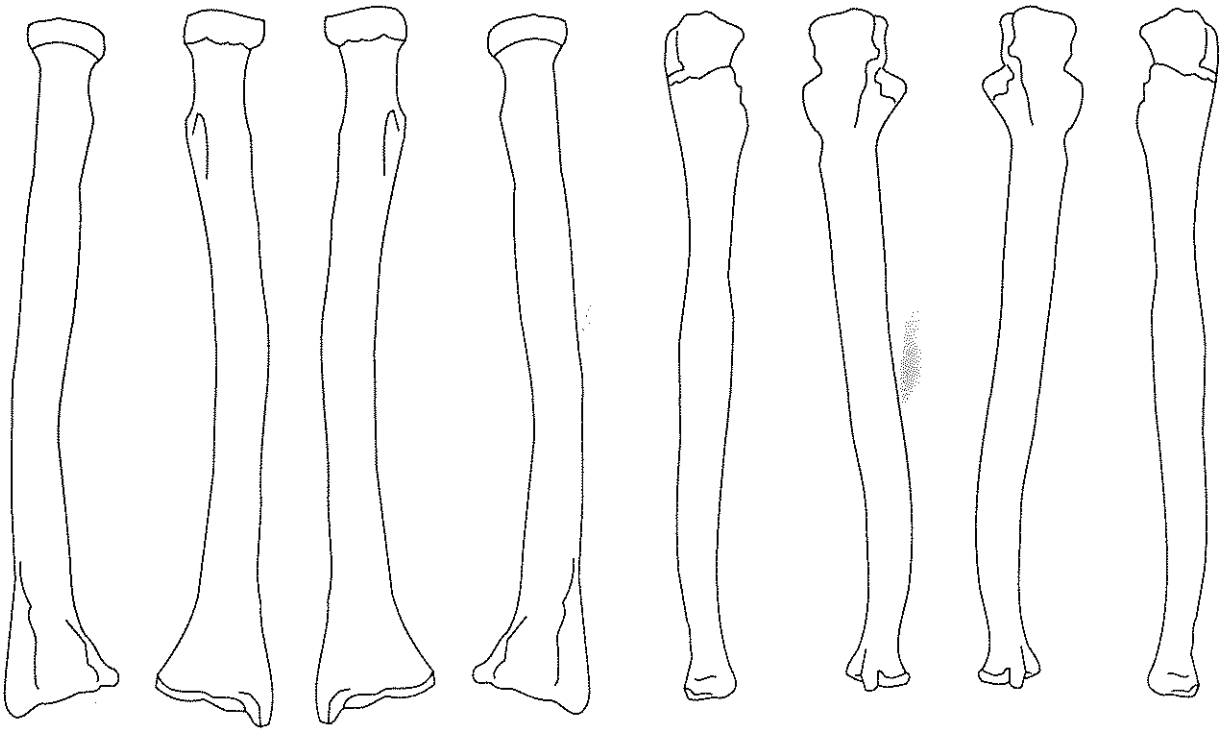

Attachment 10b: CHAPTER 2

ADULT SEX/AGE RECORDING FORM

Site Name/Number _____/_____ Observer _____

Feature/Burial Number _____/_____ Date _____

Burial/Skeleton Number _____/_____

Present Location of Collection _____

SEX

Pelvis	L	R
Ventral Arc (1-3)	____	____
Subpubic Concavity (1-3)	____	____
Ischiopubic Ramus Ridge (1-3)	____	____
Greater Sciatic Notch (1-5)	____	____
Preauricular Sulcus (0-4)	____	____

Estimated Sex, Pelvis (0-5) _____

Skull	L	M	R
Nuchal Crest (1-5)	____	____	____
Mastoid Process (1-5)	____	____	____
Supraorbital Margin (1-5)	____	____	____
Glabella (1-5)	____	____	____
Mental Eminence (1-5)	____	____	____

Estimated Sex, Skull (0-5) _____

Comments:

Series/Burial/Skeleton _____

Observer/Date _____

AGE

Pubic Symphysis	L	R
Todd (1-10)	____	____
Suchey-Brooks (1-6)	____	____

Auricular Surface (1-8)	L	R
	____	____

Suture Closure (blank = unobservable; 0 = open; 1 = minimal; 2 = significant; 3 = complete)

External Cranial Vault

1. Midlambdoid ____
2. Lambda ____
3. Obelion ____
4. Anterior Sagittal ____
5. Bregma ____
6. Midcoronal ____
7. Pterion ____
8. Sphenofrontal ____
9. Inferior Sphenotemporal ____
10. Superior Sphenotemporal ____

Palate

11. Incisive ____
12. Anterior Median Palatine ____
13. Posterior Median Palatine ____
14. Transverse Palatine ____

Internal Cranial Vault

15. Sagittal ____
16. Left Lambdoid ____
17. Left Coronal ____

Estimated Age: Young Adult (20-35 years) _____

Middle Adult (35-50 years) _____

Old Adult (50+ years) _____

Comments:

IMMATURE REMAINS RECORDING FORM: BONE UNION AND EPIPHYSEAL CLOSURE

Site Name/Number _____/_____ Observer _____

Feature/Burial Number _____/_____ Date _____

Burial/Skeleton Number _____/_____

Present Location of Collection _____

Stage of Union: blank = unobservable; 0 = open; 1 = partial union; 2 = complete union

EPIPHYSEAL FUSION

Bone	Epiphysis	Stage of Union
Cervical Vertebrae	superior	_____
	inferior	_____
Thoracic Vertebrae	superior	_____
	inferior	_____
Lumbar Vertebrae	superior	_____
	inferior	_____

		L	R
Scapula	coracoid	_____	_____
	acromion	_____	_____
Clavicle	sternal	_____	_____
Humerus	head	_____	_____
	distal	_____	_____
	medial epicondyle	_____	_____
Radius	proximal	_____	_____
	distal	_____	_____
Ulna	proximal	_____	_____
	distal	_____	_____
Os Coxae	iliac crest	_____	_____
	ischial tuberosity	_____	_____
Femur	head	_____	_____
	greater trochanter	_____	_____
	lesser trochanter	_____	_____
	distal	_____	_____
Tibia	proximal	_____	_____
	distal	_____	_____
Fibula	proximal	_____	_____
	distal	_____	_____

PRIMARY OSSIFICATION CENTERS

Bone	Area of Union	Extent
Os Coxae	ilium-pubis	_____
	ischium-pubis	_____
	ischium-ilium	_____
Sacral Segments	1-2	_____
	2-3	_____
	3-4	_____
	4-5	_____
Cervical Vertebrae		
	neural arches to each other	_____
	neural arches to centrum	_____
Thoracic Vertebrae		
	neural arches to each other	_____
	neural arches to centrum	_____
Lumbar Vertebrae		
	neural arches to each other	_____
	neural arches to centrum	_____
Cranium		
	spheno-occipital synchondrosis	_____
Occipital		
	lateral part to squama	_____
	basilar part to lateral part	_____

Series/Burial/Skeleton _____

Observer/Date _____

Estimate of chronological age based on postcranial maturation

Fetal	_____
b-5	_____
5-10	_____
10-15	_____
15-20	_____
20+	_____

Comments: _____

IMMATURE MEASUREMENTS RECORDING FORM

Site Name/Number _____/_____ Observer _____

Feature/Burial Number _____/_____ Date _____

Burial/Skeleton Number _____/_____

Present Location of Collection _____

CRANIAL MEASUREMENTS

	L	M	R
1. Lesser Wing of the Sphenoid			
(a) Length:	_____		_____
(b) Width:	_____		_____
2. Greater Wing of the Sphenoid			
(a) Length	_____		_____
(b) Width:	_____		_____
3. Body of the Sphenoid			
(a) Length:		_____	
(b) Width:		_____	
4. Petrous and Mastoid Portions of the Temporal			
(a) Length:	_____		_____
(b) Width:	_____		_____
5. Basilar Part of the Occipital			
(a) Length:		_____	
(b) Width:		_____	
6. Zygomatic			
(a) Length:	_____		_____
(b) Width:	_____		_____
7. Maxilla			
(a) Length:	_____		_____
(b) Height:	_____		_____
(c) Width:	_____		_____
8. Mandible			
(a) Length of the Body:	_____		_____
(b) Width of the Arc:	_____		_____
(c) Full Length of Half Mandible:		_____	

Series/Burial/Skeleton _____

Observer/Date _____

POSTCRANIAL MEASUREMENTS

	L	R
9. Clavicle		
(a) Length:	_____	_____
(b) Diameter:	_____	_____
10. Scapula		
(a) Length (height):	_____	_____
(b) Width:	_____	_____
(c) Length of the Spine:	_____	_____
11. Ilium		
(a) Length:	_____	_____
(b) Width:	_____	_____
12. Ischium		
(a) Length:	_____	_____
(b) Width:	_____	_____
13. Pubis		
(a) Length:	_____	_____
14. Humerus		
(a) Length:	_____	_____
(b) Width:	_____	_____
(c) Diameter:	_____	_____

	L	R
15. Ulna		
(a) Length:	_____	_____
(b) Diameter:	_____	_____
16. Radius		
(a) Length:	_____	_____
(b) Diameter:	_____	_____
17. Femur		
(a) Length:	_____	_____
(b) Width:	_____	_____
(c) Diameter:	_____	_____
18. Tibia		
(a) Length:	_____	_____
(b) Diameter:	_____	_____
19. Fibula		
(a) Length:	_____	_____
(b) Diameter:	_____	_____

Comments:

_____

_____

_____

_____

_____

_____

_____

_____

_____

_____

DENTAL INVENTORY
VISUAL RECORDING FORM: PERMANENT DENTITION

Site Name/Number _____/_____ Observer _____

Feature/Burial Number _____/_____ Date _____

Burial/Skeleton Number _____/_____

Present Location of Collection _____

MAXILLARY

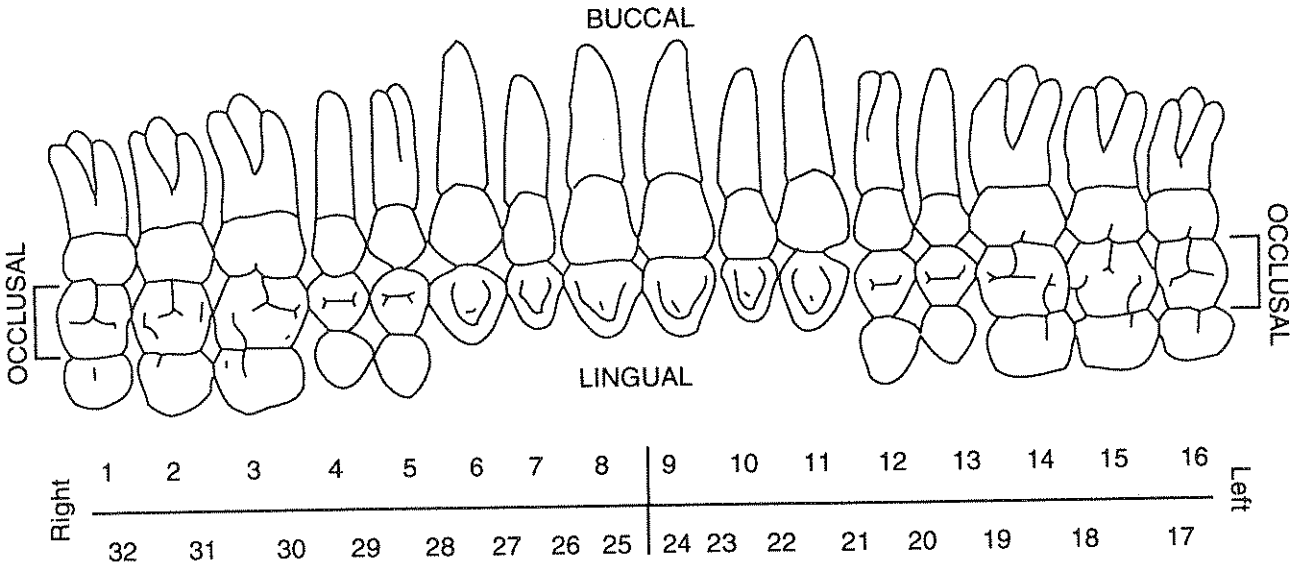

MANDIBULAR

DENTAL INVENTORY
VISUAL RECORDING FORM: DECIDUOUS DENTITION

Site Name/Number _____/_____ Observer _____

Feature/Burial Number _____/_____ Date _____

Burial/Skeleton Number _____/_____

Present Location of Collection _____

MAXILLARY

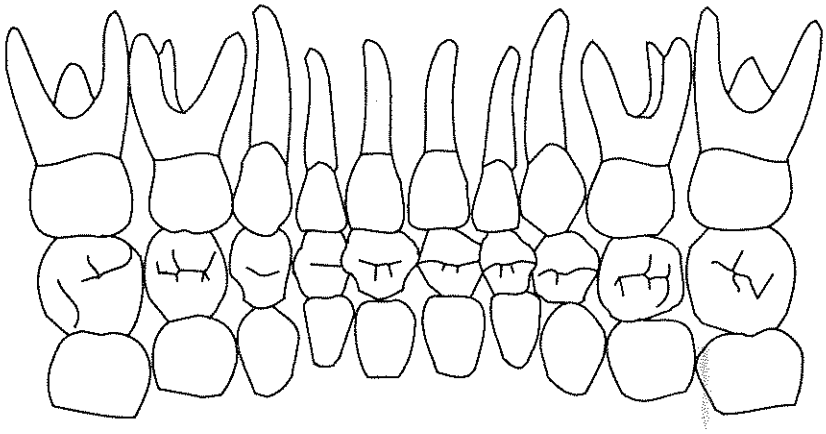

BUCCAL
OCCLUSAL
LINGUAL

BUCCAL
OCCLUSAL
LINGUAL

Right	51	52	53	54	55	56	57	58	59	60	Left
	70	69	68	67	66	65	64	63	62	61	

LINGUAL
OCCLUSAL
BUCCAL

LINGUAL
OCCLUSAL
BUCCAL

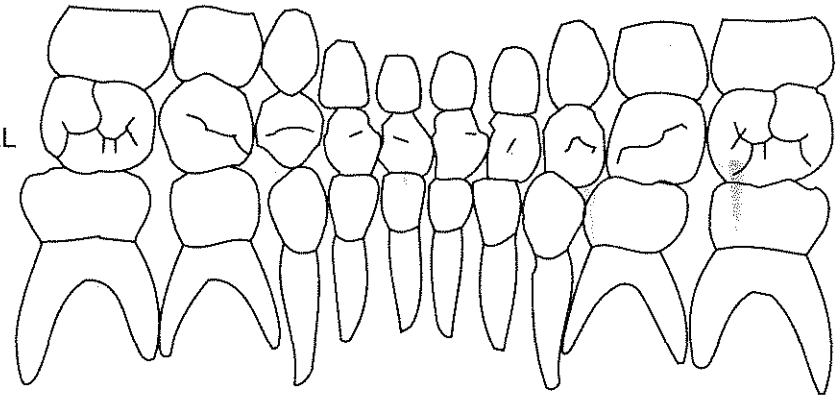

MANDIBULAR

SUPERNUMERARY TEETH AND ABSCESSES
VISUAL RECORDING FORM: MAXILLARY DENTITION

Site Name/Number _____/_____ Observer _____

Feature/Burial Number _____/_____ Date _____

Burial/Skeleton Number _____/_____

Present Location of Collection _____

Right Buccal View

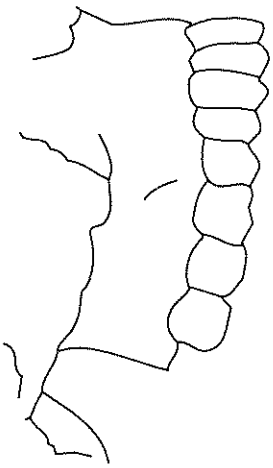

Left Buccal View

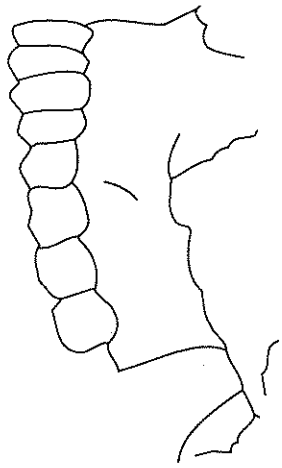

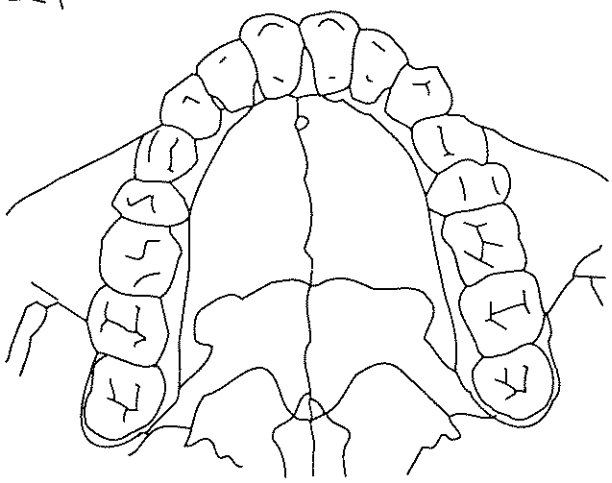

Palatal View

SUPERNUMERARY TEETH AND ABSCESSES
VISUAL RECORDING FORM: MANDIBULAR DENTITION

Site Name/Number _____/_____ Observer _____

Feature/Burial Number _____/_____ Date _____

Burial/Skeleton Number _____/_____

Present Location of Collection _____

Frontal (Labial)/Buccal View

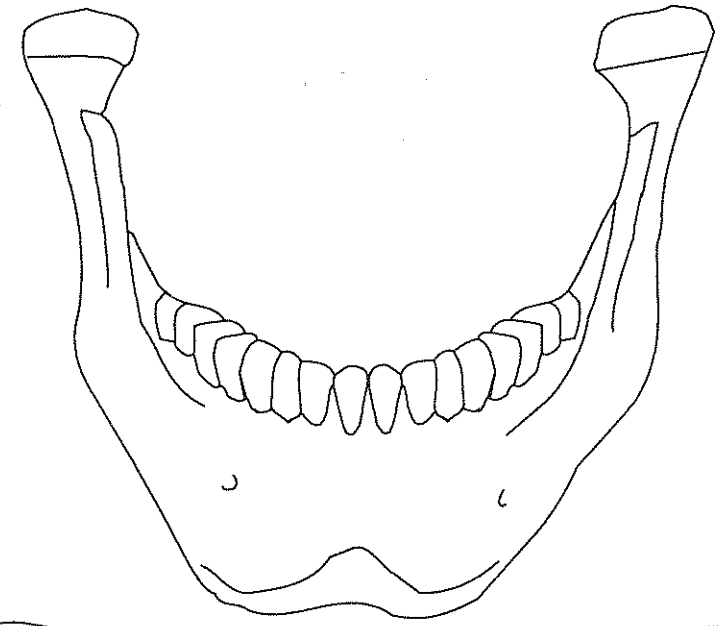

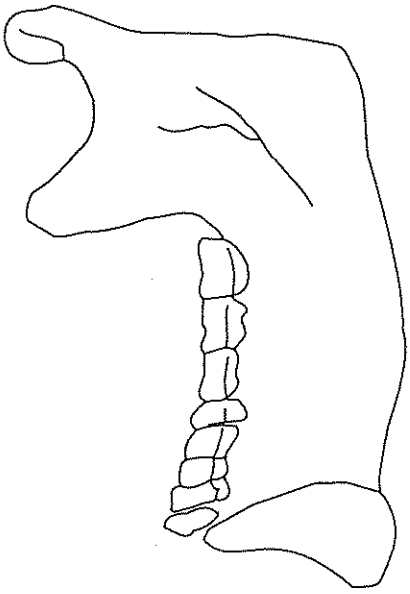

Right Lingual View

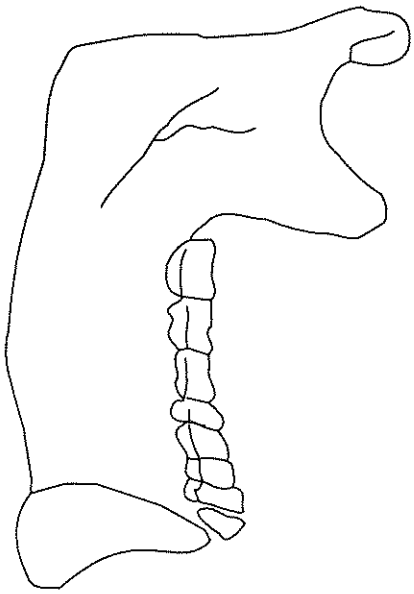

Left Lingual View

DENTAL INVENTORY RECORDING FORM
DEVELOPMENT, WEAR, AND PATHOLOGY: PERMANENT TEETH

Site Name/Number _____/_____ Observer _____

Feature/Burial Number _____/_____ Date _____

Burial/Skeleton Number _____/_____

Present Location of Collection _____

Tooth presence and development: code 1-8. For teeth entered as "1" (present, but not in occlusion), record stage of crown/root formation under "Development." **Occlusal surface wear:** use left teeth, following Smith (1984) for anterior teeth (code 1-8) and Scott (1979) for molars (code 0-10). If marked asymmetry is present, record both sides. Record each molar quadrant separate in the spaces provided (+) and the total for all four quadrants under "Total." **Caries:** code each carious lesion separately (1-7); **Abscesses:** code location (1-2). **Calculus:** code 0-3, 9. Note surface affected (buccal/labial or lingual).

		Tooth Presence	Development	Wear	Total	Caries			Abscess	Calculus	Affected
Maxillary Right	1 M^3	___	___	___	___	___	___	___	___	___	___
	2 M^2	___	___	___	___	___	___	___	___	___	___
	3 M^1	___	___	___	___	___	___	___	___	___	___
	4 P^2	___	___	___	___	___	___	___	___	___	___
	5 P^1	___	___	___	___	___	___	___	___	___	___
	6 C	___	___	___	___	___	___	___	___	___	___
	7 I^2	___	___	___	___	___	___	___	___	___	___
	8 I^1	___	___	___	___	___	___	___	___	___	___
Maxillary Left	9 I^1	___	___	___	___	___	___	___	___	___	___
	10 I^2	___	___	___	___	___	___	___	___	___	___
	11 C	___	___	___	___	___	___	___	___	___	___
	12 P^1	___	___	___	___	___	___	___	___	___	___
	13 P^2	___	___	___	___	___	___	___	___	___	___
	14 M^1	___	___	___	___	___	___	___	___	___	___
	15 M^2	___	___	___	___	___	___	___	___	___	___
	16 M^3	___	___	___	___	___	___	___	___	___	___

Series/Burial/Skeleton_____

Observer/Date_____

		Tooth Presence	Development	Wear /Total		Caries			Abscess	Calculus/Affected	
Mandibular Left	17 M_3	____	____	____	____	____	____	____	____	____	_____
	18 M_2	____	____	____	____	____	____	____	____	____	_____
	19 M_1	____	____	____	____	____	____	____	____	____	_____
	20 P_2	____	____	____	____	____	____	____	____	____	_____
	21 P_1	____	____	____	____	____	____	____	____	____	_____
	22 C	____	____	____	____	____	____	____	____	____	_____
	23 I_2	____	____	____	____	____	____	____	____	____	_____
	24 I_1	____	____	____	____	____	____	____	____	____	_____
Mandibular Right	25 I_1	____	____	____	____	____	____	____	____	____	_____
	26 I_2	____	____	____	____	____	____	____	____	____	_____
	27 C	____	____	____	____	____	____	____	____	____	_____
	28 P_1	____	____	____	____	____	____	____	____	____	_____
	29 P_2	____	____	____	____	____	____	____	____	____	_____
	30 M_1	____	____	____	____	____	____	____	____	____	_____
	31 M_2	____	____	____	____	____	____	____	____	____	_____
	32 M_3	____	____	____	____	____	____	____	____	____	_____

Estimated dental age (juveniles only)_____

Supernumerary Teeth:

Position between teeth	Location (1 - 4)	Position between teeth	Location (1 - 4)	Position between teeth	Location (1 - 4)
____/____	_____	____/____	_____	____/____	_____
____/____	_____	____/____	_____	____/____	_____

Comments:

_____

_____

_____

_____

_____

_____

DENTAL INVENTORY RECORDING FORM
DEVELOPMENT AND PATHOLOGY: DECIDUOUS TEETH

Site Name/Number _____/_____ Observer _____

Feature/Burial Number _____/_____ Date _____

Burial/Skeleton Number _____/_____

Present Location of Collection _____

Tooth presence and development: code 1-8. For teeth entered as "1" (present, but not in occlusion), record stage of crown/root formation under "Development." **Caries:** code each carious lesion separately (1-7); **Abscesses:** code location (1-2). **Calculus:** code 0-3, 9. Note surface affected (buccal/labial or lingual).

	Tooth	Presence	Development	Caries	Abscess	Calculus/Affected
Maxillary Right	51 m^2	____	____	____ ____ ____	____	____ ____
	52 m^1	____	____	____ ____ ____	____	____ ____
	53 c	____	____	____ ____ ____	____	____ ____
	54 i^2	____	____	____ ____ ____	____	____ ____
	55 i^1	____	____	____ ____ ____	____	____ ____
Maxillary Left	56 i^1	____	____	____ ____ ____	____	____ ____
	57 i^2	____	____	____ ____ ____	____	____ ____
	58 c	____	____	____ ____ ____	____	____ ____
	59 m^1	____	____	____ ____ ____	____	____ ____
	60 m^2	____	____	____ ____ ____	____	____ ____
Mandibular Left	61 m^2	____	____	____ ____ ____	____	____ ____
	62 m^1	____	____	____ ____ ____	____	____ ____
	63 c	____	____	____ ____ ____	____	____ ____
	64 i^2	____	____	____ ____ ____	____	____ ____
	65 i^1	____	____	____ ____ ____	____	____ ____
Mandibular Right	66 i^1	____	____	____ ____ ____	____	____ ____
	67 i^2	____	____	____ ____ ____	____	____ ____
	68 c	____	____	____ ____ ____	____	____ ____
	69 m^1	____	____	____ ____ ____	____	____ ____
	70 m^2	____	____	____ ____ ____	____	____ ____

Series/Burial/Skeleton_____

Observer/Date_____

Estimated dental age (juveniles only)_____

Supernumerary Teeth:	Position between teeth	Location (1 - 4)	Position between teeth	Location (1 - 4)	Position between teeth	Location (1 - 4)
	____/____	_____	____/____	_____	____/____	_____
	____/____	_____	____/____	_____	____/____	_____

Comments:

ENAMEL DEFECTS (HYPOPLASIAS AND OPACITIES) RECORDING FORM: PERMANENT TEETH

Site Name/Number _____/_____ Observer _____

Feature/Burial Number _____/_____ Date _____

Burial/Skeleton Number _____/_____

Present Location of Collection _____

Type: code 0-7 or 9; Location: measure distance from the CEJ to most occlusal portion of defect;
Color: code 1-4 for hypocalfications (type 6 or 7) only.

Maxilla, Right

Tooth	M^3			M^2			M^1			PM^2			PM^1			C			I^2			I^1		
Defect	1	2	3	1	2	3	1	2	3	1	2	3	1	2	3	1	2	3	1	2	3	1	2	3
Type																								
Location																								
Color																								

Maxilla, Left

Tooth	I^1			I^2			C			PM^1			PM^2			M^1			M^2			M^3		
Defect	1	2	3	1	2	3	1	2	3	1	2	3	1	2	3	1	2	3	1	2	3	1	2	3
Type																								
Location																								
Color																								

Mandible, Left

Tooth	M_3			M_2			M_1			PM_2			PM_1			C			I_2			I_1		
Defect	1	2	3	1	2	3	1	2	3	1	2	3	1	2	3	1	2	3	1	2	3	1	2	3
Type																								
Location																								
Color																								

Mandible, Right

Tooth	I_1			I_2			C			PM_1			PM_2			M_1			M_2			M_3		
Defect	1	2	3	1	2	3	1	2	3	1	2	3	1	2	3	1	2	3	1	2	3	1	2	3
Type																								
Location																								
Color																								

ENAMEL DEFECTS (HYPOPLASIAS AND OPACITIES) RECORDING FORM: DECIDUOUS TEETH

Site Name/Number _____/_____ Observer _____

Feature/Burial Number _____/_____ Date _____

Burial/Skeleton Number _____/_____

Present Location of Collection _____

Type: code 0-7 or 9.
Location: measure distance from the CEJ to the most occlusal portion of defect.
Color: code 1-4 for hypocalfications (type 6 or 7) only.

Maxilla, Right

Tooth	m^2			m^1			c			i^2			i^1		
Defect	1	2	3	1	2	3	1	2	3	1	2	3	1	2	3
Type															
Location															
Color															

Maxilla, Left

Tooth	i^1			i^2			c			m^1			m^2		
Defect	1	2	3	1	2	3	1	2	3	1	2	3	1	2	3
Type															
Location															
Color															

Mandible, Left

Tooth	m_2			m_1			c			i_2			i_1		
Defect	1	2	3	1	2	3	1	2	3	1	2	3	1	2	3
Type															
Location															
Color															

Mandible, Right

Tooth	i_1			i_2			c			m_1			m_2		
Defect	1	2	3	1	2	3	1	2	3	1	2	3	1	2	3
Type															
Location															
Color															

PREMORTEM DENTAL MODIFICATIONS RECORDING FORM

Site Name/Number _____/_____ Observer _____

Feature/Burial Number _____/_____ Date _____

Burial/Skeleton Number _____/_____

Present Location of Collection _____

Type of Modification: _____

1. Aesthetic modification: filing
2. Aesthetic modification: drilling
3. Dental restorations and appliances
4. Dental wear associated with artifact use or production
5. Tooth ablation

Comments:

Series/Burial/Skeleton_____

Observer/Date_____

DENTAL MEASUREMENTS AND MORPHOLOGY RECORDING FORM

Site Name/Number _____/_____ Observer _____

Feature/Burial Number _____/_____ Date _____

Burial/Skeleton Number _____/_____

Present Location of Collection _____

Dental Measurements

Record left side of arcade only; substitute antimere when left not observable.

Maxilla

Tooth	I^1	I^2	C	PM^1	PM^2	M^1	M^2	M^3
Mesiodistal diameter								
Buccolingual diameter								
Crown height								

Mandible

Tooth	M_3	M_2	M_1	PM_2	PM_1	C	I_2	I_1
Mesiodistal diameter								
Buccolingual diameter								
Crown height								

Series/Burial/Skeleton_____

Observer/Date_____

Dental Morphology

Maxilla

	Right						Left					
Tooth	M^3	M^2	M^1	PM^1	I^2	I^1	I^1	I^2	PM^1	M^1	M^2	M^3
Winging (0-4)												
Shoveling (0-7)												
Double-shoveling (0-6)												
Peg-shaped Incisor (0-2)												
Premolar Root Number (1-3)												
Hypocone (0-6)												
Metaconule (0-5)												
Carabelli's Trait (0-7)												
Enamel Extensions (0-3)												

Mandible

	Left				Right			
Tooth	M_3	M_2	M_1	PM_1	PM_1	M_1	M_2	M_3
Premolar Root Number (0-5)								
Groove Pattern (Y, +, X)								
Cusp Number (4-6)								
Protostylid (0-7)								
Cusp 5 (0-5)								
Cusp 6 (0-5)								
Cusp 7 (0-4)								
Molar Root Number (1-3)								

CRANIAL AND POSTCRANIAL MEASUREMENT RECORDING FORM: ADULT REMAINS

Site Name/Number _____/_____ Observer _____

Feature/Burial Number _____/_____ Date _____

Burial/Skeleton Number _____/_____

Present Location of Collection _____

Record all measurements to the nearest millimeter; in the case of bilateral measurements, take measurement on the left side. If right side is substituted, place an (R) next to the the measurement.
If bones are fragmented, measurements should not be taken, but dimensions should be estimated for minor erosion or reconstruction; identify these with an asterisk"*"

Cranial Measurements

1. Maximum Cranial Length: _____
2. Maximum Cranial Breadth: _____
3. Bizygomatic Diameter: _____
4. Basion-Bregma Height: _____
5. Cranial Base Length: _____
6. Basion-Prosthion Length: _____
7. Maxillo-Alveolar Breadth: _____
8. Maxillo-Alveolar Length: _____
9. Biauricular Breadth: _____
10. Upper Facial Height: _____
11. Minimum Frontal Breadth: _____
12. Upper Facial Breadth: _____
13. Nasal Height: _____
14. Nasal Breadth: _____
15. Orbital Breadth: _____
16. Orbital Height: _____
17. Biorbital Breadth: _____
18. Interorbital Breadth: _____
19. Frontal Chord: _____
20. Parietal Chord: _____
21. Occipital Chord: _____
22. Foramen Magnum Length: _____
23. Foramen Magnum Breadth: _____
24. Mastoid Length: _____
25. Chin Height_____
26. Height of the Mandibular Body: _____
27. Breadth of the Mandibular Body:_____
28. Bigonial Width: _____
29. Bicondylar Breadth: _____
30. Minimum Ramus Breadth: _____
31. Maximum Ramus Breadth: _____
32. Maximum Ramus Height: _____
33. Mandibular Length: _____
34. Mandibular Angle: _____

Series/Burial/Skeleton_____

Observer/Date _____

Record all measurements to the nearest millimeter; in the case of bilateral measurements, take measurement on the left side. If right side is substituted, place an (R) next to the the measurement.
If bones are fragmented, measurements should not be taken, but dimensions should be estimated for minor erosion or reconstruction; identify these with an asterisk"*"

Postcranial Measurements

35. Clavicle: Maximum Length: _____
36. Clavicle: Ant.-Post. Diameter at Midshaft: _____
37. Clavicle: Sup.-Inf. Diameter at Midshaft: _____
38. Scapula: Height: _____
39. Scapula: Breadth:_____
40. Humerus: Maximum Length: _____
41. Humerus: Epicondylar Breadth: _____
42. Humerus: Vertical Diameter of Head: _____
43. Humerus: Maximum Diameter at Midshaft: _____
44. Humerus: Minimum Diameter at Midshaft: _____
45. Radius: Maximum Length: _____
46. Radius: Anterior-Posterior Diameter at Midshaft : _____
47. Radius: Medial-Lateral Diameter at Midshaft: _____
48. Ulna: Maximum Length: _____
49. Ulna: Anterior-Posterior Diameter: _____
50. Ulna: Medial-Lateral Diameter: _____
51. Ulna: Physiological Length: _____
52. Ulna: Minimum Circumference:_____
53. Sacrum: Anterior Length: _____
54. Sacrum: Anterior Superior Breadth:_____
55. Sacrum: Max. Transverse Diameter of Base: _____
56. Os Coxae: Height: _____
57. Os Coxae: Iliac Breadth: _____
58. Os Coxae: Pubis Length: _____
59. Os Coxae: Ischium Length: _____
60. Femur: Maximum Length: _____
61. Femur: Bicondylar Length: _____
62. Femur: Epicondylar Breadth: _____
63. Femur: Maximum Diameter of the Femur Head: _____
64. Femur: Ant.-Post. Subtrochanteric Diameter: _____
65. Femur: Medial-Lateral Subtrochanteric Diameter: _____
66. Femur: Anterior-Posterior Midshaft Diameter: _____
67. Femur: Medial-Lateral Midshaft Diameter: _____
68. Femur: Midshaft Circumference: _____
69. Tibia: Length: _____
70. Tibia: Maximum Proximal Epiphyseal Breadth: _____
71. Tibia: Maximum Distal Epiphyseal Breadth: _____
72. Tibia: Max. Diameter at the Nutrient Foramen: _____
73. Tibia: Med.-Lat. Diameter at Nutrient Foramen: _____
74. Tibia: Circumference at the Nutrient Foramen: _____
75. Fibula: Maximum Length: _____
76. Fibula: Maximum Diameter at Midshaft: _____
77. Calcaneus: Maximum Length: _____
78. Calcaneus: Middle Breadth: _____

TAPHONOMY RECORDING FORM I: BURNED BONE

Site Name/Number _____/_____ Observer _____

Feature/Burial Number _____/_____ Date _____

Burial/Skeleton Number _____/_____

Present Location of Collection _____

List bones individually or in fragment clusters. Bone should be reported as **T**an, **B**lack (including dark brown), or **W**hite (including blue-gray). If more than one color appears on a single bone, list all appropriate colors and percentage of bone(s) affected. If reporting poorly preserved or highly fragmented materials, weights may be substituted for percentages. Surface texture should be reported as **L** (Longitudinally Split); **T** (Longitudinal and Transverse Checking); or **C** (Curved Cracks). Indicate presence by recording appropriate initials. Similarly, report the presence of deformed (warped) bone as **Y** (Present) or **N** (Not Present). The presence of surfaces shielded through articulation or by dense soft tissues should also be recorded as **Y** (Present) or **N** (Not Present) and described in the space provided.

Bone(s)	Color % Affected	Surface Texture	Warped?	Shielded Surfaces?

Series/Burial/Skeleton_____

Observer/Date _____

Bone(s)	Color % Affected	Surface Texture	Warped?	Shielded Surfaces?

TAPHONOMY RECORDING FORM II:
WEATHERING, DISCOLORATION, POLISH, CUTMARKS, GNAWING, and OTHER CULTURAL MODIFICATIONS

Site Name/Number _____/_____ Observer _____

Feature/Burial Number _____/_____ Date _____

Burial/Skeleton Number _____/_____

Present Location of Collection _____

This form is to be used in recording the following modifications: discoloration due to contact with metals, polish, cutmarks, other forms of cultural modifications, and rodent/carnivore gnawing. The following should be recorded. In every example, the nature of the modification should also be described in the space allocated.

Weathering: 1) Bone identification, 2) photographs of representative samples, 3) degree of weathering (use Behrensmeyer system provided in Table 1 for coding degree of weathering).

Discoloration: 1) Bone identification, 2) location (append drawing and photograph), 3) color of discolored bone and "normal" adjacent bone (use appropriate Munsell Chart(s)).

Polish: 1) Bone identification, 2) location (append drawing and photograph).

Cutmarks: 1) Bone identification, 2) location (append drawing and photograph), 3) number of cuts, 4) average cut length, 5) range of cut lengths, 6) sketch and cast (optional but recommended) of representative cut(s).

Evidence of Rodent and Carnivore Gnawing: 1) Bone identification,2) location (append drawing and photograph), 3) number of paired grooves or incisions. Evidence of rodent and carnivore gnawing should be recorded separately.

Other Forms of Cultural Modification Including the Creation of Artifacts: 1) Bone identification, 2) shape (append drawing and photograph).

Type of Bone Alteration	Location of Modification	# of Photographs/ # of Drawings	Additional Descriptive Information

Series/Burial/Skeleton_____

Observer/Date _____

Type of Bone Alteration	Location of Modification	# of Photographs/ # of Drawings	Additional Descriptive Information

PALEOPATHOLOGY RECORDING FORM I

SHAPE, SIZE, BONE LOSS, FORMATION, FRACTURES, AND POROTIC HYPEROSTOSIS

Site Name/Number _____/_____ Observer _____

Feature/Burial Number _____/_____ Date _____

Burial/Skeleton Number _____/_____

Present Location of Collection _____

1.0 SHAPE

Bone_____	Bone_____	Bone_____	Bone_____	Bone_____	Bone_____
Side_____	Side_____	Side_____	Side_____	Side_____	Side_____
Bone_____	Bone_____	Bone_____	Bone_____	Bone_____	Bone_____
Side_____	Side_____	Side_____	Side_____	Side_____	Side_____
Obs1_____	Obs1_____	Obs1_____	Obs1_____	Obs1_____	Obs1_____
Obs2_____	Obs2_____	Obs2_____	Obs2_____	Obs2_____	Obs2_____

2.0 SIZE

Bone_____	Bone_____	Bone_____	Bone_____	Bone_____	Bone_____
Side_____	Side_____	Side_____	Side_____	Side_____	Side_____
Obs_____	Obs_____	Obs_____	Obs_____	Obs_____	Obs_____

3.0 BONE LOSS

Bone_____	Bone_____	Bone_____	Bone_____	Bone_____	Bone_____
Side_____	Side_____	Side_____	Side_____	Side_____	Side_____
Section_____	Section_____	Section_____	Section_____	Section_____	Section_____
Aspect_____	Aspect_____	Aspect_____	Aspect_____	Aspect_____	Aspect_____
Obs1_____	Obs1_____	Obs1_____	Obs1_____	Obs1_____	Obs1_____
Obs2_____	Obs2_____	Obs2_____	Obs2_____	Obs2_____	Obs2_____
Obs3_____	Obs3_____	Obs3_____	Obs3_____	Obs3_____	Obs3_____
Obs4_____	Obs4_____	Obs4_____	Obs4_____	Obs4_____	Obs4_____
Obs5_____	Obs5_____	Obs5_____	Obs5_____	Obs5_____	Obs5_____
Obs6_____	Obs6_____	Obs6_____	Obs6_____	Obs6_____	Obs6_____
Obs7_____	Obs7_____	Obs7_____	Obs7_____	Obs7_____	Obs7_____
Obs8_____	Obs8_____	Obs8_____	Obs8_____	Obs8_____	Obs8_____

4.0 FORMATION

Bone_____	Bone_____	Bone_____	Bone_____	Bone_____	Bone_____
Side_____	Side_____	Side_____	Side_____	Side_____	Side_____
Section_____	Section_____	Section_____	Section_____	Section_____	Section_____
Aspect_____	Aspect_____	Aspect_____	Aspect_____	Aspect_____	Aspect_____
Obs1_____	Obs1_____	Obs1_____	Obs1_____	Obs1_____	Obs1_____
Obs2_____	Obs2_____	Obs2_____	Obs2_____	Obs2_____	Obs2_____
Obs3_____	Obs3_____	Obs3_____	Obs3_____	Obs3_____	Obs3_____
Obs4_____	Obs4_____	Obs4_____	Obs4_____	Obs4_____	Obs4_____
Obs5_____	Obs5_____	Obs5_____	Obs5_____	Obs5_____	Obs5_____
Obs6_____	Obs6_____	Obs6_____	Obs6_____	Obs6_____	Obs6_____

Series/Burial/Skeleton_____

Observer/Date_____

5.0 FRACTURES

Bone____	Bone____	Bone____	Bone____	Bone____	Bone____
Side_____	Side_____	Side_____	Side_____	Side_____	Side_____
Section_____	Section_____	Section_____	Section_____	Section_____	Section_____
Obs1_____	Obs1_____	Obs1_____	Obs1_____	Obs1_____	Obs1_____
Obs2_____	Obs2_____	Obs2_____	Obs2_____	Obs2_____	Obs2_____
Obs3_____	Obs3_____	Obs3_____	Obs3_____	Obs3_____	Obs3_____
Obs4_____	Obs4_____	Obs4_____	Obs4_____	Obs4_____	Obs4_____
Obs5_____	Obs5_____	Obs5_____	Obs5_____	Obs5_____	Obs5_____
Obs6_____	Obs6_____	Obs6_____	Obs6_____	Obs6_____	Obs6_____
Obs7_____	Obs7_____	Obs7_____	Obs7_____	Obs7_____	Obs7_____
Obs8_____	Obs8_____	Obs8_____	Obs8_____	Obs8_____	Obs8_____
Obs9_____	Obs9_____	Obs9_____	Obs9_____	Obs9_____	Obs9_____
Obs10_____	Obs10_____	Obs10_____	Obs10_____	Obs10_____	Obs10_____
Obs11_____	Obs11_____	Obs11_____	Obs11_____	Obs11_____	Obs11_____

6.0 POROTIC HYPEROSTOSIS

Bone_____	Bone_____	Bone_____	Bone_____	Bone_____	Bone_____
Side_____	Side_____	Side_____	Side_____	Side_____	Side_____
Obs1_____	Obs1_____	Obs1_____	Obs1_____	Obs1_____	Obs1_____
Obs2_____	Obs2_____	Obs2_____	Obs2_____	Obs2_____	Obs2_____
Obs3_____	Obs3_____	Obs3_____	Obs3_____	Obs3_____	Obs3_____

Comments:

_____

_____

_____

_____

_____

_____

_____

_____

_____

_____

_____

PALEOPATHOLOGY RECORDING FORM II
VERTEBRAL PATHOLOGY, ARTHRITIS, AND MISCELLANEOUS

Site Name/Number _____/_____ Observer _____

Feature/Burial Number _____/_____ Date _____

Burial/Skeleton Number _____/_____

Present Location of Collection _____

7.0 VERTEBRAL PATHOLOGY

Bone____	Bone____	Bone____	Bone____	Bone____	Bone____
Side_____	Side_____	Side_____	Side_____	Side_____	Side_____
Aspect_____	Aspect_____	Aspect_____	Aspect_____	Aspect_____	Aspect_____
Bone____	Bone____	Bone____	Bone____	Bone____	Bone____
Side_____	Side_____	Side_____	Side_____	Side_____	Side_____
Aspect_____	Aspect_____	Aspect_____	Aspect_____	Aspect_____	Aspect_____
Obs1_____	Obs1_____	Obs1_____	Obs1_____	Obs1_____	Obs1_____
Obs2_____	Obs2_____	Obs2_____	Obs2_____	Obs2_____	Obs2_____
Obs3_____	Obs3_____	Obs3_____	Obs3_____	Obs3_____	Obs3_____

8.0 ARTHRITIS

Bone____	Bone____	Bone____	Bone____	Bone____	Bone____
Side_____	Side_____	Side_____	Side_____	Side_____	Side_____
Section/	Section/	Section/	Section/	Section/	Section/
Aspect_____	Aspect_____	Aspect_____	Aspect_____	Aspect_____	Aspect_____
Bone____	Bone____	Bone____	Bone____	Bone____	Bone____
Side_____	Side_____	Side_____	Side_____	Side_____	Side_____
Section/	Section/	Section/	Section/	Section/	Section/
Aspect_____	Aspect_____	Aspect_____	Aspect_____	Aspect_____	Aspect_____
Obs1_____	Obs1_____	Obs1_____	Obs1_____	Obs1_____	Obs1_____
Obs2_____	Obs2_____	Obs2_____	Obs2_____	Obs2_____	Obs2_____
Obs3_____	Obs3_____	Obs3_____	Obs3_____	Obs3_____	Obs3_____
Obs4_____	Obs4_____	Obs4_____	Obs4_____	Obs4_____	Obs4_____
Obs5_____	Obs5_____	Obs5_____	Obs5_____	Obs5_____	Obs5_____
Obs6_____	Obs6_____	Obs6_____	Obs6_____	Obs6_____	Obs6_____
Obs7_____	Obs7_____	Obs7_____	Obs7_____	Obs7_____	Obs7_____
Obs8_____	Obs8_____	Obs8_____	Obs8_____	Obs8_____	Obs8_____
Obs9_____	Obs9_____	Obs9_____	Obs9_____	Obs9_____	Obs9_____

MISCELLANEOUS

Bone____	Bone____	Bone____	Bone____	Bone____	Bone____
Side_____	Side_____	Side_____	Side_____	Side_____	Side_____
Obs_____	Obs_____	Obs_____	Obs_____	Obs_____	Obs_____
Bone____	Bone____	Bone____	Bone____	Bone____	Bone____
Side_____	Side_____	Side_____	Side_____	Side_____	Side_____
Obs_____	Obs_____	Obs_____	Obs_____	Obs_____	Obs_____

Series/Burial/Skeleton_____

Observer/Date_____

COMMENTS

TREPANATION RECORDING FORM

Site Name/Number _____/_____ Observer _____

Feature/Burial Number _____/_____ Date _____

Burial/Skeleton Number _____/_____

Present Location of Collection _____

LOCATION (Bone/Side):_____

CERTAINTY:_____

1. Possible Trepanation
2. Clear Evidence of Trepanation

TECHNIQUE:_____

1. Scraping
2. Grooving
3. Boring-and-cutting
4. Rectangular incisions

HEALING:_____

1. No healing
2. Possible healing
3. Definite evidence for healing

MAXIMUM DIMENSION (mm):_____

MINIMUM DIMENSION (mm):_____

NUMBER OF ATTACHED DRAWINGS:_____/NUMBER OF PHOTOGRAPHS:_____

Comments

_____

_____

_____

_____

_____

_____

_____

_____

_____

_____

_____

Series/Burial/Skeleton_____

Observer/Date _____

CRANIAL DEFORMATION RECORDING FORM

Site Name/Number _____/_____ Observer _____

Feature/Burial Number _____/_____ Date _____

Burial/Skeleton Number _____/_____

Present Location of Collection _____

General category:_____

1. Tabular
2. Circumferential
3. Other (describe)

Posterior Aspect

Cranial deformation present:_____

1. Yes
2. No

Pressure was centered at:_____

1. Lambda
2. Squamous portion of occipital
3. Below inion

Plane of pressure in relationship to transverse plane:_____

1. Perpendicular (90^0)
2. Obtuse ($>90^0$)

Are any of the following present?_____

1. Sagittal elevation
2. Lambdic elevation
3. Lambdic depression

Pad impressions:_____

0. No pad impressions
1. One pad
2. Two pads
3. More than two pads

Pad location:_____

1. Midline
2. Symmetrically lateral to midline
3. Asymmetrically left
4. Asymmetrically right

Pad shape:_____

1. Circular or oval
2. Donut-shaped
3. Triangular
4. Irregular form
5. Not Observable

Impression of bindings visible:_____

1. Yes (describe below)
2. No

Anterior Aspect

Cranial deformation present:_____

1. Yes
2. No

Pad location:_____

1. High, near coronal suture
2. Low, near or below frontal boss

Symmetrical reshaping?_____

1. Yes
2. No, right side more deformed
3. No, left side more deformed

Bregmatic elevation?_____

1. Yes
2. No

Pad impressions:_____

0. No pad impressions
1. One Pad
2. Two Pads
9. Not observable

Pad location:_____

1. Midline
2. Symmetrically lateral to midline
3. Asymmetrically left
4. Asymmetrically right

Pad shape:_____

1. Circular or oval
2. Donut-shaped
3. Triangular
4. Irregular form
5. Not Observable

Impression of bindings visible:_____

1. Yes (describe below)
2. No

Post-coronal depression present?_____

1. Yes
2. No

Series/Burial/Skeleton_____

Observer/Date _____

Please draw outline of skull from superior and lateral aspects, indicating planes and extent of pressure, as well impressions of bindings.

LATERAL SUPERIOR

Photographs Taken

_____

_____

_____

Comments

_____

_____

_____

_____

_____

_____

_____

_____

_____

_____

_____

_____

_____

CHECKLIST FOR SKELETAL AND DENTAL SAMPLES

Site Name/Number _____/_____ Observer _____

Feature/Burial Number _____/_____ Date _____

Burial/Skeleton Number _____/_____

Present Location of Collection _____

Please indicate sample retention by an "X," followed by location where sample is curated, including name of institution and location within that institution.

1. Middle portion of femur midshaft (≥100 grams): L____/R_____
   Location:_____ ___ _____
2. Upper central incisor: L____/R_____
   Location:_____ ___ _____
3. Left ___and Right ____lower canines
   Location:_____ ___ _____
4. Two lower premolars (indicate side and position)
   Location:_____ ___ _____
5. Lower 2nd molar: L___/R___
   Location:_____ ___ _____
6. 5 Grams of trabecular bone (indicate bone and segment)_____
   Location:_____ ___ _____
7. Middle one-third of clavicle L___/R____
   Location:_____ ___ _____
8. 6th or _____(other) rib L___/R____
   Location:_____ ___ _____
9. Two sections_____or C-T scans_____ **of** R_____(or L_____) femur
   and one section_____or C-T scan_____ of L_____and R_____humeri
   Location:_____ ___ _____
10. Other samples (list bone or tooth sampled and curation location)

    Sample:_____

    Location:_____

    Sample:_____

    Location:_____

    Sample:_____

    Location:_____

Series/Burial/Skeleton_____

Observer/Date _____

Sample:_____

Location:_____

Sample:_____

Location:_____

Comments: