Monographs in Clinical Cytology
Editor: S.R. Orell
Vol. 15

Jerzy Klijanienko
Philippe Vielh

Salivary Gland Tumours

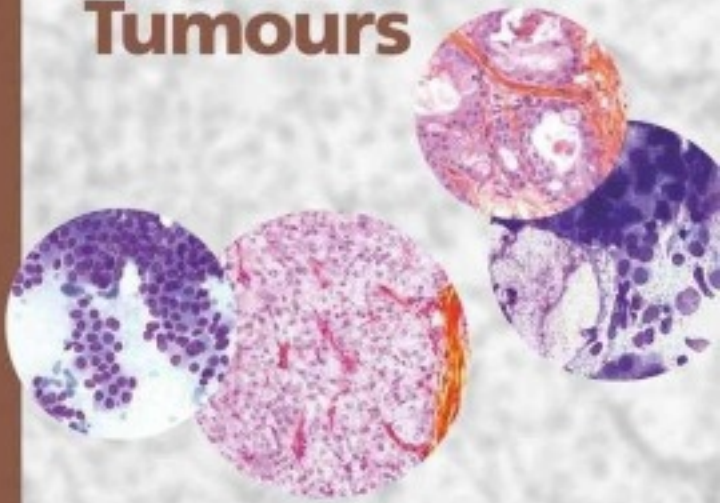

KARGER

Υλικό με προστασία πνευματικών δικαιωμάτων

Monographs in Clinical Cytology

Vol. 15

Series Editor *Svante R. Orell*, Kent Town

KARGER Basel · Freiburg · Paris · London · New York · New Delhi · Bangkok · Singapore · Tokyo · Sydney

Salivary Gland Tumours

Jerzy Klijanienko, Institut Curie, Paris
Philippe Vielh, Institut Curie, Paris

In collaboration with

John D. Batsakis, M.D. Anderson Cancer Center, Houston, Tex.
Adel K. El-Naggar, M.D. Anderson Cancer Center, Houston, Tex.
Michal Jelen, Akademia Medyczna, Wrocław
Jean-Daniel Piekarski, Fondation Adolphe de Rothschild, Paris

215 figures, 212 in color, and 52 tables, 2000

KARGER Basel · Freiburg · Paris · London · New York · New Delhi · Bangkok · Singapore · Tokyo · Sydney

Salivary Gland Tumours

Dr. Jerzy Klijanienko
Dr. Philippe Vielh
Institut Curie, Section Médicale
26, rue d'Ulm
F–75248 Paris Cedex 05 (France)
Tel. +33 1 44 32 42 60, Fax +33 1 44 32 40 71
Jerzy.Klijanienko@curie.net
Philippe.Vielh@curie.net

Library of Congress Cataloging-in-Publication Data

Salivary gland tumours/editors, Jerzy Klijanienko, Philippe Vielh; contributors, John D. Batsakis [et al.].
p.;cm. – (Monographs in clinical cytology; vol. 15)
Includes bibliographical references and index.
ISBN 3805570244 (hard cover: alk, paper)
1. Salivary glands – Tumors – Cytopathology. 2. Salivary glands – Tumors – Cytopathology – Atlases.
I. Klijanienko, Jerzy. II. Vielh, Philippe. III. Batsakis, John D. IV. Series.
[DNLM: 1. Salivary Gland Neoplasm – diagnosis – Atlases. 2. Adenocarcinoma – physiopathology – Atlases.
3. Biopsy, Needle – methods – Atlases. 4. Salivary Gland Neoplasms – physiopathology – Atlases. WI 17 S167 2000]
RC280.S3. S255 2000
616.99'2316 – dc21

Bibliographic Indices. This publication is listed in bibliographic services, including Current Contents® and Index Medicus.

Drug Dosage. The authors and the publisher have exerted every effort to ensure that drug selection and dosage set forth in this text are in accord with current recommendations and practice at the time of publication. However, in view of ongoing research, changes in government regulations, and the constant flow of information relating to drug therapy and drug reactions, the reader is urged to check the package insert for each drug for any change in indications and dosage and for added warnings and precautions. This is particularly important when the recommended agent is a new and/or infrequently employed drug.

All rights reserved. No part of this publication may be translated into other languages, reproduced or utilized in any form or by any means, electronic or mechanical, including photocopying, recording, microscopying, or by any information storage and retrieval system, without permission in writing from the publisher.

© Copyright 2000 by S. Karger AG,
P.O. Box, CH–4009 Basel (Switzerland)
Printed in Switzerland on acid-free paper by
Reinhardt Druck, Basel
www.karger.com
ISBN 3–8055–7024–4

To my daughters: Alice and Julie,
my parents: Teresa and Tadeusz,
to my sorely missed grandmother Wiktoria and Aunt Iwona,
and to Marie.

J. Klijanienko

To Laetitia Gorce, my nephews: Laure, Eric and Luc, and my forward-looking father.

Ph. Vielh

Contents

X Foreword

XI Preface

XII Acknowledgements

Chapter 1

1 **Introduction**

1 1.1. Demographics of Salivary Gland Tumours
1 1.2. History and Current Aspects of Fine-Needle Aspiration Cytology of Salivary Tumours
2 1.3. Accuracy of Fine-Needle Aspiration Cytology in Salivary Tumours
2 1.4. Clinical Indications for Fine-Needle Aspiration Cytology
4 1.5. Complications of Fine-Needle Aspiration Cytology

Chapter 2

5 **Fine-Needle Aspiration Cytology Procedure and Ancillary Techniques**

5 2.1. Specimen Processing
5 2.2. Choice of Ancillary Techniques
5 2.2.1. Cytochemistry
6 2.2.2. Immunocytochemistry
6 2.2.3. Cytogenetic Analysis
6 2.2.4. Molecular Genetic Analysis
6 2.2.5. DNA Content Analysis by Flow Cytometry
6 2.2.6. Microbiology Cultures

Chapter 3

7 **Imaging of Salivary Gland Tumours**
In collaboration with J.-D. Piekarski

Chapter 4

9 **Salivary Gland Anatomy and Tumour Histogenesis**
In collaboration with M. Jelen and A.K. El-Naggar

9 4.1. Structure and Anatomy
9 4.1.1. Parotid Gland
10 4.1.2. Submandibular Gland
10 4.1.3. Sublingual Gland
10 4.1.4. Minor Salivary Glands
10 4.2. Tumour Histogenesis

Chapter 5

11 **Basic Cytological Components and Diagnostic Approach**
In collaboration with A.K. El-Naggar

11 5.1. Components
11 5.1.1. Cells
17 5.1.2. Stroma
20 5.2. Tumour Classification
20 5.3. Diagnostic Approach

Chapter 6

22 **Adenomas**

22 6.1. Adenomas with Prominent Myoepithelial Cells
22 6.1.1. Pleomorphic Adenoma
29 6.1.2. Myoepithelioma (Myoepithelial Adenoma)
31 6.2. Adenomas with Prominent Oncocytes
31 6.2.1. Warthin's Tumour (Adenolymphoma)
36 6.2.2. Oncocytoma (Oncocytic Adenoma) and Oncocytosis
38 6.3. Adenomas with Prominent Basaloid Cells: Basal Cell and Canalicular Adenomas
43 6.4. Adenomas with Prominent Sebaceous Cells
43 6.4.1. Sebaceous Adenoma and Sebaceous Lymphadenoma
45 6.5. Papillary and Cystic Adenomas
45 6.5.1. Ductal Papilloma
46 6.5.2. Cystadenomas

Chapter 7

47 **High- and Intermediate-Grade Carcinomas**

47 7.1. Carcinomas with Squamous Cells
47 7.1.1. High-Grade Mucoepidermoid Carcinoma
52 7.1.2. Primary Squamous Cell Carcinoma
56 7.2. Undifferentiated Carcinoma
56 7.2.1. Large Cell Undifferentiated Carcinoma
56 7.2.2. Lymphoepithelial Carcinoma (Nasopharyngeal Type)
59 7.3. Carcinomas with Prominent Myoepithelial Cells
59 7.3.1. Adenoid Cystic Carcinoma
64 7.3.2. Epithelial-Myoepithelial (Clear Cell) Carcinoma
69 7.3.3. Malignant Myoepithelioma (Myoepithelial Carcinoma)
70 7.4. Carcinomas with Oncocytes
71 7.4.1. Malignant Oncocytoma (Oncocytic Carcinoma)
72 7.4.2. Carcinoma Ex Warthin's Tumour
72 7.5. Carcinomas with Sebaceous Cells
72 7.5.1. Sebaceous Carcinoma and Sebaceous Lymphadenocarcinoma
73 7.6. Other Carcinomas
73 7.6.1. Salivary Duct Carcinoma
77 7.6.2. Adenocarcinoma Not Otherwise Specified (NOS)
78 7.6.3. Small Cell Carcinoma
80 7.6.4. Mucinous Adenocarcinoma
80 7.6.5. Carcinoma Ex Pleomorphic Adenoma
85 7.6.6. Carcinosarcoma (True Malignant Mixed Tumour)

Chapter 8

86 **Low-Grade Carcinomas**

86 8.1. Low-Grade Mucoepidermoid Carcinoma
91 8.2. Acinic Cell Carcinoma
96 8.3. Polymorphous Low-Grade Adenocarcinoma
100 8.4. Papillary Cystadenocarcinoma
101 8.5. Basal Cell Adenocarcinoma

Chapter 9

106 **Benign and Malignant Mesenchymal Tumours and Miscellaneous Lesions**

106 9.1. Benign Mesenchymal Tumours
106 9.2. Malignant Mesenchymal Tumours
114 9.3. Miscellaneous Lesions

Chapter 10

115 **Lymphomas**
In collaboration with M. Jelen

Chapter 11

118 **Secondary Tumours**

Chapter 12

121 **Tumour-Like Lesions**

121 12.1. Sialadenosis
123 12.2. Necrotizing Sialometaplasia
123 12.3. Lymphoepithelial Lesions
125 12.4. Salivary Gland Cysts
127 12.5. Küttner's Tumour (Chronic Sclerosing Sialadenitis)
130 12.6. Reactive Processes

131 **References**

139 **Index**

Foreword

Who better to prepare a monograph of the cytopathology of salivary gland tumors than investigators from the Institut Curie, Paris, France? Drs. Klijanienko and Vielh are the latest in a galaxy of international authorities from that famed institution, which include Antoine Zajdela, Jacques Brugère, and Pierre Bataïni. These giants of Cytopathology, Head and Neck Surgery and Radiation Oncology were forerunners in what today is called 'interdisciplinary' management of patients with cancer. And this was being done at the Institut Curie as long as 1954!

The fine-needle aspiration cytopathology of salivary gland lesions has clinically and diagnostically matured over the past four decades. With the maturation of cytopathologic sensitivity and specificity, as well as accuracy of benign from malignant, has come the recognition of the clinical utility and limitations of the procedure. Overzealous adherents, who seemed more concerned with their diagnostic acumen, have been replaced by workers like Klijanienko and Vielh who, as they have in the monograph, in presenting a balanced viewpoint, see themselves as part of a team. Because of this leitmotif, the monograph stands out as not only an atlas but as a contemporary assessment of salivary gland oncology. It is as fine tribute to the authors' teachers.

John G. Batsakis, MD
Professor Emeritus of Pathology and
Former Head, Division of Pathology
University of Texas M.D. Anderson Cancer Center
Houston, Tex.

Preface

Salivary gland tumours constitute a special and difficult area of histopathology. Only pathologists who work for several years in specialized hospitals or oncology units accumulate sufficient experience to become confident in this field. Experience in diagnostic cytology of salivary gland tumours is also limited. Although fine-needle aspiration cytology is widely accepted as a tool in the pretreatment diagnostic work-up in several types of cancer, it remains controversial in salivary gland tumours despite numerous reports describing its high level of accuracy and simplicity.

Knowledge about salivary gland tumours has increased tremendously since the first edition of 'Histological Typing of Salivary Gland Tumours' in 1972. Nine types of adenomas and 18 types of primary carcinomas are currently recognized [300]. This classification is designed to facilitate the surgical pathologist's routine work. It reflects differences in prognosis and treatment, but still does not cover the whole spectrum of salivary gland tumours. This wide variety of tumours may make histological diagnosis difficult. The variability of histological patterns within the same tumour is an even more important problem in cytology, which can be only partly overcome by extensive sampling.

At the Institut Curie, fine-needle aspiration cytology of salivary gland lesions has been integrated into routine clinical practice since 1954, allowing review of a large series of cytology smears, but this long recruitment period has required histological reclassification to include more recently defined entities.

We have used the most recent [300] World Health Organization classification including several modifications proposed by the Armed Forces Institute of Pathology [89]. This manual focuses on the cytology of salivary gland tumours. We apologize to the many authors dealing with the histological aspects, who are not referred to in this monograph.

We hope that this monograph will be useful to pathologists practising cytological diagnosis of salivary gland lesions.

J. Klijanienko, Ph. Vielh

Acknowledgements

We would like to thank Dr. Antoine Zajdela, the pioneer of cytopathology and former Head of Cytopathology at the Institut Curie. He collected many of the cases presented in this monograph during his 40 years of practice. We also thank him for his constructive comments and moral support.

This work would not have been possible without the help of Drs. Jacques Brugère and Pierre Bataïni, former Heads of Head and Neck Surgery and Radiotherapy, respectively, who encouraged us and furthered our experience in salivary gland pathology.

We thank Mrs. Françoise Smadja for her precious skills in keeping the Institut Curie's archives in an exemplary order and Mrs. Véronique Marck and Eliane Padoy for their outstanding help in collecting cytology files. We also greatly appreciate Mr. Jean-Pierre Laborde for his crucial professional and friendly help for illustrations.

We gratefully acknowledge Prof. Jean-Pierre Camilleri, Director of the Medical Section of the Institut Curie, for his invaluable help during this work.

J. Klijanienko, Ph. Vielh

I would like to thank Dr. Christian Micheau, retired Head of Pathology at the Institut Gustave-Roussy (Villejuif), and Prof. Esteban Cvitkovic (Hôpital Paul Brousse, Villejuif) who initiated me in head and neck pathology, and Prof. Gerhard Seifert (Hamburg, Germany) who tolerated me as a young resident during the EORTC Salivary Tumours Histologic Panels.

J. Klijanienko

Chapter 1

Introduction

This volume is designed to describe the cytological diagnostic criteria of salivary gland tumours, to demonstrate that fine-needle aspiration cytology can be a simple and reliable method of diagnosis, and to dispel a number of common misconceptions related to fine-needle aspiration cytology in this area.

1.1. Demographics of Salivary Gland Tumours

Salivary gland tumours are uncommon. They account for about 3% of all head and neck tumours. The majority of these tumours occur during the fourth to seventh decades. The age-adjusted incidence is approximately 1.3 for males and 1 for females. There is a slight female predominance for benign tumours, but carcinomas are equally represented in both sexes. Two-thirds of tumours are benign and one-third are malignant [163].

The parotid gland is the gland most frequently involved (68%), while minor salivary glands and the submandibular glands are less commonly affected (23 vs. 9%) [89, 90]. The commonest benign tumour (60–70%) is pleomorphic adenoma. It usually arises in the parotid glands (75–80%), followed by the submandibular (5–10%), and minor salivary glands (10%). Warthin's tumour represents approximately 15% of all benign epithelial tumours (mainly involving the parotid gland), while oncocytoma (<0.5%), basal cell and other adenomas are rare. The commonest malignant tumour is adenoid cystic carcinoma (10%), followed by mucoepidermoid (5%), acinic cell (2%) and epithelial-myoepithelial carcinomas (0.5%) [163].

Most tumours in children are benign. Haemangioma and pleomorphic adenoma are the most frequent. Mucoepidermoid carcinoma is the commonest malignant tumour, but sarcomas, lymphomas, and acinic cell carcinomas have also been described [90].

1.2. History and Current Aspects of Fine-Needle Aspiration Cytology of Salivary Tumours

Fine-needle aspiration cytology was introduced in the 1920s by Martin and Ellis [238] at the Memorial Hospital in New York and by Dudgeon and Patrick [87] in St. Thomas' Hospital in London. Both centres reported very encouraging results, but this procedure declined in both centres 20 years later.

Pioneer series of salivary gland cytopathology were also published in France in 1959 [10, 31] and fine-needle aspiration cytology of salivary gland tumours was fully developed in the early 1950s in Europe by Antoine Zajdela at the Institut Curie (Paris) and Joseph Zajicek at the Karolinska Institute (Stockholm). Josef Zajicek's Scandinavian school of cytopathology defined modern fine-needle aspiration cytology, cytological morphological criteria and the differential diagnosis of the major tumour entities. This resulted in five [96, 222, 241, 270, 353] publications totalling more than 1,000 histologically correlated and well-documented cases. In 1980, Zajdela et al. [352] introduced fine-needle sampling without aspiration which was successfully used in salivary gland tumours. The value of cytology in salivary gland pathology was rapidly confirmed in the 1970s in the rest of Europe [32, 68, 340, 345]. After initial reluctance to adopt this technique, fine-needle aspiration cytology was introduced in the United States in the 1970s [63, 115, 201, 216, 230, 261, 310] and in Canada [277]. To date, nearly 4,000 cases of salivary gland lesions studied by cytology have been reported in the literature.

Despite this extensive literature, fine-needle aspiration cytology of salivary gland lesions still appears to be underutilized. At least five factors contribute to this situation:

– The rarity of salivary gland tumours make it difficult to collect representative cytology series, resulting in unfamiliarity of clinicians and lack of experience of pathologists with this technique.

– Continuous progress in the histological classification up until 1991 [300] limiting the value of large historical series.
– The lack of correlation between cytological and histological findings in early 'learning' series, giving this technique a 'bad reputation'.
– Unique use of Papanicolaou stain, which is less informative than the May-Grünwald-Giemsa stain.
– A trend from fine-needle to large-core biopsies as a result of professional pressures.

The replacement of 18 G needles by finer needles (23 or 27 G), the rare complications reported, and the growing accuracy and simplicity of the technique have led to a renewed interest in this technique, as reflected by the large number of scientific publications (approximately 40) each year.

1.3. Accuracy of Fine-Needle Aspiration Cytology in Salivary Tumours

Table 1.1 summarizes the accuracy of the technique for cytological diagnosis of salivary masses up until January 1999. Sensitivity ranges from 62 to 98%, specificity ranges from 85 to 100%, and accuracy ranges from 81 to 97%. However, these results must be interpreted cautiously, as this table includes statistics from early Scandinavian series using the Foote and Frazell [113] tumour classification. The classification of salivary gland tumours has changed over the last 45 years and several previously benign lesions are now considered to be low-grade malignancies. It is therefore possible that a large percentage of cases were misdiagnosed in historical series, while the rates of recurrent neoplasms were overestimated. We also encountered this problem, and approximately 35% of tumours were histologically reclassified according to WHO 1991 criteria.

The accuracy of cytology varies according to particular tumour types (tables 1.2, 1.3). Meta-analysis of the data of more than 300 publications published up until 1999 showed that benign lesions were correctly diagnosed in 92.5% of cases, but it is impossible to accurately assess the number of concordant diagnoses. False-positive or suspicious diagnoses leading to surgery were made in 3.3% of cases. The most difficult entity is basal cell adenoma, which has frequently been misdiagnosed as adenoid cystic carcinoma.

Malignancy was diagnosed or suspected in 85.1% of cases of malignant tumours, with 11.9% of false-negative results. The most difficult entities are low-grade mucoepidermoid carcinoma and carcinoma ex pleomorphic adenoma. Other malignancies, such as adenoid cystic carcinoma, acinic cell carcinoma and lymphoma, were also characterized by a relatively high false-negative rate, but this occurred mainly during the 'learning' period of early series.

Table 1.1. Sensitivity, specificity and accuracy of cytology in salivary gland lesions

Authors [ref.]	Year	Number	Sensitivity	Specificity	Accuracy
Mavec et al. [241]	1964	652	?	?	?
Eneroth et al. [96]	1967	690	64	95	89
Persson, Zettergren [270]	1973	216	86	99	95
Lindberg, Åckerman [222]	1976	461	67	85	81
Qizilbash et al. [277]	1985	101	88	100	98
O'Dwyer et al. [261]	1986	341	73	94	93
Layfield et al. [219]	1987	171	91	98	92
Jayaram et al. [169]	1989	195	81	94	88
Shaha et al. [305]	1990	160	95	98	97
Smith Frable, Frable [313]	1991	182	93	99	96
MacLeod, Frable [230]	1993	582	93	99	97
Zurrida et al. [358]	1993	246	62	100	87
Orell [263]	1995	325	85	99	94
Atula et al. [14]	1996	218	?	?	?
Filopoulos et al. [109]	1998	121	95	98	97
Boccato et al. [29]	1998	554	98	98	97
Al-Khafaji et al. [8]	1998	154	82	86	84
Our series	1999	1,253	94	97	95

Series including more than 100 histologically correlated cases. Statistics from the literature. Data are in %.

It must be stressed that the main objective of cytological diagnosis is to rule out neoplasia or confirm the presence of malignancy. Accurate tumour typing is less important and may be deferred to the definitive histological examination.

Finally, aspiration cytology can also be curative in the case of cystic lesions.

1.4. Clinical Indications for Fine-Needle Aspiration Cytology

The value of any diagnostic test is its ability to determine and perhaps modify the patient's further management [217]. The purpose of fine-needle aspiration cytology is to provide a diagnosis that eliminates the need for surgery in non-neoplastic lesions and guides treatment decisions. Fine-needle aspiration cytology should define whether or not the lesion is neoplastic. In the case of a neoplasm, fine-needle aspiration cytology indicates whether it is high-grade or low-grade malignant. The recognition of high-grade primary carcinoma, high-grade lymphoma or salivary gland metas-

Table 1.2. Diagnostic accuracy of cytology in benign salivary gland lesions

Types	Number	Benign	Suspicious/ false-positive	Unsatisfactory
Pleomorphic adenoma	1,747	1,642 (94)	53 (3)	52 (3)
Myoepithelioma	21	21 (100)	0	0
Basal cell adenoma	42	35 (83.3)	7 (16.7)	0
Warthin's tumour	265	244 (92.1)	6 (2.3)	15 (5.7)
Oncocytoma	24	22 (92)	2 (8)	0
Sebaceous adenoma	3	3 (100)	0	0
Inverted ductal papilloma	1	0	1	0
Intraductal papilloma	1	1	0	0
Soft tissue, benign	85	69 (81.2)	2 (2/3)	14 (16.5)
Subtotal, benign tumours	2,189	2,037 (93.1)	71 (3.2)	81 (3.7)
Sialadenosis	30	30 (100)	0	0
Lymphoepithelial lesion	49	47 (96)	1 (2)	1 (2)
Salivary cysts	48	41 (85.4)	3 (6.3)	4 (8.3)
Küttner's tumour	89	70 (78.7)	5 (5.6)	14 (15.7)
Subtotal, tumour-like lesions	216	188 (87)	9 (4.2)	19 (8.8)
Total benign	2,405	2,225 (92.5)	80 (3.3)	100 (4.2)

Statistics from the literature (up to 1999) including our series. % in parentheses.

Table 1.3. Diagnostic accuracy of cytology in malignant salivary gland

Malignancy	Number	Malignant	Suspicious	False-negative	Unsatisfactory
Acinic cell carcinoma	158	118 (74.4)	6 (3.8)	30 (19)	4 (2.5)
Mucoepidermoid carcinoma	169	99 (58.6)	15 (8.9)	39 (23)	16 (9.5)
Adenoid cystic carcinoma	247	205 (83)	8 (3.2)	30 (12.2)	4 (1.6)
Polymorphous low-grade carcinoma	17	15 (88.2)	0	2 (11.8)	0
Epithelial-myoepithelial carcinoma	13	10 (76.9)	1 (7.7)	1 (7.7)	1 (7.7)
Basal cell adenocarcinoma	11	11 (100)	0	0	0
Sebaceous carcinoma	4	4 (100)	0	0	0
Papillary cystadenocarcinoma	6	5 (83)	0	1 (17)	0
Mucinous adenocarcinoma	2	2	0	0	0
Oncocytic carcinoma	11	10 (91)	0	1 (9)	0
Salivary duct carcinoma	54	50 (92.6)	1 (1.8)	3 (5.6)	0
Malignant myoepithelioma	14	11 (79)	0	3 (21)	0
Carcinoma ex pleomorphic adenoma	68	37 (54.4)	6 (8.8)	24 (35.3)	1 (1.5)
Carcinosarcoma	5	4 (80)	1 (20)	0	0
Carcinoma ex Warthin's tumour	2	1	1	0	0
Squamous cell carcinoma	73	67 (91.8)	1 (1.4)	3 (4.1)	2 (2.7)
Small cell carcinoma	15	15 (100)	0	0	0
Undifferentiated carcinoma	20	13 (65)	6 (30)	1 (5)	0
Secondary tumour [1]	302	282 (93.4)	5 (1.6)	6 (2)	9 (3)
Hodgkin and lymphoma [2]	137	108 (78.8)	10 (7.3)	17 (12.4)	2 (1.5)
Sarcoma	29	25 (86.2)	1 (3.4)	3 (10.4)	0
Total	1,355	1,091 (80.5)	62 (4.6)	161 (11.9)	41 (3)

Statistics from the literature (up to 1999) including our series. % in parentheses.

[1] Not always histologically verified.

[2] Primary or secondary.

tasis from a known or unknown primary is especially important in order to correctly manage the patient.

A review of large series shows that fine-needle aspiration cytology of salivary tumours is safe, easy to perform, and accurate; all palpable salivary tumours should therefore be studied cytologically. In addition, fine-needle aspiration cytology provides even better results than frozen sections [153] and therefore constitutes a valuable noninvasive method of preoperative diagnosis. Finally, in the case of metastatic disease, the cytological diagnosis may be sufficient to indicate palliative medical treatment.

1.5. Complications of Fine-Needle Aspiration Cytology

There are virtually no complications and only a few cases have been reported. Post-cytology tumour necrosis may occasionally be seen [175, 218, 273]. In contrast with open surgical biopsies, tumour implantation of the needle tract has not been described [101, 241], and systematic histological sections of fine-needle tracts failed to demonstrate any tumour implants [108].

Chapter 2

Fine-Needle Aspiration Cytology Procedure and Ancillary Techniques

Table 2.1 lists the equipment useful for fine-needle aspiration cytology.

2.1. Specimen Processing

We strongly recommend that fine-needle aspiration cytology be performed by pathologists. The lesion should be immobilized with the fingers in order to clearly define the optimal skin site for aspiration. We use disposable 25 G needles (external diameter 0.6 mm) without local anaesthesia. The needle is inserted into the central part of the tumour and moved within the mass without aspiration until the first drops of blood appear in the barrel of the needle. Tissue resistance to the needle is an important parameter to ensure satisfactory material. The procedure is repeated once or twice.

Collected material is ejected onto a slide with a disposable 10-ml syringe, and a thin smear is made with a second slide. The consistency of ejected material is also an important parameter in quality control of sampling. In several tumours, such as pleomorphic adenomas, the dense, stroma-rich aspirated cytological material is difficult to smear. In such cases, needle sampling is firm. In cystic tumours, mucoid material or clear fluid may be aspirated. The pathologist should avoid prolonged sampling to prevent coagulation of the aspirated material. A second aspiration should be preferred to prolonged sampling.

Table 2.1. Equipment for fine-needle sampling in salivary gland tumours.

1. 25 or 27 G needles
2. Glass slides
3. Alcohol pads
4. 95% alcohol fixative for Papanicolaou stain
5. Diff-Quik stain
6. Microscope
7. Sterile vial for microbiology cultures, Hanks' balanced salt solution for cell suspension

Immediate microscopic examination is recommended during the sampling procedure, using Diff-Quik stain. At the Institut Curie, we use Diff-Quik stain (Dade-Merz AG, Düdingen, Germany, distributed by Baxter). This simple stain is performed on air-dried slides and allows sampled material to be analysed in 40 s. Diff-Quik stained slides can also be destained with toluene and then restained using May-Grünwald-Giemsa (MGG). This examination allows the pathologist to determine whether the needle is well targeted in the tumour mass and whether adequate material has been obtained. As the analysis of salivary gland tumours may also require ancillary techniques, Diff-Quik can be used to programme special samples for cytochemistry, immunocytochemistry, cytogenetics, flow cytometry and/or microbiology.

We use both the MGG and Papanicolaou methods for definitive staining. For MGG, slides are air-dried for 1 h before staining. For Papanicolaou, the wet slides are immediately fixed in 95% ethanol. When only a limited number of slides are available, we strongly recommend the use of MGG stain rather than Papanicolaou stain, as it is more informative for stromal and cytoplasmic analyses.

2.2. Choice of Ancillary Techniques

Several ancillary techniques, such as cytochemistry, immunocytochemistry and flow cytometry (DNA ploidy or immunophenotyping), can be applied directly on cell suspensions [92]. For this purpose, cells are immersed in 1 ml of Hanks' balanced salt solution (Gibco, Life Technologies, UK). After cytocentrifugation at 700 *g* for 5 min, the cellularity is checked by Diff-Quik stain, and the remaining suspension can be used for ancillary techniques.

2.2.1. Cytochemistry

Alcian blue, mucicarmine, or periodic acid-Schiff (PAS) at different pH are stains that can easily be applied to air-dried slides and cytospin suspensions. Leukocytes and histiocytes are used as internal controls for PAS staining intensity.

2.2.2. Immunocytochemistry

These techniques can easily be applied to smears and cytospin preparations. Centrifugation provides multiple slides, but we recommend parallel immunocytochemical staining on both smears and cytospin slides.

Immunocytochemical detection of intermediate filament markers plays a crucial role in diagnosis [25, 54, 133, 172, 228, 258, 266, 285, 333, 355, 356]. In particular, antibodies to S-100 protein, smooth muscle actin (SMA) and desmin are important to differentiate myoepitheliomas, myoepithelial carcinomas, rhabdomyomas and sarcomas. These three markers give varying degrees of positivity in myoepithelial tumours, but only desmin and SMA are positive in myogenic tumours. The use of antibodies directed against keratin and S-100 proteins help to distinguish between epithelial-myoepithelial carcinoma and several other tumours with similar morphology. Similarly, the use of antibodies directed against keratin and S-100 proteins, and antibodies such as HMB-45 and leukocyte common antigen are critical in the differential diagnosis between melanoma, undifferentiated carcinoma and large cell lymphoma.

2.2.3. Cytogenetic Analysis

Cytogenetic studies of salivary gland tumours have clearly shown recurrent chromosomal translocations and nonrandom alterations in defined subtypes. Cytogenetic rearrangements at chromosomes 8q12-15, 12q13-15 and 3p21 have been found in approximately 50% of pleomorphic adenomas [40]. Moreover, concurrent cytogenetic abnormalities in the stromal and cellular components of these tumours suggest an association with their morphological and possibly their potential biological features. Recently, a high mobility group protein gene (HMGI-C gene) has been cloned at the 12q15 multiple aberration region [295]. This gene may be involved in the development of pleomorphic adenoma and other benign mesenchymal tumours with similar chromosomal alterations. Other less frequently analysed tumours have manifested certain chromosomal abnormalities such as t(11;19), t(6;16) and t(2;7) in mucoepidermoid carcinoma and t(6;9), t(6;14) and t(5;12) in adenoid cystic carcinoma [39, 236]. More detailed analysis of these sites may therefore identify specific oncogenes and tumour suppressor genes putatively associated with the development and progression of these tumours.

2.2.4. Molecular Genetic Analysis

Recent advances in molecular techniques and the availability of molecular markers have allowed the analysis of submicroscopic alterations in interphase and extracted tissue from these tumours. These studies, although preliminary, have set the stage for in-depth analysis of target chromosomes to identify putative genes associated with these tumours.

2.2.4.1. Interphase in situ Hybridization (FISH)

Although limited, a few studies using the FISH technique have reported numerical and structural chromosomal alterations in interphase cells allowing the analysis of clonal heterogeneity and verifying data obtained from cytogenetic analyses [293].

2.2.4.2. Microsatellite Genetic Analysis

Several studies using polymorphic markers for detailed screening of genetic aberrations in salivary gland tumours have recently been published. The results show frequent loss of heterozygosity (LOH) in chromosomes 8q and 12q in pleomorphic adenomas, chromosomes 1p, 2p, 6q, 17p and 19q in adenoid cystic carcinomas and chromosomes 2p, 5p, 12p and 16q in mucoepidermoid carcinomas [128, 171, 348]. Furthermore, studies of several cases of carcinoma ex pleomorphic adenoma suggest that alterations at chromosomes 8q and/or 12q could be associated with development of pleomorphic adenoma and 17p alterations may be acquired during progression. Tumours with LOH have also been shown to manifest aggressive biological characteristics. Further studies of tumour categories and in-depth analysis of target regions may lead to identification of the genes involved in their development and progression which, in the future, may be used for diagnosis and clinical management of these tumours.

2.2.5. DNA Content Analysis by Flow Cytometry

Cytological material is ideal for DNA flow cytometric analyses when it is representative and when it contains a sufficient number of cells. DNA content can be performed on 10,000–20,000 cells, and regular fine-needle sampling contains approximately 1,000,000 cells [335].

DNA aneuploidy is associated with a poorer prognosis for several tumours, but nuclear DNA content analyses of malignant salivary gland tumours are still limited [91, 227].

2.2.6. Microbiology Cultures

Cytological material can easily be used for microbiological culture. Diff-Quik stain can discriminate between specific, nonspecific and giant cell inflammation. Samples should be sent to the microbiology laboratory as soon as possible, together with basic clinical data concerning age, sex, fever, past history, possible current antibiotic and the cytological features of inflammation.

Chapter 3

Imaging of Salivary Gland Tumours

Imaging is important in the diagnosis of salivary gland lesions [180]. The choice of imaging modality depends on the clinical presentation and has changed considerably over recent years. Ultrasound or computed tomography (CT) are the examinations of choice in patients with a history of acute or subacute painful swelling of a salivary gland suggestive of an inflammatory process. Plain x-rays can still be used to detect radiopaque sialolithiasis, but CT and even ultrasound also easily detect calcified stones.

Sialography uses contrast agent to demonstrate duct anatomy and very subtle findings, such as those observed in autoimmune disease (e.g. Sjögren's syndrome), but the diagnosis of these diseases is now essentially based on serology.

Magnetic resonance imaging (MRI) is currently the best examination for slow-growing masses. It provides excellent soft tissue visualization with good spatial resolution [170]. Because of the cost and accessibility of MRI and CT, these techniques are largely used in the evaluation of salivary gland masses. A CT contrast agent allows better differentiation. MRI and CT can explore the deep spaces in the craniofacial region (deep lobe of the parotid, parapharyngeal spaces, lymph nodes). MRI and CT can also differentiate intraglandular from extraglandular masses. The presence of intraparotid nodes can sometimes mimic a parotid mass and the detection of multiple nodes in the facial and cervical regions may be helpful.

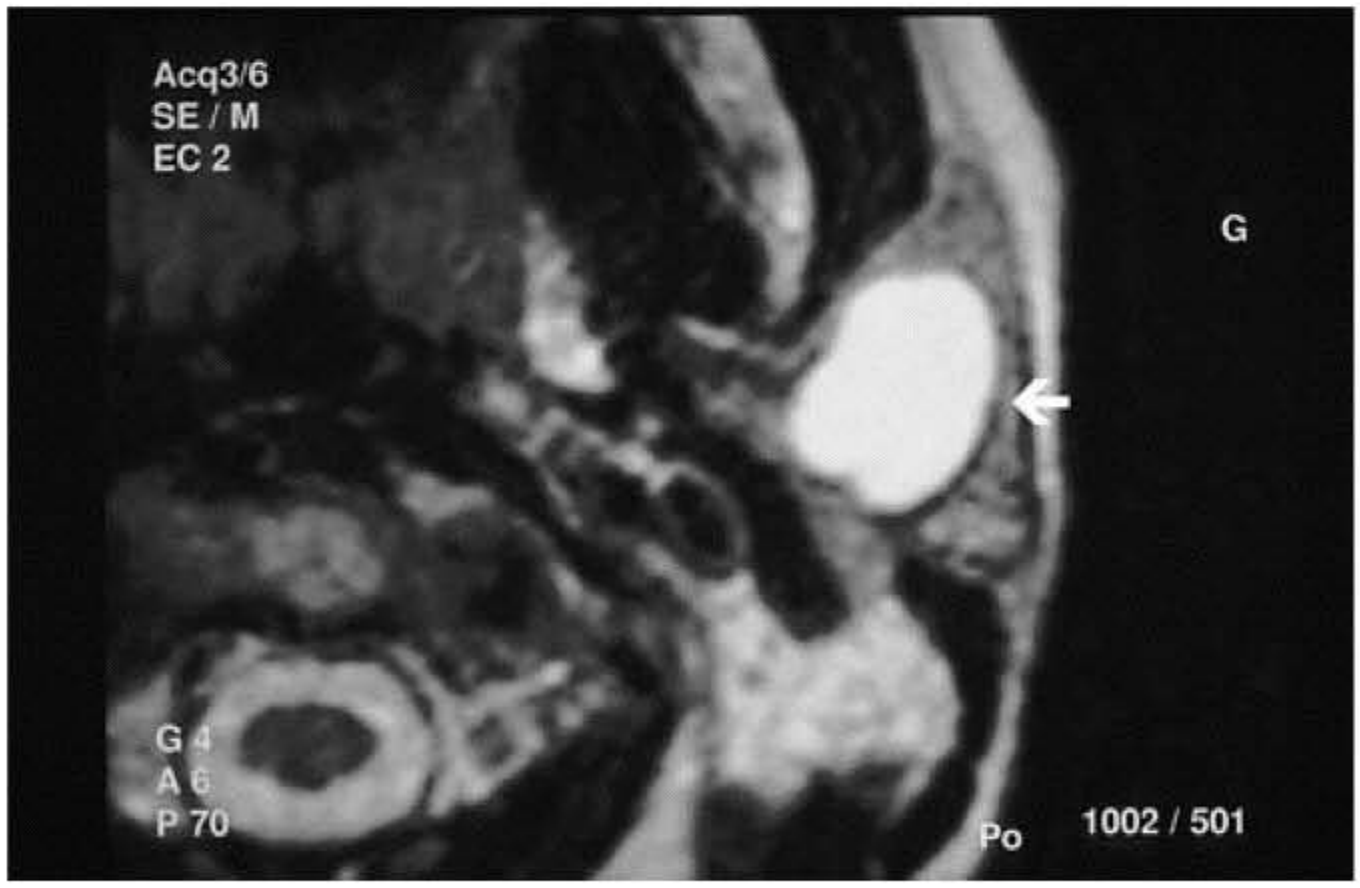

Fig. 3.1. Large left intraparotid cyst (arrow) with a high-intensity signal on axial T2-weighted MRI.

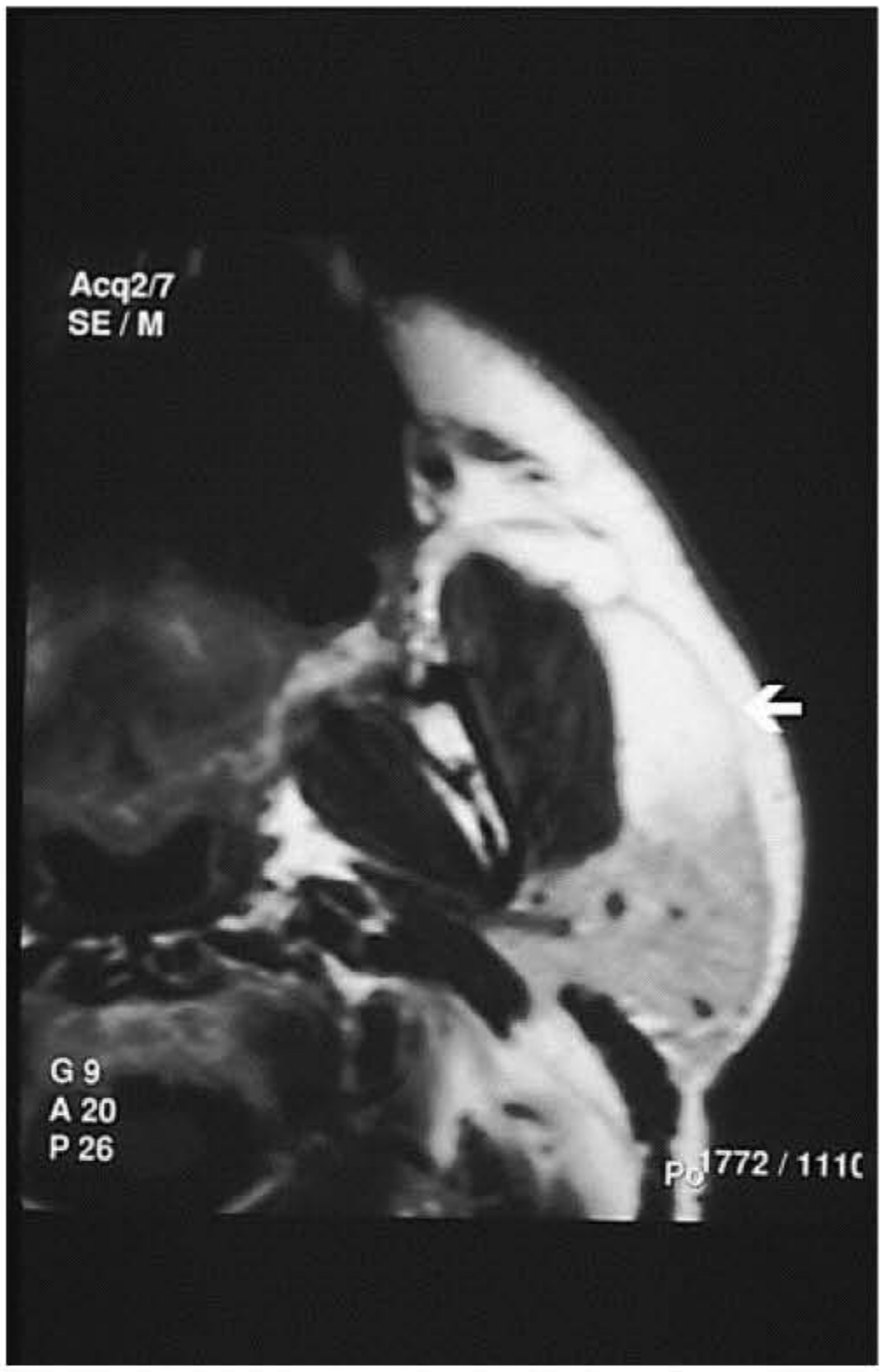

Fig. 3.2. Lipoma (arrow) of the anterior part of the left parotid gland displacing the normal tissue on axial T1-weighted MRI.

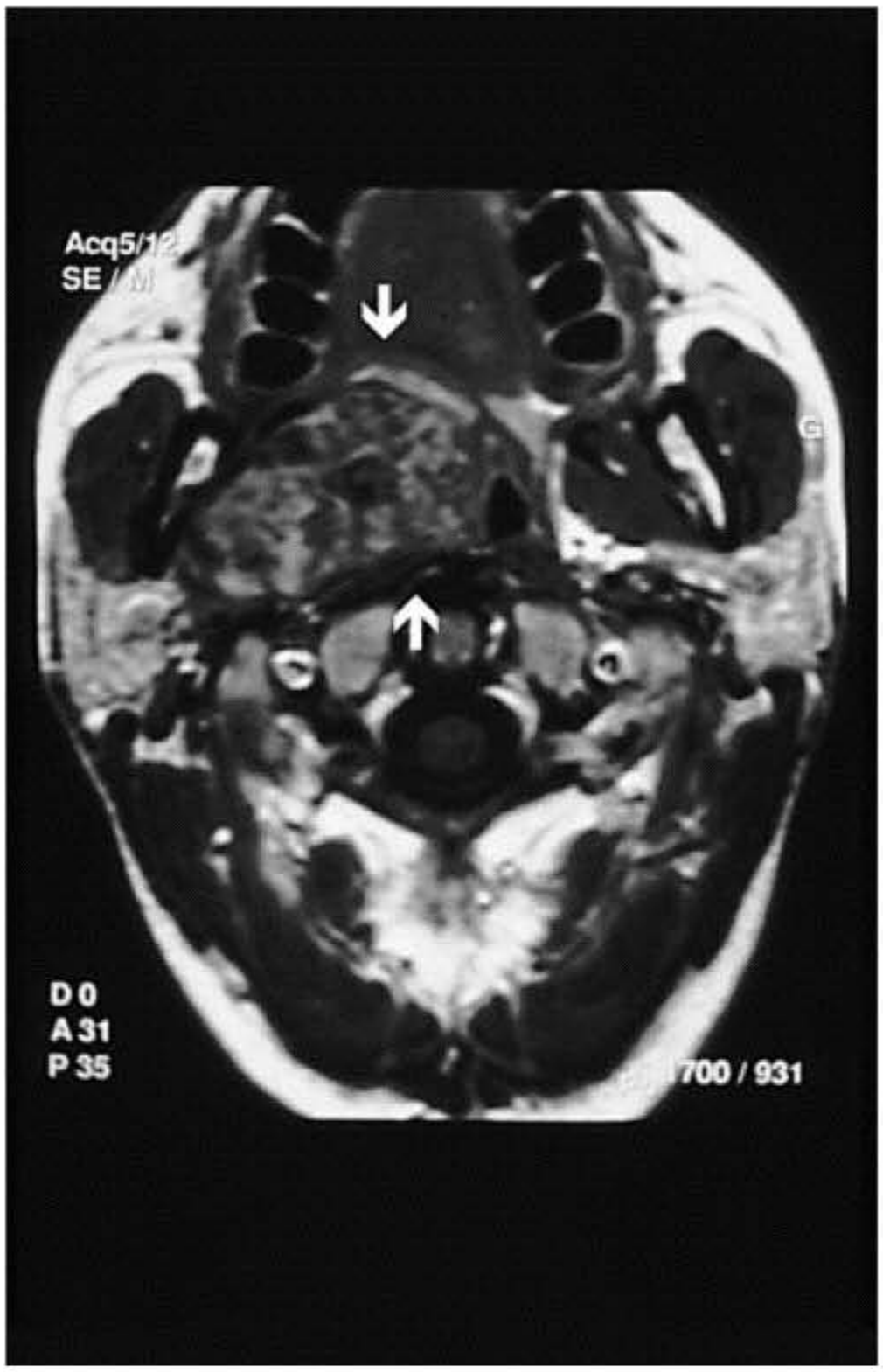

Fig. 3.3. Large tumour (arrows) next to the deep lobe of the right parotid gland, occupying the parapharyngeal space on contrast-enhanced axial T1-weighted MRI.

Masses can be solid, cystic or complex (fig. 3.1–3.3). Cystic masses can be isolated or related to a branchial cleft cyst. The presence of multiple cystic lesions in the parotid gland is suggestive of a diagnosis of HIV infection [156–237]. Retention cysts are usually seen in the floor of the mouth.

Pleomorphic adenoma is the commonest benign tumour. It is usually visualized as a round or oval intraglandular mass with smooth margins. Large pleomorphic adenomas can be heterogeneous with cystic areas or necrosis and sometimes calcifications. The most striking feature is a high-intensity signal on T2-weighted MRI, but this feature is not specific. Pleomorphic adenomas are enhanced by injection of contrast agent (iodinated contrast agent with CT, Gadolinium with MRI) [164].

Malignant tumours have poorly defined margins and are more heterogeneous. The presence of local pathological lymph nodes can also suggest the diagnosis of malignancy, but, in reality, there are no specific features and the definitive diagnosis is made by the pathologist.

Fine-needle sampling of salivary masses is increasingly effective. Ultrasound, CT or even MRI (with dedicated needles) are very helpful to guide needle sampling, particularly in partly cystic lesions, and close collaboration with an experienced pathologist provides accurate diagnoses in more than 90% of cases [173].

Chapter 4

Salivary Gland Anatomy and Tumour Histogenesis

4.1. Structure and Anatomy

In humans there are three pairs of major glands and numerous minor glands scattered throughout the mucosa of the oral cavity [239]. The main function of these glands is the production of saliva. Although morphologically and functionally similar, glands present in other anatomical regions of the head and neck are not considered to be salivary glands due to the lack of saliva. Salivary glands are composed of a system of acini and branching ducts that open into the oral cavity via excretory ducts. Salivary glands have different cellular compositions and functions, which largely depend on the acinar cell composition (serous and mucinous cells). The composition of the saliva depends on the relative proportions of these cells in a given gland.

4.1.1. Parotid Gland

The parotid gland is the largest of all salivary glands and weighs approximately 20–30 g. The parotid gland lies on the inferior aspect of the mandible. The parotid glands secretes saliva into the oral cavity via Stensen's duct. The duct emerges from the anterior part of the gland, crosses the lateral surface of the masseter muscle to penetrate the buccal fat and buccinator muscle at the anterior border of the masseter and opens onto the oral mucosa opposite the maxillary second molar tooth. In 20% of the population, an accessory parotid gland is situated anteriorly to the main parotid gland. Intraparotid lymph nodes are mainly located in the superficial lobe and drain the anterior portion of the ear, external auditory meatus, skin of the temporal and frontotemporal regions, eyelids, conjunctiva, roof of the nose, tympanic cavity and the parotid gland itself. These lymph nodes drain into the deep cervical lymph node chain. The duct structure of the gland consists of the main excretory duct, the interlobular duct and intralobular striated duct, which gives rise to the smaller intercalated branches connected to the acini. The parotid acini are spherical clusters of 3–6 cells surrounded by a basement membrane and containing a small lumen. Acinar cells have a triangular shape with their base lying on the basement membrane and their apex directed towards the lumen. Acinar cells are characterized by a small uniform nucleus and abundant cytoplasm rich in basophilic zymogen granules, the secretory granules. These granules are periodic acid-Schiff positive, but resistant to diastase digestion and negative for mucicarmine staining. The degree of cytoplasmic granulation is closely correlated with the activity of the cells. The intercalated duct is lined by cuboidal cells with a small nucleus and scant cytoplasm. This segment of the duct system is relatively short and difficult to identify. The outer layer of both the acini and intercalated duct cells is composed of myoepithelial cells, which are typically flat with branching cytoplasmic processes that extend to the intercalated duct cells. These cells exhibit cytoplasmic characteristics of epithelial and smooth muscles and are believed to play a role in the secretion of saliva via their contractile properties. The striated duct emerges from the intercalated duct. It is lined by columnar epithelium with central uniform nuclei and intensely eosinophilic cytoplasm due to the high mitochondrial content. The luminal aspect of the cells exhibits a fine vertical striation, the distinctive feature of this ductal segment. This striation is due to prominent basal folding of the plasma membranes. Sporadic myoepithelial and basal cells may rarely be found between the striated cells and the basement membrane of the duct. Interlobular and secretory ducts are lined by stratified columnar epithelium and the basal cell layer that separates them from the underlying basement membrane. Occasionally, mucin (goblet) cells may be found interspersed between

the duct cells. The segment of secretory duct near the oral mucosa is lined by stratified squamous epithelium. The gland is separated into lobules by thin fibrous septa and is surrounded by a capsule within and between the lobules. Variable amounts of adipose tissue may also be found and the degree of fat content increases with age. The parotid gland is uniquely characterized by the presence of lymphoid tissue that may contain foci of glandular structures in their medullary region. Not infrequently, sebaceous cells and small sebaceous glands can be found in the parotid parenchyma.

4.1.2. Submandibular Gland

The submandibular gland is the second largest salivary gland. It is located in the submandibular triangle defined by the inferior mandibular border and the anterior and posterior bellies of the digastric muscle. The main excretory duct, Wharton's duct, emerges from the superior aspect of the gland to open in the sublingual caruncula near the lingual frenum in the anterior floor of the mouth. The acini of the submandibular gland are a mixture of mucinous and serous cells with a predominance of mucinous cells. Serous cells are typically located at the periphery of mucinous cells. Mucinous cells are characterized by abundant clear or finely granular cytoplasm with basal nuclei. In general, there is considerably less adipose tissue than in the parotid gland and no lymphoid tissue is found.

4.1.3. Sublingual Gland

This gland is the smallest of all major salivary glands and weighs approximately 2–5 g. It lies in the floor of the mouth, in contact with the sublingual fossa on the lingual aspect of the mandible. This gland produces multiple sublingual ducts that open directly into the oral cavity. The largest of these ducts is called Bartholin's duct and opens into the mandibular duct posterior to its opening in the caruncula. This is a mixed serous and mucinous gland. The serous cells are located peripherally and form demilunes around the mucinous cells. The acini in this gland are typically elongated and the lobular glandular architecture in less developed than in the parotid and submandibular glands. This gland is also devoid of any lymphoid content.

4.1.4. Minor Salivary Glands

Numerous (500–1000) minor salivary lobules are dispersed underneath the oral epithelium. The glandular lobules are 1–5 mm in diameter and are separated by thin corrective tissue. Lobules have their own excretory ducts that open directly into the oral cavity.

4.2. Tumour Histogenesis

Pathological alteration of glandular and secretory duct cells results in totally different physiological function and morphological features. Examples of such altered cells include mucosal and squamous cells observed in mucoepidermal tumours and in atrophic changes of salivary glands; sebaceous cells emerging as a result of metaplasia of excretory duct epithelium, but also revealed in 28% of healthy salivary glands and in the vicinity of tumours in about 25% of cases. Such cells constitute the predominant component of certain tumours, such as sebaceous adenoma, sebaceous lymphadenoma or sebaceous carcinoma. These salivary gland epithelial cells have a high potential for multidirectional differentiation. Other cells emerging in pathological states are clear cells. The characteristic signs of these cells are a distinct 'plant' cell membrane and water-clear cytoplasm because of the high percentage of glycogen and huge vesicular nuclei with condensed chromatin; they are exclusively found in pleomorphic adenoma, mucoepidermoid carcinoma, acinic cell carcinoma, and epithelial-myoepithelial carcinoma. The last cell type is the oncocyte, derived from various origins; they may arise from mucous cells, serous cells, excretory ducts and also myoepithelial cells. They are analogous to cells occurring in the thyroid gland, adrenal cortex and hypophysis. The formation of these cells is related to mitochondrial hyperplasia. Apart from non-neoplastic changes, such as oncocytosis, oncocytes are an important component of pleomorphic adenomas, Warthin's tumours and the main component of oncocytic adenoma-carcinoma.

The histogenesis of pleomorphic adenoma has been discussed for many years. The mixture of various cell types has raised a lot of controversy among pathologists and cannot be easily elucidated. Two histogenetic hypotheses are distinguished. One hypothesis, proposed by the oldest researchers of the German school, suggests that the tumour has a diploplastic structure, i.e. it simultaneously arises from epithelial and mesenchymal components, corresponding to the concept of mixed tumour. The second hypothesis, proposed by the French school, suggests that the tumour is exclusively derived from epithelium and develops from mature salivary tissue, whereas mesenchymal components are the result of stromal metaplasia occurring as a consequence of chemical influences, secreted by epithelial tumour cells; this concept corresponds to the name pleomorphic adenoma. Since that time, a third concept of concomitant origin from epithelial and myoepithelial cells, supported by immunohistochemical and ultrastructural investigations, now prevails [52, 53, 71–76, 103, 160, 228, 258, 264, 268, 297].

Chapter 5

Basic Cytological Components and Diagnostic Approach

5.1. Components

Cytological smears from salivary gland tumours may be either cellular and/or stroma-rich. The correct recognition of both cellular and stromal tumour components (stroma is well presented by MGG stain) is very important for diagnosis and tumour typing.

5.1.1. Cells

5.1.1.1. Myoepithelial Cells

This cell type is rarely seen as an isolated element in non-neoplastic salivary gland tissue and myoepithelial cells are closely related to epithelial structures. Neoplastically modified myoepithelial cells play a key role in the characteristics of certain salivary gland tumours. One of the commonest patterns is large cells with an oval to plasmacytoid shape, oval to round nuclei and large, well-delimited strongly blue cytoplasm (fig. 5.1, 5.2) [198]. Highly cellular benign tumours, such as cellular pleomorphic adenoma, may present marked anisokaryosis, but no mitotic activity. Less common forms are epithelioid spindle-shaped, or clear cell variants (fig. 5.3). Malignant myoepithelial cells usually demonstrate increased mitotic activity, cytological pleomorphism or loss of cytoplasm. Certain malignant cells may resemble basaloid cells (fig. 5.4) [195].

5.1.1.2. Oncocytes

Oncocytes are large cells with a greyish cytoplasm on MGG stain (fig. 5.5, 5.6). They are the result of age-induced variations and become constant after the age of 70 years, with no pathological significance. The cytoplasm of oncocytes contains numerous mitochondria giving a granular appearance on light microscopy. This cell type participates in about 10% of various salivary tumours, including benign and malignant oncocytomas, Warthin's tumour and pleomorphic adenoma [199].

The differential diagnosis must include moderately differentiated acinar cells in acinic cell adenocarcinoma, intermediate-type cells in mucoepidermoid carcinoma, oncocyte-like cells in certain variants of salivary duct carcinoma and clear cells in mucoepidermoid carcinoma.

5.1.1.3. Basal Cells

Basal cells are uniform and arranged in tubular and trabecular patterns. Solid, three-dimensional nests are often present. Epithelial cells are columnar or cuboidal with scant or absent cytoplasm, and regular, elongated nuclei without atypia or mitotic activity (fig. 5.7) [188]. Malignant basal cells are arranged in aggregates and trabeculae of various sizes. Cells are small, round with scant cytoplasm and dark nucleus. The peripheral part of cell aggregates is lined by palisading cells in contact with the stroma. In the centre of the aggregates, the cells are larger and slightly eosinophilic; a squamoid appearance is occasionally seen [188]. Tubules, if present, show periodic acid-Schiff positive hyaline deposits. Mucicarmine stain is negative.

Basal cells should be differentiated from myoepithelial/basaloid cells in solid-type adenoid cystic carcinoma, cellular pleomorphic adenoma and basal cell carcinoma of the skin. The characteristic connective tissue fragments in adenoid cystic carcinoma, the presence of a large blue cytoplasm in cellular pleomorphic adenoma and clinical evidence of skin tumour in basal cell carcinoma may be helpful to distinguish basal cells.

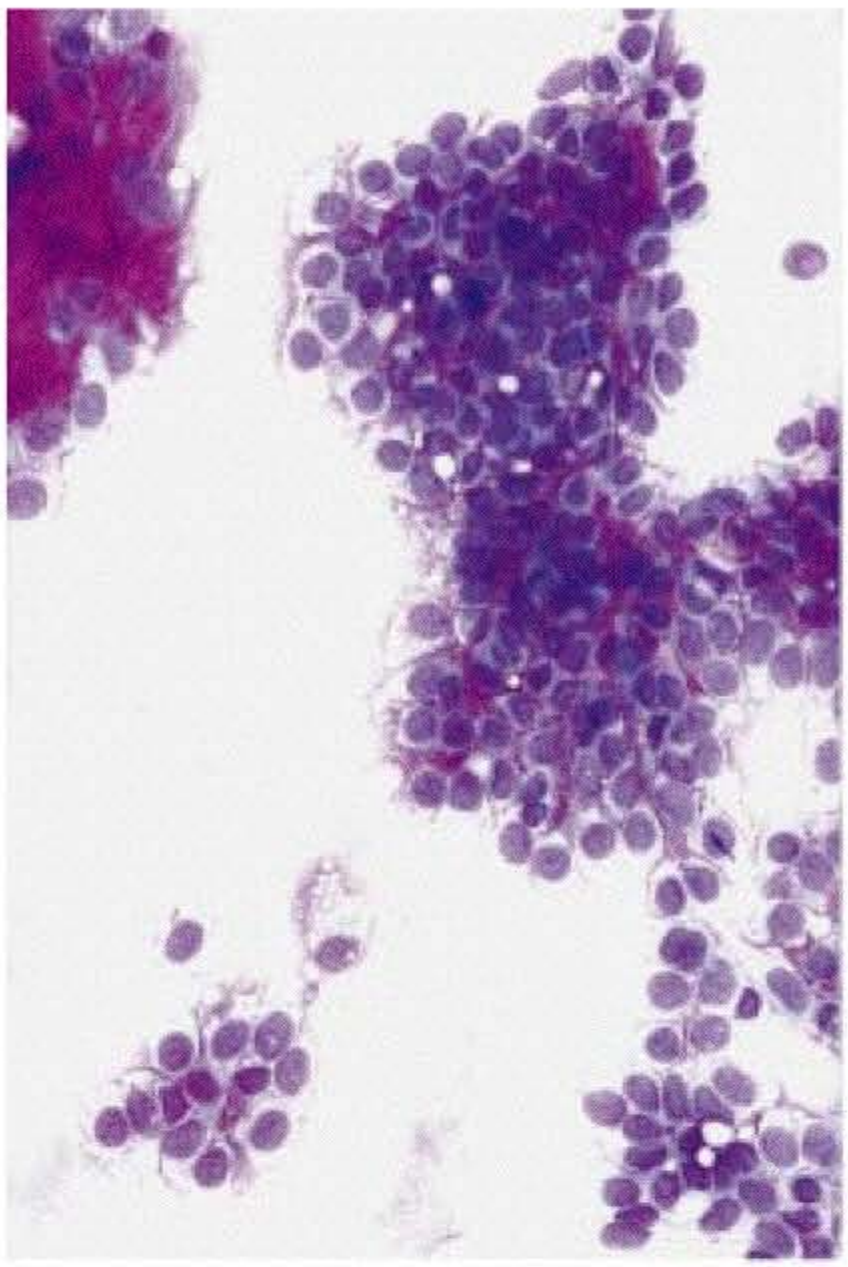

5.1

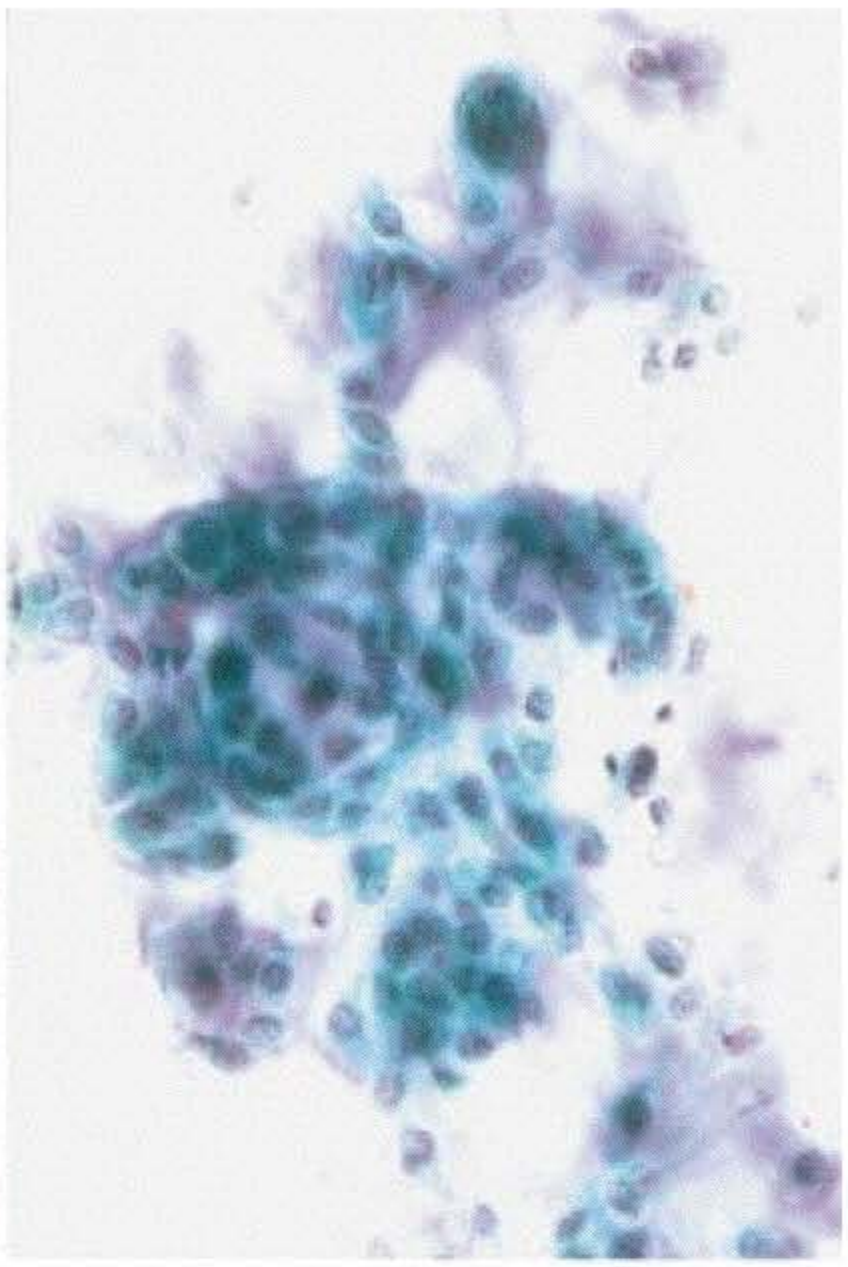

5.2

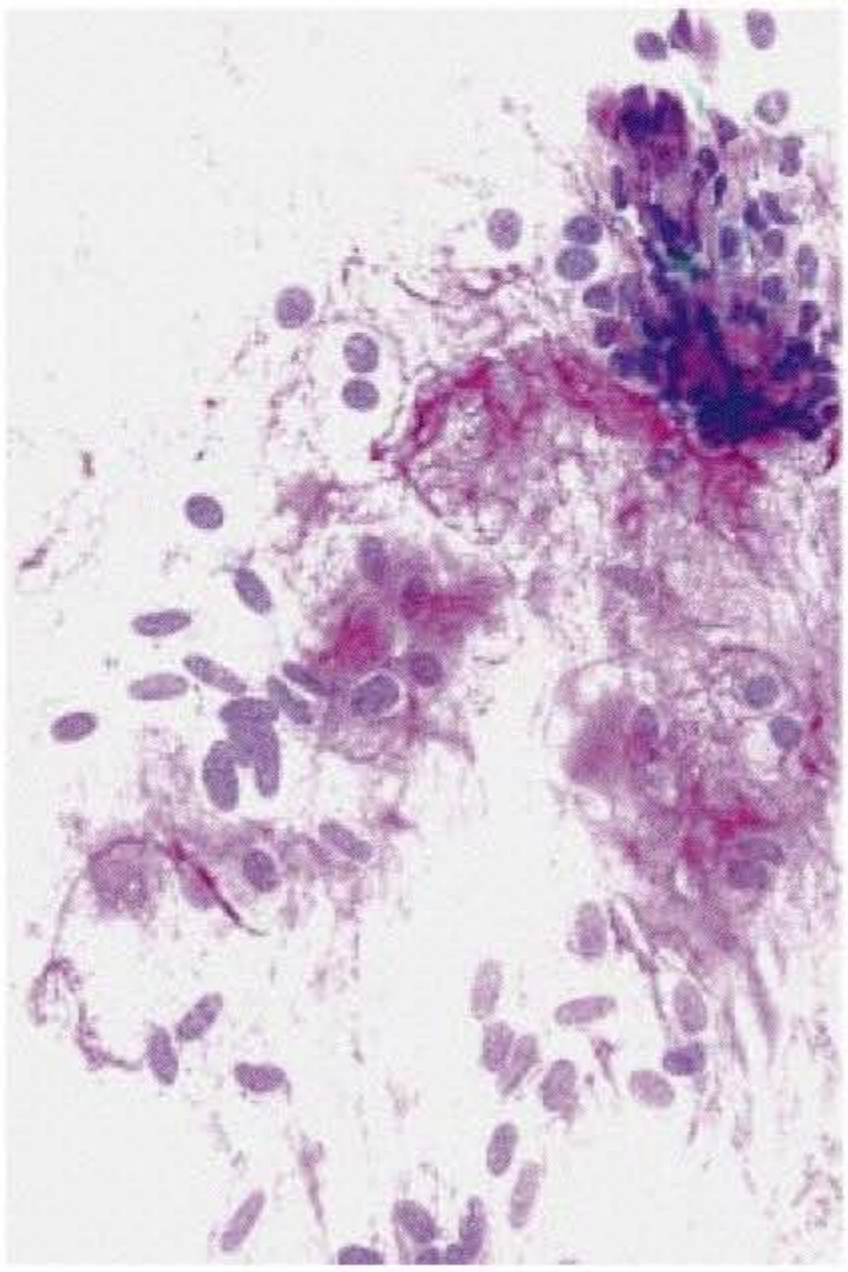

5.3

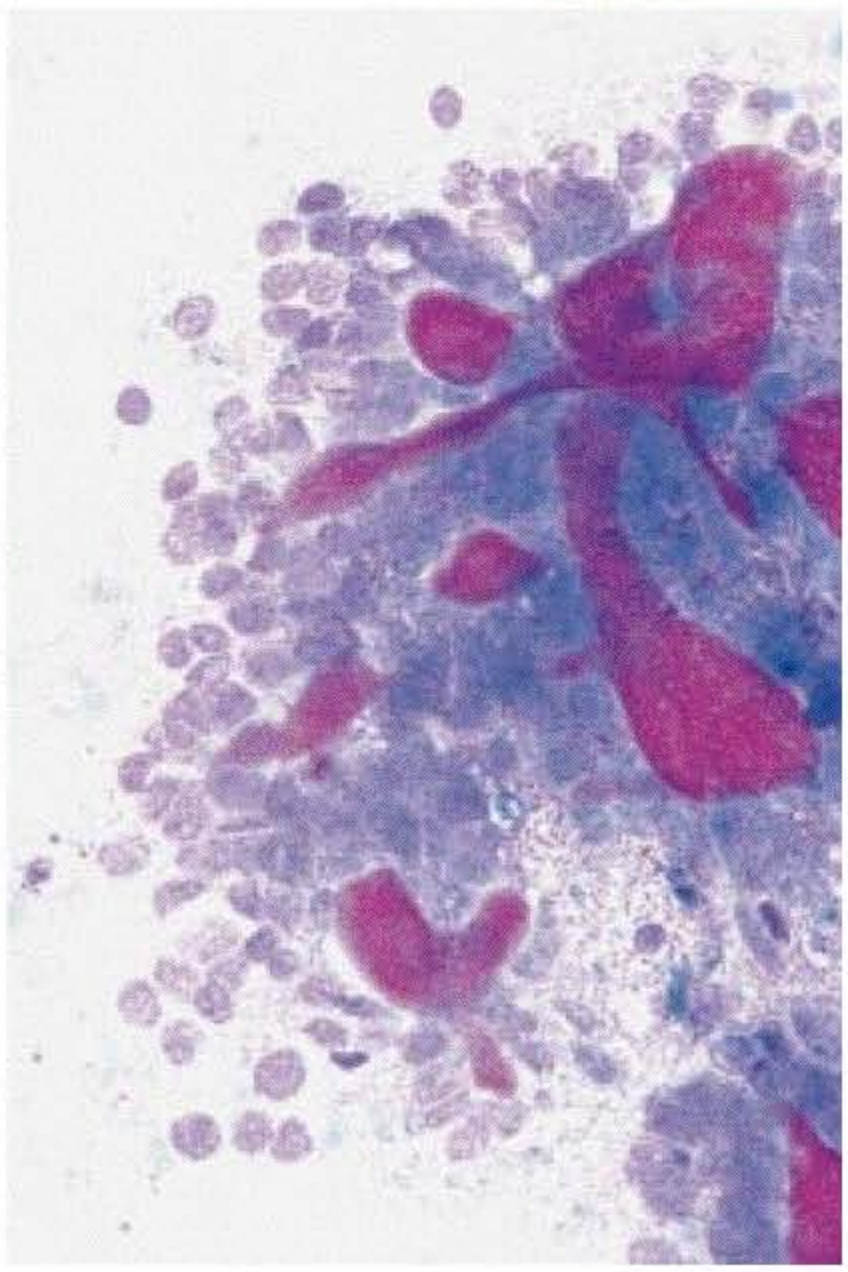

5.4

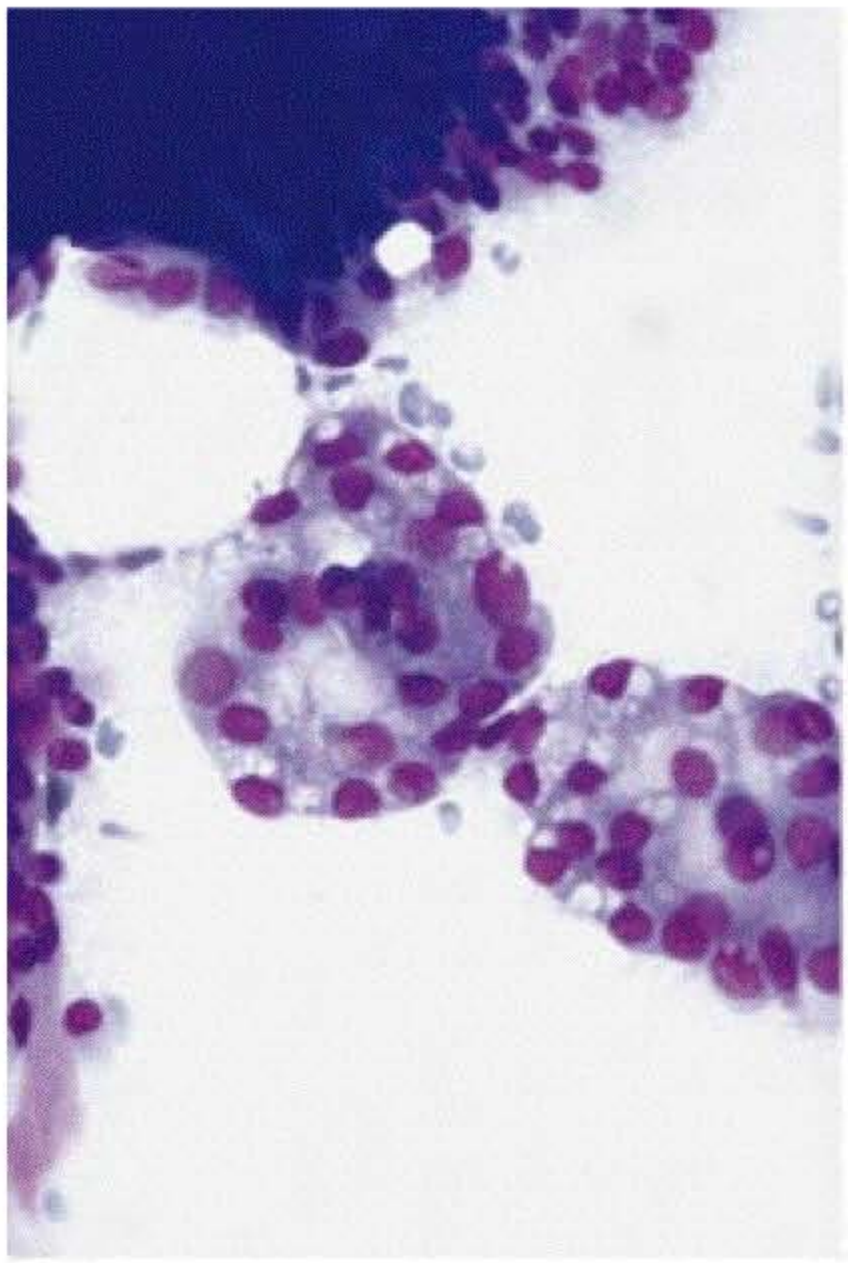

5.5

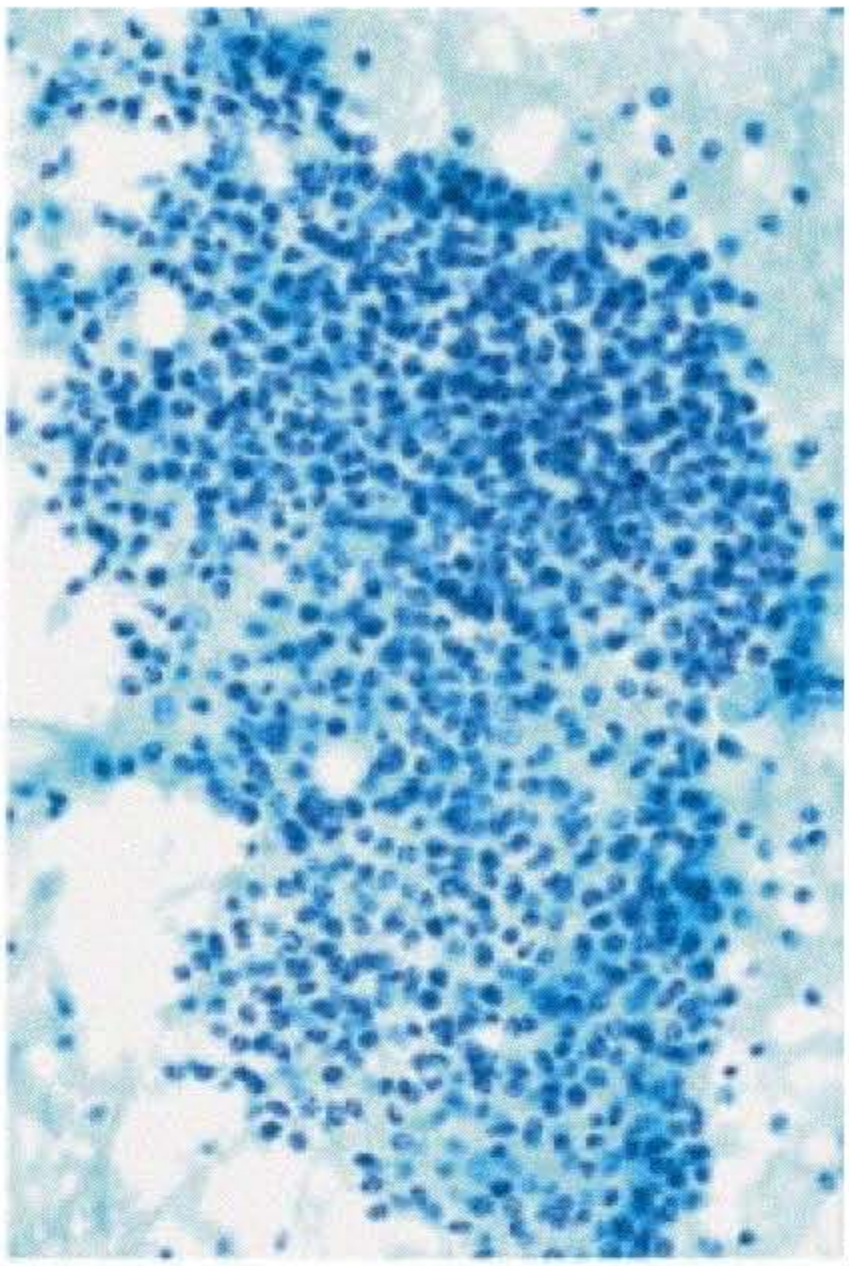

5.6

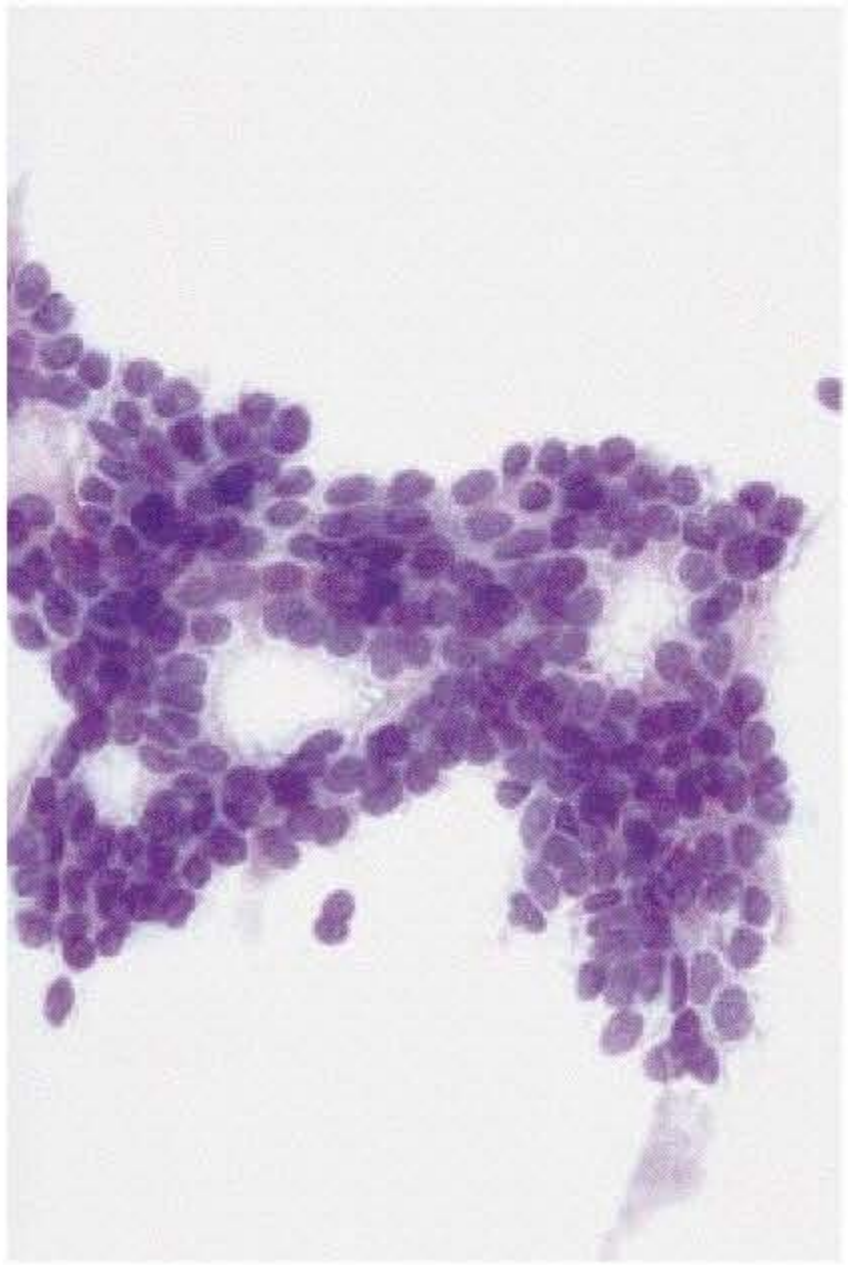

5.7

Fig. 5.1. Plasmacytoid myoepithelial cells with well-preserved cytoplasmic limits in pleomorphic adenoma, arranged in clusters or isolated. Nuclear pleomorphism can be seen. MGG. ×128.

Fig. 5.2. Plasmacytoid myoepithelial cells in pleomorphic adenoma. Papanicolaou. ×128.

Fig. 5.3. Spindle-shaped myoepithelial cells in myoepithelioma. MGG. ×128.

Fig. 5.4. Malignant myoepithelial cells with a basaloid morphology in adenoid cystic carcinoma. MGG. ×128.

Fig. 5.5. Oncocytes with vacuolized (clear) cytoplasm in pleomorphic adenoma. MGG. ×128.

Fig. 5.6. Oncocytes in Warthin's tumour. Papanicolaou. ×64.

Fig. 5.7. Basaloid cells with scant cytoplasm in basal cell adenoma. Nuclei are regular. MGG. ×128.

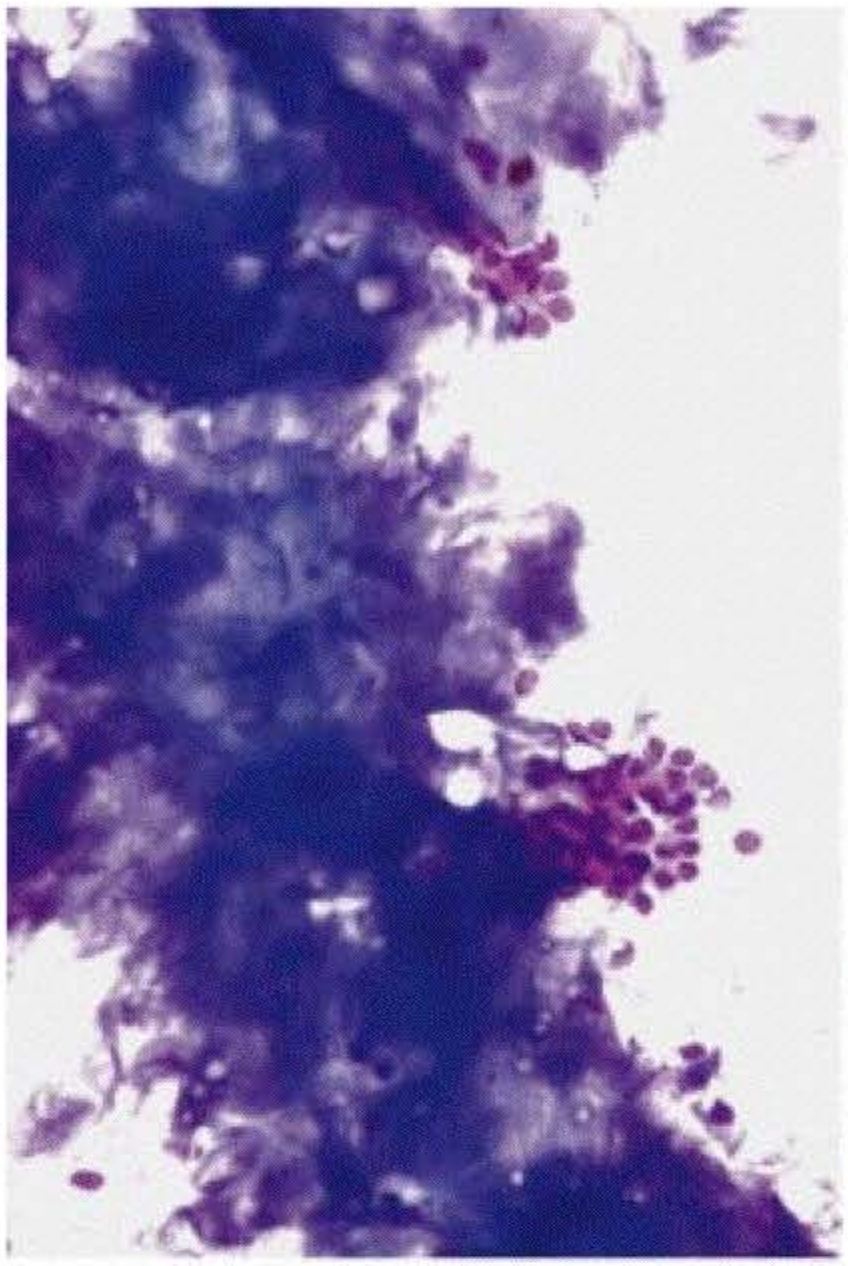

5.8

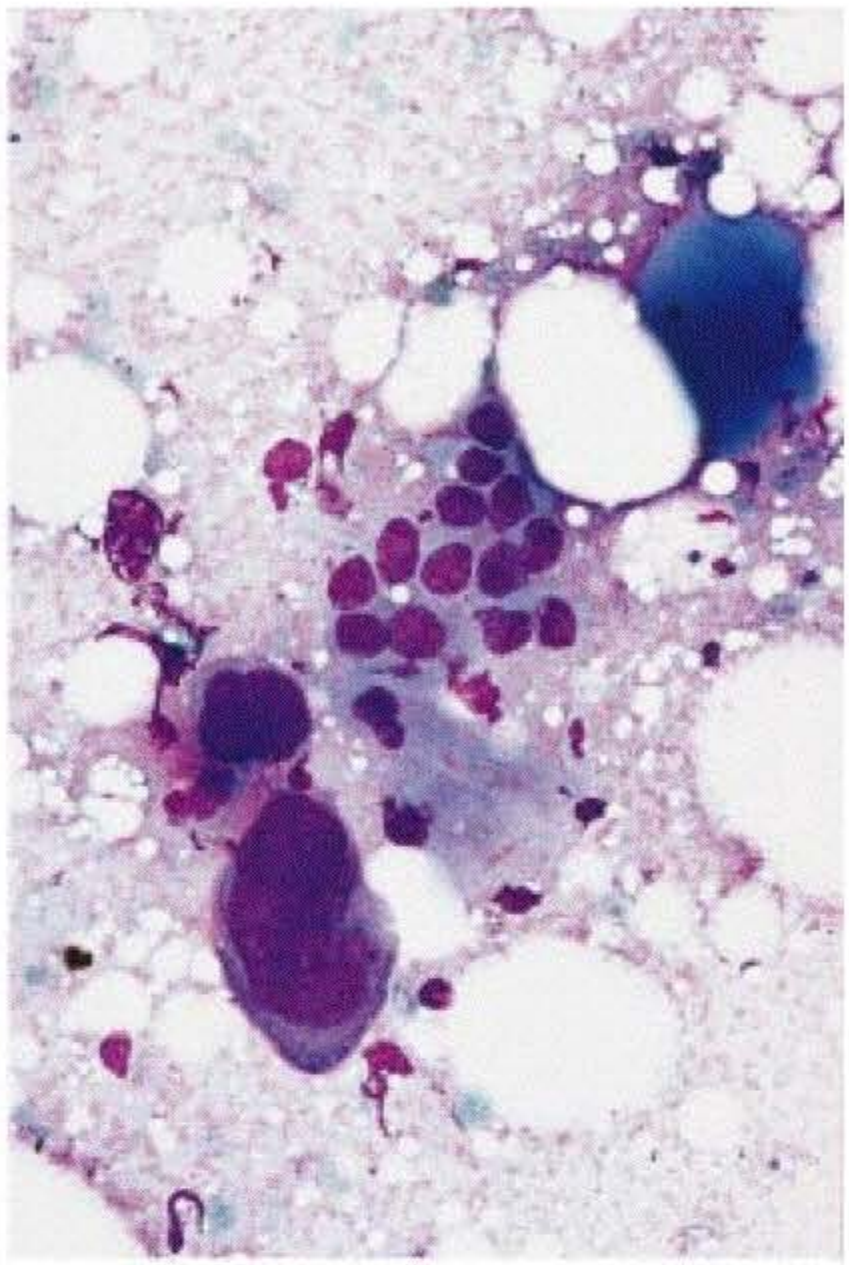

5.9

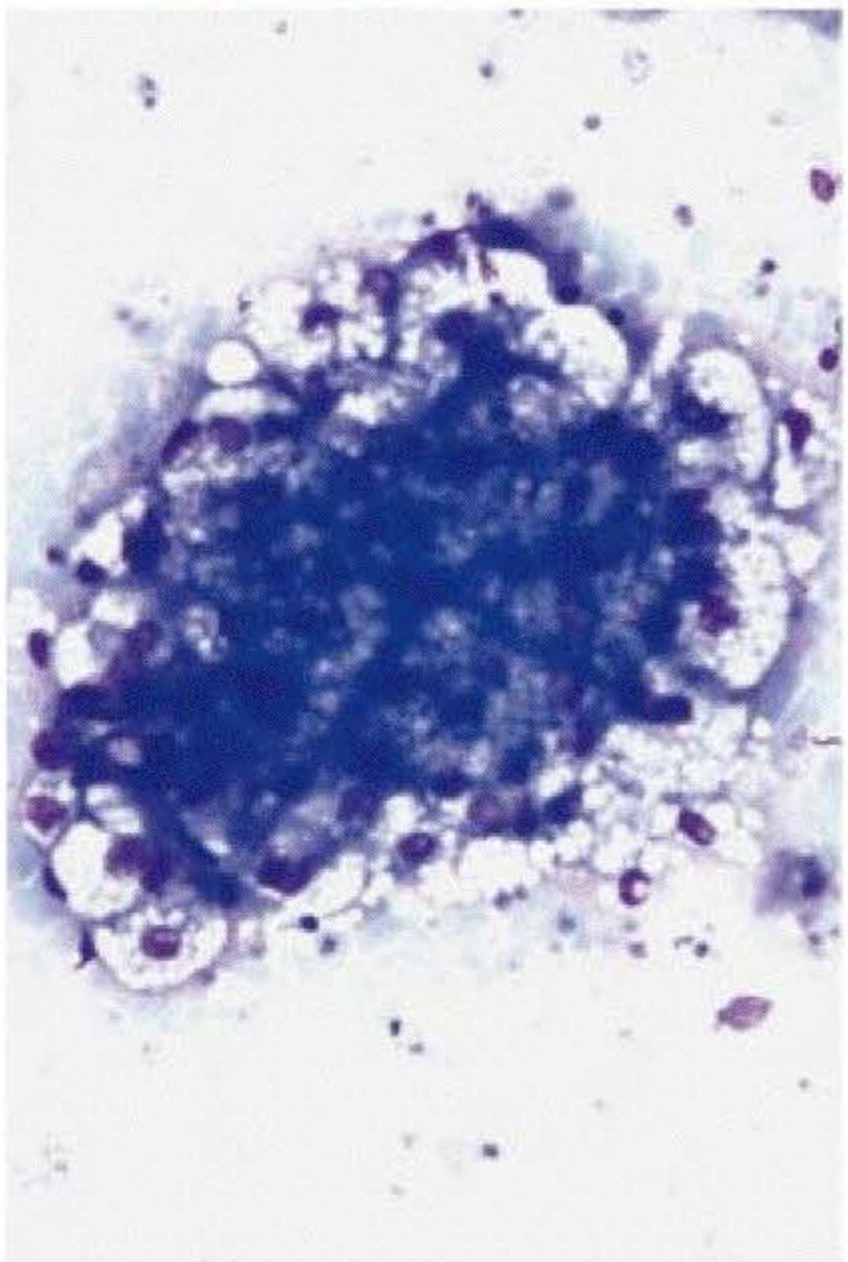

5.10

Fig. 5.8. Benign squamous cells and keratin debris in pleomorphic adenoma. MGG. E 64.
Fig. 5.9. Malignant squamous cells and keratin debris in high-grade mucoepidermoid carcinoma. MGG. E128.
Fig. 5.10. Sebaceous cells in Warthin's tumour. MGG. E128.

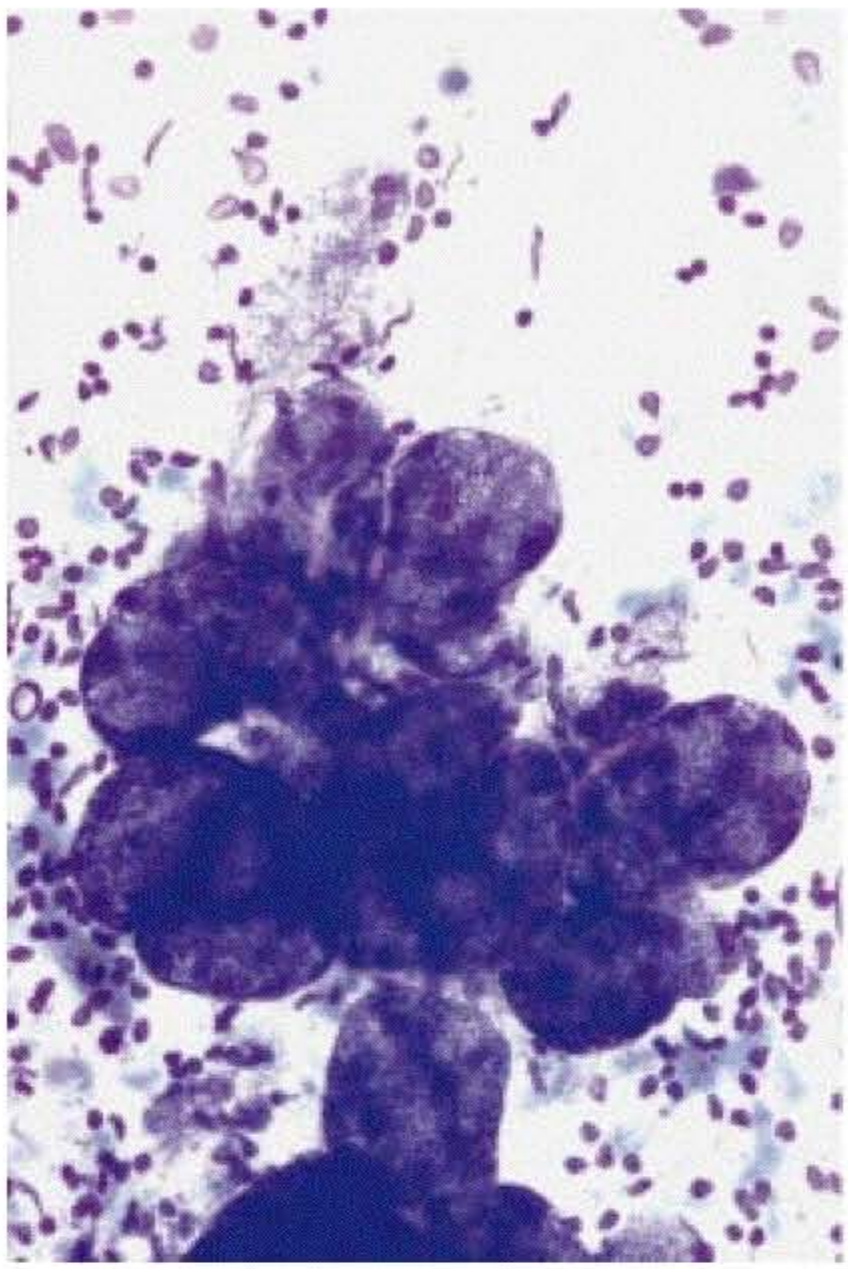

5.11

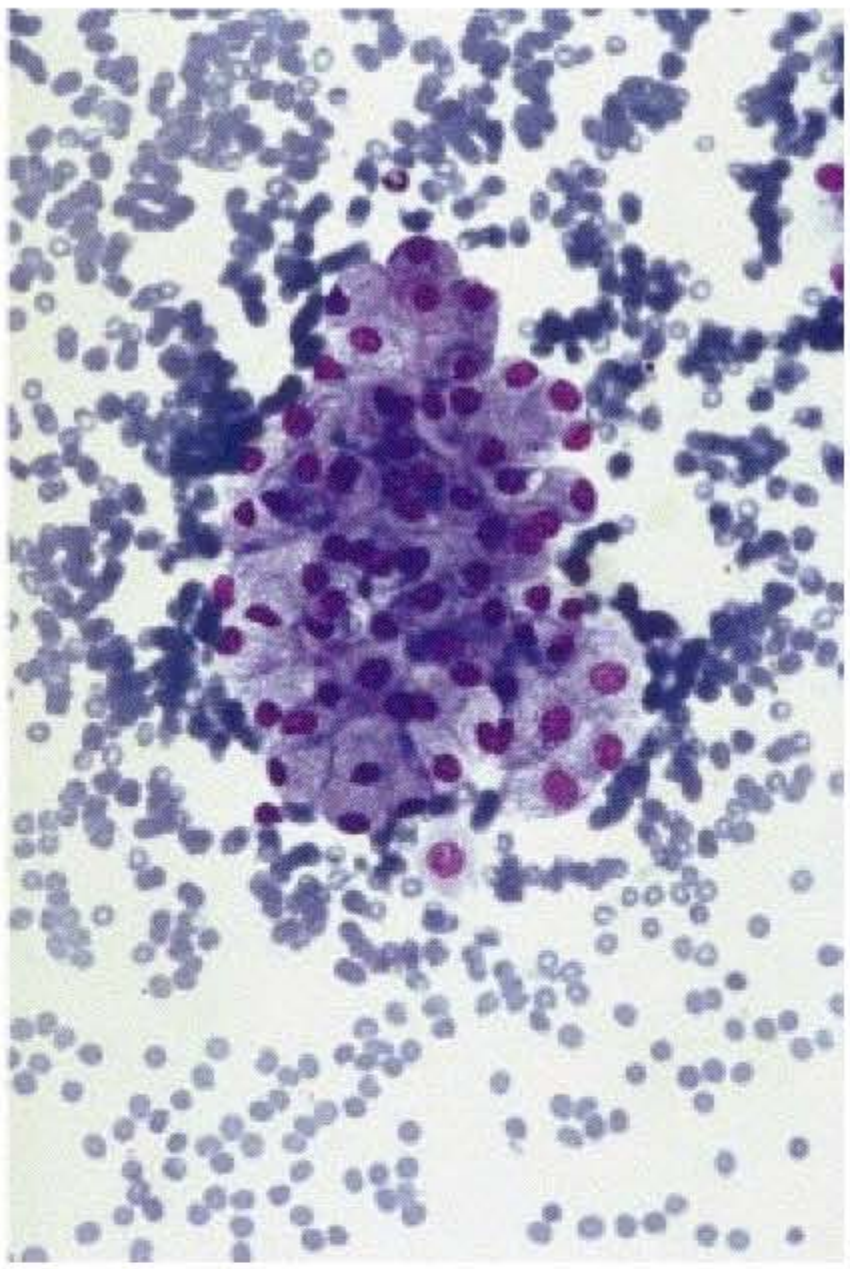

5.12

Fig. 5.11. Benign acinar cells in sialadenosis. MGG. ×128.
Fig. 5.12. Malignant acinar cells in acinic cell carcinoma. MGG. ×128.

5.1.1.4. Squamous Cells

Benign or malignant squamous cells are frequently seen in aspirates from squamous cell carcinoma, high-grade mucoepidermoid carcinoma, pleomorphic adenoma, Warthin's tumour, basal cell tumours, necrotizing sialometaplasia, and salivary cysts (fig. 5.8, 5.9) [196, 197]. Malignant squamous cells are commonly seen in secondary tumours of the salivary gland, mainly from the head and neck.

5.1.1.5. Sebaceous Cells

Sebaceous cells are common in salivary glands, specially in the parotid gland [239]. The presence of these elements in salivary gland is unclear. Sebaceous cells in salivary glands are now considered to be due to holocrine differentiation. Sebaceous cells may participate in primary tumours such as sebaceous adenoma, sebaceous carcinoma and parotid cysts (fig. 5.10) [7, 135, 182]. Sebaceous cells are not seen in cytological smears from normal salivary glands. Benign sebaceous cells may be occasionally seen in pleomorphic adenoma and Warthin's tumour.

5.1.1.6. Acinar Cells

Normal acinar cells are divided into serous and mucous types. Serous acini consist of epithelial cells with a basal nucleus, dense cytoplasm, and strongly PAS-positive zymogen granules. Mucous acini are larger than serous acini and have an irregular pattern. They contain acid sialomucins (positively stained with Alcian blue, or mucicarmine), and neutral sialomucins (PAS-positive) [280]. Benign and malignant acinar cells are easily recognized cytologically (fig. 5.11, 5.12), as they have the same appearance as in histological sections. In well-differentiated forms, they are large cells with small basal nuclei, arranged in alveolar structures. The cytoplasm is clear and vacuolized. In less differentiated forms, they have numerous intracytoplasmic vacuoles or reddish deposits [193].

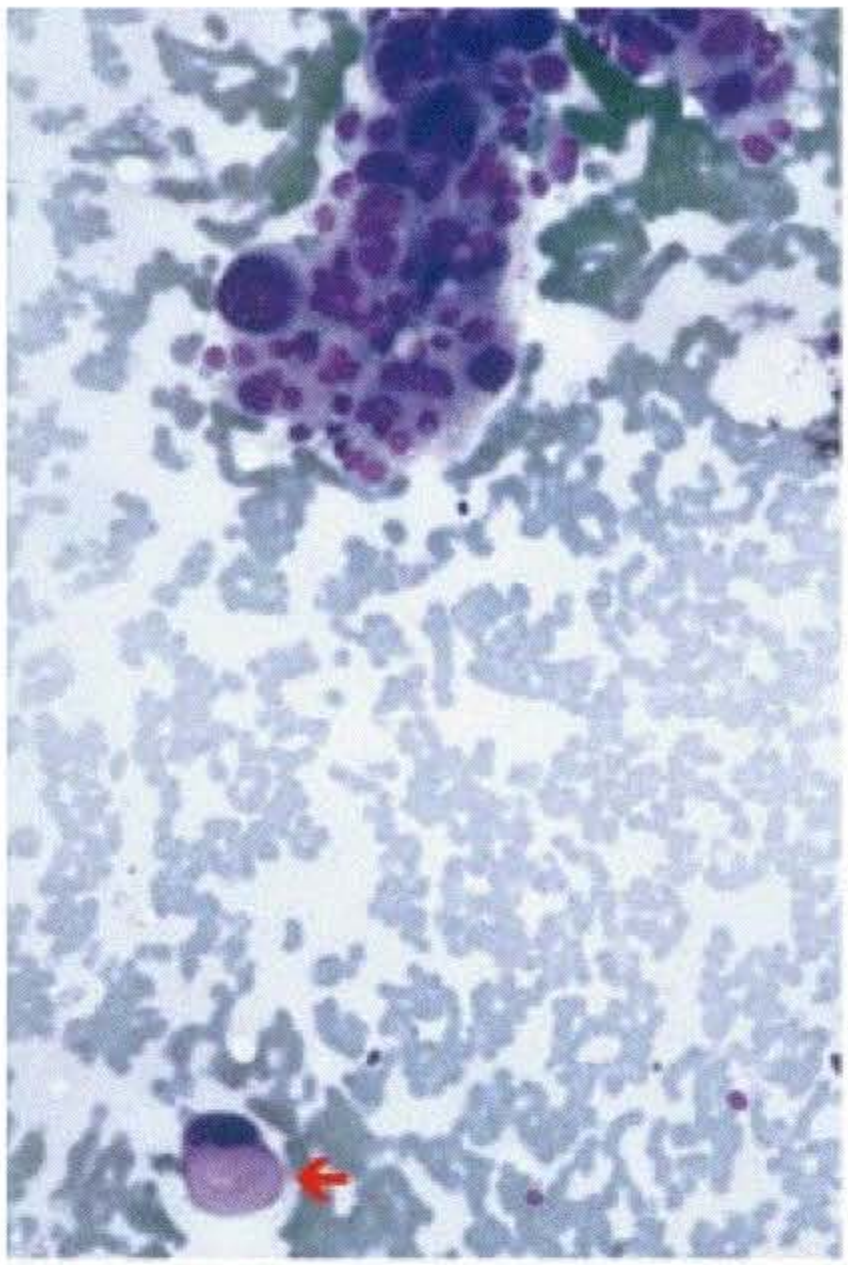

5.13

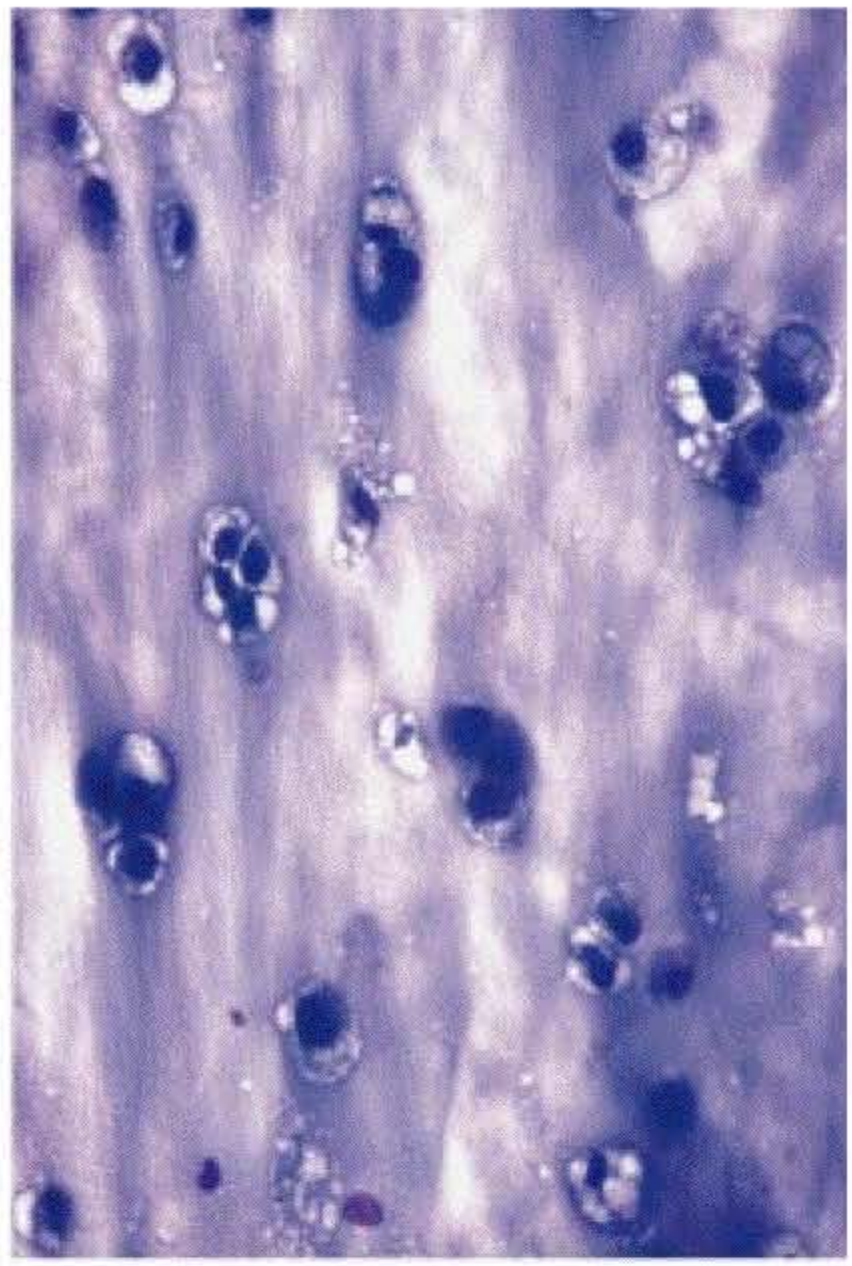

5.14

5.15

Fig. 5.13. Mucus-secreting (goblet) cell (arrow) in high-grade mucoepidermoid carcinoma. MGG. ×128.
Fig. 5.14. Histiocyte-like, mucus-secreting cells in low-grade mucoepidermoid carcinoma. MGG. ×128.
Fig. 5.15. Crystalloids (cholesterol?) in Warthin's tumour. MGG. ×128.

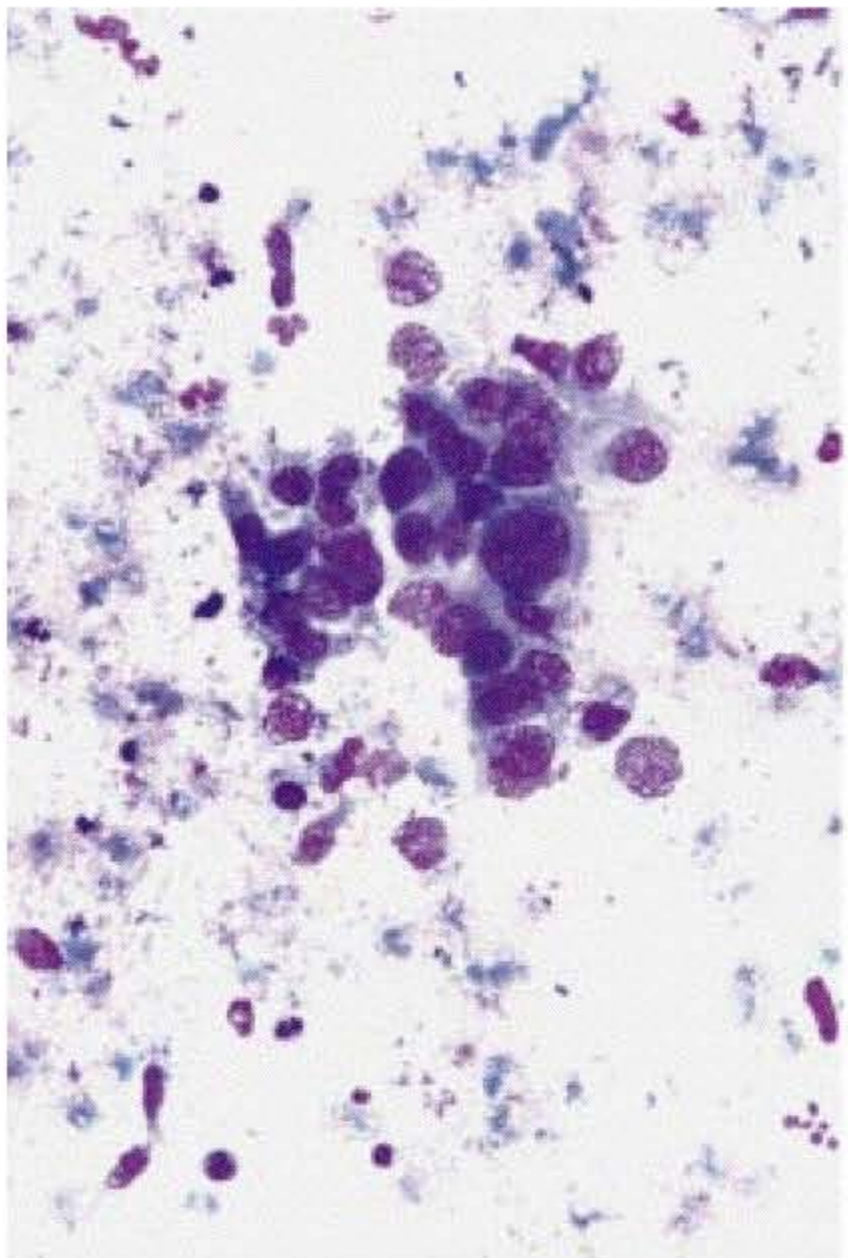

5.16

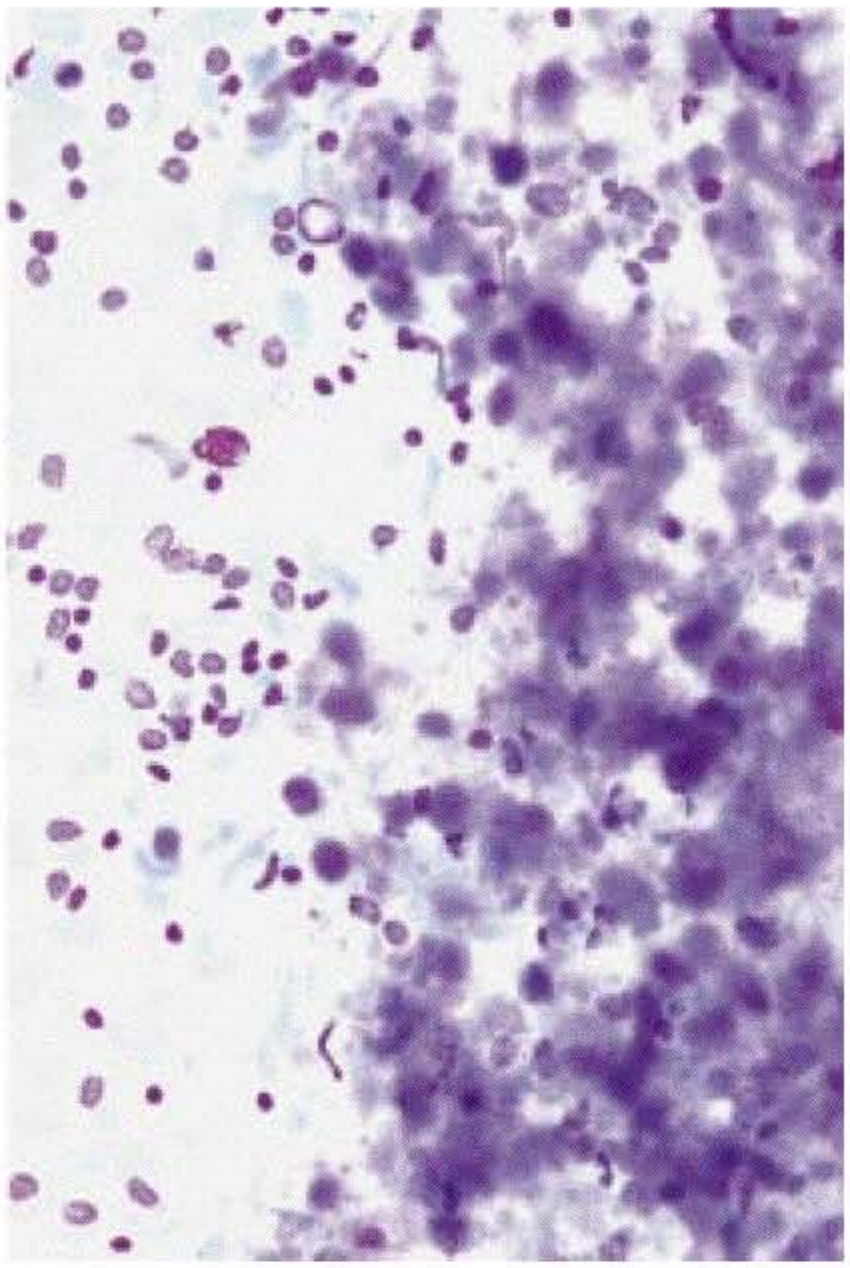

5.17

Fig. 5.16. Necrotic background in adenocarcinoma not otherwise specified (NOS). MGG. ×128.
Fig. 5.17. Pseudonecrosis in Warthin's tumour. MGG. ×128.

5.1.1.7. Mucus-Secreting Cells

Mucus-secreting cells are seen in metaplastic processes. Metaplasia may occur in chronic inflammation and salivary lithiases, pleomorphic adenoma, Warthin's tumour and in malignant tumours, such as mucoepidermoid carcinoma. Mucus-secreting cells have a pseudohistiocytic morphology in certain forms of low-grade mucoepidermoid carcinoma (fig. 5.13, 5.14) [196].

5.1.2. Stroma

Stromal morphology is of capital importance in the cytology of salivary gland tumours and can be more accurately analysed with MGG stain than Papanicolaou stain. Crystalloids, necrosis, connective tissue fragments and mucoid provide valuable information about cells, secretions and stroma.

5.1.2.1. Crystals

5.1.2.1.1. Tyrosine-Rich Crystalloids. Although tyrosine is a major component, the presence of arginine, tryptophan and sulfhydryl groups is frequently detected biochemically. Their relative frequency in pleomorphic adenomas ranges from 2 to 20% [43, 51, 162]. However, tyrosine-rich crystalloids are not pathognomonic for pleomorphic adenomas, as such aggregates have also been described in malignant salivary tumours including adenoid cystic carcinoma [138], carcinoma ex pleomorphic adenoma [328], and polymorphous low-grade adenocarcinoma [147, 284].

5.1.2.1.2. Other Crystals. Crystalloids may be formed by retained saliva products and then aggregate into calculi. Calcifications may therefore be observed in chronic inflammation and cystic lesions [325, 326]. Asteroid bodies and calcium oxalate crystalloids have been described in fine-needle aspirates in salivary sarcoidosis [269]. Crystals are commonly seen in Warthin's tumour (fig. 5.15).

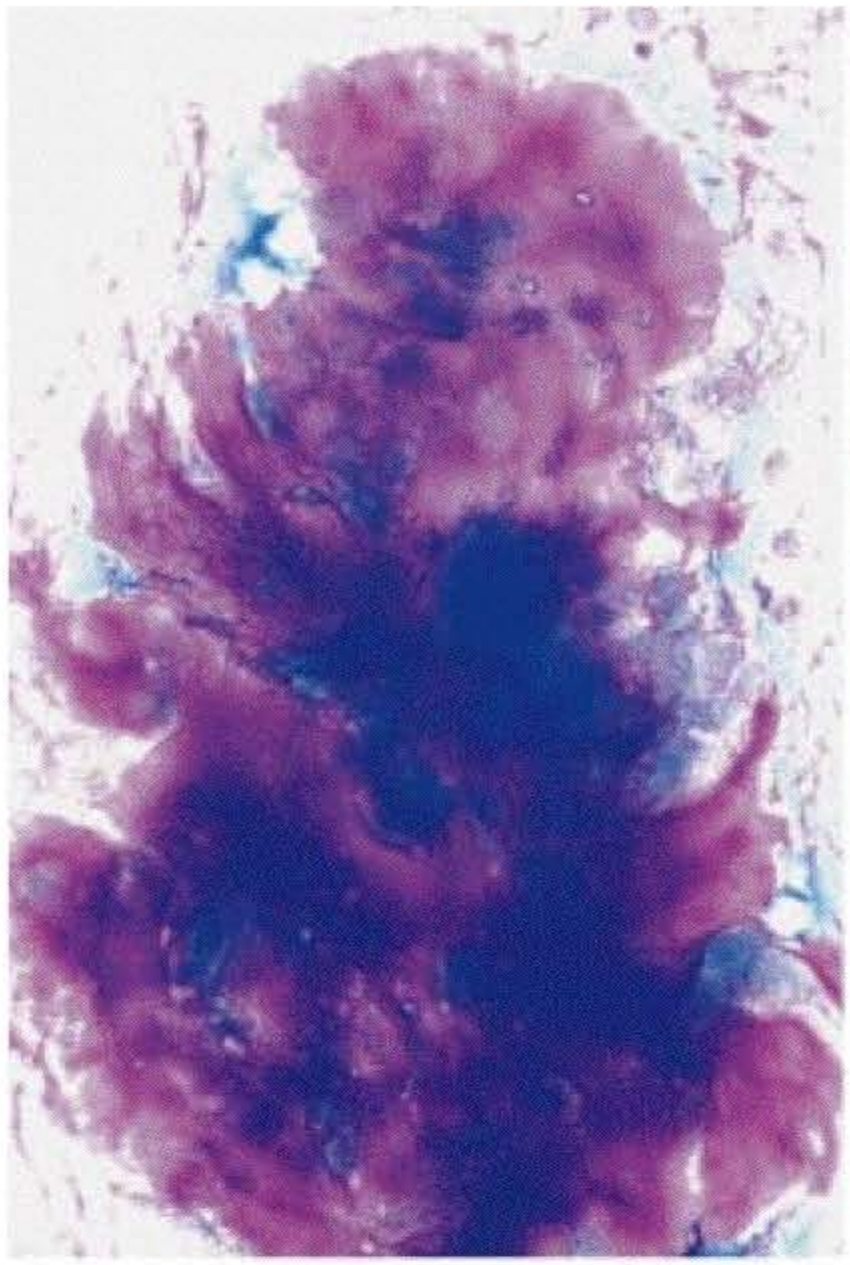

5.18

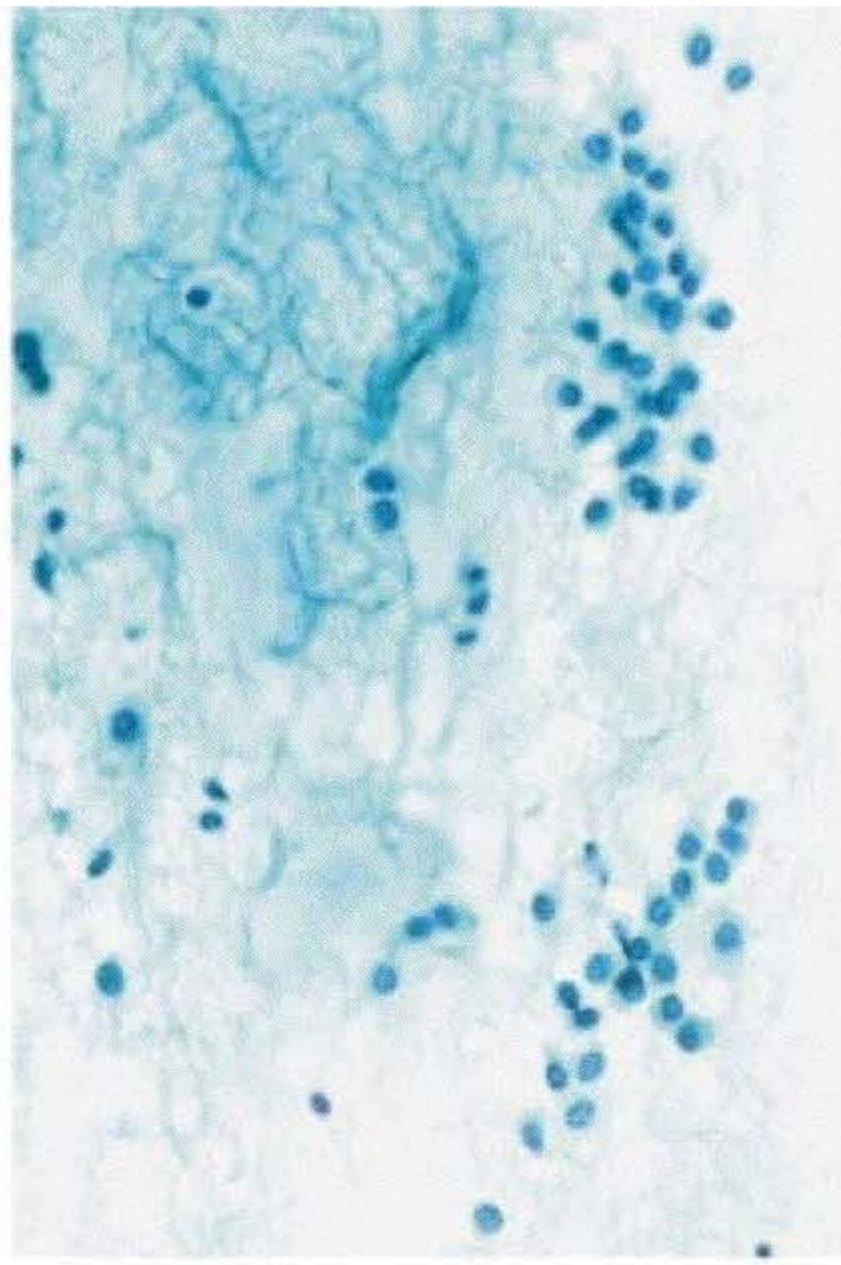

5.19

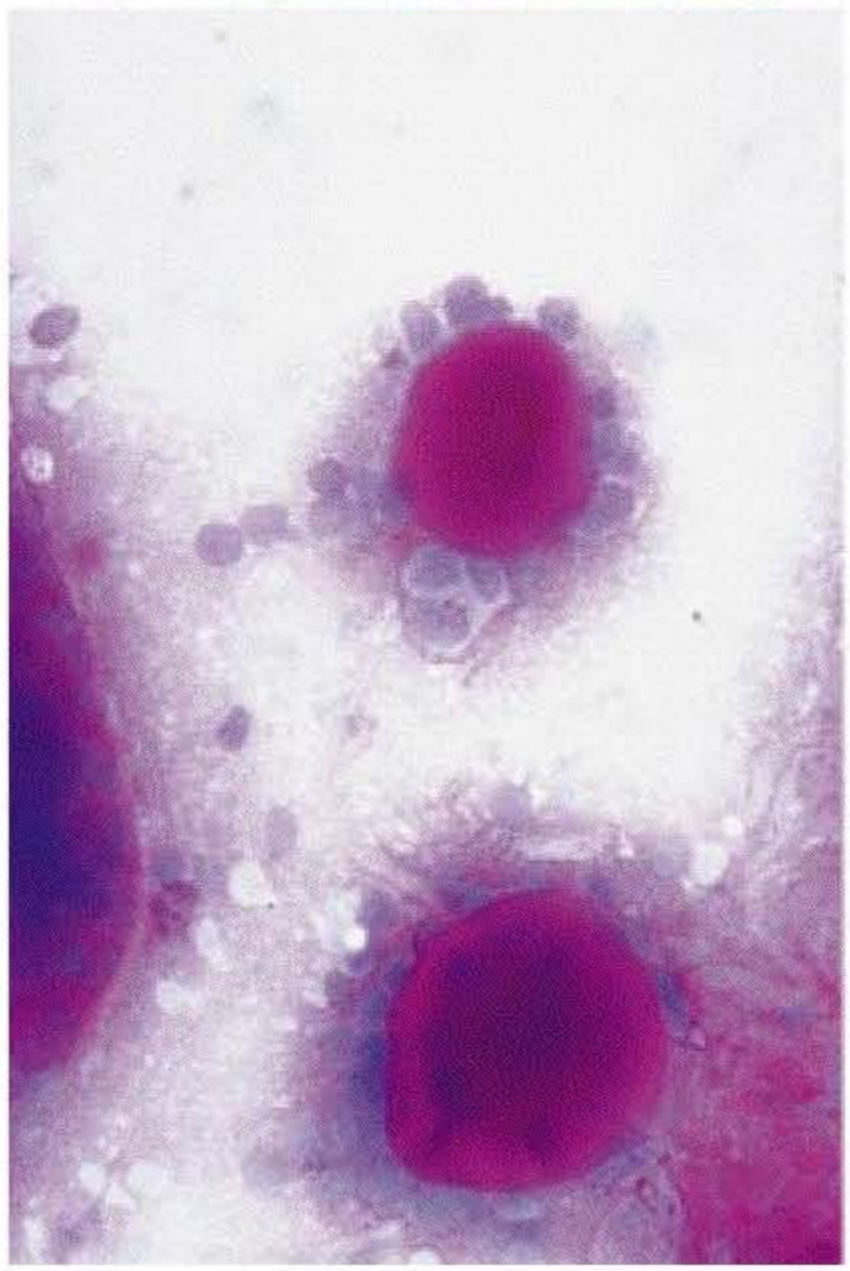

5.20

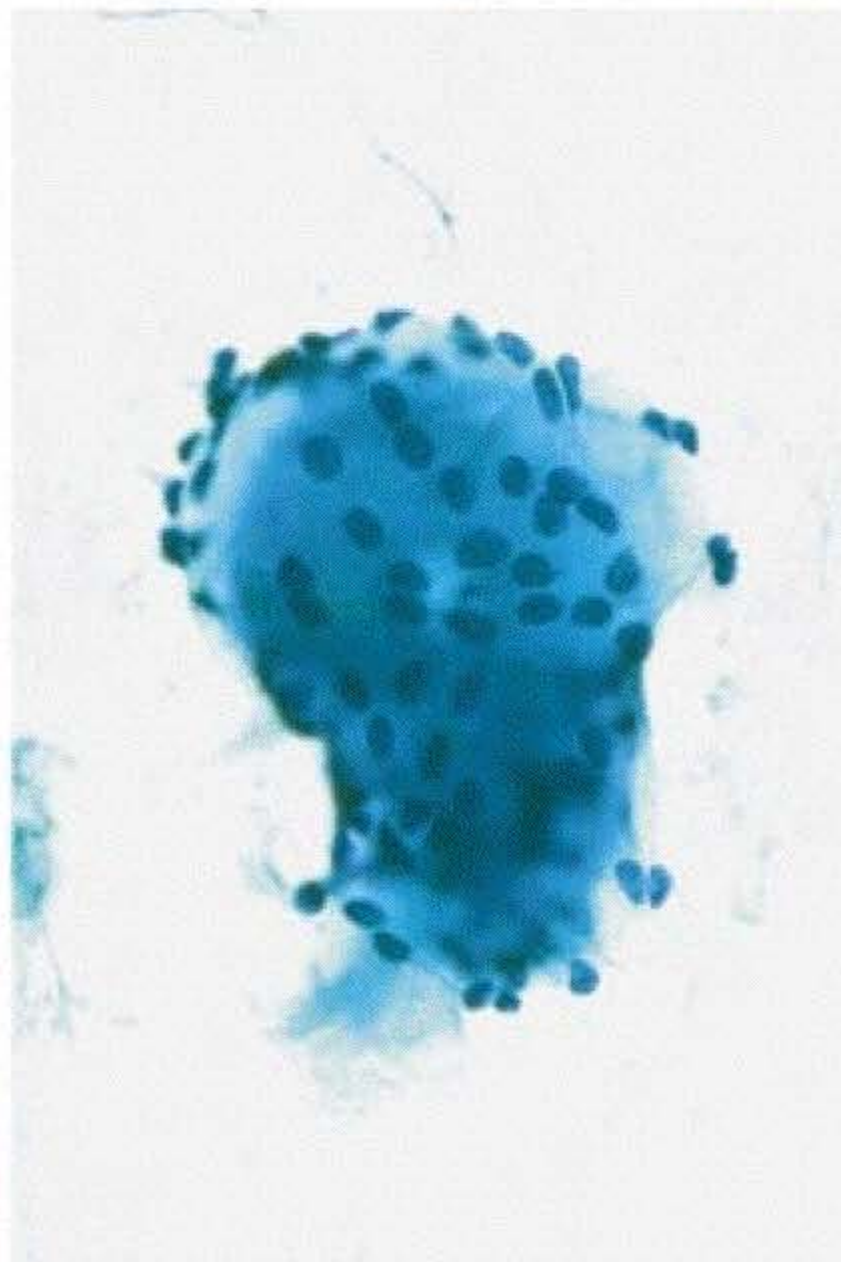

5.21

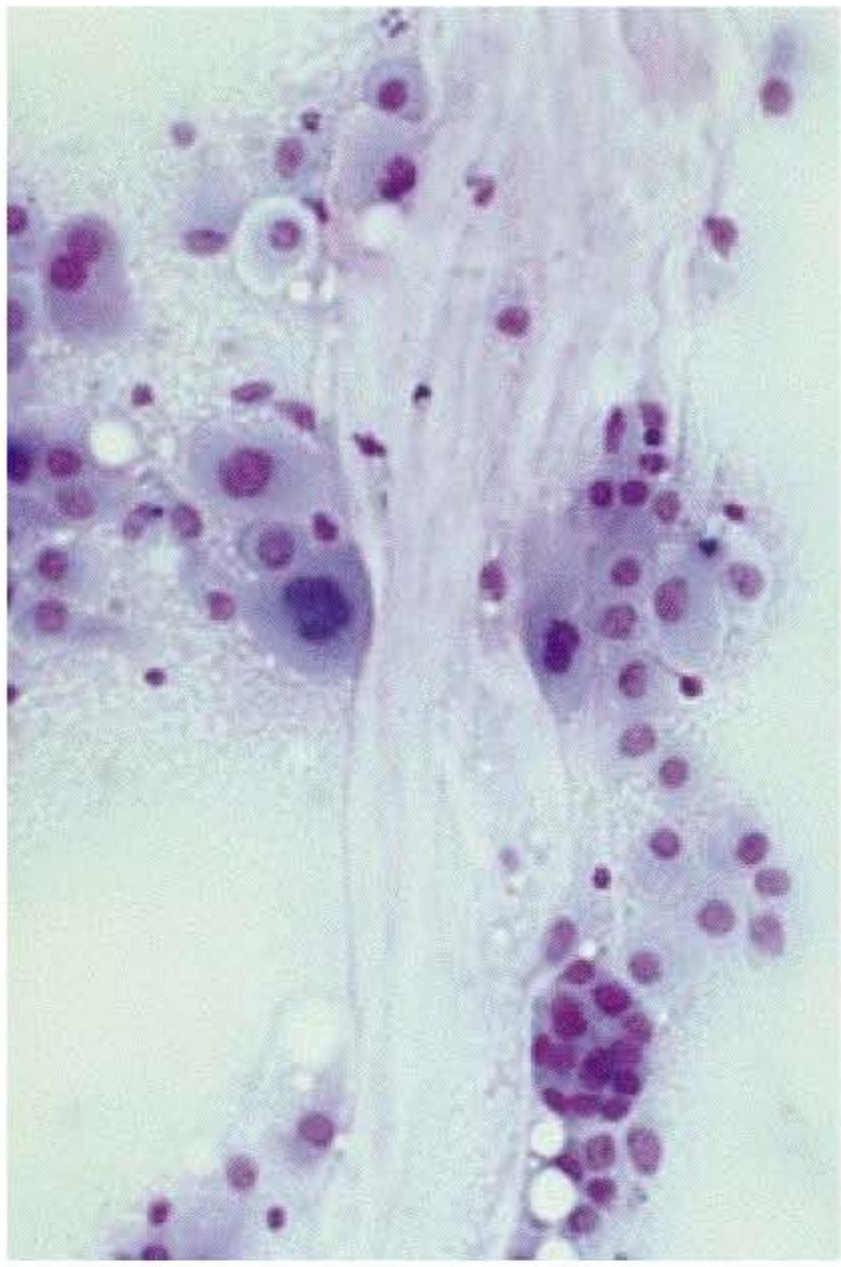

5.22

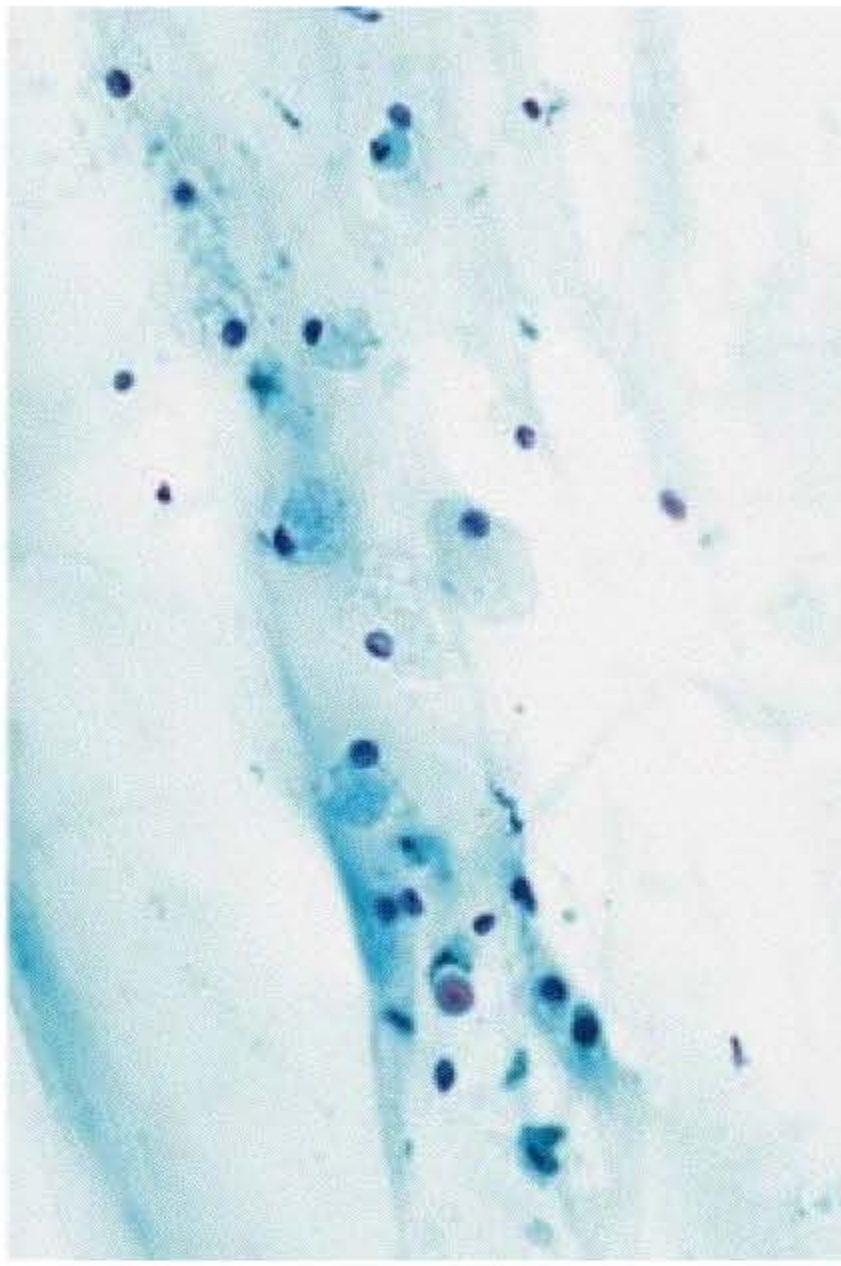

5.23

Fig. 5.22. Mucus in mucoepidermoid carcinoma ex pleomorphic adenoma. MGG. ×128.
Fig. 5.23. Mucus in mucoepidermoid carcinoma. Papanicolaou. ×128.

5.1.2.2. Necrosis and Pseudonecrosis

Necrosis is common in high-grade carcinomas, such as salivary duct carcinoma, mucoepidermoid carcinoma and primary squamous cell carcinoma (fig. 5.16). Pseudonecrosis is commonly seen in cysts and Warthin's tumour (fig. 5.17).

Fig. 5.18. Chondromyxoid connective tissue fragments in pleomorphic adenoma. MGG. ×128.
Fig. 5.19. Chondromyxoid connective tissue fragments in pleomorphic adenoma. Papanicolaou. ×128.
Fig. 5.20. Hyaline globules in adenoid cystic carcinoma. MGG. ×128.
Fig. 5.21. Hyaline globules in adenoid cystic carcinoma. Papanicolaou. ×128.

5.1.2.3. Connective Tissue Stromal Fragments

Poorly circumscribed, highly eosinophilic fragments are always seen in pleomorphic adenoma (fig. 5.18, 5.19), but also in variable proportions in polymorphous low-grade adenocarcinoma, epithelial-myoepithelial carcinoma, basal cell adenoma/adenocarcinoma and papillary adenocarcinoma. Round, hyaline globules are frequent in adenoid cystic carcinoma, polymorphous low-grade adenocarcinoma, epithelial-myoepithelial carcinoma and basal cell tumours (fig. 5.20, 5.21) [188, 194, 195, 200].

5.1.2.4. Mucoid and Mucin

Polychromatic, ranging from pink to dark blue, mucoid is commonly seen in low-grade mucoepidermoid carcinoma, rarely in high-grade mucoepidermoid carcinoma or pleomorphic adenoma (fig. 5.22, 5.23). Scant mucoid may be seen in Küttner's tumour.

Abundant mucinous secretion is predominant in mucinous adenocarcinoma.

5.2. Tumour Classification

Salivary gland tumours represent a challenging diagnosis [332]. At the present time, epithelial lesions include 9 types of adenomas (table 5.1) and 18 types of primary carcinomas, as described by the WHO classification [300]. Only one new entity (hyalinizing clear cell carcinoma: never reported in cytology) has been described in the literature since 1991.

The classification presented by the Armed Forces Institute of Pathology (AFIP) [90] (table 5.2) identifies the same entities, but classifies malignancies as high-, intermediate- and low-grade tumours. This classification into three prognostic grades is very useful in cytopathology. High- or intermediate-grade malignant cells are easily recognized by cytology in tumours such as salivary duct carcinoma, squamous cell carcinoma, small cell carcinoma, high-grade mucoepidermoid carcinoma or adenoid cystic carcinoma. In contrast, low-grade carcinomas, such as low-grade mucoepidermoid carcinoma or low-grade carcinoma arising in pleomorphic adenoma, are more difficult to identify on cytology.

5.3. Diagnostic Approach

The cytological diagnosis of salivary gland tumours consists of two different steps: (1) initial approach allowing classification of the tumour as neoplastic, benign or malignant, followed, in the case of malignancy, by classification as high- or low-grade (tables 5.1, 5.2), and (2) accurate tumour typing (table 5.2).

From a clinical and surgical point of view, the initial approach is sufficient for appropriate patient management. Accurate tumour typing is optional, but more satisfactory for the pathologist. Routine salivary cytopathology is able to classify tumours into several distinct cell types according to their predominant components, i.e. myoepithelial, oncocytic, basal, sebaceous, squamous and/or metaplastic cells. Certain groups may be subdivided into stroma-rich and stroma-poor. The differential diagnosis (table 5.3) must include all of the tumour entities within the same group, and less often members of different groups. The best illustration is pleomorphic adenoma which is a stroma-rich and myoepithelial richly cellular tumour. It must be differentiated from myoepithelioma, adenoid cystic carcinoma, epithelial-myoepithelial carcinoma and polymorphous low-grade adenocarcinoma, as well as from basaloid cell tumours such as basal cell adenoma and adenocarcinoma.

Table 5.1. Histological classification of benign salivary gland lesions according to WHO [300]

Adenomas	Tumour-like lesions
Pleomorphic adenoma	Sialadenosis
Myoepithelioma	Oncocytosis
Basal cell adenoma	Necrotizing sialometaplasia
Warthin's tumour	Benign lymphoepithelial lesion
Oncocytoma	Salivary gland cysts
Canalicular adenoma	Küttner's tumour
Sebaceous adenoma	Cystic lymphoid hyperplasia in AIDS
Ductal papilloma	Reactive processes
Inverted ductal papilloma	
Intraductal papilloma	
Sialadenoma papilliferum	
Cystadenoma	
Papillary cystadenoma	
Mucinous cystadenoma	

Table 5.2. Histological classification of salivary gland malignancies according to prognostic grade [90]

High- and intermediate-grade	Low-grade
Mucoepidermoid carcinoma	
Adenocarcinoma NOS	
Carcinoma ex pleomorphic adenoma	
Lymphoma	
Adenoid cystic carcinoma	Polymorphous low-grade adenocarcinoma
Carcinosarcoma	Metastasizing pleomorphic adenoma
Squamous cell carcinoma	Basal cell adenocarcinoma
Undifferentiated carcinoma	Acinic cell carcinoma
Salivary duct carcinoma	
Myoepithelial carcinoma	
Epithelial-myoepithelial carcinoma	
(Papillary) cystadenocarcinoma	
Sebaceous carcinoma	
Mucinous carcinoma	
Oncocytic carcinoma	
Secondary tumours	

Table 5.3. Main cytological differential diagnoses of salivary gland tumours

Group	Difficult differential diagnosis	Essential differential diagnosis
Myoepithelial, stroma-rich		
Pleomorphic adenoma	Should be accurately typed	Adenoid cystic carcinoma
Polymorphous low-grade adenocarcinoma	Adenoid cystic carcinoma	Pleomorphic adenoma
Adenoid cystic carcinoma	High-grade carcinoma	Pleomorphic adenoma
Epimyoepithelial carcinoma	Adenoid cystic carcinoma	Pleomorphic adenoma
Myoepithelial, stroma-poor		
Myoepithelioma	Pleomorphic adenoma	
Malignant myoepithelioma	High-grade carcinoma	Pleomorphic adenoma
Oncocytic, stroma-rich		
Warthin's tumour	Oncocytoma, cysts	Mucoepidermoid carcinoma
Oncocytic, stroma-poor		
Oncocytoma	Warthin's tumour	Acinic cell carcinoma
Oncocytic carcinoma	High-grade carcinoma	
Basaloid		
Basaloid adenomas		Adenoid cystic carcinoma
Basal cell adenocarcinoma	Adenoid cystic carcinoma	Pleomorphic adenoma
Sebaceous		
Sebaceous adenoma		
Sebaceous carcinoma	High-grade carcinoma	
Cystic (clear)		
Papillary adenomas	Cysts, Warthin's tumour	Squamous cell carcinoma
Cystic (mucoid, necrotic)		
Warthin's tumour	Cysts	Mucoepidermoid carcinoma
Mucoepidermoid carcinoma	Squamous cell carcinoma	Warthin's tumour
Necrotizing sialometaplasia	Warthin's tumour	Squamous cell carcinoma
Lymphoepithelial lesion	Cysts, lymphadenitis	High-grade carcinoma
Küttner's tumour	Inflammation	Mucoepidermoid carcinoma
Squamous		
Mucoepidermoid carcinoma	Squamous cell carcinoma	Warthin's tumour
Squamous cell carcinoma	Mucoepidermoid carcinoma	Cysts, Warthin's tumour
Küttner's tumour	Inflammation	Mucoepidermoid carcinoma
Acinar		
Acinic cell carcinoma	Low-grade carcinoma	Oncocytoma
Sialometaplasia	Missed target	Acinic cell carcinoma
High-grade NOS		
Salivary duct carcinoma	High-grade carcinoma	Metastasis
Carcinoma ex pleomorphic adenoma	Carcinoma NOS	Pleomorphic adenoma
Poorly differentiated		
Small cell carcinoma	High-grade carcinoma	Lymphoma
Large cell carcinoma	High-grade carcinoma	Lymphoma
Lymphoepithelial carcinoma	High-grade carcinoma	Lymphoma
Lymphocytic		
Lymphoma, low-grade	Should be accurately typed	Inflammation
Lymphoma, high-grade	Should be accurately typed	High-grade carcinoma

Chapter 6

Adenomas

Salivary adenomas comprise 9 histological types and 5 subtypes [300]: pleomorphic adenoma, myoepithelioma (myoepithelial adenoma), basal cell adenoma, Warthin's tumour (adenolymphoma), oncocytoma (oncocytic adenoma), canalicular adenoma, sebaceous adenoma, ductal papilloma (inverted ductal papilloma, intraductal papilloma and sialadenoma papilliferum) and cystadenoma (papillary cystadenoma and mucinous cystadenoma). They represent approximately 85% of all parotid gland tumours, 63% of submandibular gland tumours, 14% of sublingual gland tumours and 54% of minor salivary gland tumours.

To facilitate tumour typing and differential diagnosis, we have classified adenomas according to their predominant myoepithelial, oncocytic, basaloid, sebaceous and papillary-cystic cytological components.

6.1. Adenomas with Prominent Myoepithelial Cells

6.1.1. Pleomorphic Adenoma

6.1.1.1. General

Pleomorphic adenoma is the commonest salivary gland tumour. It accounts for 60–70% of all parotid gland, submandibular gland or accessory gland tumours, while sublingual sites are extremely rare [90]. It is a slowly growing, painless and movable mass, observed in patients with an average age of 40–45 years and a female predominance [90]. In advanced cases, fixed and ulcerated pleomorphic adenomas may clinically simulate malignancy. Pleomorphic adenomas may occur in young children, but with an incidence of less than 1%.

A very rare variant, called metastasizing pleomorphic adenoma, is histologically benign, but inexplicably presents with distant metastases [90, 186].

6.1.1.2. Histopathology

Pleomorphic adenomas are composed of varying proportions of myoepithelial and epithelial cells and stroma. Myoepithelial cells take on a variety of forms: spindle-shaped, clear, plasmacytoid. Epithelial intercalated-type cells form ducts, cribriform sheets, cords, or nests. Squamous cell metaplasia, especially lining cystic formations, may be seen in about 20% of tumours. Similarly, goblet cells, oncocytes or sebaceous cells may also be present. Stroma may be oedematous-mucoid, hyalinized, chondroid, osseous or fibrous. In some rare cases, extensive lipometaplasia may be seen [89].

The relative proportion of cellular and stromal components allows a subdivision of pleomorphic adenomas into chondromyxoid (60–70% of cases), cellular (20–30% of cases), myoepithelial and metaplastic subtypes [113].

6.1.1.3. Cytopathology

Two components are required to reliably make a diagnosis of pleomorphic adenoma: myoepithelial cells and chondromyxoid stroma [169, 198, 263, 336]:

- myoepithelial cells, either spindle-shaped or plasmacytoid, exhibit characteristic well-defined and abundant cytoplasm. Nuclei are oval to round with delicate chromatin. Rare cases show mild to severe anisokaryosis, which is not suggestive of malignant transformation;
- chondromyxoid stroma, fibrillary structures, collagen and hyalinization appear pale with Papanicolaou stain and are better appreciated as eosinophilic-magenta or purple elements on MGG stain. The presence of epithelial cells has no diagnostic value except in metaplastic subtypes. Rare findings include a cystic appearance of smears and scant mucus.

Fig. 6.1. Typical pleomorphic adenoma (stroma-rich). Note the characteristic chondromyxoid stroma, strongly eosinophilic on MGG stain, and the poorly-stained myoepithelial cells. MGG. ×128.

Fig. 6.2. Typical pleomorphic adenoma (stroma-rich). The chondromyxoid stroma has a fibrous appearance on Papanicolaou stain. ×64.

Fig. 6.3. Typical pleomorphic adenoma. Plasmacytoid myoepithelial cells with well-delimited cytoplasm. These cells are characteristic of pleomorphic adenoma and myoepithelioma. MGG. ×128.

Fig. 6.4. Typical pleomorphic adenoma. Plasmacytoid myoepithelial cells. Papanicolaou. ×128.

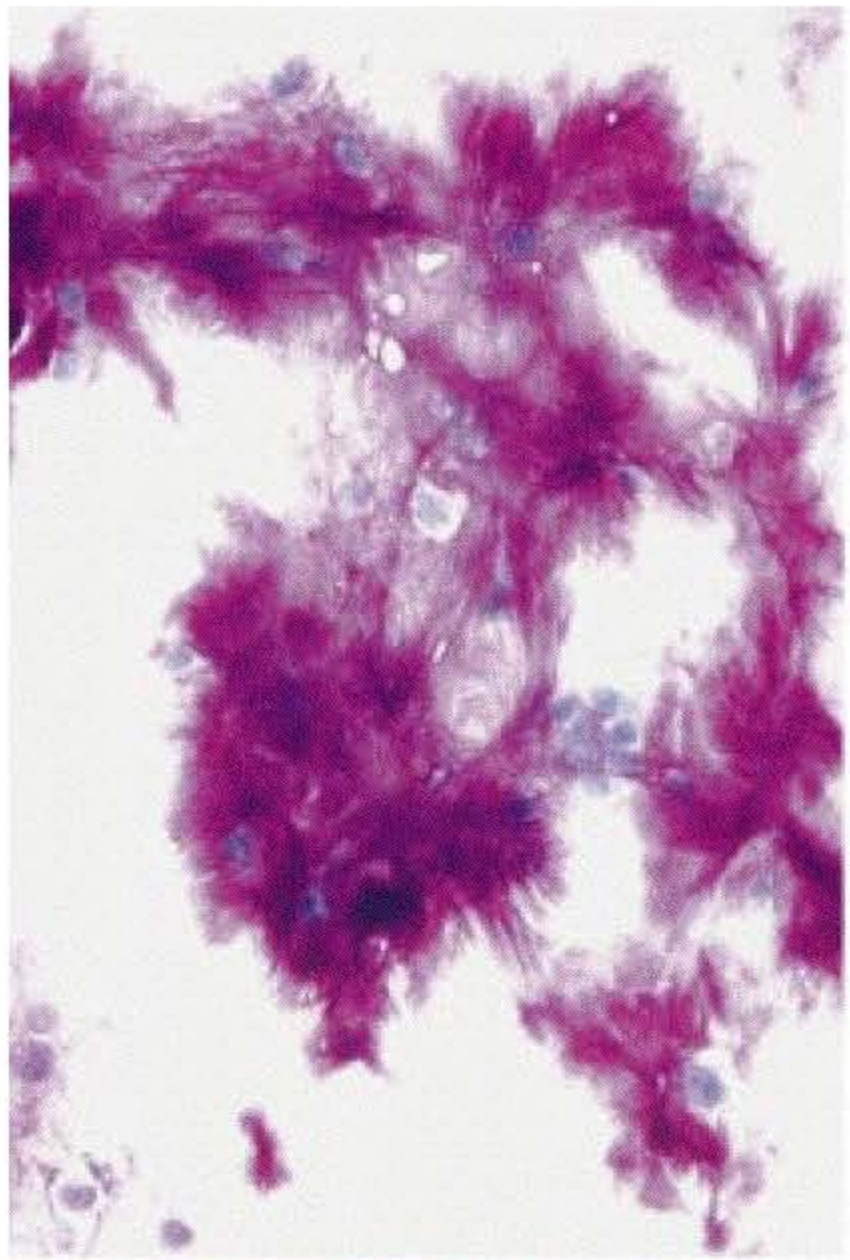

6.1

6.2

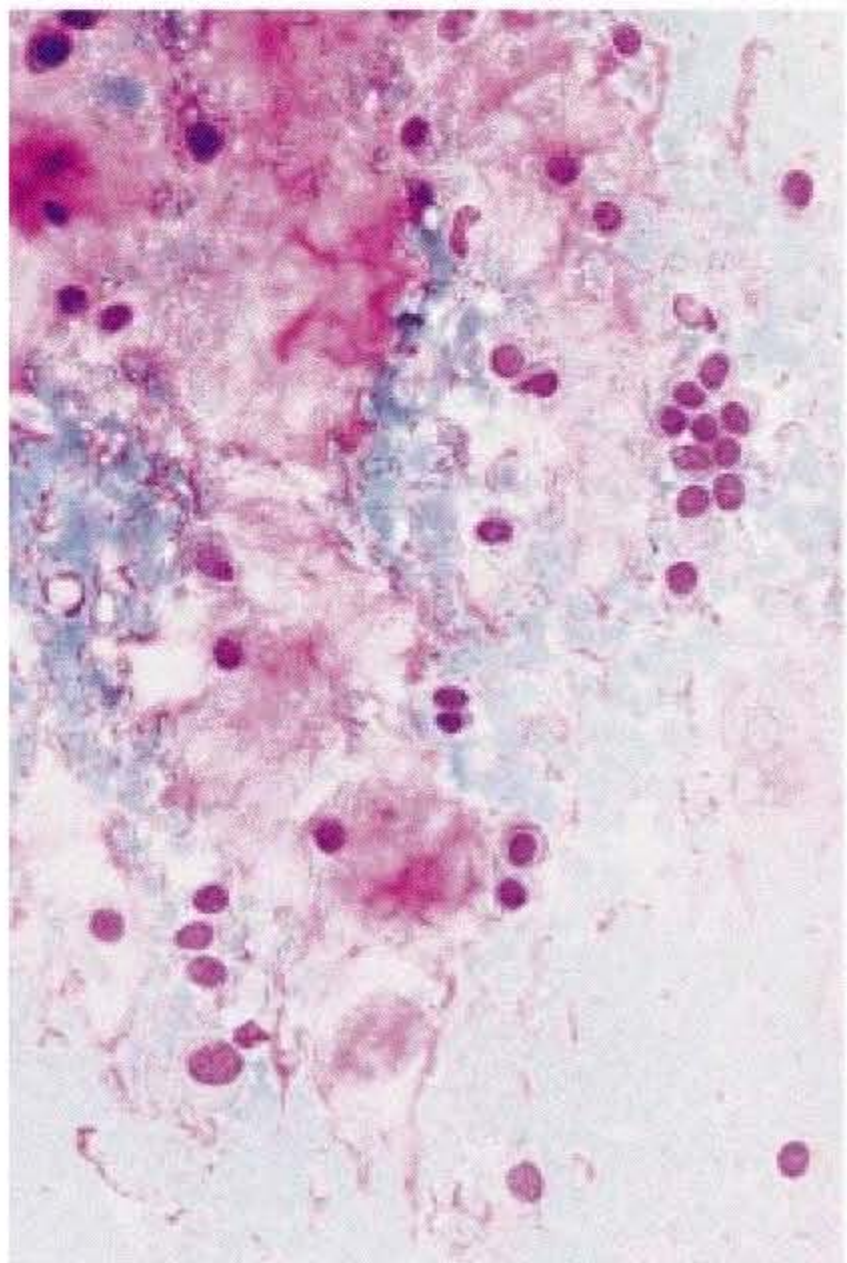

6.3

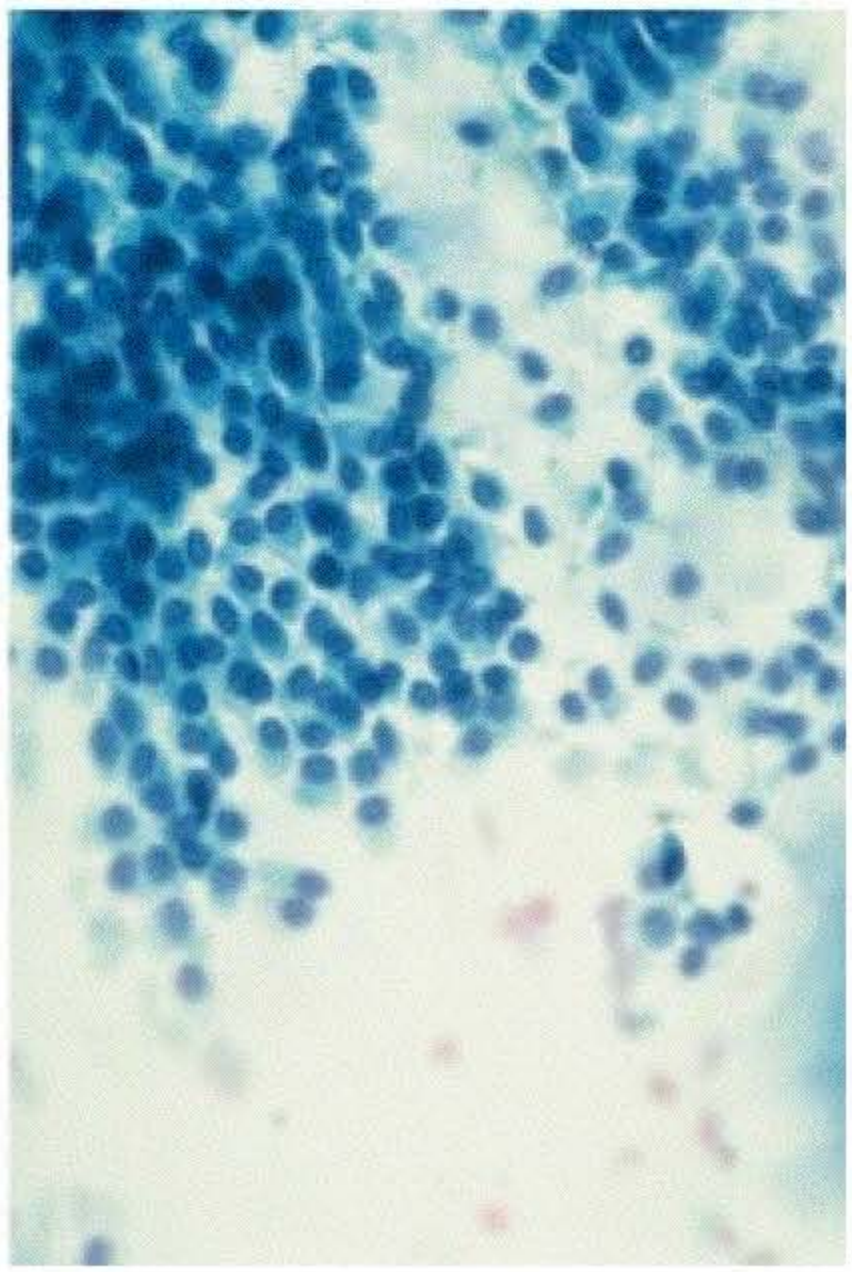

6.4

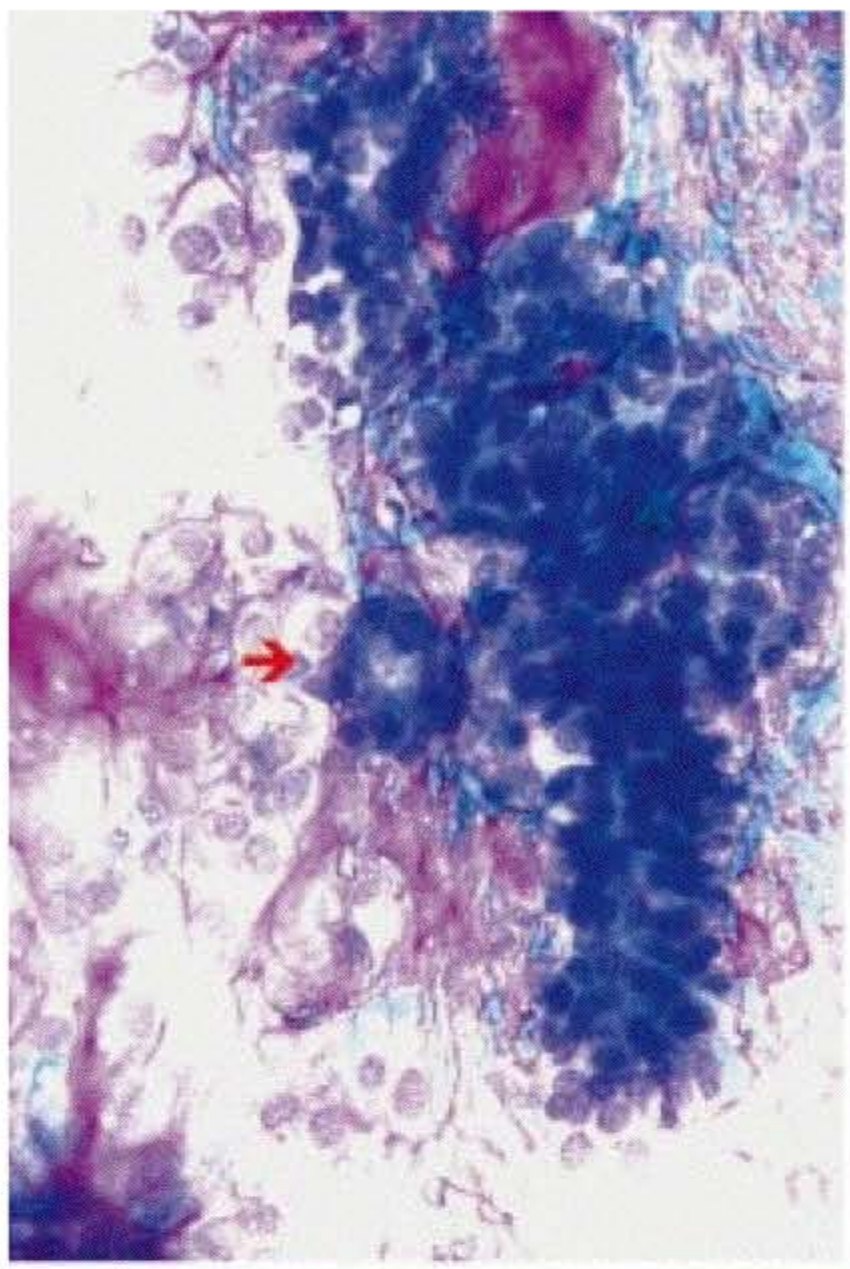

6.5

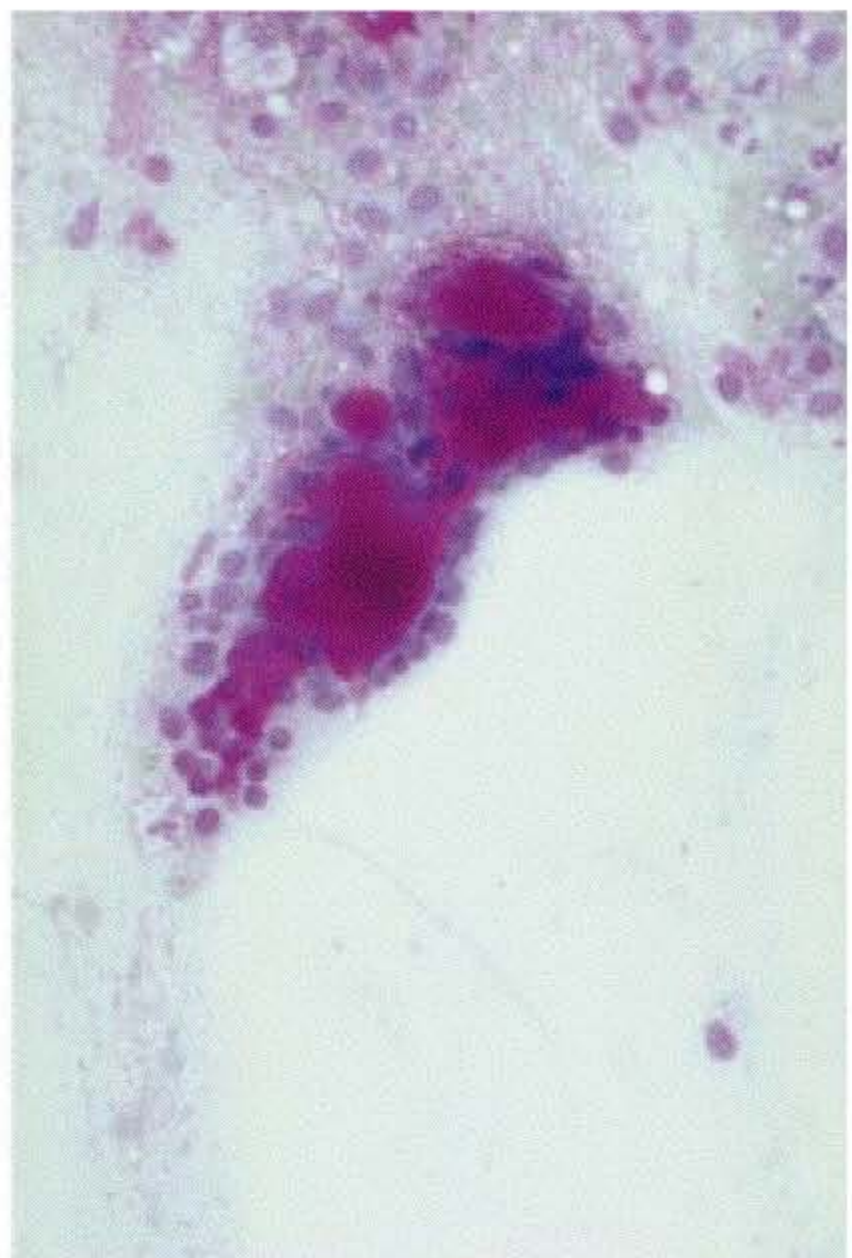

6.6

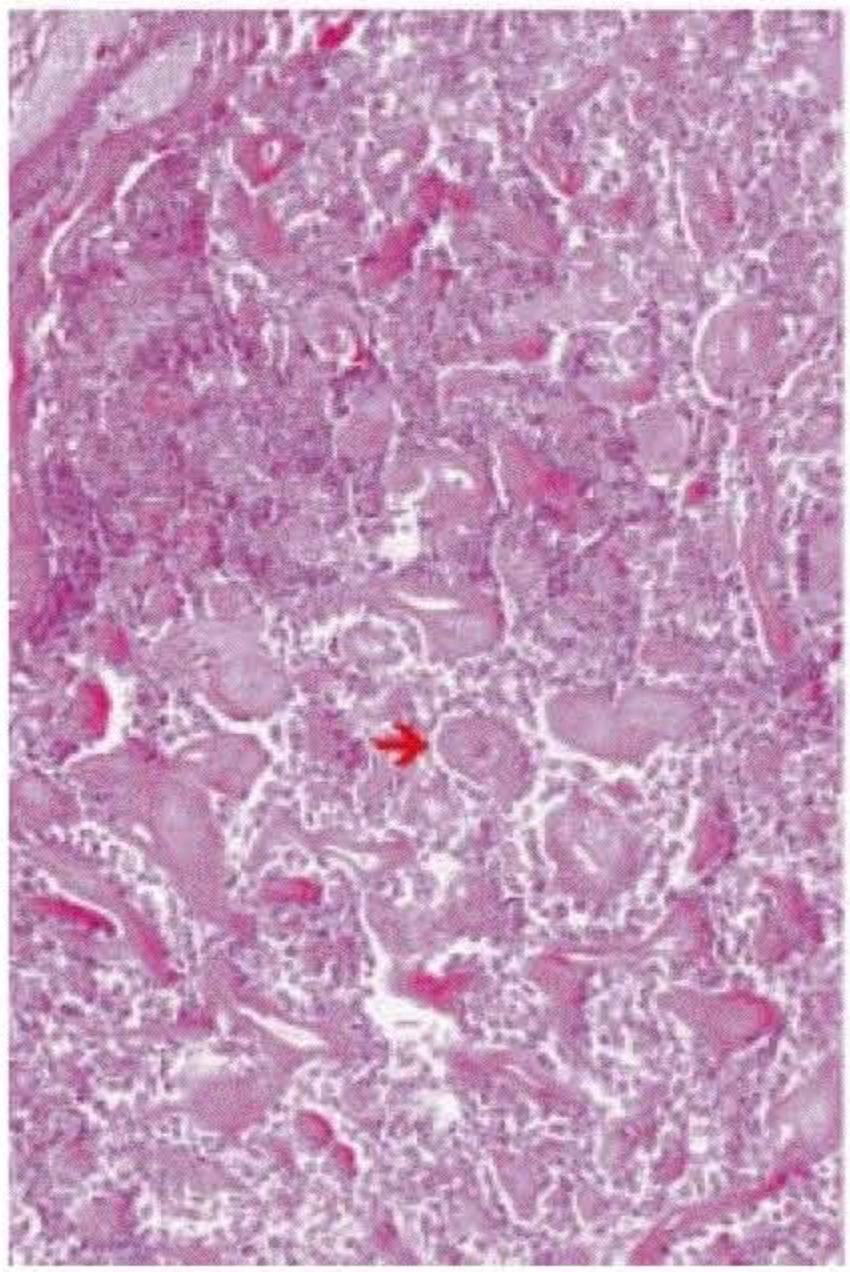

6.7

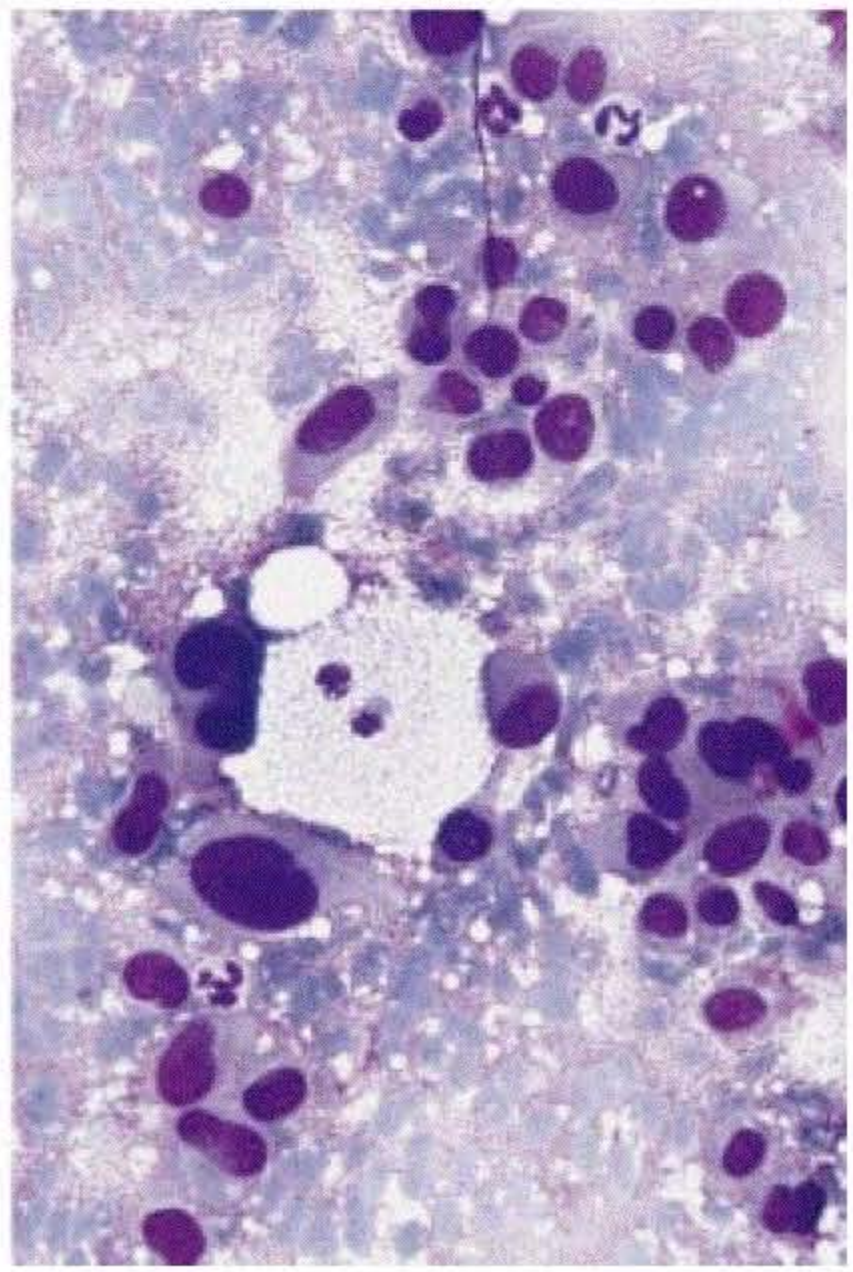

6.8

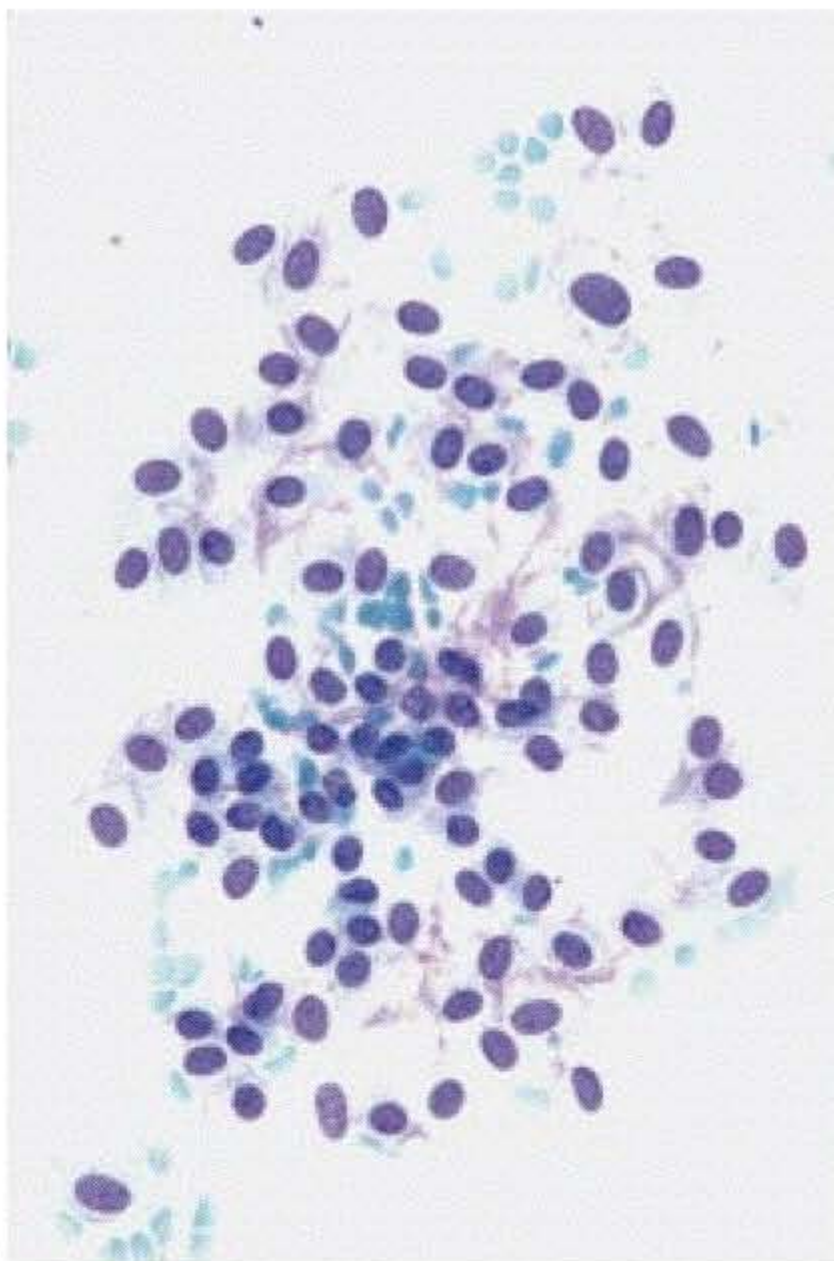

6.9

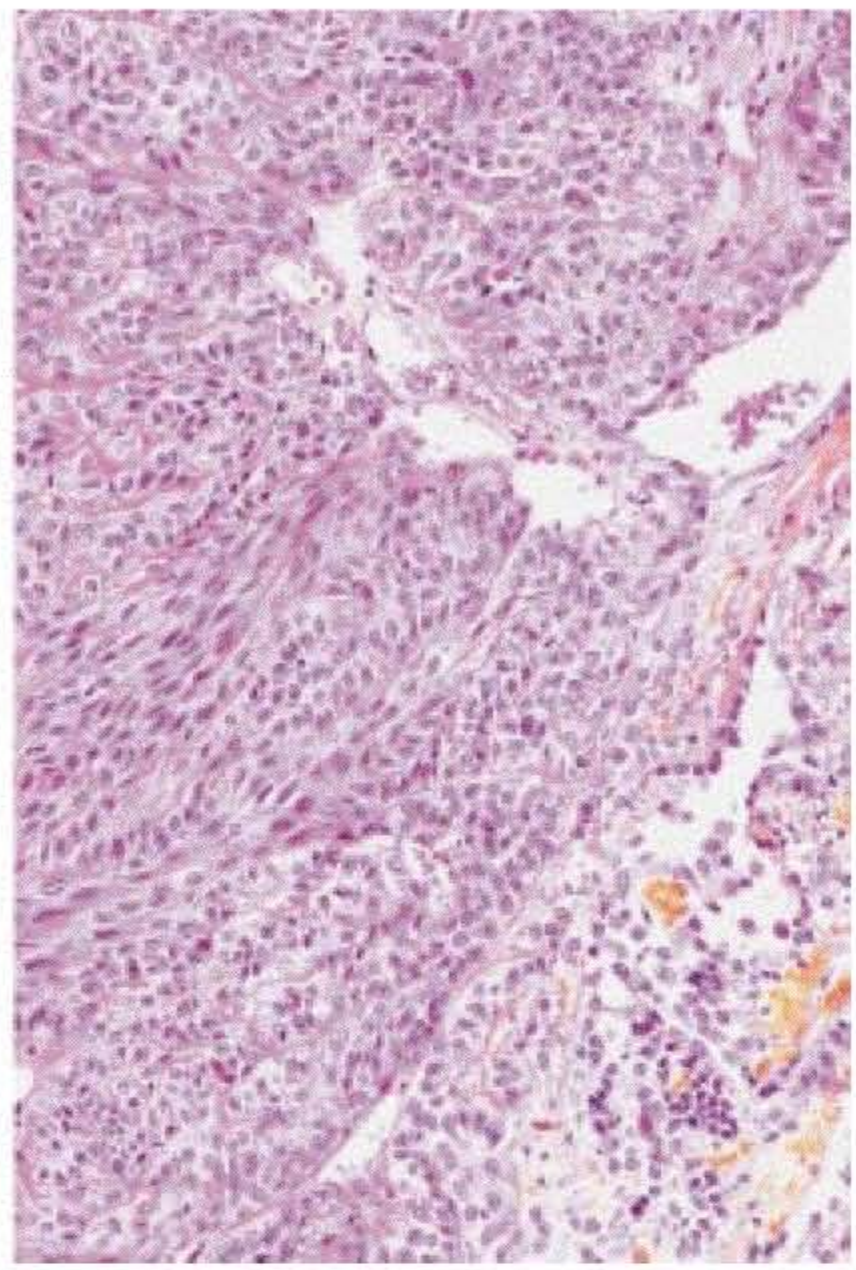

6.10

Fig. 6.9. Myoepithelial pleomorphic adenoma. Uniform proliferation of spindle-shaped and plasmacytoid myoepithelial cells. Chondromyxoid stroma is absent. This pattern is impossible to differentiate from myoepithelioma (see fig. 6.18). MGG. ×128.

Fig. 6.10. Pleomorphic adenoma. Histological sections corresponding to figure 6.9. HES. ×32.

6.1.1.3.1. Chondromyxoid Pleomorphic Adenoma. The cytological appearance is characteristic. Aspirates are stroma-rich and paucicellular. The smears consist of dense, strongly eosinophilic (MGG stain), acellular or fibrillary material with occasional myoepithelial cells and rare epithelial cells (fig. 6.1, 6.2). Cells within the stroma may be poorly stained and may resemble ghost cells.

Fig. 6.5. Cellular pleomorphic adenoma composed of chondromyxoid stroma, isolated or clustered myoepithelial cells with spindle-shaped or plasmacytoid morphology, and some glandular structures (arrow). MGG. ×128.

Fig. 6.6. Cellular pleomorphic adenoma. Stromal cores resembling hyaline globules surrounded by cohesive cells. This rare pattern of cellular pleomorphic adenoma may suggest adenoid cystic, epithelial-myoepithelial, polymorphous low-grade and basal cell adenocarcinomas. MGG. ×128.

Fig. 6.7. Cellular pleomorphic adenoma. Histological section corresponding to figure 6.6. A myoepithelial island with hyalinized stroma can be seen in the centre (arrow), mimicking adenoid cystic carcinoma. HES. ×32.

Fig. 6.8. Pleomorphic adenoma. Mild to severe but focal atypia of plasmacytoid myoepithelial cells. This pattern should not lead to a diagnosis of carcinoma ex pleomorphic adenoma. MGG. ×128.

6.1.1.3.2. Cellular Pleomorphic Adenoma. Cytological smears are richly cellular and stroma-poor with numerous myoepithelial and rare epithelial cells, isolated or in pseudopapillary formations with a central band of fibrous tissue (fig. 6.3–6.7). Nuclear pleomorphism (atypia) (fig. 6.8) and intranuclear inclusions may be observed in myoepithelial cells. Stroma is scant and may form globules mimicking other types of salivary malignancies. Naked nuclei are rare and limited to some cases.

6.1.1.3.3. Myoepithelial Pleomorphic Adenoma. The myoepithelial variant is a very rare setting for pleomorphic adenoma. Smears are composed of myoepithelial cells with fibrous stroma, but when stroma is absent, the differential diagnosis with myoepithelioma is impossible (fig. 6.9, 6.10). Epithelial cells are occasionally found.

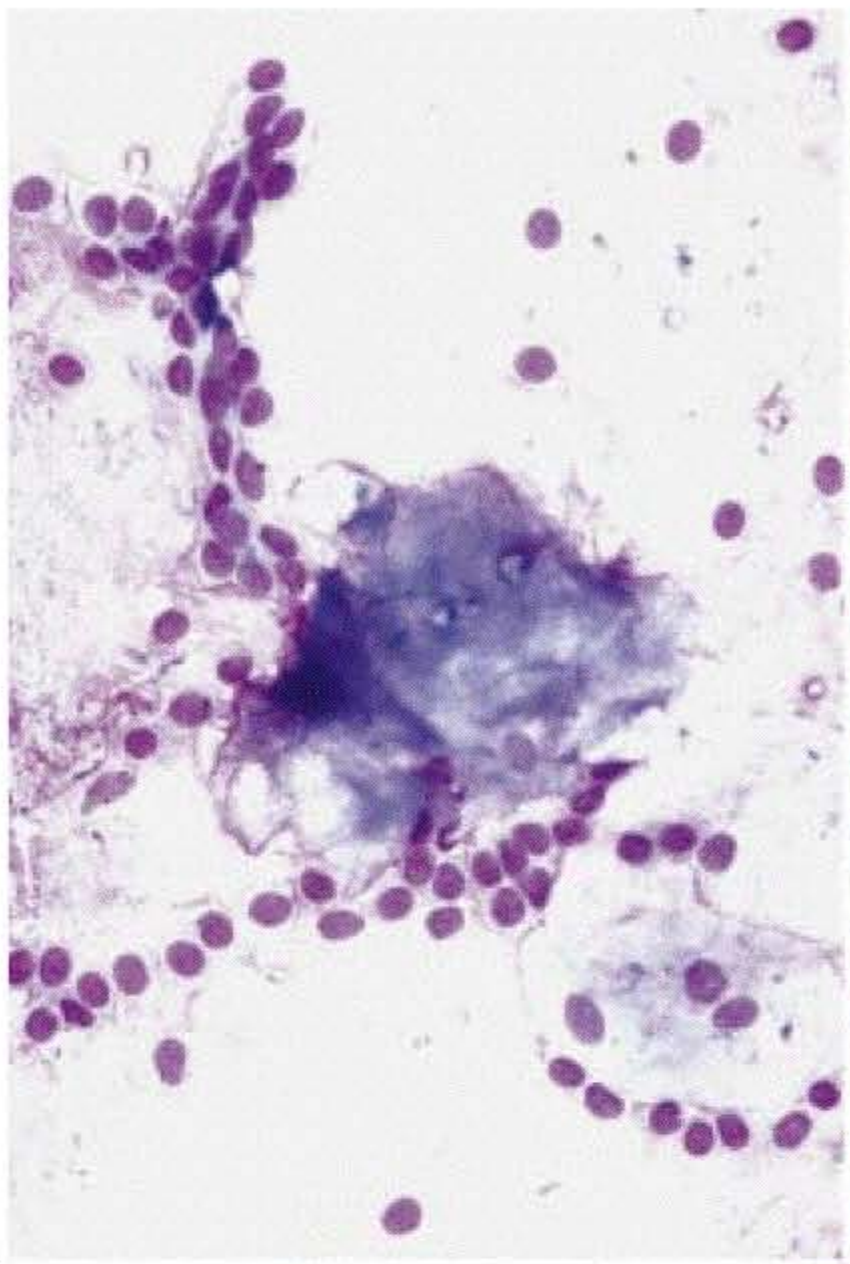

6.11

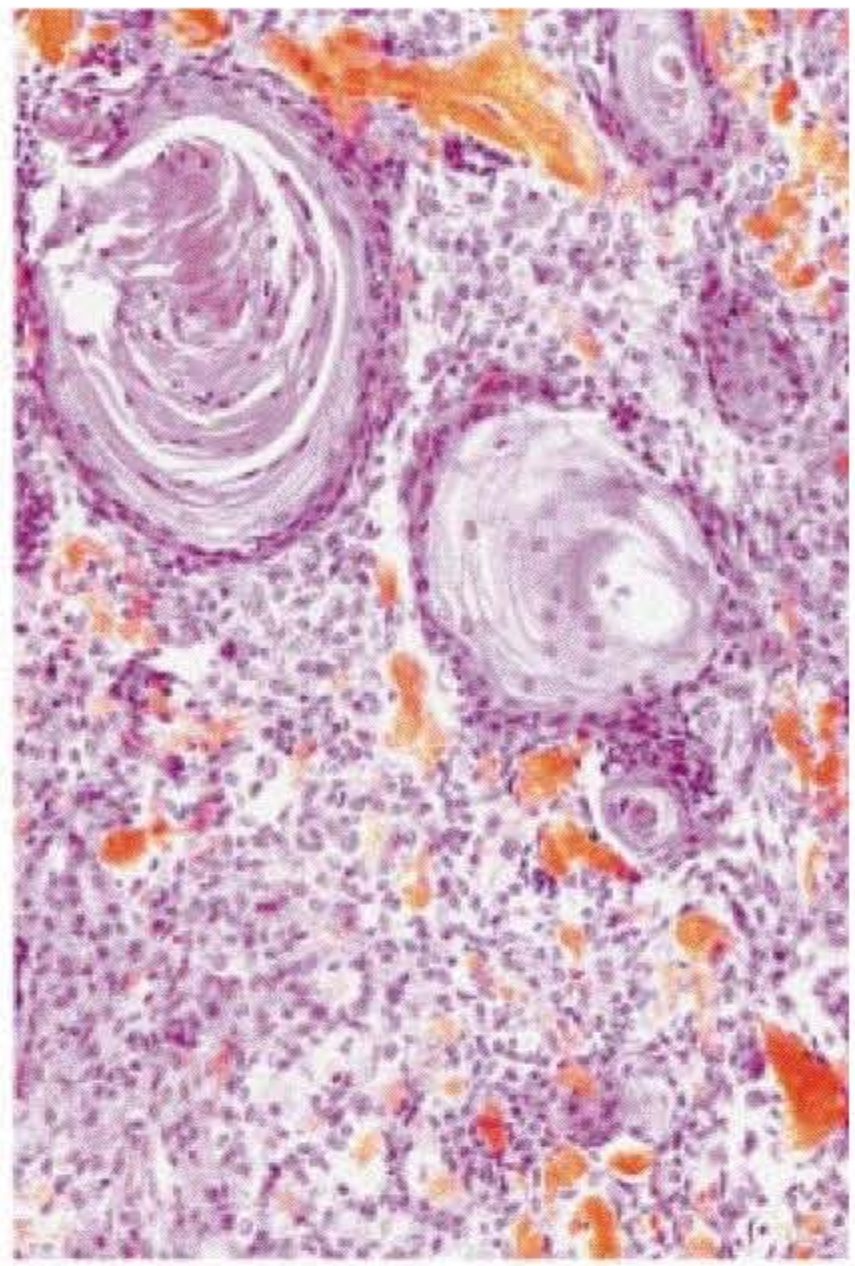

6.12

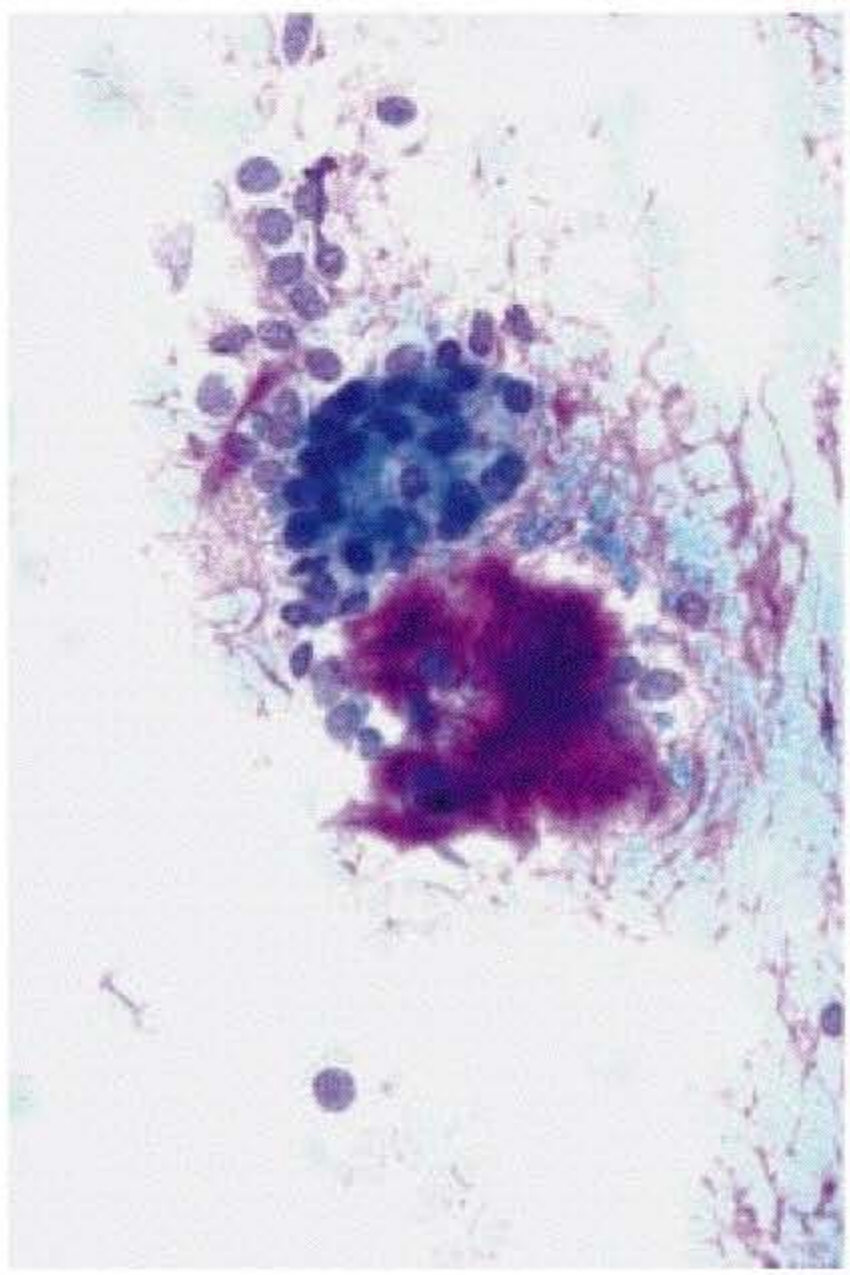

6.13

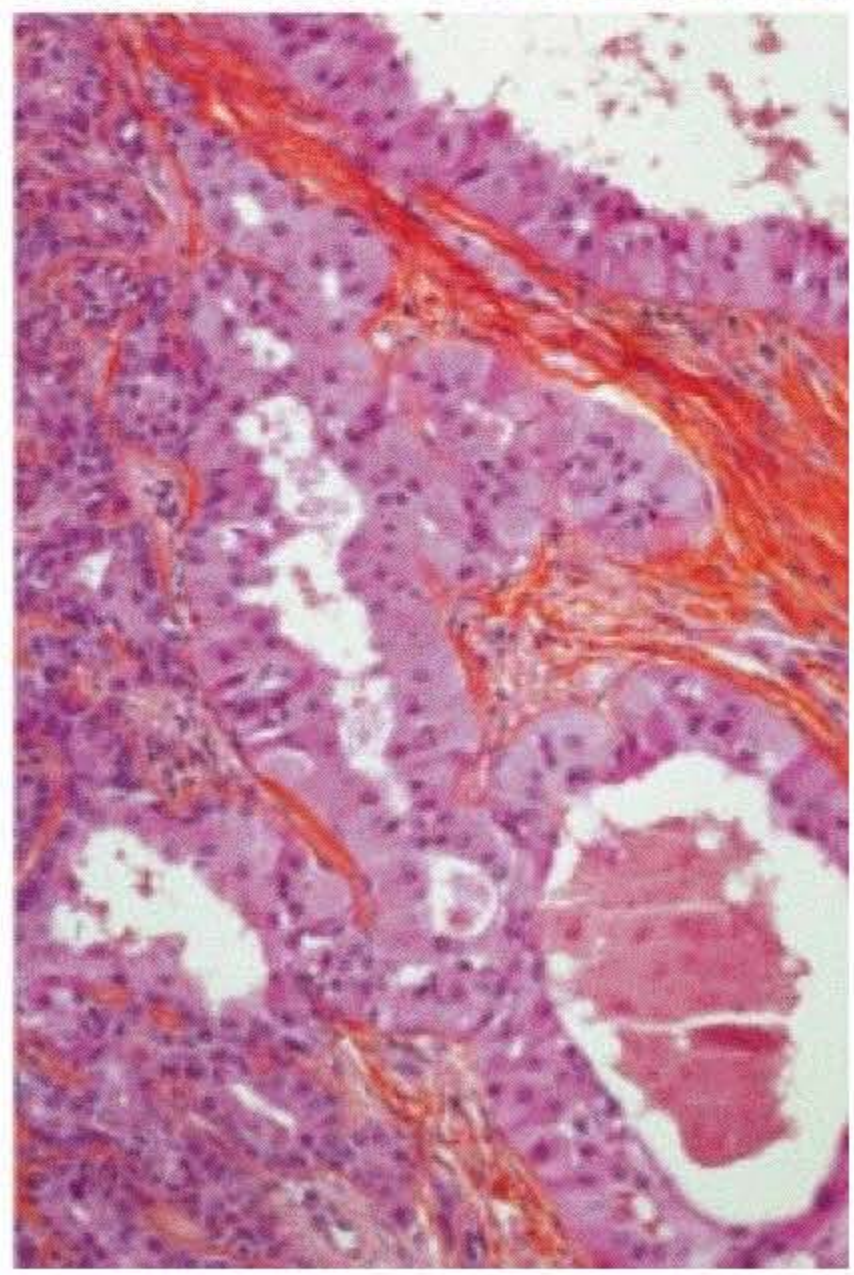

6.14

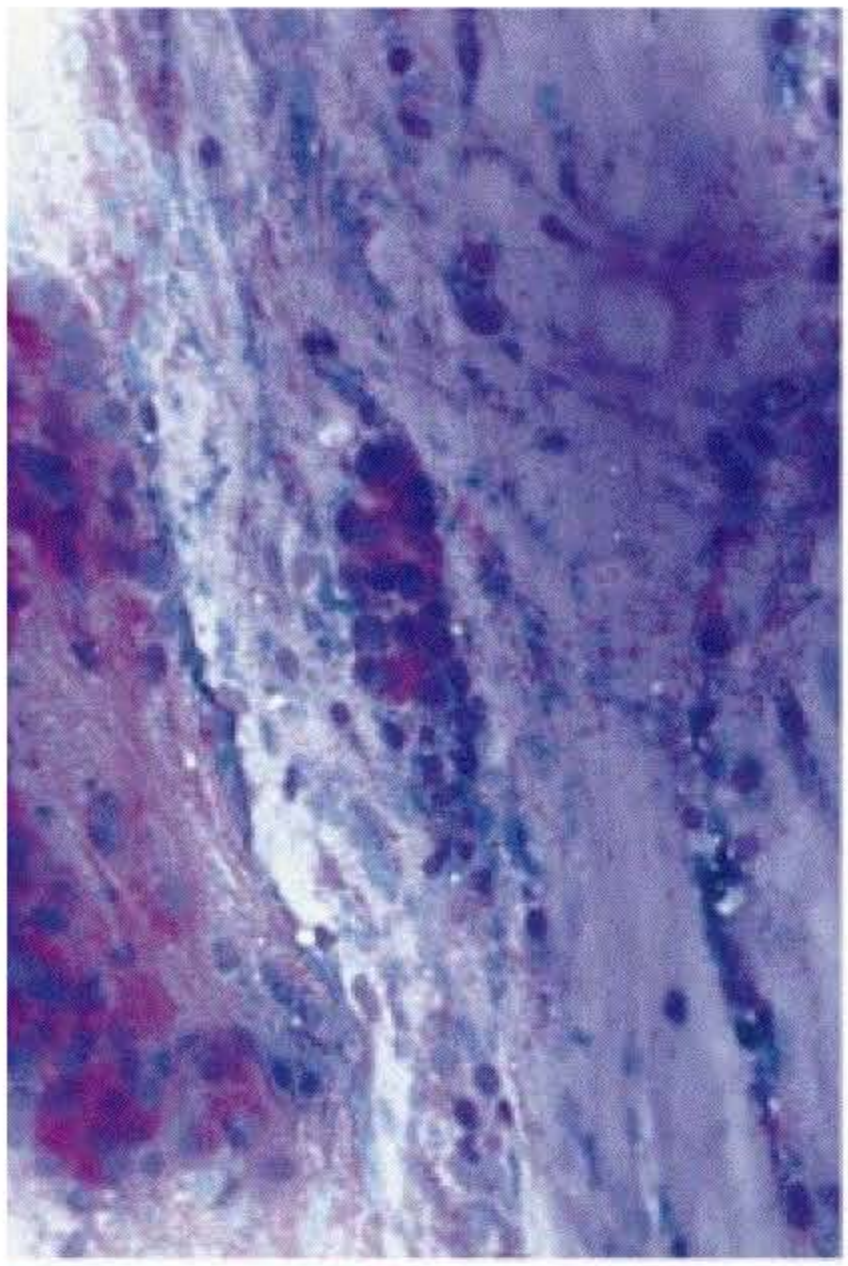

6.15

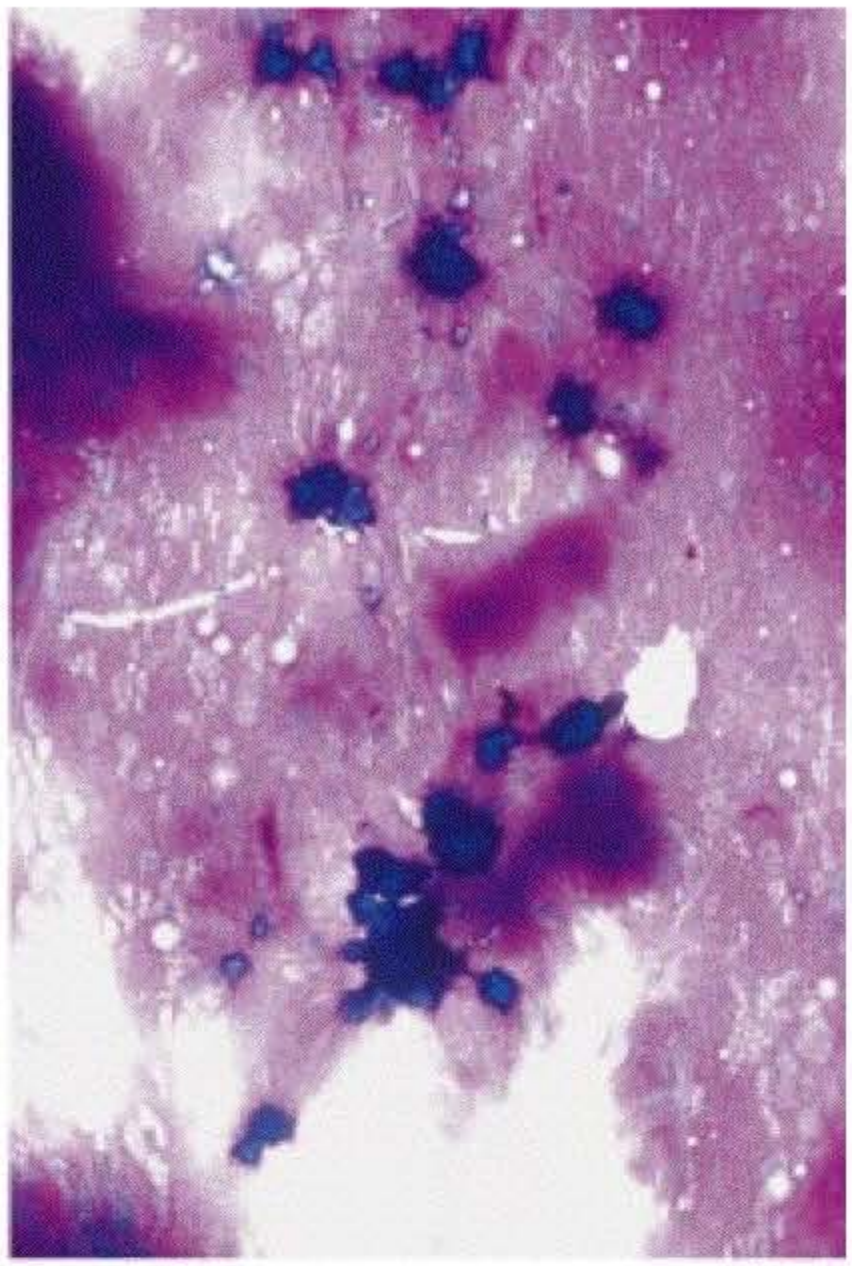

6.16

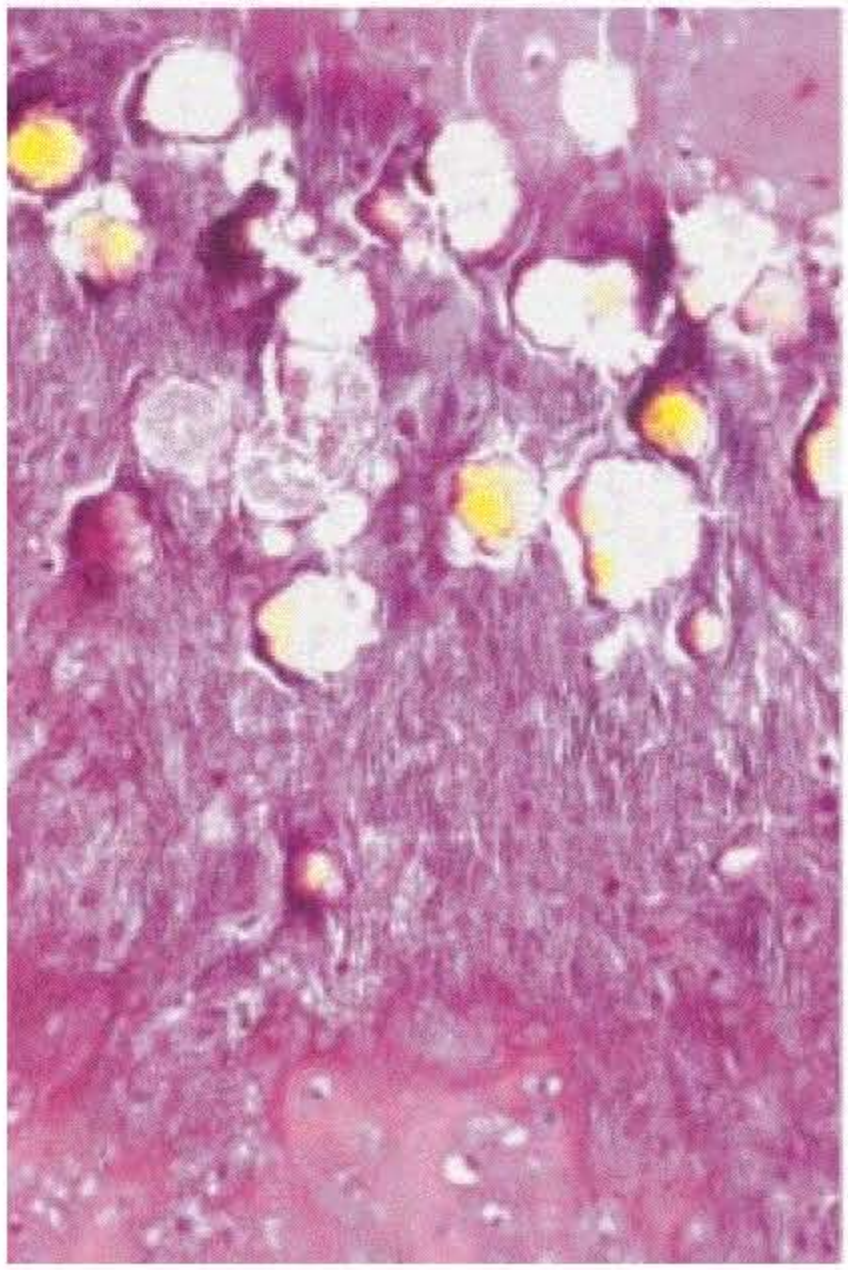

6.17

Fig. 6.11. Pleomorphic adenoma with squamous metaplasia. Keratin debris presenting as amorphous basophilic fragments neighbouring scant myoepithelial cells. MGG. ×128.

Fig. 6.12. Pleomorphic adenoma. Histological section corresponding to figure 6.11 showing focal squamous metaplasia. HES. ×32.

Fig. 6.13. Pleomorphic adenoma with oncocytic metaplasia. Well-delimited clusters of oncocytes adjacent to chondromyxoid stroma and myoepithelial plasmacytoid cells. MGG. ×128.

Fig. 6.14. Pleomorphic adenoma. Histological section corresponding to figure 6.13 showing focal oncocytic metaplasia. HES. ×64.

Fig. 6.15. Pleomorphic adenoma with mucus. Chondromyxoid stroma and plasmacytoid myoepithelial cells are well seen. This appearance should be differentiated from low-grade mucoepidermoid carcinoma arising in pleomorphic adenoma. Note that intermediate, squamoid and mucus-secreting cells are absent. MGG. ×128.

Fig. 6.16. Pleomorphic adenoma with tyrosine-rich crystalloids (appearing as dark violet deposits within chondromyxoid stroma). MGG. ×128.

Fig. 6.17. Pleomorphic adenoma. Histological section corresponding to figure 6.16 showing yellow crystalloids. HES. ×64.

Table 6.1. Correlation between cytology and histology in pleomorphic adenomas

Author [ref.]	Number	Benign	Suspicious and false-positive	Unsatisfactory
Von Haam [337]	38	38 (100)	0	0
Eneroth, Zajicek [98]	361	341 (94.5)	17 (4.7)	3 (0.8)
Persson, Zettergren [270]	136	132 (97)	2 (1.5)	2 (1.5)
Lindberg, Åkerman [222]	235	218 (92.8)	3 (1.3)	14 (5.9)
Qizilbash et al. [277]	79	77 (97.5)	2 (2.5)	0
Jayaram et al. [169]	26	25 (96.2)	1 (3.8)	0
Zurrida et al. [358]	120	110 (91.7)	0	10 (8.3)
Orell [263]	156	147 (94.2)	7 (4.5)	2 (1.3)
Klijanienko, Vielh [198]	412	383 (93)	18 (4.4)	11 (2.6)
Viguer et al. [336]	184	171 (93)	3 (1.6)	10 (5.4)
Total	1,747	1,642 (94)	53 (3)	52 (3)

Statistics from major series in the literature. % in parentheses.

6.1.1.3.4. Metaplastic Pleomorphic Adenoma. Metaplastic cells, especially squamous, oncocytic, goblet cells, mucoid and adipocytes intermingled with typical features of pleomorphic adenoma may be seen in various proportions (fig. 6.11–6.15), as well as tyrosine-rich crystalloids [33] (fig. 6.16, 6.17).

6.1.1.4. Diagnostic Accuracy

Table 6.1 shows the correlation between cytology and histology in several large series of pleomorphic adenomas. The diagnosis of pleomorphic adenoma is obvious in typical tumours representing the large majority of cases. The suspicious and false-positive rates represent 3% of cases.

6.1.1.5. Differential Diagnosis

Table 6.3 summarizes the main differential diagnoses of pleomorphic adenoma.

6.1.1.5.1. Pleomorphic Adenoma with Hyaline Globules vs. Adenoid Cystic Carcinoma, Polymorphous Low-Grade Carcinoma, Epithelial-Myoepithelial Carcinoma and Basal Cell Tumours. One of the classical alarming patterns is the presence of isolated stromal hyalinized globules sometimes surrounded by cohesive cells (fig. 6.6, 6.7). The other, morphologically similar pattern, is a focal cribriform architecture with clusters of myoepithelial cells. Cytologically, the differential diagnosis is based on recognition of myoepithelial cells with distinctive cytoplasm. Adenoid cystic carcinoma, epithelial-myoepithelial carcinoma, polymorphous low-grade adenocarcinoma and basal cell tumours lack scattered myoepithelial plasmacytoid cells [188, 194, 195, 200] (fig. 6.35, 7.21, 7.23, 7.30, 8.22, 8.29). Inversely, pleomorphic adenomas usually lack the naked nuclei frequently present in adenoid cystic carcinoma, polymorphous low-grade adenocarcinoma, epithelial-myoepithelial carcinoma and basal cell tumours [93, 188, 194]. Basal cells, however, may exhibit well-delimited cytoplasm and mimic myoepithelial cells, but their cytoplasm is smaller and they do not have a plasmacytoid shape (fig. 6.35). Basal cell tumours are also characterized by the presence of three-dimensional dark clusters and peripheral palisading (fig. 6.35).

Table 6.2. Correlation between cytology and histology in myoepitheliomas

Author [ref.]	Number	Benign	Suspicious and false-positive	Unsatisfactory
Zurrida et al. [358]	10	10	0	0
Dodd et al. [84]	1	1	0	0
Hara et al. [146]	1	1	0	0
Orell [263]	3	3	0	0
Katsuyama et al. [174]	1	1	0	0
Our series	5	1	0	0
Total	21	21	0	0

Statistics from the literature.

6.1.1.5.2. Pleomorphic Adenoma with Mucoid Stroma vs. Low-Grade Mucoepidermoid Carcinoma. Another diagnostic difficulty is the presence of mucoid background within a typical appearance of pleomorphic adenoma (fig.

6.15) [198, 322]. The arguments in favour of mucoepidermoid carcinoma are the presence of intermediate, squamous and mucus-producing cells (fig. 7.1, 7.5, 7.8). It has also been reported [93] that chondromyxoid stroma can be confused with mucin associated with mucoepidermoid carcinoma. This differential diagnosis can be facilitated by using MGG stain, which stains mucin from dark blue to clear pink with characteristic striations (fig. 8.3).

6.1.1.5.3. Pleomorphic Adenoma (Stroma-Poor) vs. Myoepithelioma. When stromal fragments are absent or extremely scant, the differential diagnosis between pleomorphic adenoma and myoepithelioma often remains impossible (fig. 6.9, 6.18). However, this failure to distinguish between these two tumours is not dramatic, as the therapeutic strategy is similar in both cases.

6.1.1.5.4. Pleomorphic Adenoma vs. Metastasizing Pleomorphic Adenoma. Even when smears are typical of pleomorphic adenoma, the possibility of undersampled carcinoma arising from pleomorphic adenoma cannot be ruled out. Similarly, metastasizing mixed tumour does not present any specific morphological features [28, 186, 191].

Pleomorphic Adenoma

In favour of the diagnosis

Plasmacytoid or spindle-shaped myoepithelial cells and chondromyxoid stroma; absence of naked nuclei

Difficulties

Naked nuclei, mucus, hyaline globules, squamous cells or oncocytes, nuclear pleomorphism (atypia)

Against the diagnosis

Finger-like and/or tubular structures, mucus-secreting and/or intermediate cells, lack of myoepithelial cells or of chondromyxoid stroma

6.1.2. Myoepithelioma (Myoepithelial Adenoma)

The term myoepithelioma is reserved for tumours composed of spindle-shaped or plasmacytoid cells without epithelial glandular structures.

6.1.2.1. General

Approximately 100 myoepitheliomas have been reported in the literature [90]. Fifty-one percent of tumours are located in the parotid gland, 27% in the palate and 12% in the submandibular gland [18]. The age and sex distributions are similar to those of pleomorphic adenomas.

6.1.2.2. Histopathology

Four types of myoepithelioma are described: spindle-shaped, plasmacytoid, epithelioid and mixed spindle-shaped intermingled with plasmacytoid cells. Tumours exhibiting few (more than 10% of cut surface) epithelial structures within a predominant proliferation of myoepithelial cells are classified as myoepithelial subtype of pleomorphic adenoma [21, 89].

6.1.2.3. Cytopathology

Smears are composed of uniform, spindle-shaped or plasmacytoid cells with well-delimited cytoplasm. Binucleation may be seen. Cell clusters show a mosaic arrangement. No atypia or mitosis are seen [84, 146, 174, 263, 350] (fig. 6.18–6.21).

6.1.2.4. Diagnostic Accuracy

Table 6.2 summarizes the correlation between cytology and histology in the few examples of myoepitheliomas reported in the literature. No suspicious or false-positive diagnoses were made, and five tumours were misdiagnosed as pleomorphic adenoma.

6.1.2.5. Differential Diagnosis

Table 6.3 summarizes the main differential diagnoses of myoepithelioma.

6.1.2.5.1. Myoepithelioma vs. Cellular Pleomorphic Adenoma. The cytological appearance is characteristic for a myoepithelial origin, but indistinguishable from cellular pleomorphic adenoma when stromal fragments are present (fig. 6.9, 6.18) [146].

6.1.2.5.2. Myoepithelioma vs. Malignant Myoepithelioma. Malignant myoepithelioma should be suggested in the case of marked atypia, necrosis or mitotic figures or intranuclear or intracytoplasmic inclusions (fig. 7.36, 7.37).

Myoepithelioma

In favour of the diagnosis

Plasmacytoid or spindle-shaped cells with well-delimited cytoplasm, fibrous stroma

Difficulties

Chondromyxoid or fibrous stroma may be absent

Against the diagnosis

Mitotic figures, marked atypia, intranuclear or intracytoplasmic inclusions

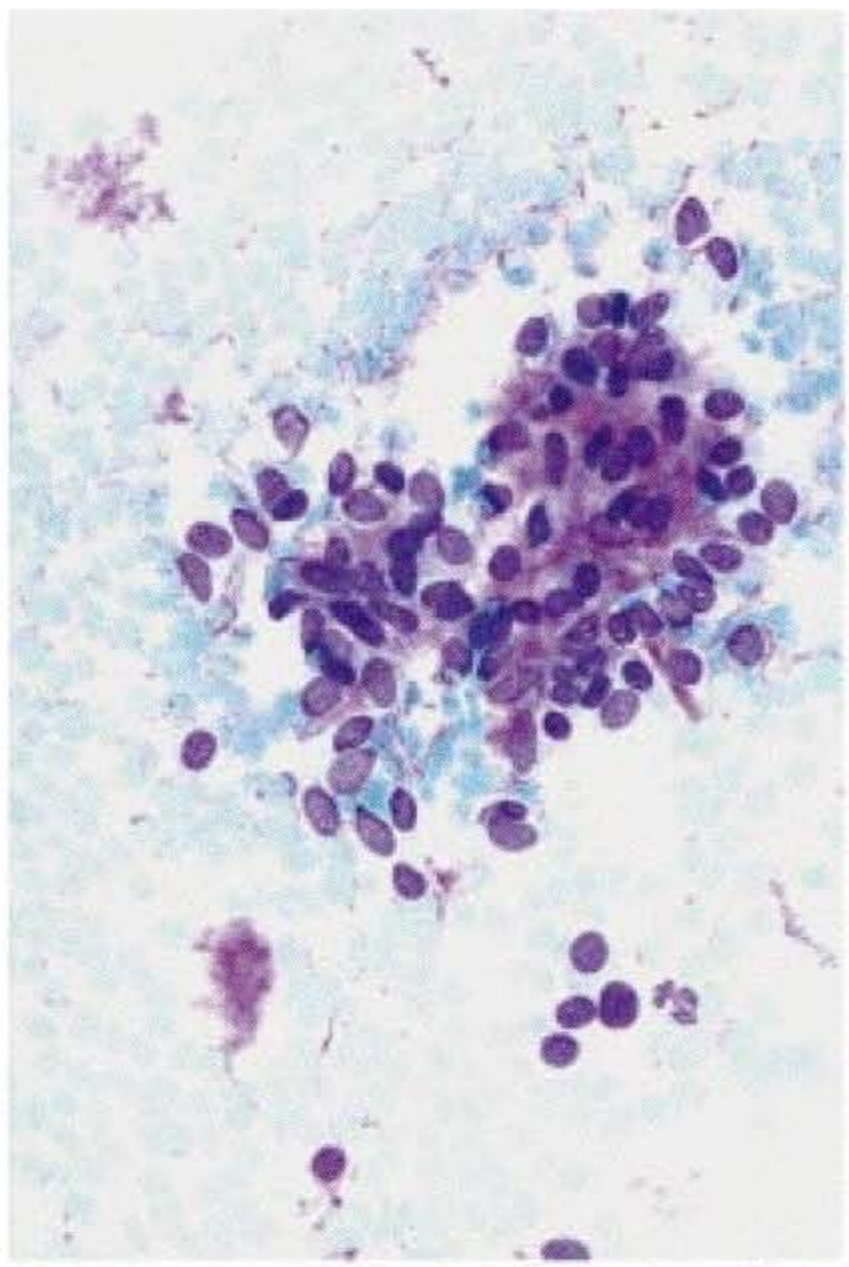

6.18

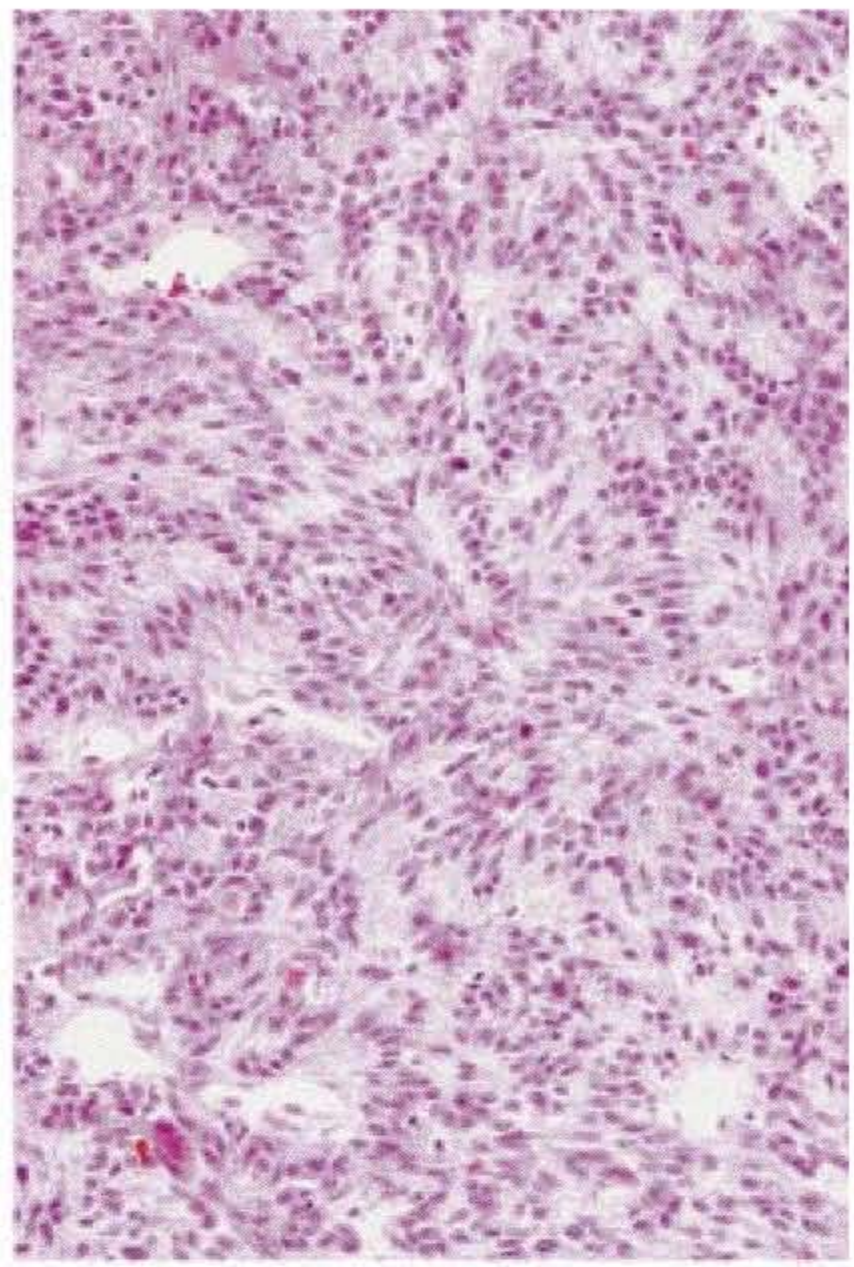

6.19

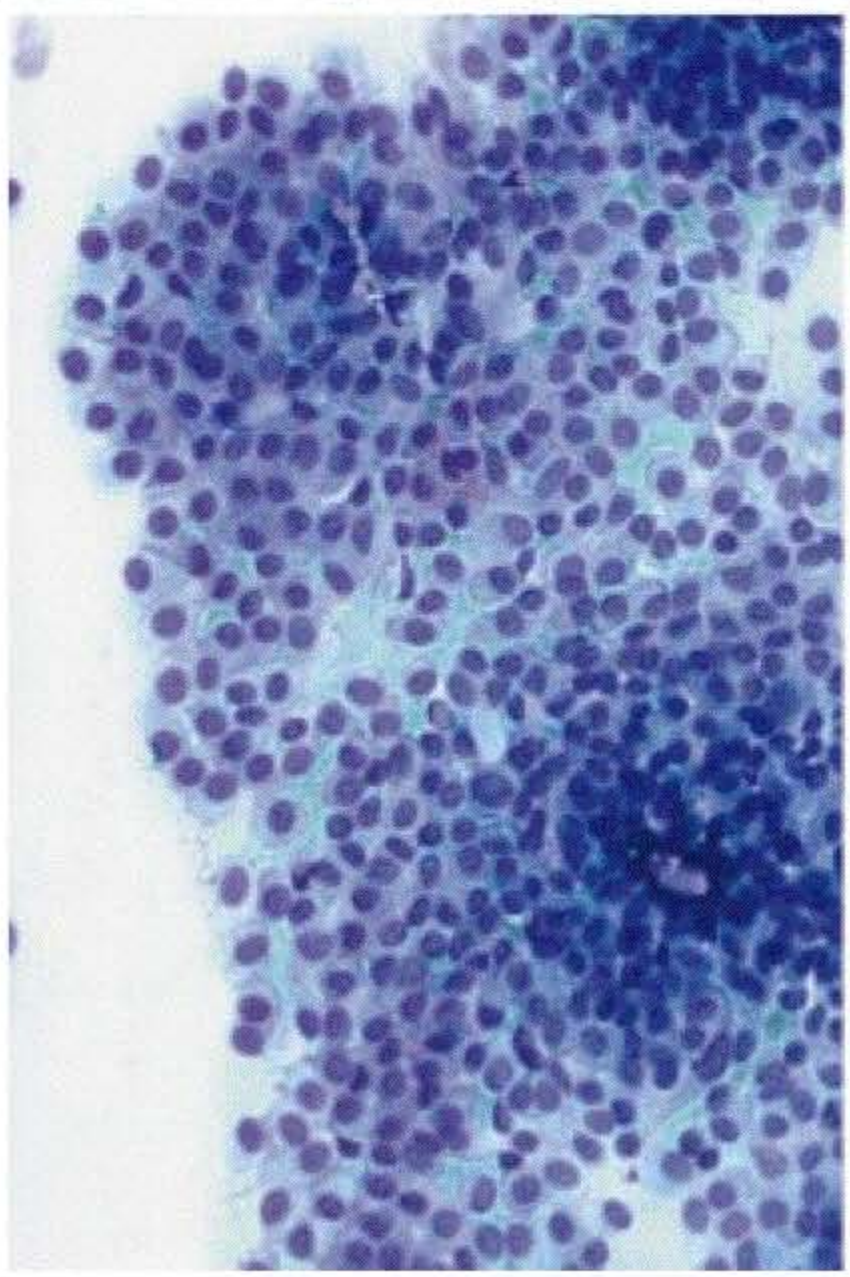

6.20

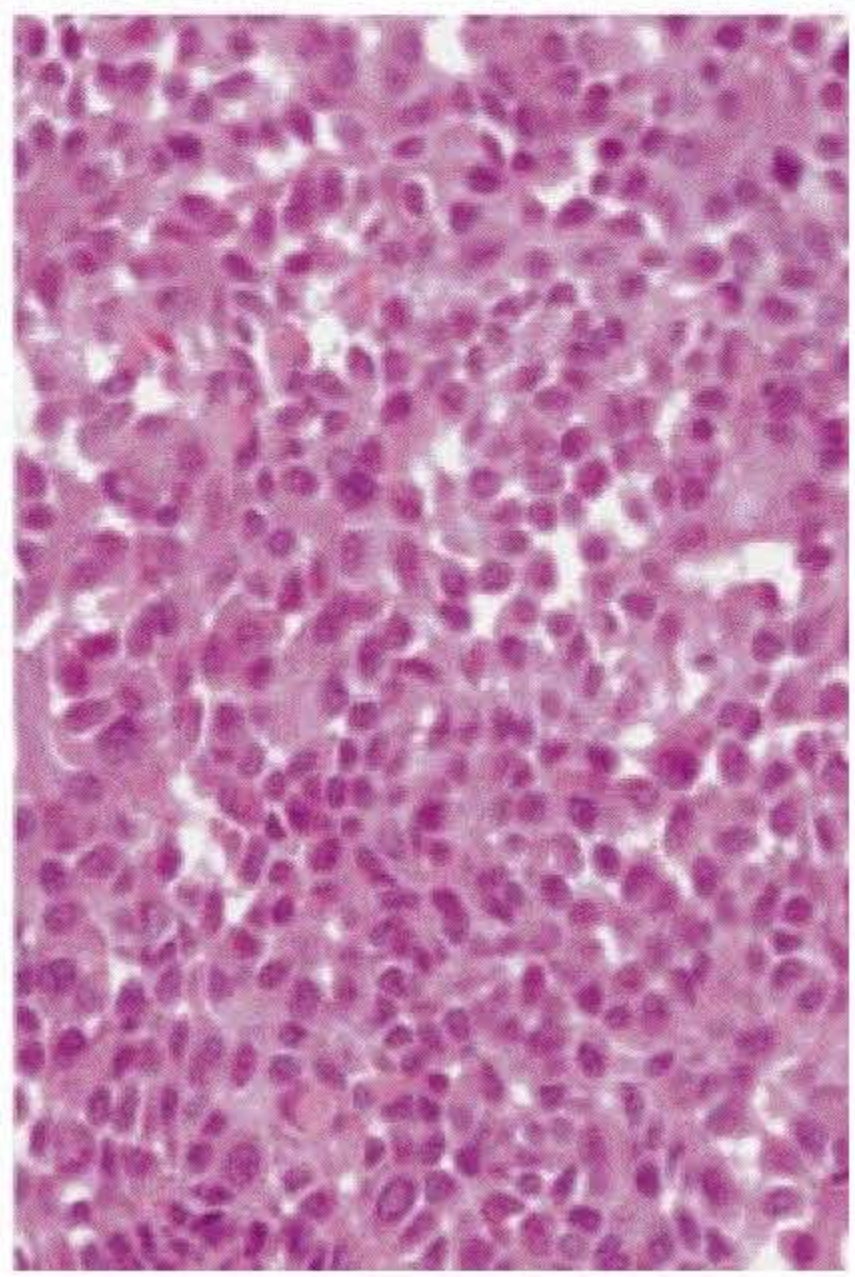

6.21

Table 6.3. Differential diagnosis of adenomas with prominent myoepithelial cells (pleomorphic adenoma and myoepithelioma)

	Pleomorphic adenoma		Myo-epithe-lioma	Adenoid cystic carcinoma	Epithelial-myoepi-thelial carcinoma	Polymorphous low-grade adeno-carcinoma	Basal cell tumours
	chondro-myxoid	cellular					
Cells							
Plasmacytoid	+	++	++	–	+/–	–	–
Spindle-shaped	+	++	++	–	–	?	?
Basaloid	–	–	–	++	?	–	++
Naked nuclei	+/–	+/–	–	++	?	?	++
Squamous	+	+/–	–	+/–	?	+/–	+
Stroma							
Globules	+/–	+/–	–	++	++	++	+
Chondromyxoid	++	+	–	–	–	–	–
Fibrous	+/–	+/–	+/–	+/–	?	?	+

++ = common; +, = rare; +/– = occasionally seen; – = absent.

6.2. Adenomas with Prominent Oncocytes

Cytologically, a prominent population of benign oncocytes is observed in Warthin's tumour, oncocytic papillary cystadenoma, and oncocytic adenoma/hyperplasia. The commonest oncocytic tumour is Warthin's tumour.

6.2.1. Warthin's Tumour (Adenolymphoma)

6.2.1.1. General

Warthin's tumour mainly arises in the lower pole of the parotid gland, accounting for 2–10% of all parotid gland tumours. It is characterized by a male predominance [90]. No specific age has been observed, but the majority of patients present during the sixth decade of life [90].

6.2.1.2. Histopathology

Histological sections show papillary proliferation composed of oncocytes with an inner layer of tall nonciliated cells, and an outer layer of cuboidal cells [89]. Squamous, sebaceous metaplasia or spontaneous necrosis may be occasionally seen [242]. The prominent lymphoid stroma usually consists of lymphocytes organized in follicles with germinal centres. The cystic spaces contain macroscopically clear or brown fluid, corresponding to serous or mucoid fluid on microscopy.

Fig. 6.18. Myoepithelioma. Spindle-shaped myoepithelial cells arranged in three-dimensional clusters. Note the absence of chondromyxoid stroma. MGG. ×128.

Fig. 6.19. Myoepithelioma. Histological section corresponding to figure 6.18. Epithelial structures are absent. HES. ×64.

Fig. 6.20. Myoepithelioma. Plasmacytoid myoepithelial cells. Chondromyxoid stroma is absent. MGG. ×128.

Fig. 6.21. Myoepithelioma. Histological sections corresponding to figure 6.20. HES. ×128.

6.2.1.3. Cytopathology

Tumour aspirates are often liquid. Three distinct cytological components, either isolated or associated, are commonly present in different proportions on the smears [199, 263]: (1) oncocytes, either isolated, in clusters or in papillary structures with a polyhedral appearance and a large, finely granular cytoplasm; (2) lymphoid stroma resembling stimulated lymph node, and (3) necrosis or necrosis-like material (fig. 6.22–6.24).

Accurate typing of Warthin's tumour is easy when it exhibits three characteristic components, i.e. oncocytes, lymphocytes and inflammatory/necrotic-like material (fig. 6.22–6.25). However, smears are commonly less representative and may be composed of only one or two components. In our experience, the presence of oncocytes, lymphocytes or pseudonecrosis is sufficient for accurate typing.

A few cases may exhibit squamous or sebaceous cells, extracellular mucoid substance containing acute inflammatory cells (fig. 6.25–6.27) or crystalloids. Mast cells are frequently seen within oncocytic clusters (fig. 6.28).

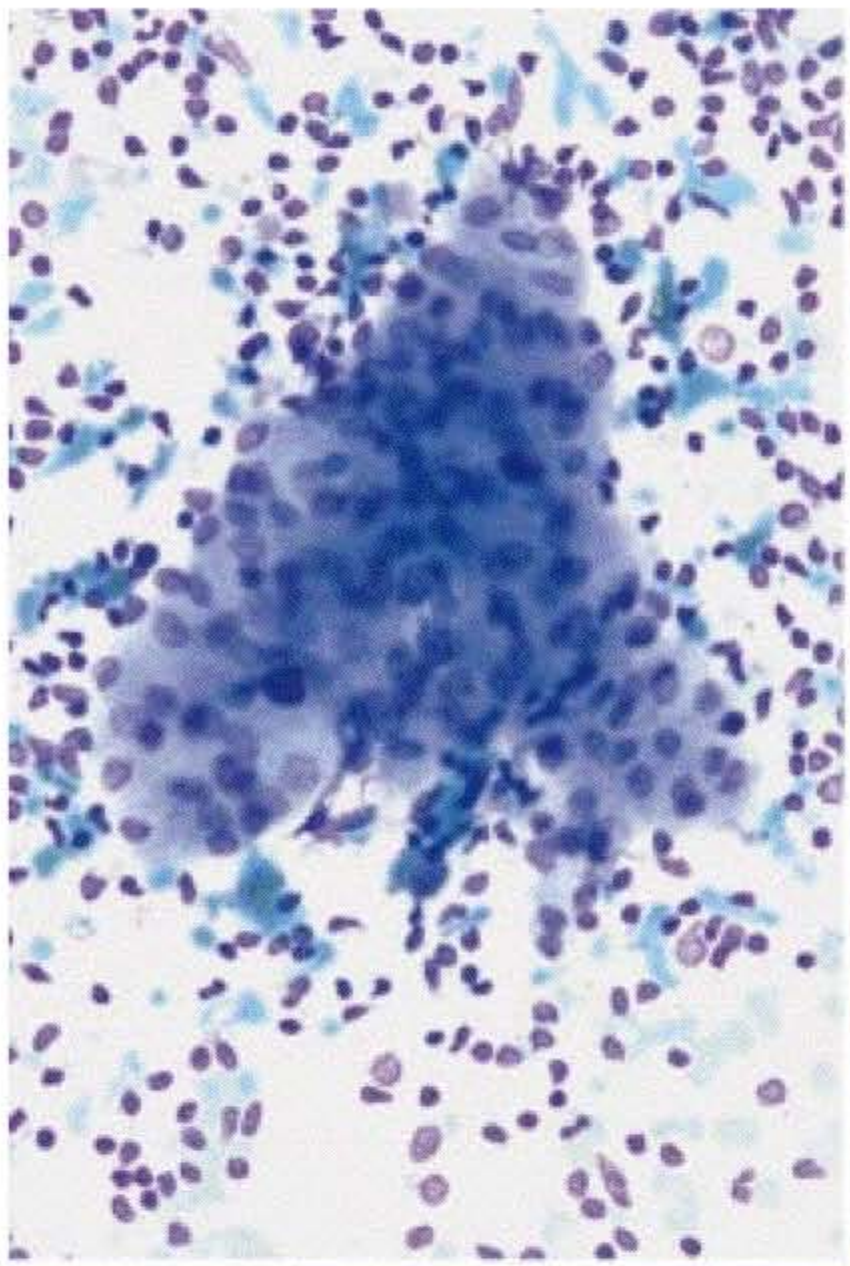

6.22

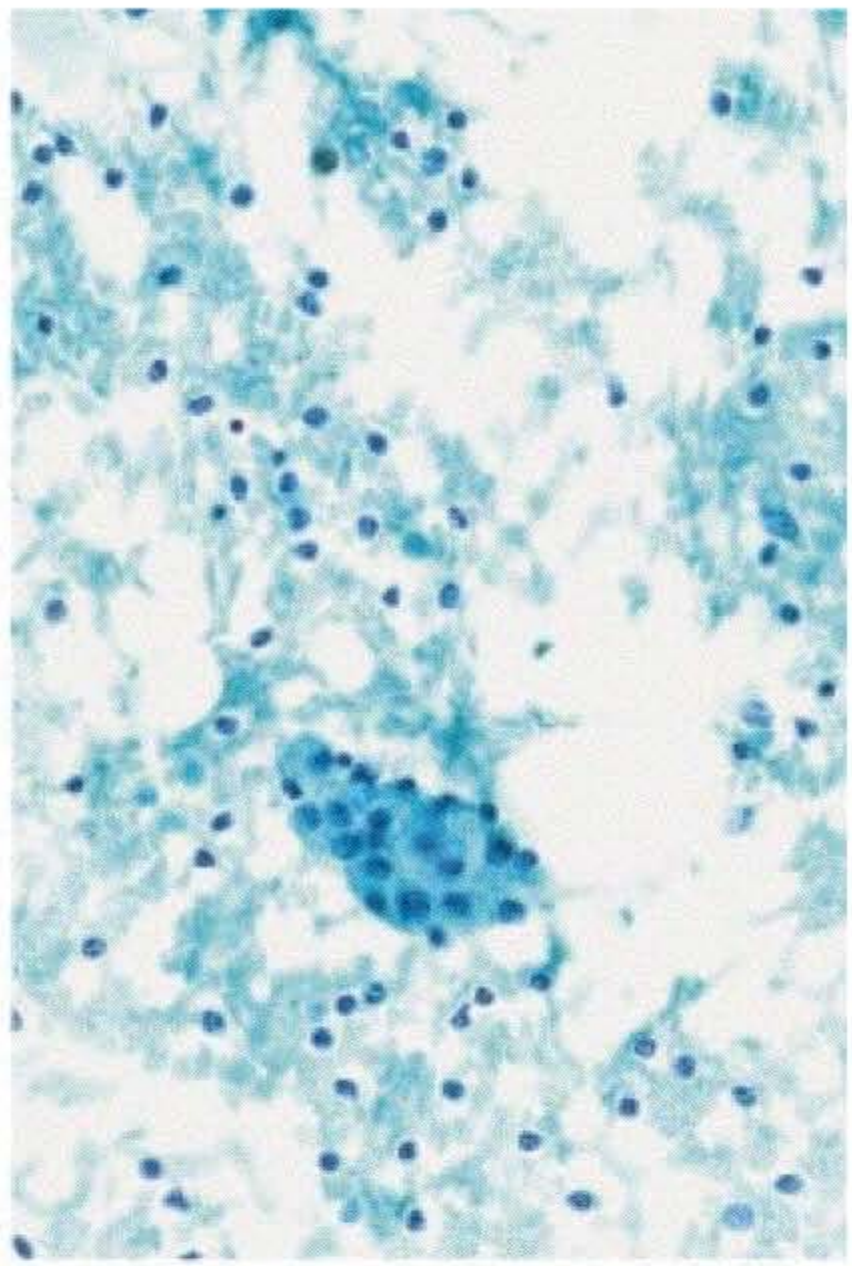

6.23

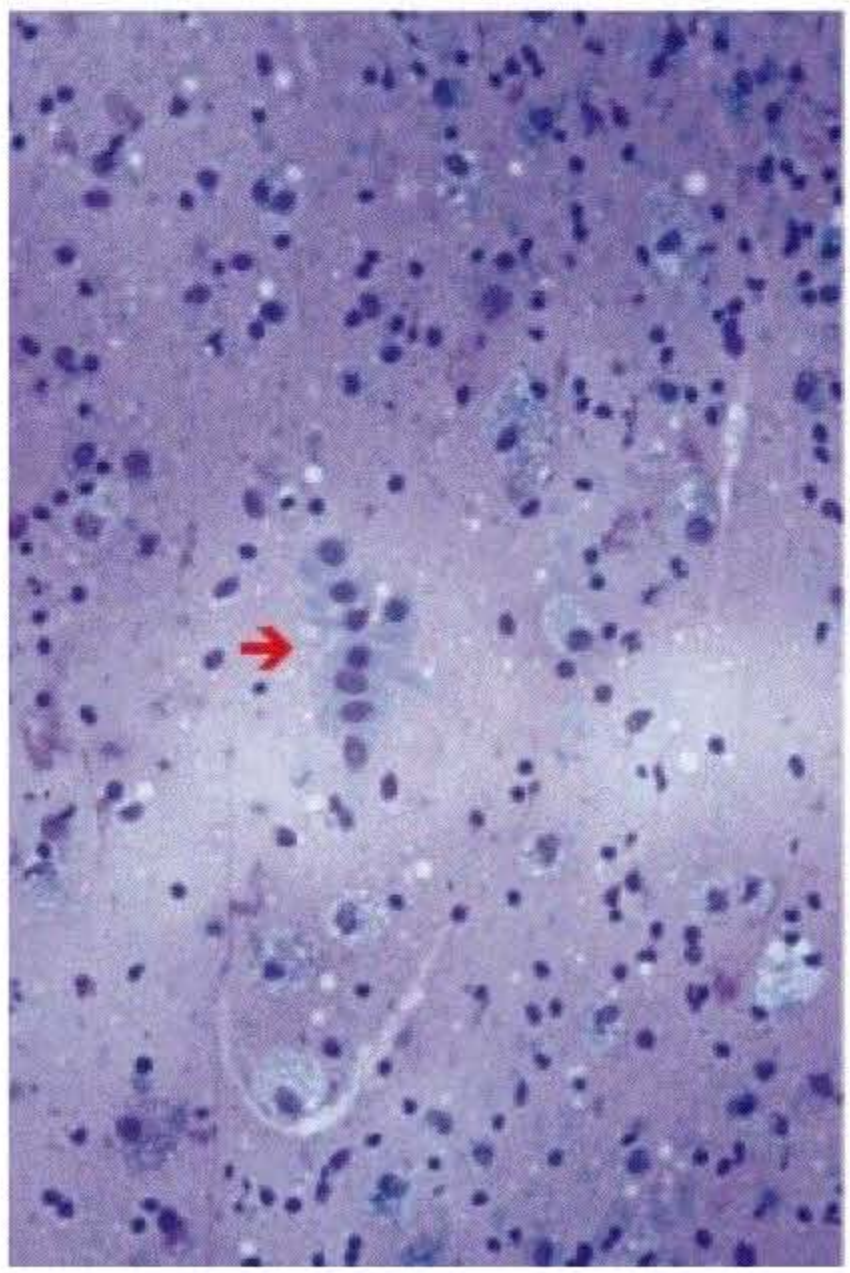

6.24

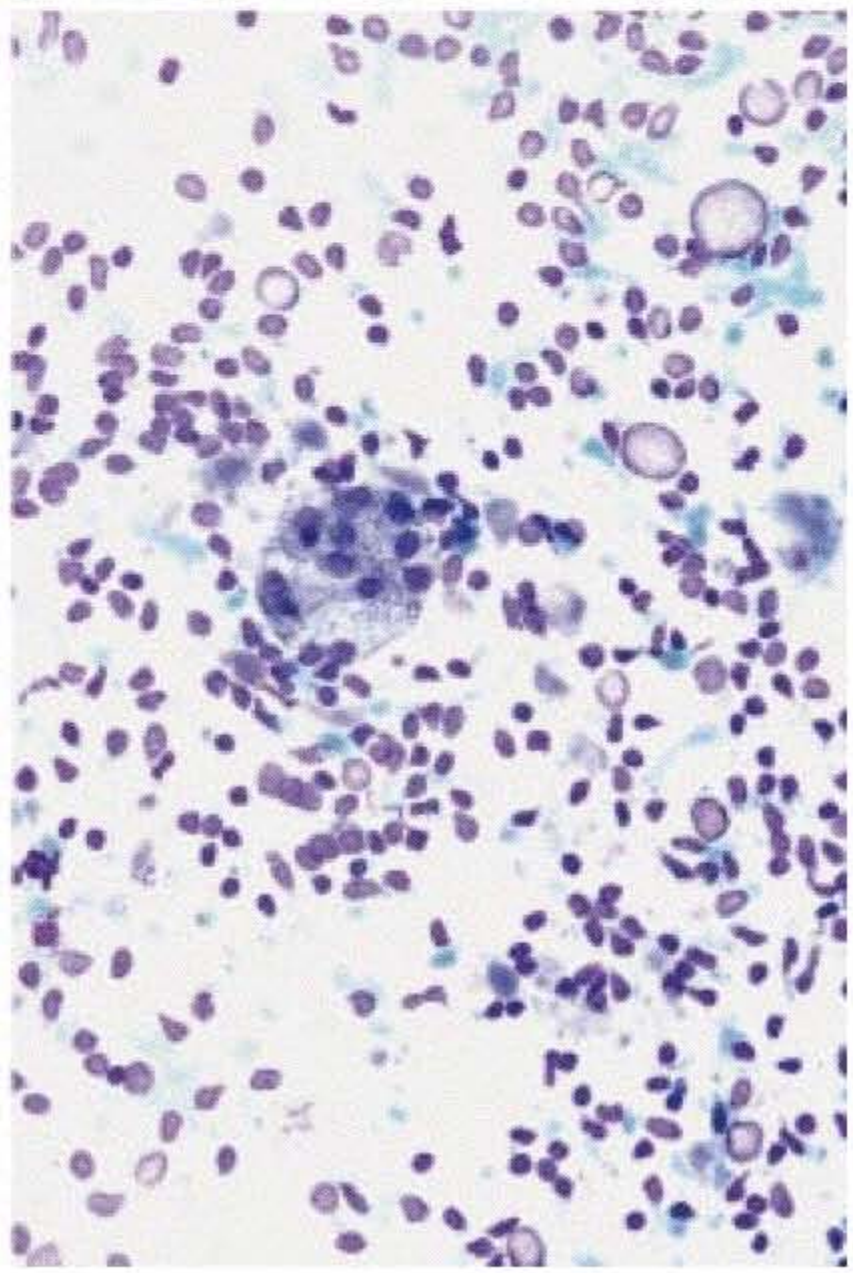

6.25

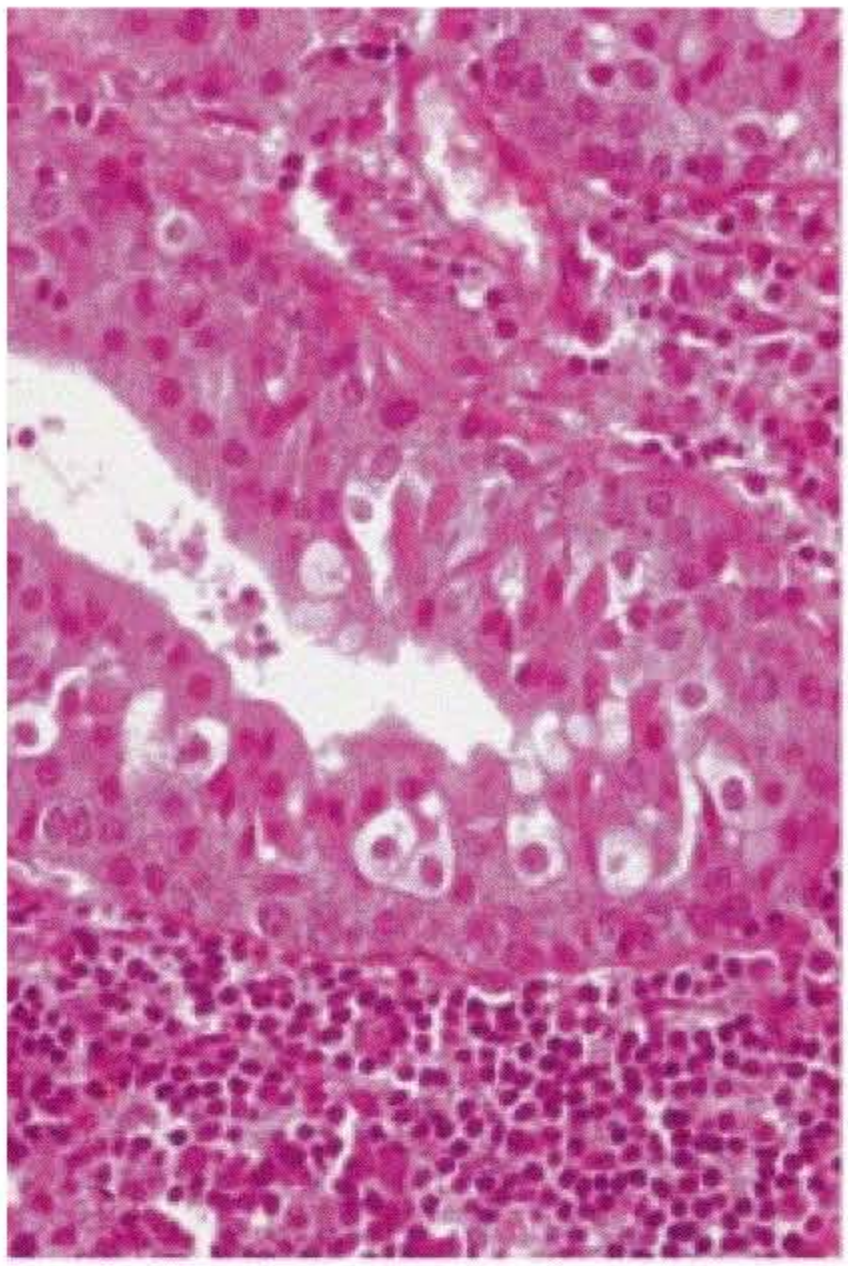

6.26

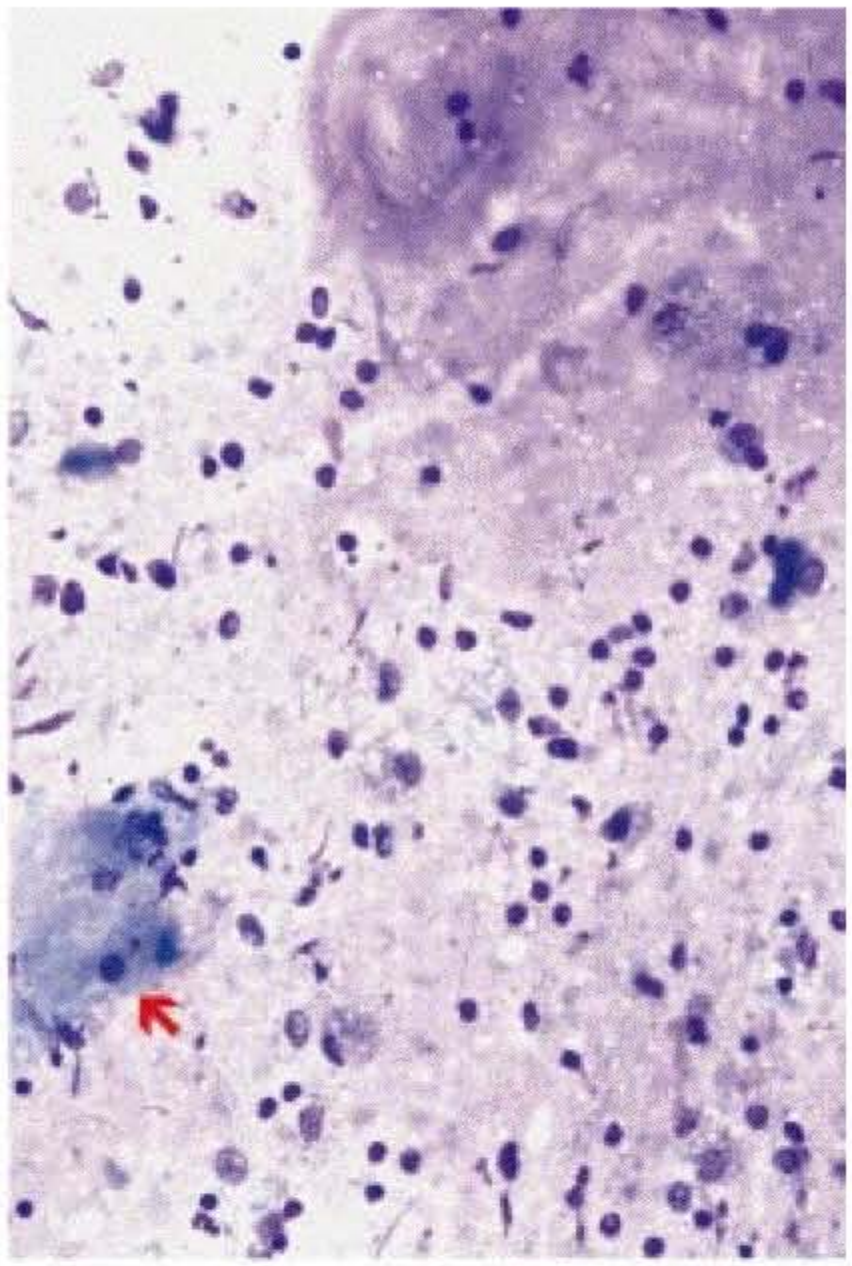

6.27

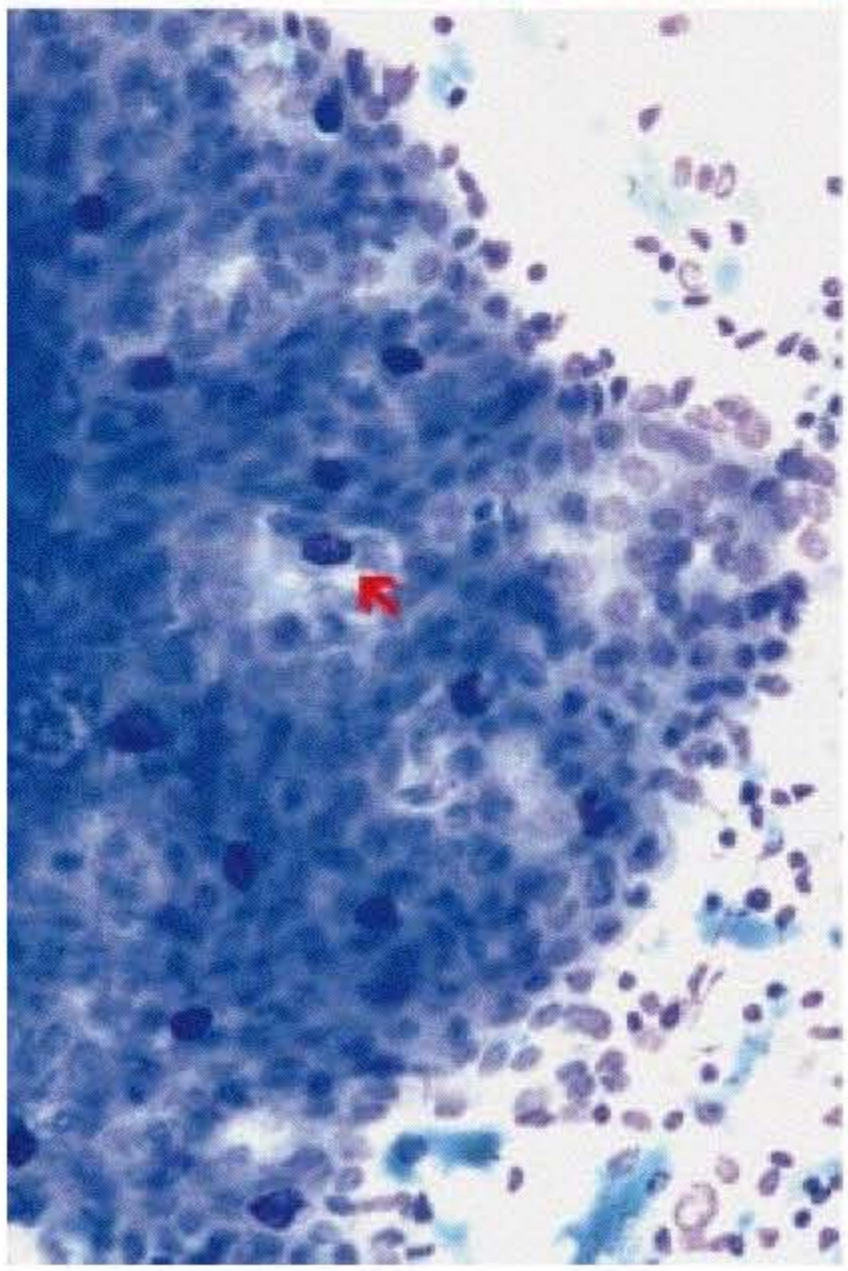

6.28

Fig. 6.22. Typical Warthin's tumour. Large clusters of oncocytes with abundant cytoplasm and numerous lymphocytes in the background. MGG. ×128.

Fig. 6.23. Typical Warthin's tumour. Papanicolaou. ×128.

Fig. 6.24. Warthin's tumour. Extensive pseudonecrosis, reminiscent of low-grade mucoepidermoid carcinoma. Note the presence of oncocytes (arrow) strongly suggesting the diagnosis of Warthin's tumour. MGG. ×128.

Fig. 6.25. Warthin's tumour. Small cluster of sebaceous cells with characteristic multivacuolated cytoplasm and eccentric small nuclei. Lymphocytes are numerous. This pattern may be suggestive of sebaceous lymphadenoma, but oncocytes (not shown) are also present. MGG. ×128.

Fig. 6.26. Warthin's tumour. Histological section corresponding to figure 6.25 showing sebaceous metaplasia. HES. ×128.

Fig. 6.27. Warthin's tumour. Some Warthin's tumours may show focal mucoid stroma and squamous cells (arrow) suggesting low-grade mucoepidermoid carcinoma. The presence of oncocytes (not shown here) helps in the differential diagnosis. MGG. ×128.

Fig. 6.28. Warthin's tumour. Mast cells (arrow) within a cluster of oncocytes. MGG. ×128.

Table 6.4. Correlation between cytology and histology in Warthin's tumours

Author [ref.]	Number	Benign	Suspicious and false-positive	Unsatisfactory
Eneroth, Zajicek [99]	45	44 (97.8)	1 (2.2)	0
Persson, Zettergren [270]	24	21 (87.5)	1 (4.2)	2 (8.3)
Lindberg, Åkerman [222]	31	26 (83.9)	3 (9.7)	2 (6.4)
Kline et al. [201]	7	7 (100)	0	0
Qizilbash et al. [277]	8	8 (100)	0	0
Zurrida et al. [358]	37	33 (89.2)	0	4 (10.8)
Orell [263]	42	41 (97.6)	1 (2.4)	0
Klijanienko, Vielh [199]	71	64 (90.1)	0	7 (9.9)
Total	265	244 (92.1)	6 (2.3)	15 (5.7)

Statistics from the literature. % in parentheses.

Table 6.5. Differential diagnosis of Warthin's tumour

	Warthin's tumour	Oncocytoma	Low-grade mucoepidermoid carcinoma	Squamous cell carcinoma	Acinic cell carcinoma
Cells					
Oncocytes (-like)	++	++	+/–	–	+/–
Squamous	+/–	–	+	++	–
Intermediate	–	–	+	+/–	–
Goblet cells	+/–	–	++	–	–
Mast cells	++	–	+/–	–	–
Stroma					
Lymphocytic	++	–	+/–	+/–	+
Necrotic	++	–	++	++	–
Mucoid	+/–	–	++	–	–

++ = common; + = rare; +/– = occasionally seen; – = absent.

6.2.1.4. Diagnostic Accuracy

More than 250 cases have been reported in the literature, with accurate diagnoses of benign lesions in 92.1% of cases and suspicious and false-negative diagnoses in 2.3% of cases (table 6.4).

6.2.1.5. Differential Diagnosis

Table 6.5 summarizes the main differential diagnoses of Warthin's tumour.

6.2.1.5.1. Warthin's Tumour vs. Oncocytoma, Abscess, Lymphadenitis. When smears show a single cytological component, the correct diagnosis is more difficult and the differential diagnosis should include other benign conditions such as oncocytoma, intraparotid lymphadenitis and salivary cyst/abscess, when the smears contain only oncocytes, lymphocytes or an inflammatory necrosis, respectively. The presence of mast cells may be helpful in the diagnosis of Warthin's tumour, but they are also present in 10% of mucoepidermoid carcinomas (fig. 8.11) and 5% of pleomorphic adenomas [196, 198].

6.2.1.5.2. Warthin's Tumour vs. Squamous Cell and Low-Grade Mucoepidermoid Carcinomas. In some rare cases, cytological difficulties may be encountered in the presence of squamous metaplasia and/or mucoid background and such cases should be differentiated from primary salivary squamous cell or low-grade mucoepidermoid carcinoma, intraparotid metastasis from head and neck squamous cell carcinoma and squamous cell or mucoepidermoid carcinoma arising from Warthin's tumour (fig. 6.29) [255].

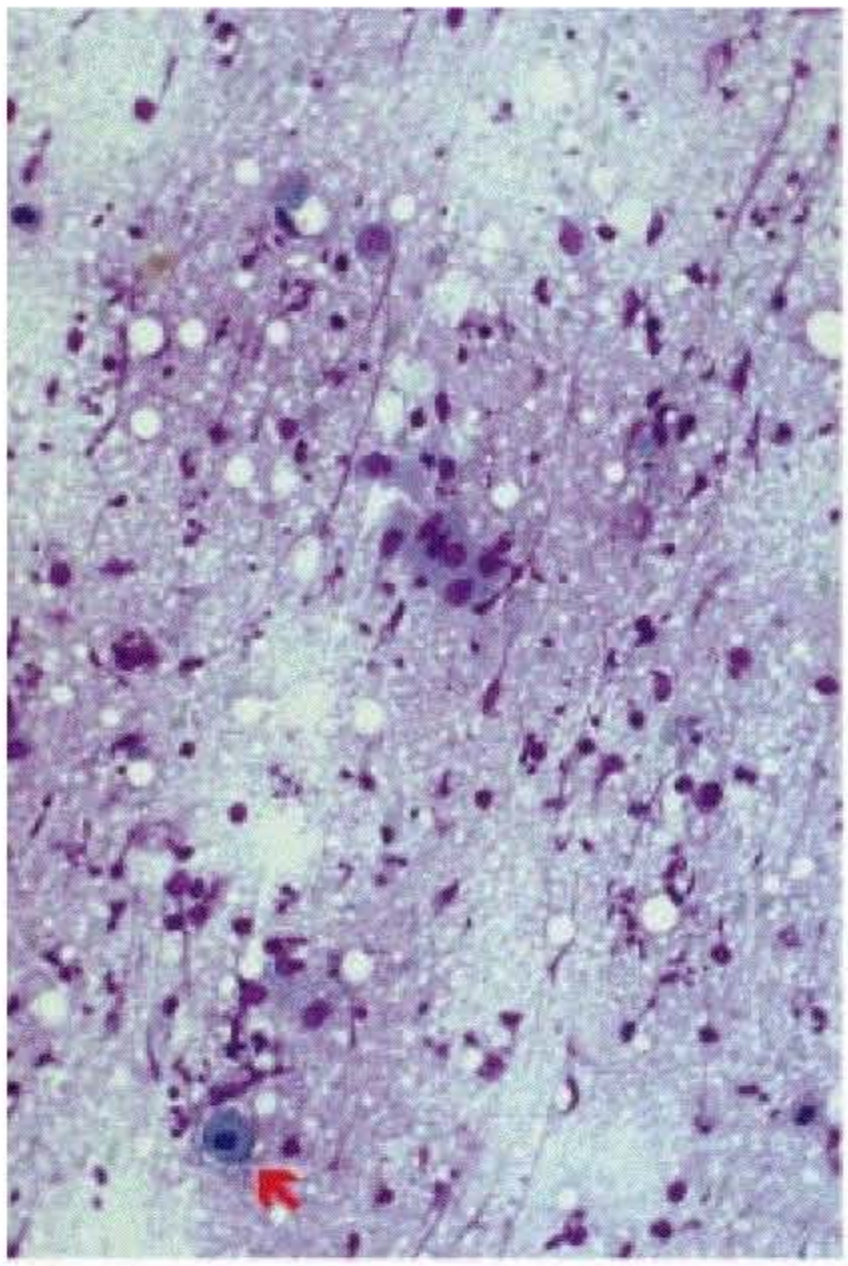

6.29

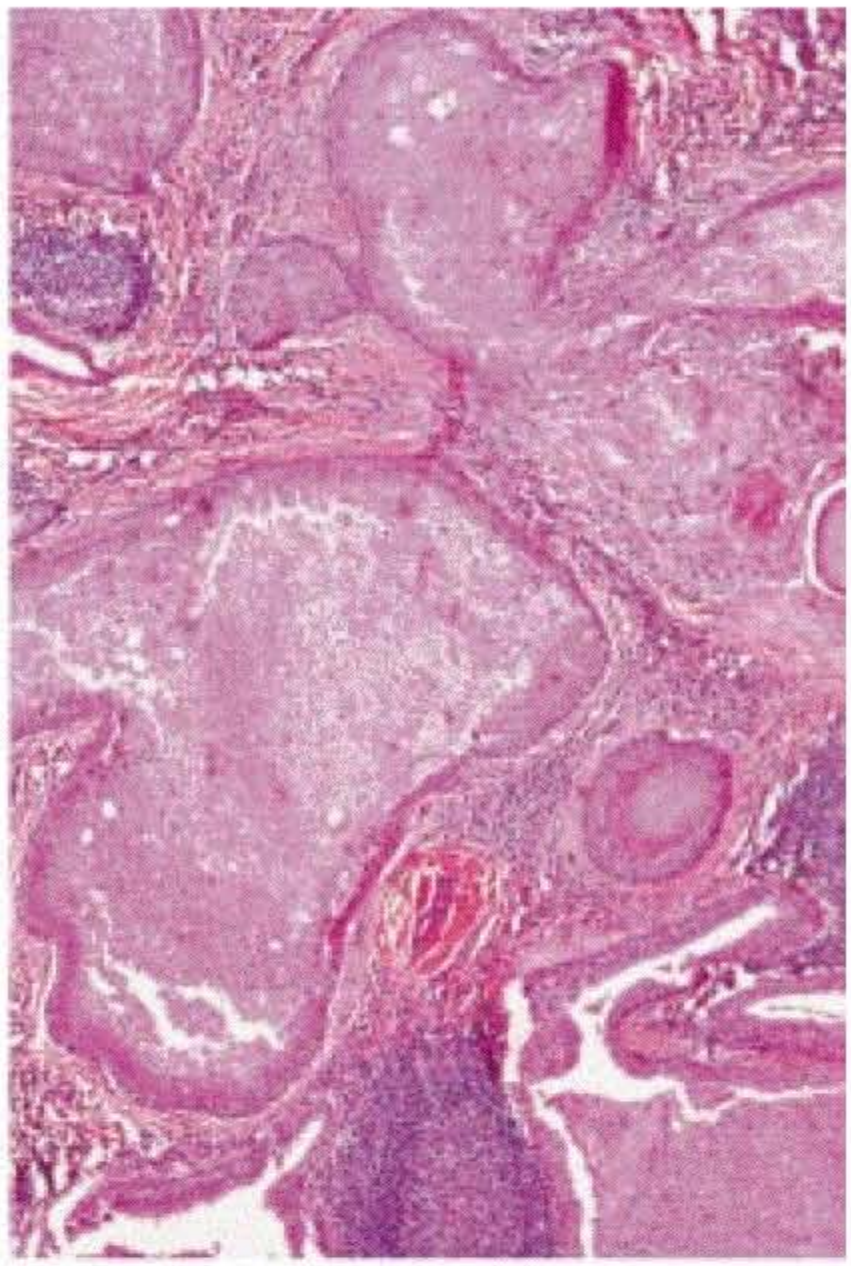

6.30

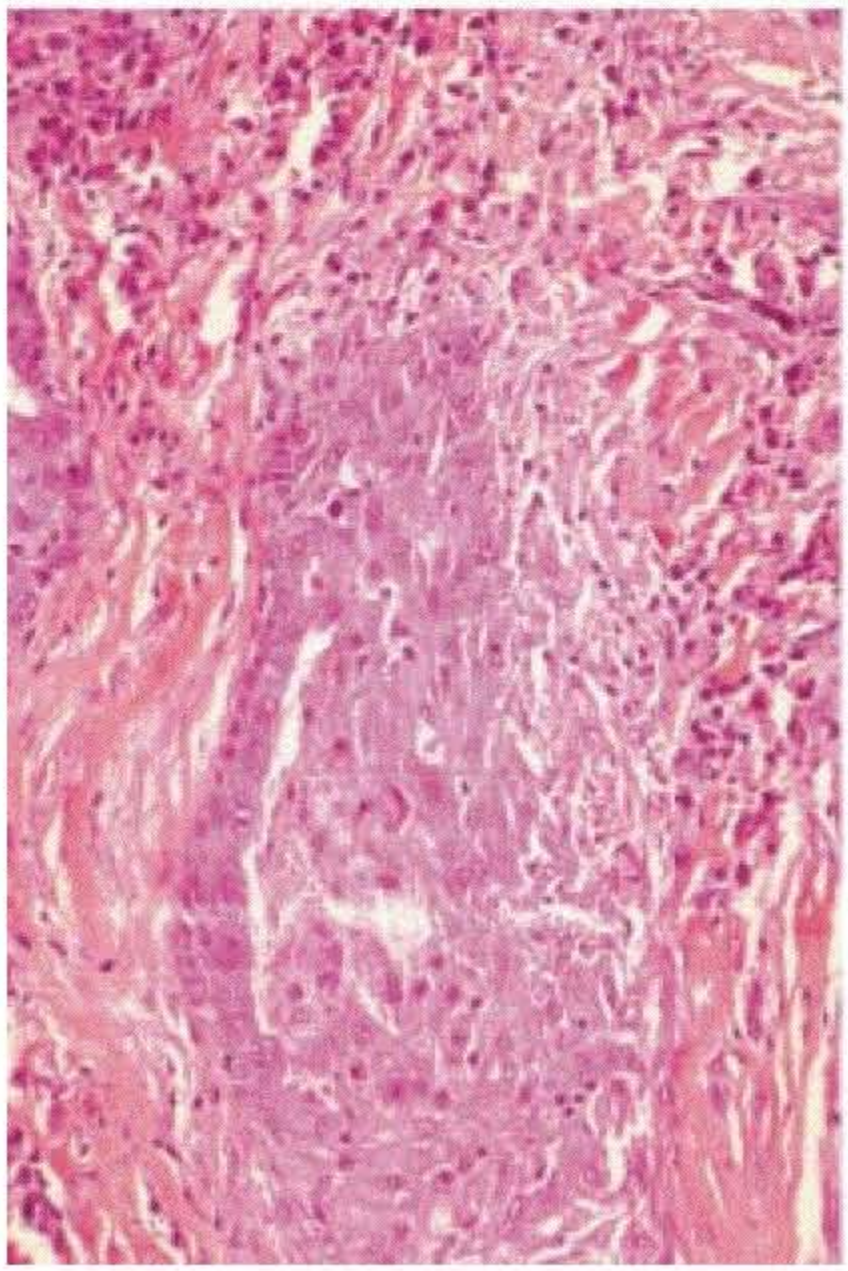

6.31

Fig. 6.29. Carcinoma ex Warthin's tumour. Isolated oncocytes and lymphocytes. Note the presence of malignant squamous cells (arrow) in a mucoid background. This case was misdiagnosed as low-grade mucoepidermoid carcinoma. MGG. ×128.

Fig. 6.30. Carcinoma ex Warthin's tumour. Histological section corresponding to figure 6.29 showing large cysts lined by squamous cells with a necrotic content. Underlying Warthin's tumour is seen at the periphery of this figure. HES. ×32.

Fig. 6.31. Carcinoma ex Warthin's tumour. Same histological section showing squamous cell carcinoma. HES. ×64.

The differential diagnosis between metaplastic Warthin's tumour and squamous cell carcinoma has been described as difficult, especially when squamous cells are numerous and when the background is necrotic [17, 56, 208, 213, 262]. Smears should always be examined for the presence of oncocytes, as they are absent in primary salivary squamous cell carcinoma (fig. 6.24, 6.27, 7.15, 7.16).

The differential diagnosis between Warthin's tumour with mucoid stroma and low-grade mucoepidermoid carcinoma may be difficult, especially when the smears are mucus-rich and necrotic (fig. 8.3, 8.4). Once again, the presence of isolated or clustered oncocytes considerably facilitates accurate tumour typing. Occasionally, oncocyte-like cells may be seen in certain mucoepidermoid carcinomas, but characteristic mucoid background and malignant squamous cells are also present, easily confirming the diagnosis of carcinoma [196].

Intraparotid metastasis from squamous cell carcinoma may be rapidly excluded by clinical evidence of head and neck squamous cell carcinoma of the skin or possibly the mucosa. Smears from metastatic squamous cell carcinoma show numerous malignant cells, whereas squamous cells in Warthin's tumour are rare and present no criteria of malignancy.

6.2.1.5.3. Warthin's Tumour vs. Acinic Cell Carcinoma. Moderately and poorly differentiated acinic cell carcinomas may contain cells resembling oncocytes (fig. 8.17) [193]. Acinic cell carcinomas may also contain lymphocytic stroma (fig. 8.14). The lack of finely granular acinar cells and the presence of necrosis and mast cells are in favour of Warthin's tumour.

6.2.1.5.4. Warthin's Tumour vs. Carcinoma ex Warthin's Tumour. Smears containing squamous cells (associated squamous metaplasia post fine-needle sampling) or mucoid material may lead to an incorrect diagnosis of malignant Warthin's tumour, an exceedingly rare entity, with only 24 cases reported in the literature (fig. 6.29–31) [255].

Warthin's Tumour

In favour of the diagnosis

Oncocytes, lymphocytes, necrosis, mast cells

Difficulties

Squamous cells, mucoid background, extensive necrosis

Against the diagnosis

Intermediate cells, malignant squamous cells, mucus-secreting cells

6.2.2. Oncocytoma (Oncocytic Adenoma) and Oncocytosis

6.2.2.1. General

Oncocytomas are very rare, representing around 1% of all salivary gland tumours. Eighty percent of tumours arise in the parotid gland. Oncocytomas are mainly seen in patients in the seventh and eighth decades of life, but paediatric cases have also been reported [90]. Clinical behaviour is typically benign with a low recurrence rate and malignant transformation is rare [99]. Oncocytosis is cytologically identical to oncocytoma.

6.2.2.2. Histopathology

Macroscopically, these tumours are off-white and are often well encapsulated. Clear-cut distinction of oncocytic adenomatous hyperplasia of the parotid gland (oncocytosis) from multinodular oncocytoma (true adenoma) is not always possible, as the histological features of these two lesions overlap. Cystic spaces are occasionally seen.

Oncocytic tumour cells are large, well defined, with a polyhedral or rounded shape, and granular cytoplasm. Nuclei are small and regular, with few mitotic figures. Clear cells with a certain degree of atypia are variants of oncocytes [89].

6.2.2.3. Cytopathology

Cytological smears are characteristic [261, 263, 277]. Oncocytes are isolated or cohesive in irregular clusters. The nucleus is large, often with prominent nucleoli and mild atypia. The cytoplasm is large and finely granular (fig. 6.32–6.34). Mitotic figures are not seen. Some oncocytomas contain a small number of clear cells. Cytological smears in clear cell oncocytoma are dominated by large polyhedral cells with abundant clear or microvacuolated cytoplasm.

6.2.2.4. Diagnostic Accuracy

Cytological reports of oncocytoma are rare and limited. A review of large series, including our own, revealed 24 oncocytomas correlated with histology (table 6.6). The diagnostic accuracy was 92%. False-suspicious diagnoses were made in 2 cases because of morphological similarities with adenoid cystic carcinoma in 1 case, and aberrant PSA immunohistochemical positivity in the other.

6.2.2.5. Differential Diagnosis

The cytology of oncocytoma is characteristic, despite occasional cases showing moderate atypia and rare cells with clarified cytoplasm. A review of large series showed that oncocytoma was frequently misdiagnosed as Warthin's tumour.

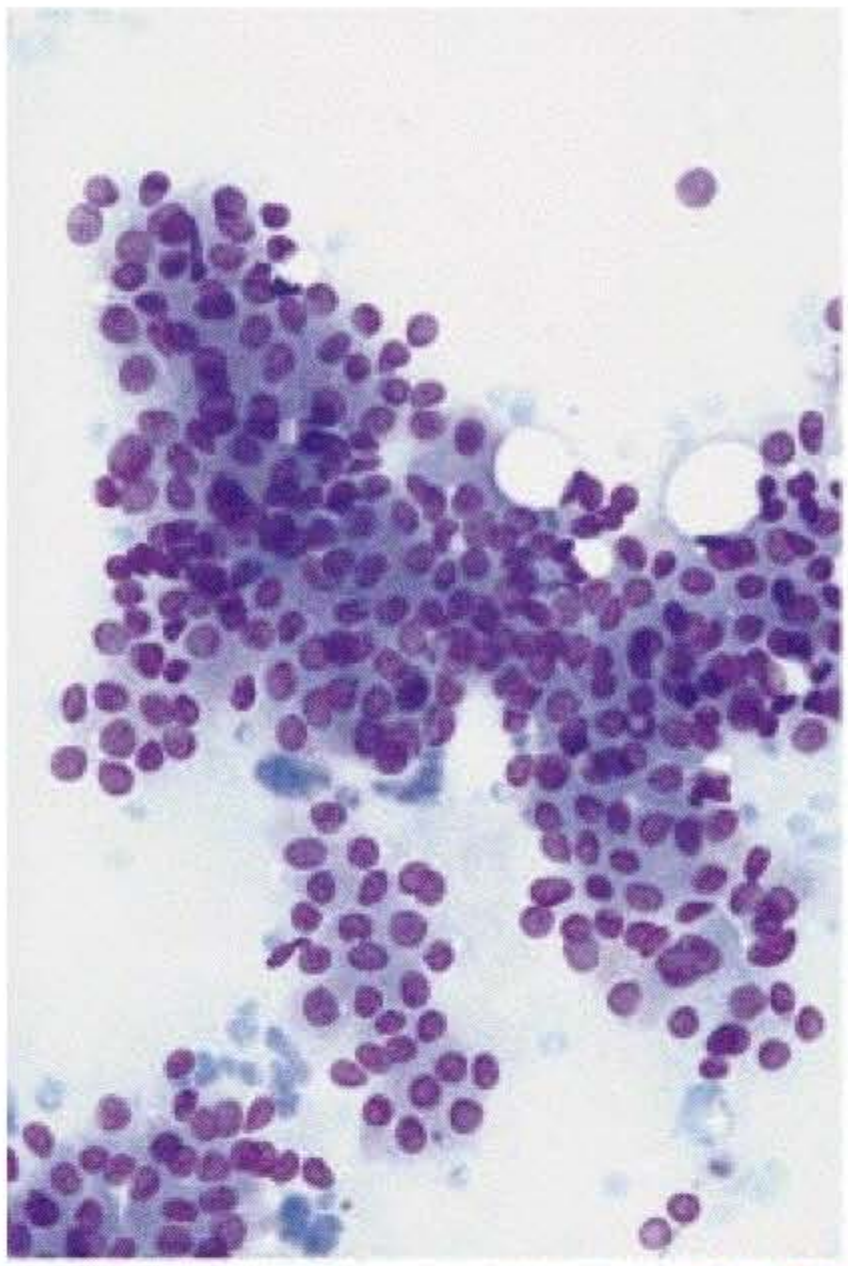

6.32

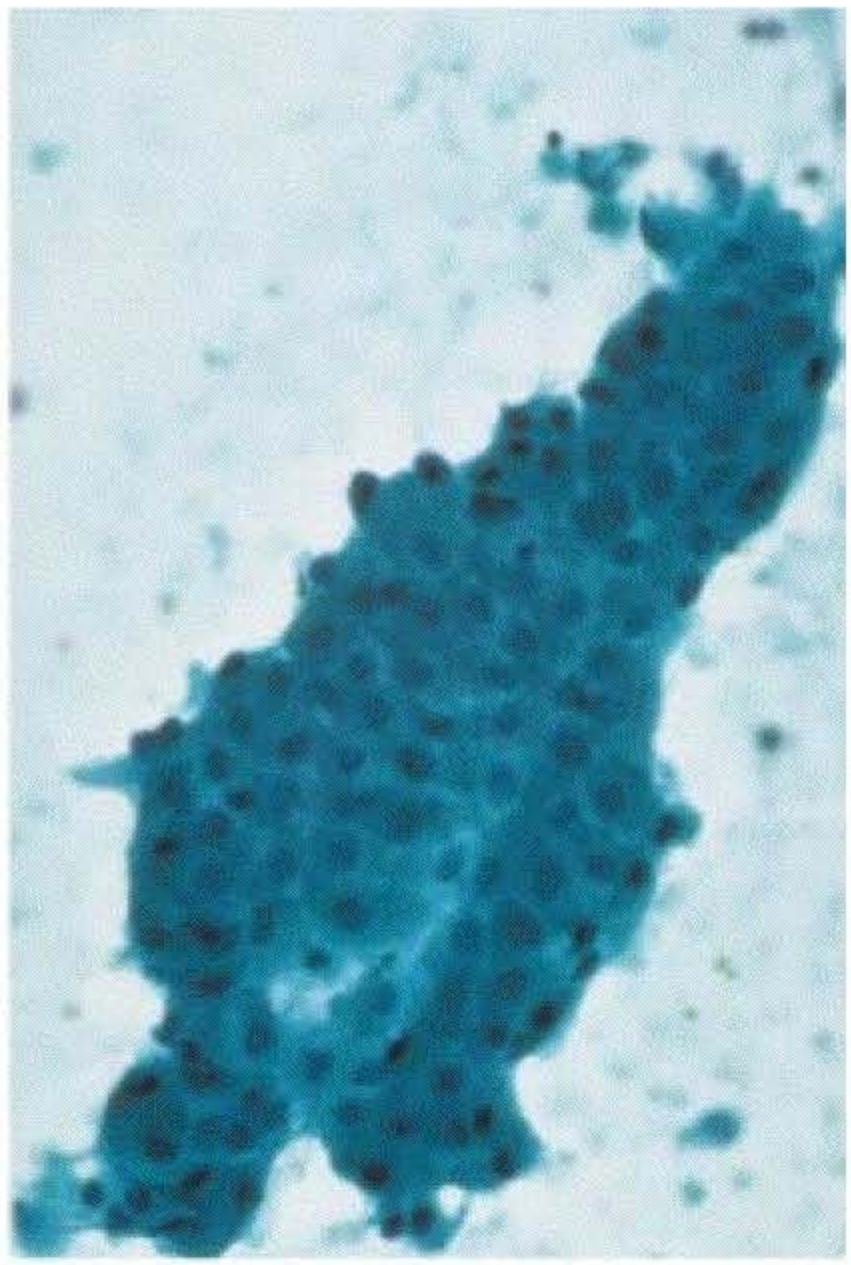

6.33

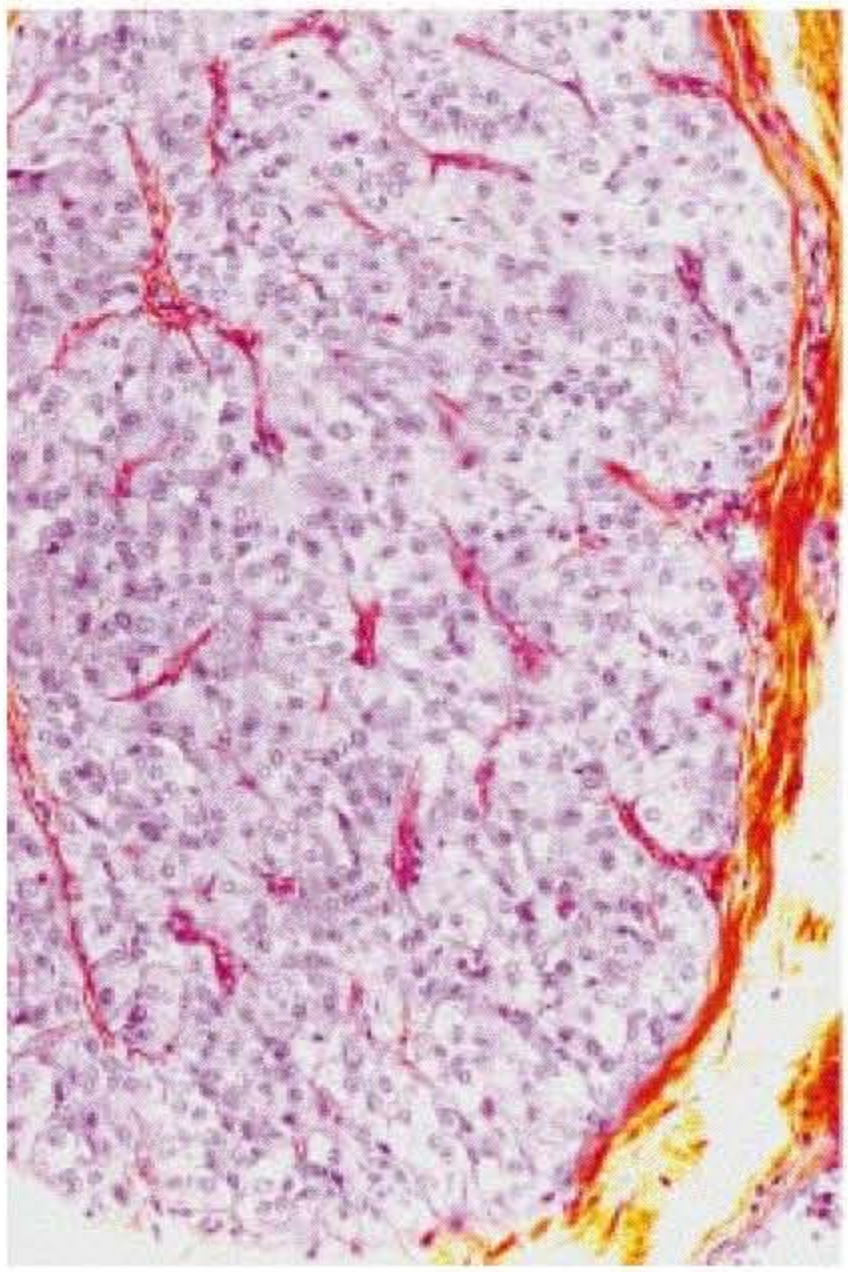

6.34

Fig. 6.32. Oncocytoma. A cluster of oncocytes showing cells with regular eccentric or central nuclei. Cytoplasm is abundant and slightly basophilic. Lymphocytes and mast cells are absent. MGG. ×128.
Fig. 6.33. Oncocytoma. Papanicolaou. ×128.
Fig. 6.34. Oncocytoma. Histological section corresponding to figures 6.33 and 6.34. Note the well-delimited tumour margins. HES. ×32.

Table 6.6. Correlation between cytology and histology in oncocytomas

Author [ref.]	Number	Benign	Suspicious and false-positive	Unsatisfactory
Mavec et al. [241]	3	3	0	0
Persson, Zettergren [270]	1	1	0	0
Qizilbash et al. [277]	2	2	0	0
O'Dwyer et al. [261]	3	3	0	0
Weinberger et al. [341]	1	1	0	0
Zurrida et al. [350]	1	1	0	0
Orell [263]	3	3	0	0
Cajulis et al. [41]	1	0	1	0
Boccato et al. [29]	1	1	0	0
Al-Khafaji et al. [8]	2	2	0	0
Holmes et al. [157]	1	0	1	0
Our series	5	5	0	0
Total	24	22 (92)	2 (8)	0

Statistics from the literature. % in parentheses.

6.2.2.5.1. Oncocytoma vs. Warthin's Tumour. The failure to distinguish between these two entities has no clinical consequences. Smears from Warthin's tumour yield necrotic-like background and lymphocytes. However, mast cells are frequently seen within oncocytic clusters. It has been suggested that oncocytoma shows three-dimensional clusters of oncocytes, while Warthin's tumour presents two-dimensional clusters of oncocytes (fig. 6.32).

6.2.2.5.2. Oncocytoma vs. Mucoepidermoid Carcinoma with Oncocytic Metaplasia. Mucoepidermoid carcinoma may occasionally contain areas of oncocytic metaplasia and clarified cells. The mucoid background, intermediate and mucus-secreting cells indicate the correct diagnosis.

6.2.2.5.3. Oncocytoma vs. Epithelial-Myoepithelial Carcinoma. The marked variation in nuclear size and prominent nucleoli has been reported [215] to be a diagnostic problem in the distinction from epithelial-myoepithelial carcinoma, but recognition of the smooth nuclear contours and the interspersed population of typical oncocytes leads to the correct diagnosis.

6.2.2.5.4. Oncocytoma vs. Acinic Cell Carcinoma. Acinic cell carcinomas may contain cells resembling oncocytes, but finely vacuolated acinar cells and numerous naked nuclei are also present (fig. 8.17) [193].

6.2.2.5.5. Oncocytoma vs. Malignant Oncocytoma. Malignant oncocytoma mimics oncocytoma, due to the lack of prominent atypia or necrosis. Numerous mitotic figures and single, large intracytoplasmic vacuoles, may be in favour of malignancy (fig. 7.39).

Oncocytoma

In favour of the diagnosis

Numerous isolated or clustered oncocytes

Difficulties

Clarified or vacuolated cells, mild nuclear atypia

Against the diagnosis

Lymphocytes, (pseudo)necrosis, numerous mitotic figures, chondromyxoid stroma, myoepithelial cells

6.3. Adenomas with Prominent Basaloid Cells: Basal Cell and Canalicular Adenomas

The terms 'basaloid cell adenoma', 'trabecular adenoma', 'tubular adenoma', 'canalicular adenoma', and 'monomorphic adenoma' have been used synonymously in the literature. Cytologically, we use the term 'basal cell adenoma' to describe both canalicular and basal cell adenomas.

6.3.1. General

Canalicular adenoma is a rare tumour, clinically localized in the upper lip and oral cavity in patients during the seventh decade. Only exceptional cases have been located in major glands [90, 107, 260].

Basal cell adenoma represents approximately 2–4% of all benign salivary gland tumours and are mainly located in the major salivary glands [19, 90, 254]. The average age of diagnosis is 57.7 years. Malignant change into basal cell adenocarcinoma and adenoid cystic carcinoma has been reported [89, 226].

Fig. 6.35. Basal cell adenoma. Regular, basaloid cells arranged in a dark, three-dimensional cluster. Note the scant cytoplasm and peripheral palisading (arrow). MGG. ×128.

Fig. 6.36. Basal cell adenoma (solid subtype). Histological section corresponding to figure 6.35. HES. ×64.

Fig. 6.37. Canalicular adenoma of the lip. Pseudopapillary cluster of oval or spindle-shaped basaloid cells. Cytoplasm is scant. MGG. ×128.

Fig. 6.38. Canalicular adenoma. Histological section corresponding to figure 6.37. HES. ×64.

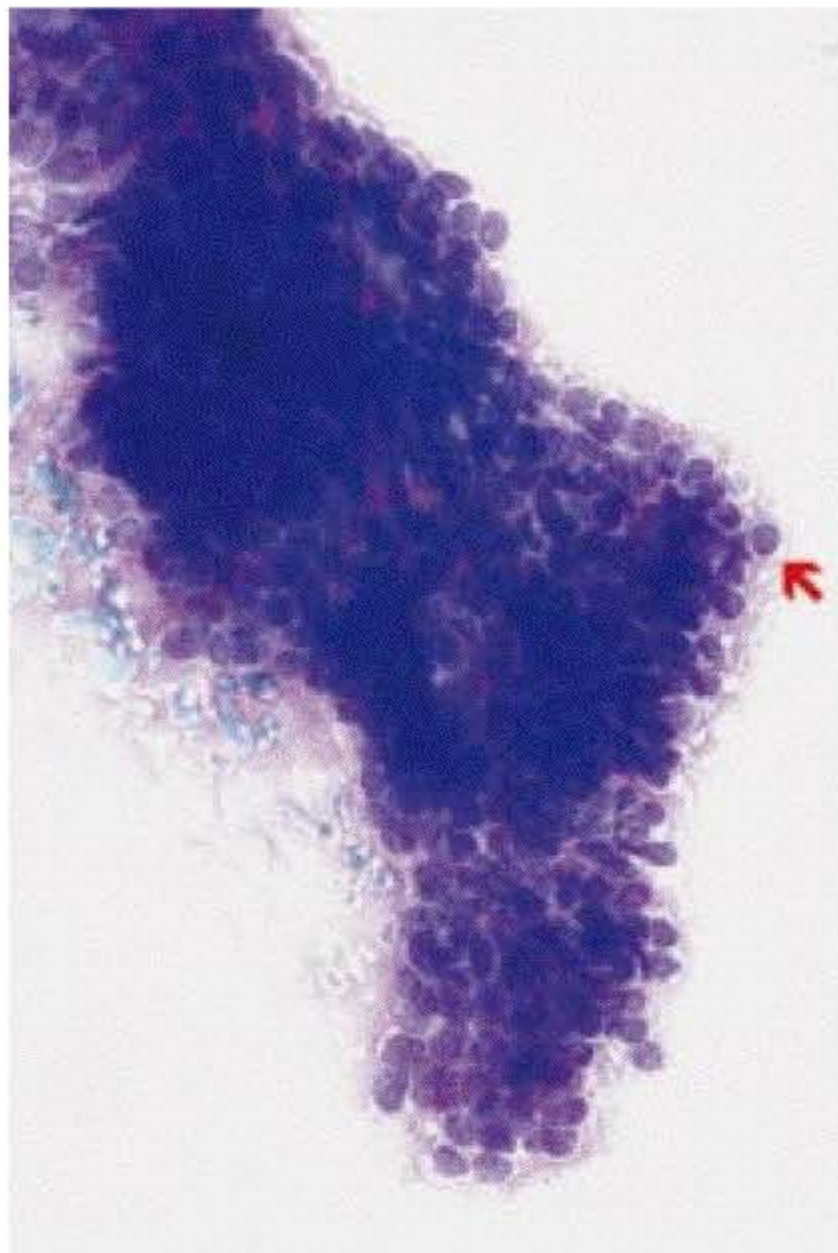

6.35

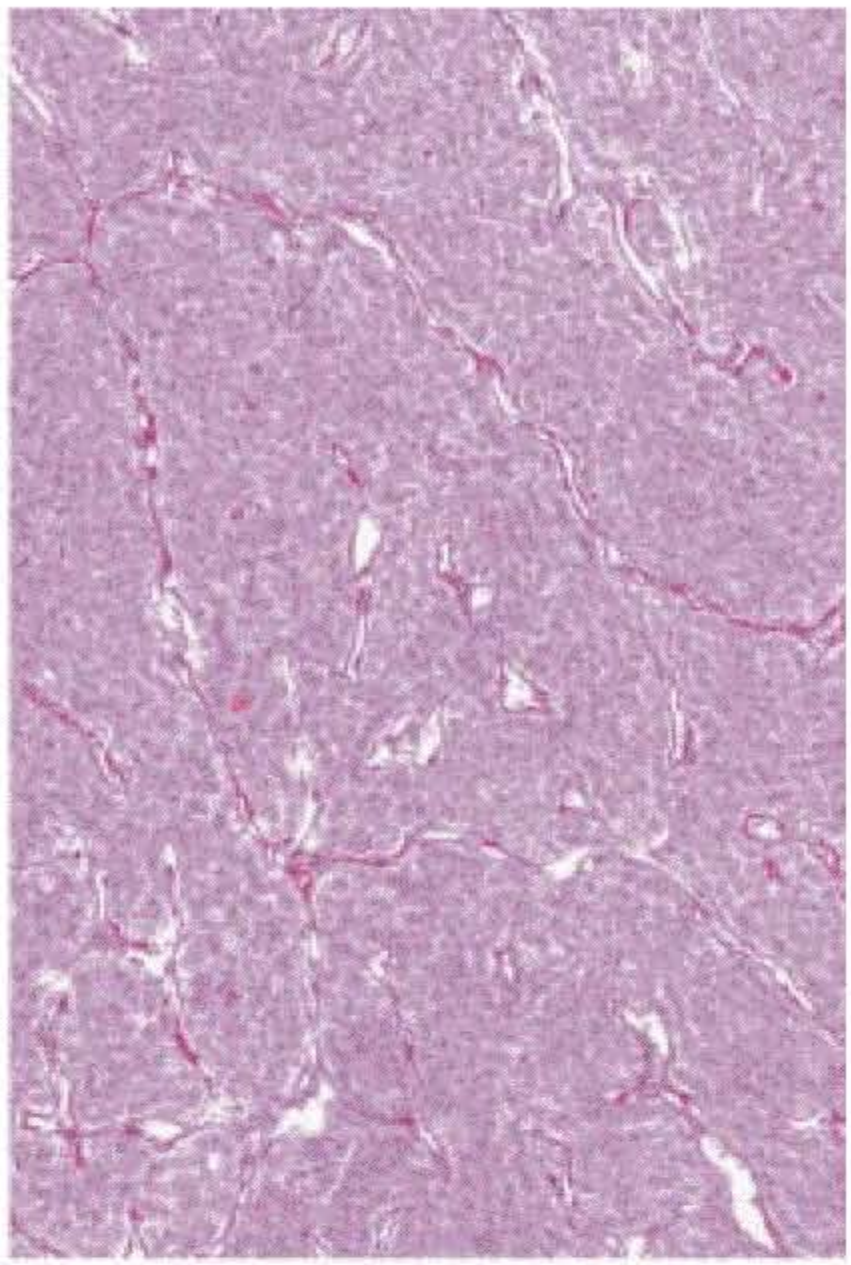

6.36

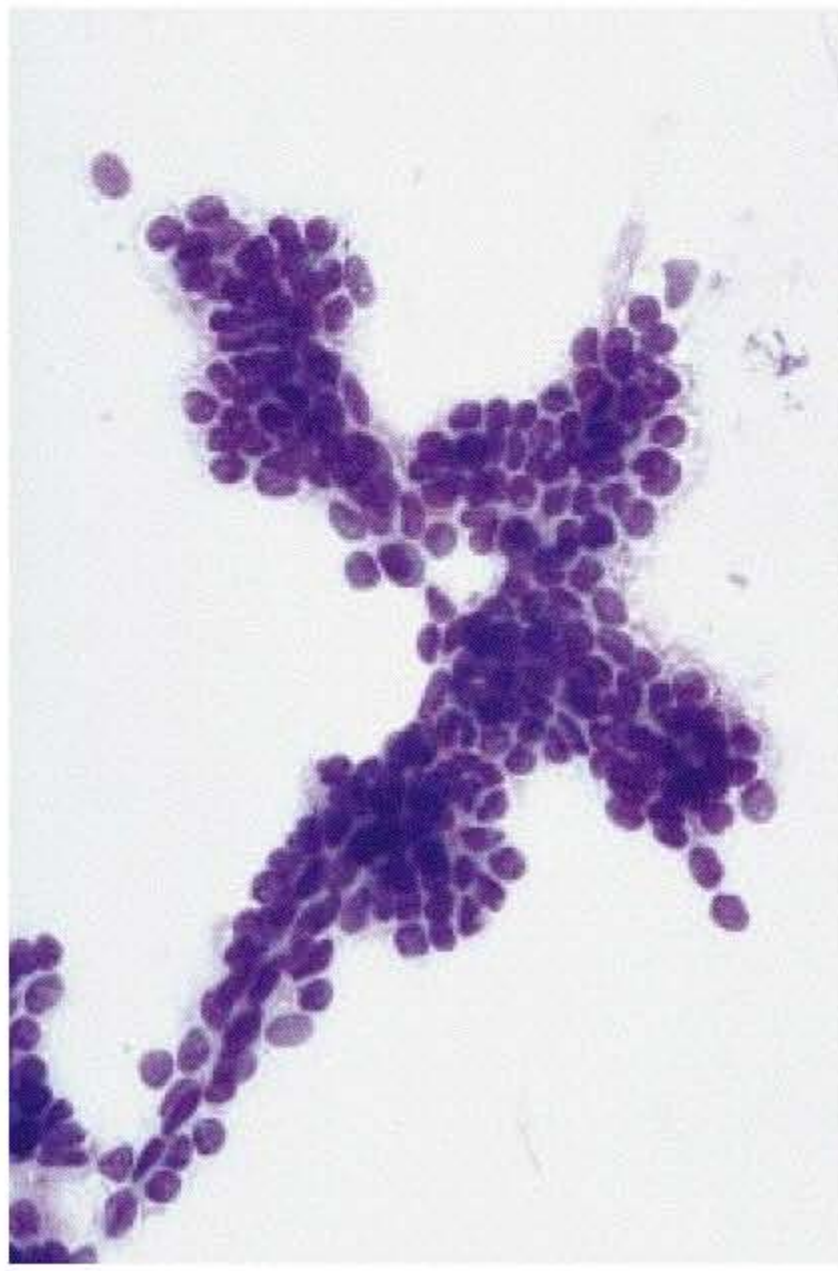

6.37

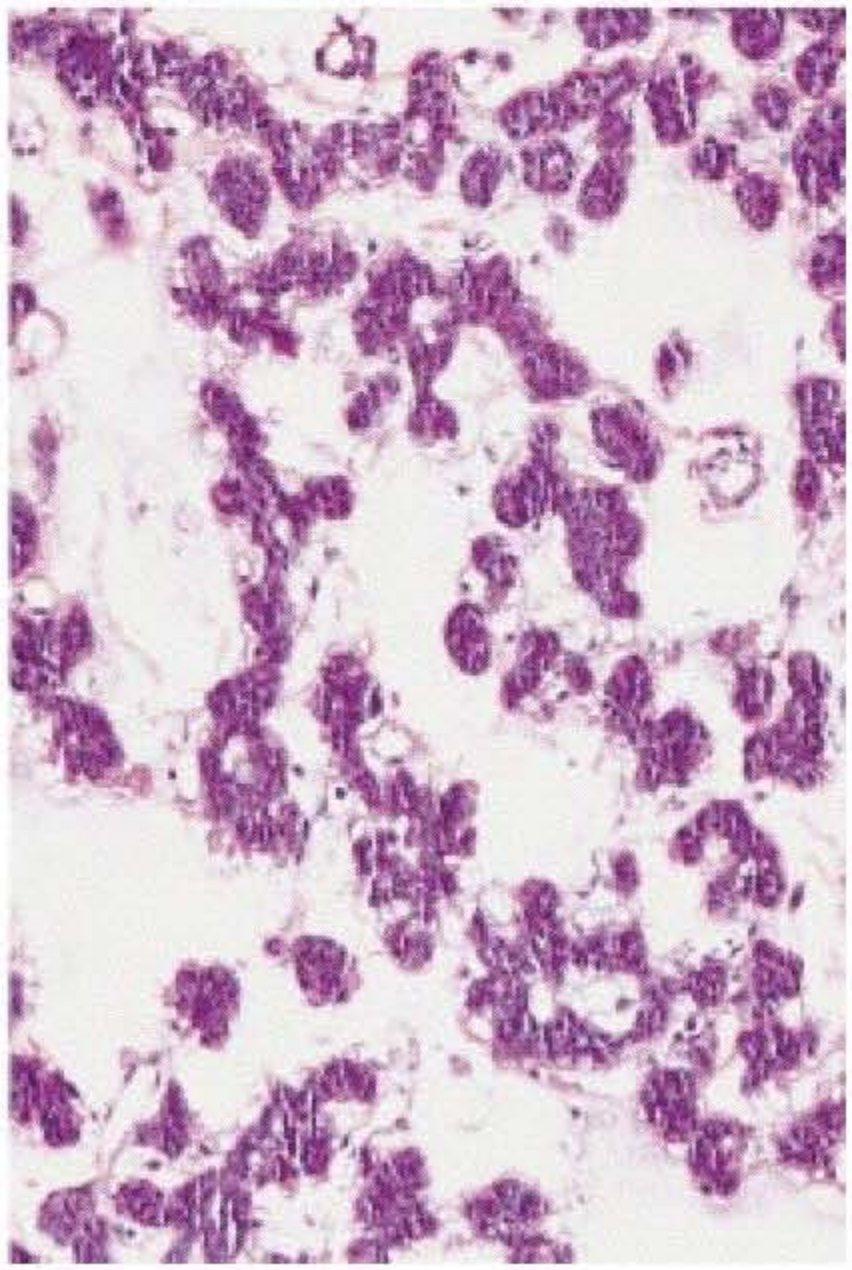

6.38

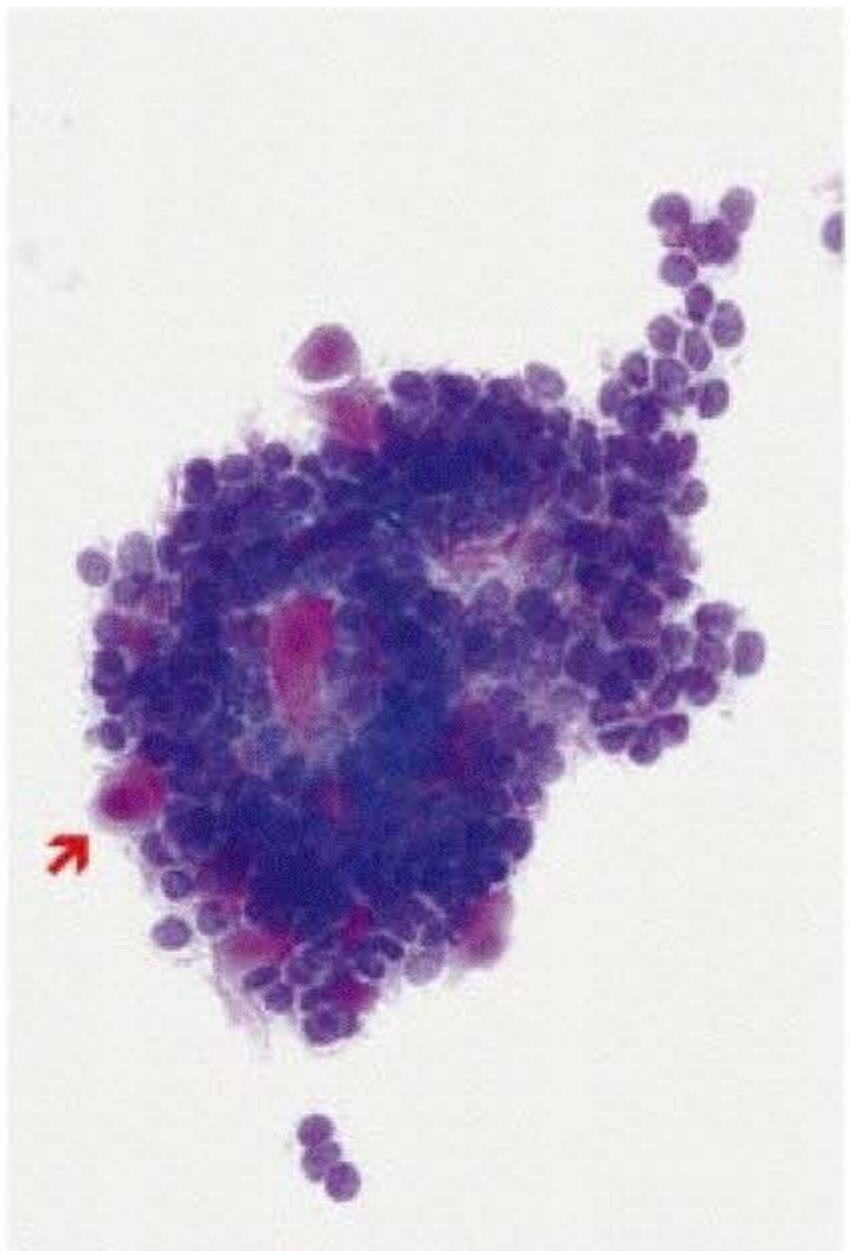

6.39

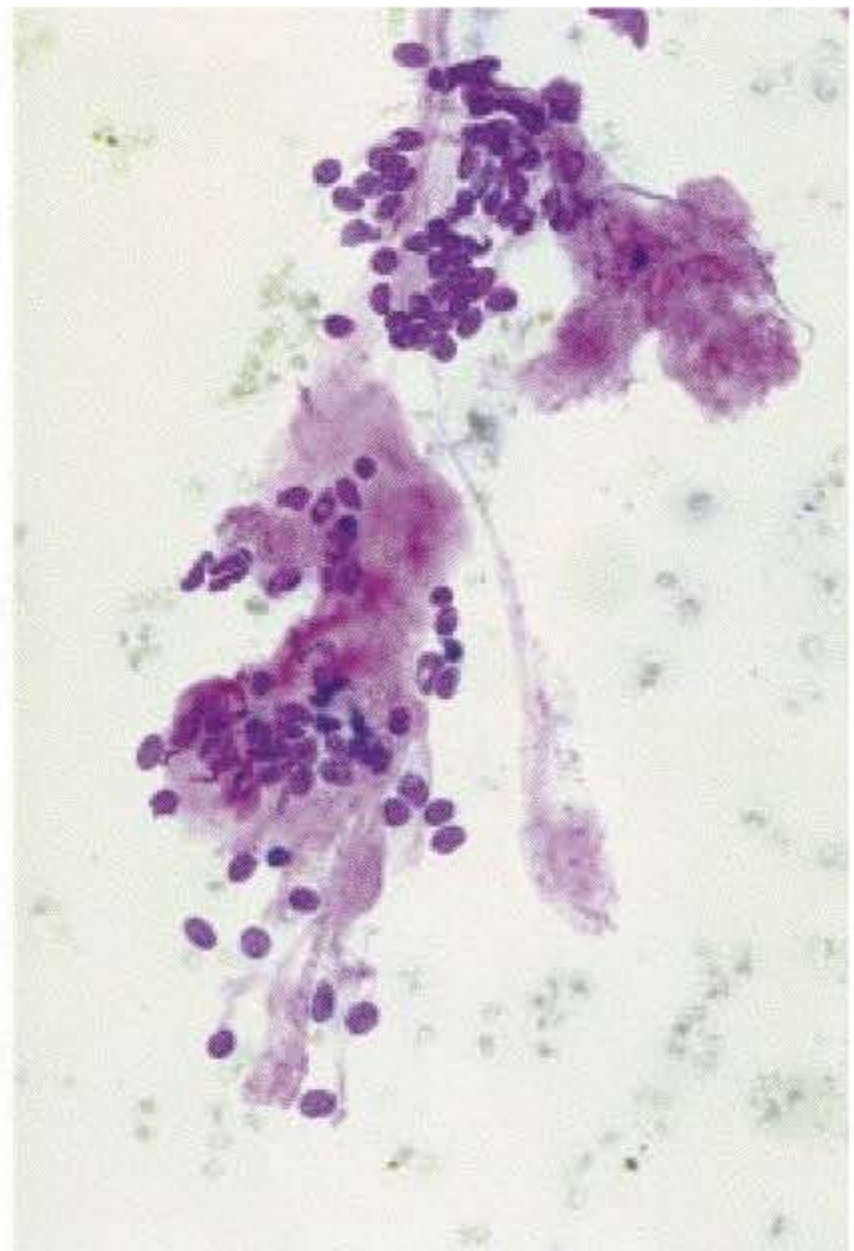

6.40

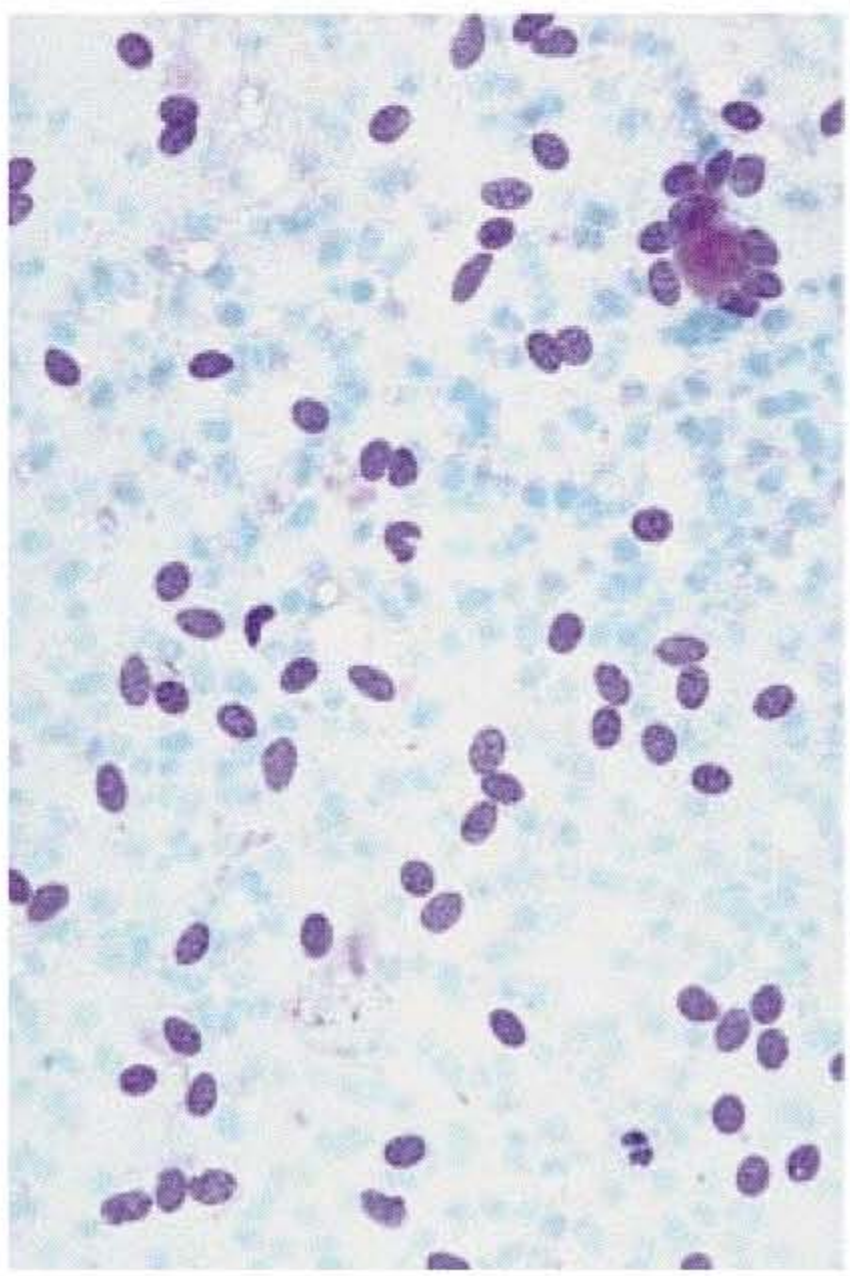

6.41

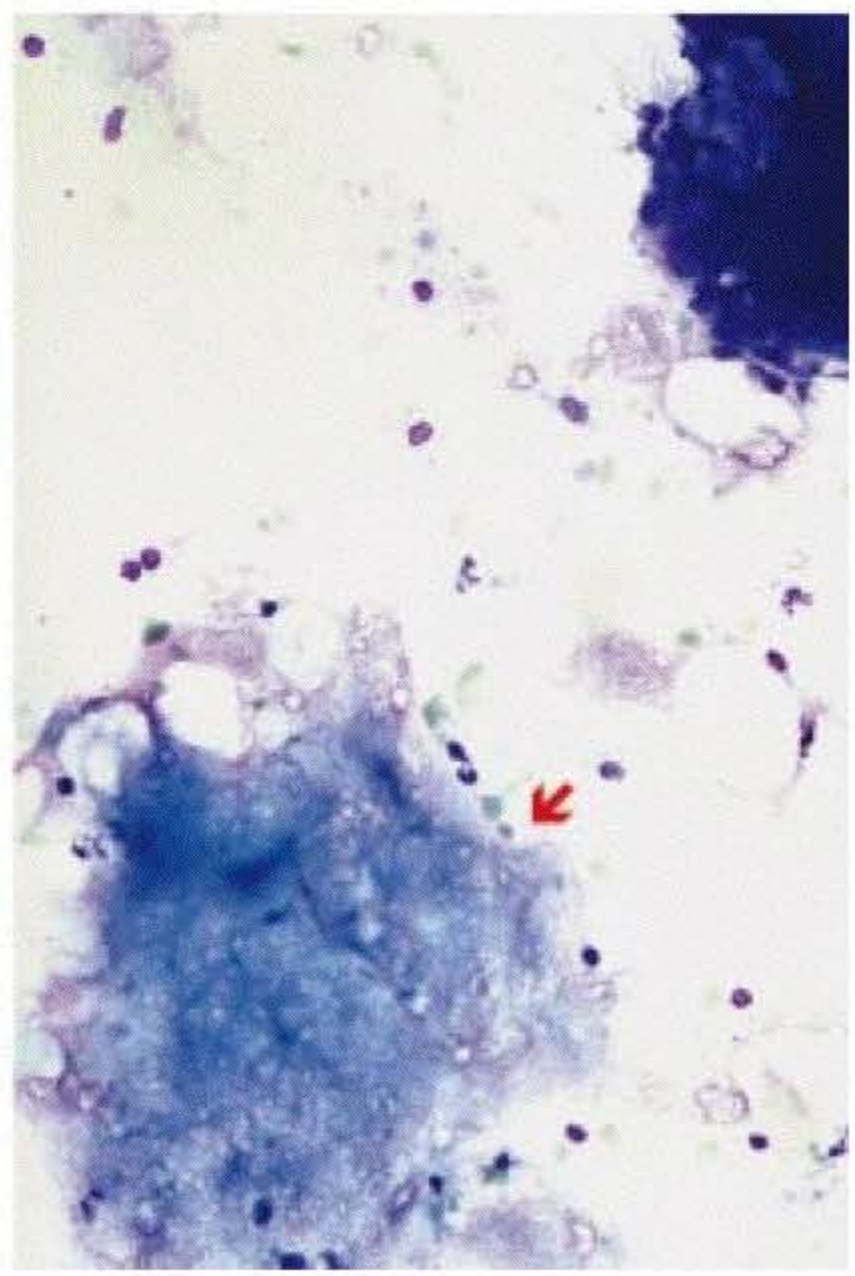

6.42

6.3.2. Histopathology

Canalicular adenoma is composed of isomorphic cells with moderate eosinophilic cytoplasm. Nuclei are basophilic and regular without atypia or mitotic activity. These cells are arranged in columns or cords with tubular spaces. Mucous cells or oncocytic differentiation is occasionally present [248]. Stroma is paucicellular and composed of sparse fibrillary elements with numerous vessels.

Basal cell adenomas are divided into four histological varieties: basal cell (solid), tubular, trabecular and papillary [254]. Keratin pearl formation is occasionally seen. Basal cells are columnar or cuboidal and arranged in tubular, trabecular or solid patterns with cystic spaces. The cytoplasm is scant and eosinophilic. Nuclei are regular, elongated without mitotic activity. The stroma is loose with a delicate vascular network. Basal cell adenoma is suggested to be a benign counterpart of adenoid cystic carcinoma and basal cell adenocarcinoma.

6.3.3. Cytopathology

Canalicular and basal cell adenomas are indistinguishable cytologically [161, 188, 223, 321]. Characteristic cytological features include monotonous and invariably isolated or cohesive small ovoid basal cells. Nuclei contain bland chromatin without nucleoli. Peripheral palisading and whorling are occasionally seen in some clusters (fig. 6.35–6.38). In some cases, cells are arranged in pseudopapillary formations adjacent to hyaline globules with an intensely eosinophilic appearance on MGG stain (fig. 6.39). Stroma, if present, is scant and fibrous (fig. 6.40). Chondromyxoid and myoepithelial cells with well-delimited cytoplasm are absent. Naked nuclei, keratin debris and squamous cells may occasionally be seen [188] (fig. 6.41, 6.42).

6.3.4. Diagnostic Accuracy

A total of 42 cases of cytologically diagnosed basal cell adenoma have been reported in the literature. False-positive and false-suspicious diagnoses accounted for 16.7% of cases, illustrating the difficulties in distinguishing between basal cell adenoma and adenoid cystic carcinoma (table 6.7).

Table 6.7. Correlation between cytology and histology of basal cell (and canalicular) adenoma

Author [ref.]	Number	Benign	Suspicious and false-positive	Unsatisfactory
Hood et al. [158]	2	0	2	0
Layfield [214]	1	0	1	0
Qizilbash et al. [277]	2	2	0	0
Stanley et al. [320]	2	1	1	0
Hruban et al. [161]	2	2	0	0
López, Ballestín [223]	1	1	0	0
Sparrow, Frost [314]	2	2	0	0
Zurrida et al. [358]	5	5	0	0
Orell [263]	5	3	2	0
Stanley et al. [321]	8	7	1	0
Gupta [142]	1	1	0	0
Klijanienko et al. [188]	11	11	0	0
Total	42	35 (83.3)	7 (16.7)	0

Statistics from the literature. % in parentheses.

6.3.5. Differential Diagnosis

Table 6.8 summarizes the differential diagnosis of basal cell adenoma. Basal cell adenomas should be differentiated from basal cell adenocarcinoma, poorly differentiated (solid) adenoid cystic carcinoma and morphologically similar tumours (epithelial-myoepithelial carcinoma, polymorphous low-grade adenocarcinoma, certain forms of cellular pleomorphic adenoma) and primary or metastatic basal cell carcinoma of the skin (table 6.8).

6.3.5.1. Basal Cell Adenoma vs. Basal Cell Adenocarcinoma

Basal cell adenocarcinoma constitutes a major differential diagnostic problem due to the cytomorphological similarity between the two entities (fig. 6.35, 6.37, 8.29, 8.33). Tumours with basaloid features exhibiting cytonuclear pleomorphism, large three-dimensional cellular clusters with glandular structures, mitotic figures and/or evidence of necrosis may be malignant (fig. 8.30–8.32). Moreover, adenocarcinoma may develop in pre-existing adenoma in approximately 25% of cases [299]. Malignancy therefore cannot be definitively excluded in a cytologically benign specimen without histological examination of these lesions.

Fig. 6.39. Basal cell adenoma. Large cluster of dark basaloid cells with a thin cytoplasmic rim. Stroma is scant and contains hyaline globules (arrow). MGG. ×128.

Fig. 6.40. Fibrous stroma in basal cell adenoma. Note the presence of naked nuclei. Corresponding histological sections showed membranous basal cell adenoma. MGG. ×128.

Fig. 6.41. Basal cell adenoma. Area showing numerous naked nuclei. MGG. ×128.

Fig. 6.42. Basal cell adenoma with squamous metaplasia (arrow). MGG. ×128.

Table 6.8. Quantitative differential diagnosis of basal cell adenoma

Component	Basal cell adenoma	Basal cell adenocarcinoma	Adenoid cystic carcinoma	Cellular pleomorphic adenoma
Cells				
Plasmacytoid	–	–	–	++
Basal	++	++	+/–	–
Squamous	+	+/–	+/–	+/–
Naked nuclei	++	+/–	++	–
Peripheral palisading	+/–	+/–	–	–
Stroma				
Chondromyxoid	–	–	–	+
Globules	+/–	+/–	++	+/–
Finger-like structures	–	–	++	–
Mucoid	+/–	–	–	+/–

++ = common; + = rare; +/– = ocasionally seen; – = absent.

6.3.5.2. Basal Cell Adenoma vs. Adenoid Cystic Carcinoma

Difficulties of differential diagnosis are encountered with poorly differentiated adenoid cystic carcinoma, epithelial-myoepithelial carcinoma, polymorphous low-grade adenocarcinoma and certain forms of cellular pleomorphic adenoma when smears contain hyaline globules intimately associated with basaloid clusters (fig. 6.6, 7.21). This problem has been largely discussed in the literature, reporting a high rate of false-positive or false-suspicious results [158, 188, 214, 263, 320, 321]. We look for tubular or finger-like structures rather than hyaline globules in favour of the diagnosis of adenoid cystic carcinoma (fig. 7.23–7.25, 7.27). However, in poorly differentiated adenoid cystic carcinoma, the high mitotic count, coarse chromatin and necrosis readily distinguish this high-grade carcinoma from basal cell adenoma. Similarly, Zajicek [353], Hood et al. [158] and Layfield [214] also indicated that stromal quantity, distribution and staining were most helpful in differentiating basal cell adenomas and adenoid cystic carcinoma.

6.3.5.3 Basal Cell Adenoma vs. Epithelial-Myoepithelial Carcinoma and Polymorphous Low-Grade Adenocarcinoma

The differential diagnosis also includes other carcinomas exhibiting hyaline globules. Epithelial-myoepithelial and polymorphous low-grade carcinomas usually show cytological patterns closely resembling adenoid cystic carcinoma (fig. 7.31, 8.24). Once again, the presence of three-dimensional clusters and peripheral palisading, the complete absence of myoepithelial cells, and clinical evidence of palatal tumour may be useful in the diagnosis [188, 200].

6.3.5.4. Basal Cell Adenoma vs. Cellular Pleomorphic Adenoma

The presence of eosinophilic connective tissue fragments and well-preserved cytoplasm in basal cells may lead to an incorrect diagnosis of pleomorphic adenoma. Identification of myoepithelial spindle-shaped or plasmacytoid myoepithelial cells with well-delimited, abundant cytoplasm, argues against the diagnosis of basal cell tumour. Inversely, the presence of numerous naked nuclei argues against the diagnosis of pleomorphic adenoma (fig. 6.41).

6.3.5.5. Basal Cell Adenoma vs. Metastatic Basal Cell Carcinoma

Basal cell adenomas may mimic a metastasis of a skin basal cell carcinoma to the parotid gland. The cytological diagnosis must be accompanied by careful clinical examination of the orbital area and skin.

Basal Cell and Canalicular Adenomas

In favour of the diagnosis

Basaloid cells with narrow cytoplasm, three-dimensional clusters, naked nuclei, bland chromatin; plasmacytoid myoepithelial cells are never seen

Difficulties

Squamous cells, hyaline globules

Against the diagnosis

Necrosis, mitotic figures, tubular and finger-like structures, coarse chromatin

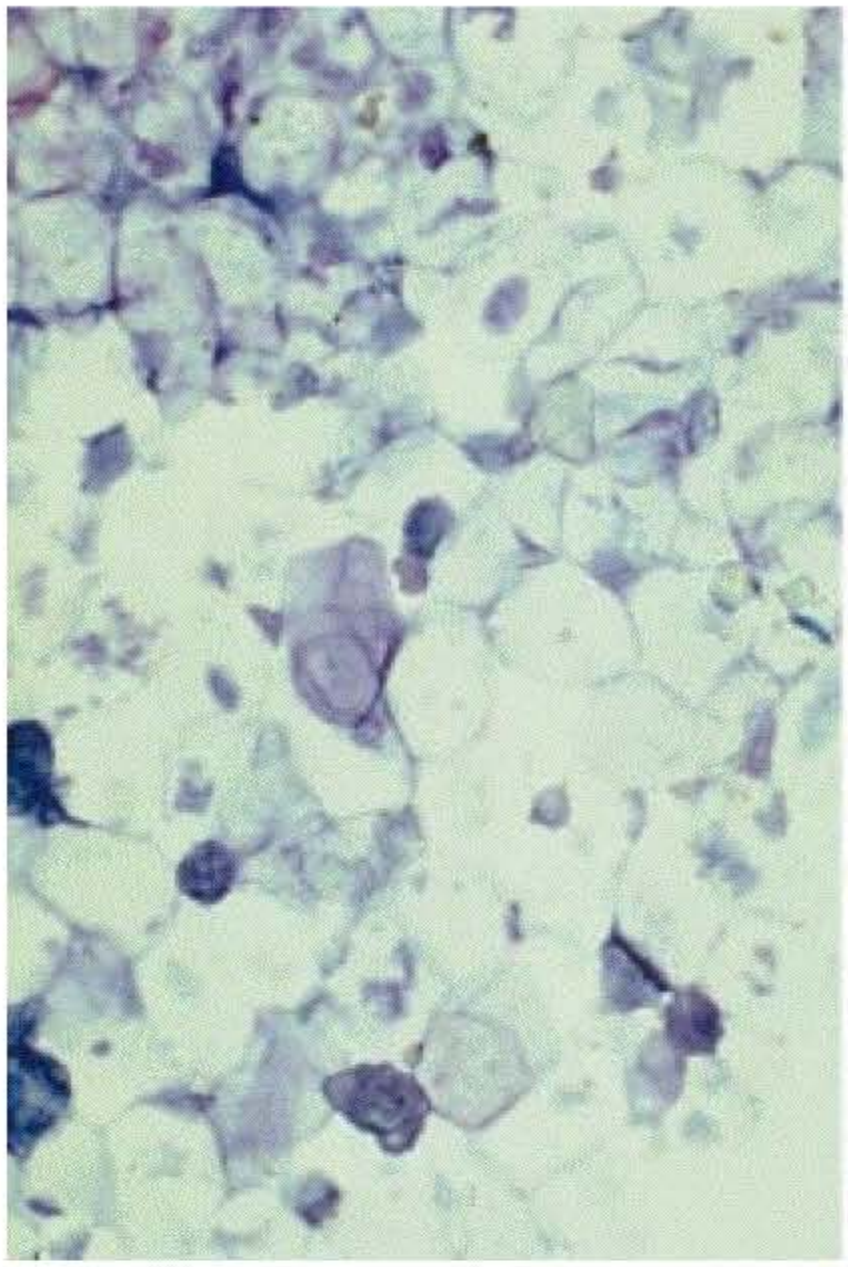

6.43

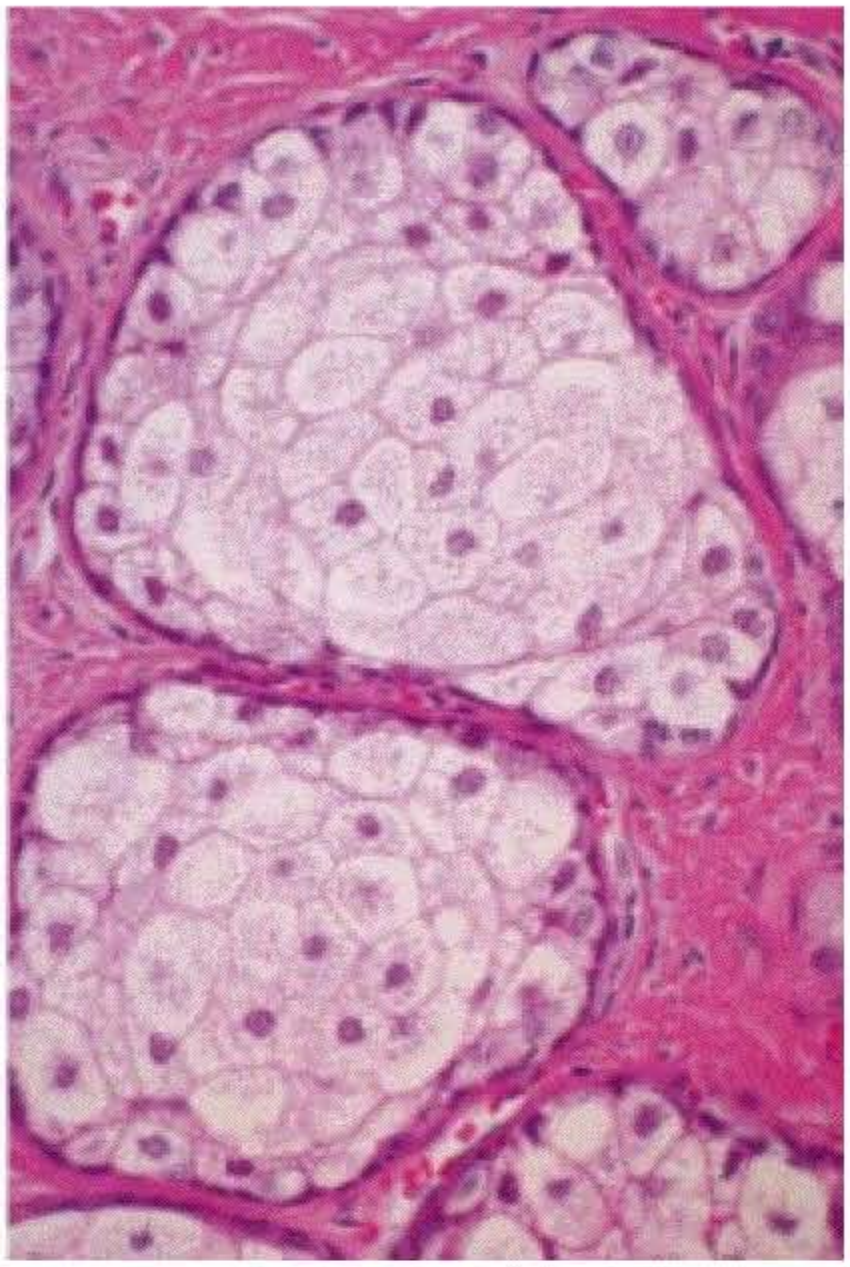

6.44

Fig. 6.43. Sebaceous adenoma composed of large, optically empty cells. MGG. E128.
Fig. 6.44. Histological section of sebaceous adenoma. HE. E128.

6.4. Adenomas with Prominent Sebaceous Cells

Sebaceous tumours of salivary gland are extremely rare, although sebaceous cells are relatively common in salivary parenchyma. Benign sebaceous tumours include sebaceous adenoma and sebaceous lymphadenoma.

6.4.1. Sebaceous Adenoma and Sebaceous Lymphadenoma

This is a benign solid or cystic lesion composed of sebaceous cells arranged in nests with minimal atypia. Oncocytic metaplasia, giant cell foreign body granuloma, and dense lymphoid stroma may be seen [132, 135].

Only 3 cases of sebaceous adenoma have been studied cytologically [82, 353] and another case has been observed at the Institut Curie. The smears described by Zajicek [353] were composed of large cells with small and eccentrically located nuclei. The cytoplasm was finely granular and certain cells were vacuolated. The case analysed by Derias et al. [82] was composed of clusters of large cells with foamy cytoplasm. The cytoplasm was suggestive of sebaceous cells. Atypia and mitotic figures were not seen. Our case of sebaceous adenoma was composed of large, optically empty cells with a histiocyte-like morphology and small hyperchromatic nuclei (fig. 6.43, 6.44). These cells resemble sebaceous cells from epidermoid cysts.

Sebaceous adenoma may be differentiated from sebaceous carcinoma, which shows high-grade malignant cells (fig. 7.41).

Sebaceous cells may also be found in a variety of salivary tumours: pleomorphic adenomas, Warthin's tumours, mucoepidermoid carcinomas and oncocytomas [131].

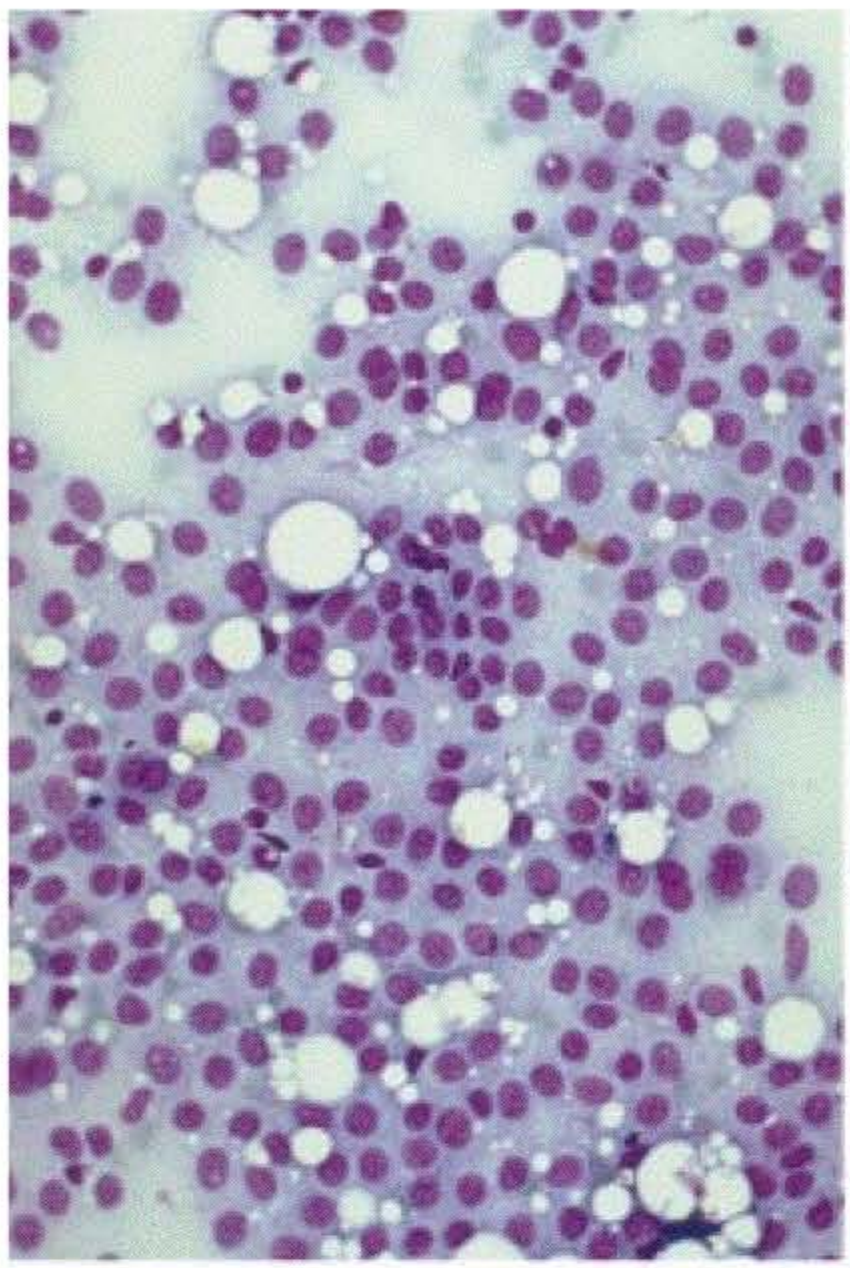

6.45

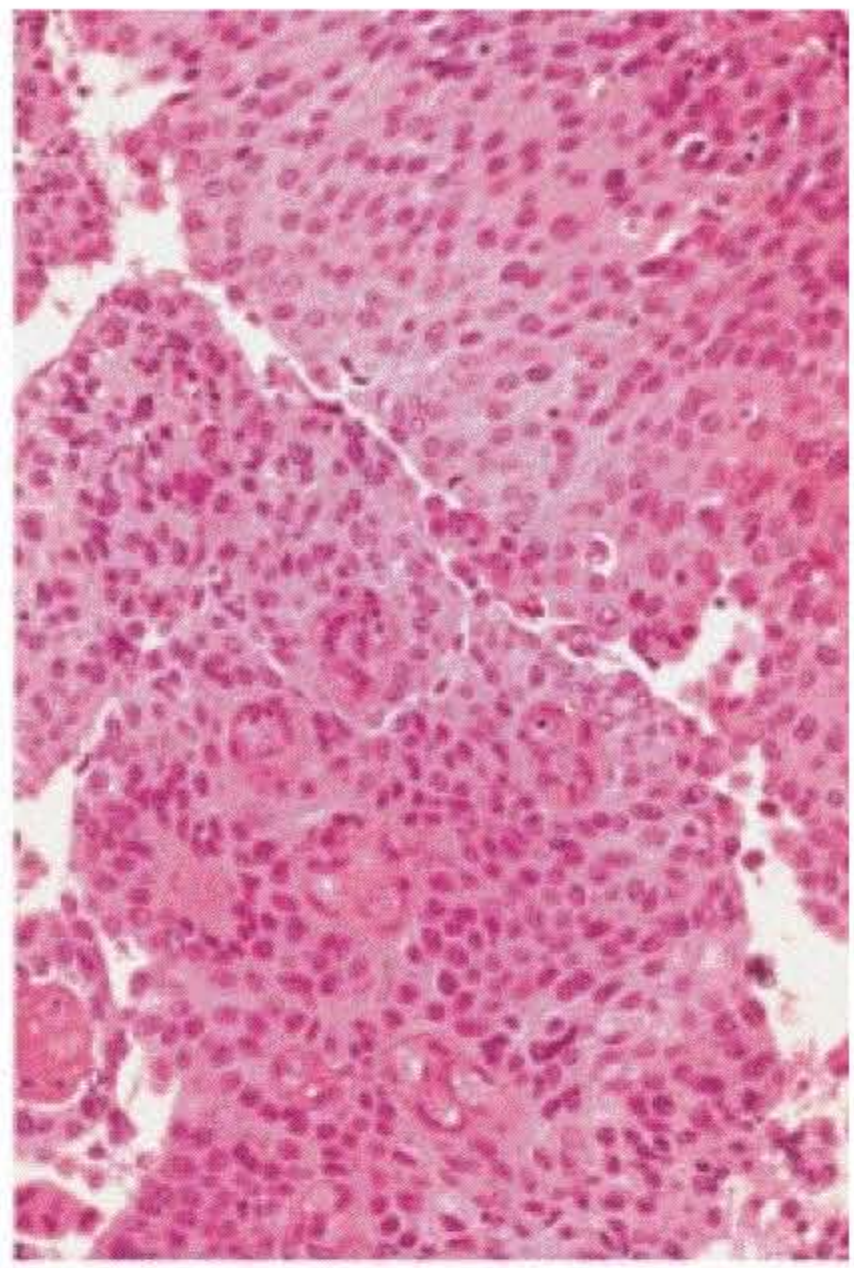

6.46

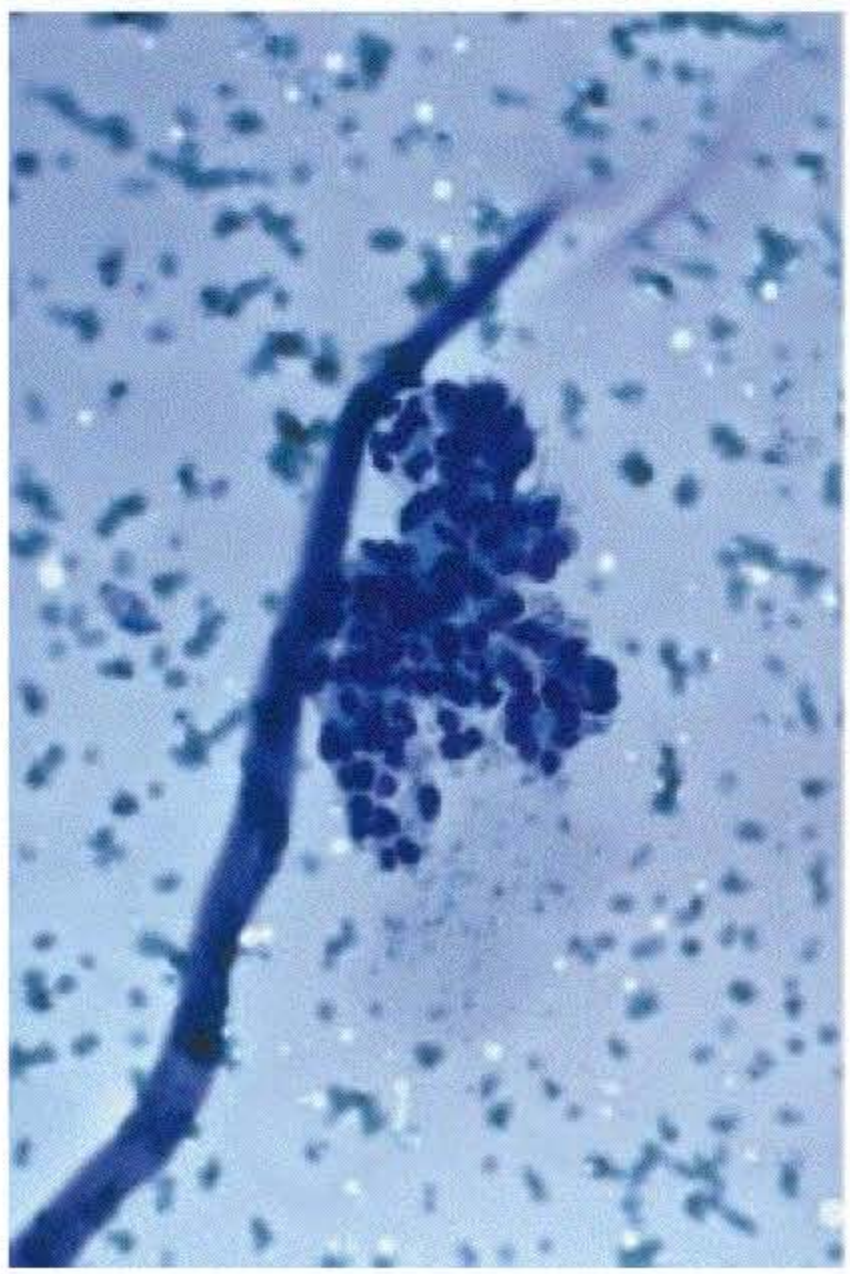

6.47

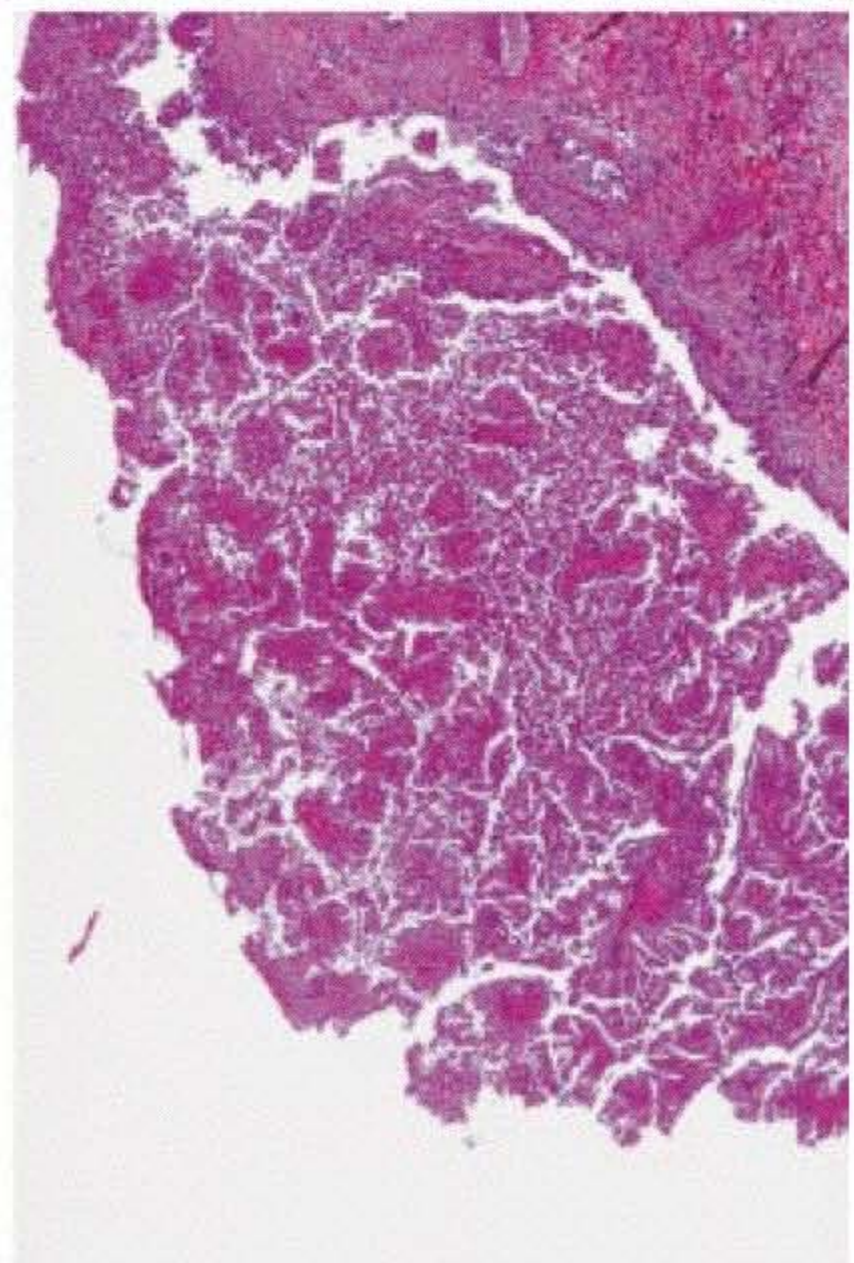

6.48

Sebaceous Adenoma

In favour of the diagnosis

Sebaceous cells, lymphocytes

Difficulties

Histiocytic-like cells

Against the diagnosis

Atypical cells

6.5. Papillary and Cystic Adenomas

Benign papillary tumours, other than Warthin's tumour, are extremely rare, with characteristic varying morphology allowing the distinction of three types: inverted ductal papilloma, intraductal papilloma and sialadenoma papilliferum. No cytological reports of these lesions have been described in the literature.

6.5.1. Ductal Papilloma

6.5.1.1. Inverted Ductal Papilloma

Only 15 inverted ductal papillomas arising in the minor salivary glands (lips) have been reported in the literature [89, 90]. Histologically, tumours are well circumscribed, with no features of infiltration. They consist of a papillary proliferation of basal or squamous cells. Interspersed goblet cells may be seen. The distinction between salivary inverted ductal papilloma and other papillomas of sinonasal tract is important, because the latter may undergo malignant transformation. Inverted ductal papilloma is generally easily distinguished from mucoepidermoid carcinoma, as inverted papillary adenoma lacks polycystic and infiltrating proliferation.

We have seen only one example of inverted ductal papilloma, in which the tumour was composed of regular epithelial cells with an abundant and clear basophilic cytoplasm and a central nucleus. Atypia, mitotic figures and necrosis were absent. A diagnosis of metastasis of low-grade urothelial carcinoma was suggested (fig. 6.45, 6.46). Inverted ductal papilloma may need to be differentiated from plasmacytoid myoepithelioma, in which the nuclei are situated peripherally (fig. 6.20).

Fig. 6.45. Inverted ductal papilloma. Regular epithelial cells with centrally sited nuclei. Atypia, mitotic figures and necrosis are absent. Cytoplasm is abundant and clear to basophilic. MGG. E128.

Fig. 6.46. Inverted ductal papilloma. Histological section corresponding to figure 6.45 showing a papillary tumour composed of epidermoid-like cells. The peripheral limits of this tumour were well demarcated (not shown). HES. E64.

Fig. 6.47. Intraductal papilloma. Cystic and strongly basophilic background with a small papillary cluster of dystrophic epithelial cells. This case was misdiagnosed as salivary cyst. MGG. E128.

Fig. 6.48. Corresponding histological section showing cystic dilatation of a large salivary duct partially filled with papilloma. It consists of connective tissue cores covered by columnar epithelium. HES. E32.

Inverted Ductal Papilloma

In favour of the diagnosis

Large isolated or clustered urothelial-like cells; central nuclei

Difficulties

Squamous-like cells

Against the diagnosis

Atypical squamous cells

6.5.1.2. Intraductal Papilloma

Approximately 30 cases of intraductal papilloma have been described in the literature [89, 90]. This tumour mainly arises in the minor salivary glands during the fifth and sixth decades of life. It is a well-circumscribed, unilocular cystic formation lined by a single layer of cuboidal epithelium. Papillary formations are thin, branching and lined by the same cuboidal ductal cells. Several mucous cells may be seen [176]. There is no proliferation of epithelium into or beyond the cyst wall.

Only 1 case of intraductal papilloma has been seen in our files. The background was cystic showing few papillary structures of epithelial cells (fig. 6.47, 6.48). No atypia, mitotic figures, necrosis or mucus were seen. The main differential diagnosis is salivary cysts.

Intraductal Papilloma

In favour of the diagnosis

Cystic tumour, papillary nonmalignant structures

Difficulties

Paucity of epithelial cells

Against the diagnosis

Mucus-secreting cells, necrosis, oncocytes

6.5.1.3. Sialadenoma Papilliferum

Approximately 50 cases of sialadenoma papilliferum arising in the minor salivary glands and exceptionally in the parotid gland have been reported in the literature [89, 90]. The tumour is well circumscribed, sessile or pedunculated. It consists of papillary squamous projections with numer-

ous cystic spaces lined by columnar cells and basal cuboidal eosinophilic oncocyte-like cells. The stroma is fibrous and richly vascular.

To our knowledge, sialadenoma papilliferum has never been described in the cytological literature.

6.5.2. Cystadenomas

Two variants of cystadenoma are distinguished by the WHO classification [300]: papillary cystadenoma and mucinous cystadenoma. They constitute 2.2% of all benign salivary gland tumours [90]. Sixty-five percent arise in the major salivary glands with median age of 53.5 and 55 years, respectively [89, 90]. Histologically, it consists of a multilocular proliferation of glandular epithelium. Epithelial cells may be columnar, cuboidal, squamous or oncocytic-like. Papillary formations are frequently seen. Stroma is fibrous, rarely with prominent lymphocytic elements.

To our knowledge, mucinous cystadenoma has never been described in the cytological literature. We have seen 3 cases of papillary cystadenoma, all composed of acellular fluid. All cases were misdiagnosed as salivary cysts.

Papillary cystadenoma should be differentiated from Warthin's tumour in the presence of oncocytes, papillary formations, and lymphoid stroma.

Papillary Cystadenoma

In favour of the diagnosis

Cystic tumour

Difficulties

Rare oncocytes

Against the diagnosis

Numerous oncocytes, necrosis, lymphocytes

Chapter 7

High- and Intermediate-Grade Carcinomas

A review of the relevant cytological literature shows that high- and intermediate-grade carcinomas are recognized cytologically as being malignant, but are less frequently accurately typed. The classical example is the difficulty of differentiating high-grade mucoepidermoid carcinoma from squamous cell carcinoma or adenoid cystic carcinoma from epithelial-myoepithelial carcinoma.

From a clinical point of view, the cytological subdivision of malignant tumours into high-/intermediate- and low-grade is more important than subtyping.

7.1. Carcinomas with Squamous Cells

Squamous cell differentiation is a common finding in benign and malignant salivary gland tumours. Squamous metaplasia may be seen in necrotizing sialometaplasia of minor salivary glands and in Warthin's tumour, adenoid cystic carcinoma, sebaceous carcinoma basal cell adenoma, and pleomorphic adenoma. The distinction between primary squamous cell carcinoma of the salivary glands and metastases is based on the clinical history. Adenosquamous carcinoma is a rare variant of squamous cell carcinoma, predominantly affecting the minor salivary glands.

In this chapter, we describe two entities with predominant squamous cellular features: high- and intermediate-grade mucoepidermoid carcinoma and primary squamous cell carcinoma.

7.1.1. High-Grade Mucoepidermoid Carcinoma

7.1.1.1. General

Mucoepidermoid carcinoma is one of the commonest malignant salivary gland tumours. It represents 3–5% of all salivary gland tumours, 17–30% of salivary gland carcinomas, and its incidence has been found to peak at about the fifth decade [90]. It is more common in North America than in Europe. 70% of mucoepidermoid carcinomas arise in the major salivary glands.

7.1.1.2. Histopathology

Mucoepidermoid carcinoma is composed of three cell types: intermediate, squamous and mucin-secreting cells [89]. High-grade mucoepidermoid carcinomas are often solid with a predominance of intermediate and squamous cells. Mucus-secreting cells are scant and their presence should be demonstrated using special stains.

7.1.1.3. Cytopathology

Fine-needle sampling from high-grade solid forms are highly cellular with both single cells and cellular clusters in a background of scant mucin. Three cell types are found in variable amounts from case to case [62, 196]:

(1) Intermediate cells, frequently present, are pathognomonic for mucoepidermoid carcinoma. They have round nuclei without or with moderate atypia and prominent nucleoli on Papanicolaou stain. These cells are isolated and/or clustered. Cytoplasm is moderately abundant, clear or granular. Intranuclear inclusions are occasionally seen (fig. 7.1–7.3).

(2) Squamous cells are less frequent. Atypia may be marked in poorly differentiated tumours. Cytoplasm may show inconspicuous to marked keratinization (fig. 7.4–7.7). Keratin debris may occasionally be found.

(3) Mucus-secreting cells are scant or absent in high-grade tumours. When present, mucus-secreting cells are intermixed within large clusters of intermediate cells or may be isolated with characteristic histiocyte-like or goblet cell morphology. Pseudo-histiocyte cells have small, dark nuclei and vacuolized cytoplasm. Goblet cells have small, round, eccentric nuclei and a large cytoplasmic inclusion (fig. 7.8–7.10).

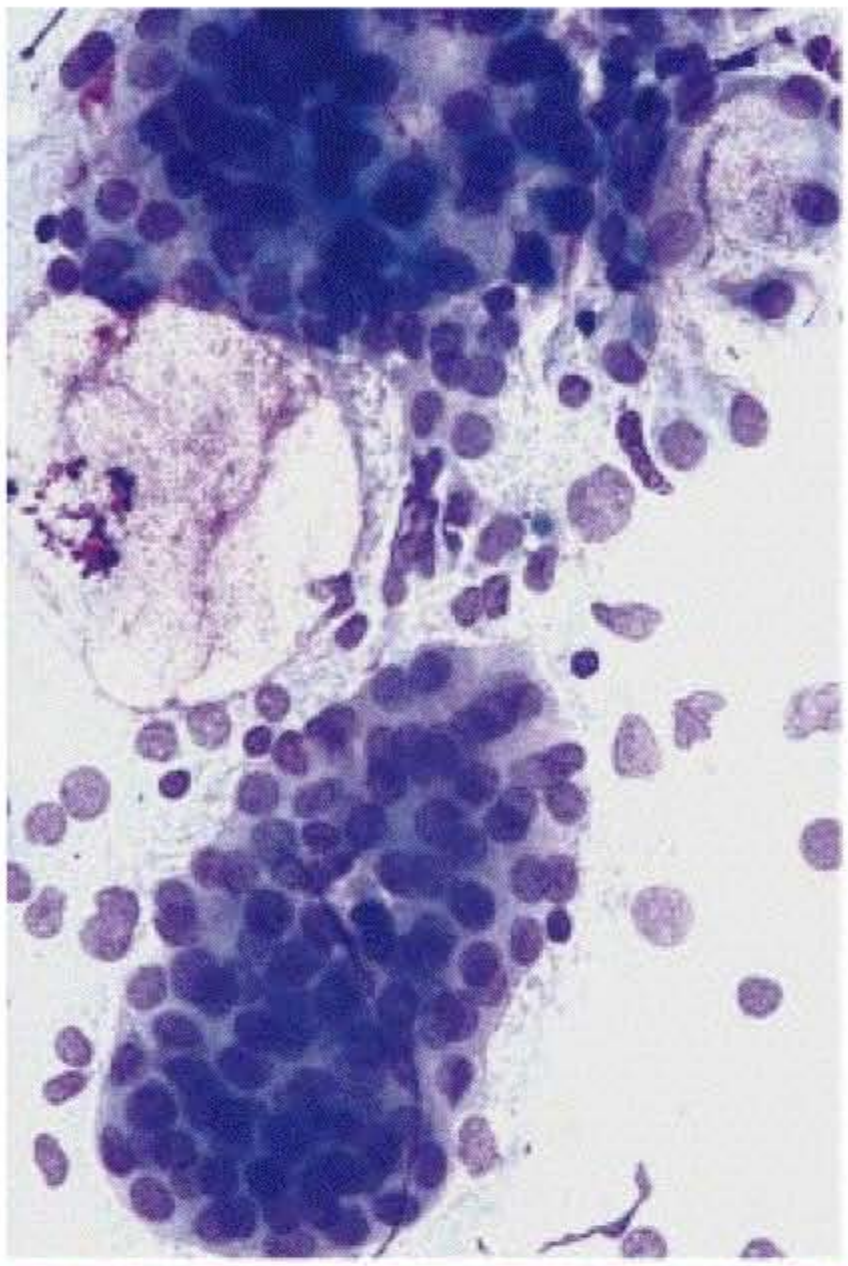

7.1

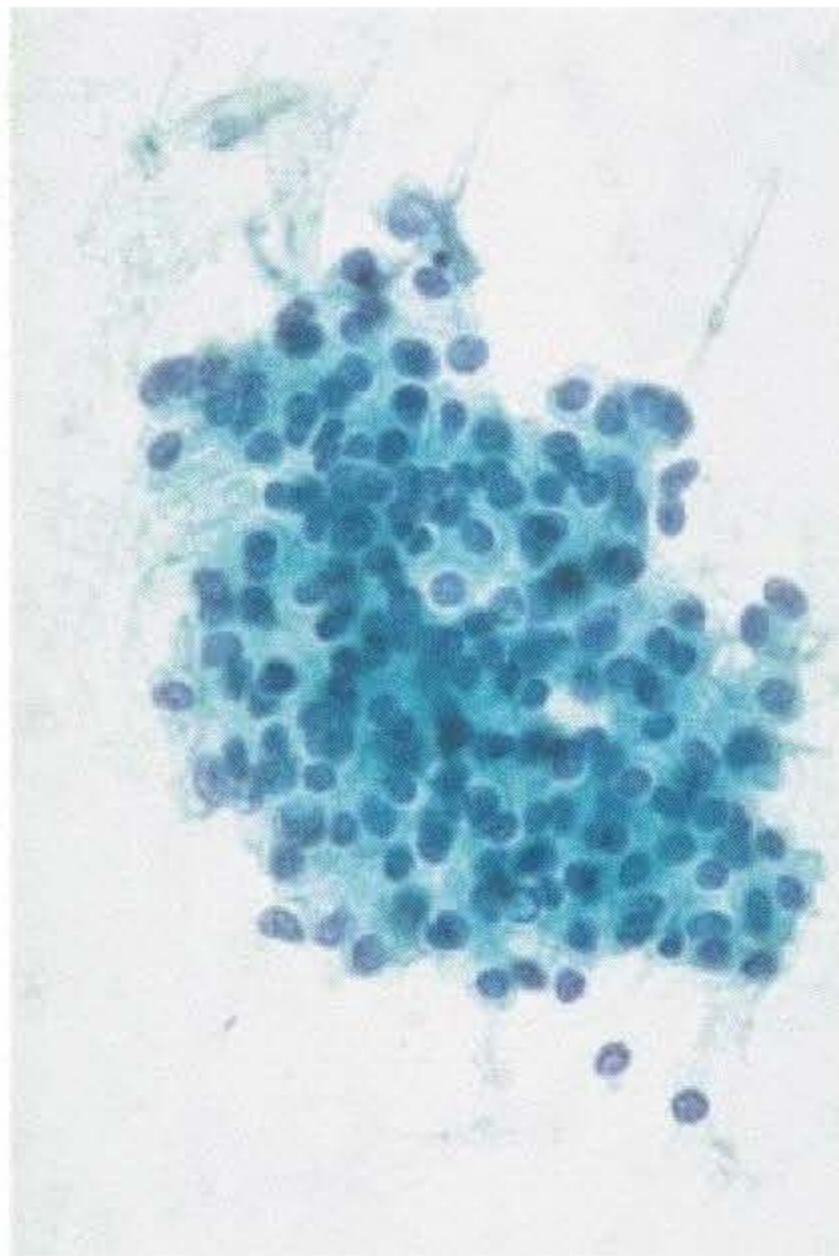

7.2

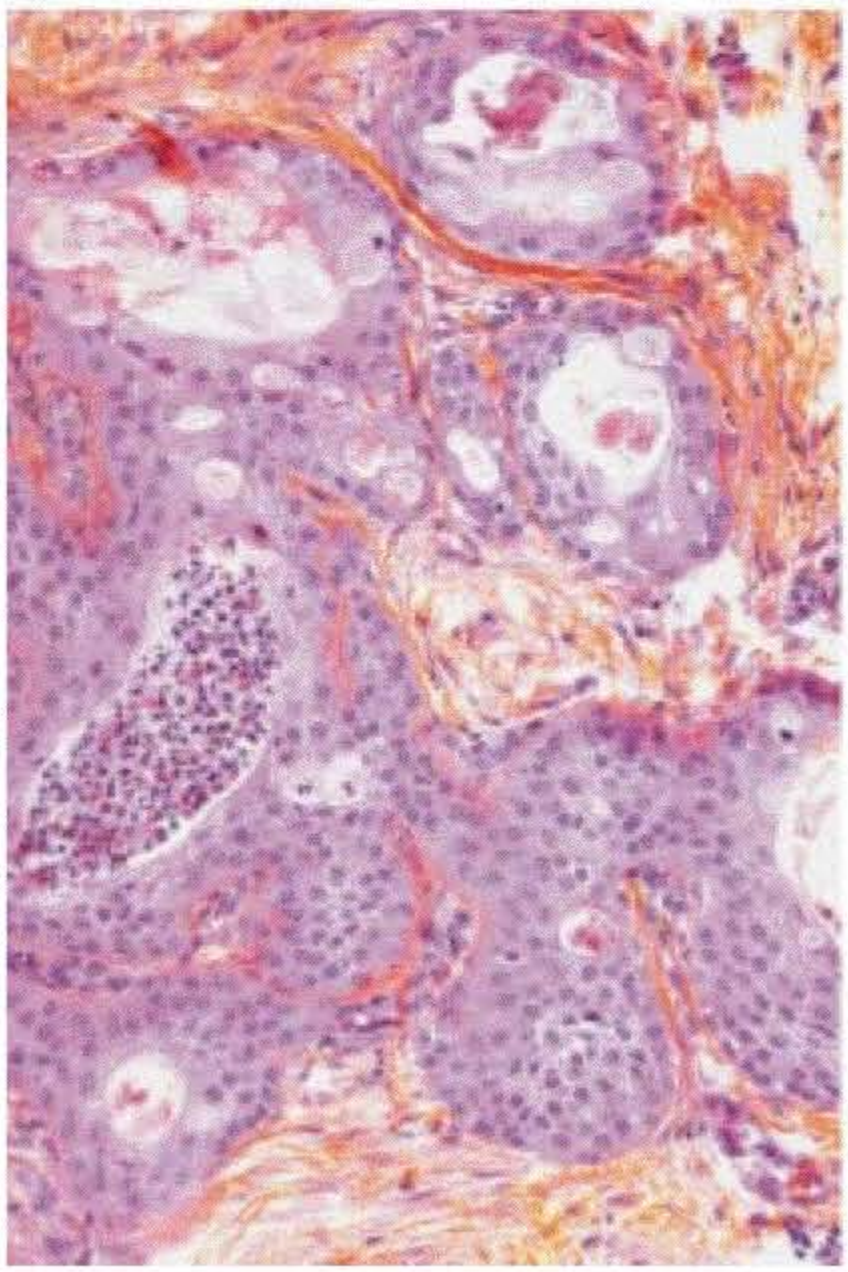

7.3

Fig. 7.1. High-grade mucoepidermoid carcinoma. Clusters of intermediate cells with regular nuclei. Mucus-secreting cells are also present. MGG. ×128.

Fig. 7.2. High-grade mucoepidermoid carcinoma. Cluster of intermediate cells. Papanicolaou. ×128.

Fig. 7.3. High-grade mucoepidermoid carcinoma. Histological section corresponding to figure 7.1 showing solid sheets of intermediate cells with mucus-secreting cells. HES. ×64.

Fig. 7.4. High-grade mucoepidermoid carcinoma. Intermediate cells with squamous cells in the centre. MGG. ×128.

Fig. 7.5. High-grade mucoepidermoid carcinoma. Malignant squamous cells. MGG. ×128.

Fig. 7.6. High-grade mucoepidermoid carcinoma. Malignant squamous cells. Papanicolaou. ×128.

Fig. 7.7. High-grade mucoepidermoid carcinoma. Histological section corresponding to figure 7.5. Mucus-secreting cells stained by Alcian blue are not shown. HES. ×64.

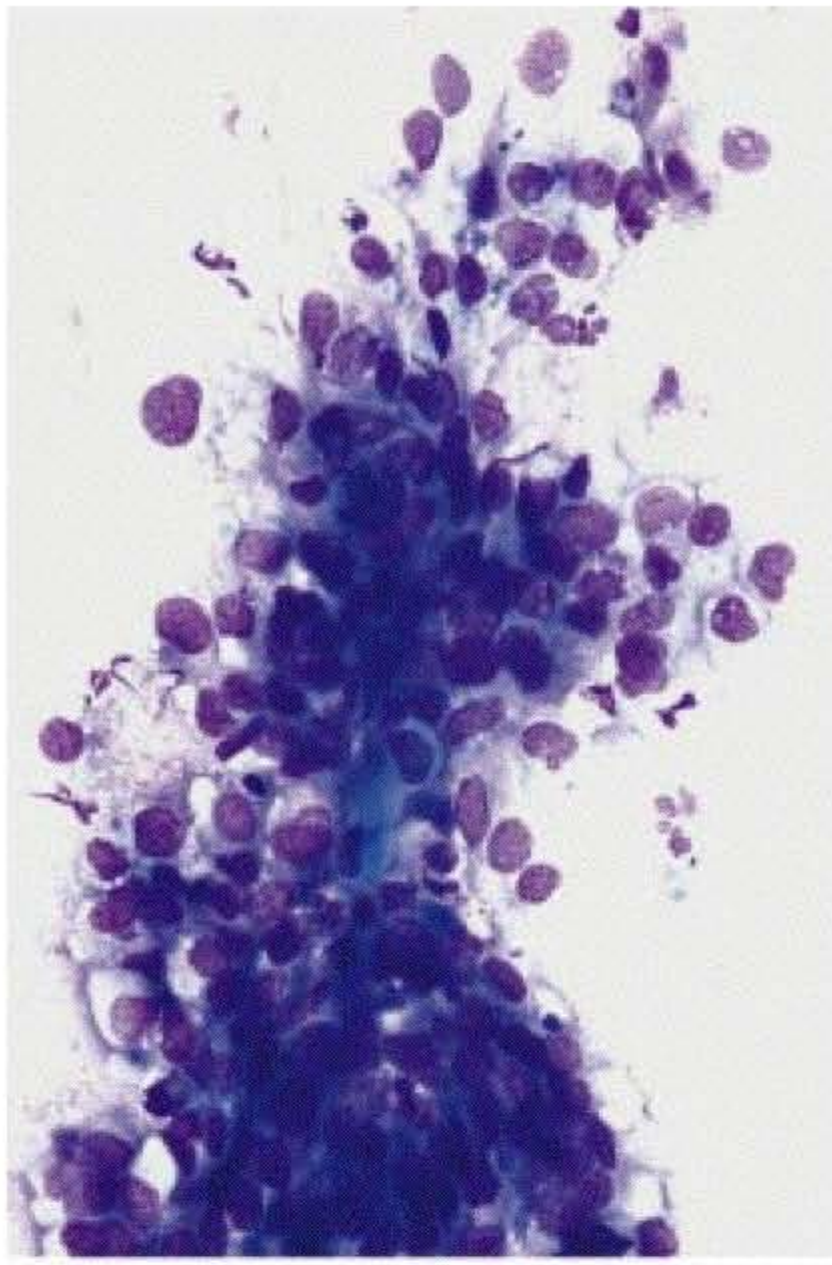

7.4

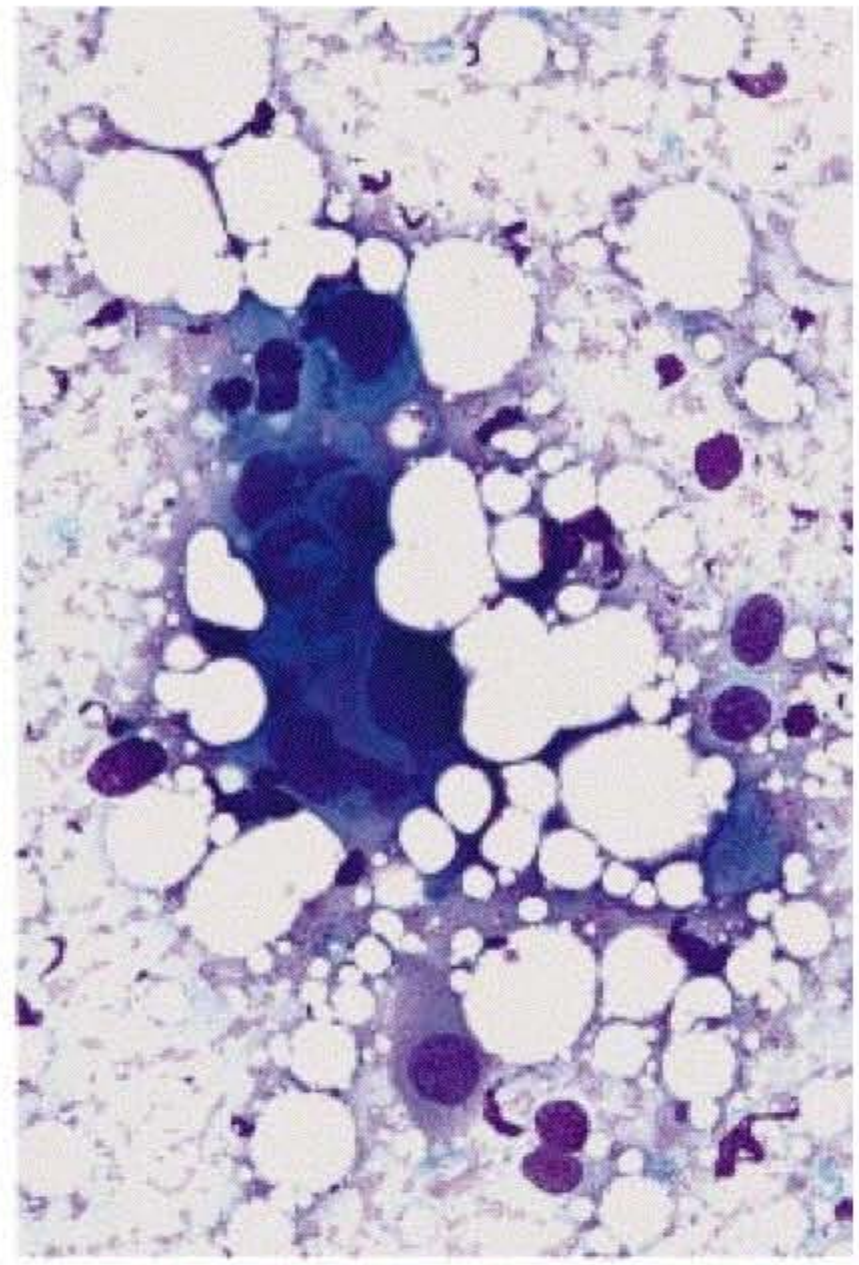

7.5

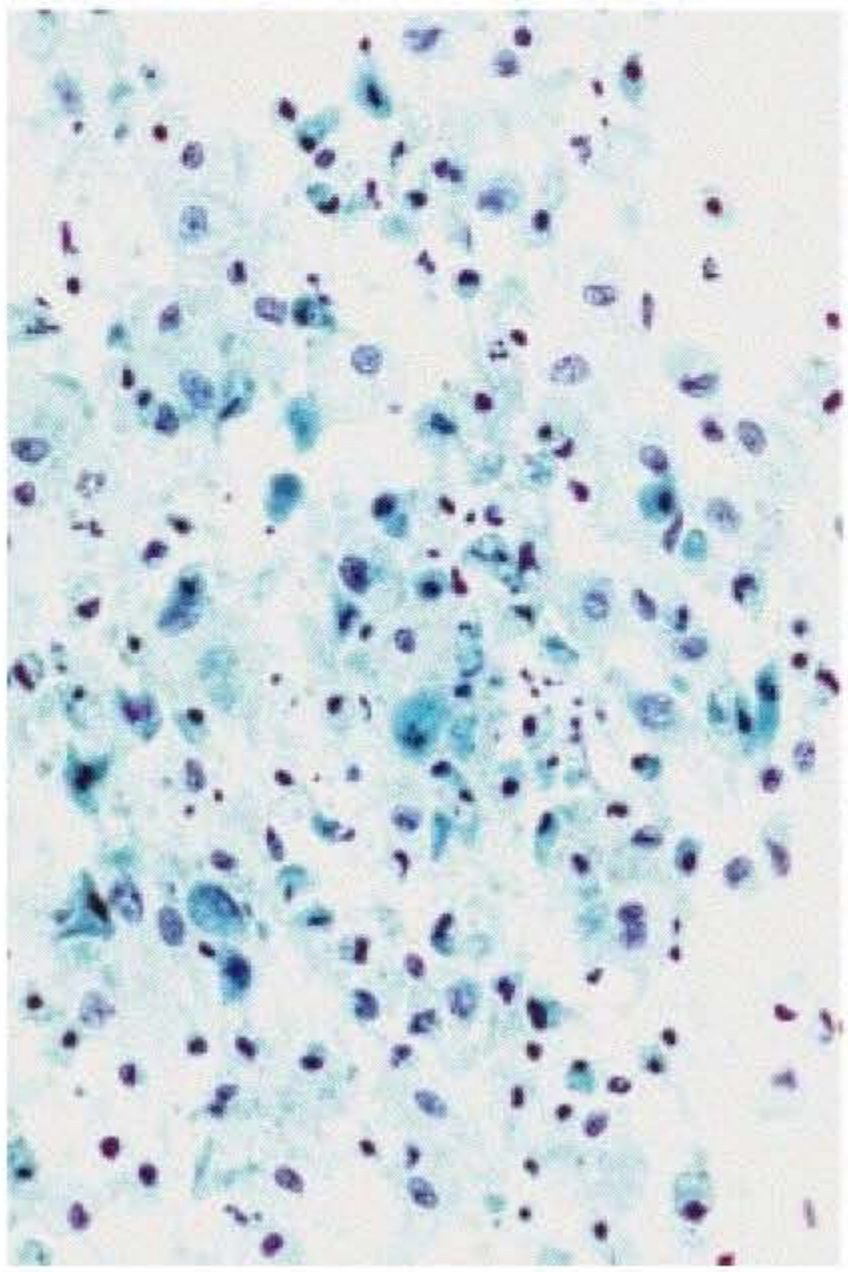

7.6

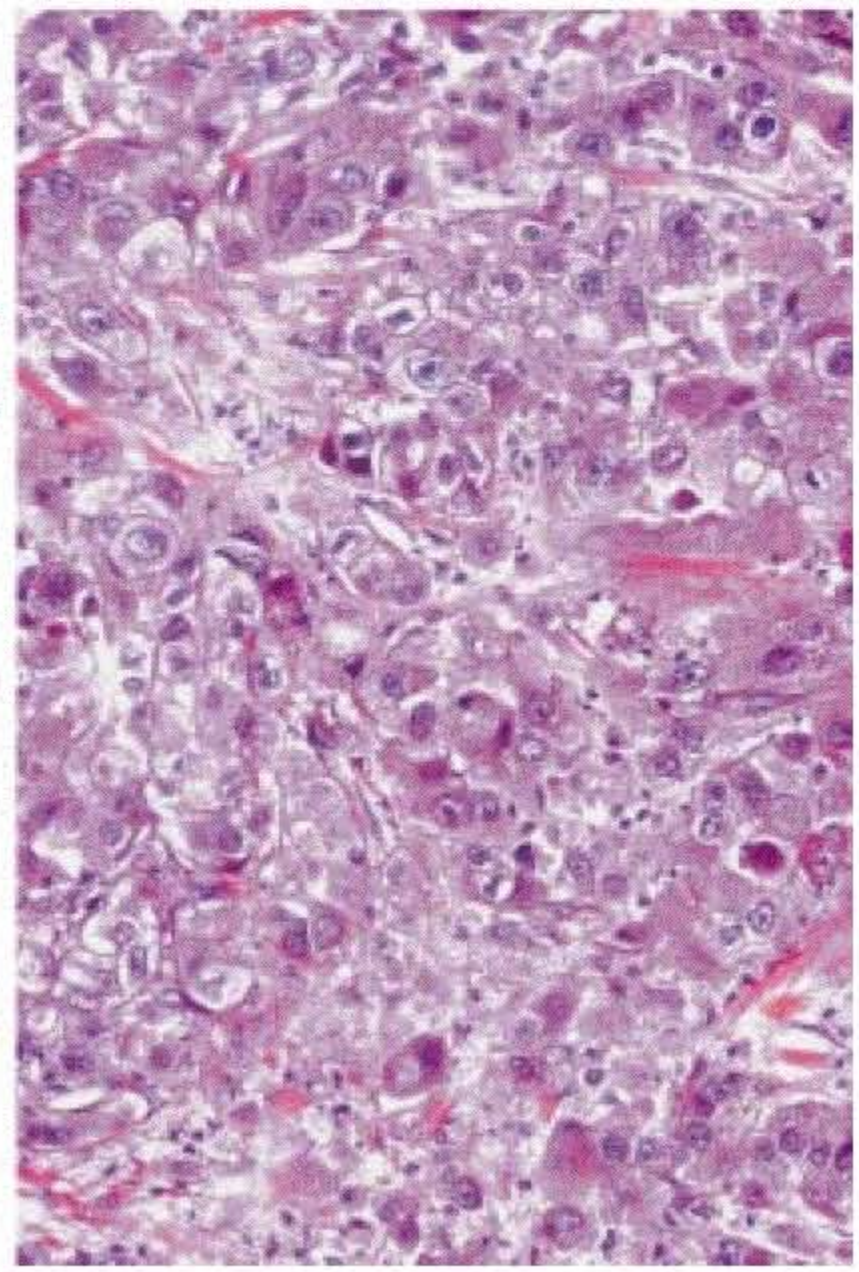

7.7

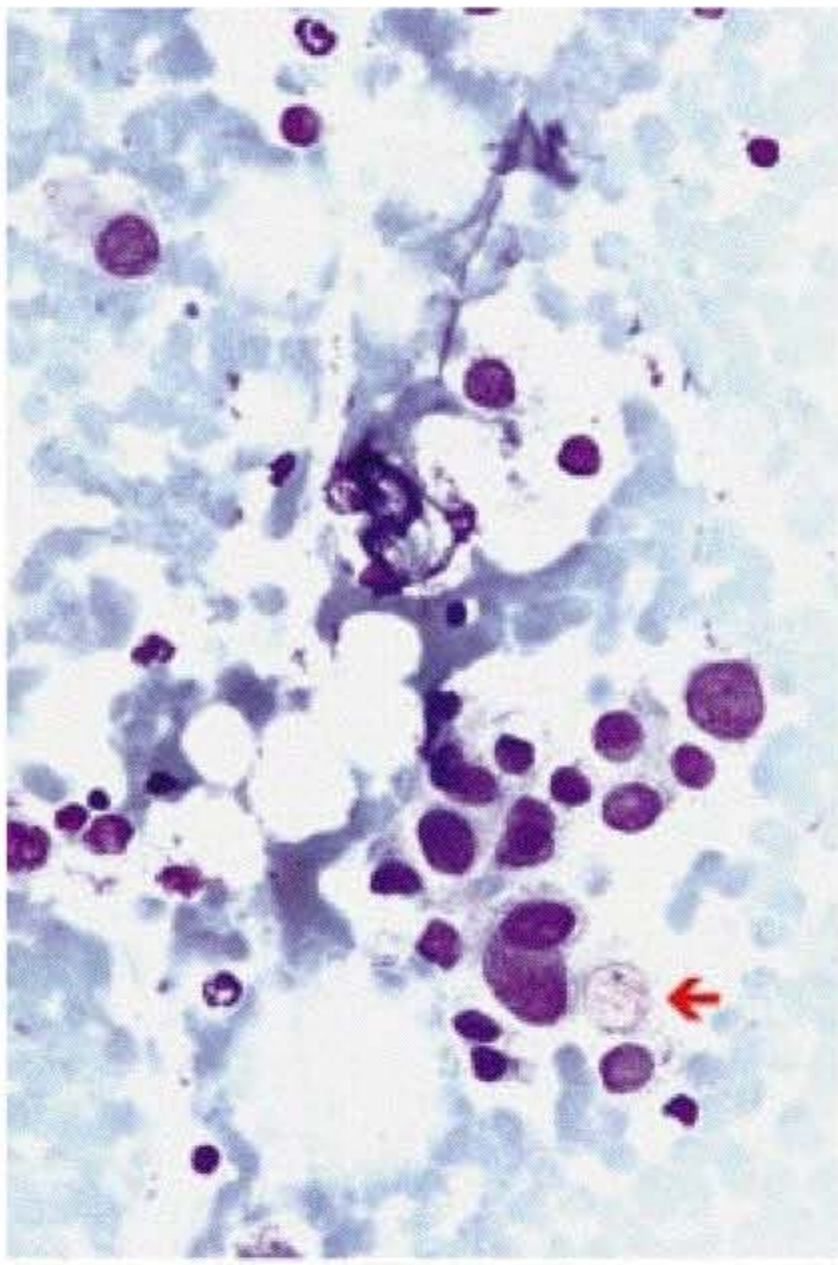

7.8

7.9

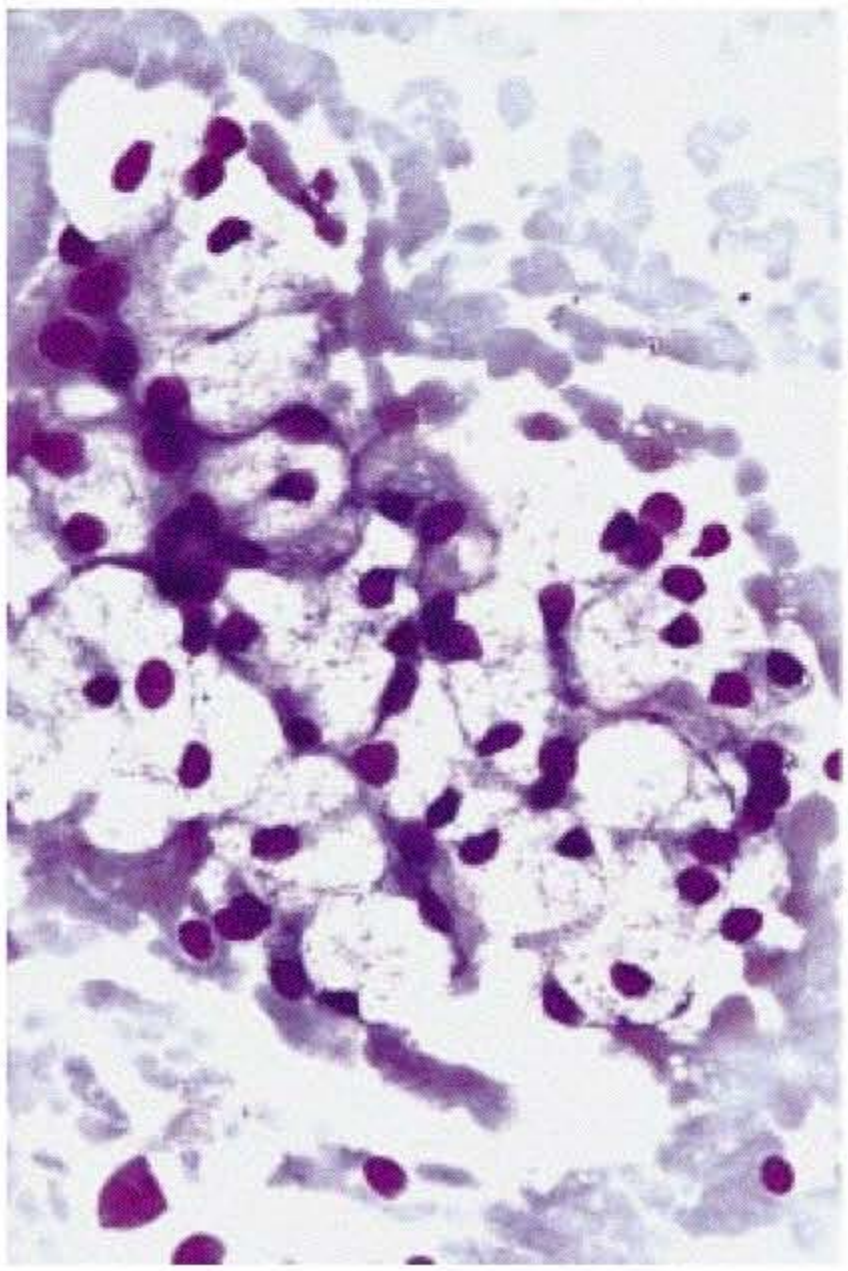

7.10

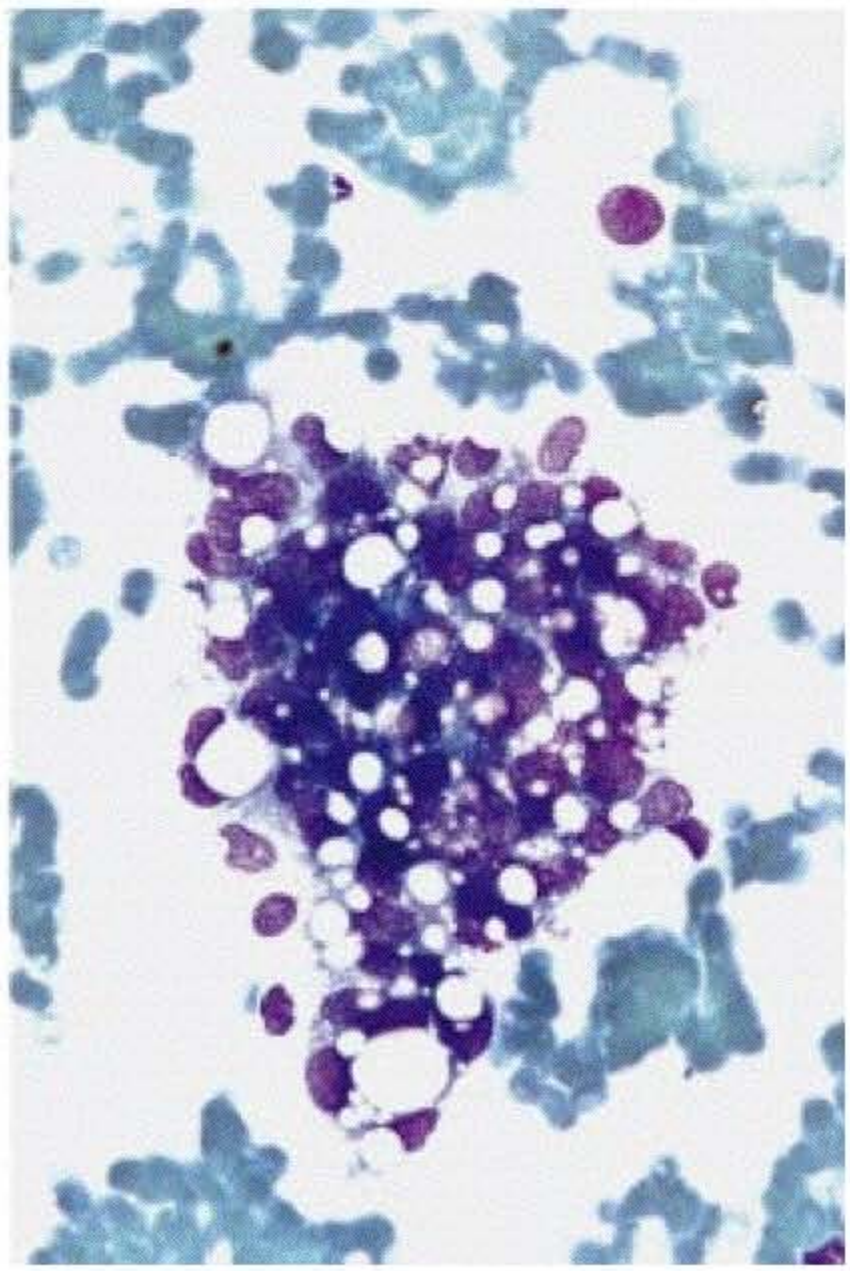

7.11

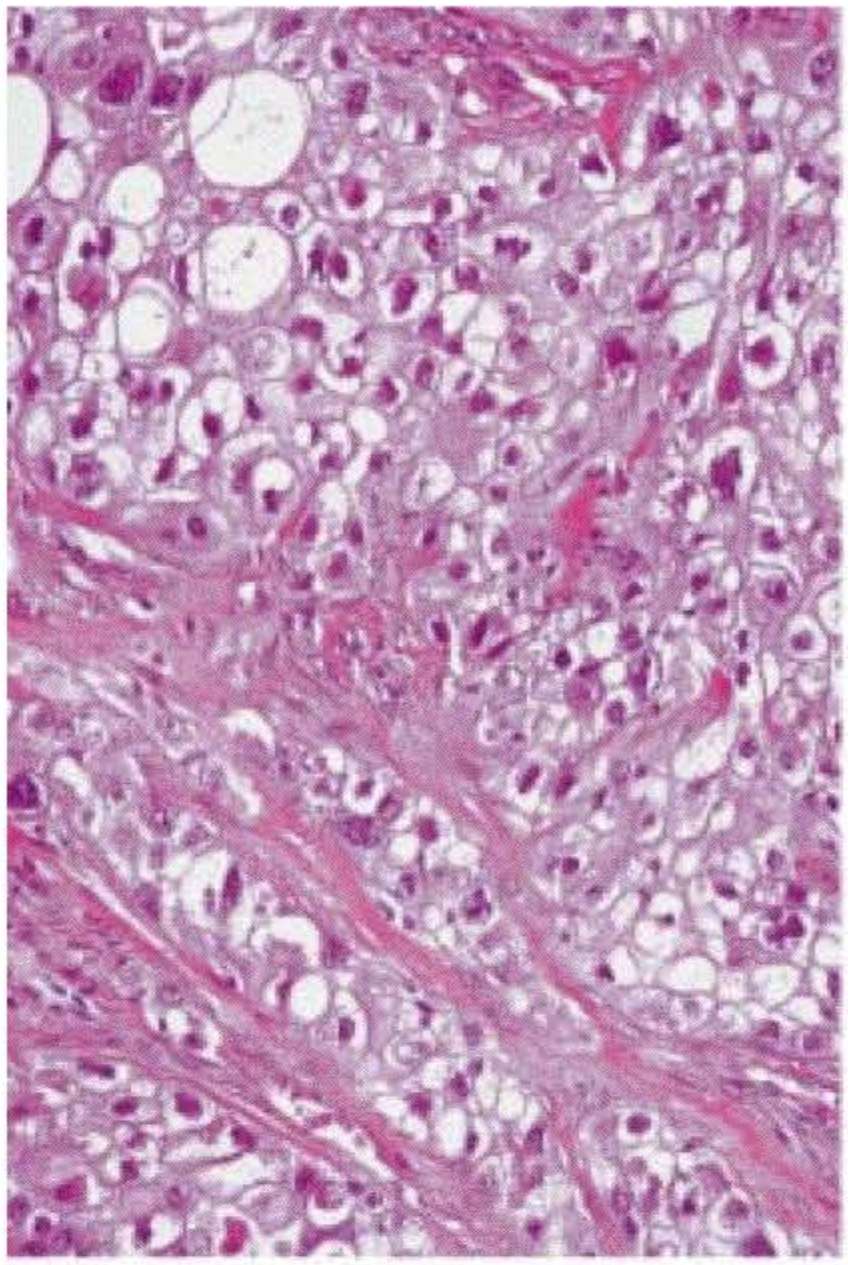

7.12

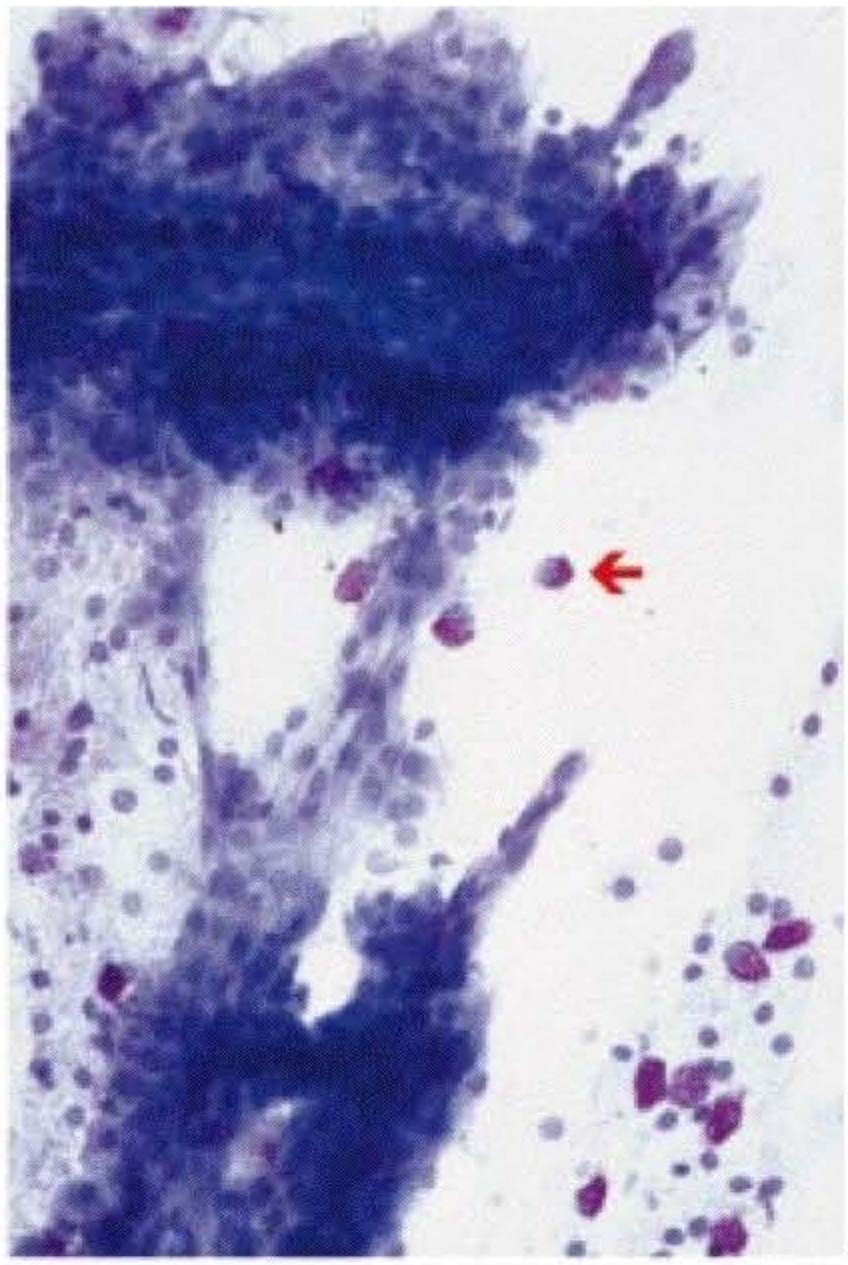

7.13

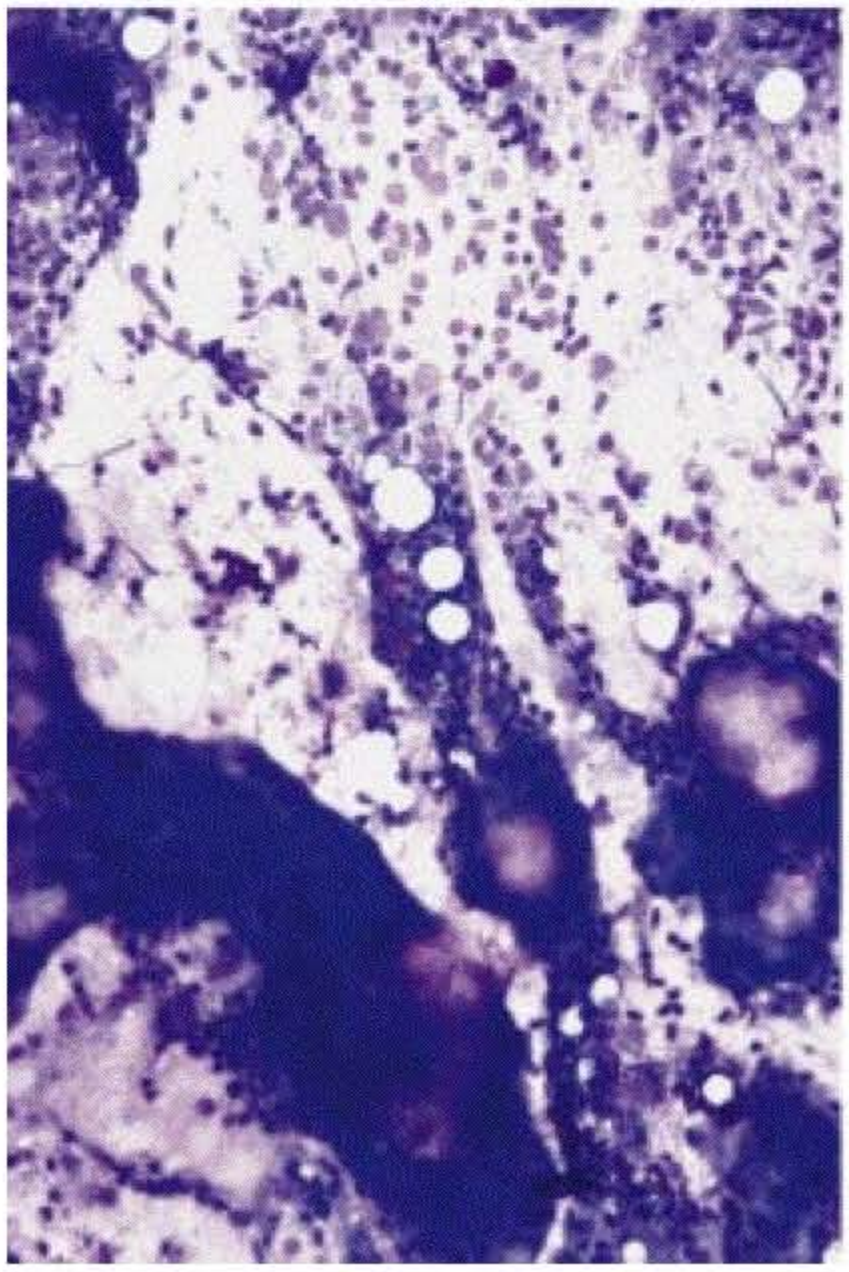

7.14

Fig. 7.8. High-grade mucoepidermoid carcinoma. Mucus-secreting (goblet) cells (arrow) with intracytoplasmic vacuoles. MGG. ×128.

Fig. 7.9. High-grade mucoepidermoid carcinoma. Mucus-secreting (goblet) cells (arrow) with large intracytoplasmic vacuole. Papanicolaou. ×128.

Fig. 7.10. High-grade mucoepidermoid carcinoma. Clear mucus-secreting cells. MGG. ×128.

Fig. 7.11. High-grade mucoepidermoid carcinoma. Clear (vacuolated) cells. This pattern is rarely observed in mucoepidermoid carcinoma. MGG. ×128.

Fig. 7.12. High-grade mucoepidermoid carcinoma. Histological section corresponding to figure 7.11 showing clear cell variant. HES. ×64.

Fig. 7.13. High-grade mucoepidermoid carcinoma with mast cells (arrow). MGG. ×128.

Fig. 7.14. High-grade mucoepidermoid carcinoma. Dark clusters of intermediate and mucus-secreting cells. Mucoid in the background. MGG. ×64.

Occasionally, clear cells with microvacuolized cytoplasm, oncocyte-like or sebaceous-like cells are found [151, 166]. Intermediate cell clusters may also contain mast cells (fig. 7.11–7.13) [62, 196].

Variable amounts of inflammatory cells and mucus (cystic component) are frequently seen in the background (fig. 7.14).

7.1.1.4. Diagnostic Accuracy

Mucoepidermoid carcinoma has extensively been studied in the literature, but few cytology studies have accurately classified high- or low-grade mucoepidermoid carcinoma. In our previous study [196], malignancy was diagnosed or suspected in 87% of high-grade tumours. Table 7.1 summarizes selected large series without distinction between the two histoprognostic grades.

7.1.1.5. Differential Diagnosis

Table 7.2 summarizes the differential diagnosis of high-grade mucoepidermoid carcinoma. The morphological and quantitative variability of the cellular elements observed cytologically in high-grade mucoepidermoid carcinoma account for the diagnostic difficulties. The problem here is not the possibility of a false-negative diagnosis, but rather the difficulty of accurate tumour typing.

The diagnosis is obvious when smears are composed of intermediate, squamous and mucin-producing cells and present a mucoid background [62, 196]. When the smears are composed of malignant cells, squamous or intermediate type, the differential diagnosis with squamous cell carcinoma and salivary duct carcinoma should be considered, respectively. In both instances, the failure to distinguish between these two tumours is not dramatic, as clinical management is identical and requires immediate histological confirmation and a search for a possible primary.

7.1.1.5.1. High-Grade Mucoepidermoid Carcinoma vs. Squamous Cell Carcinoma. When smears are composed of squamous cells with marked keratinization, and lack mucoid background or mucus-secreting cells, the differential diagnosis with squamous cell carcinoma is not possible (fig. 7.5, 7.16).

7.1.1.5.2. High-Grade Mucoepidermoid Carcinoma vs. Salivary Duct Carcinoma. When smears are composed of atypical intermediate cells or squamous-like cells, the differential diagnosis with salivary duct carcinoma should be considered (fig. 7.45).

7.1.1.5.3. High-Grade Mucoepidermoid Carcinoma vs. Warthin's Tumour. Less often, when the smears are poorly representative and composed of mucoid fluid with necrotic debris or clusters of pseudo-oncocytes containing scattered mast cells, the differential diagnosis with Warthin's tumour should be considered. The presence of true oncocytes, isolated or clustered, intermingled with lymphocytes and pseudonecrosis, is in favour of Warthin's tumour (fig. 6.24, 6.27).

7.1.1.5.4. High-Grade Mucoepidermoid Carcinoma vs. Carcinoma Ex Pleomorphic adenoma. The coexistence of features of mucoepidermoid carcinoma and pleomorphic adenoma are in favour of a diagnosis of carcinoma ex pleomorphic adenoma, keeping in mind that scant mucoid stroma may also be found in pleomorphic adenoma. The differential diagnosis may be guided by a clinical history of pleomorphic adenoma (fig. 7.56).

High-Grade Mucoepidermoid Carcinoma

In favour of the diagnosis

Clustered or isolated intermediate-type cells, mucus-secreting cells, mucoid, inflammatory background, squamous cells are less frequent

Difficulties

Lack of mucoid background, lack of mucus-secreting cells, mast cells, vacuolated cells

Against the diagnosis

Myoepithelial cells, oncocytes, marked keratinization in squamous cells

7.1.2. Primary Squamous Cell Carcinoma

The development of squamous cell carcinoma as a primary tumour of the major salivary glands may be linked to squamous metaplasia occurring in the salivary ducts, particularly in association with sialolithiasis or chronic inflammation. Primary salivary squamous cell carcinoma has also been reported to occur more frequently after previous radiotherapy of the head and neck region [90]. Squamous cell carcinoma may also arise in the minor salivary glands, but cannot be distinguished from squamous cell carcinoma arising from adjacent squamous mucosa. Before accepting a primary origin in salivary gland, particularly the parotid, a metastasis must be excluded.

7.1.2.1. General

Primary salivary squamous cell carcinoma represents 0.9–4.7% of all salivary gland malignancies. In the AFIP series [90] collecting 224 cases, the mean and median age were 60.5 and 60 years, respectively, with an age range of 7–95 years and a female to male ratio of 3:1.

Table 7.1. Correlation between cytology and histology for high- and low-grade mucoepidermoid carcinomas

Author [ref.]	Number	Malignant	Suspicious	False-negative	Unsatisfactory
Persson, Zettergren [270]	4	3 (75)	0	1 (25)	0
Zajicek et al. [354]	24	13 (54.2)	0	11 (45.8)	0
Lindberg, Åkerman [222]	13	3 (23)	4	4 (31)	2
Kline et al. [201]	9	6 (67)	3	0	0
Qizilbash et al. [277]	3	3 (100)	0	0	0
O'Dwyer et al. [261]	14	4 (50)	3	5 (36)	2
Jayaram et al. [169]	6	5 (83)	0	1	0
Smith Frable, Frable [313]	5	1 (20)	0	3	1
Kumar et al. [207]	18	11 (61)	0	4 (22.2)	3
Zurrida et al. [358]	15	10 (67	0	2 (13)	3
Orell [263]	8	6 (75)	0	2 (25)	0
Klijanienko, Vielh [196]	50	34 (68)	5 (10)	6 (12)	5 (10)
Total	169	99 (58.6)	15 (8.9)	39 (23)	16 (9.5)

Statistics from the literature. % in parentheses.

Table 7.2. Quantitative differential diagnosis of high-grade mucoepidermoid carcinoma

	High-grade muco-epidermoid carcinoma	Squamous cell carcinoma	Warthin's tumour	Pleomorphic adenoma
Cells				
Squamous	+	++	+/–	+/–
Intermediate	++	+/–	–	–
Mucus-secreting	+	–	+/–	+/–
Myoepithelial	–	–	–	++
Clear cells	+	+	+/–	+/–
Mast cells	+/–	–	+	+/–
Oncocytic	+/–	–	++	+/–
Keratin debris	+	++	+/–	+/–
Stroma				
Chondromyxoid	–	–	–	++
Mucoid	+	–	+/–	+/–
Inflammatory	++	++	++	–
Necrotic	++	++	++	–

++ = Common; + = rare; +/– = occasionally seen; – = absent.

7.1.2.2. Histopathology

These tumours are histologically similar to squamous cell carcinomas in other sites [89].

7.1.2.3. Cytopathology

Smears are richly cellular [197]. Tumour cells have round or ovoid nuclei with dense nuclear chromatin. Severe nuclear atypia is not uncommon. The cytoplasm varies in size, ranging from large cells without keratinization to scant mature keratinization (fig. 7.15). Naked nuclei, cells with a spindle-shaped appearance and keratin debris are also commonly detected (fig. 7.16, 7.17). Inflammatory necrosis may be predominant on smears. Mucoid background is never seen, but mucin may be present.

7.1.2.4. Diagnostic Accuracy

Primary salivary squamous cell carcinoma has been extensively studied by cytology. Table 7.3 summarizes the accuracy of cytology. More than 93% of tumours are diagnosed or suspected.

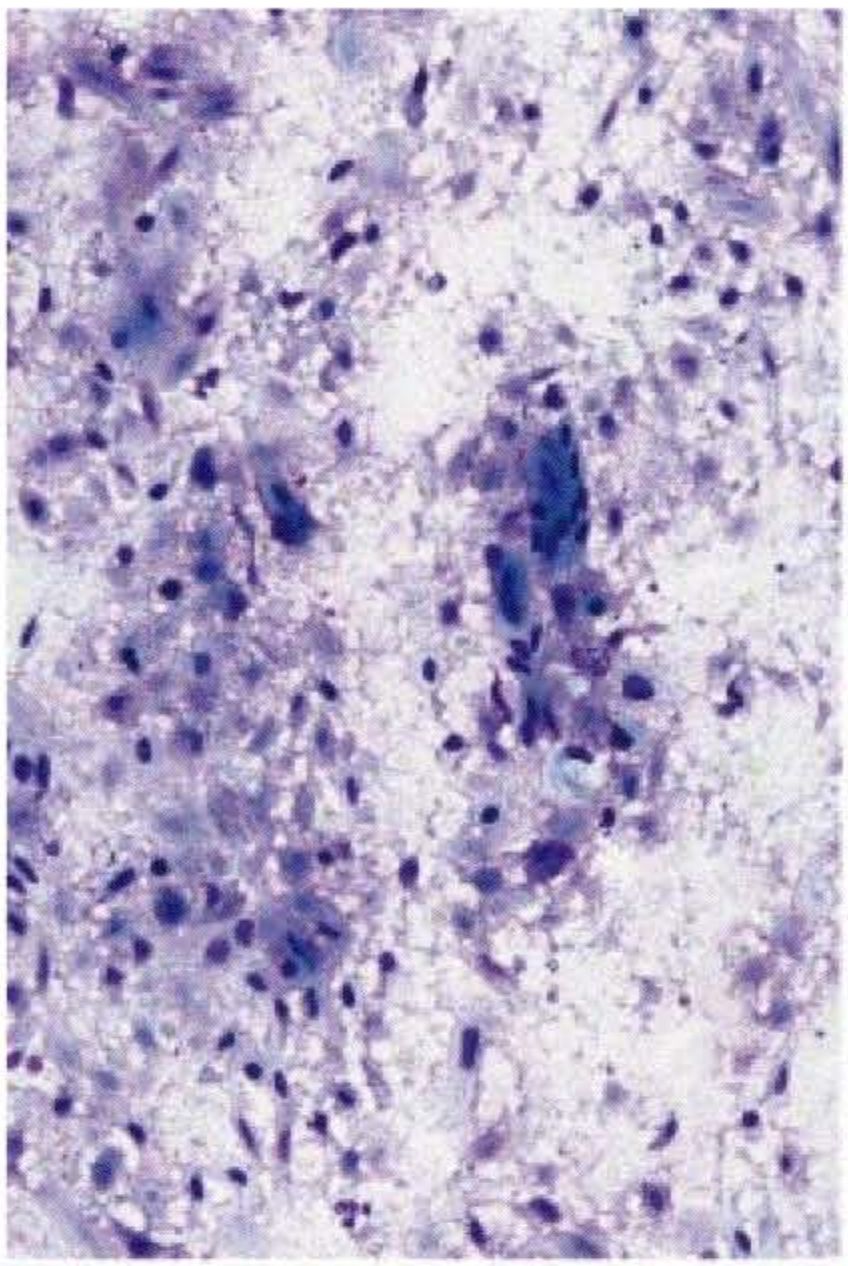

7.15

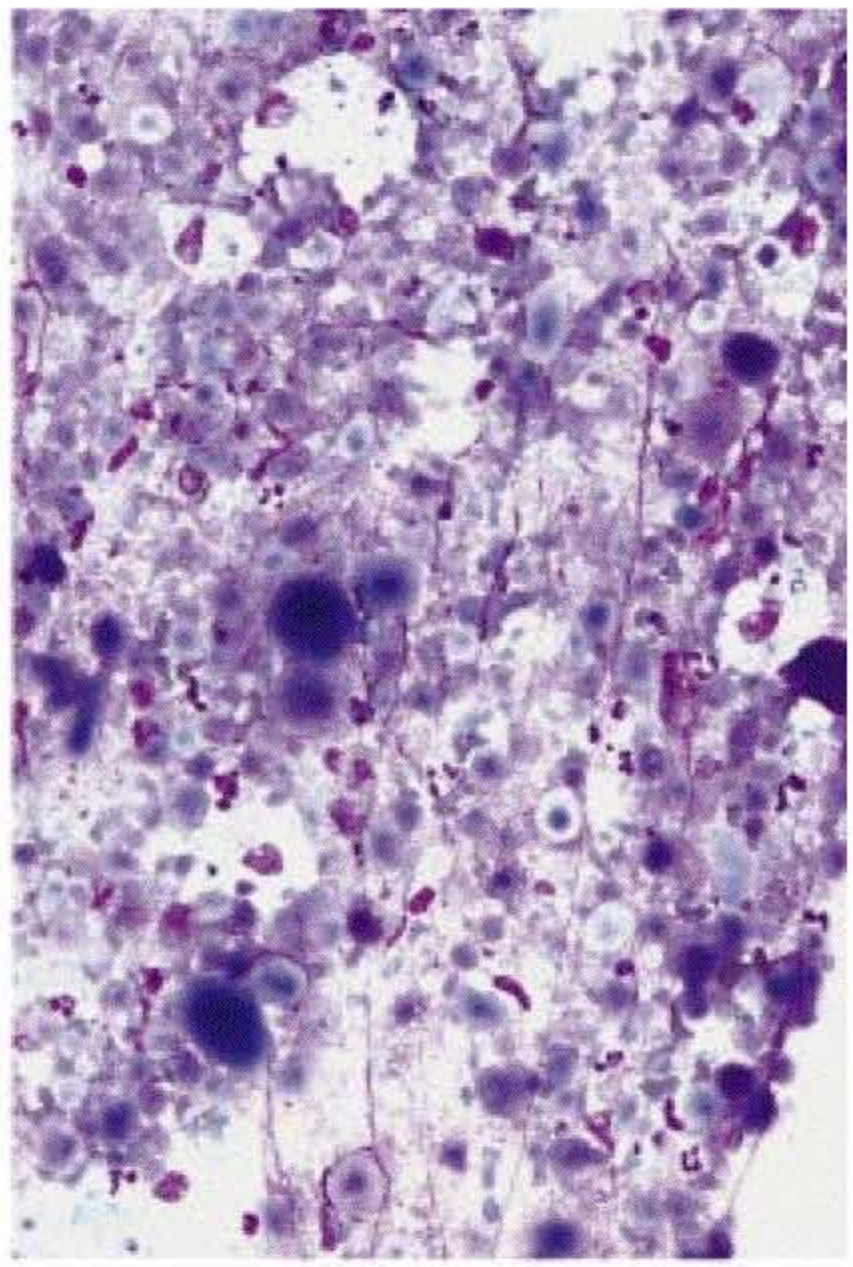

7.16

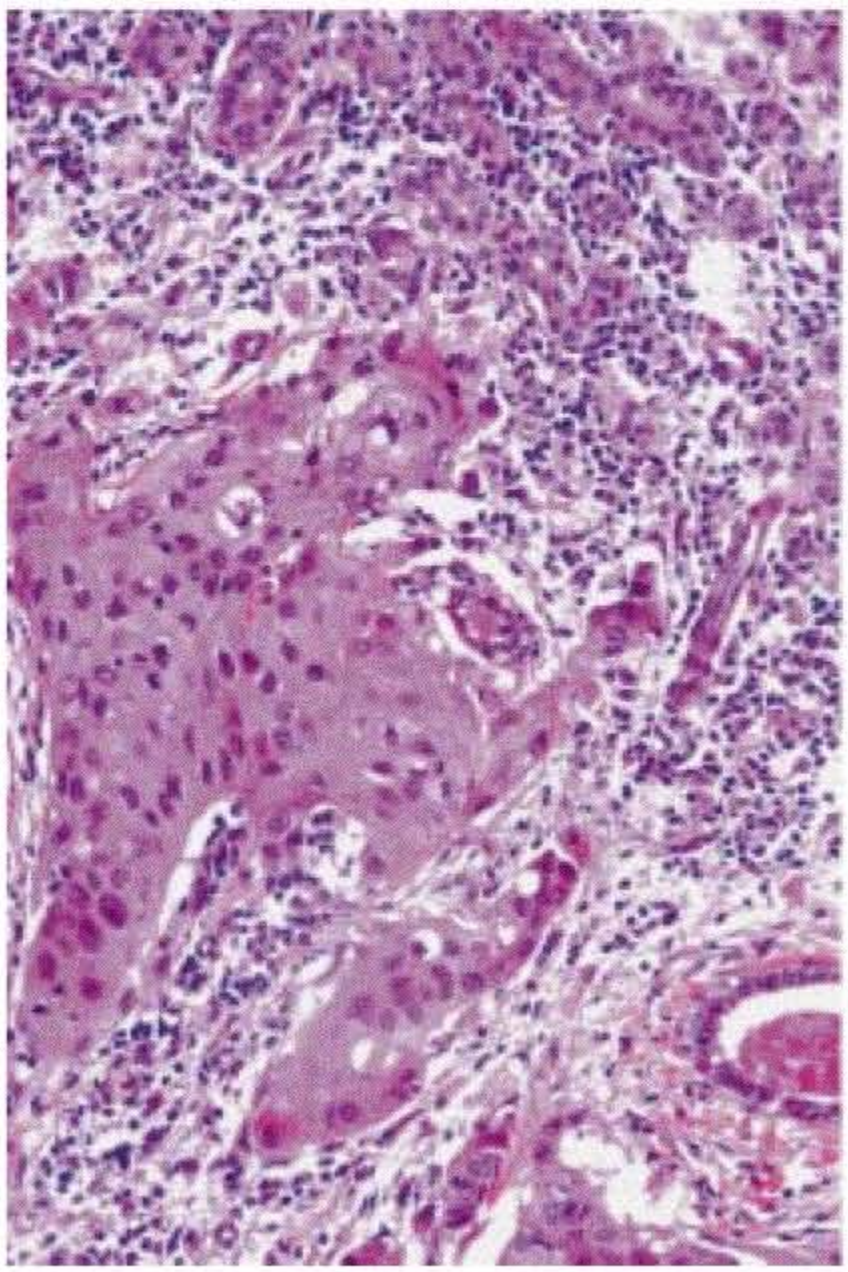

7.17

Fig. 7.15. Squamous cell carcinoma, well-differentiated. Malignant squamous cells and keratin fragments. MGG. ×128.

Fig. 7.16. Squamous cell carcinoma. Necrosis with keratin. MGG. ×128.

Fig. 7.17. Squamous cell carcinoma. Histological section corresponding to figure 7.16 showing moderately-differentiated carcinoma. HES. ×64.

Table 7.3. Correlation between cytology and histology of primary salivary squamous cell carcinomas

Author [ref.]	Number	Malignant	Suspicious	False-negative	Unsatisfactory
Bonneau, Sommer [31]	1	1	0	0	0
Persson, Zettergren [270]	4	4	0	0	0
Jayaram et al. [169]	2	2	0	0	0
Young et al. [351]	8	6	0	0	2
Orell [263]	14	13	0	1	0
Klijanienko, Vielh [197]	44	41	1	2	0
Total	73	67 (91.8)	1 (1.4)	3 (4.1)	2 (2.7)

Statistics from the literature. % in parentheses.

7.1.2.5. Differential Diagnosis

Salivary squamous cell carcinoma should be differentiated from metastatic cutaneous squamous cell carcinoma and high-grade mucoepidermoid carcinoma (table 7.4).

7.1.2.5.1. Squamous Cell Carcinoma vs. High-Grade Mucoepidermoid Carcinoma. High-grade mucoepidermoid carcinomas may mimic poorly-differentiated squamous cell carcinomas because of their paucity of glandular elements. PAS, mucicarmine or Alcian blue stains may be helpful, although a definitive diagnosis can sometimes only be established after histological examination of the surgical specimen. Intermediate cells and three-dimensional clusters of cells among minimally keratinizing malignant cells and rare keratin debris are very helpful cytological features of intermediate- or high-grade mucoepidermoid carcinoma when mucus-secreting cells are absent. In contrast, squamous cell carcinomas are highly keratinizing tumours with abundant keratin debris. When mucoepidermoid carcinoma shows squamous keratinizing cells, the distinction between these two tumours is not possible (fig. 7.5, 7.16) [196].

7.1.2.5.2. Squamous Cell Carcinoma vs. Pseudoneoplastic and Inflammatory Conditions. Other diagnostic difficulties may also be encountered with necrotizing sialometaplasia and radiation-induced sialadenitis, due to the presence of squamous cells and inflammatory stroma. Fine-needle sampling of radiation-induced sialadenitis may reveal smears with bizarre atypical cells. It can be distinguished from carcinoma by recognition of scant cellularity and tight clustering of atypical cells in short segments of the duct, whereas true squamous cell carcinomas generally yield more cellular material with numerous single malignant cells rather than cohesive aggregates. It has also been noted that squamous cell carcinoma should be differentiated from squamous cell carcinoma arising from pleomorphic adenoma or Warthin's tumour.

Table 7.4. Quantitative differential diagnosis of primary salivary squamous cell carcinoma

	Squamous cell carcinoma	High-grade mucoepidermoid carcinoma
Cells		
Squamous	++	+
Mucus-secreting	–	+
Keratin debris	++	+
Stroma		
Mucoid	–	+
Necrotic	++	+

++ = Common; + = rare; – = absent.

7.1.2.5.3. Squamous Cell Carcinoma vs. Squamous Metaplasia in Salivary Tumours. Benign metaplastic squamous cells may occasionally be seen in pleomorphic adenoma, Warthin's and Küttner's tumours, basal cell adenomas/adenocarcinomas and in adenoid cystic carcinoma (fig. 12.2).

Squamous Cell Carcinoma

In favour of the diagnosis

Clustered or isolated squamous cells, inflammatory background; lack of mucus-secreting cells

Difficulties

Extensive necrosis

Against the diagnosis

Mucus-secreting and intermediate cells

7.2. Undifferentiated Carcinoma

The WHO classification [300] distinguishes two subtypes of undifferentiated carcinoma: large cell and lymphoepithelial carcinoma. Lymphoepithelial carcinoma, the so-called malignant lymphoepithelial lesion, is morphologically identical to undifferentiated carcinoma of nasopharyngeal type from nasopharynx or Waldeyer's ring [89]. Because of the extreme rarity of these tumours, the diagnosis of salivary lymphoepithelial carcinoma can only be made after exclusion of a primary nasopharyngeal tumour.

7.2.1. Large Cell Undifferentiated Carcinoma

This entity is defined as salivary gland carcinoma with no specific histological features.

7.2.1.1. General

The tumour arises almost exclusively from the parotid gland in middle-aged to elderly patients [253].

7.2.1.2. Histopathology

Grossly, it is characterized by a solid and infiltrating mass with necrotic and haemorrhagic areas. The tumour is typically composed of cords and nests of large cells with abundant cytoplasm, with no ducts or glandular differentiation [89]. Multinucleated or spindle cells may be present [105].

7.2.1.3. Cytopathology

Smears show nonspecific features of high-grade malignancy [250]. They are richly cellular, with isolated cells or cells arranged in small clusters (fig. 7.18). Nuclei may be eccentrically located with a plasmacytoid appearance. Binucleated cells are common.

7.2.1.4. Diagnostic Accuracy

Only 2 cases have been reported in the cytological literature [250] and we have observed 3 cases, all diagnosed as malignant.

7.2.1.5. Differential Diagnosis

Accurate typing of large cell undifferentiated carcinoma is not possible, as smears show nonspecific features of high-grade carcinoma. Moreover, accurate typing has no clinical consequences, but recognition of high-grade malignancy is extremely important, as it leads to histological diagnosis and appropriate patient management. The differential diagnosis may include lymphoepithelial carcinoma, salivary duct carcinoma, high-grade mucoepidermoid carcinoma, squamous cell carcinoma, malignant oncocytoma, and metastatic melanoma.

7.2.1.5.1. Large Cell Undifferentiated Carcinoma vs. Lymphoepithelial Carcinoma. Lymphoepithelial carcinoma is composed of immature cells with prominent nucleoli. Numerous lymphocytes are present in the background (fig. 7.19).

7.2.1.5.2. Large Cell Undifferentiated Carcinoma vs. Salivary Duct Carcinoma. Salivary duct carcinoma may be composed of large, atypical cells resembling breast adenocarcinoma (fig. 7.45). Oncocytic-like cells and extensive necrosis are common features.

7.2.1.5.3. Large Cell Undifferentiated Carcinoma vs. Mucoepidermoid Carcinoma, High-Grade. High-grade mucoepidermoid carcinoma is likely when the smears show mucus-secreting and squamous cells. Similarly, strongly keratinizing, atypical cells are in favour of squamous cell carcinoma (fig. 7.4).

7.2.1.5.4. Large Cell Undifferentiated Carcinoma vs. Malignant Oncocytoma. Oncocytic carcinoma is composed of large, mononucleated or binucleated cells (fig. 7.39).

7.2.1.5.5. Large Cell Undifferentiated Carcinoma vs. Melanoma. Melanoma contains large mononucleated and binucleated cells with occasional intranuclear inclusions and melanin deposits. Specific immunocytochemistry may be useful in the differential diagnosis (fig. 11.1).

Large Cell Undifferentiated Carcinoma

In favour of the diagnosis

Clustered or isolated poorly-differentiated or undifferentiated cells

Difficulties

Binucleated cells

Against the diagnosis

Mucus-secreting, squamous, and intermediate cells; lymphocytic background, comedo-like necrosis

7.2.2. Lymphoepithelial Carcinoma (Nasopharyngeal Type)

These tumours are recognized by histological, clinical and sometimes by Epstein-Barr virus (EBV) serological findings. Salivary tumours have been mainly described in the EBV endemic geographical areas (Eskimos and Southeast Chinese). However, several families with a high incidence of salivary lymphoepithelial carcinoma have also been reported.

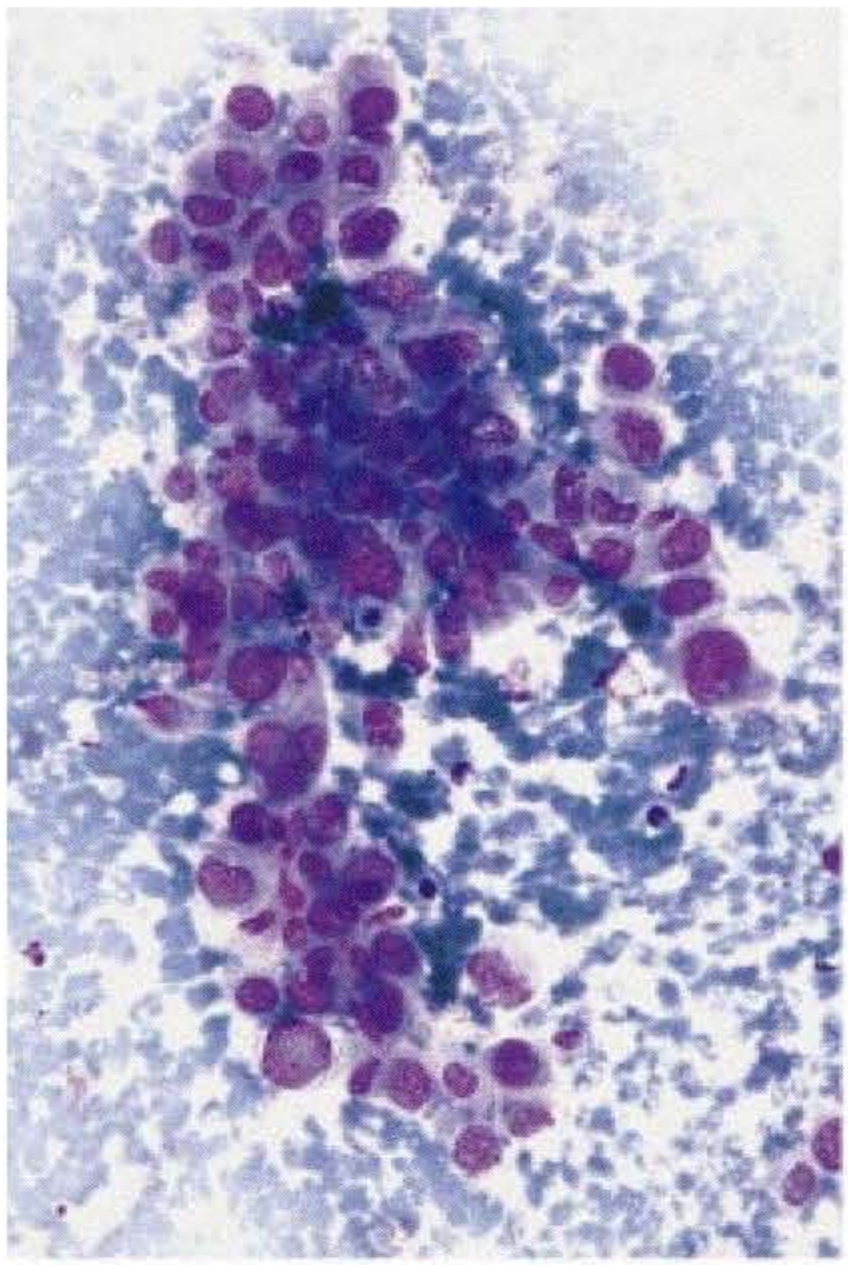

7.18

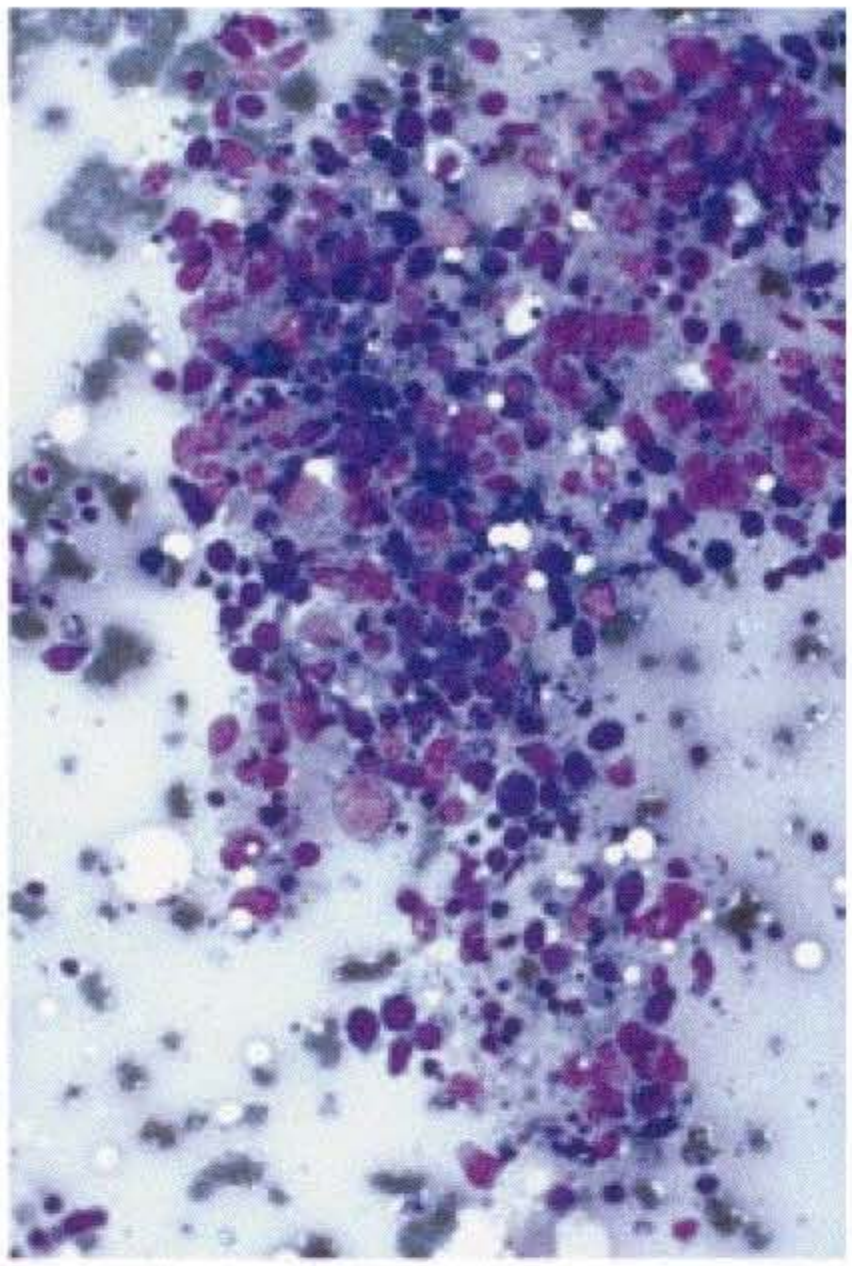

7.19

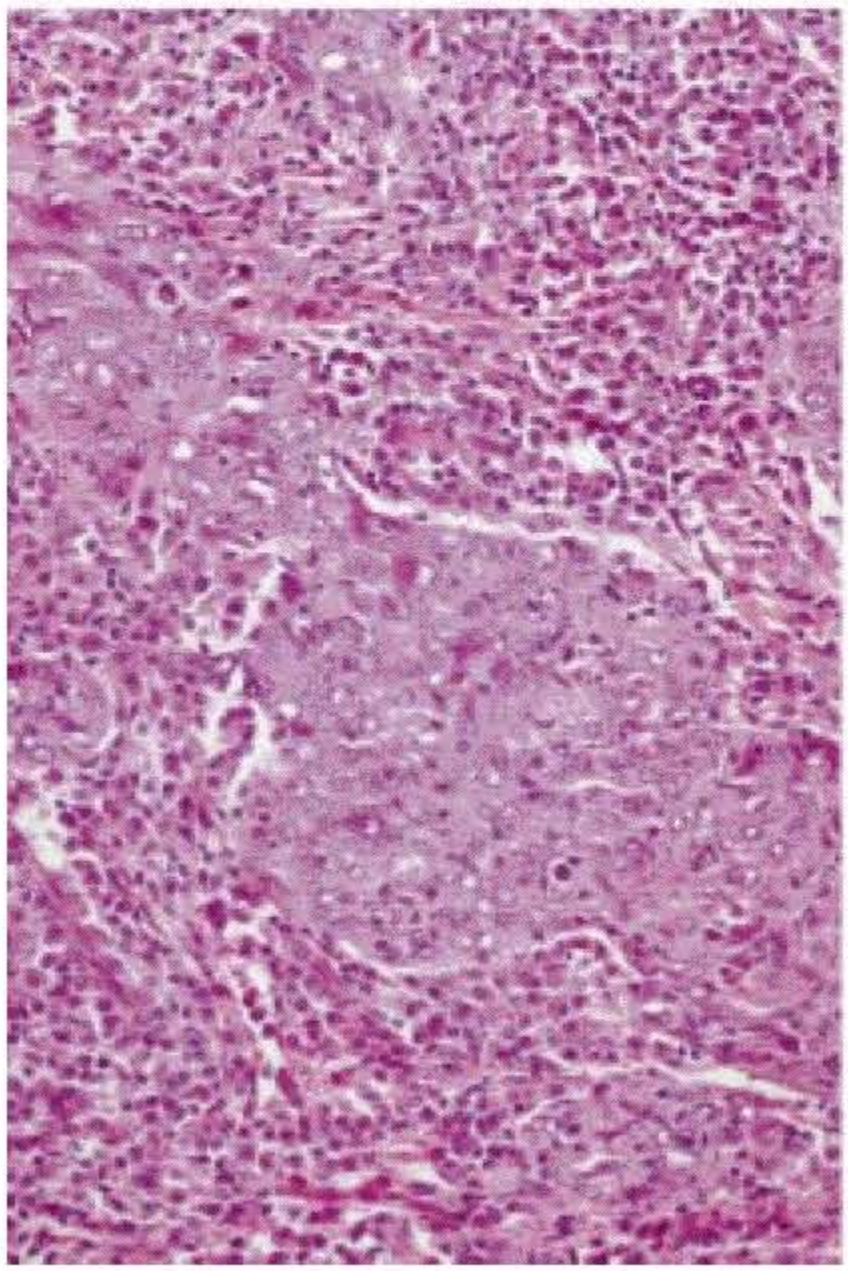

7.20

Fig. 7.18. Large cell undifferentiated carcinoma. Nonspecific cells corresponding to a high-grade neoplasm. MGG. E 128.

Fig. 7.19. Lymphoepithelial carcinoma of the parotid gland. Undifferentiated carcinomatous cells are intimately intermingled with lymphocytes and histiocytes. MGG. E 128.

Fig. 7.20. Lymphoepithelial carcinoma. Histological section corresponding to figure 7.19. HES. E 64.

Table 7.5. Correlation between cytology and histology of lymphoepithelial carcinomas

Author [ref.]	Number	Malignant	Suspicious	False-negative	Unsatisfactory
Günhan et al. [140]	2	2	0	0	0
Thompson et al. [329]	1	1	0	0	0
Stanley et al. [318]	1	1	0	0	0
Safneck et al. [292]	9	3	5	1	0
Khurana et al. [178]	1	1	0	0	0
Our series	4	3	1	0	0
Total	18	11 (61.1)	6 (33.3)	1 (5.6)	0

Statistics from the literature. % in parentheses.

7.2.2.1. General

There is slight female predominance (sex ratio: 1.25). Tumours often arise in the parotid glands, while the submandibular and sublingual glands are less frequently involved.

7.2.2.2. Histopathology

The histological classification of nasopharyngeal carcinoma [89, 243] is based on two histological types: keratinizing squamous cell carcinoma and poorly-differentiated or undifferentiated nonkeratinizing carcinoma [300].

7.2.2.3. Cytopathology

Lymphoepithelial carcinoma is characterized by syncytial clumps of large, polyhedral to spindle-shaped cells with vesicular optically empty nuclei and prominent nucleoli [49, 140, 178, 292]. Papanicolaou stain preserves chromatin structure and nucleoli are well seen even in poorly preserved samples. Stroma is mixed granulomatous and consists of abundant small lymphocytes and plasma cells (fig. 7.19, 7.20).

7.2.2.4. Diagnostic Accuracy

Cytological examples of lymphoepithelial carcinoma have been reported. Malignancy was diagnosed or suspected in 94.4% of cases, including our cases (table 7.5).

7.2.2.5. Differential Diagnosis

The differential diagnosis of this tumour includes Hodgkin's lymphoma and poorly-differentiated squamous cell carcinoma (table 7.6).

7.2.2.5.1. Lymphoepithelial Carcinoma vs. Hodgkin's Lymphoma. Hodgkin's lymphoma may involve salivary glands as a manifestation of systemic disease. Characteristic Reed-Sternberg cells and inflammatory polymorphous stroma with eosinophilic leukocytes may guide the differential diagnosis [318].

Table 7.6. Quantitative differential diagnosis of lymphoepithelial carcinoma

	Lymphoepithelial carcinoma	Squamous cell carcinoma	Hodgkin's lymphoma
Cells			
Spindle-shaped	+	+	–
Squamous	–	++	–
Keratin debris	–	++	–
Stroma			
Granulomatous	++	–	++
Necrotic	+/–	++	–

++ = Common; + = rare; – = absent.

7.2.2.5.2. Lymphoepithelial Carcinoma vs. Squamous Cell Carcinoma. Squamous cell carcinoma usually shows numerous squamous cells with variable degrees of keratinization, whereas lymphoepithelial carcinoma is composed of nonkeratinizing cells (fig. 7.15). Inflammatory polymorphous stroma is also absent in squamous cell carcinoma.

7.2.2.5.3. Lymphoepithelial Carcinoma, Primary vs. Lymphoepithelial Carcinoma, Metastatic. Primary parotid carcinoma is diagnosed after exclusion of undifferentiated nasopharyngeal carcinoma. It should be noted that a solitary metastasis to the parotid gland, without nodal involvement from nasopharynx, is rare.

Lymphoepithelial Carcinoma

In favour of the diagnosis

Clustered or isolated undifferentiated cells with prominent nucleoli; inflammatory/lymphocytic background; absence of keratinizing cells

Difficulties

Rare spindle-shaped cells

Against the diagnosis

Keratinizing cells; Reed-Sternberg cells

7.3. Carcinomas with Prominent Myoepithelial Cells

This constitutes a large group of distinctive tumours including high- and intermediate-grade malignancies: adenoid cystic carcinoma, epithelial-myoepithelial carcinoma (see comment 7.3.2.1) and malignant myoepithelioma. These malignancies may arise from pleomorphic adenoma. The differential diagnosis must also include low-grade malignancies and adenomas, especially low-grade polymorphous adenocarcinoma (which is often morphologically indistinguishable from adenoid cystic carcinoma), basal cell adenoma and basal cell adenocarcinoma.

7.3.1. Adenoid Cystic Carcinoma

7.3.1.1. General

Adenoid cystic carcinoma accounts for about 10% of all salivary gland tumours and is the commonest malignancy of submandibular and minor salivary glands [90, 315]. Adenoid cystic carcinoma usually occurs during the fifth to seventh decades of life, but cases have also been reported in young patients. Clinically, the patient presents with a slowly growing mass. Recurrences are the major problem and may indicate a fatal outcome [189, 315]. Metastases are common, mainly involving the lungs, lymph nodes and bones [316]. Tumours involving minor salivary glands, advanced clinical stage, duration of symptoms (less than 1 year), solid pattern and positive surgical margins are factors associated with a poor prognosis.

Malignant transformation of basal cell and pleomorphic adenomas into adenoid cystic carcinoma has been reported [89].

7.3.1.2. Histopathology

The histological patterns are cribriform (well-differentiated) in 45%, tubular (moderately-differentiated) in 35%, and solid (poorly-differentiated) in 10–20% [89]. Histologically, the tumour is composed of monomorphic basaloid cells with scant and slightly basophilic cytoplasm (MGG). Nuclear atypia and mitoses are rare. Squamous metaplasia, clear cells and spindle-shaped cells and papillary formations are rarely seen. Tumour cells are arranged in solid sheets, tubular formations or cribriform islands. There is a variable quantity of stroma and perineural permeation is commonly observed.

7.3.1.3. Cytopathology

Cytology smears are richly cellular and stroma-rich. Four characteristic stromal patterns may be seen [195]: (1) ovoid and round hyaline globules, varying considerably in size; these hyaline globules are sometimes numerous and arranged in 'bunches of grapes' (fig. 7.21, 7.22); (2) tubular and cylindrical structures with naked nuclei attached in the middle and separated at each end (fig. 7.23, 7.24); (3) finger-like bowl-shaped stromal structures with variable numbers of naked nuclei attached in the middle and separated at the blunt end (fig. 7.25, 7.26), and (4) acellular connective tissue debris with clearly demarcated borders (fig. 7.27).

The cellular material is monomorphic and composed of isolated and small clusters of basaloid-like cells with or without an extremely scant cytoplasm and with coarse nuclear chromatin (fig. 7.28, 7.29). Mild nuclear atypia (anisokaryosis or true pleomorphism) and squamous cells may occasionally be seen.

7.3.1.4. Diagnostic Accuracy

Adenoid cystic carcinoma has extensively been studied in the cytological literature. Table 7.7 shows several large series. Diagnoses of malignant and suspicious malignant lesions represent 86.2% of cases. False-negative results are mainly related to confusion with pleomorphic adenoma.

7.3.1.5. Differential Diagnosis

The presence of round hyaline globules should not automatically lead to a diagnosis of adenoid cystic carcinoma, as these elements may occasionally be seen in other benign and malignant salivary gland tumours, such as pleomorphic adenoma [198], basal cell adenoma [188], polymorphous low-grade adenocarcinoma [200] and epithelial-myoepithelial carcinoma [194] (table 7.8).

7.3.1.5.1. Adenoid Cystic Carcinoma vs. Cellular Pleomorphic Adenoma. Correct recognition of myoepithelial cells in pleomorphic adenoma with distinctive cytoplasmic borders is extremely important in the differential diagnosis. Adenoid cystic carcinoma lacks dispersed myoepithelial cells with well-demarcated cytoplasm [220] (fig. 6.3), while pleomorphic adenomas usually lack naked nuclei, which are frequently present in adenoid cystic carcinoma (fig.

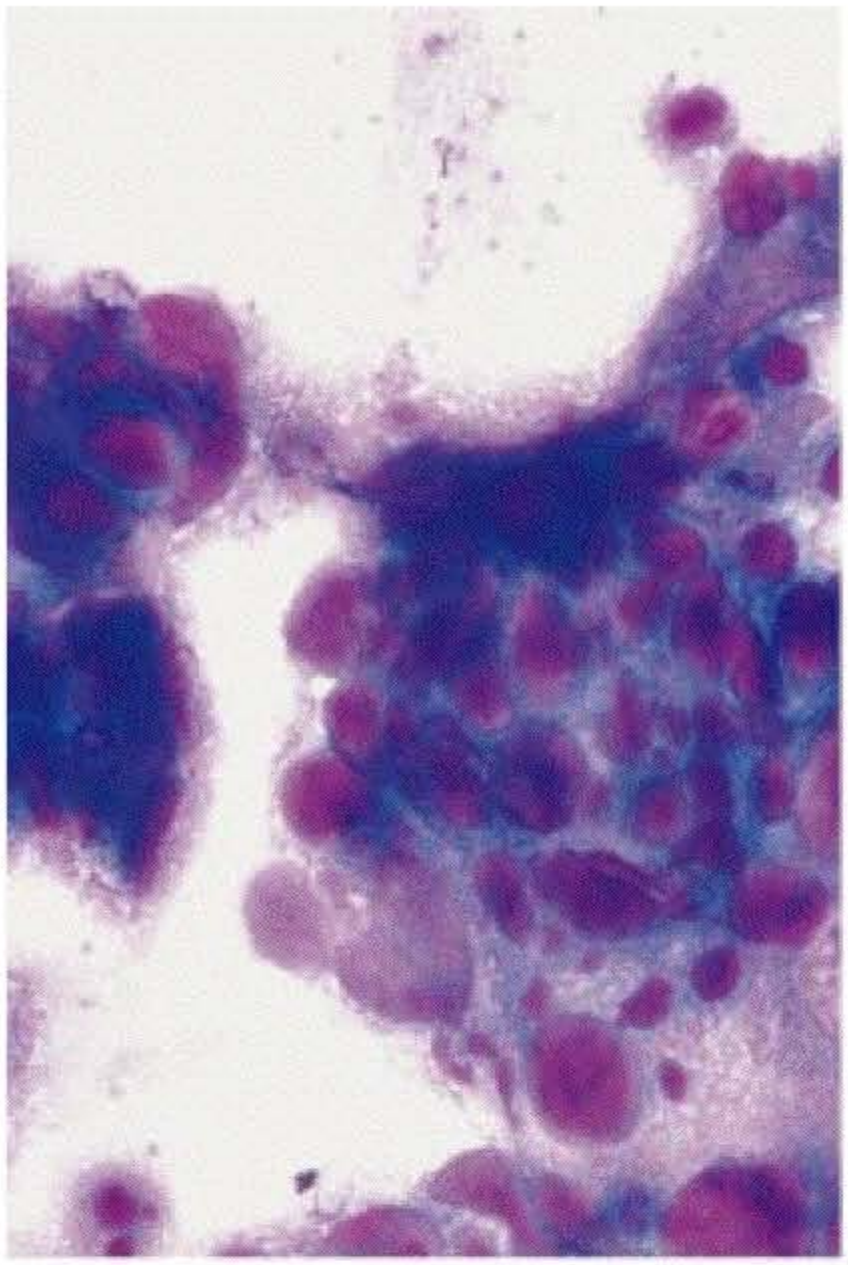

7.21

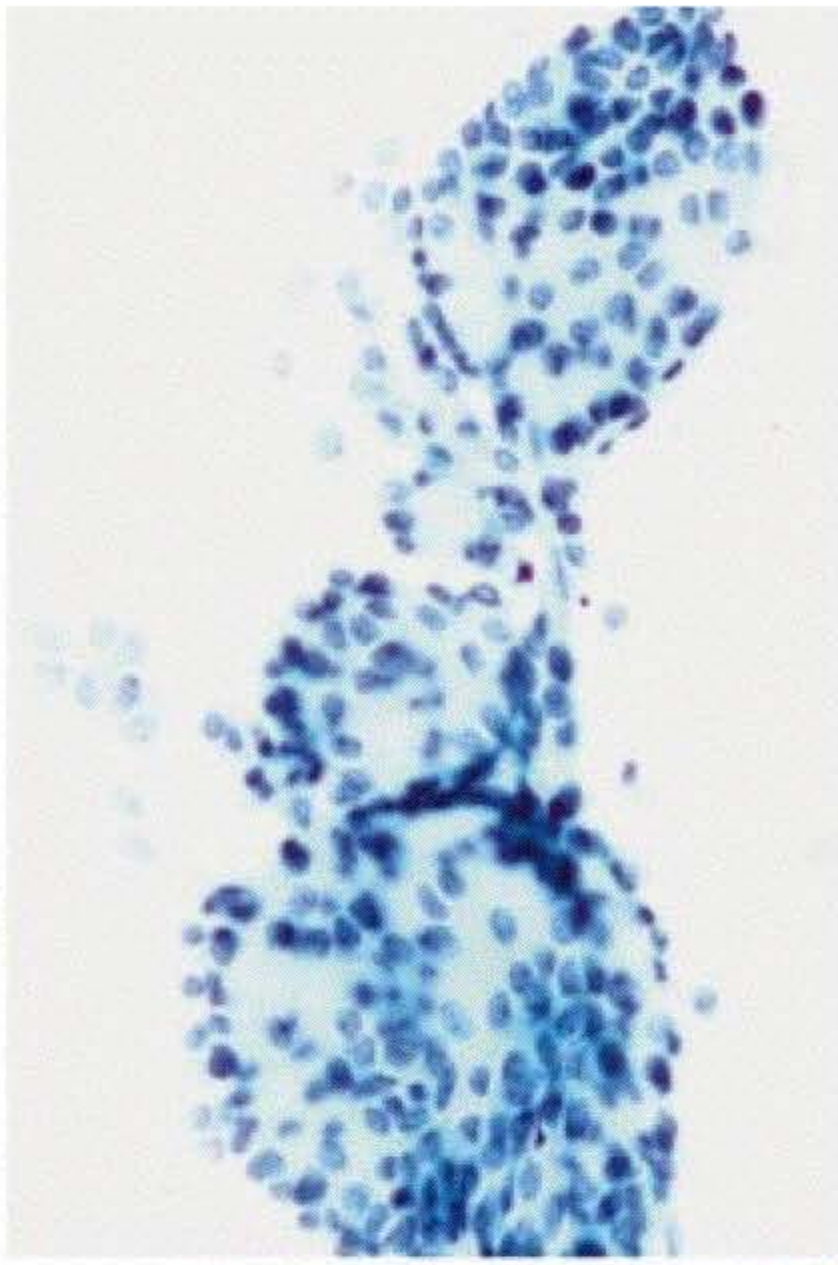

7.22

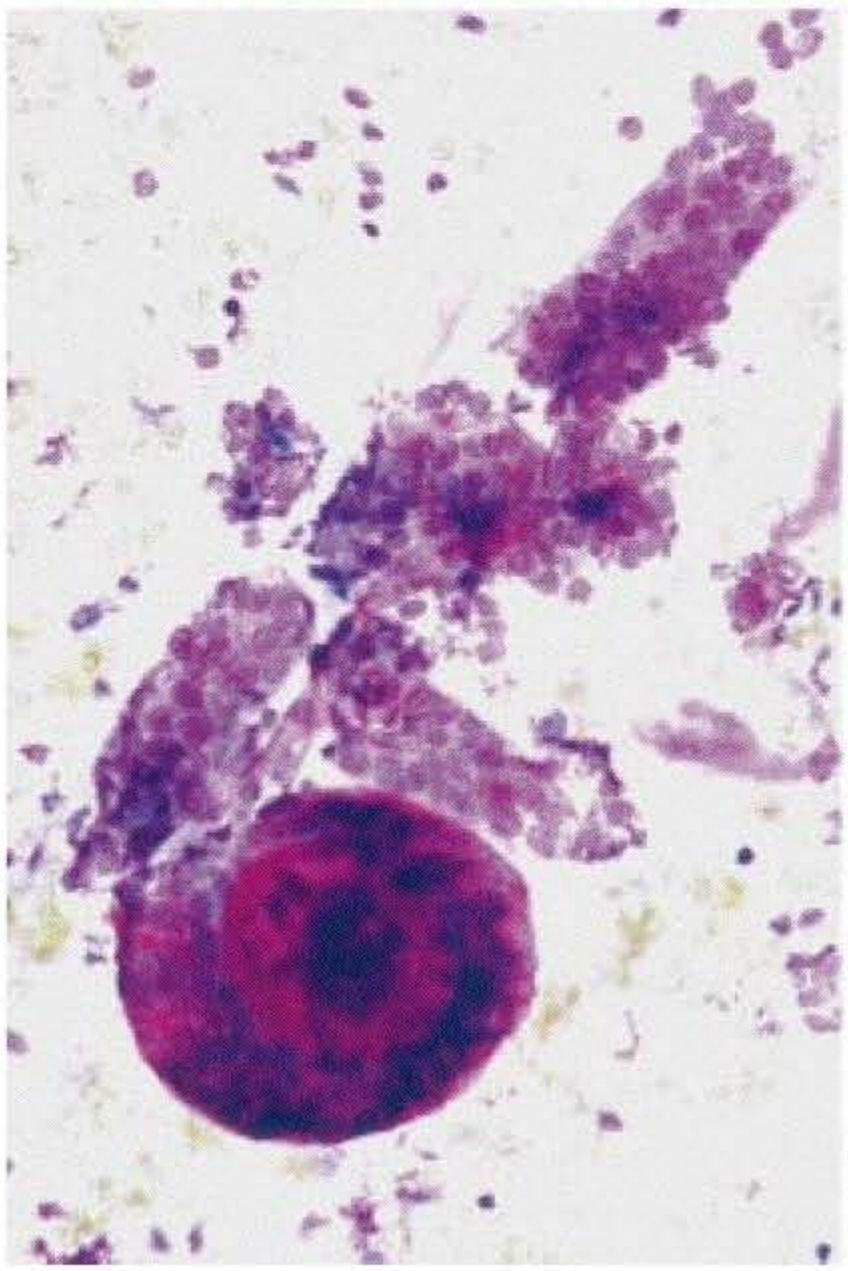

7.23

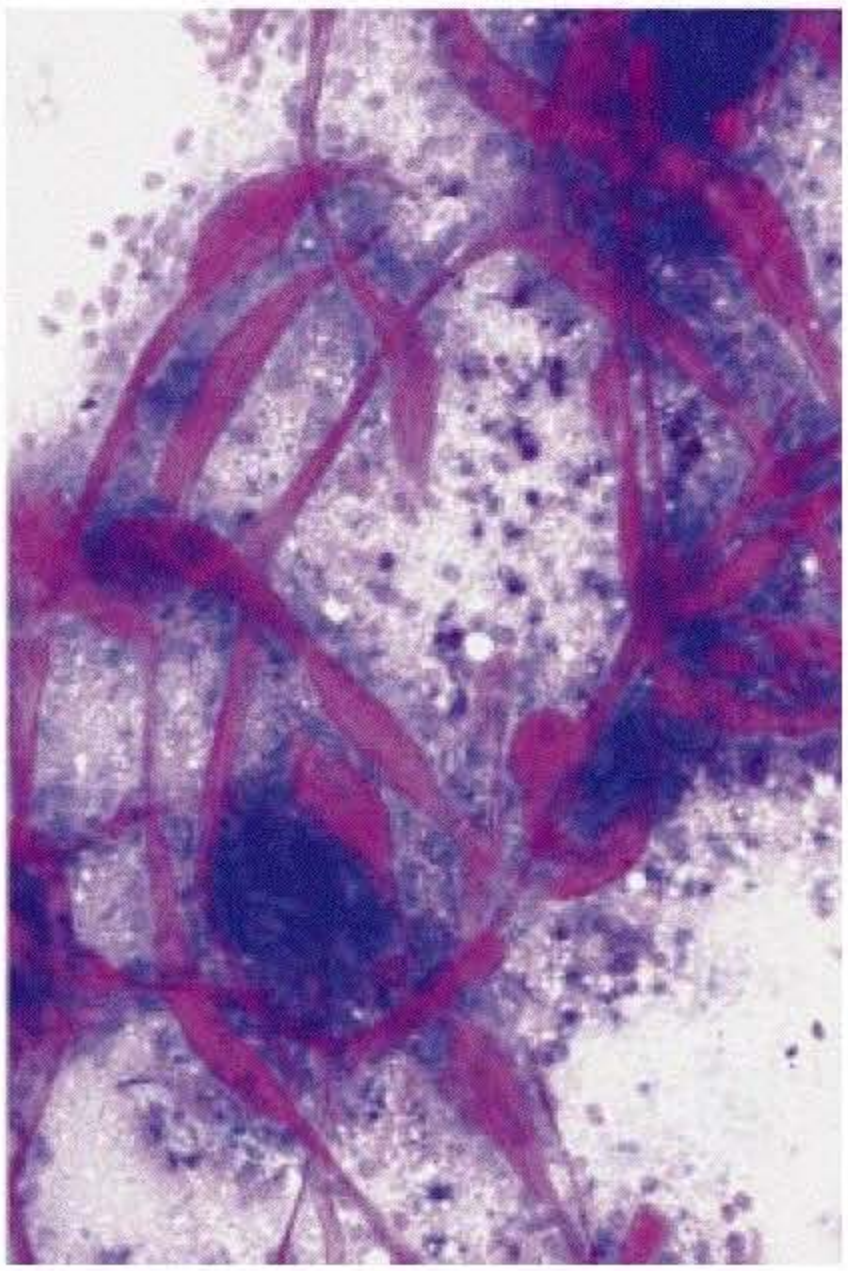

7.24

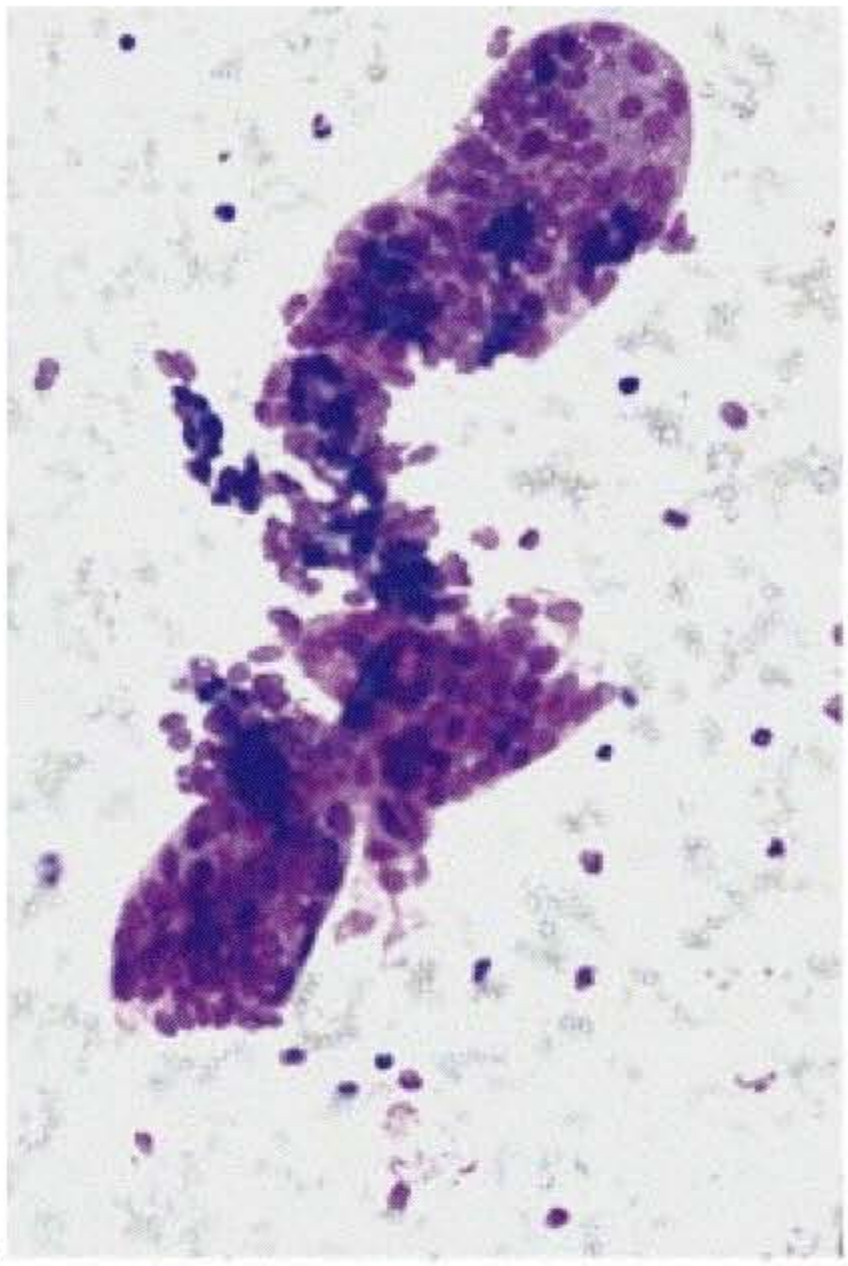

7.25

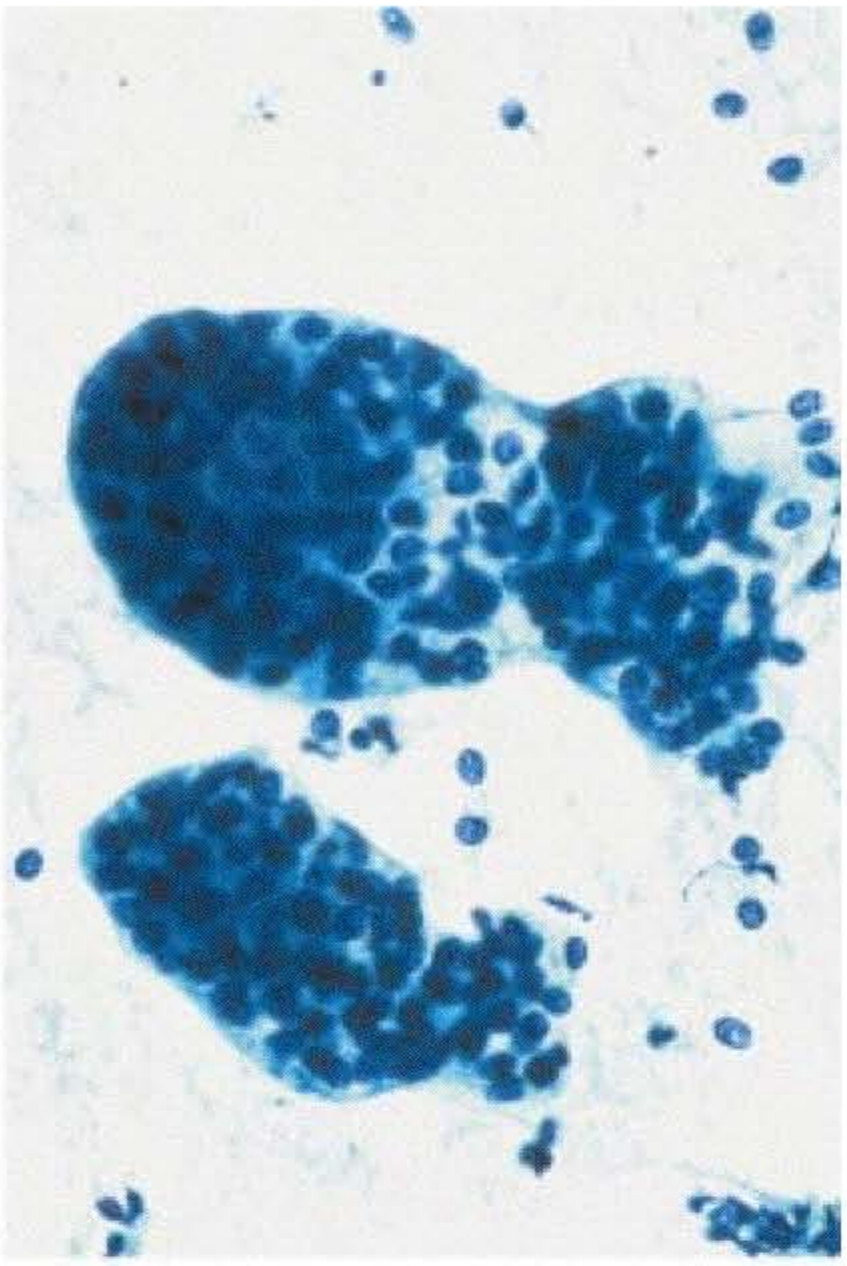

7.26

7.27

Fig. 7.21. Adenoid cystic carcinoma. Hyaline globules. MGG. ×64.

Fig. 7.22. Adenoid cystic carcinoma. Hyaline globules. Papanicolaou. ×128.

Fig. 7.23. Adenoid cystic carcinoma. Tubular and cylindrical structures, with naked nuclei attached in the middle and separated at each end. MGG. ×128.

Fig. 7.24. Adenoid cystic carcinoma. Long and thin tubular structures with cells at the periphery. MGG. ×64.

Fig. 7.25. Adenoid cystic carcinoma. Finger-like, bowl-shaped, stromal structures with variable numbers of naked nuclei attached in the middle and separated at the blunt end. MGG. ×128.

Fig. 7.26. Adenoid cystic carcinoma. Finger-like, bowl-shaped, stromal structures. Papanicolaou. ×128.

Fig. 7.27. Adenoid cystic carcinoma. Connective tissue debris with clearly demarcated borders. MGG. ×128.

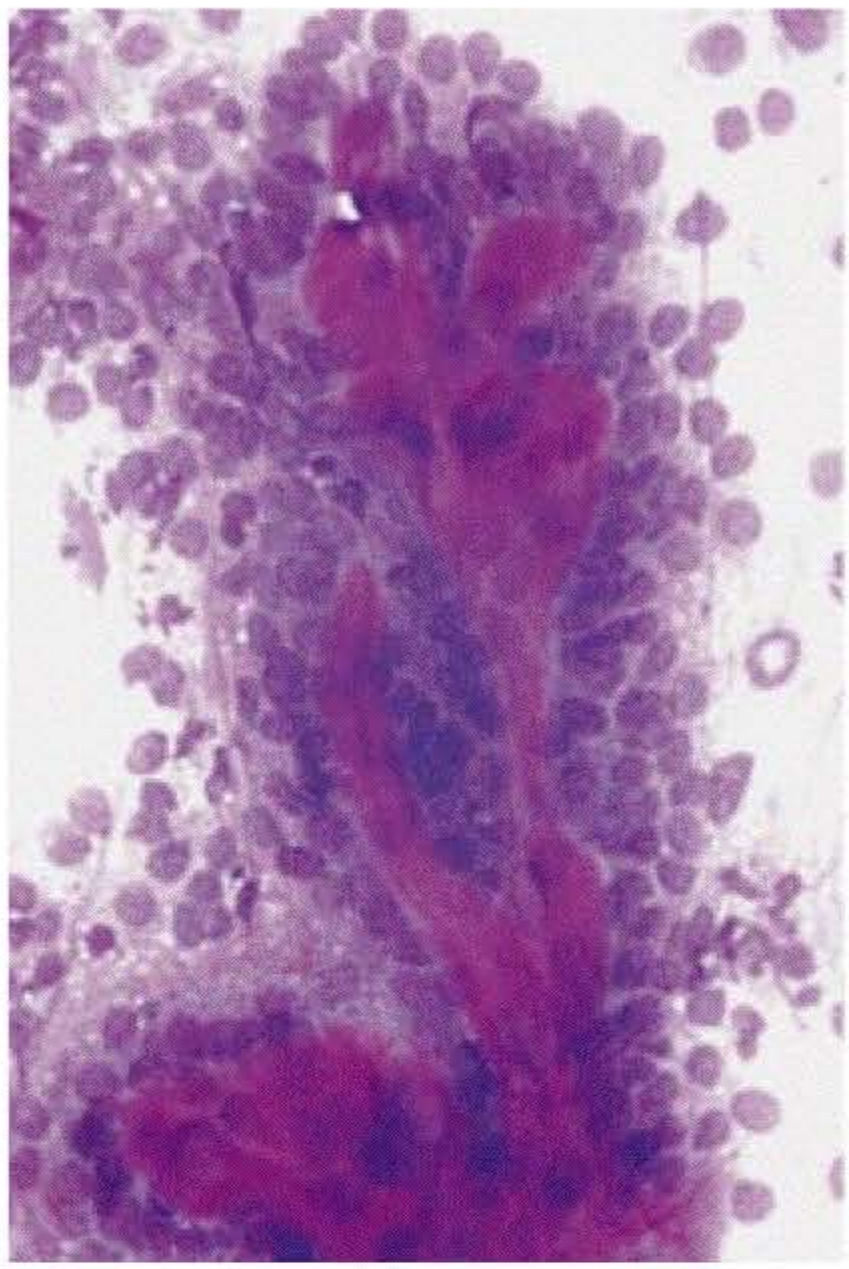

7.28

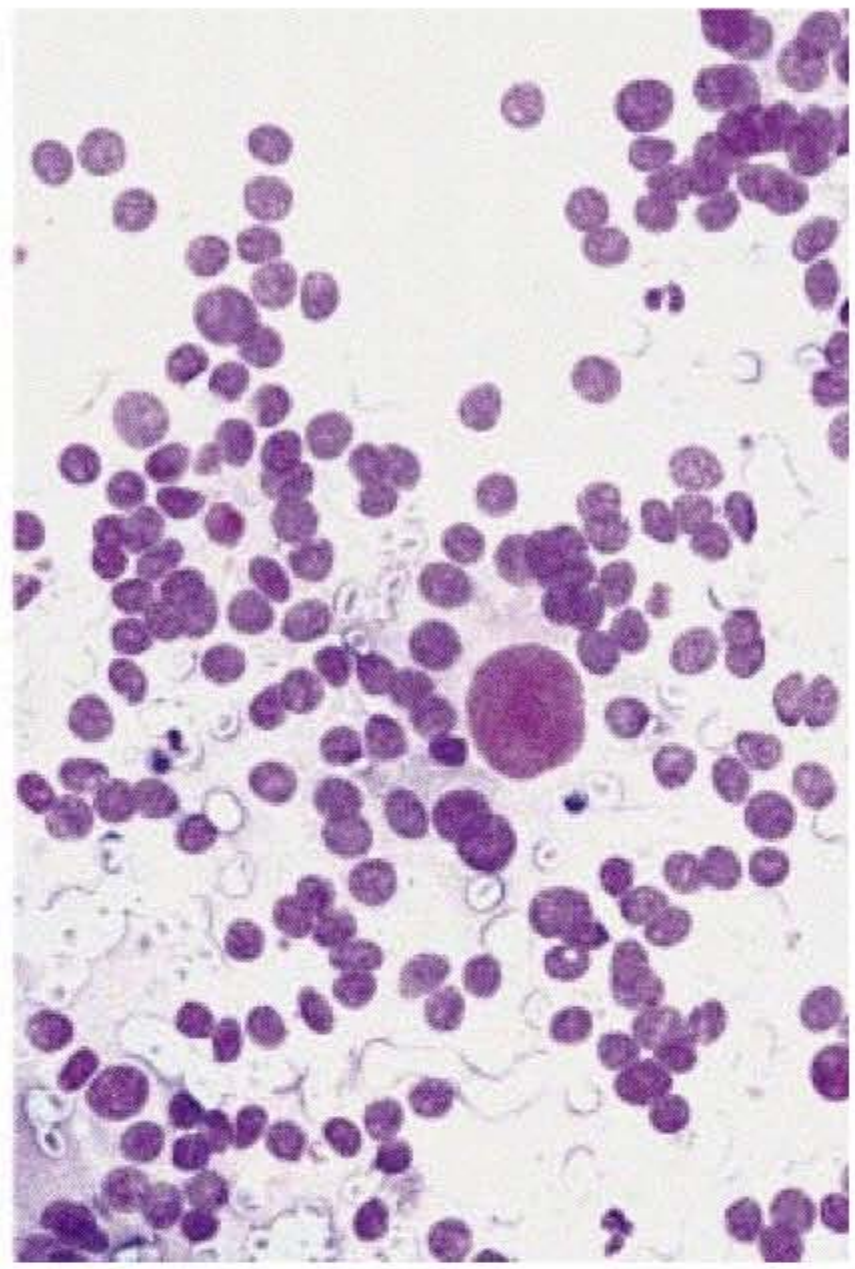

7.29

Fig. 7.28. Adenoid cystic carcinoma. Monomorphic cells with basaloid morphology with no or extremely scant cytoplasm and coarse chromatin. MGG. ×128.
Fig. 7.29. Adenoid cystic carcinoma. Basaloid cells with mild nuclear atypia. MGG. ×128.

Table 7.7. Correlation between cytology and histology of adenoid cystic carcinomas

Author [ref.]	Number	Malignant	Suspicious	False-negative	Unsatisfactory
Eneroth, Zajicek [100]	45	30	0	15	0
Persson, Zettergren [270]	6	5	0	0	1
Lindberg, Åkerman [222]	11	7	0	3	1
Qizilbash et al. [277]	3	3	0	0	0
O'Dwyer et al. [261]	8	6	1	1	0
Jayaram et al. [169]	7	6	0	1	0
Young et al. [351]	8	7	0	1	0
Smith Frable, Frable [313]	3	3	0	0	0
Zurrida et al. [358]	6	3	0	2	1
Orell [263]	11	10	0	1	0
Klijanienko, Vielh [195]	75	72	1	1	1
Nagel et al. [256]	64	53	6	5	0
Total	247	205 (83)	8 (3.2)	30 (12.2)	4 (1.6)

Statistics from the literature. % in parentheses.

Table 7.8. Quantitative differential diagnosis of adenoid cystic carcinoma

Component	Adenoid cystic carcinoma	Cellular pleomorphic adenoma	Basal cell tumours	Epithelial-myoepithelial carcinoma	Polymorphous low-grade adenocarcinoma
Cells					
Plasmacytoid	–	++	–	+/–	–
Basal	+/–	–	++	+/–	+
Naked nuclei	++	–	++	+/–	+/–
Squamous	+/–	+/–	+	–	–
Stroma					
Chondromyxoid	–	+	–	–	–
Mucoid	–	+/–	–	–	–
Tubular structures	++	–	–	–	–
Finger-like structures	++	–	–	–	
Globules	++	+/–	+/–	+	++

++ = Common; + = rare; +/– = occasionally seen; – = absent.

7.23). Hyaline globules are numerous in adenoid cystic carcinoma, but infrequent in pleomorphic adenoma, and nuclear chromatin is coarse in adenoid cystic carcinoma (fig. 7.28).

7.3.1.5.2. Adenoid Cystic Carcinoma vs. Basal Cell Adenoma and Basal Cell Adenocarcinoma. Cytological differences between adenoid cystic carcinoma and basal cell adenoma are often subtle, and include the arrangement of basaloid cells and the distribution of background material [188]. Tubular or finger-like structures rather than hyaline globules are suggestive of adenoid cystic carcinoma (fig. 7.23, 7.25, 7.27). Unlike adenoid cystic carcinomas, basal cell adenomas are composed of small, regular, ovoid to round cells with scanty cytoplasm and a bland nuclear chromatin. Staining differences of the matrix of the globules are observed between the two tumour types. In addition to cytological features, the presence of mitotic figures and necrosis may also be highly suggestive of solid-type adenoid cystic carcinoma [188].

7.3.1.5.3. Adenoid Cystic Carcinoma vs. Polymorphous Low-Grade Adenocarcinoma. The morphology of polymorphous low-grade adenocarcinoma often resembles that of adenoid cystic carcinoma and consists of various growth patterns ranging from solid to tubular, papillary, cribriform (pseudoadenoid cystic) or fascicular, while the cells are always small to medium-sized, regular, and without nuclear atypia (fig. 8.22, 8.23) [200]. Polymorphous low-grade adenocarcinoma affects the palate more frequently than adenoid cystic carcinoma. Mistaking polymorphous low-grade adenocarcinoma for adenoid cystic carcinoma on cytology smears is not dramatic, as both tumours are malignant: polymorphous low-grade adenocarcinoma is a low-grade malignancy, whereas tubulo-cribriform and solid variants of adenoid cystic carcinoma are intermediate and high-grade tumours, respectively.

7.3.1.5.4. Adenoid Cystic Carcinoma vs. Epithelial-Myoepithelial Carcinoma. The cytological features of epithelial-myoepithelial carcinoma are sometimes difficult to recognize due to the morphological similarities with adenoid cystic carcinoma [194]. They include three-dimensional cellular aggregates of basaloid cells, with clear cells at the periphery of clusters, and the presence of acellular hyaline material (fig. 7.30, 7.31). The presence of basaloid cells and amorphous stromal substance may be reminiscent of adenoid cystic carcinoma, but the presence of clear cells is distinctive.

7.3.1.5.5. Adenoid Cystic Carcinoma vs. Nonsalivary Tumours. Hyaline globules may occasionally be seen in nonsalivary gland tumours such as dermal eccrine spiradenoma [30, 205], basal cell carcinoma of the skin [234], and basaloid-squamous carcinoma of the head and neck (fig. 9.19) [126]. The main differential diagnosis is basaloid squamous carcinoma of the head and neck, but the presence of distinctive squamous differentiation should facilitate the differential diagnosis.

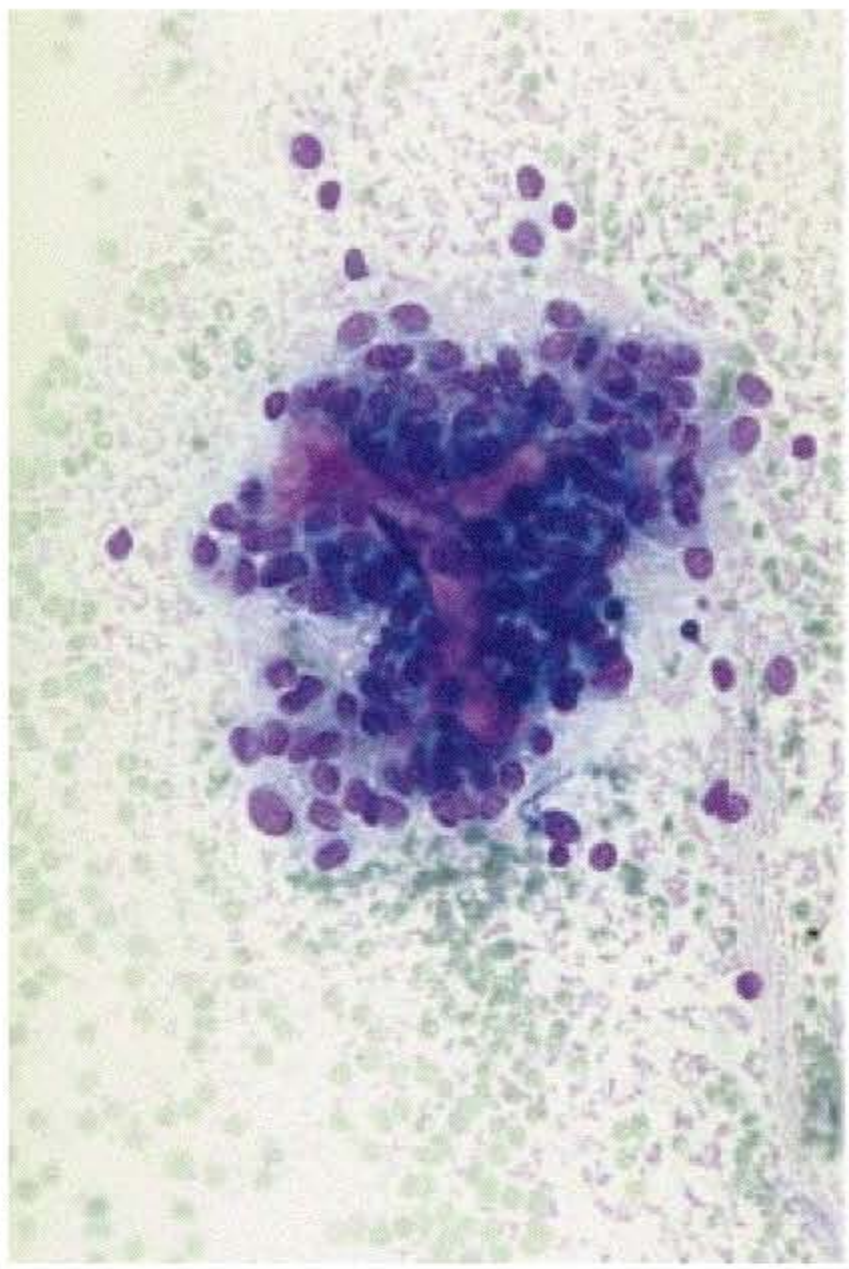

7.30

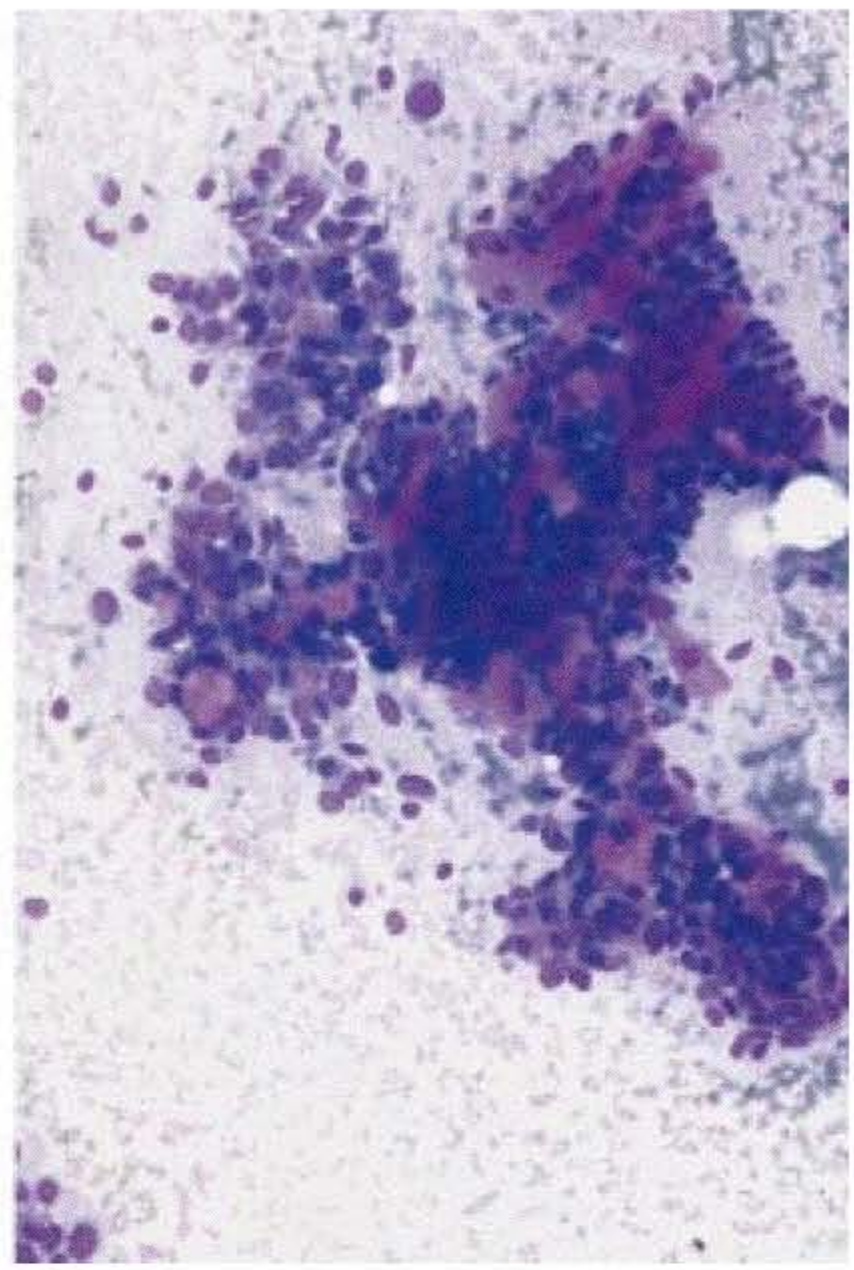

7.31

Fig. 7.30. Epithelial-myoepithelial carcinoma. Clusters of monotonous oval cells. Cytoplasm is either abundant and slightly basophilic or scant. MGG. ×128.
Fig. 7.31. Epithelial-myoepithelial carcinoma. Pseudopapillary formations with strongly eosinophilic stromal cores. MGG. ×128.

Adenoid Cystic Carcinoma

In favour of the diagnosis

Hyaline globules, tubular and cylindrical structures, finger-like, bowl-shaped stromal structures, naked nuclei

Difficulties

Necrosis and mitotic figures in solid-type, squamous cells

Against the diagnosis

Plasmacytoid cells with well-defined cytoplasmic borders, chondromyxoid stroma, three-dimensional basaloid clusters, clear cells

7.3.2. Epithelial-Myoepithelial (Clear Cell) Carcinoma

The classification of epithelial-myoepithelial carcinoma and clear cell carcinoma remains controversial. Epithelial-myoepithelial carcinoma presents a wide spectrum of cellular differentiation, and tumours may be exclusively composed of clear myoepithelial cells (clear cell carcinoma), or may contain a mixture of ductal cells distributed in round or cylindrical groups surrounded by large, clear myoepithelial cells (epithelial-myoepithelial carcinoma) [26, 67]. Batsakis [20] suggested that clear cell tumours are variants of epithelial-myoepithelial carcinoma in which ductal differentiation is inconspicuous (monomorphic epithelial-myoepithelial carcinoma). Similarly, the most recent WHO classification [300] has combined both clear cell carcinoma and myoepithelial carcinoma as a single entity. However, since the term 'epithelial-myoepithelial' implies a biphasic differentiation, other investigators [55, 90] classify monomorphous clear cell carcinomas separately.

The entity termed 'hyalinizing clear cell carcinoma' [245] is not included in the recent WHO classification [300] and has never been reported in the cytological literature.

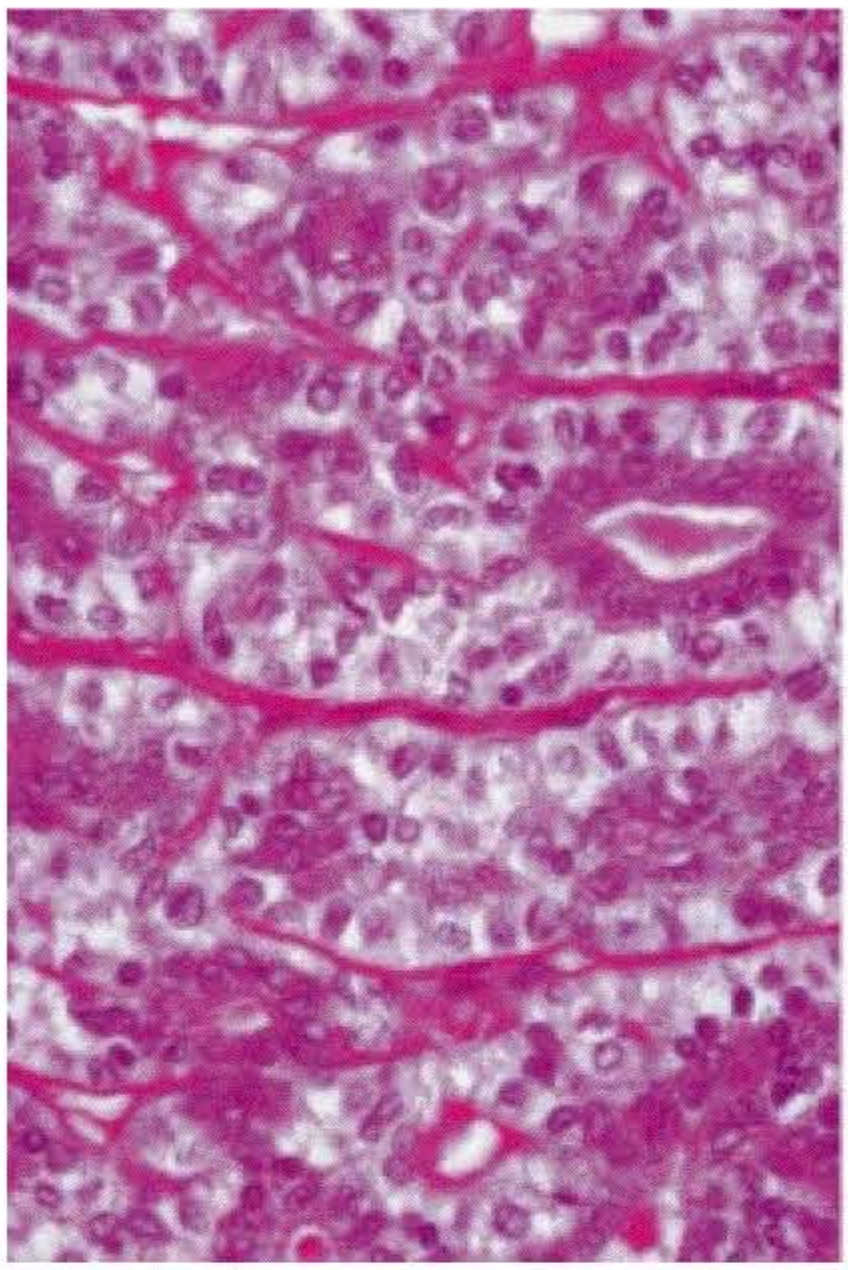

7.32

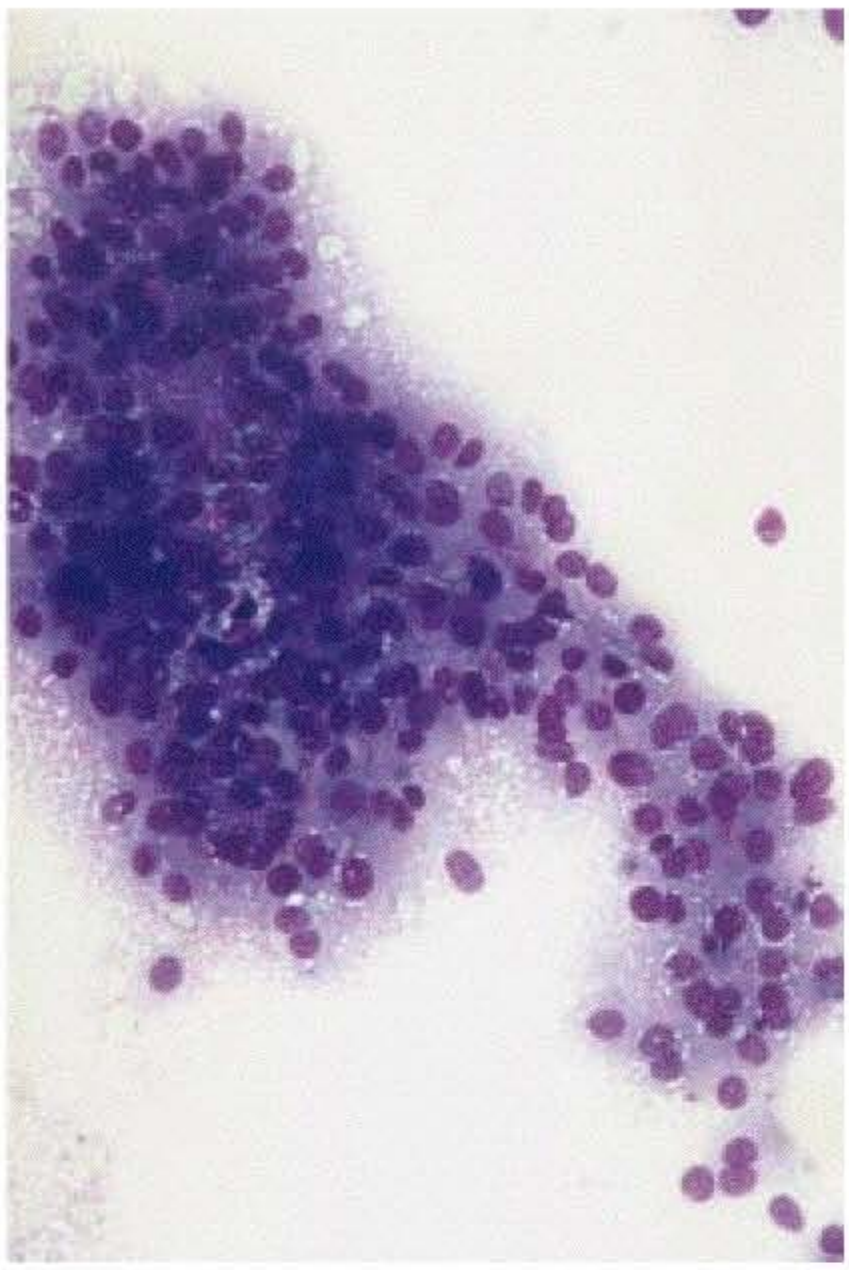

7.33

Fig. 7.32. Epithelial-myoepithelial carcinoma. Histological section corresponding to figure 7.31. HES. ×128.
Fig. 7.33. Epithelial-myoepithelial carcinoma. Microvacuolated cytoplasm. MGG. ×128.

7.3.2.1. General

Approximately 100 cases of epithelial-myoepithelial carcinoma have been reported [89]. The clear cell variant without ductal structures mainly occurs in the intraoral minor salivary glands, whereas epithelial-myoepithelial carcinoma usually arises in the parotid gland [249]. They account for less than 1% of all types of primary salivary gland tumours, with a peak incidence in the seventh and eighth decades, and a twofold higher incidence in women than in men. Clinically, epithelial-myoepithelial carcinoma is an intermediate-grade malignancy [89].

7.3.2.2. Histopathology

These tumours are derived from the intercalated ducts and may produce tubules composed of two cell types: epithelial and myoepithelial [89]. A spectrum of morphological appearances may be seen. Classically, clear cell carcinomas are divided into four architectural subtypes according to the predominant cellular organization: solid, tubular, cribriform and papillary. Several tumours are exclusively composed of clear myoepithelium-derived cells with no evidence of lumina or lumen-lining basophil cells. The cytoplasm of clear cells tends to be hydropic and contains glycogen. These cells are arranged in round or trabecular sheets, whereas epithelial cells are arranged in tubes or are disseminated without any glandular differentiation. The growth pattern may vary from solid lobules, separated by hyalinized fibrous septa, to irregular, papillary cystic arrangements. Nuclei show varying degrees of atypia, which may be correlated with a poor prognosis [112]. Necrosis is common.

7.3.2.3. Cytopathology

The smears contain both cellular and stromal components [194]:

– The cellular material always includes both isolated cells and clusters of oval cells. The cells are frequently arranged in pseudopapillary formations with intensely eosinophilic stromal cores on MGG stain (fig 7.30–7.32). The cytoplasm is either abundant and slightly basophilic or scant. The cells rarely present a vacuolated cytoplasm and,

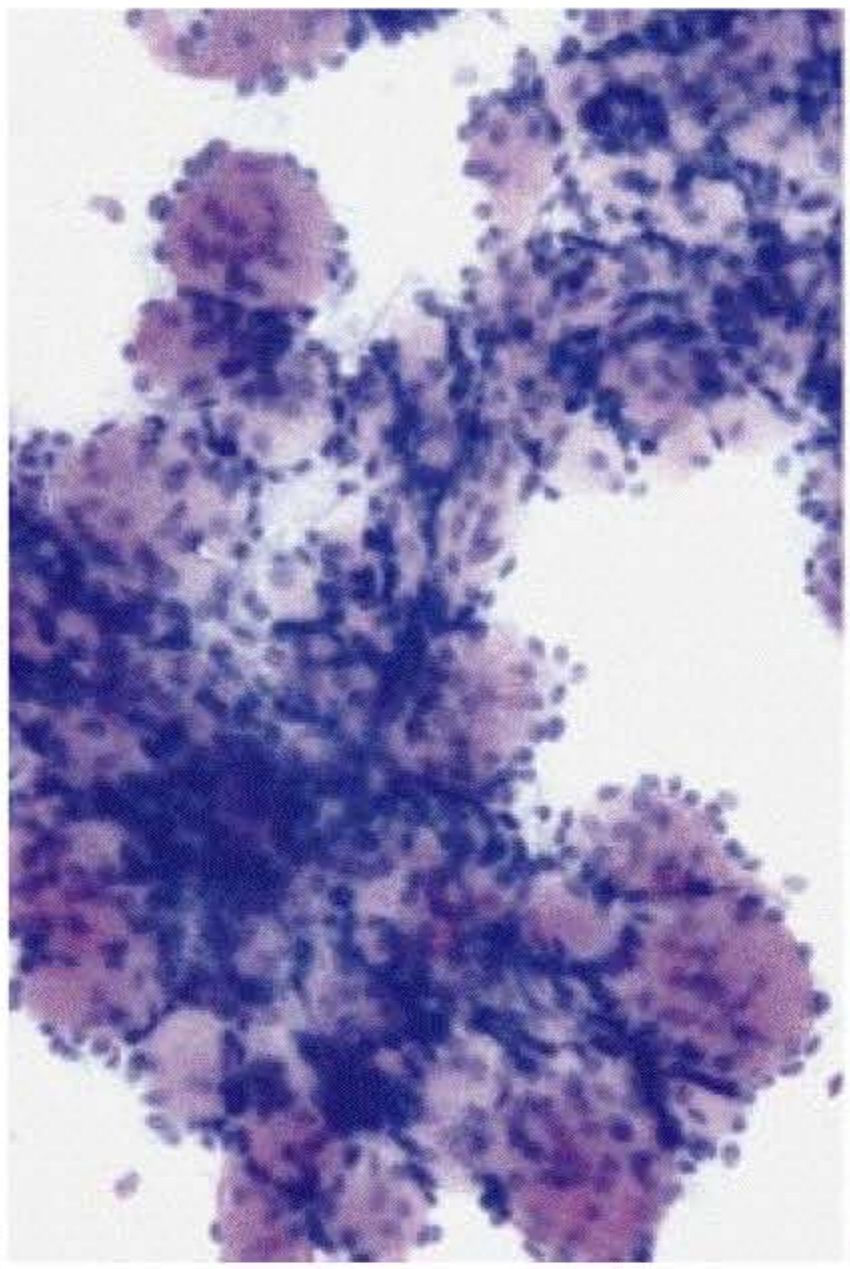

7.34

7.35

Fig. 7.34. Epithelial-myoepithelial carcinoma. Round hyaline globules surrounded by polyhedral cells. MGG. E 64.
Fig. 7.35. Epithelial-myoepithelial carcinoma. Hyaline globules and tubular structures. Papanicolaou. E 64.

interestingly, no obvious clear cells are seen on MGG-stained smears (fig. 7.33), but clear cells may be demonstrated by Papanicolaou stain. Plasmacytoid cells and naked nuclei are occasionally present.

– Stromal round hyaline globules, surrounded by polyhedral cells, suggestive of adenoid cystic carcinoma may be seen (fig. 7.34, 7.35). Eosinophilic stromal fragments, scant mucoid and inflammatory cells may also be observed in the background.

7.3.2.4. Diagnostic Accuracy

Only 16 cases have been reported to date (table 7.9), and 82% of carcinomas were diagnosed or suspected.

7.3.2.5. Differential Diagnosis

The many difficulties and pitfalls encountered in the diagnosis of salivary gland clear cell tumours have been described in the cytopathological literature. Epithelial-myoepithelial carcinoma may present similar features to adenoid cystic carcinoma and polymorphous low-grade adenocarcinoma and the differential diagnosis between these entities may therefore be sometimes extremely difficult. Cellular pleomorphic adenoma, acinic cell carcinoma, and metastatic renal cell carcinoma should also be considered in the differential diagnosis (table 7.10).

7.3.2.5.1. Epithelial-Myoepithelial Carcinoma vs. Adenoid Cystic Carcinoma. The cytological differential diagnosis between epithelial-myoepithelial carcinoma and adenoid cystic carcinoma may be very difficult due to the occasional presence of hyaline globules, with an intense magenta stain on MGG in epithelial-myoepithelial carcinoma, and three-dimensional cellular aggregates of basaloid cells which are clear at the periphery of clusters (fig. 7.24, 7.34). As previously described, we believe that cylindrical and finger-like structures are in favour of adenoid cystic carcinoma (fig. 7.23–7.25, 7.27) [195]. The presence of clear or vacuolated cells is also an element against the diagnosis of adenoid cystic carcinoma (fig. 7.33).

Table 7.9. Correlation between cytology and histology of epithelial-myoepithelial carcinomas

Author [ref.]	Number	Malignant	Suspicious	False-negative	Unsatisfactory
Qizilbash et al. [278]	1	0	0	0	1
Carillo et al. [44]	1	1	0	0	0
Arora et al. [11]	1	1	0	0	0
Woyke, Jach [344]	1	1	0	0	0
Kocjan et al. [203]	1	0	0	1	0
Layfield, Glasgow [215]	2	2	0	0	0
Orell [263]	1	0	1	0	0
Zocchi et al. [357]	1	0	1	0	0
Wax, Layfield [339]	1	1	0	0	0
Stewart et al. [324]	1	0	0	1	0
Klijanienko, Vielh [194]	5	5	0	0	0
Total	16	11 (68.7)	2 (12.5)	2 (12.5)	1 (6.3)

Statistics from the literature. % in parentheses.

Table 7.10. Quantitative differential diagnosis of epithelial-myoepithelial carcinoma

Component	Epithelial-myoepithelial carcinoma	Adenoid cystic carcinoma	Polymorphous low-grade adeno-carcinoma	Cellular pleomorphic adenoma	Acinic cell carcinoma	Renal cell carcinoma
Cells						
Pseudopapillae	+	+/–	++	+/–	–	+/–
Vacuolated	+	–	–	–	++	++
Plasmacytoid	+/–	–	–	++	–	–
Squamous	–	+/–	–	+/–	–	–
Naked nuclei	+/–	++	+/–	–	++	++
Stroma						
Chondromyxoid	–	–	–	+	–	–
Globules	+	++	++	+/–	–	–

++ = Common; + = rare; +/– = occasionally; – = absent.

7.3.2.5.2. Epithelial-Myoepithelial Carcinoma vs. Polymorphous Low-Grade Adenocarcinoma. Polymorphous low-grade adenocarcinoma is another differential diagnostic problem, due to the presence of pseudopapillary formations and hyaline globules (fig. 8.23, 8.24). In polymorphous low-grade adenocarcinoma, smears are composed of isolated cells and clusters of cells with a polyhedral or oval shape. Cytoplasmic vacuolization or clear cells are not seen. The cells are frequently arranged in pseudopapillary formations with a dendritic stromal core [200].

7.3.2.5.3. Epithelial-Myoepithelial Carcinoma vs. Cellular Pleomorphic Adenoma. Smears containing scattered cells with a myoepithelial (plasmacytoid) morphology and eosinophilic stromal fragments may lead to an incorrect diagnosis of pleomorphic adenoma. Numerous plasmacytoid cells with abundant cytoplasm and chondromyxoid matrix are characteristic of pleomorphic adenoma, whereas the cells of epithelial-myoepithelial carcinoma have scant cytoplasm (fig. 6.3). The presence of naked nuclei also argues against a diagnosis of pleomorphic adenoma.

7.3.2.5.4. Epithelial-Myoepithelial Carcinoma vs. Acinic Cell Carcinoma. The presence of clear, vacuolated cells in epithelial-myoepithelial carcinoma should be differentiated from acinic cell carcinoma [193]. Acinic cell carcinoma is characterized by clusters of cells with small nuclei and a finely vacuolated cytoplasm (fig. 8.12, 8.16). In contrast

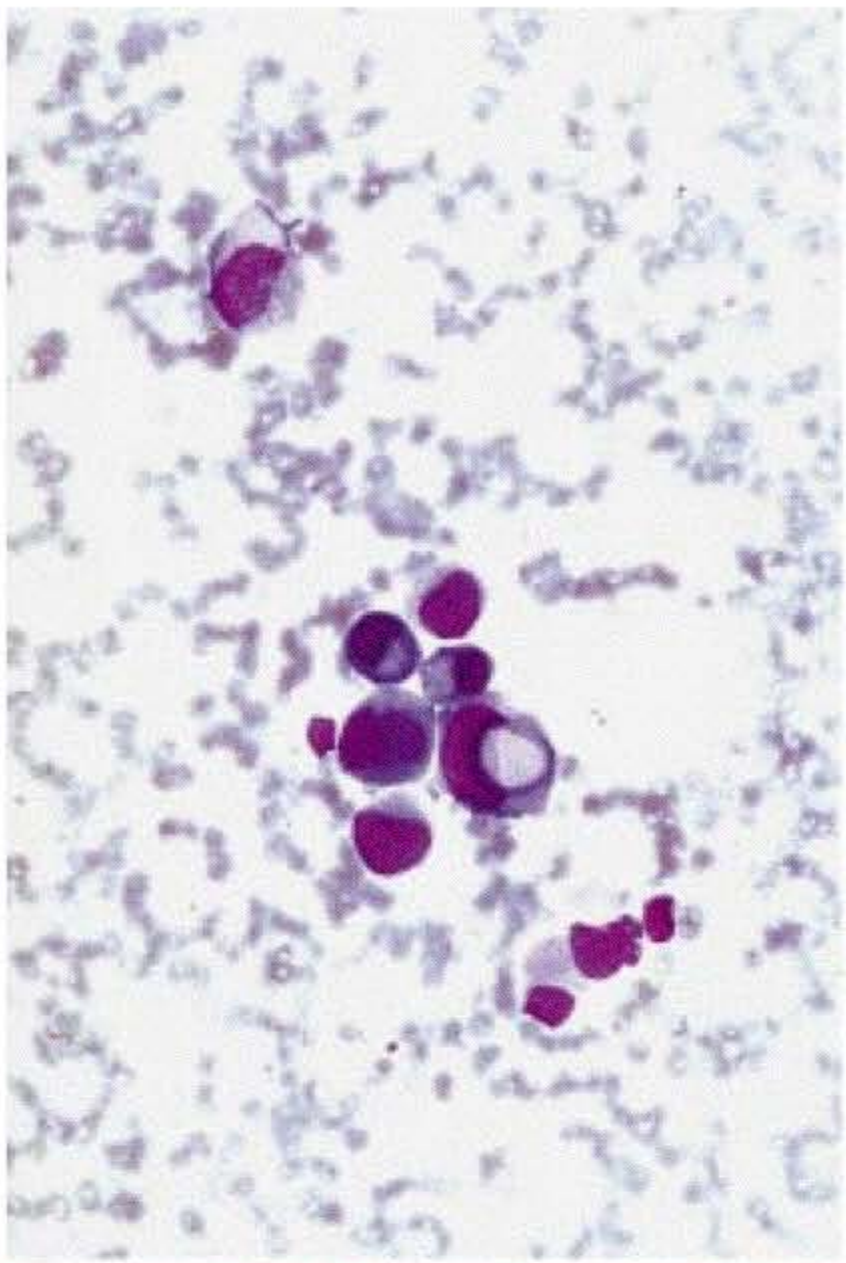

7.36

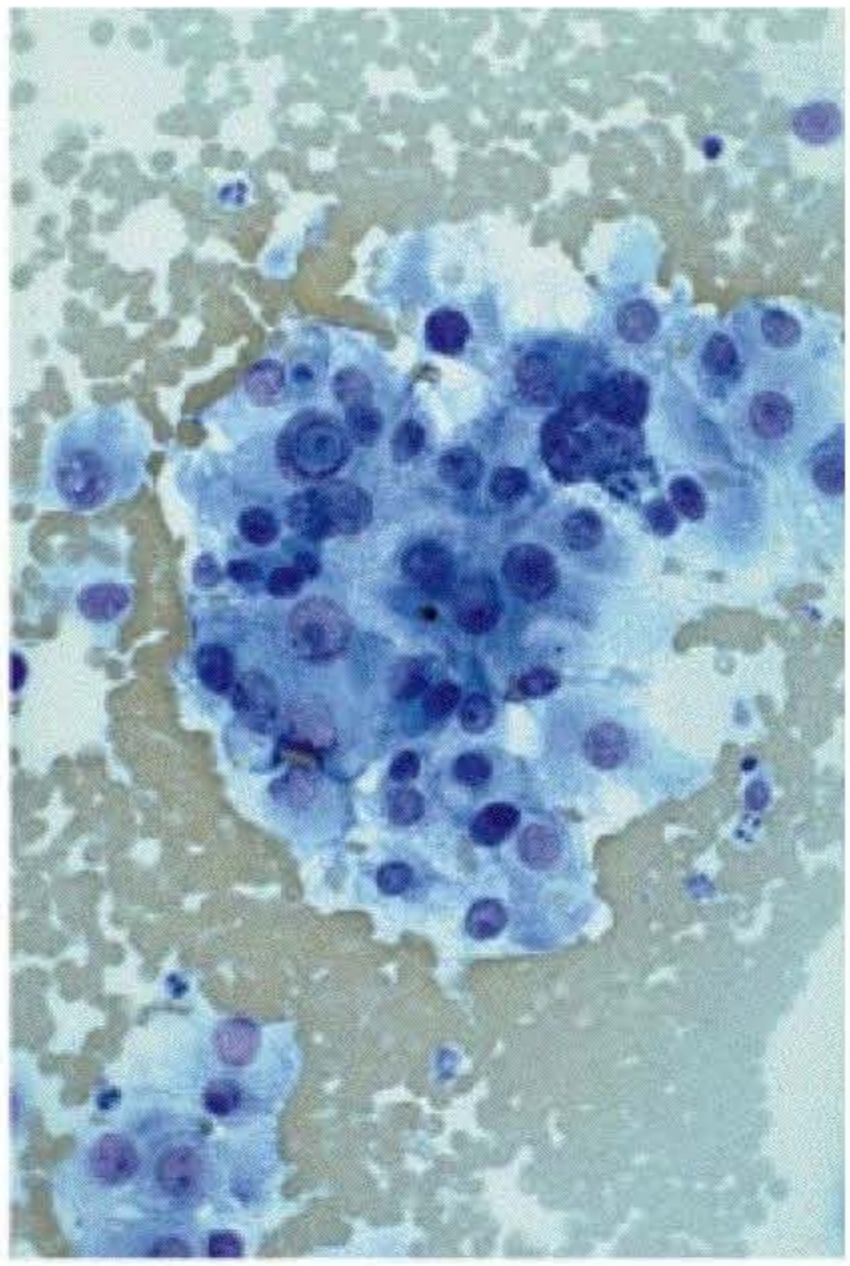

7.37

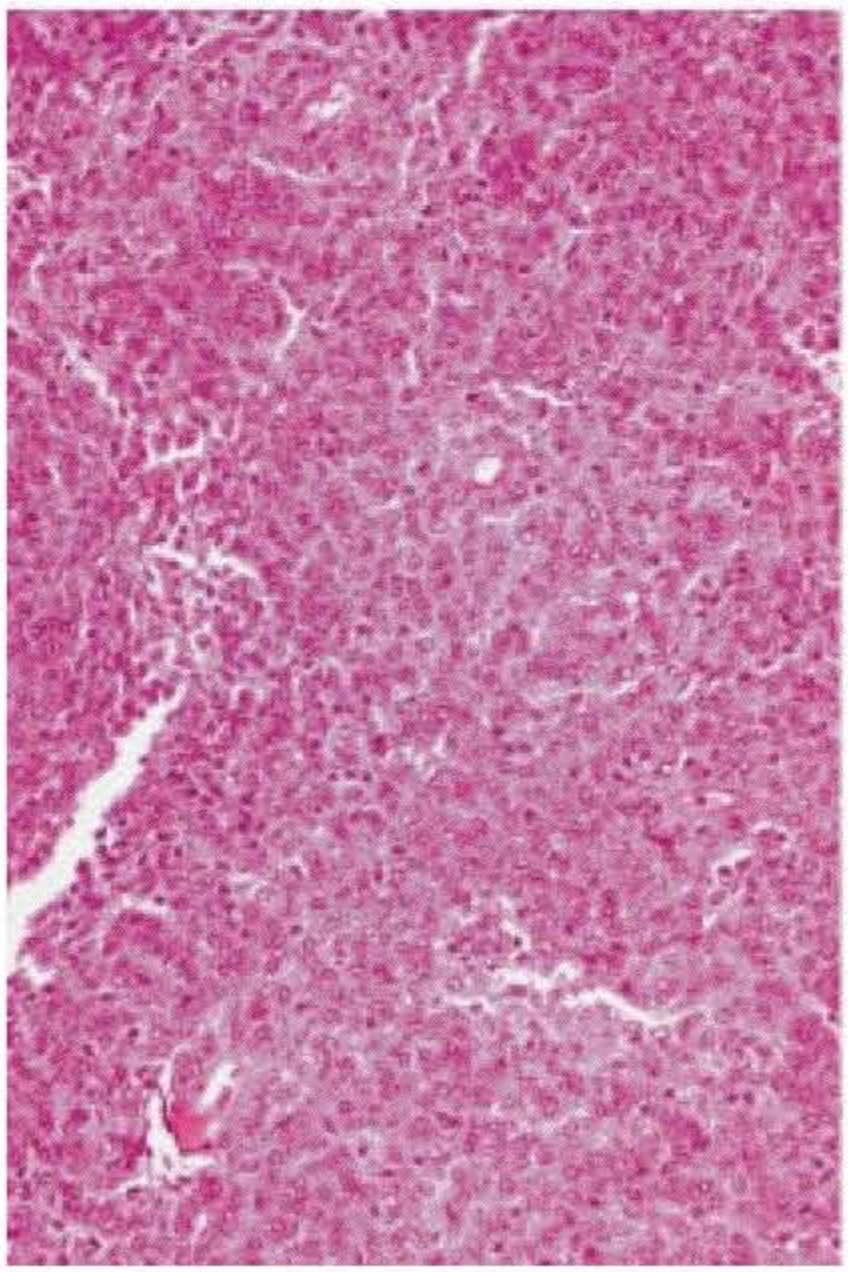

7.38

Fig. 7.36. Malignant myoepithelioma. Single cells with intracytoplasmic inclusions. MGG. E128.
Fig. 7.37. Malignant myoepithelioma. Cells with oncocytic-like morphology. Note the presence of an intranuclear inclusion. MGG. E128.
Fig. 7.38. Malignant myoepithelioma. Histological section corresponding to figure 7.37. HES. E32.

with epithelial-myoepithelial carcinoma, stromal connective fragments are scant or absent in acinic cell carcinoma. In addition, numerous naked nuclei or lymphocytes are commonly observed in acinic cell carcinoma (fig. 8.14).

7.3.2.5.5. Epithelial-Myoepithelial Carcinoma vs. Renal Cell Carcinoma. The monotonous cell composition and the presence of capillary septa are highly characteristic of metastatic renal cell carcinoma.

Epithelial-Myoepithelial Carcinoma

In favour of the diagnosis

Pseudopapillary structures of ovoid cells with clear peripheral cells, stromal fragments, naked nuclei

Difficulties

Hyaline globules, plasmacytoid cells

Against the diagnosis

Squamous cells, numerous plasmacytoid cells with abundant cytoplasm, chondromyxoid stroma, tubular and cylindrical structures, finger-like, bowl-shaped stromal structures

7.3.3. Malignant Myoepithelioma (Myoepithelial Carcinoma)

7.3.3.1. General

Malignant myoepithelioma represents 0.2% of all epithelial tumours. It may either arise de novo or develop in a pre-existing pleomorphic adenoma [89]. The cases reported in the literature occurred in the parotid gland and minor salivary glands. There is no sex predominance.

7.3.3.2. Histopathology

The tumour is not encapsulated and may be quite cellular and suggestive of sarcoma. It is characterized by atypical myoepithelial cells showing increased mitotic activity. Tumour cells may be plasmacytoid or spindle-shaped. Epithelial elements are absent, and giant cells may be seen. These tumours have an aggressive infiltrating growth [89].

7.3.3.3. Cytopathology

The smears are highly cellular and show single cells or clusters. They are composed of an admixture of large, roundish basophilic (MGG) and spindle-shaped cells. Nuclei are hyperchromatic with small distinct nucleoli and irregular nuclear membranes (Papanicolaou stain). The cytoplasm is often finely vacuolated, and intranuclear or intracytoplasmic inclusions are frequently seen. Mitotic figures may be visible. Stroma is scant or absent (fig. 7.36–7.38) [83, 330].

7.3.3.4. Diagnostic Accuracy

Only 9 cytological examples of malignant myoepithelioma have been reported to date (table 7.11).

7.3.3.5. Differential Diagnosis

The presence of roundish and spindle-shaped cells should suggest the diagnosis of myoepithelial tumour, while the presence of intranuclear or intracytoplasmic inclusions, nuclear atypia and mitotic figures are in favour of malignancy. The differential diagnosis must include myoepithelioma and oncocytoma (table 7.12).

Table 7.11. Correlation between cytology and histology of malignant myoepithelioma

Author [ref.]	Number	Malignant	Suspicious	Myoepithelioma	Unsatisfactory
Torlakovic et al. [330]	2	2	0	0	0
Di Palma et al. [83]	5	2	0	3	0
Chow et al. [59]	1	1	0	0	0
Sironi et al. [309]	1	1	0	0	0
Kuwabara et al. [210]	1	1	0	0	0
Our series	5	5	0	0	0
Total	14	11 (79)	0	3 (21)	0

Statistics from the literature. % in parentheses.

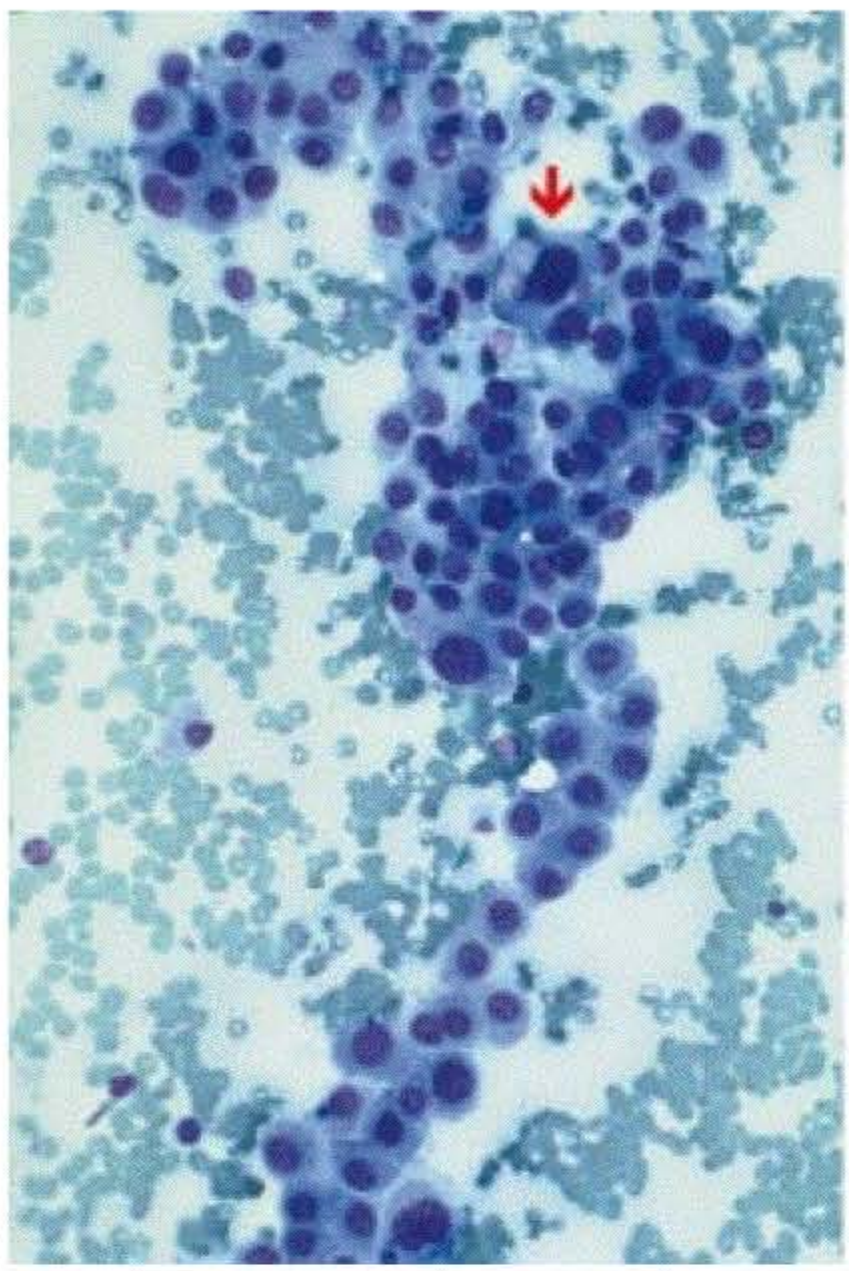

7.39

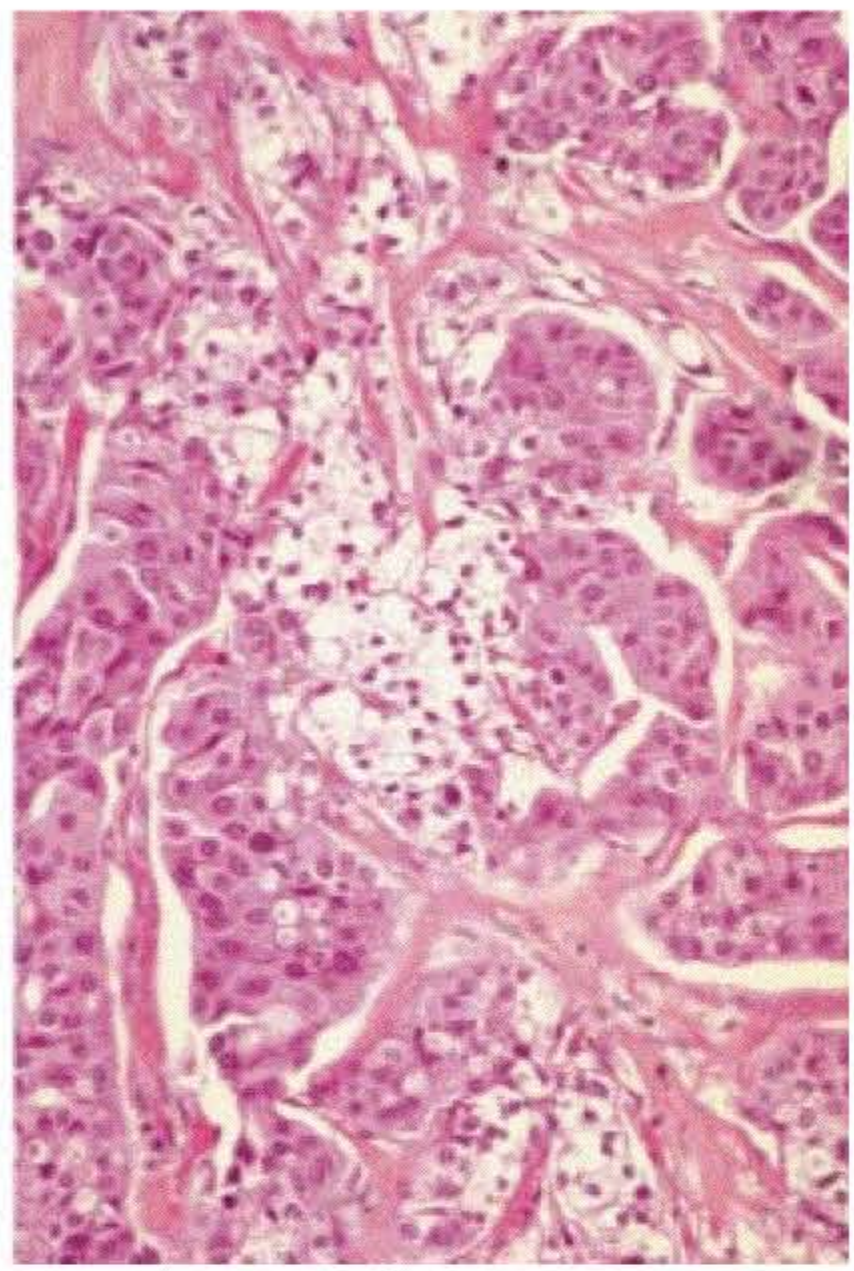

7.40

Fig. 7.39. Malignant oncocytoma. Large cells with strongly basophilic grey and granular cytoplasm with occasional vacuolization (clear cells) (arrow), and fairly regular nuclei. MGG. ×128.
Fig. 7.40. Malignant oncocytoma. Histological section corresponding to figure 7.39. HES. ×64.

Table 7.12. Differential diagnosis of malignant myoepithelioma

Cells	Malignant myoepithelioma	Myoepithelioma	Oncocytoma
Plasmacytoid	+/–	++	–
Spindle-shaped	++	++	?
Roundish	++	–	++
Mitotic figures	+	–	–
Inclusions	+	–	–

++ = Common; + = rare; +/– = occasionally seen; – = absent.

Malignant Myoepithelioma

In favour of the diagnosis

Large roundish and spindle-shaped cells, intranuclear or intracytoplasmic inclusions, mitotic figures, nuclear atypia

Difficulties

Lack of marked atypia or mitotic figures

Against the diagnosis

Plasmacytoid cells, chondromyxoid stroma

7.4. Carcinomas with Oncocytes

This chapter includes malignant oncocytoma and carcinoma ex Warthin's tumour, which is not a real oncocytic tumour, but which may show malignant cells associated with numerous oncocytes.

Table 7.13. Correlation between cytology and histology of malignant oncocytoma

Author [ref.]	Number	Malignant	Oncocytoma	Unsatisfactory
Austin et al. [16]	1	1	0	0
Abdul-Karim, Weaver [2]	1	0	1	0
Laforga, Aranda [211]	1	1	0	0
Rajan et al. [282]	1	1	0	0
Harrison et al. [149]	1	1	0	0
Wu, Silvernagel [347]	1	1	0	0
Our series	5	5	0	0
Total:	11	10 (91)	1 (9)	0 (0)

Statistics from the literature. % in parentheses.

Table 7.14. Differential diagnosis of malignant oncocytoma

	Oncocytic carcinoma	Oncocytoma	Warthin's tumour	Salivary duct carcinoma	Mucoepidermoid carcinoma, low-grade
Cells					
Oncocytes	++	++	++	++	+/–
Squamous	–	–	+/–	–	+
Intermediate	–	–	–	–	+
Goblet cells	–	–	+/–	–	++
Mast cells	–	–	++	–	+/–
Atypia, mitoses	+/–	+/–	–	++	+
Stroma					
Necrotic	+/–	–	++	++	++
Mucoid	–	–	+/–	–	++

++ = Common; + = rare; +/– = occasionally seen; – = absent.

7.4.1. Malignant Oncocytoma (Oncocytic Carcinoma)

7.4.1.1. General

Salivary oncocytic carcinoma represents 5% of all oncocytic tumours, and only 0.005% of all benign or malignant salivary gland tumours [137]. Less than 60 cases have been reported in the literature to date [89]. A male predilection (62.5%) and parotid predominance (91.3%) are observed. Sixty percent of patients with oncocytic carcinoma exhibit regional or distant metastases, and 47% patients die from their tumour. The recurrence rate is about 33%.

7.4.1.2. Histopathology

The diagnosis of malignant oncocytoma should be based on unequivocal morphological arguments of oncocytic origin of the carcinomatous cells, malignant behaviour, atypia, mitotic figures, and lack of encapsulation [89].

7.4.1.3. Cytopathology

The material is richly cellular and shows small clusters and isolated cells with an oncocytic morphology, characterized by large, strongly blue/grey (MGG stain) and granular cytoplasm with occasional vacuolization, and uniform nuclei (fig. 7.39, 7.40) often polarized with prominent nucleoli and coarse chromatin. Several cells may be binucleated. Mitoses are rare or absent in cytological smears. The background may contain several naked nuclei and lymphocytes.

7.4.1.4. Diagnostic Accuracy

Few examples of oncocytic carcinoma have been reported. Despite morphological similarities between oncocytic carcinoma and oncocytoma all, except one, were cytologically diagnosed as malignant (table 7.13).

7.4.1.5. Differential Diagnosis

Malignant oncocytoma must be distinguished from oncocytoma, Warthin's tumour, oncocytic variant of salivary duct carcinoma, mucoepidermoid carcinoma and metastatic melanoma (table 7.14).

7.4.1.5.1. Malignant Oncocytoma vs. Oncocytoma. Malignant oncocytoma may mimic oncocytoma, when promi-

nent atypia, mitotic figures and necrosis are missing. The diagnosis of malignancy may be very difficult, but may be guided by the clinical presentation.

7.4.1.5.2. Malignant Oncocytoma vs. Warthin's Tumour. Warthin's tumour shows clusters of cohesive oncocytes without atypia or mitosis and occasional mast cells (fig. 6.28). The absence of nuclear atypia and mitotic figures and the presence of lymphocytic stroma are in favour of Warthin's tumour.

7.4.1.5.3. Malignant Oncocytoma vs. Salivary Duct Carcinoma, Oncocytic Variant. Some salivary duct carcinomas with oncocytes are indistinguishable from malignant oncocytoma (fig. 7.47).

7.4.1.5.4. Malignant Oncocytoma vs. Mucoepidermoid Carcinoma with Oncocytic Metaplasia. Oncocytic metaplasia is a rare event in mucoepidermoid carcinoma. Mucoid background, intermediate cells and mucus-secreting cells may indicate the correct diagnosis.

7.4.1.5.5. Malignant Oncocytoma vs. Metastatic Melanoma. Nonpigmented melanoma may mimic oncocytic carcinoma, especially when cells are round and binucleated (fig. 11.2). Clinical history, intranuclear inclusions in melanoma and immunocytochemistry (HMB-45, S-100 protein) are crucial for accurate diagnosis.

Malignant Oncocytoma

In favour of the diagnosis

Abundant, granular cytoplasm, nuclear atypia, binucleated cells, coarse chromatin, mitotic figures

Difficulties

Occasional lack of nuclear atypia and mitosis

Against the diagnosis

Extensive necrosis, plasmacytoid cells, chondromyxoid stroma, mucus-secreting cells, mast cells

7.4.2. Carcinoma Ex Warthin's Tumour

7.4.2.1. General

This extremely rare malignancy shows a male predominance and usually involves the parotid gland or intraparotid lymph nodes in middle-aged or elderly men, often following irradiation.

7.4.2.3. Histopathology

It is a poorly-defined solid or cystic mass composed of either oncocytic carcinoma cells or, less frequently, squamous cells or cells resembling intermediate or mucin-secreting cells [298, 311].

7.4.2.3. Cytopathology

Only 1 case has been reported [69] and smears were suggestive of squamous cell carcinoma. We have also observed 1 case with features of Warthin's tumour (clustered oncocytes, necrosis, lymphocytes) intermingled with atypical keratinizing squamous cells, leading to a diagnosis of atypical Warthin's tumour (fig. 6.29–6.31).

7.4.2.4. Differential Diagnosis

Squamous metaplasia or cystic changes in benign Warthin's tumour may be suggestive of malignancy and a series of articles report this difficult differential diagnosis [17, 58, 213, 262]. These errors are due to the lack of typical features of Warthin's tumour and the presence of individual atypical squamous cells in a necrotic background mimicking carcinoma (fig. 6.24, 6.27) [17].

7.5. Carcinomas with Sebaceous Cells

7.5.1. Sebaceous Carcinoma and Sebaceous Lymphadenocarcinoma

Sebaceous carcinoma and sebaceous lymphadenocarcinoma appear to be intermediate-grade malignant tumours that recur and occasionally metastasize.

7.5.1.1. General

Approximately 30 cases of salivary sebaceous carcinoma have been reported in the literature [89]. Tumours arise exclusively in the parotid gland with no sex predominance.

7.5.1.2. Histopathology

The tumour consists of predominantly sebaceous cells with varying degrees of maturity [131, 132]. Cells are large with hyperchromatic nuclei and abundant clear to eosinophilic cytoplasm. Nuclear atypia and cell pleomorphism are common. Foreign body giant cell granulomas, oncocytes and squamous metaplasia may be seen.

Lymphadenocarcinoma is the rarest form of sebaceous tumours [131, 132] and may be associated with various salivary gland carcinomas [132, 296].

7.5.1.3. Cytopathology

Only one cytological report of metastatic sebaceous carcinoma of the parotid gland has been published [235]. In our experience of 4 cases, cytology of sebaceous carcinoma shows numerous highly malignant epithelial cells with cytoplasmic secretory granules, either isolated or in clusters (fig. 7.41, 7.42).

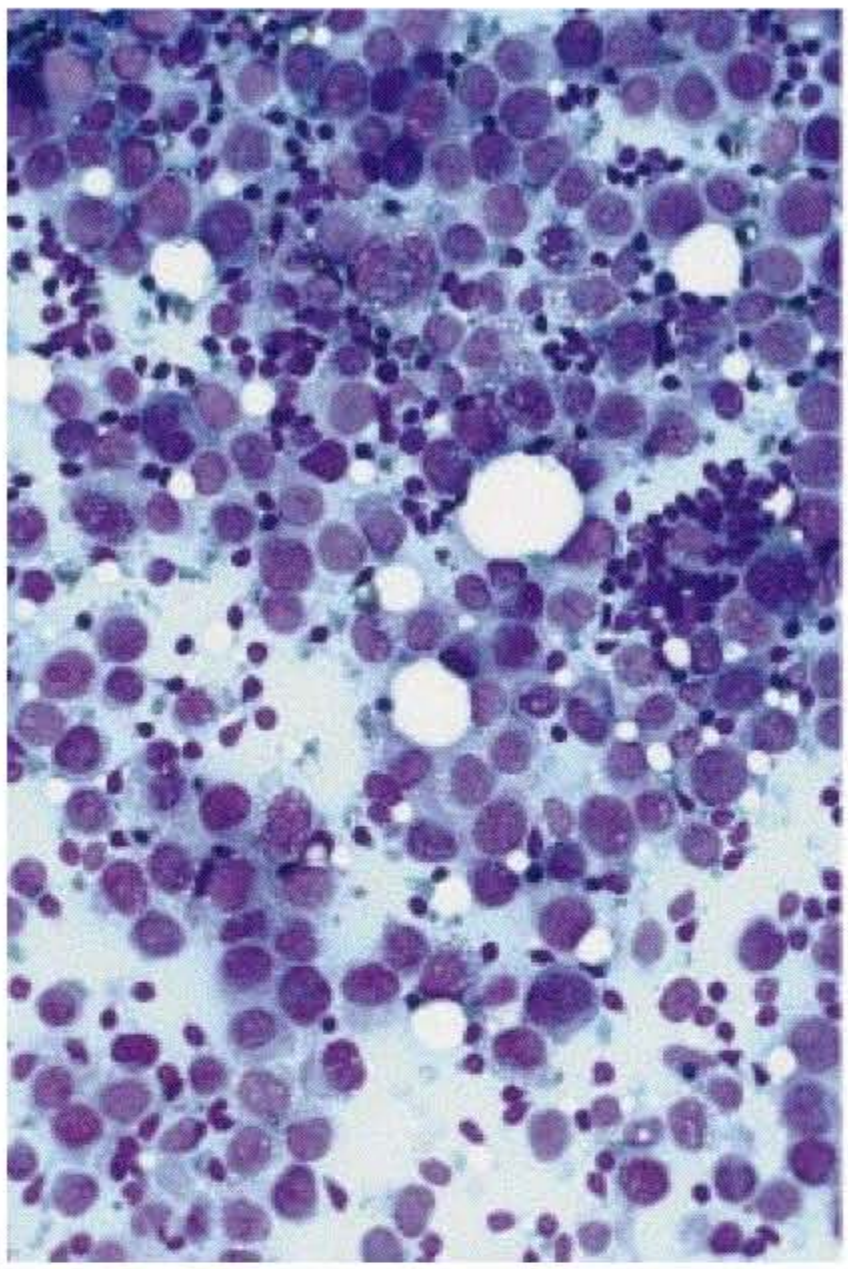

7.41

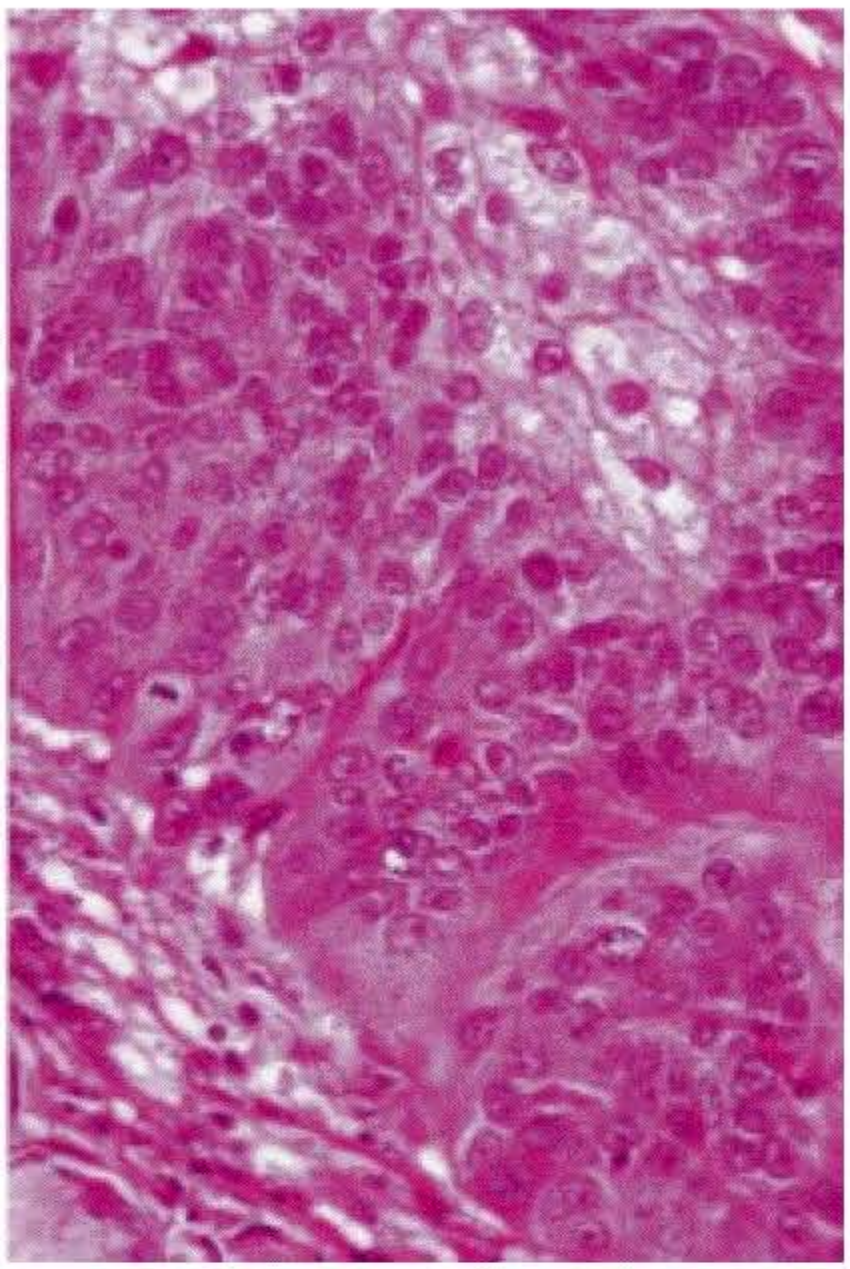

7.42

Fig. 7.41. Sebaceous carcinoma. Isolated carcinomatous cells with fine intracytoplasmic secretory vacuoles. Numerous lymphocytes in the background. MGG. E128.
Fig. 7.42. Sebaceous carcinoma. Histological section corresponding to figure 7.41. HES. E128.

7.5.1.4. Differential Diagnosis

Sebaceous carcinoma must be differentiated from sebaceous adenoma, tumours of the skin appendages and metastatic sebaceous carcinoma from another site.

7.6. Other Carcinomas

7.6.1. Salivary Duct Carcinoma

Salivary duct carcinoma is an uncommon and distinctive primary salivary gland malignancy derived from large intralobular and extralobular ducts. This entity was first described in 1968 by Kleinsasser et al. [183] and nearly 150 cases have subsequently been reported.

7.6.1.1. General

This tumour represented 2.8% of primary malignancies in the series reported by Simpson et al. [307]. It is located in the parotid gland in nearly 85% of cases with a predilection for men in the sixth and seventh decades (male/female ratio: 5:1) [89].

7.6.1.2. Histopathology

Salivary duct carcinoma is characterized by morphological features and an invasive growth pattern similar to those of mammary duct carcinomas, and is associated with early regional and distant metastases [89]. The intraductal component exhibits three histological patterns: papillary formations, cribriform pattern, and features resembling comedocarcinoma of the breast with prominent central necrosis. Severe to moderate nuclear atypia and numerous mitotic figures are commonly seen. Oncocytic salivary duct carcinomas [225] are composed of large cells with abundant granular cytoplasm. They are arranged in papillary or solid patterns and exhibit severe nuclear atypia. The tumours have a predominantly fibrotic and inflammatory stroma.

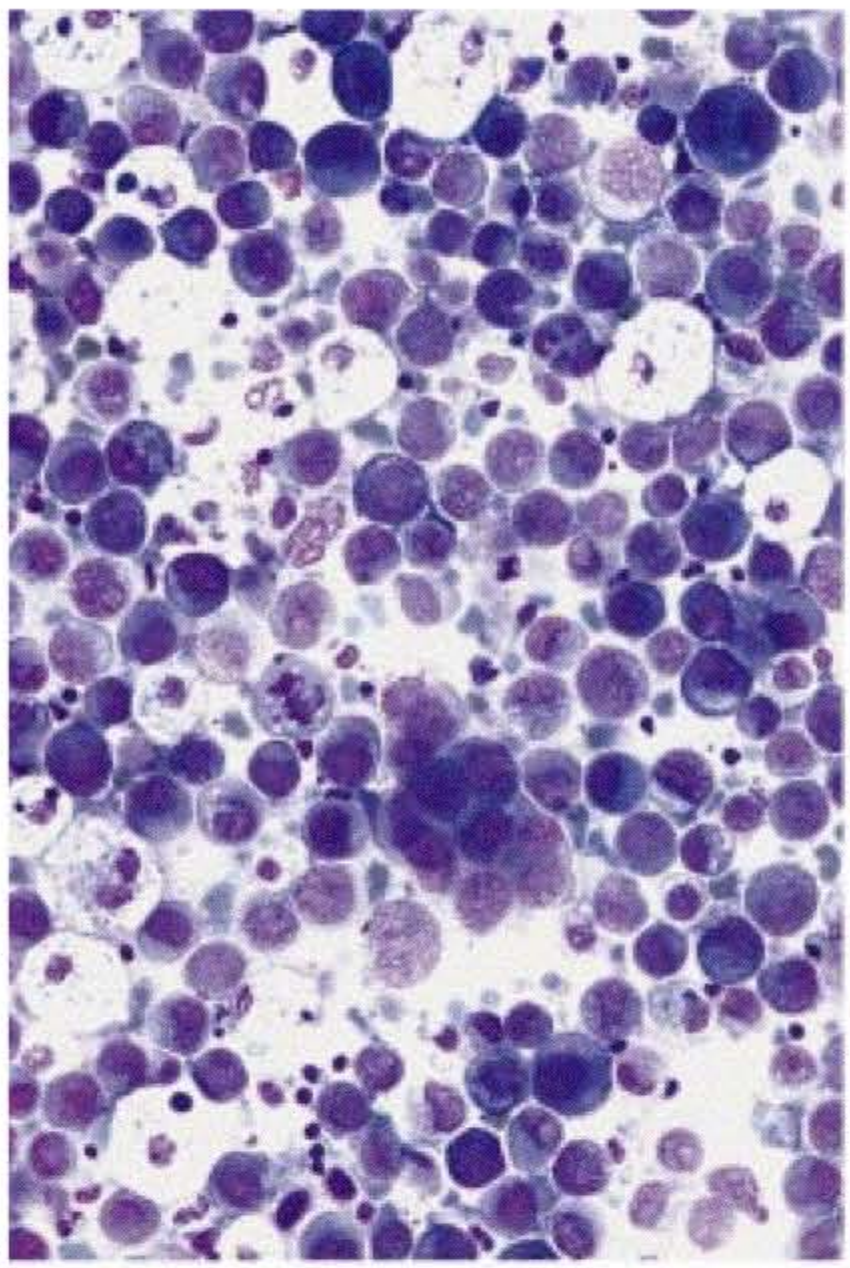

7.43

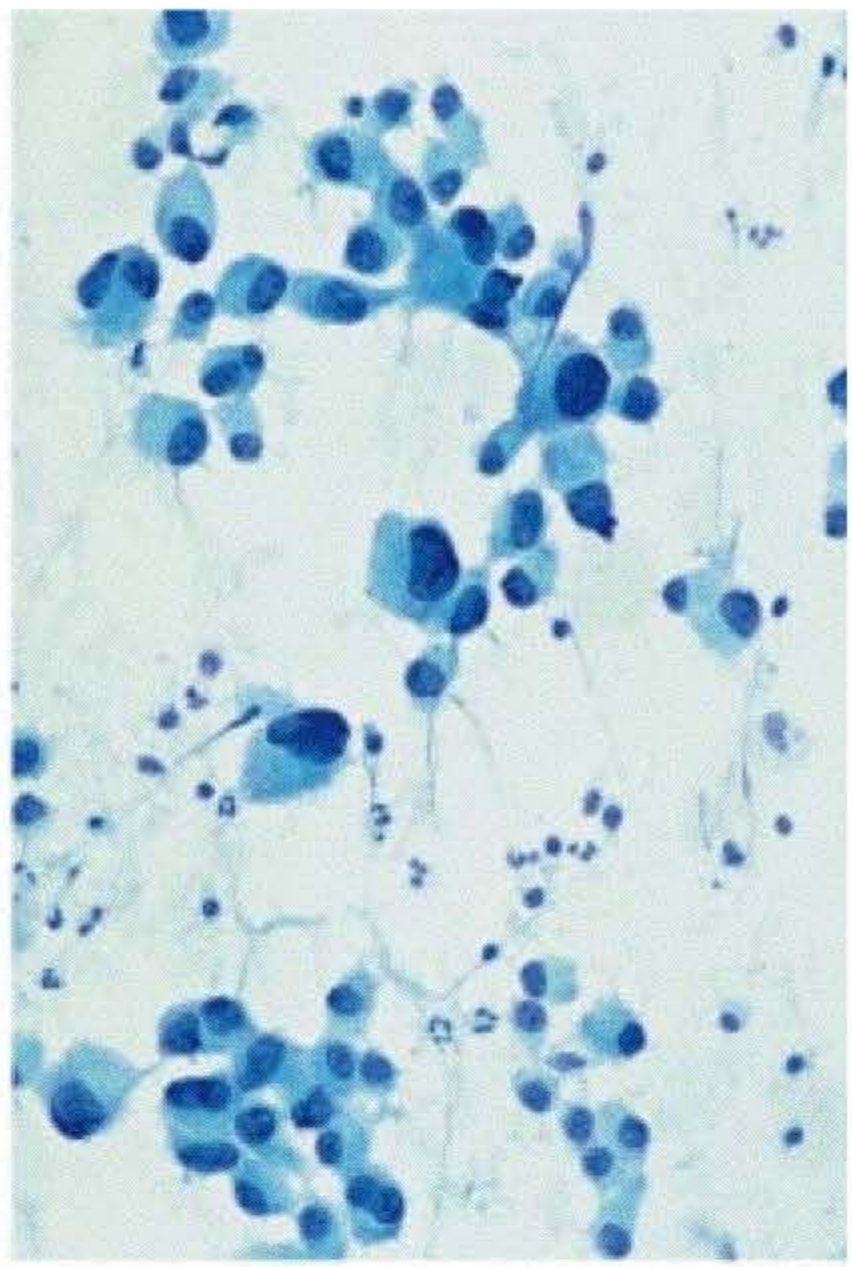

7.44

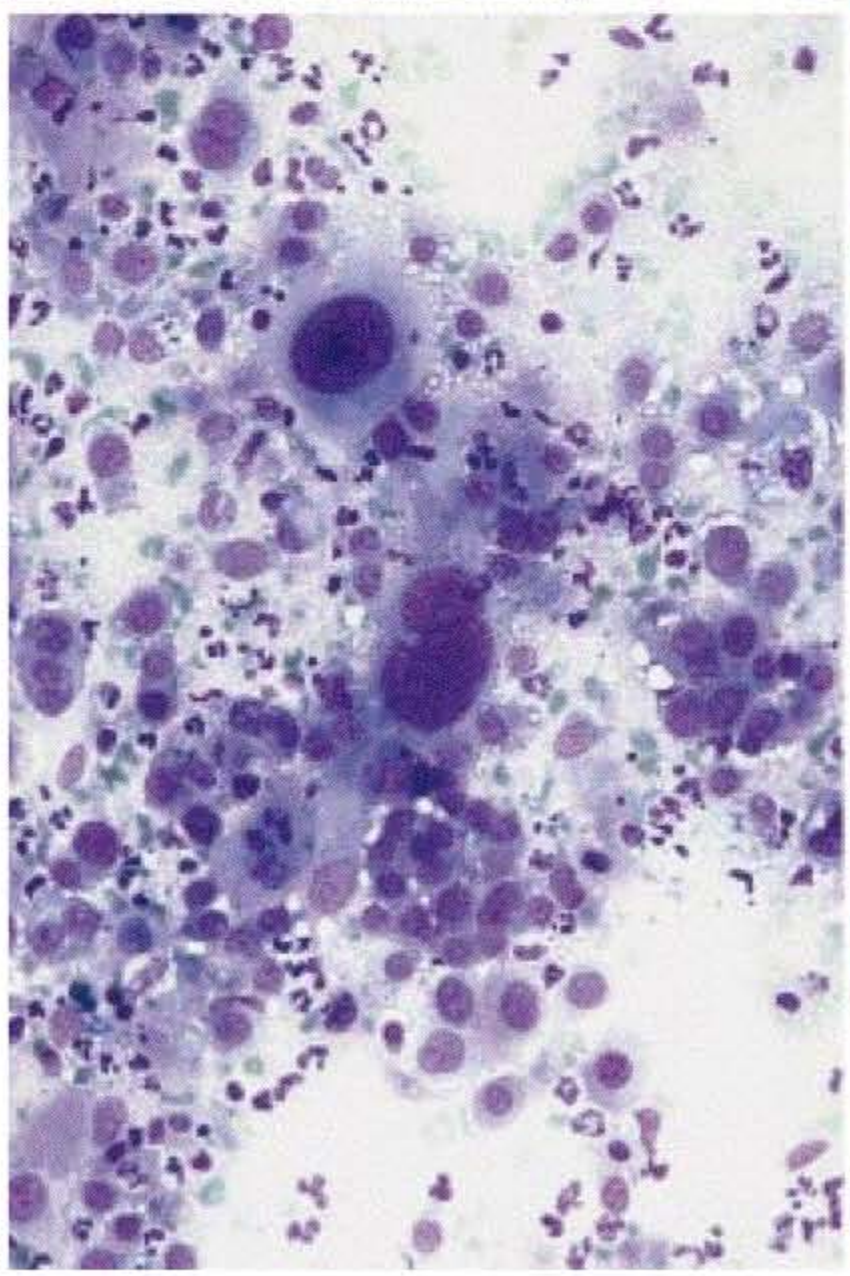

7.45

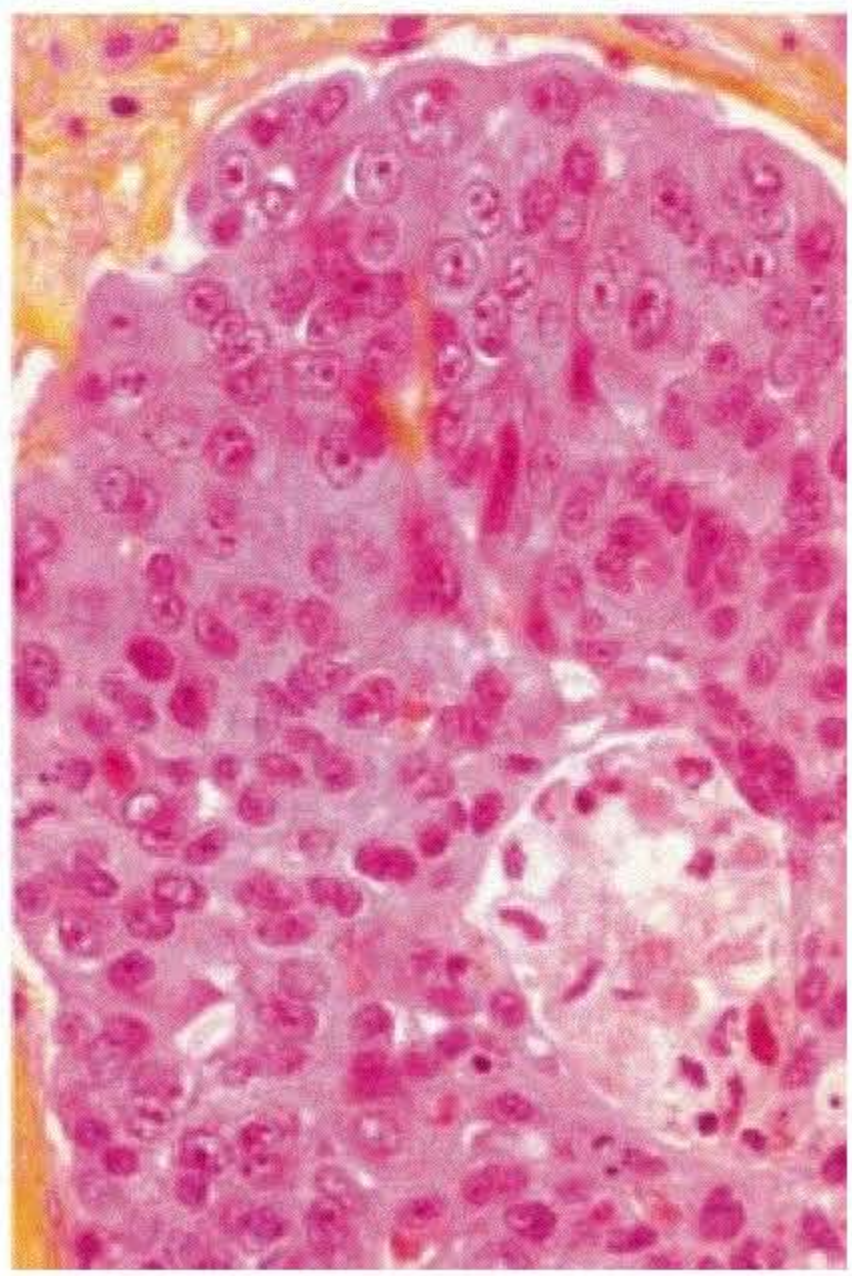

7.46

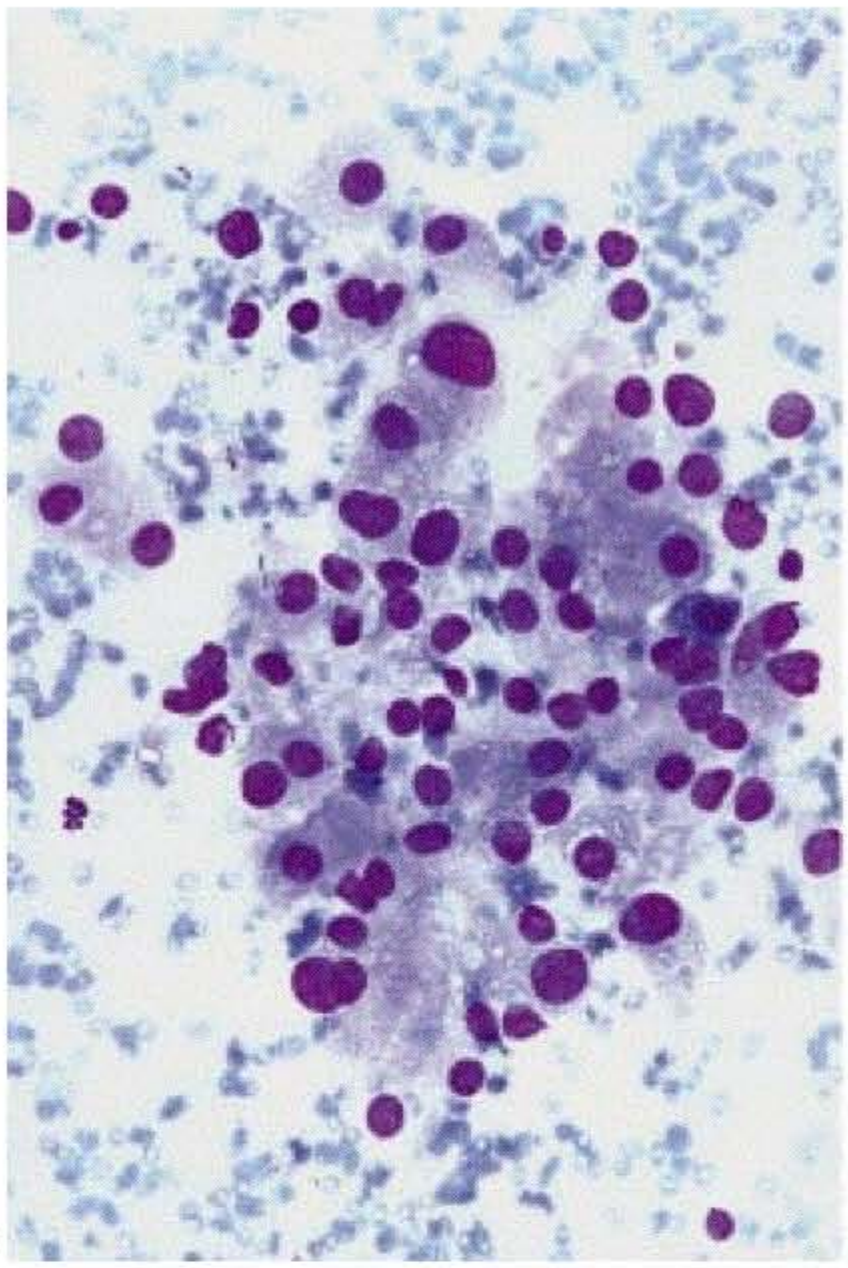

7.47

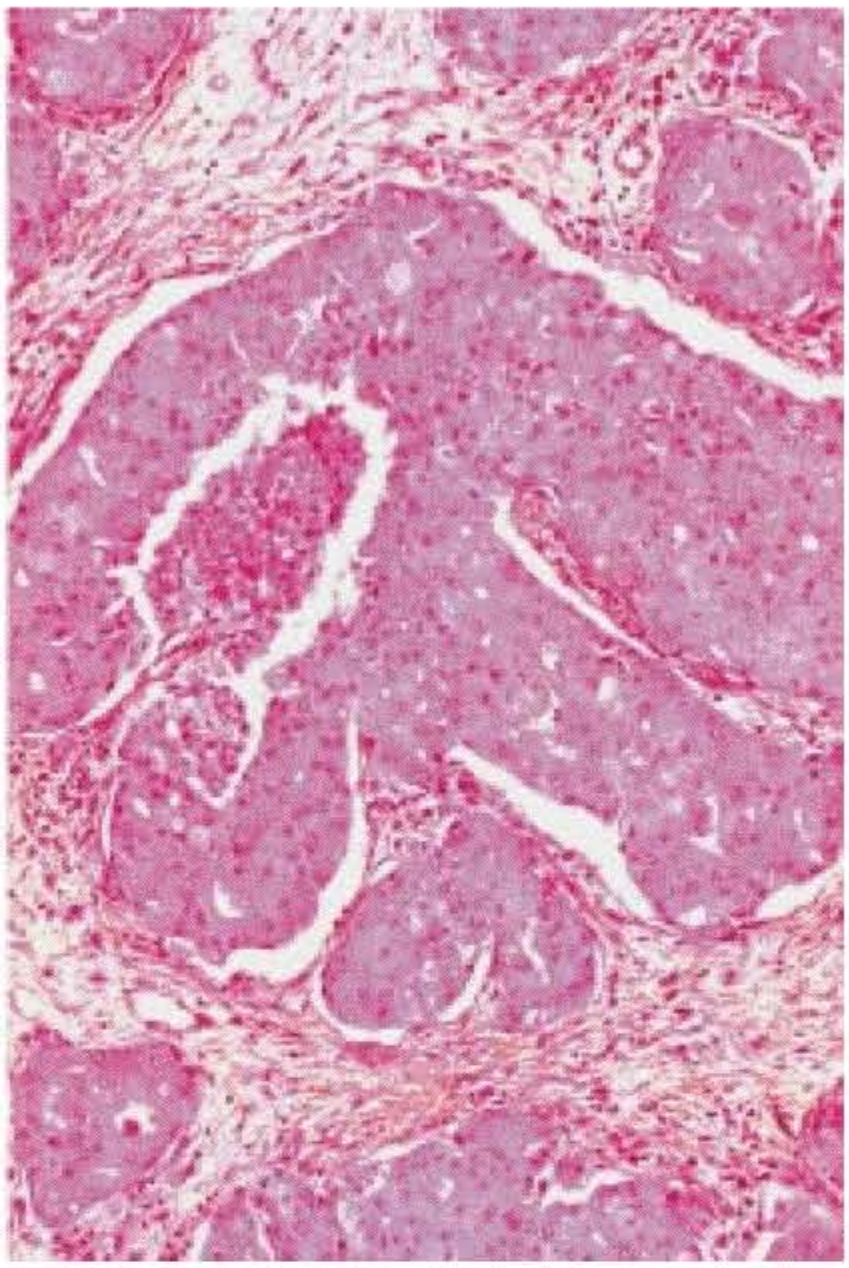

7.48

Fig. 7.47. Salivary duct carcinoma. Oncocytic-like cells with ill-defined eosinophilic cytoplasm. MGG. ×128.
Fig. 7.48. Salivary duct carcinoma. Histological section corresponding to figure 7.47. HES. ×32.

Low-grade salivary duct carcinoma [81] is a recently described and disputed variant, with predominant intraductal growth.

7.6.1.3. Cytopathology

Cytologically, most reported cases show features of high-grade malignancy [192]. The cytological smears are rich in cells. Cells are either isolated or grouped in three-dimensional pseudopapillary and cribriform clusters with atypical nuclei and prominent nucleoli reminiscent of mammary ductal or prostate carcinomas (fig. 7.43–7.46). Intranuclear vacuoles and multinucleated cells are occasionally seen. Extensive necrosis may be present in some cases. The cytoplasm is abundant and slightly blue on MGG stain, and many cytoplasmic vacuoles are observed. Oncocytic-like tumours show large cells with ill-defined eosinophilic (MGG) cytoplasm (fig. 7.47, 7.48). Necrosis is scant or absent in these cases.

Low-grade salivary duct carcinoma is characterized by the growth of monotonous cells in a papillary configuration [57].

Fig. 7.43. Salivary duct carcinoma. Isolated cells with irregular nuclei. MGG. ×128.
Fig. 7.44. Salivary duct carcinoma. Eccentric and irregular nuclei. Papanicolaou. ×128.
Fig. 7.45. Salivary duct carcinoma. Large malignant cells in a necrotic and inflammatory background. MGG. ×128.
Fig. 7.46. Salivary duct carcinoma. Histological section corresponding to figure 7.35. HES. ×128.

7.6.1.4. Diagnostic Accuracy

Table 7.15 shows that salivary duct carcinoma is diagnosed or suspected to be a high-grade malignancy on cytology in more than 94% of cases. Accurate tumour typing is more difficult, but possible in the presence of comedonecrosis.

Table 7.15. Correlation between cytology and histology of salivary duct carcinomas

Author [ref.]	Number	Malignant	Suspicious	False-negative	Unsatisfactory
Gal et al. [119]	1	1	0	0	0
Dee et al. [79]	11	1	0	0	0
Zurrida et al. [358]	4	4	0	0	0
Elsheikh et al. [94]	2	2	0	0	0
Orell [263]	2	1	1	0	0
Khurana et al. [177]	8	2	0	3	0
Fýrat et al. [118]	5	5	0	0	0
Domson, Wakely [85]	2	2	0	0	0
Coleccia et al. [66]	1	1	0	0	0
Klijanienko, Vielh [192]	21	21	0	0	0
Garcia-Bonafé et al. [120]	7	7	0	0	0
Gilcrease et al. [127]	2	2	0	0	0
Total	56	52 (92.9)	1 (1.8)	3 (5.3)	0

Statistics from the literature. % in parentheses.

Table 7.16. Quantitative differential diagnosis of salivary duct carcinoma

Component	Salivary duct carcinoma	Mucoepidermoid carcinoma, high-grade	Squamous cell carcinoma	Malignant oncocytoma
Cells				
Large epithelial				
Squamous	–	+	++	–
Oncocytic	+	+/–	–	++
Nuclear atypia	++	+	++	+
Stroma				
Mucoid	–	+/–	–	–
Necrosis	+	+	++	+

++ = Common; + = rare; +/– = occasionally seen; – = absent.

7.6.1.5. Differential Diagnosis

Salivary duct carcinoma should be included in the differential diagnosis of major salivary gland malignancies, such as mucoepidermoid carcinoma, squamous cell carcinoma, oncocytic carcinoma, and breast carcinoma metastatic to the salivary gland (table 7.16).

7.6.1.4.1. Salivary Duct Carcinoma vs. High-Grade Mucoepidermoid Carcinoma and Squamous Cell Carcinoma. High-grade mucoepidermoid carcinoma is composed of squamoid, intermediate and rare mucous cells [196] with frequent mitotic figures and may mimic salivary duct carcinoma cells (fig. 7.8). However, the presence of intermediate cells and mucous cells argues against such a diagnosis. Similarly, squamous cell carcinoma is composed of round, ovoid or enlarged atypical cells with dense nuclear chromatin and tumour necrosis; naked nuclei and keratin debris are commonly encountered (fig. 7.15) [197]. Marked keratinization is a feature that excludes the two diagnoses of salivary duct carcinomas and mucoepidermoid carcinoma.

7.6.1.4.2. Salivary Duct Carcinoma vs. Malignant Oncocytoma. Malignant oncocytoma may raise problems of differential diagnosis, as some salivary duct carcinomas may exhibit oncocytic features (fig. 7.47). The marked cytonuclear atypia typically present in salivary duct carcinoma and the infrequency of oncocytic carcinoma may help to guide the diagnosis (fig. 7.39).

7.6.1.4.3. Salivary Duct Carcinoma vs. Metastatic Adenocarcinomas. Salivary duct carcinomas may be indistin-

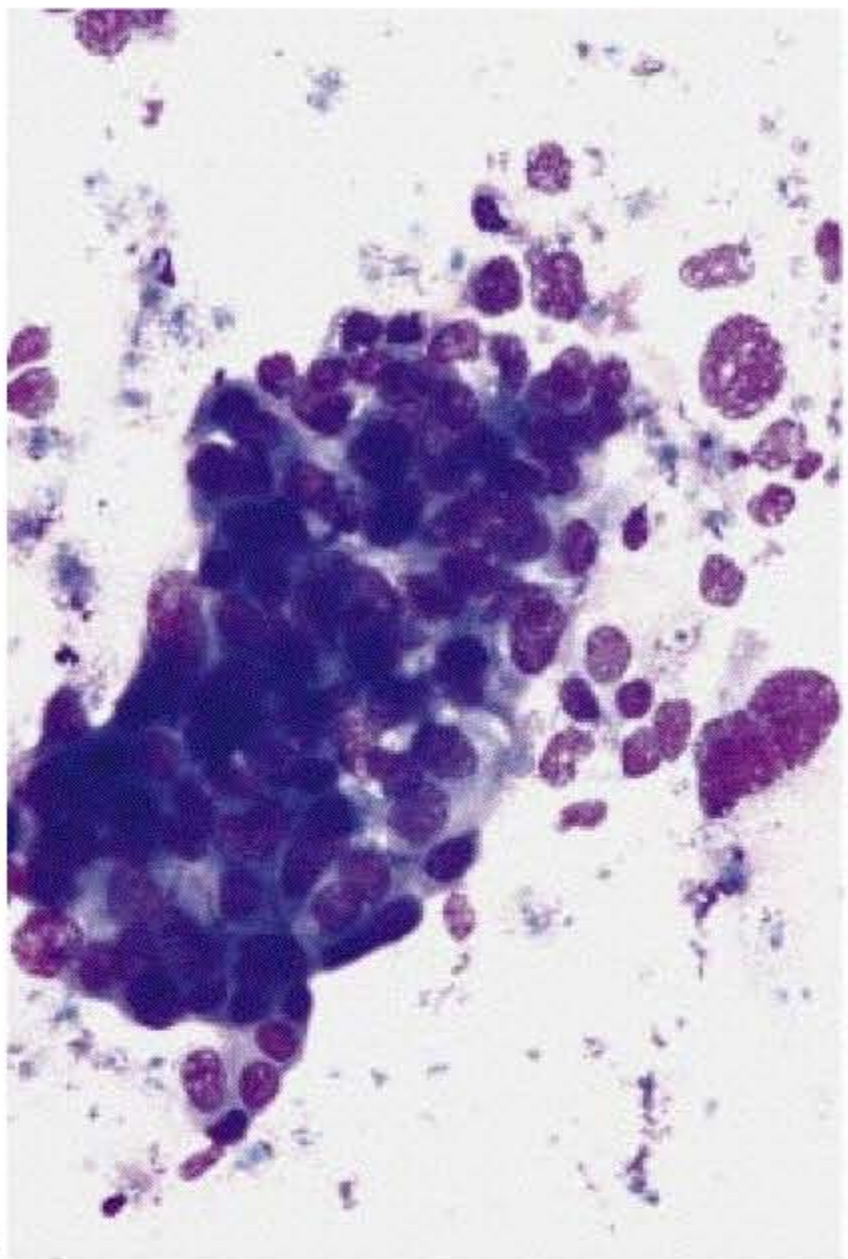

7.49

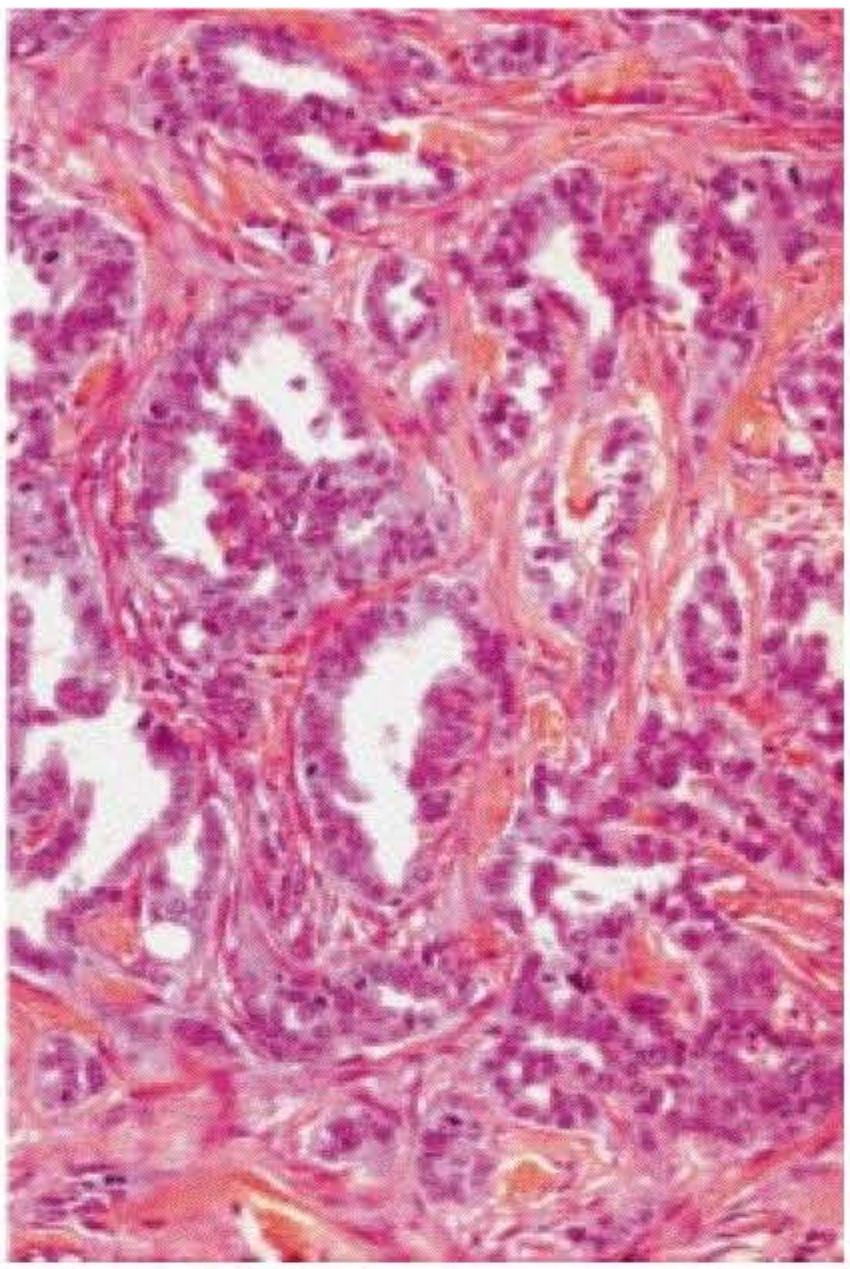

7.50

Fig. 7.49. Adenocarcinoma NOS. Nonspecific, clustered malignant cells. MGG. ×128.
Fig. 7.50. Adenocarcinoma NOS. Histological section corresponding to figure 7.49 showing tubulo-trabecular adenocarcinoma. HES. ×64.

guishable from metastatic prostate or breast adenocarcinomas (fig. 11.4), requiring more detailed clinical assessment.

7.6.1.4.4. Low-Grade Salivary Duct Carcinoma vs. Pleomorphic Adenoma. These two entities can be distinguished by the presence of plasmacytoid myoepithelial cells with well-defined cytoplasmic borders.

Salivary Duct Carcinoma

In favour of the diagnosis

Granular cytoplasm, nuclear atypia, binucleated cells, mitotic figures, comedonecrosis

Difficulties

Occasional cytoplasmic microvacuolizations and intranuclear inclusions

Against the diagnosis

Mucus-secreting cells, mucoid background, squamous cells

7.6.2. Adenocarcinoma Not Otherwise Specified (NOS)

'Not otherwise specified' literally means that the histopathologist cannot classify a tumour into one of the specific types listed in the WHO classification [300].

7.6.2.1. General

This is a diminishing group of salivary gland malignancies [23]. The various carcinomas not otherwise specified represent approximately 4–9% of all salivary gland tumours [90, 316]. Adenocarcinomas NOS mainly arise in the minor salivary glands, followed by the nasal sinuses and larynx. Major glands are involved in 32–60% of cases [90]. Clinically, tumours present features of low- or high-grade malignancy, with a potential for local recurrence and lymph node and distant metastases (lung, bone, skin).

Table 7.17. Correlation between cytology and histology in small cell carcinoma

Author [ref.]	Number	Malignant	False-negative	Unsatisfactory
Currens et al. [70]	1	1	0	0
Mair et al. [232]	1	0	0	0
Cameron et al. [42]	1	1	0	0
Shin, Caraway [306]	1	1	0	0
Our series[1]	11	11	0	0
Total	15	15	0	0

Statistics from the literature.
[1] Including neuroendocrine carcinomas.

7.6.2.2. Histopathology

These tumours may be classified into seven histological patterns: typical, mucinous, papillary, trabecular, papillary and mucinous, sebaceous, and others. Almost 95% of these adenocarcinomas show at least one of the first three morphological patterns [89].

7.6.2.3. Cytopathology

Smears show high-grade malignant glandular cells with no specific features (fig. 7.49, 7.50).

7.6.2.4. Differential Diagnosis

Adenocarcinoma NOS should be differentiated from pleomorphic adenoma, clear cell carcinoma, acinic cell adenocarcinoma, mucoepidermoid carcinoma, papillary cystadenocarcinoma, mucinous adenocarcinoma, salivary duct carcinoma and pleomorphic low-grade adenocarcinoma.

7.6.3. Small Cell Carcinoma

Small cell carcinoma of salivary glands has similar morphology, immunoreactivity and natural history to those of its pulmonary counterpart [89]. Small cell carcinoma is a diagnosis of exclusion when no primary can be found in the conventional sites.

7.6.3.1. General

This is a very rare entity, accounting for 1.7% of primary parotid gland malignancies and 2.2% of submandibular gland tumours, with a total of about 60 cases reported in the literature. The female/male ratio is 6:1. Isolated cases of primary or metastatic Merkel cell tumour-like neuroendocrine carcinoma and tumours involving the accessory salivary glands have also been reported [122, 206, 349].

7.6.3.2. Histopathology

Small cell carcinoma presents as a soft, light tan nodule, microscopically identical to small cell carcinoma of the lung. Two distinctive types, small cell carcinoma and small cell carcinoma with ductal differentiation, have been described. Squamous and exocrine cells may occasionally be seen [134, 150, 289].

7.6.3.3. Cytopathology

Smears are cellular and composed of small to moderate-sized malignant cells with hyperchromatic and immature nuclei [42, 232], possibly with marked nuclear pleomorphism. Nuclear moulding and mitotic figures are quite suggestive. Cytoplasm is scant. The background is often necrotic and inflammatory (fig. 7.51–7.53).

7.6.3.4. Diagnostic Accuracy

Cytological reports of small cell carcinoma (primary in the parotid gland or metastatic to the parotid gland) are very rare [350]. Cytology is characterized by a high rate (100%) of accurate diagnosis in the reported cases (table 7.17).

7.6.3.5. Differential Diagnosis

Several tumours may be composed of small and undifferentiated cells, including poorly-differentiated squamous cell carcinoma, malignant lymphoma or metastatic small cell carcinoma. Immunocytochemical staining and clinical history are helpful in the differential diagnosis.

Small Cell Carcinoma

In favour of the diagnosis

Little or no cytoplasm, 'delicate' immature nuclei, nuclear moulding, focal necrosis, numerous mitotic figures

Difficulties

Extensive necrosis, marked nuclear pleomorphism

Against the diagnosis

Squamous cells, dot and juxtanuclear keratin positivity

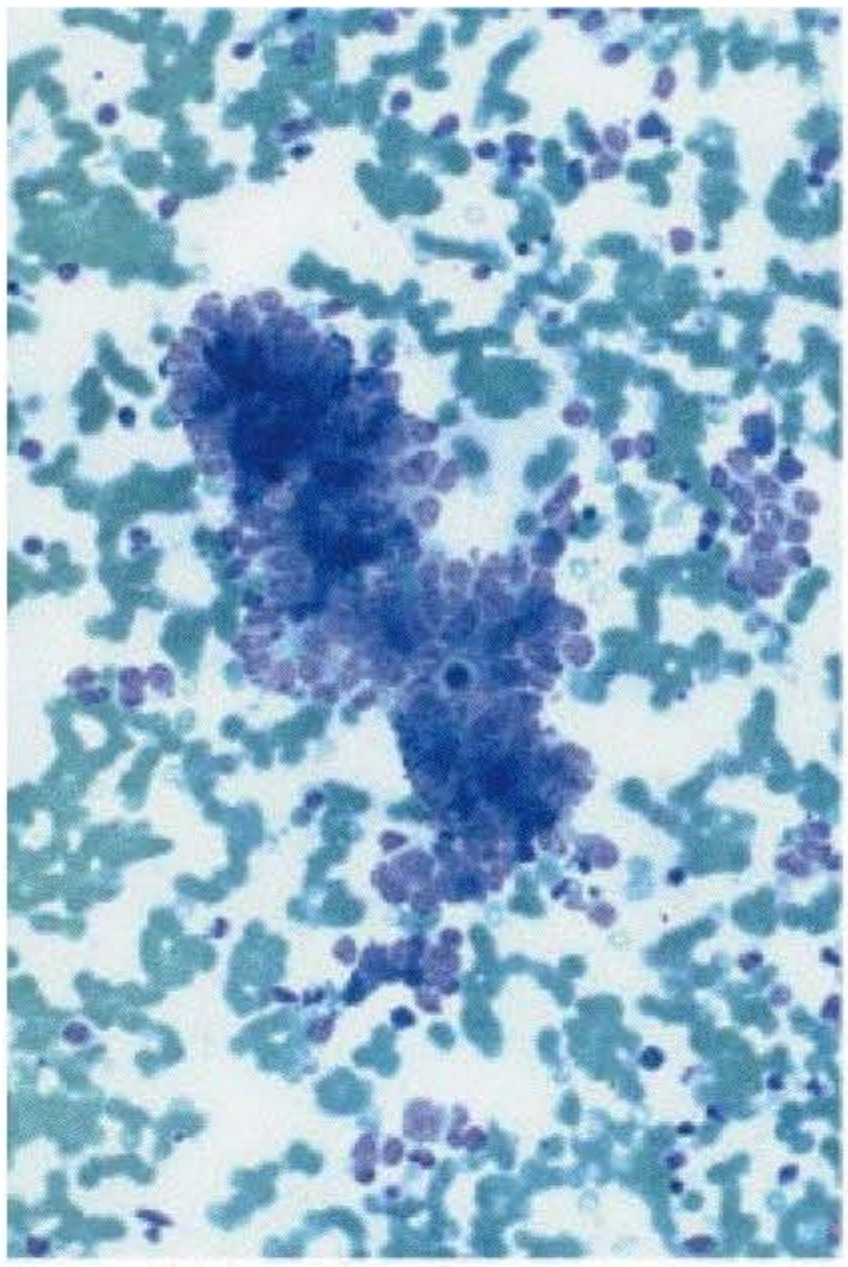

7.51

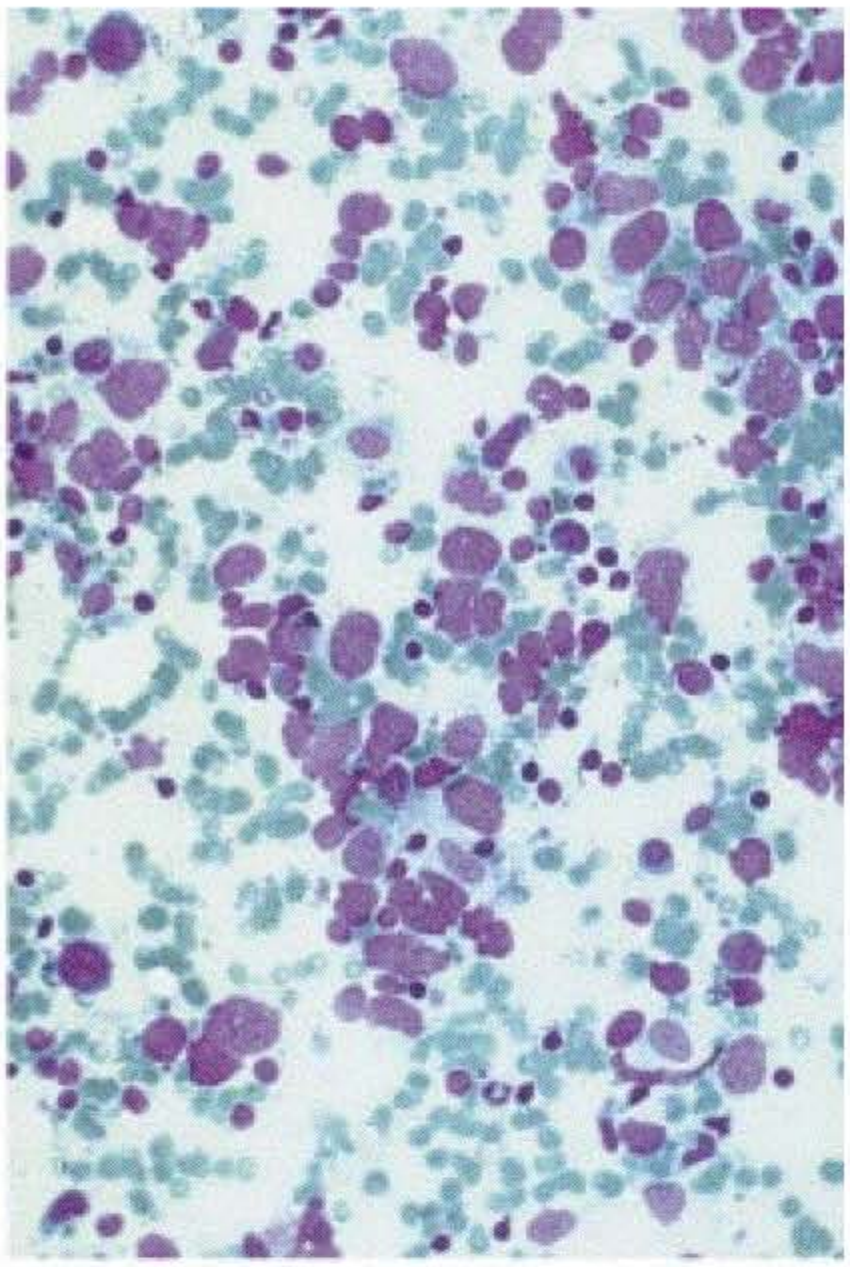

7.52

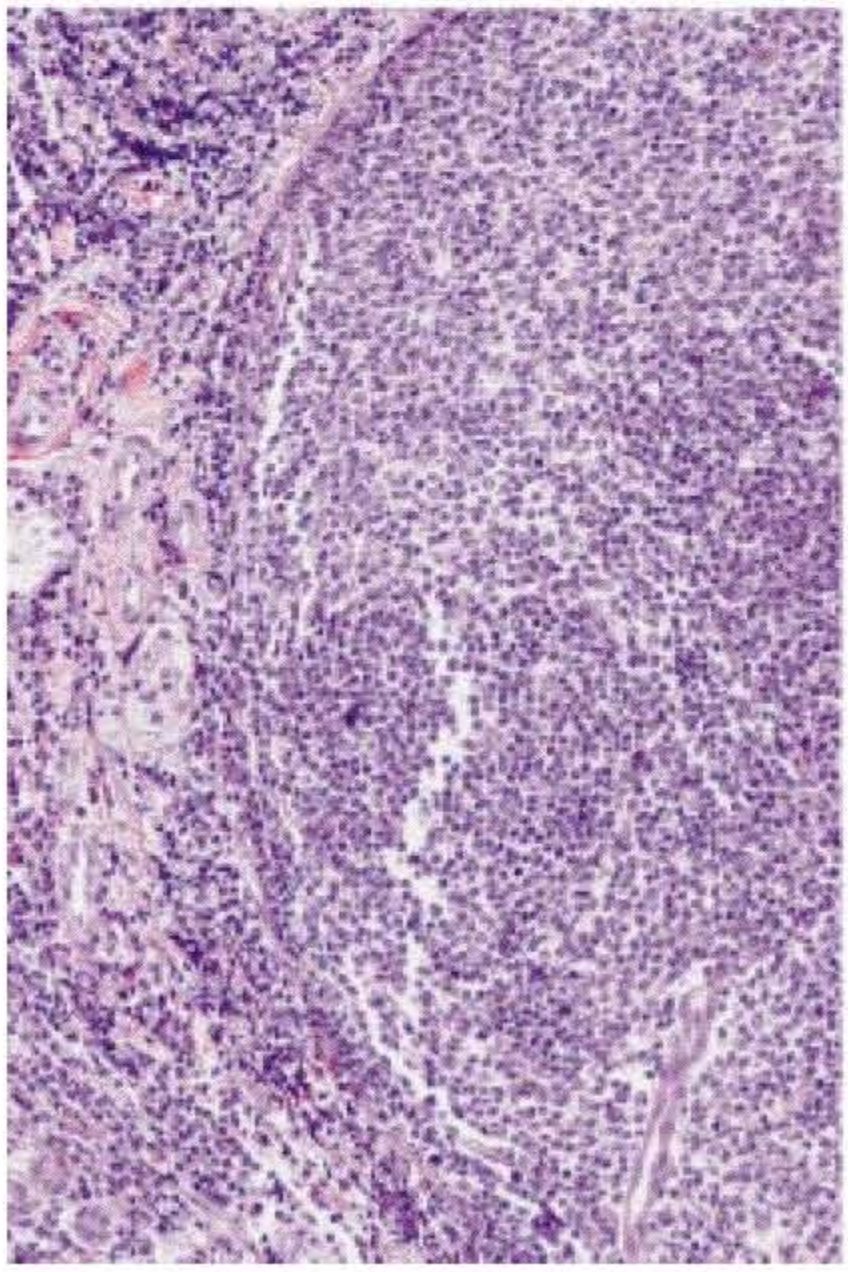

7.53

Fig. 7.51. Small cell carcinoma. Three-dimensional cluster of small cells showing neuroendocrine features. MGG. E128.

Fig. 7.52. Small cell carcinoma. Nuclear atypia. Cytoplasm is inconspicuous or absent. MGG. E128.

Fig. 7.53. Small cell carcinoma. Histological section corresponding to figure 7.53. HES. E32.

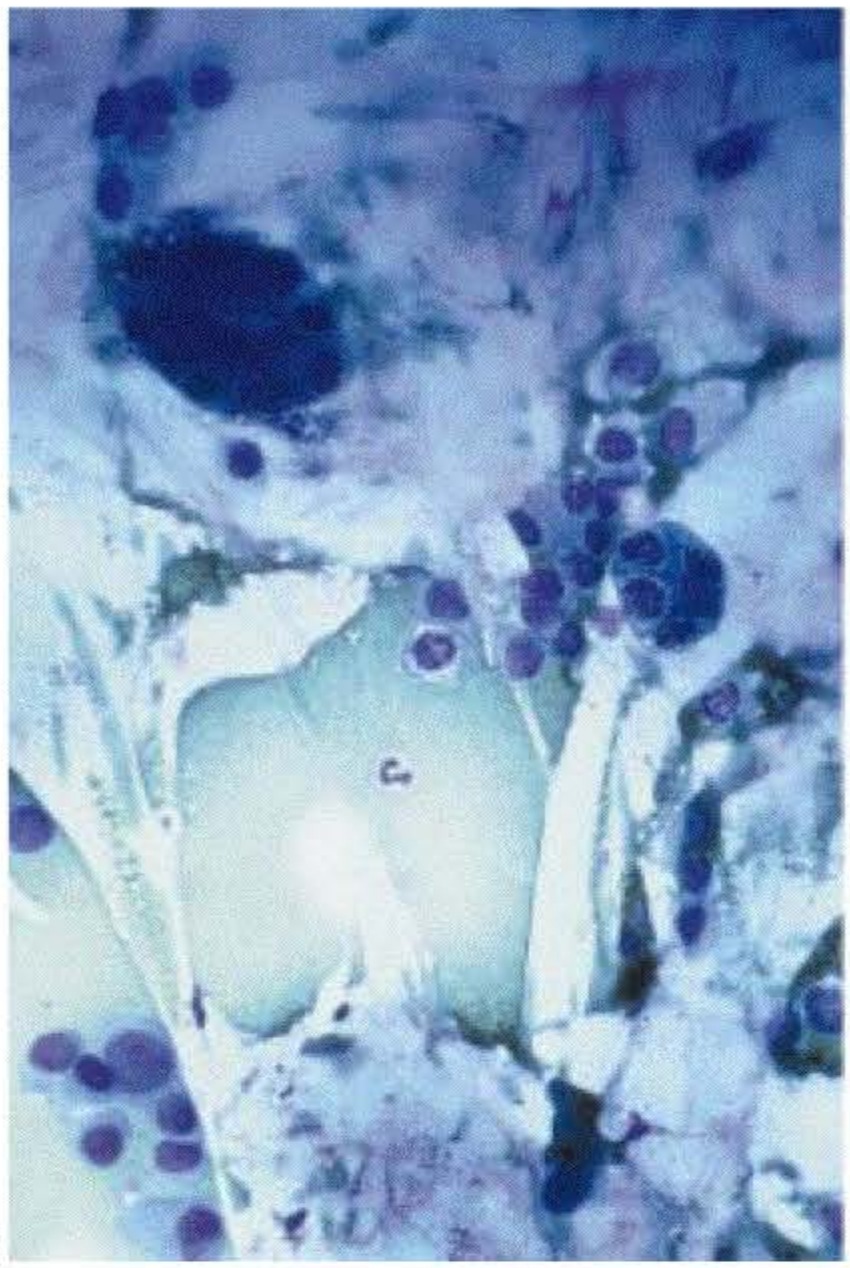

7.54

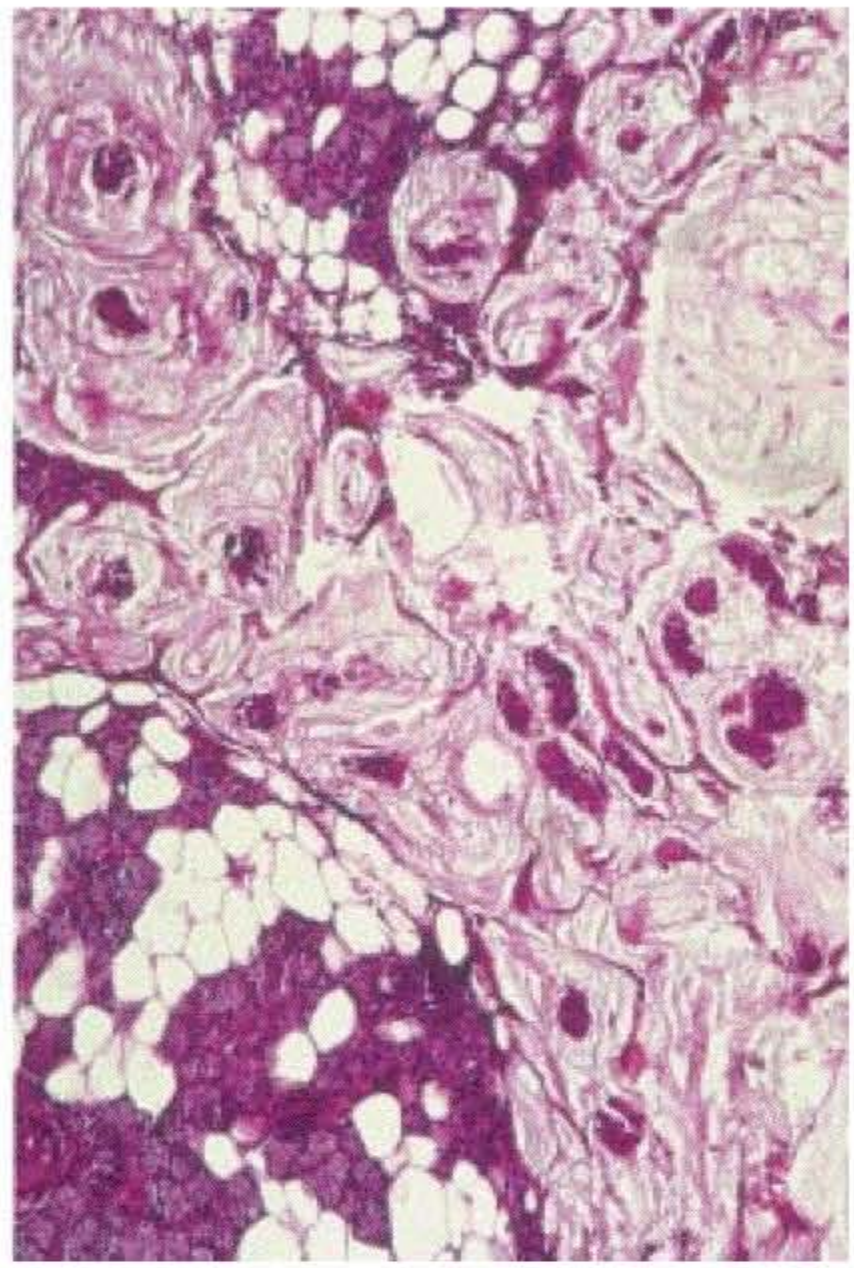

7.55

Fig. 7.54. Mucinous carcinoma. Large areas of mucus containing small clusters or isolated cells. MGG. ×128.
Fig. 7.55. Mucinous carcinoma. Histological section corresponding to figure 7.54 showing carcinoma infiltrating the parotid parenchyma. No other site was found in this patient. HES. ×32.

7.6.4. Mucinous Adenocarcinoma

Only isolated cases have been reported [334, 265] and present similar histological features to mucinous adenocarcinoma in the gastrointestinal tract and other sites [89]. We have seen two examples (fig. 7.54, 7.55). The tumour consists of mucus-secreting cells lining cysts filled with abundant mucous material (>50%). Squamous or intermediate cells are absent. The mucoid substance stains with mucicarmine, periodic acid-Schiff, and Alcian blue. It should always be differentiated from metastatic adenocarcinoma and mucoepidermoid carcinoma (fig. 8.5).

7.6.5. Carcinoma Ex Pleomorphic Adenoma

7.6.5.1. General

Carcinoma ex pleomorphic adenoma is an uncommon tumour accounting for 2.2% of all salivary tumours, 4.5% of all pleomorphic adenomas and 6.5% of all malignant tumours [89]. The incidence of this malignancy has been correlated with the duration of pleomorphic adenoma, but no definitive association with either of the gross features has been reported.

Clinically, carcinoma ex pleomorphic adenoma presents in two forms: de novo or recurrent with in situ or infiltrating patterns [130].

Fig. 7.56. Mucoepidermoid carcinoma ex pleomorphic adenoma. Mucus-secreting cells (red arrow) and keratin squames (yellow arrow). Background is mucoid. Note the chondromyxoid stroma containing myoepithelial cells. MGG. ×128.
Fig. 7.57. Mucoepidermoid carcinoma ex pleomorphic adenoma. Intermediate, squamous (arrow) cells and chondromyxoid. MGG. ×128.
Fig. 7.58. Mucoepidermoid carcinoma ex pleomorphic adenoma. Histological section corresponding to figure 7.57 showing mucoepidermoid carcinoma (above) and pleomorphic adenoma (below). HES. ×32.
Fig. 7.59. Mucoepidermoid carcinoma ex pleomorphic adenoma. Same case as figure 7.58. Mucus-secreting cells are Alcian blue-positive. ×128.

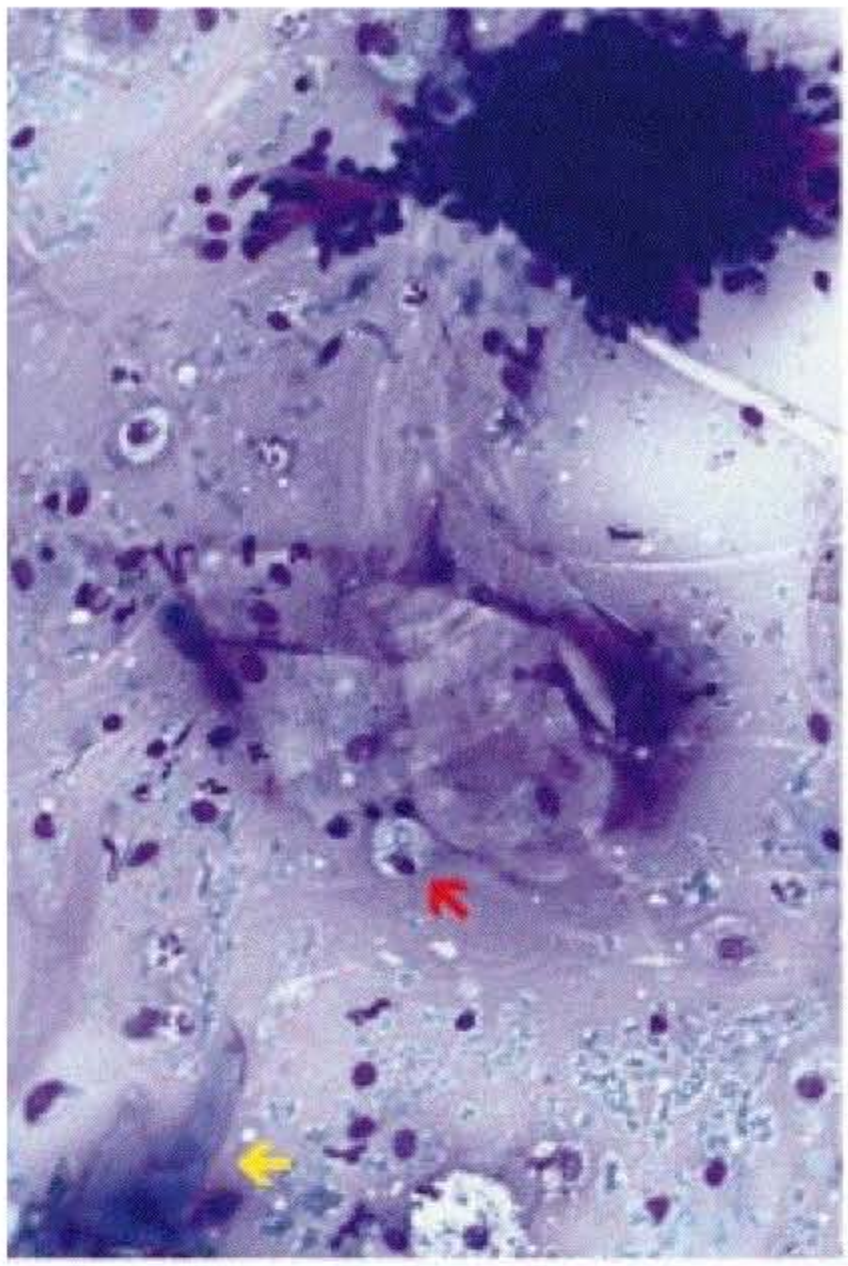

7.56

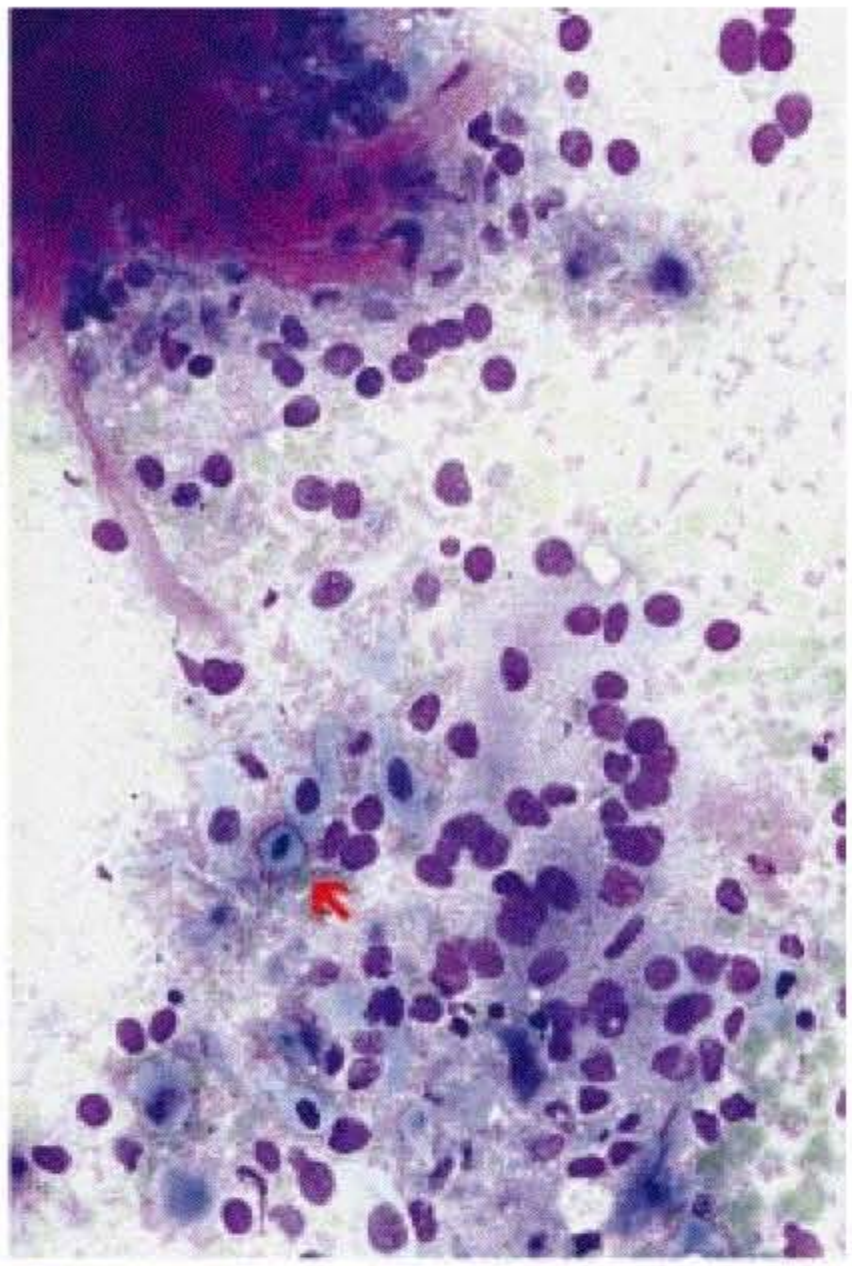

7.57

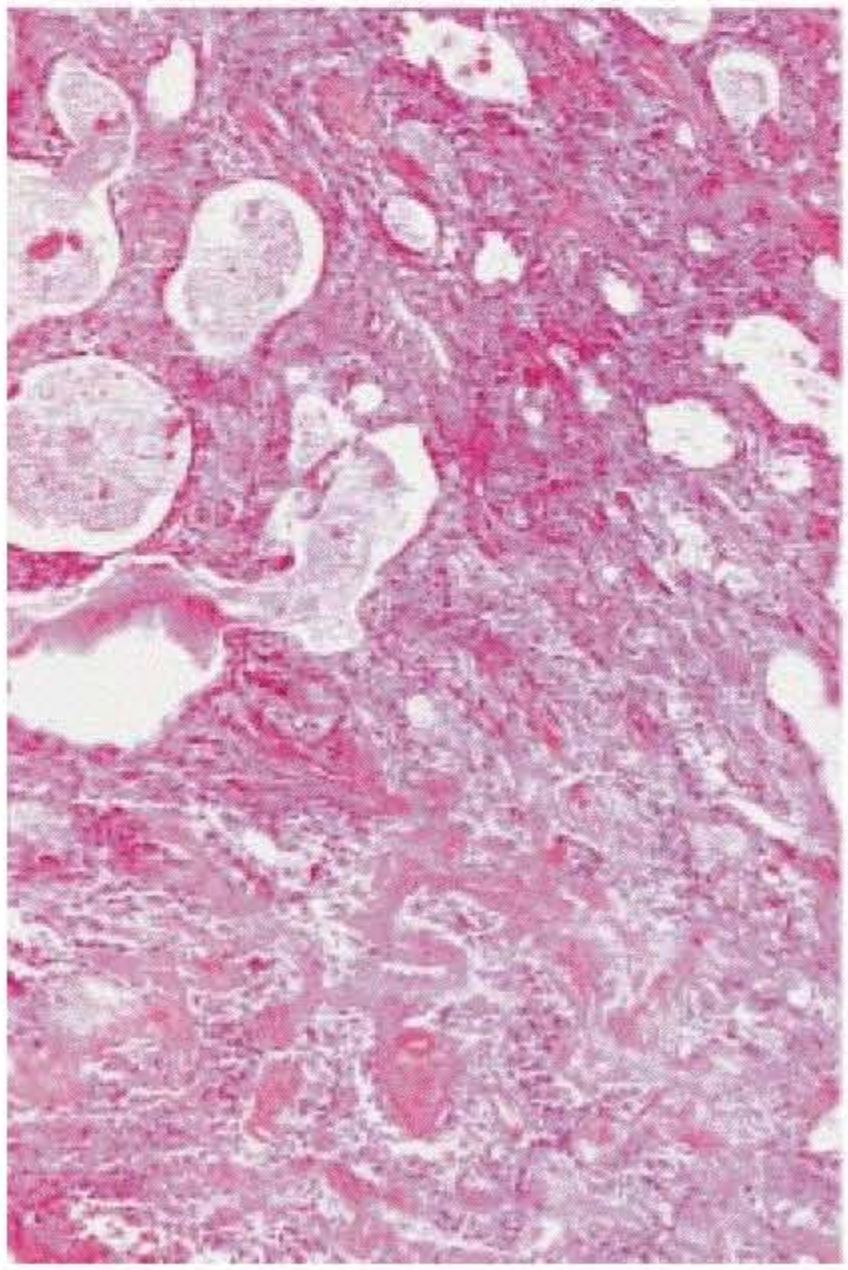

7.58

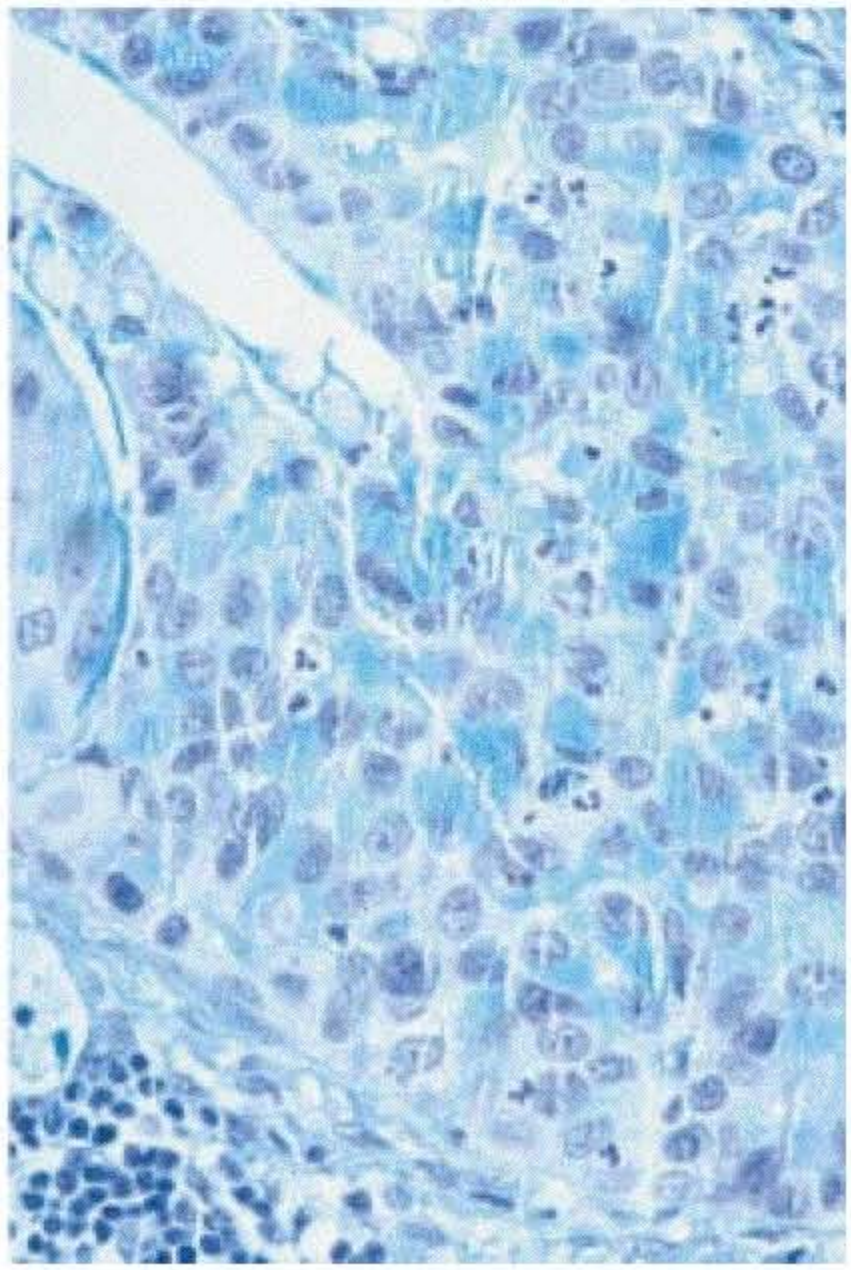

7.59

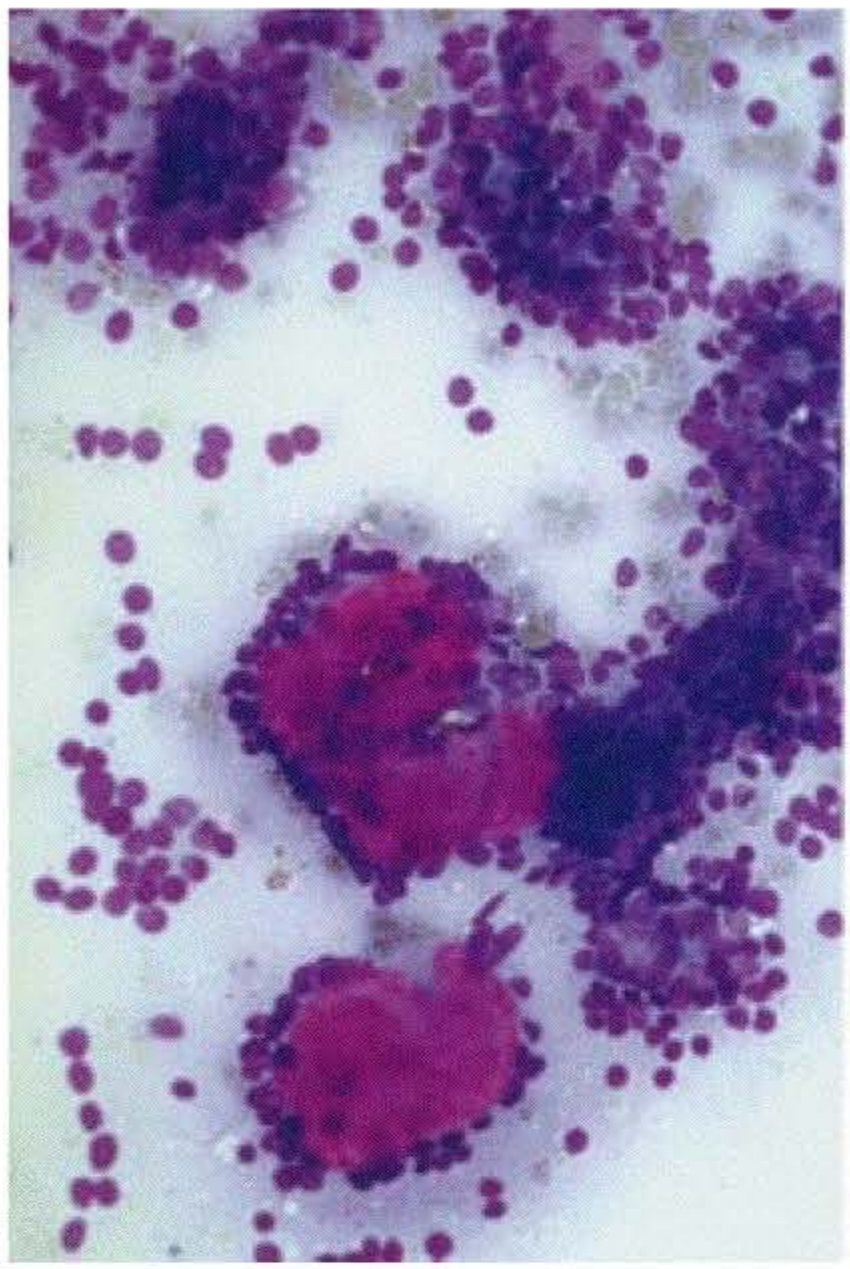

7.60

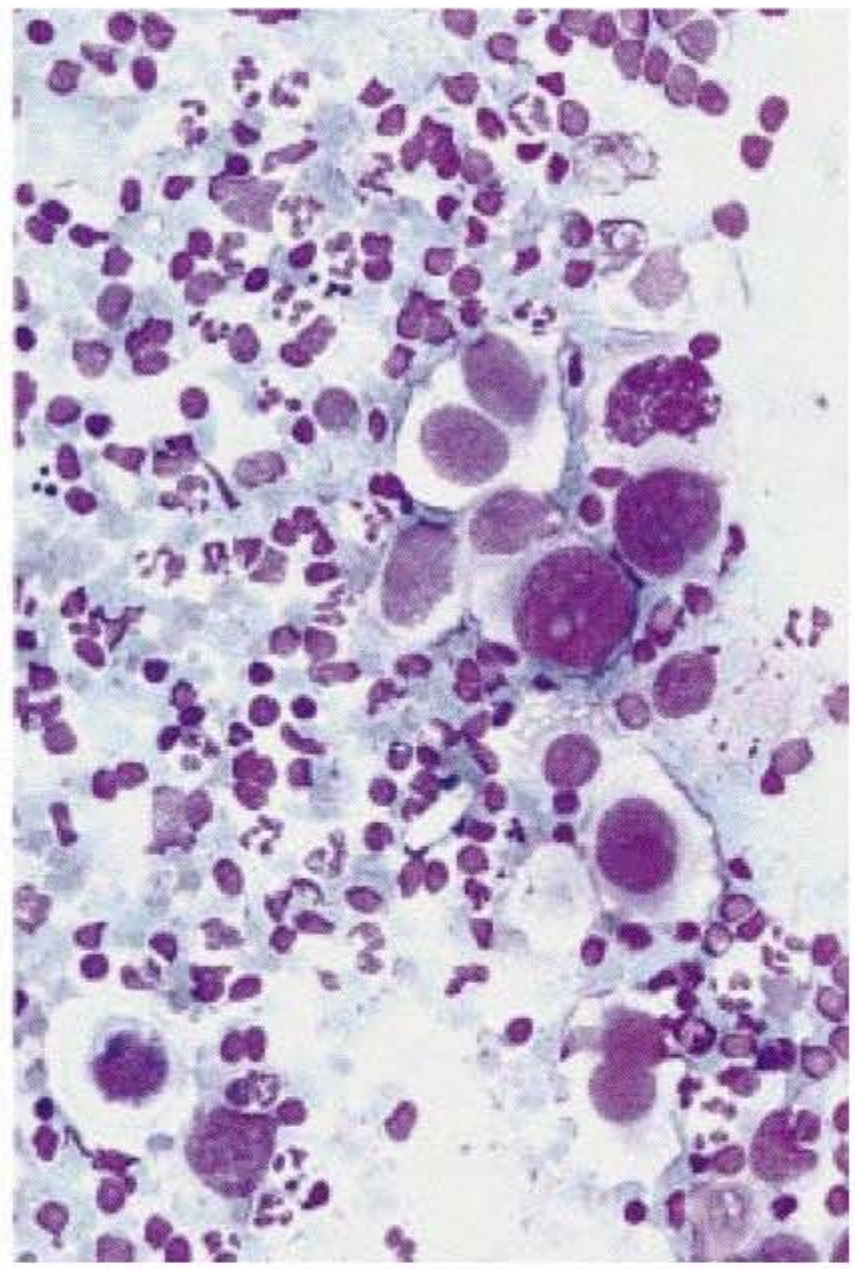

7.61

Fig. 7.60. Adenoid cystic carcinoma ex pleomorphic adenoma. Pleomorphic adenoma patterns were not found. MGG. ×128.

Fig. 7.61. Salivary duct carcinoma ex pleomorphic adenoma. Isolated malignant cells with numerous lymphocytes. Pleomorphic adenoma patterns were not found. MGG. ×128.

7.6.5.2. Histopathology

The nature and extent of the carcinomatous component may vary according to the type of carcinoma. The malignant component typically consists of poorly-differentiated adenocarcinoma, but a wide spectrum of histological subtypes and grades may be observed [89, 130, 184].

7.6.5.3. Cytopathology

Fine-needle sampling is an accurate technique to diagnose high-grade carcinoma ex pleomorphic adenoma, but difficulties may be encountered in the diagnosis of low-grade malignancies [184, 187]. An accurate diagnosis may be established in the case of high-grade mucoepidermoid carcinoma arising in pleomorphic adenoma, when characteristic cytological features of the latter (plasmacytoid cells and chondromyxoid stroma) coexists with malignant cells typical of the former (fig. 7.56–7.59). In general, high-grade malignancies arising in pleomorphic adenoma can be accurately diagnosed by cytology regardless of whether the tumour is infiltrative or in situ (fig. 7.60–7.64). However, smears frequently contain only three-dimensional clusters or glandular structures, making cytological analysis difficult.

Fig. 7.62. Salivary duct carcinoma ex pleomorphic adenoma. Histological section corresponding to figure 7.61. Pleomorphic adenoma is not shown. HES. ×32.

Fig. 7.63. Squamous cell carcinoma ex pleomorphic adenoma. Malignant keratinising cells. Pleomorphic adenoma patterns were not found. MGG. ×128.

Fig. 7.64. Squamous cell carcinoma ex pleomorphic adenoma. Pleomorphic adenoma is not shown. HES. ×64.

Fig. 7.65. Carcinosarcoma. Chondromyxoid stroma with dark myoepithelial cells and one large sarcoma cell (arrow). Corresponding histology showed chondrosarcoma and poorly-differentiated adenocarcinoma. MGG. ×128.

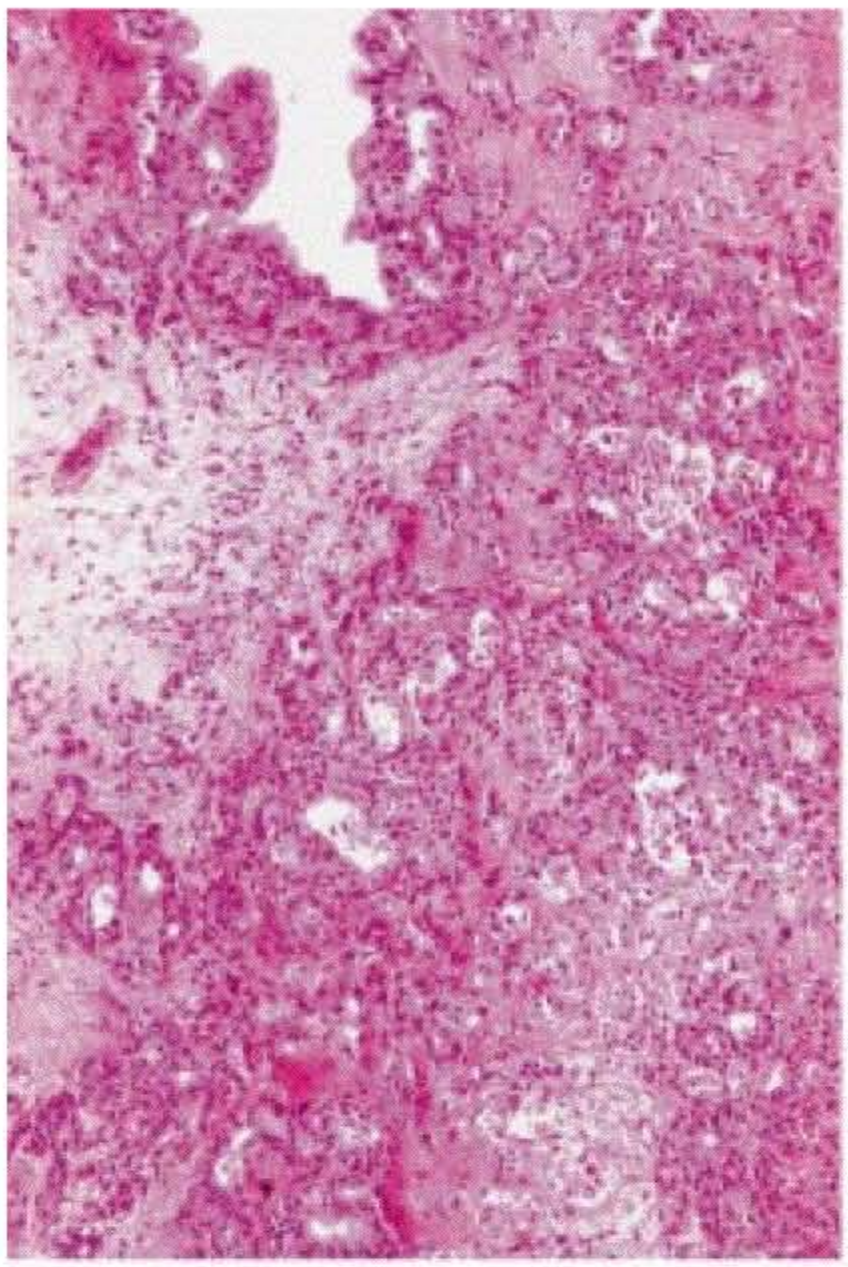

7.62

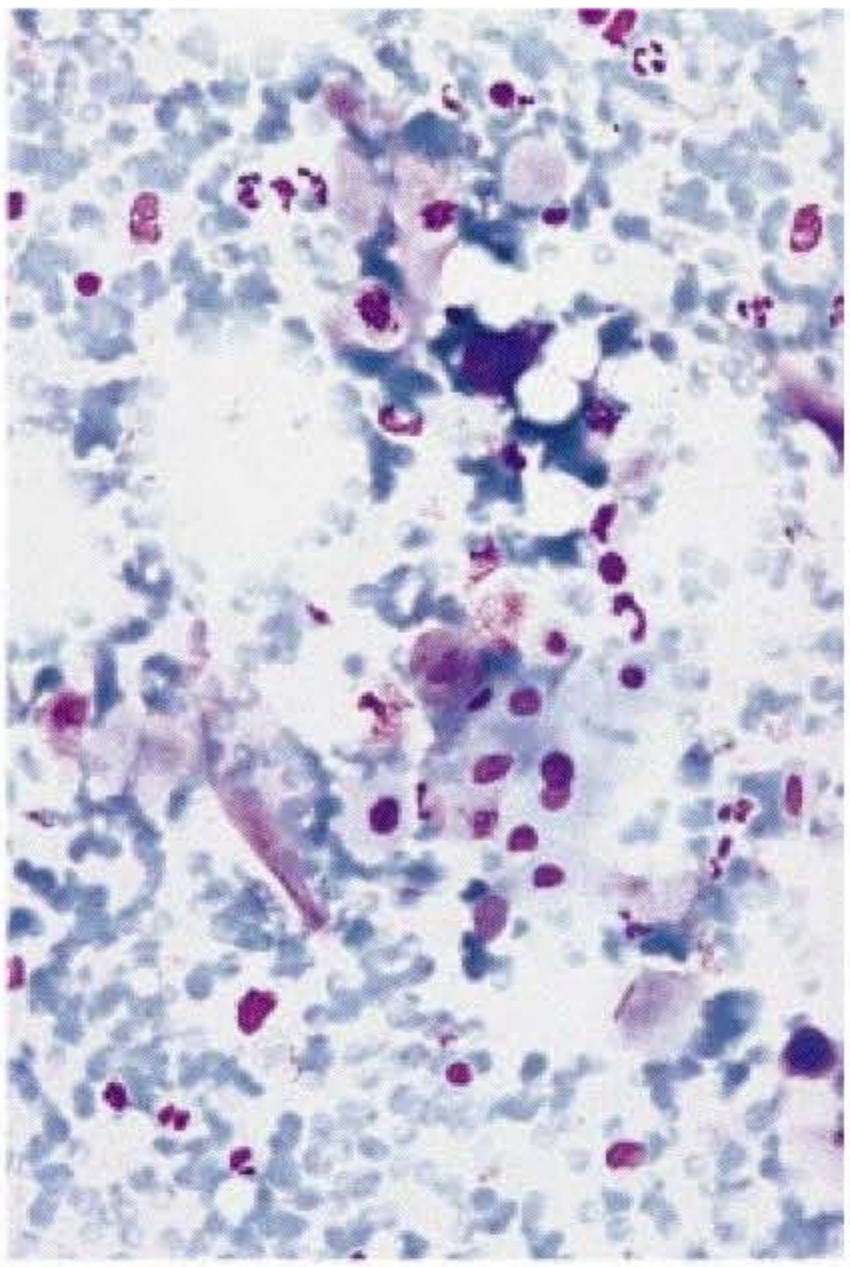

7.63

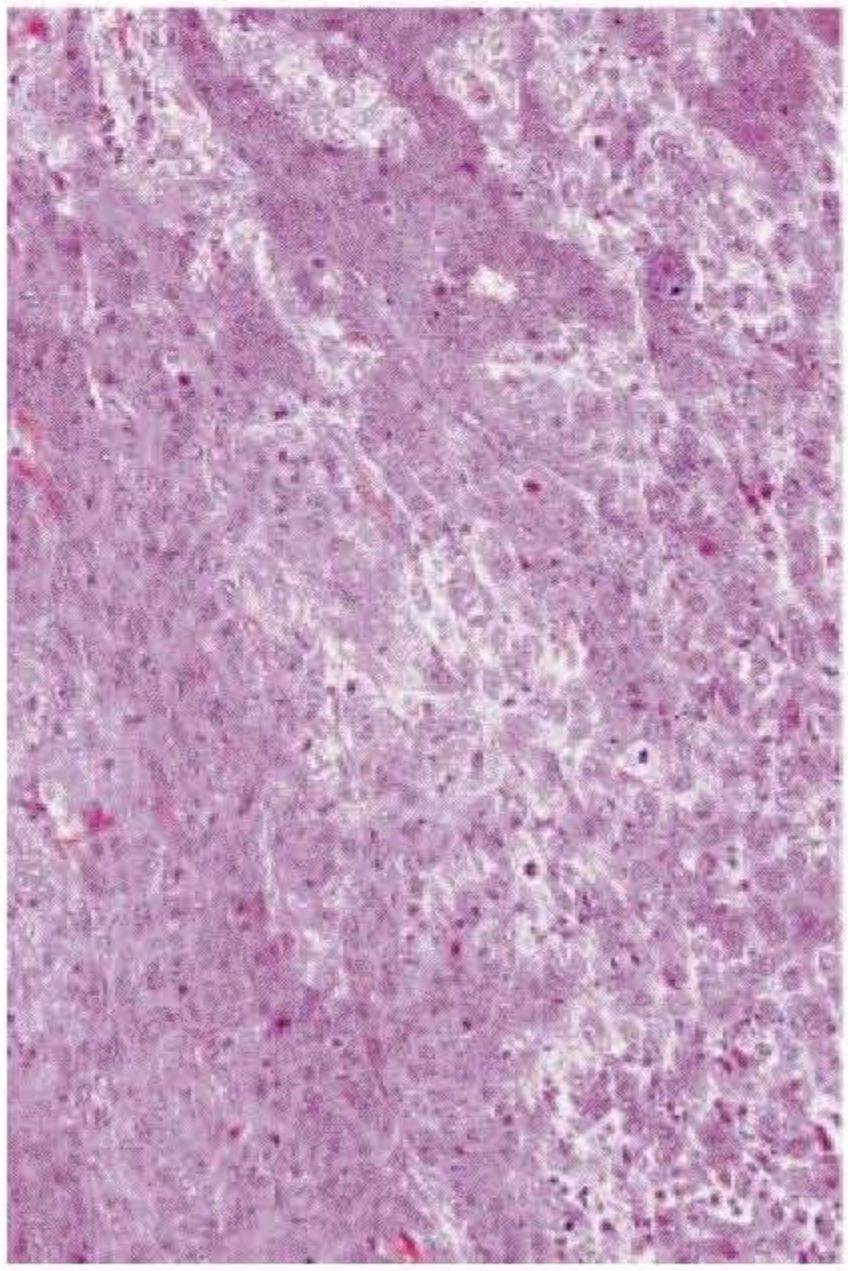

7.64

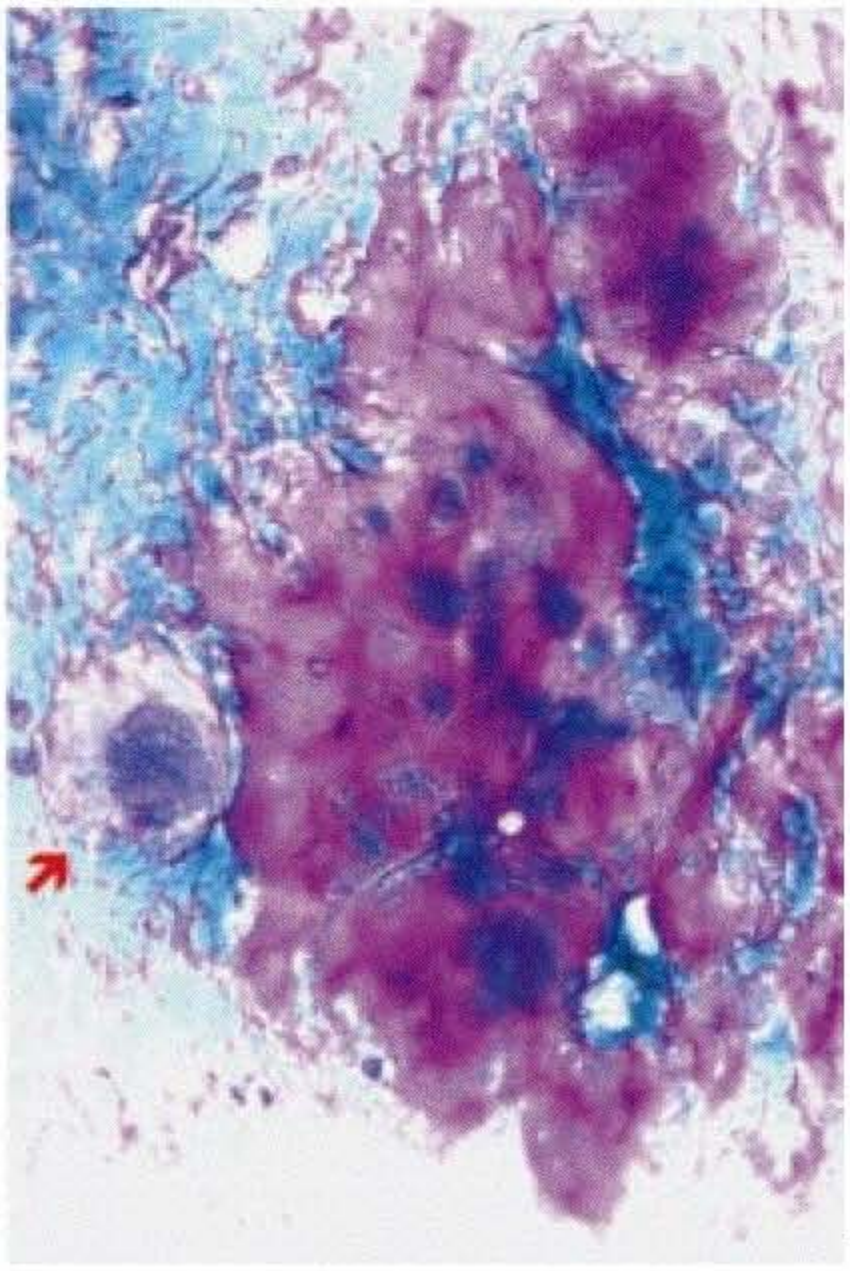

7.65

Table 7.18. Correlation between cytology and histology in carcinoma ex pleomorphic adenoma

Author [ref.]	Number	Malignant	Suspicious	False-negative	Unsatisfactory
Bonneau, Sommer [31]	6	4	0	2	0
Eneroth et al. [96]	5	3	1	1	0
Persson, Zettergren [270]	3	1	0	2	0
Lindberg, Åkerman [222]	3	1	0	2	0
Geisinger et al. [123]	1	1	0	0	0
O'Dwyer et al. [261]	3	1	0	2	0
Young et al. [351]	1	0	0	0	1
Smith Frable, Frable [313]	2	2	0	0	0
Zurrida et al. [358]	1	1	0	0	0
Klitz, Bishop Pitman [202]	4	2	1	1	0
Jacobs [165]	1	1	0	0	0
Orell [263]	6	3	2	1	0
Pitman [276]	1	1	0	0	0
Ersöz et al. [104]	1	1	0	0	0
Al-Khafaji [8]	2	0	0	2	0
Heintz et al. [152]	1	1	0	0	0
Klijanienko, Vielh [184]	26	13	2	11	0
Anand, Brockie [9]	1	1	0	0	0
Total	68	37 (54.4)	6 (8.8)	24 (35.3)	1 (1.5)

Statistics from the literature. % in parentheses.

Table 7.19. Correlation between cytology and histology in carcinosarcomas

Author [ref.]	Number	Malignant	Suspicious	False-negative	Unsatisfactory
Granger et al. [139]	1	1	0	0	0
De la Torre, Larsson [78]	1	1	0	0	0
Kim et al. [181]	1	1	0	0	0
Latkovitch, Johnson [212]	1	0	1	0	0
Our series	1	1	0	0	0
Total	5	4 (80)	1 (20)	0 (0)	0 (0)

Statistics from the literature. % in parentheses.

7.6.5.4. Diagnostic Accuracy

False-negative results are mainly related to tumour sampling. This is underscored by the finding of false-negative cytological diagnoses in low-grade categories. Although no difference in tumour size is found between cytologically positive and negative cases, the influence of this parameter in low-grade malignancy cannot be excluded. Collective analysis of preoperative cytological examinations showed that malignancy is recognized in only 54.4% of tumours. This tumour is characterized by a very high rate (35.3%) of false-negative results, the highest of all salivary gland tumours (table 7.18).

7.6.5.5. Differential Diagnosis

The main differential diagnoses are cellular pleomorphic adenoma and low-grade malignancies arising in pleomorphic adenoma, such as low-grade polymorphous adenocarcinoma and basal cell adenocarcinoma. Smears positive for high-grade malignancy require accurate tumour typing.

Carcinoma Ex Pleomorphic Adenoma

In favour of the diagnosis

Signs of carcinoma adjacent to features of pleomorphic adenoma (plasmacytoid myoepithelial cells with coarse chromatin, chondromyxoid stroma)

Difficulties

Low-grade malignancies, de novo pattern

Against the diagnosis

Marked variation of nuclear size of myoepithelial cells suggests highly cellular pleomorphic adenoma

7.6.6. Carcinosarcoma (True Malignant Mixed Tumour)

7.6.6.1 General

Fewer than 50 cases have been reported in the literature. These tumours arise from main or accessory salivary glands [89].

7.6.6.2. Histopathology

These tumours are composed of an admixture of carcinoma and sarcoma [89, 121]. The carcinomatous component is poorly-differentiated adenocarcinoma and the sarcomatous component may correspond to chondrosarcoma, osteosarcoma, fibrosarcoma, malignant fibrous histiocytoma, rhabdomyosarcoma or liposarcoma.

7.6.6.3. Cytopathology

The diagnosis of carcinosarcoma may be established in the combined presence of definite carcinomatous cells and sarcomatous components (fig. 7.65).

7.6.6.4. Diagnostic Accuracy

Only four well-documented examples have been reported in the cytological literature (table 7.19).

7.6.6.5. Differential Diagnosis

The sarcomatous component represents a diagnostic challenge and must be differentiated from primary or metastatic sarcoma, especially chondrosarcoma. The differential diagnosis must also include chordoma (fig. 9.15), and pleomorphic adenoma with nuclear atypia (fig. 6.8) [198].

Chapter 8

Low-Grade Carcinomas

Low-grade tumours in general are characterized by a lower rate of accurate cytological diagnosis. This is particularly marked for mucoepidermoid carcinoma and acinic cell carcinoma. Low-grade tumours must be differentiated not only from their benign counterparts and similar neoplastic or pseudoneoplastic lesions (mucoepidermoid carcinoma versus cysts, basal cell adenocarcinoma versus basal cell adenoma, polymorphous low-grade adenocarcinoma versus cellular pleomorphic adenoma, papillary cystic adenocarcinoma versus papillary cystadenoma), but also from intermediate- and high-grade malignancies, especially adenoid cystic carcinoma and epithelial-myoepithelial carcinoma.

8.1. Low-Grade Mucoepidermoid Carcinoma

Foote and Frazell [113] classified mucoepidermoid carcinomas into three grades of malignancy: low-grade (well-differentiated form which exhibits more than 50% of mucous structures), intermediate-grade (10–50% of mucous structures) and high-grade (less than 10% of mucous structures). A consensus has still not been reached, as many investigators advocate the use of only two grades (i.e. low- and high-grade), as recommended by the recent WHO classification [300]. This two-step grading fits with cytology findings, since high- and intermediate-grade tumours are cytologically similar, whereas low-grade tumours exhibit more subtle cytological abnormalities often difficult to diagnose.

8.1.1. General

Low-grade mucoepidermoid carcinomas represent approximately 80% of all mucoepidermoid carcinomas of major and minor salivary glands [89] with a mortality rate of 3.3 versus 57% for intermediate- and high-grade mucoepidermoid carcinomas.

8.1.2. Histopathology

Low-grade mucoepidermoid carcinomas are composed of unilocular or multilocular cystic growth with papillary projections [89]. These structures are lined by mucus-secreting cells. Cysts have a mucoid content and contain isolated mucus-secreting cells, inflammatory cells and cell fragments (fig. 8.1, 8.2). Tubular structures and solid cords of intermediate cells may be present, but squamous cells with scant keratinization are exceptional and mitotic figures are rare or absent. Stroma is often fibrous and contains extracellular mucin and inflammatory cells.

8.1.3. Cytopathology

In contrast with high-grade carcinoma, smears are paucicellular and stroma-rich [62, 196]. Aspiration biopsy usually yields cyst fluid, which may result in a reduction of tumour volume and the material is difficult to smear.

The stroma is composed of metachromatic, dark blue to pink dense mucoid material on MGG stain (clear to dark green when Papanicolaou stain is used) (fig. 8.3).

Cellular material is scant and generally composed of two cell types: mucus-secreting cells and intermediate cells. Mucus-secreting cells may be loosely cohesive and may therefore closely resemble histiocytes with small, uniform nuclei and abundant micro- and macrovacuolated cytoplasm (fig. 8.4). Some mucus-secreting cells are character-

Fig. 8.1. Low-grade mucoepidermoid carcinoma. Histological section showing multilocular cyst with papillary projections. HES. ×32.

Fig. 8.2. Low-grade mucoepidermoid carcinoma. Mucoid content with numerous mucus-secreting cells with clear cytoplasm and inflammatory cells. HES. ×64.

Fig. 8.3. Low-grade mucoepidermoid carcinoma. Characteristic mucus-rich background. MGG. ×128.

Fig. 8.4. Low-grade mucoepidermoid carcinoma. Histiocyte-like, mucus-secreting cell (arrow). MGG. ×128.

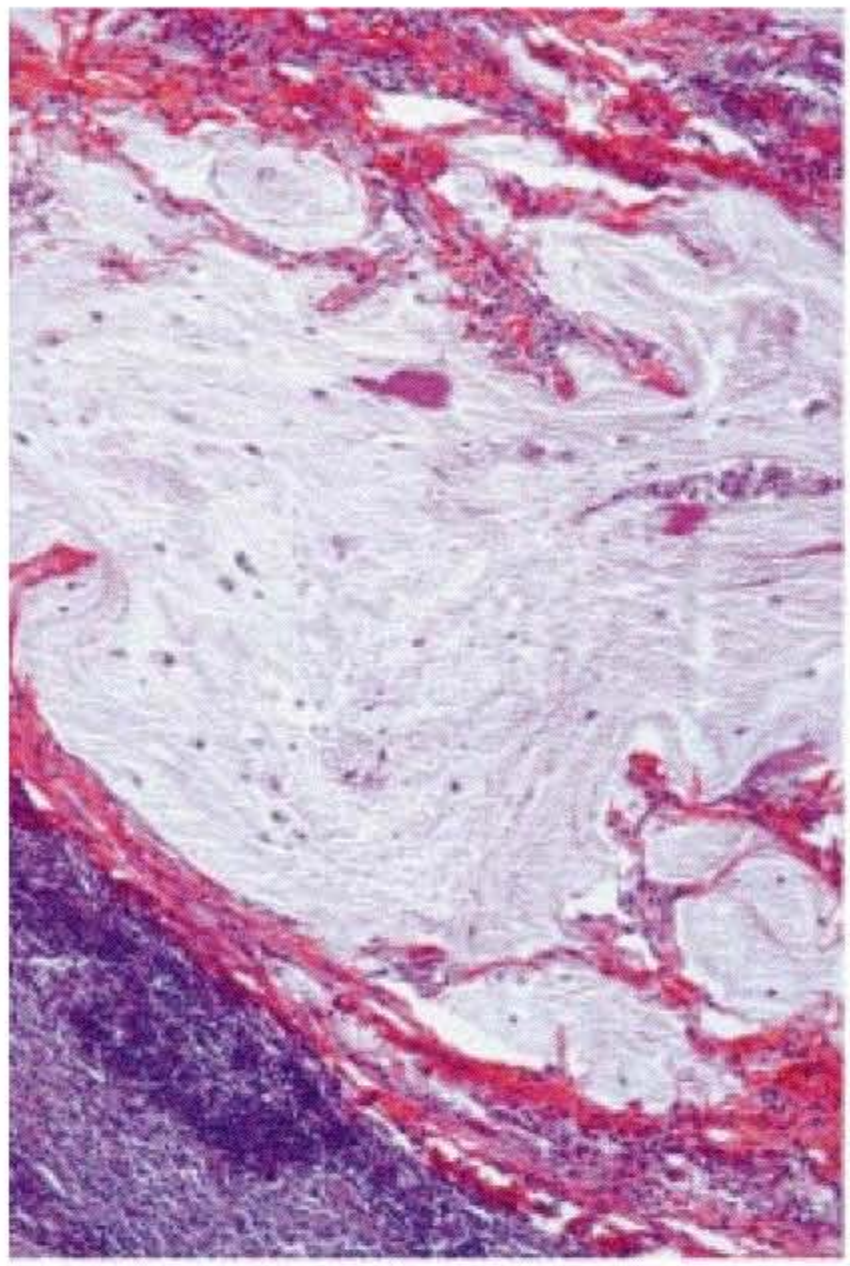

8.1

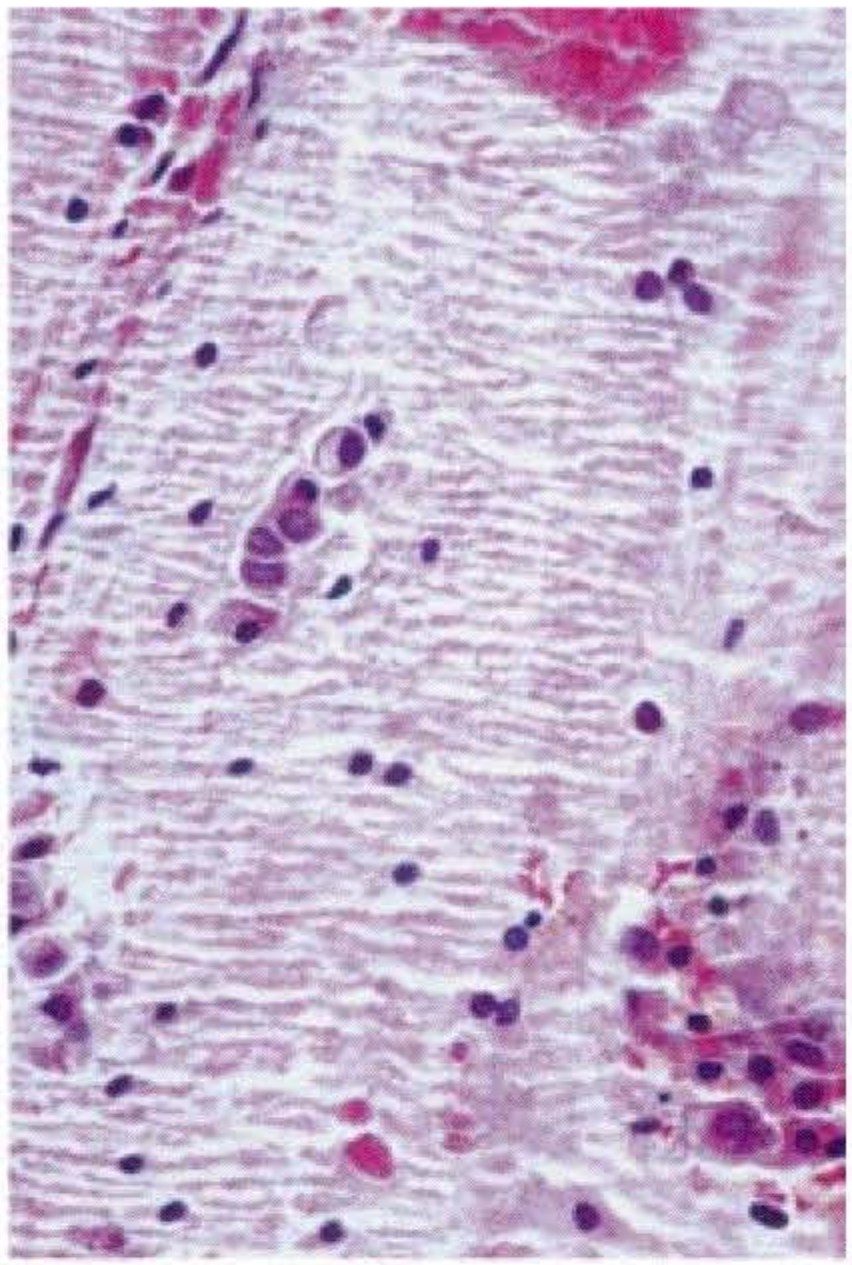

8.2

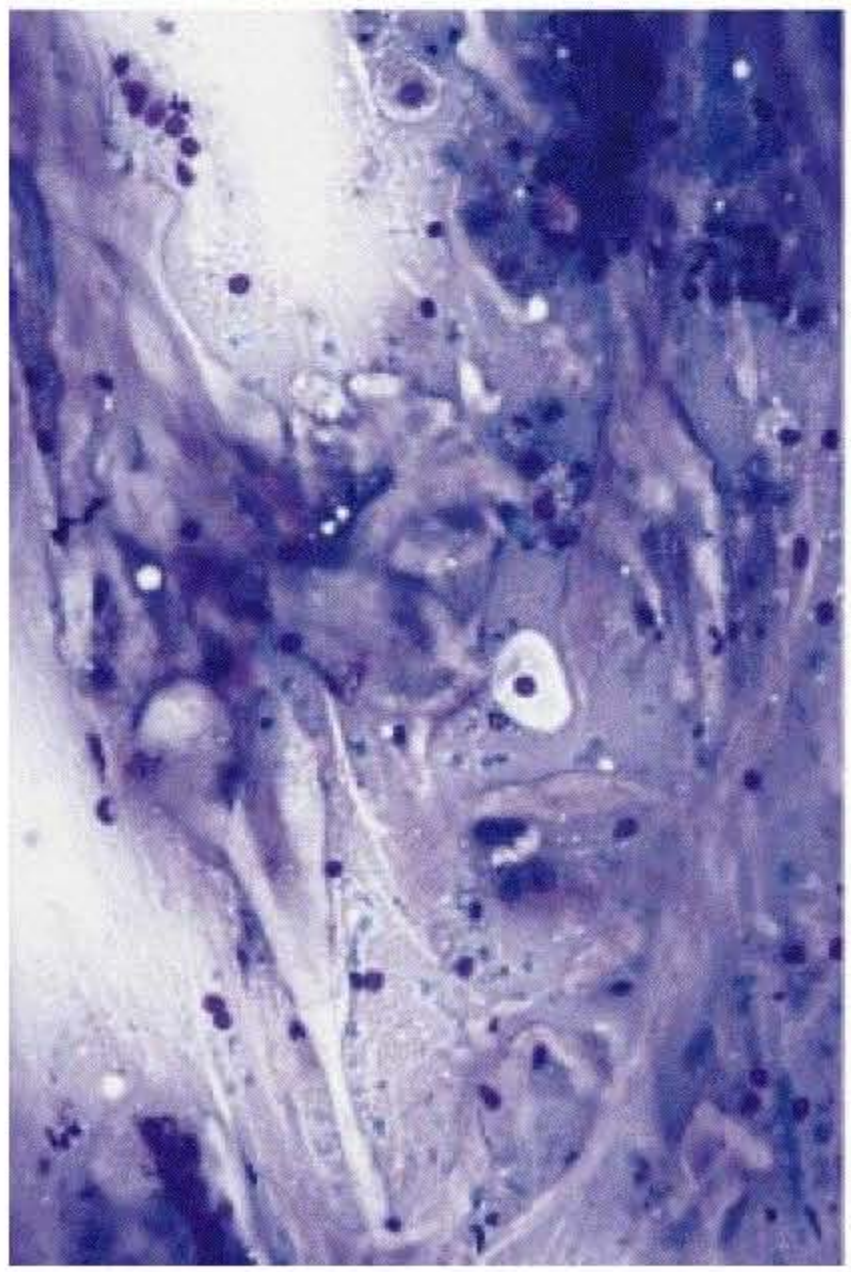

8.3

8.4

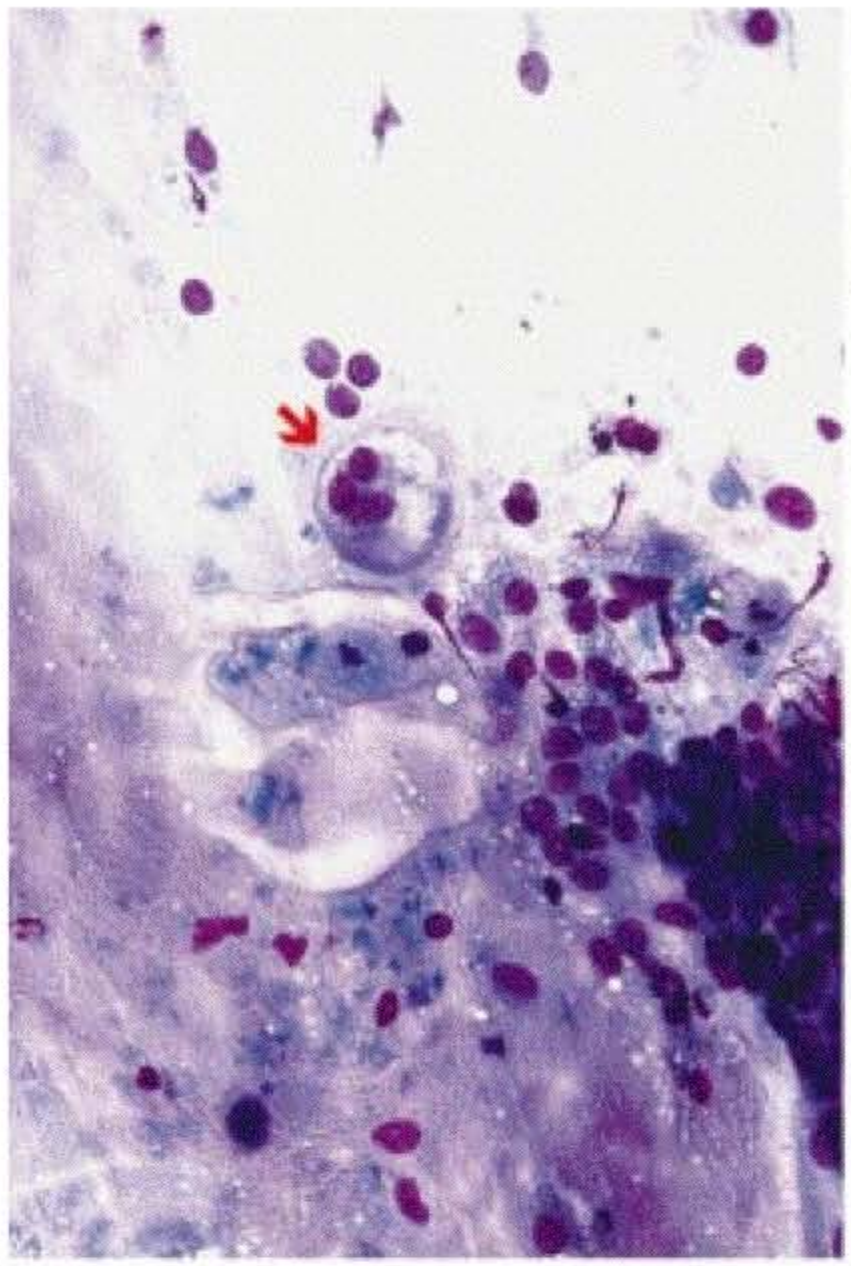

8.5

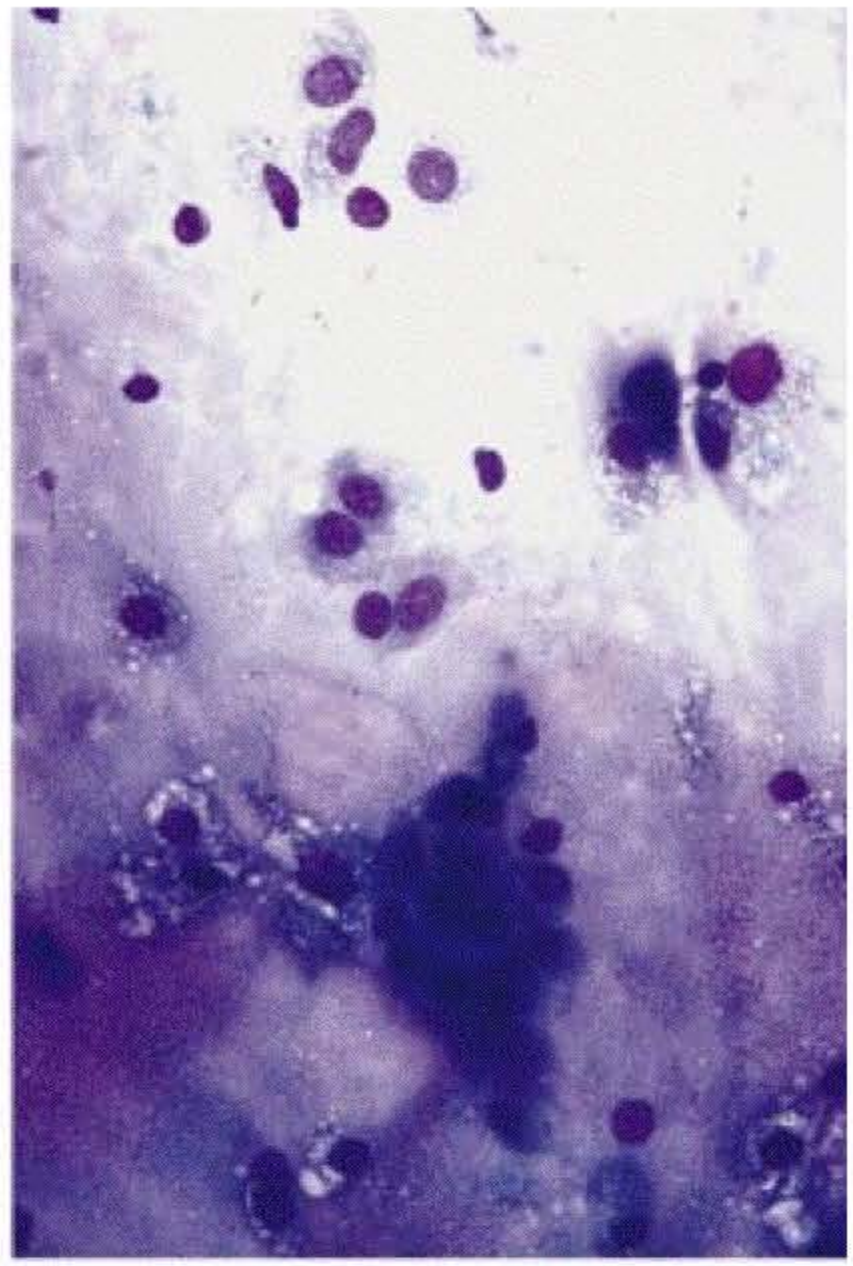

8.6

8.7

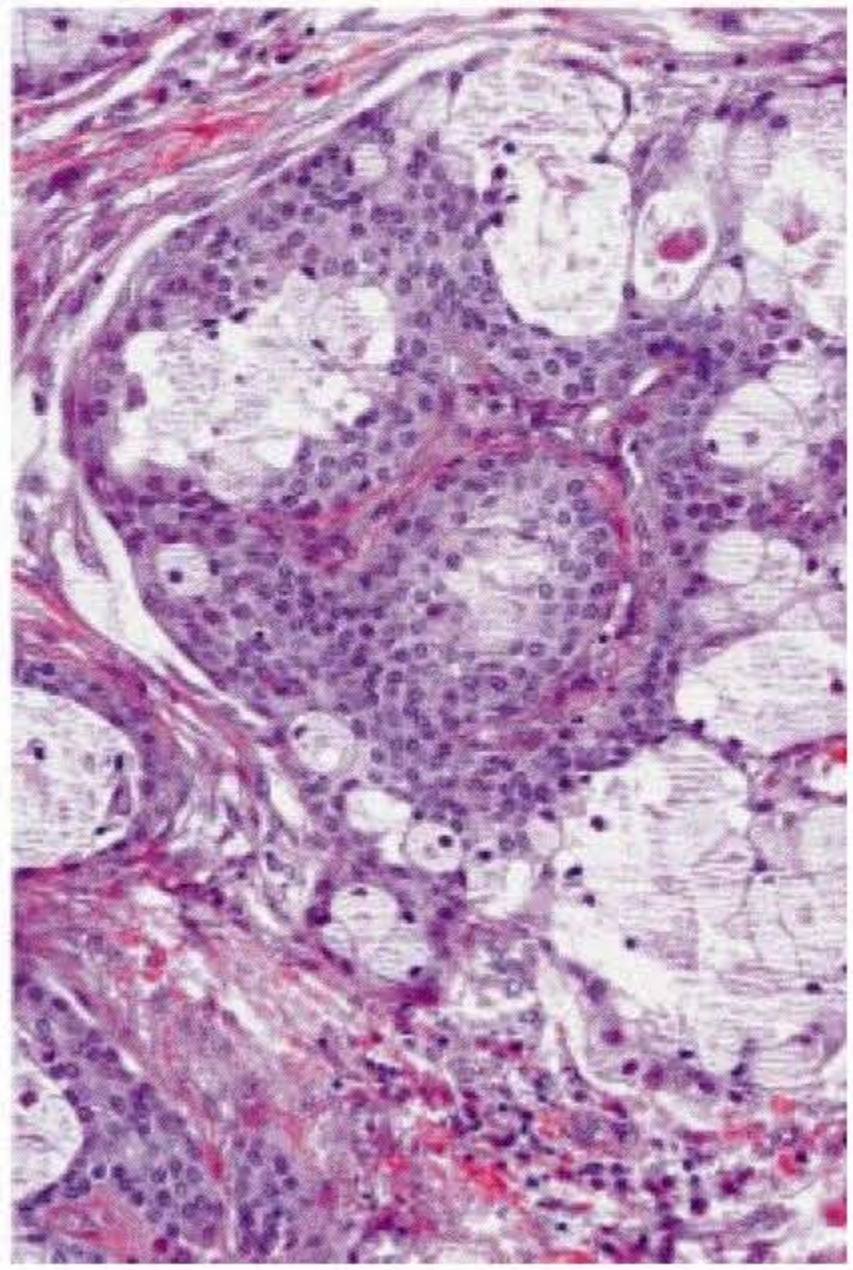

8.8

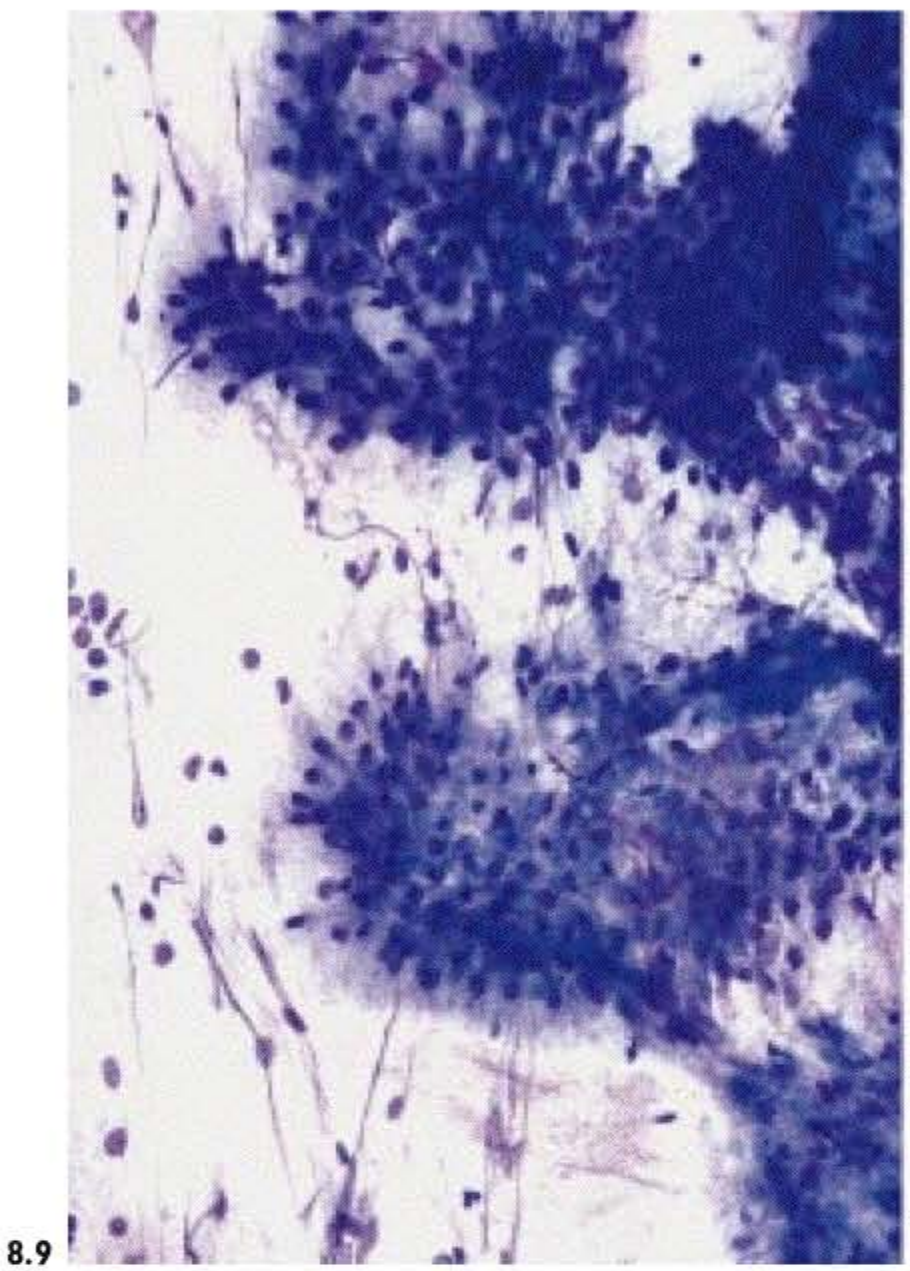

8.9

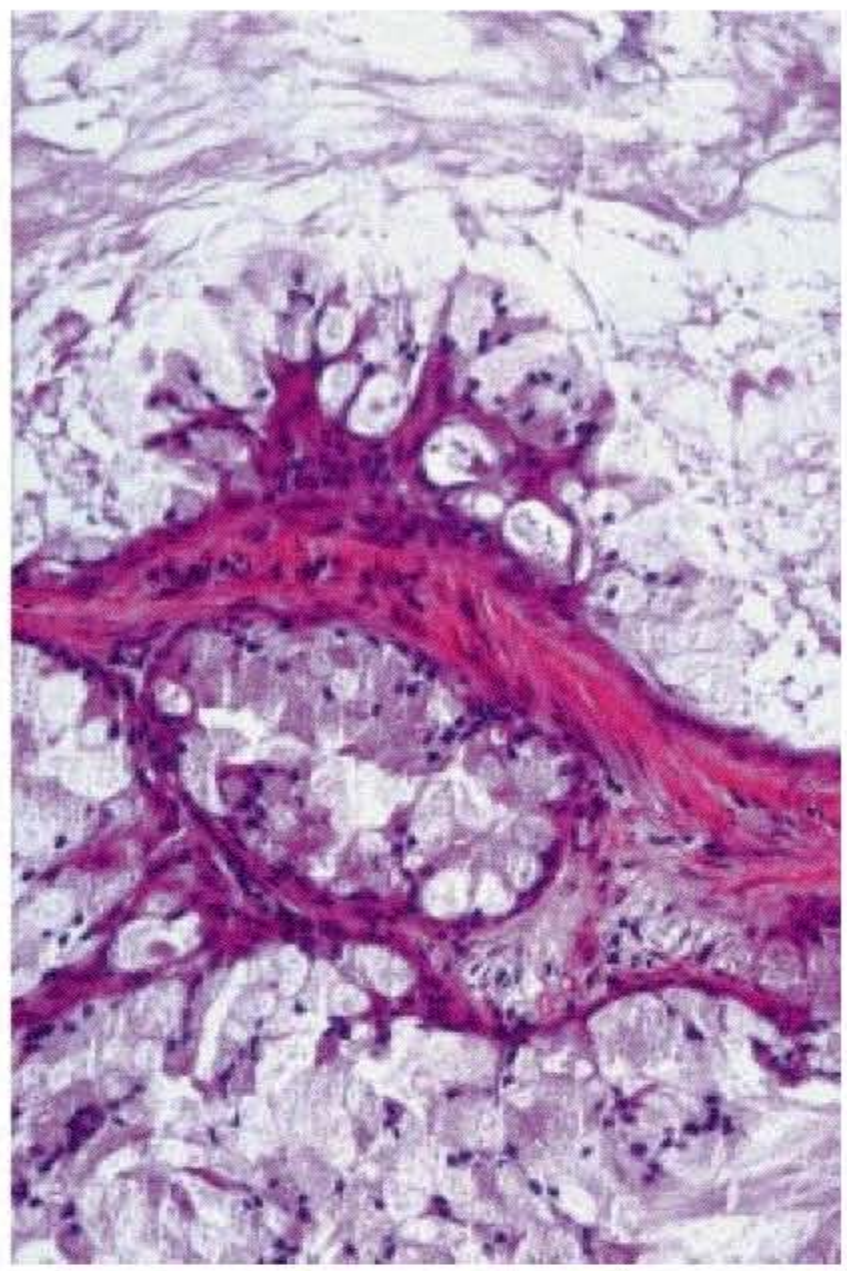

8.10

Fig. 8.9. Low-grade mucoepidermoid carcinoma. Projections lined by goblet cells. MGG. ×64.
Fig. 8.10. Low-grade mucoepidermoid carcinoma. Histological section corresponding to figure 8.9. HES. ×32.

ized by the presence of large intracytoplasmic vacuoles (goblet cells) (fig. 8.5). Intermediate cells are frequently clustered. Occasionally, both mucus-secreting and intermediate cells are clustered in oval or papillary formations (fig. 8.6–8.10). Squamous cells are exceptional.

Inflammatory cells, mast cells, pseudo-oncocytes and stromal fragments may also be seen (fig. 8.3, 8.11).

Fig. 8.5. Low-grade mucoepidermoid carcinoma. Goblet cells (arrow) with large intracytoplasmic vacuoles. MGG. ×128.
Fig. 8.6. Low-grade mucoepidermoid carcinoma. Histiocyte-like and goblet cells in an abundant mucoid background. MGG. ×128.
Fig. 8.7. Low-grade mucoepidermoid carcinoma. Clustered mucus-secreting and intermediate cells. MGG. ×128.
Fig. 8.8. Low-grade mucoepidermoid carcinoma. Histological section corresponding to figure 8.7. showing oval or papillary formations with mucus-secreting and intermediate cells. HES. ×64.

8.1.4. Diagnostic Accuracy

The cystic nature of the sample, the failure to recognize the epithelial nature of such cells with a finely vacuolated cytoplasm, and the absence or rarity of intermediate or squamous cells, explain why low-grade mucoepidermoid carcinomas are often misdiagnosed as benign tumours or cysts.

The classification into two histoprognostic groups is poorly reported in the literature, and detailed data are generally not available. However, there is a general consensus that low-grade mucoepidermoid carcinoma is difficult to diagnose as malignancy. In our previous study [196] of 22 low-grade mucoepidermoid carcinomas, malignancy was diagnosed or suspected in only 15 (68%) cases. We propose that, when the cystic lesion does not disappear after fine-needle aspiration, or when an unsatisfactory and purely mucoid cytological sample is obtained, the patient should be referred for ultrasound-guided fine-needle sampling or surgery with intraoperative frozen section examination.

Table 8.1. Quantitative differential diagnosis of low-grade mucoepidermoid carcinoma

Component	Low-grade mucoepidermoid carcinoma	Salivary cyst	Warthin's tumour	Pleomorphic adenoma	Küttner's tumour
Stroma					
Mucoid	++	+	+/–	+/–	+
Inflammatory	+	+/–	++	–	++
(Pseudo)necrotic	+	+	++	–	+
Chondromyxoid	–	–	–	++	–
Cells					
Mucus-secreting	++	+/–	–	–	+
Intermediate	+	–	–	–	–
Plasmacytoid	–	–	–	++	–
Oncocytes	+/–	+/–	++	+/–	–
Mast cells	+/–	–	+	+/–	–

++ = Common; + = rare; +/– = occasionally seen; – = absent.

8.1.5. Differential Diagnosis

Low-grade mucoepidermoid carcinoma should be differentiated from salivary cyst, Warthin's tumour, pleomorphic adenoma with mucoid stroma and Küttner's tumour (table 8.1).

8.1.5.1. Low-Grade Mucoepidermoid Carcinoma vs. Salivary Cyst

The differential diagnosis is impossible when the smear only contains mucoid stroma with no epithelial cells (fig. 12.6). However, the presence of mucus-secreting (pseudohistiocytic and goblet) cells is strongly in favour of mucoepidermoid carcinoma (fig. 8.4, 8.5).

8.1.5.2. Low-Grade Mucoepidermoid Carcinoma vs. Warthin's Tumour

Warthin's tumour may occasionally show dense mucoid secretion, pseudonecrosis and scant oncocytes (fig. 6.24, 6.27). The differential diagnosis with low-grade mucoepidermoid carcinoma may be difficult in such cases. The presence of isolated or clustered oncocytes is in favour of Warthin's tumour, but oncocyte-like cells may also be seen in some mucoepidermoid carcinomas. In contrast, the presence of mucus-secreting (pseudohistiocytic or goblet) cells and intermediate (isolated or clustered) cells is in favour of mucoepidermoid carcinoma (fig. 8.4, 8.5).

Mast cells may be present in both entities, but are more frequent in Warthin's tumour (fig. 6.28, 8.11).

8.1.5.3. Low-Grade Mucoepidermoid Carcinoma vs. Pleomorphic Adenoma with Mucoid Stroma

Mucoid stroma, seen in rare examples of pleomorphic adenoma, may mimic low-grade mucoepidermoid carcinoma (fig. 6.15). The presence of plasmacytoid cells and chondromyxoid stroma are strongly in favour of pleomorphic adenoma. The diagnosis of mucoepidermoid carcinoma arising from pleomorphic adenoma is based on the concurrent presence of pleomorphic adenoma (plasmacytoid cells and chondromyxoid stroma) and mucoepidermoid carcinoma (mucoid stroma, mucus-secreting cells, intermediate cells) (fig. 7.56, 7.57).

8.1.5.4. Low-Grade Mucoepidermoid Carcinoma vs. Küttner's Tumour

Extreme caution is required in the case of a submandibular tumour, especially with a long clinical history. Dark clusters of metaplastic epithelial cells, mucoid secretion, histiocytes and acute and subacute inflammatory cells in Küttner's tumour may mimic low-grade mucoepidermoid carcinoma (fig. 12.8). We suggest that all submandibular gland tumours be underdiagnosed when a mucoepidermoid carcinoma is suspected, with referral of the patient for surgery with intraoperative frozen section examination.

Low-Grade Mucoepidermoid Carcinoma

In favour of the diagnosis

Cystic tumour, characteristic mucoid stroma, clustered or isolated mucus-secreting (pseudohistiocytic and goblet) cells, intermediate cells, mast cells

Difficulties

Purely mucoid smears, oncocytic-like cells, submandibular site

Against the diagnosis

Plasmacytoid cells, chondromyxoid stroma, oncocytes

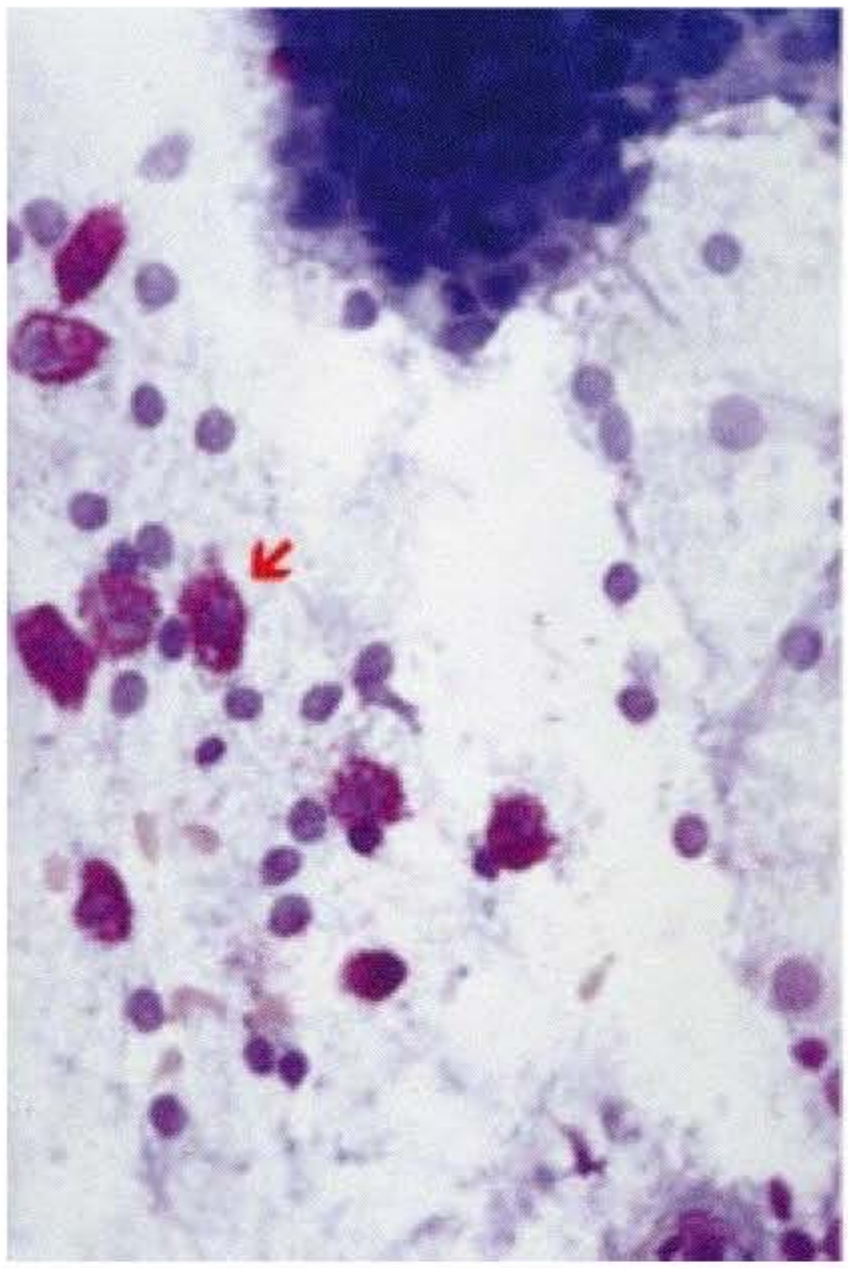

8.11

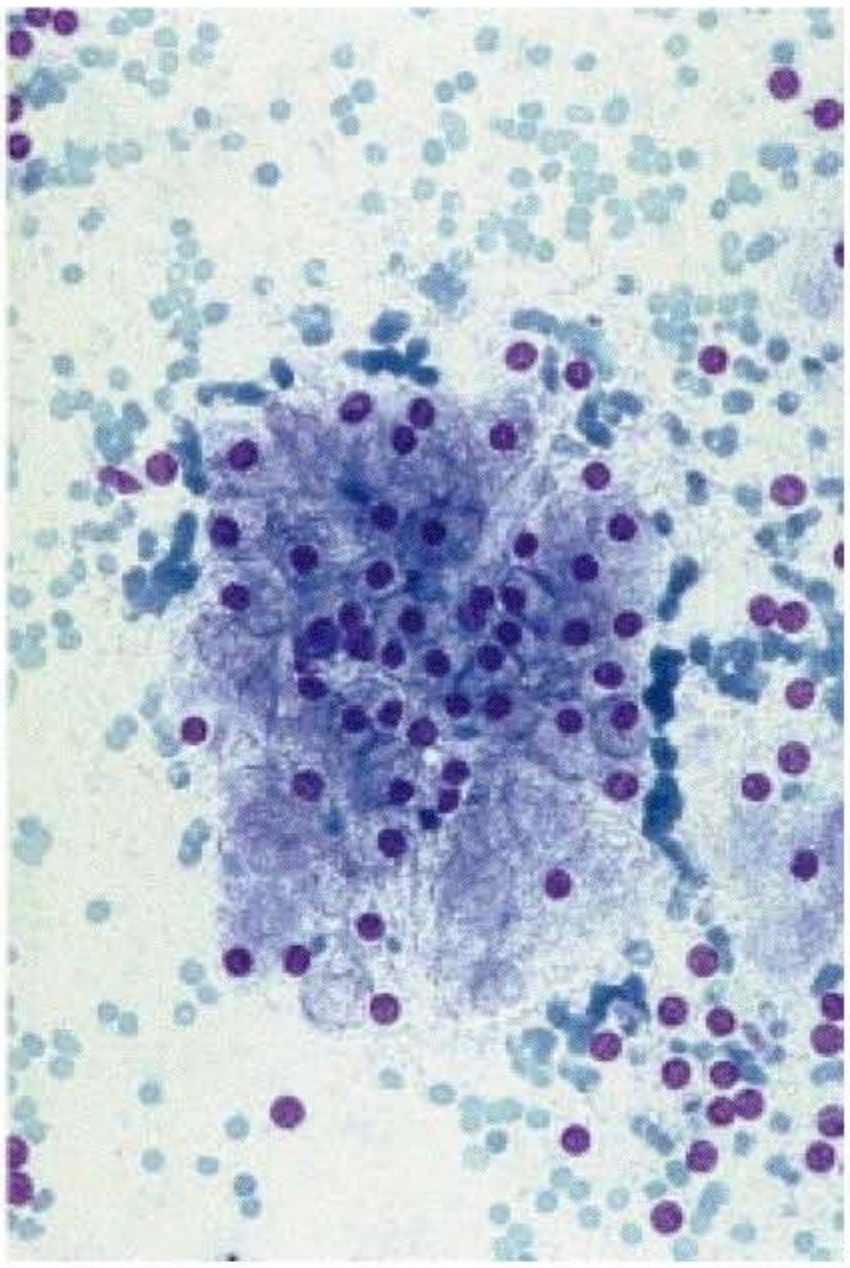

8.12

Fig. 8.11. Mucoepidermoid carcinoma, low-grade. Mast cells (arrow). MGG. ×128.
Fig. 8.12. Acinic cell carcinoma, well-differentiated. Large acinar cells with eccentric nuclei and abundant basophilic granular cytoplasm. These cells are frequently arranged in clusters with acinar and glandular structures. MGG. ×128.

8.2. Acinic Cell Carcinoma

Acinic cell carcinoma is a low-grade malignant tumour with a risk of local recurrence and metastasis.

8.2.1. General

Acinic cell carcinoma represents 2–7% of all salivary gland tumours. It predominantly arises in the parotid gland, occasionally affects the submandibular glands and is quite rare in the minor glands [5]. Bilateral forms have been described [60]. This tumour is more common in women with a peak incidence in the fifth and sixth decades, but paediatric cases have also been described [22, 90, 271].

Local recurrence is observed in approximately 20% of surgically treated tumours. Ten percent of patients present regional lymph node metastases, and distant metastases are observed in 6% of cases.

8.2.2. Histopathology

Four histological subtypes can be distinguished [221]: (1) solid type (50%), containing large numbers of well-differentiated acinar cells and most closely resembling normal parotid gland parenchyma. Stromal lymphocytic infiltration is present in some cases. (2) Microcystic pattern (30%), showing numerous cystic spaces which are limited by acinar, intercalated duct-like and vacuolated cells. (3) Follicular pattern (15%), with a thyroid-like appearance. The cystic spaces contain eosinophilic material simulating a colloid appearance. (4) Papillary-cystic pattern (5%), exhibiting cystic architecture associated with papillary projections.

None of the four growth patterns nor the predominance of a particular cell type appears to be predictive of the prognosis, except for the papillocystic variant which has a poor clinical outcome [316]. The value of grading in acinic cell carcinoma is still controversial [22].

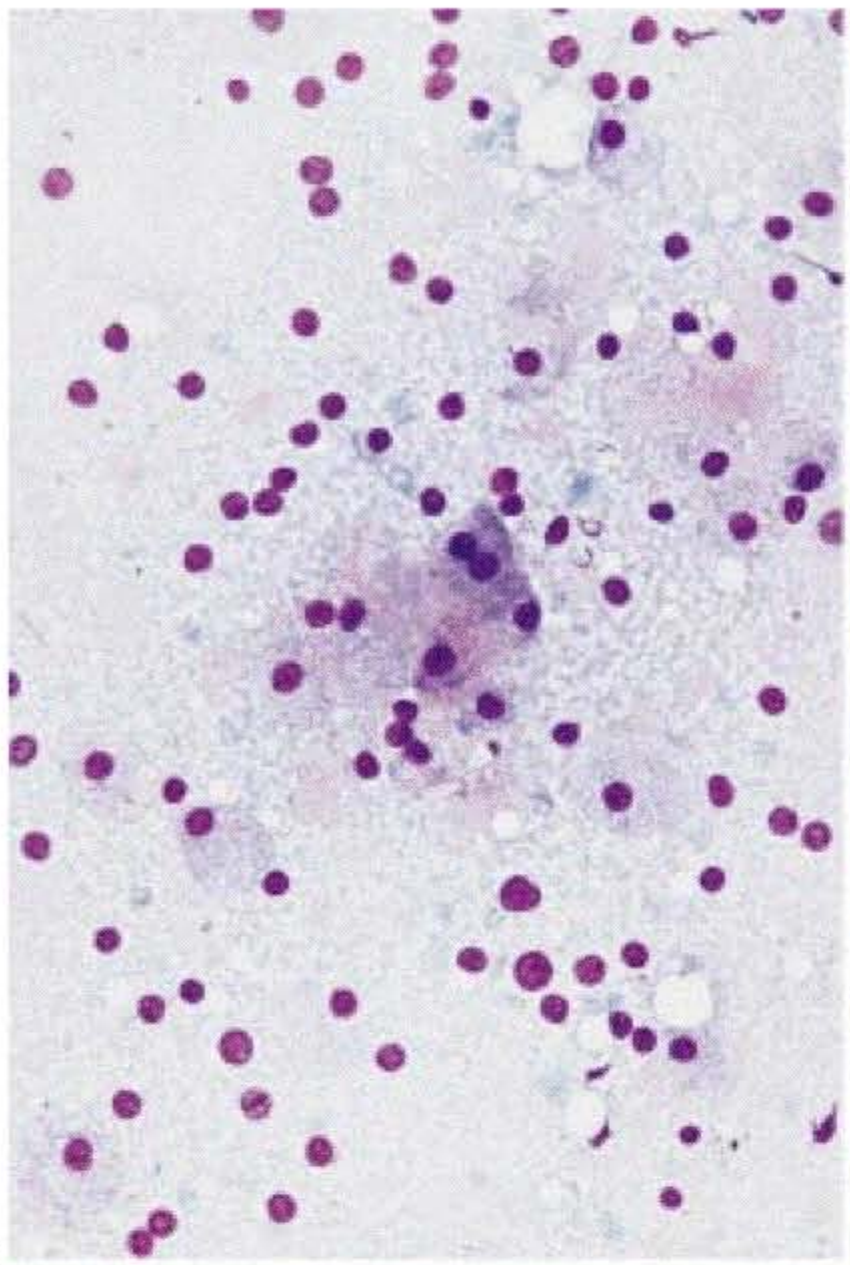

8.13

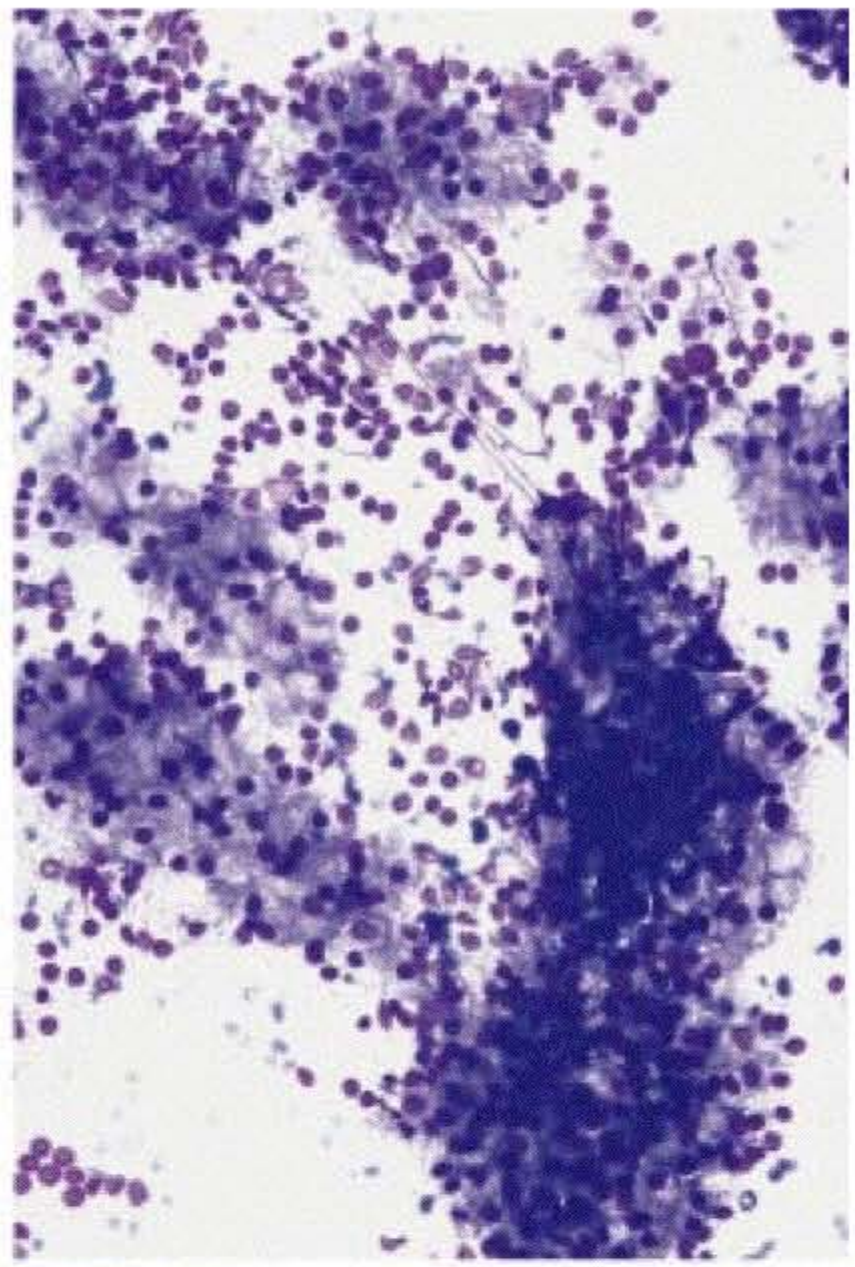

8.14

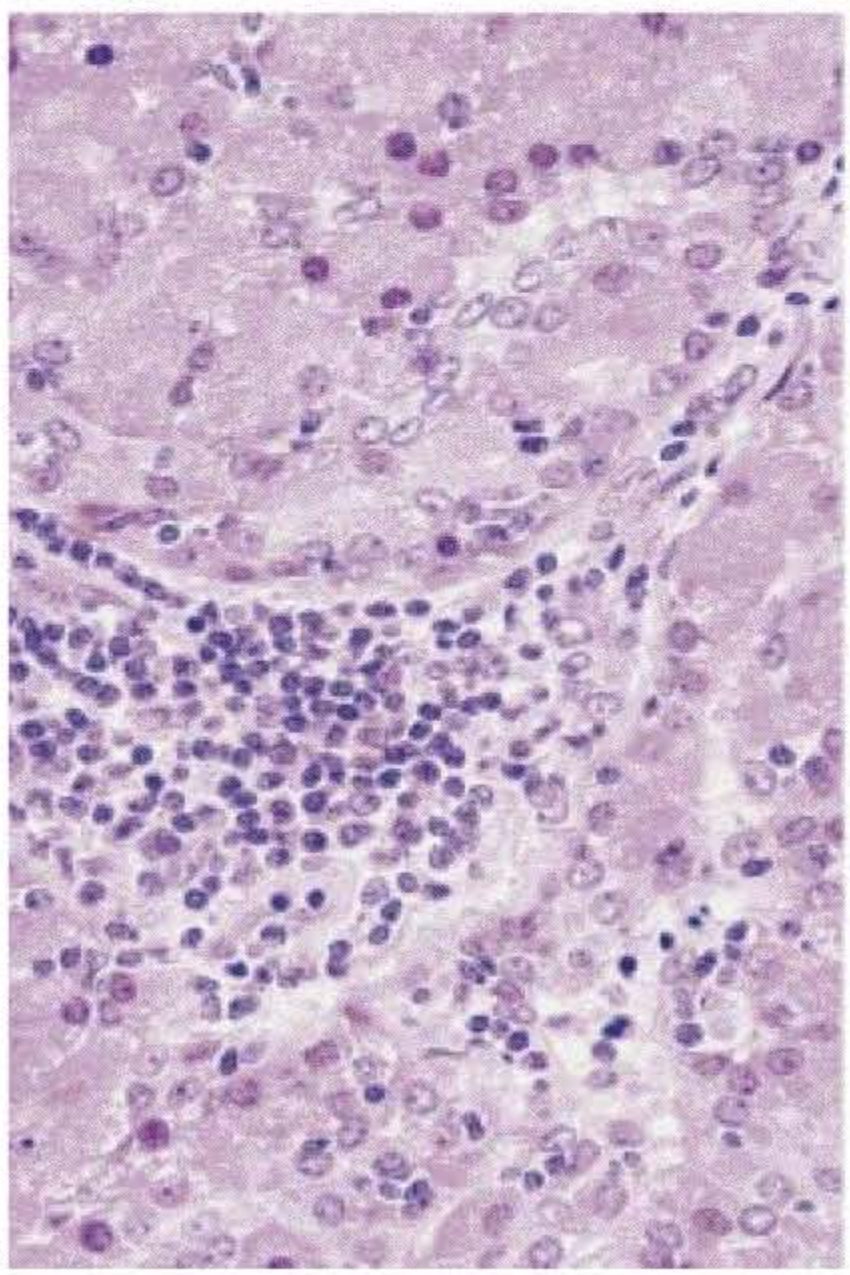

8.15

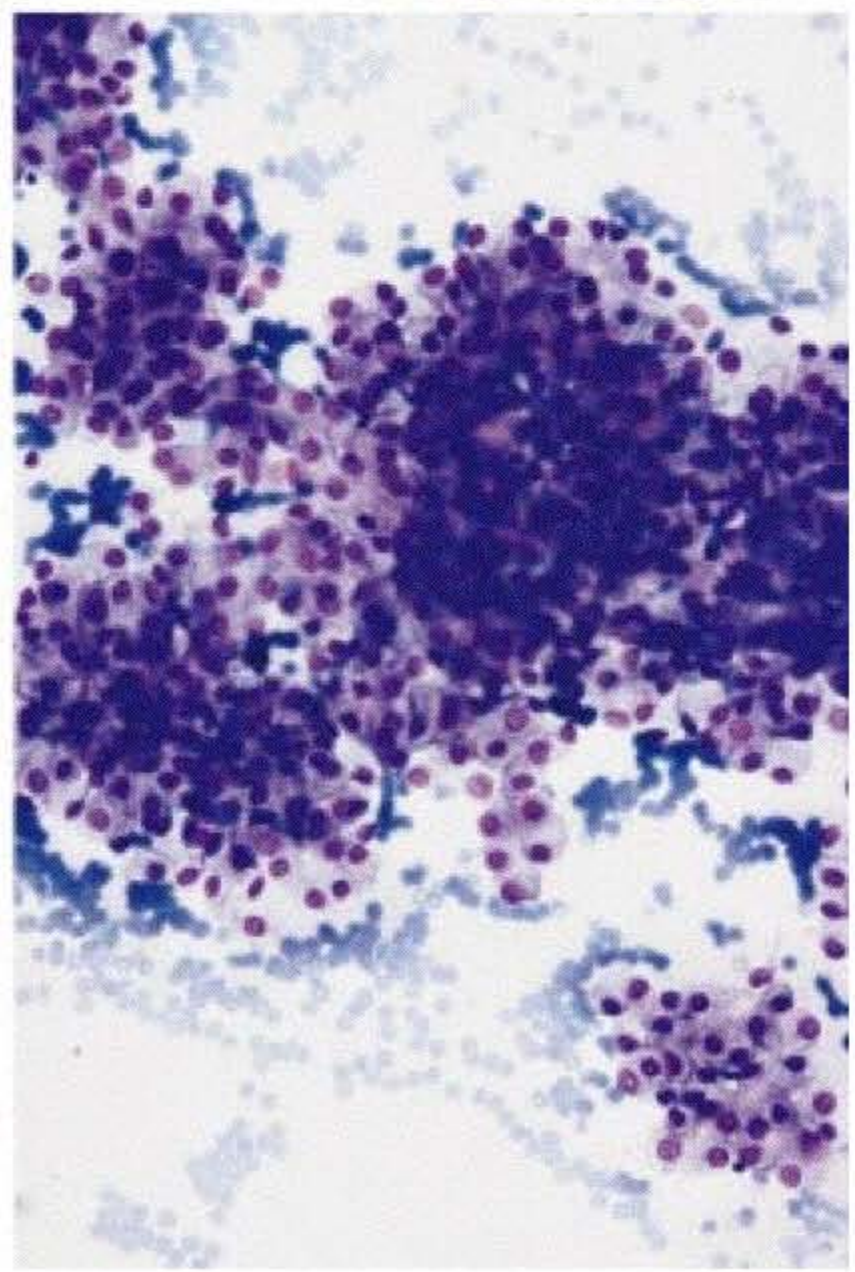

8.16

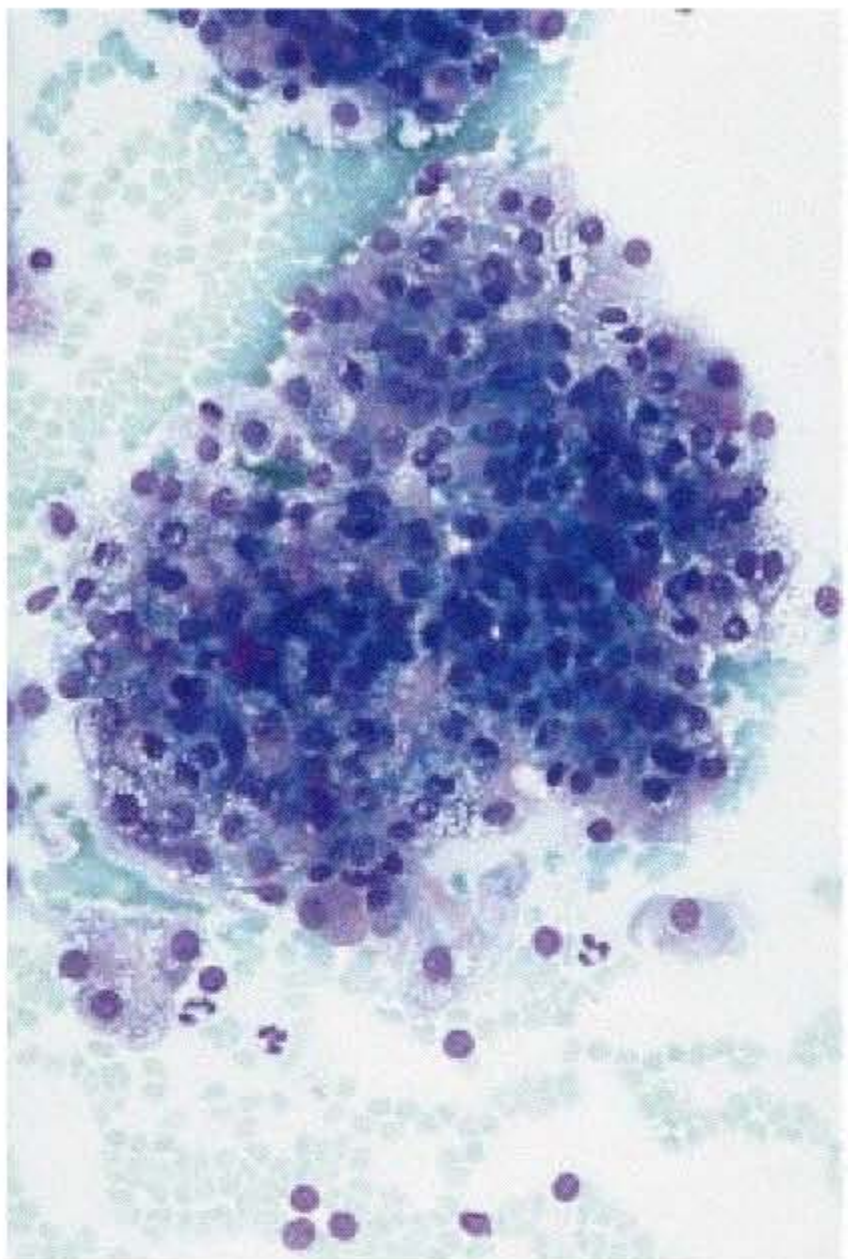

8.17

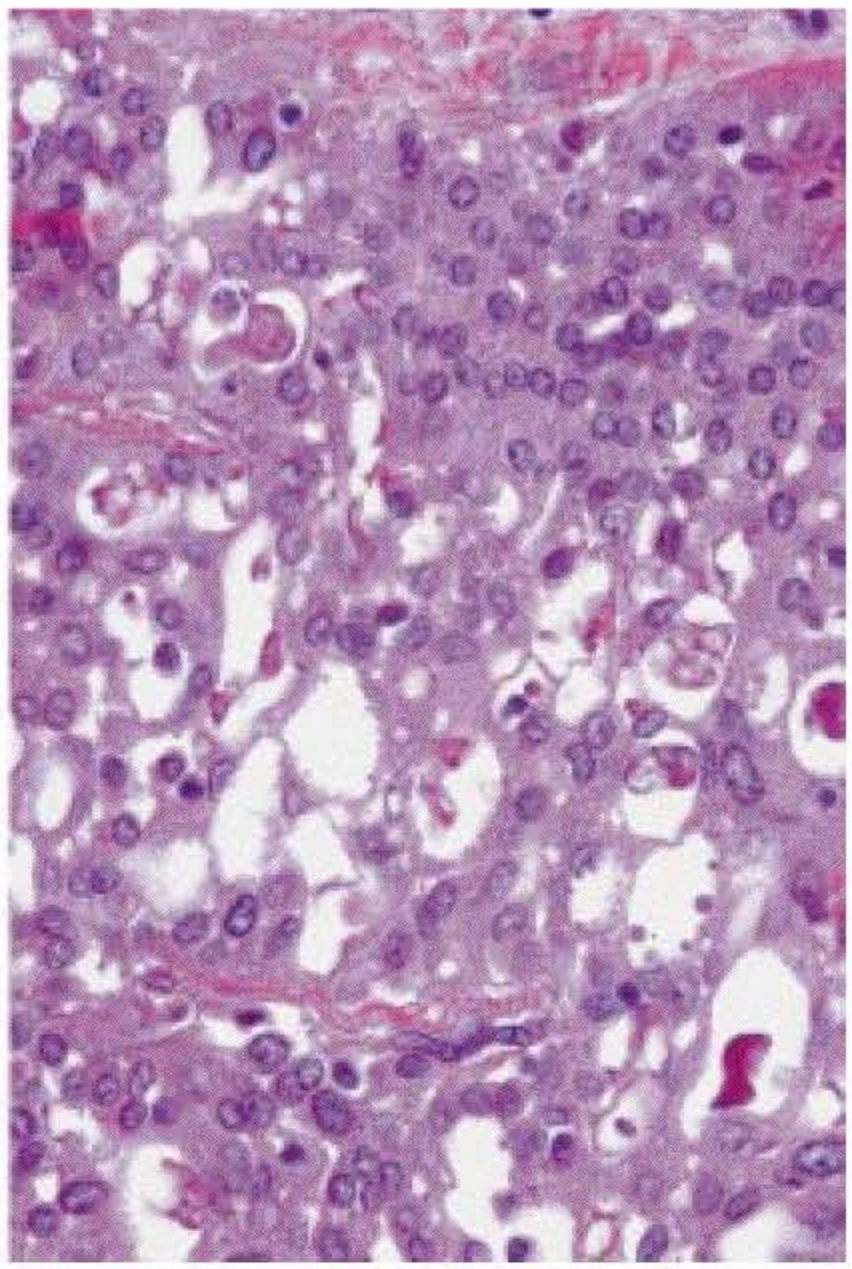

8.18

Fig. 8.17. Acinic cell carcinoma, moderately-differentiated. Oncocytic-like cells and round cells with poorly-vacuolated cytoplasm. MGG. ×128.
Fig. 8.18. Acinic cell carcinoma, moderately-differentiated. Histological section corresponding to figure 8.17. HES. ×128.

8.2.3. Cytopathology

Cytological diagnosis is based on cellular differentiation, i.e. well-, moderately- and poorly-differentiated acinic cell carcinomas. Smears are richly cellular and stroma-poor [193, 257]. Accurate diagnosis is based on recognition of acinar cells: acinar morphology of carcinomatous cells, and acinar architecture in clusters. Classical morphological parameters of malignancy such as necrosis, mitotic figures and nuclear atypia are rare or absent.

Fig. 8.13. Acinic cell carcinoma, well-differentiated. Naked nuclei are present in the background. MGG. ×128.
Fig. 8.14. Acinic cell carcinoma, well-differentiated with numerous lymphocytes. MGG. ×128.
Fig. 8.15. Acinic cell carcinoma, well-differentiated. Histological section corresponding to figure 8.14. HES. ×128.
Fig. 8.16. Acinic cell carcinoma, moderately-differentiated. Acinar cells (smaller than in the well-differentiated form) with round to oval, peripherally placed nuclei and vacuolated cytoplasm. MGG. ×128.

In well-differentiated tumours, smears contain characteristic, large acinar cells with a typical polyhedral shape, eccentric nuclei and abundant blue/grey (MGG) granular cytoplasm mimicking normal salivary acinar cells (fig. 8.12). The cells are frequently arranged in clusters with acinar and glandular structures adherent to blood vessels. Numerous naked nuclei are present in the background (fig. 8.13). Lymphocytes may be present (fig. 8.14, 8.15). Necrosis is rare or absent.

In moderately-differentiated tumours, acinar cells are smaller, round to oval, with polarized nuclei and rarefied (vacuolated) cytoplasm (fig. 8.16–8.18). Oncocytic-like cells, dark cuboidal cells, round cells with azurophilic (MGG) cytoplasmic granules and nonspecific glandular cells may be seen (fig. 8.17, 8.19). The nuclei appear uniform with smooth nuclear membranes (Papanicolaou stain). Coarse chromatin is observed in less differentiated forms and small to large nucleoli are usually present. Tumour cells

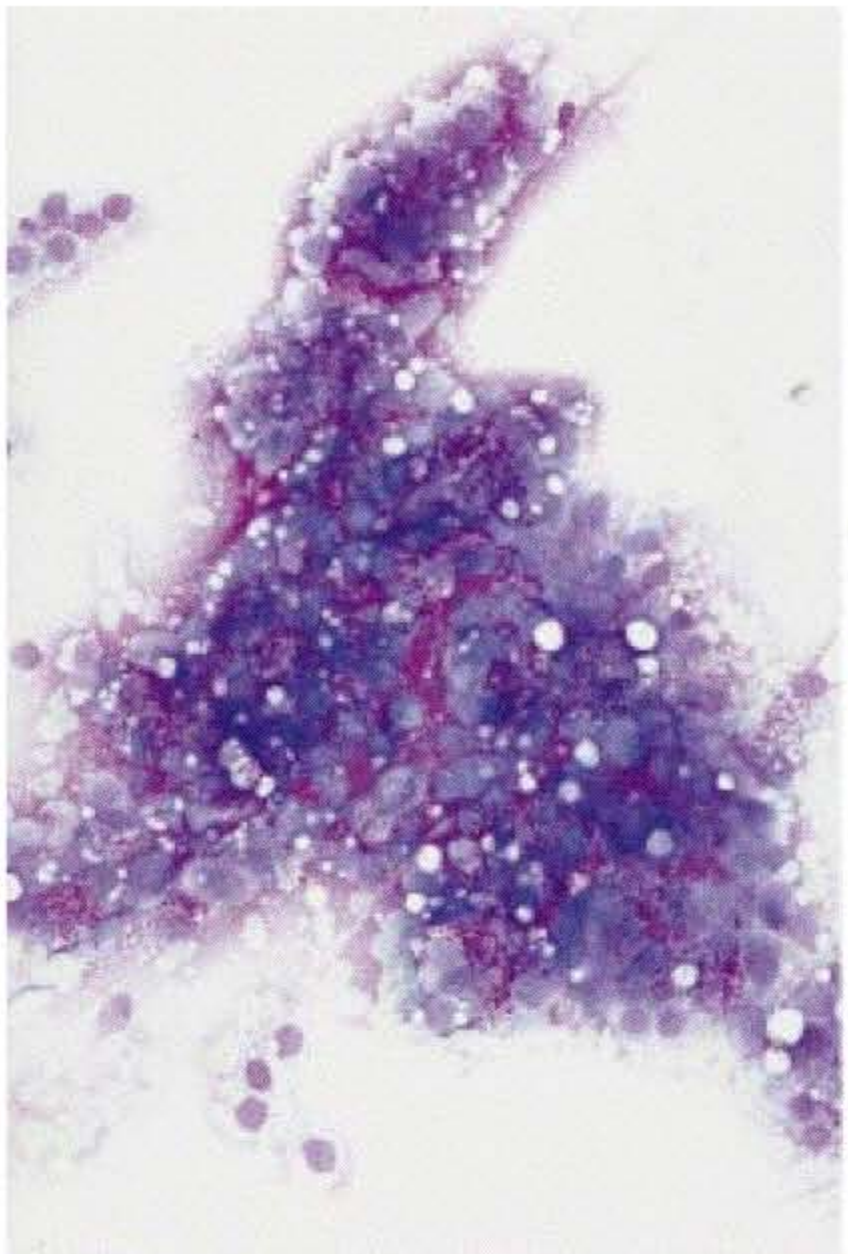

8.19

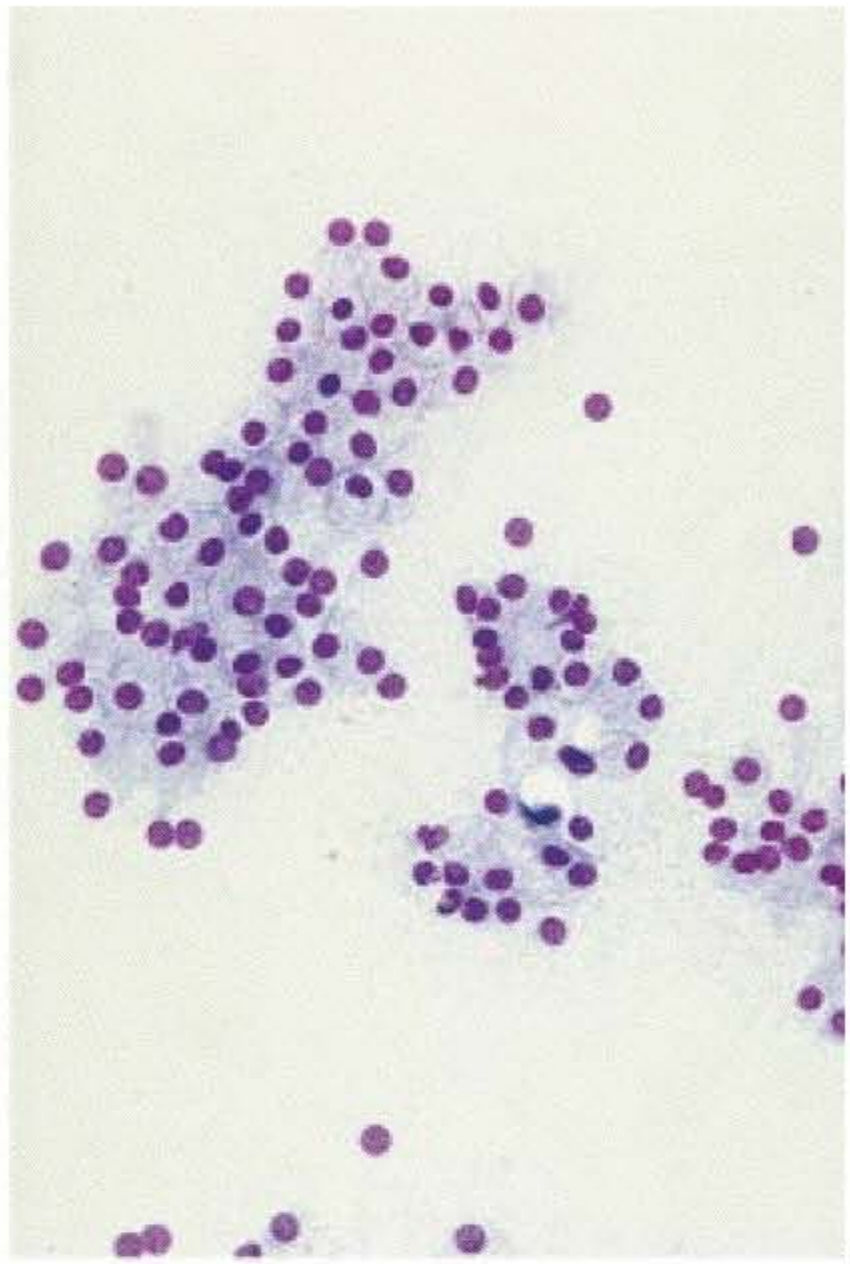

8.20

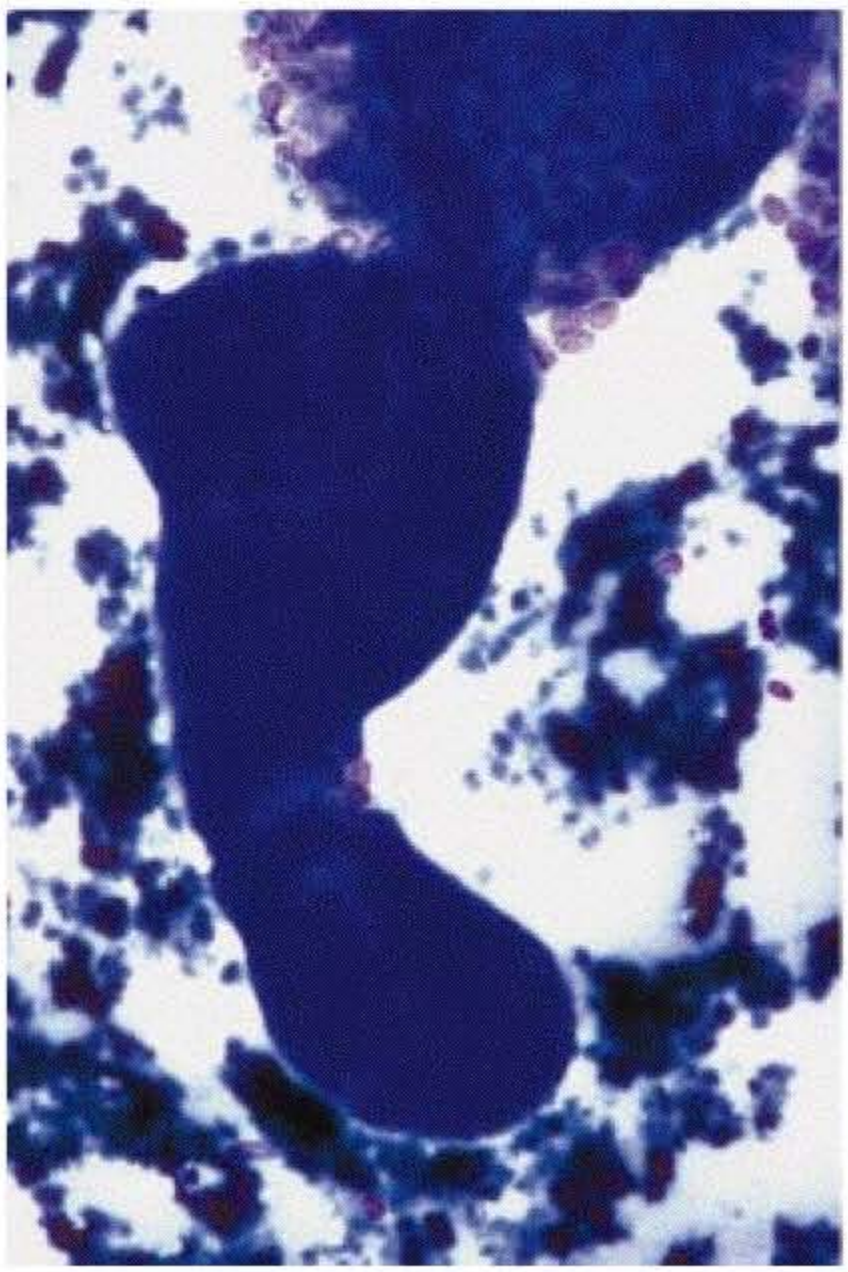

8.21

Fig. 8.19. Acinic cell carcinoma, moderately-differentiated. Azurophilic cytoplasmic granules and non-specific glandular cells. MGG. ×128.

Fig. 8.20. Acinic cell carcinoma, moderately-differentiated. Clustered cells with glandular pattern. MGG. ×128.

Fig. 8.21. Acinic cell carcinoma, moderately-differentiated. Papillary and three-dimensional pattern. MGG. ×128.

Table 8.2. Diagnostic accuracy of acinic cell carcinoma

Author [ref.]	Number	Malignant	Suspicious	False-negative	Unsatisfactory
Eneroth et al. [97]	34	22	0	12	0
Persson, Zettergren [270]	6	6	0	0	0
Woyke et al. [346]	1	1	0	0	0
Lindberg, Åkerman [222]	7	4	0	3	0
Palma et al. [267]	2	2	0	0	0
Bottles, Löwhagen [34]	1	1	0	0	0
Whitlatch [342]	1	1	0	0	0
O'Dwyer et al. [261]	5	4	0	1	0
Qizilbash, Young [279]	7	6	0	1	0
Layfield et al. [219]	3	3	0	0	0
Kocjan et al. [204]	2	2	0	0	0
Smith Frable, Frable [313]	2	2	0	0	0
Weinberger et al. [341]	2	0	0	2	0
Abad et al. [1]	3	3	0	0	0
Chan et al. [48]	2	2	0	0	0
Zurrida et al. [358]	5	2	0	3	0
Orell [263]	10	9	0	1	0
Nagel et al. [257]	40	29	4	4	3
Klijanienko, Vielh [193]	22	18	2	1	1
Al-Khafaji et al. [8]	5	3	0	2	0
Total	158	118 (74.7)	6 (3.8)	30 (19)	4 (2.5)

Statistics from the literature. % in parentheses.

are isolated or clustered with glandular or papillary structures (fig. 8.20, 8.21). Some tumours may contain intracytoplasmic crystalloids. Numerous naked nuclei are present in the background. Necrosis and stroma are scant or absent.

Carcinomatous cells with slightly vacuolated cytoplasm and nuclear atypia are seen in poorly-differentiated tumours. Occasional naked nuclei and scant stroma may be observed and necrosis may be present. Psammoma bodies have been occasionally reported [34, 342, 257].

8.2.4. Diagnostic Accuracy

About 170 cases have been described to date. Table 8.2 shows the results obtained in several series: 78.5% of acinic cell carcinomas were classified as malignant or suspicious, and the large percentage (19%) of tumours underdiagnosed as benign were mainly mistaken for pleomorphic adenoma or Warthin's tumour.

8.2.5. Differential Diagnosis

Acinic cell carcinoma must be differentiated from epithelial-myoepithelial carcinoma, mucoepidermoid carcinoma with oncocytic-like cells, oncocytoma, cellular pleomorphic adenoma, Warthin's tumour and metastatic renal cell carcinoma (table 8.3). It has also been suggested that sialadenosis may mimic acinic cell carcinoma.

8.2.5.1. Acinic Cell Carcinoma vs. Epithelial-Myoepithelial Carcinoma

Epithelial-myoepithelial carcinoma represents the main differential diagnosis, especially when acinic cell carcinoma is composed of clear (vacuolated) cells. Cytological features of epithelial-myoepithelial carcinoma include three-dimensional cellular aggregates with clear cytoplasm at the periphery and presence of acellular hyaline material (fig. 7.30, 7.31). In contrast with epithelial-myoepithelial carcinoma, stromal connective tissue fragments are scant or absent in acinic cell carcinoma. The associated presence of numerous naked nuclei or lymphocytes is highly suggestive of acinic cell carcinoma.

8.2.5.2. Acinic Cell Carcinoma vs. Mucoepidermoid Carcinoma with Oncocytic-Like or Vacuolated Cells

The difficulty encountered in differentiating the oncocytic-like or vacuolated-cell variant of mucoepidermoid

Table 8.3. Differential diagnosis of acinic cell carcinoma

Component	Acinic cel carcinoma	Epithelial-myo-epithelial carcinoma	Mucoepidermoid carcinoma, high-grade	Cellular pleomorphic adenoma	Warthin's tumour	Oncocytoma
Cells						
Acinar	++	–	–	–	–	–
Vacuolated/clear	++	+	+/–	–	+/–	+/–
Oncocytes (-like)	+/–	?	+/–	+/–	++	++
Plasmacytoid	–	+/–	–	++	–	–
Squamous	–	–	++	+/–	+/–	–
Naked nuclei	++	+/–	+/–	–	–	+/–
Stroma						
Chondro myxoid	–	–	–	+	–	–
Globules	–	+	–	+/–	–	–
Mucoid	–	–	++	+/–	+/–	–
Lymphocytic	+	+	+	–	++	–

++ = Common; + = rare; +/– = occasionally seen; – = absent.

carcinoma (fig. 7.11) from acinic cell carcinoma can be resolved by the absence of mucus-secreting cells, intermediate/squamous cells, or extracellular mucus.

8.2.5.3. Acinic Cell Carcinoma vs. Cellular Pleomorphic Adenoma

Acinic cell carcinoma should also be differentiated from the cellular variant of pleomorphic adenoma, in which the presence of even scant to rich stromal chondromyxoid material is very helpful. Plasmacytoid myoepithelial cells are also absent in acinic cell carcinoma.

8.2.5.4. Acinic Cell Carcinoma vs. Warthin's Tumour and Oncocytoma

The differential diagnosis also includes oncocytic cell tumours such as Warthin's tumour when lymphocytes are numerous, and oncocytoma (fig. 6.22, 6.32). Both entities can be excluded by the presence of clarified (vacuolated) cells arranged in acini and numerous naked nuclei, usually seen in acinic cell carcinoma (fig. 8.13, 8.17).

8.2.5.5. Acinic Cell Carcinoma vs. Metastatic Renal Cell Carcinoma

The clinical presentation may be helpful in the differential diagnosis between these two entities.

8.2.5.6. Acinic Cell Carcinoma vs. Sialadenosis

Well-differentiated acinic cell carcinoma may be distinguished from sialadenosis (fig. 12.1) by the abundance of acinic cells, the absence of adipocytes and ductal cells, and the presence of numerous naked nuclei and connective strands.

Acinic Cell Carcinoma

In favour of the diagnosis

Clustered or isolated large acinar cells, acinar architecture of clusters, azurophilic cytoplasmic granulations, vascular cores, naked nuclei, 'monotonous smears'

Difficulties

Lymphocytic stroma, poorly-differentiated cells, oncocytic-like cells, crystalloids

Against the diagnosis

Extensive necrosis, plasmacytoid cells, true oncocytes, squamous cells, chondromyxoid stroma

8.3. Polymorphous Low-Grade Adenocarcinoma

8.3.1. General

Polymorphous low-grade adenocarcinoma occurs almost exclusively in minor salivary glands, especially in the hard palate, oral mucosa, upper lip, retromolar region, floor of mouth and tongue [89]. The age of onset ranges from the third to ninth decades with a median age of 60 years. Local recurrence and local lymph node involvement may be observed [4, 106].

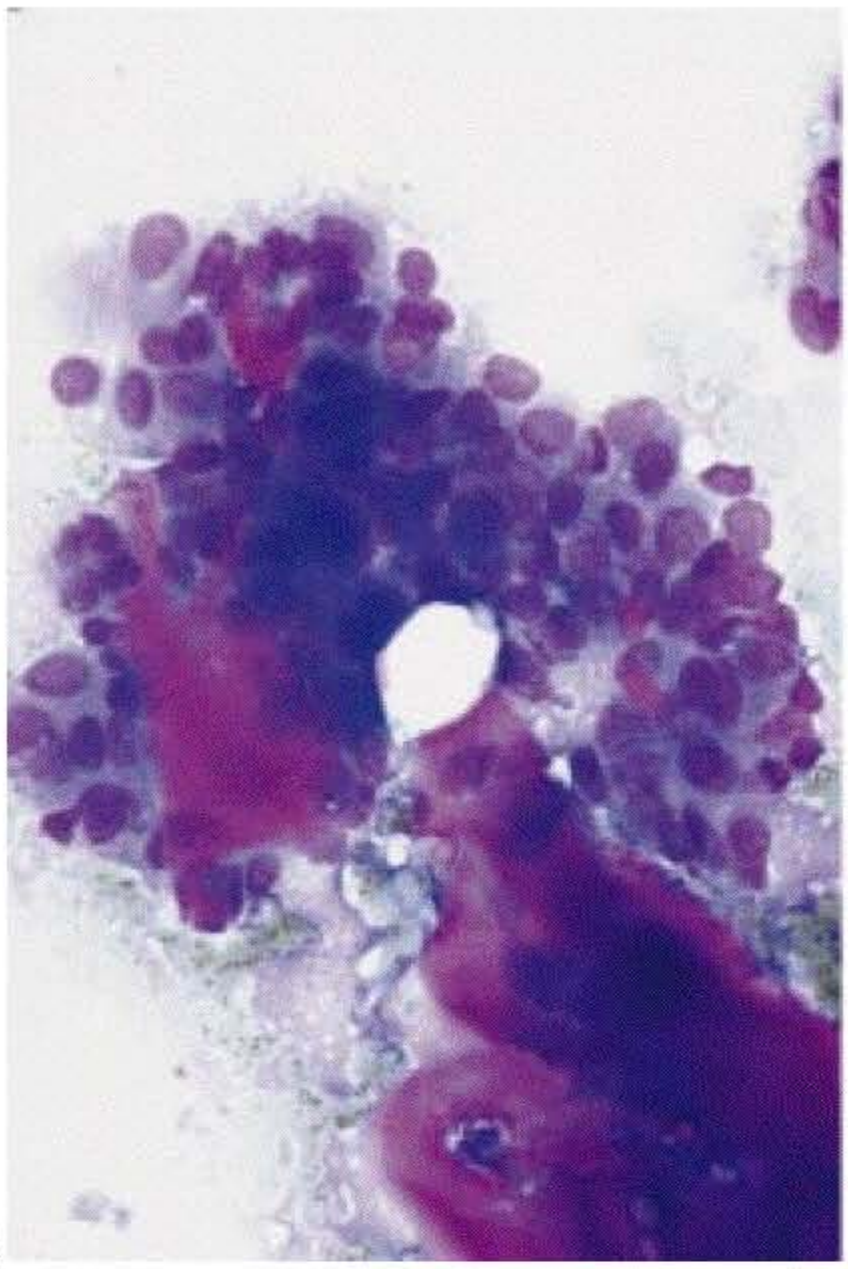

8.22

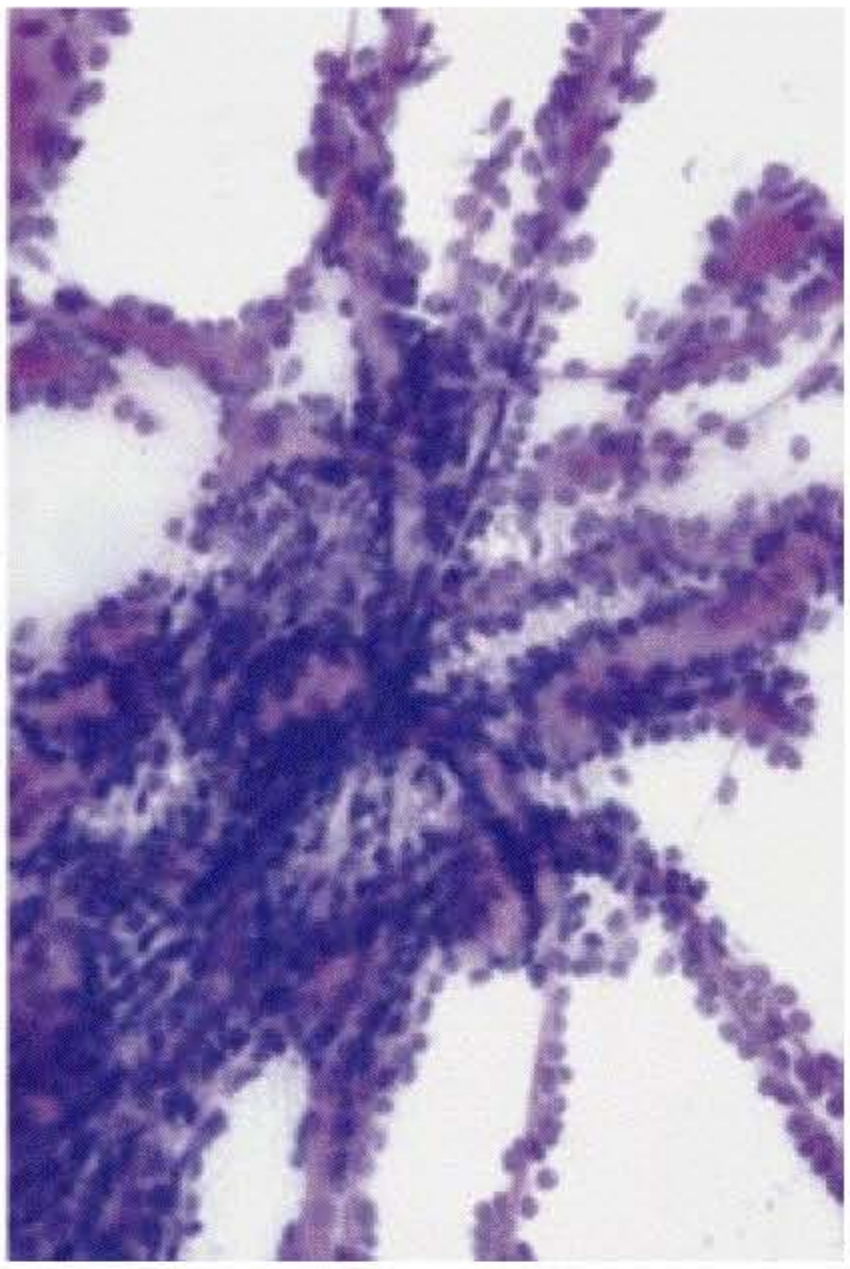

8.23

Fig. 8.22. Polymorphous low-grade adenocarcinoma. Clustered epithelial cells with a polyhedral or oval shape. Note the abundant connective tissue core. MGG. ×128.
Fig. 8.23. Polymorphous low-grade adenocarcinoma. Pseudopapillary formations with a dendritic stromal core. MGG. ×64.

8.3.2. Histopathology

Polymorphous low-grade adenocarcinoma is grossly well circumscribed, but microscopically infiltrating [89]. Adjacent bone destruction is frequent. The polymorphous nature of the tumour refers to the variety of cellular and architectural features. The growth patterns include solid islands, tubules, trabeculae, cribriform nests, cysts, pseudoadenoid cystic patterns and papillary configurations. Perineural and perivascular invasion is often present [133]. Mitotic figures and necrosis are rare. Tumour cells are small to medium-sized with no cytonuclear atypia. Areas of clear cells, oncocytic or mucin-filled cells are occasionally observed [106]. Nuclei are ovoid to spindle-shaped with small nucleoli.

8.3.3. Cytopathology

Smears from polymorphous low-grade adenocarcinoma contain both cellular and stromal components [125, 200]:

The cellular material is composed of polyhedral or oval epithelial cells, isolated and in clusters (fig. 8.22, 8.23). No cytoplasmic vacuoles or clear cells are noted. The cytoplasm is stripped in most tumour cells. Slight nuclear pleomorphism is also observed, but mitotic figures are absent. Chromatin is delicate and nucleoli are small or inconspicuous. Intranuclear inclusions may be seen. Cells are frequently grouped in pseudopapillary formations with a dendritic stromal core.

Stromal material consists of purple-magenta fragments on MGG stain. Hyaline globules, similar to those seen in adenoid cystic carcinoma, are frequently detected (fig. 8.24, 8.25). Crystalloids have been reported [61].

8.3.4. Diagnostic Accuracy

Only a few examples of polymorphous low-grade adenocarcinoma are reported. Table 8.4 shows that 83.3% of tumours were cytologically diagnosed as malignant.

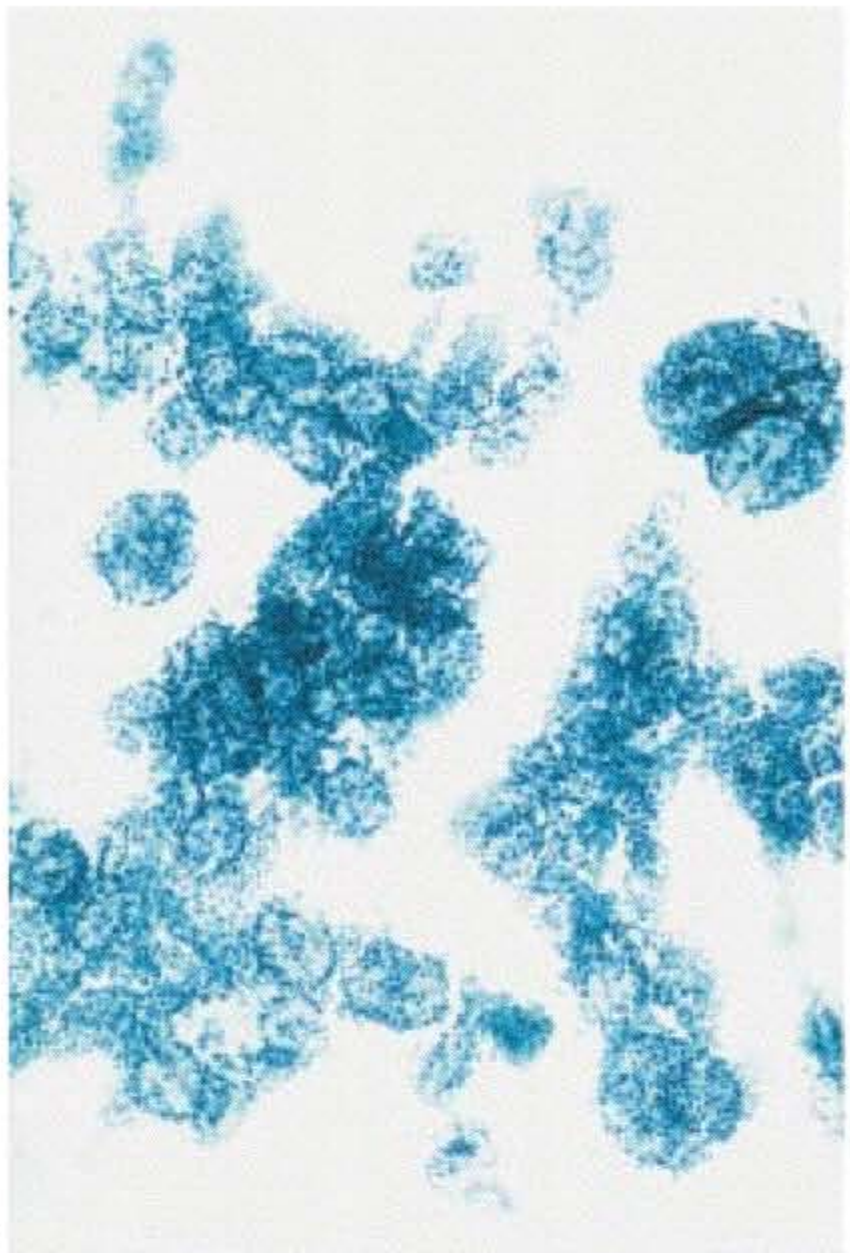

8.24

8.25

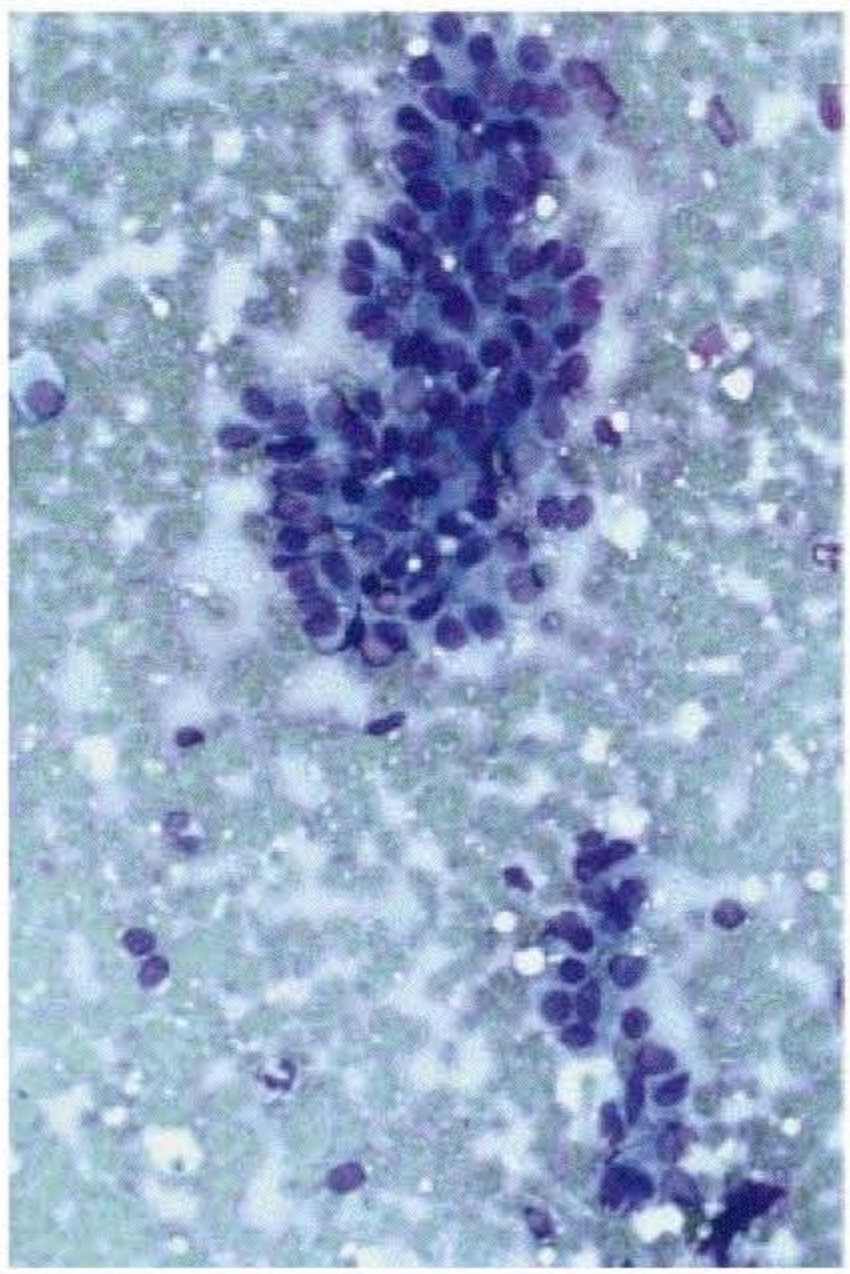

8.26

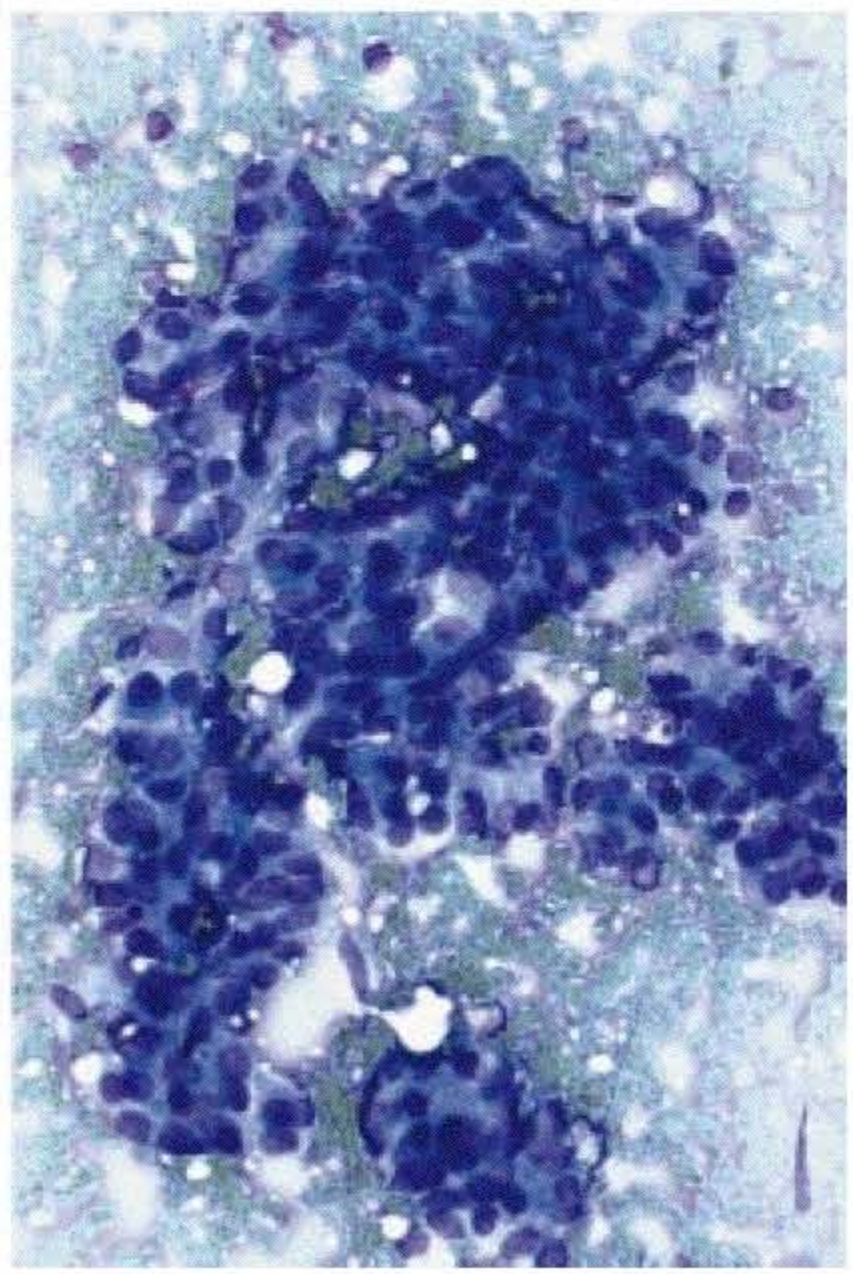

8.27

Table 8.4. Correlation between cytology and histology of polymorphous low-grade carcinomas

Author [ref.]	Number	Malignant	Suspicious	False-negative	Unsatisfactory
Frierson et al. [116]	1	1	0	0	0
Cleveland et al [61]	1	1	0	0	0
Orell [263]	1	1	0	0	0
Klijanienko, Vielh [200]	12	10	0	2	0
Al-Khafaji et al. [8]	2	2	0	0	0
Watanabe et al. [338]	1	0	0	1	0
Mincione et al. [247]	1	1	0	0	0
Gibbons et al. [125]	5	4	0	1	0
Total	24	20 (83.3)	0	4 (16.7)	0

Statistics from the literature. % in parentheses.

Table 8.5. Quantitative cytological differential diagnosis of polymorphous low-grade adenocarcinoma and papillary cystadenocarcinoma

Component	Polymorphous low-grade adenocarcinoma	Papillary cystadeno-carcinoma	Adenoid cystic carcinoma	Epithelial-myoepithelial carcinoma	Cellular pleomorphic adenoma
Cells					
Pseudopapillary	++	+/–	–	+/–	+/–
Plasmacytoid	–	–	–	+/–	++
Clear/vacuolated	–	–	–	+	+/–
Squamous	–	–	+/–	–	+/–
Atypia	+/–	–	+/–	+/–	+
Stroma					
Chondromyxoid	–	–	–	–	+
Hyaline globules	++	–	++	+/–	++
Connective fragments	+	+	+	+/–	+/–
Crystalloids	+/–	–	–	–	+/–

++ = Common; + = rare; +/– = occasionally; – = absent.

8.3.5. Differential Diagnosis

Polymorphous low-grade adenocarcinoma must be distinguished from papillary cystadenocarcinoma, adenoid cystic carcinoma, epithelial-myoepithelial carcinoma and cellular type of pleomorphic adenoma (table 8.5).

Fig. 8.24. Polymorphous low-grade adenocarcinoma. Hyaline globules similar to those seen in adenoid cystic carcinoma. Papanicolaou. ×64.

Fig. 8.25. Polymorphous low-grade adenocarcinoma. Three-dimensional clusters with hyaline cores. MGG. ×128.

Fig. 8.26. Papillary cystadenocarcinoma. Clusters of ovoid cells with stippled nuclear chromatin. MGG. ×128.

Fig. 8.27. Papillary cystadenocarcinoma. Slight pseudopapillary configuration. MGG. ×128.

8.3.5.1. Polymorphous Low-Grade Adenocarcinoma vs. Papillary Cystadenocarcinoma

Papillary cystadenocarcinoma is composed of clusters of uniform cells with rare (pseudo)papillae without mucin (fig. 8.26, 8.27). The cells of polymorphous low-grade adenocarcinoma are similar, but (pseudo)papillae seems to be more frequent. Hyaline globules are not found in papillary cystadenocarcinoma.

8.3.5.2. Polymorphous Low-Grade Adenocarcinoma vs. Adenoid Cystic Carcinoma

The difficulties in distinguishing polymorphous low-grade adenocarcinoma from adenoid cystic carcinoma are due to the occasional presence of hyaline deposits, with an

intense magenta colour on MGG stain (fig. 7.21, 8.24, 8.25). In polymorphous low-grade adenocarcinoma, the nuclei are larger, rounder, and more uniform than the angular hyperchromatic nuclei resembling basal cells observed in adenoid cystic carcinoma (fig. 7.29). Moreover, necrosis, which may be present in the solid variant of adenoid cystic carcinoma, is rarely seen in polymorphous low-grade adenocarcinoma, and the presence of pseudopapillary formations (fig. 8.23) is exceptional in adenoid cystic carcinoma.

8.3.5.3. Polymorphous Low-Grade Adenocarcinoma vs. Epithelial-Myoepithelial Carcinoma

The differential diagnosis between polymorphous low-grade adenocarcinoma and epithelial-myoepithelial carcinoma is extremely difficult, but the latter may show a bimodal cell population: ductal cells with dark cytoplasm and myoepithelial cells with clear cytoplasm. This is especially evident on Papanicolaou stain, and less visible on MGG stain. The differential diagnosis may be impossible when the epithelial-myoepithelial carcinoma is monomorphous and mainly composed of myoepithelial cells (clear cell carcinoma). Epithelial-myoepithelial carcinoma exhibits isolated and clusters of oval cells (fig. 7.30). Cells are frequently arranged in pseudopapillary formations with stromal cores and rarely with hyaline globules. The cytoplasm is either large and slightly pale blue (MGG stain) or scant, resembling basal cells. The cells in polymorphous low-grade adenocarcinoma rarely have a vacuolated cytoplasm.

8.3.5.4. Polymorphous Low-Grade Adenocarcinoma vs. Cellular Pleomorphic Adenoma

Eosinophilic stromal fragments may be observed in the background, possibly leading to an incorrect diagnosis of pleomorphic adenoma. In contrast with polymorphous low-grade adenocarcinoma, epithelial cells are rarely arranged in tubular structures around hyaline deposits in pleomorphic adenoma (fig. 6.6, 8.24). Moreover, plasmacytoid cells with abundant cytoplasm are characteristic of pleomorphic adenomas (fig. 6.3).

Polymorphous Low-Grade Adenocarcinoma

In favour of the diagnosis

Polyhedral or oval cells in pseudopapillary clusters, nuclei with delicate chromatin, hyaline globules, location to minor salivary glands

Difficulties

Marked nuclear pleomorphism, numerous hyaline globules

Against the diagnosis

Finger-like and tubular structures, basaloid cells, chondromyxoid stroma

8.4. Papillary Cystadenocarcinoma

This entity was more recently [300] distinguished from salivary gland tumours exhibiting similar cystic and papillary patterns: mucoepidermoid carcinoma, acinic cell adenocarcinoma, polymorphous low-grade adenocarcinoma and carcinoma ex pleomorphic adenoma.

8.4.1. General

The incidence of papillary cystadenocarcinoma is difficult to define. The AFIP recently reviewed [114] their series of 57 cases in patients between the ages of 20 and 86 years with no sex predominance. Tumours mainly occurred in the major salivary glands. Papillary cystadenocarcinoma has a similar behaviour to 'low-grade papillary adenocarcinoma of palatal salivary gland origin' [246].

8.4.2. Histopathology

Papillary cystadenocarcinoma is composed of multilocular cysts lined by a single layer of epithelium, cribriform clusters and papillae, as well as solid areas [89]. Some tumours show true papillary structures composed of mucus-secreting cells and poorly differentiated cells with numerous mitotic figures.

8.4.3. Cytopathology

Smears from papillary cystadenocarcinoma are richly cellular and composed of clusters of ovoid cells with stippled nuclear chromatin [200] and rare clusters with a slight pseudopapillary configuration (fig. 8.26–8.28). The case described by Pisharodi [275] consisted of papillae composed of monotonous cells with occasional fibrovascular cores. The cytoplasm is large and pale blue (MGG). Numerous naked nuclei and strongly eosinophilic stromal fragments are frequently found in the background. Hyaline globules or mucin are not found.

8.4.4. Diagnostic Accuracy

Six examples of papillary cystadenocarcinoma have been published (table 8.6).

8.4.5. Differential Diagnosis

Papillary cystadenocarcinoma must be distinguished cytologically from polymorphous low-grade adenocarcinoma

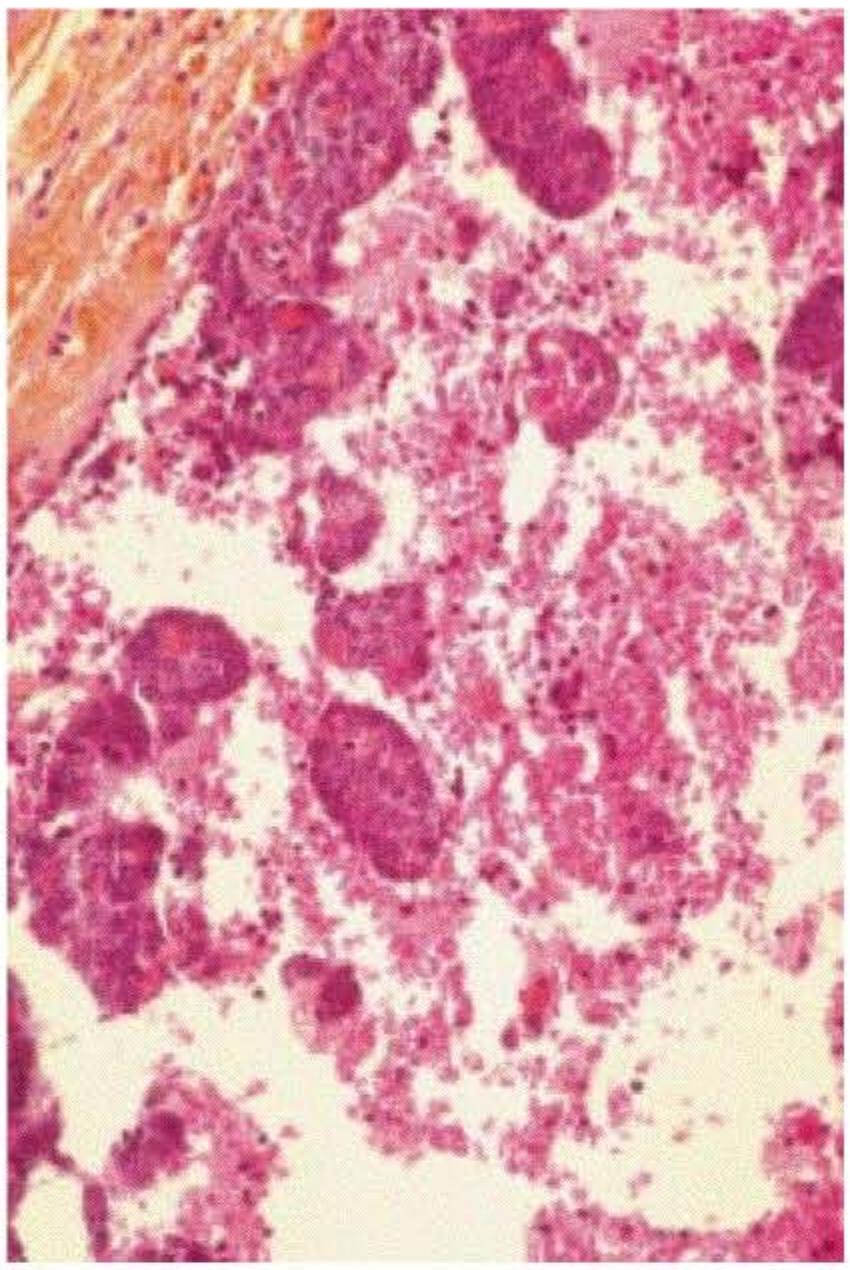

Fig. 8.28. Papillary cystadenocarcinoma. Histological section corresponding to Fig. 8.27. HES. ×64.

Table 8.6. Correlation between cytology and histology of papillary cystadenocarcinoma

Author [ref.]	Number	Malignant	Suspicious	False-negative	Unsatisfactory
Pisharodi [275]	1	1	0	0	0
Klijanienko, Vielh [200]	5	4	0	1	0
Total	6	5	0	1	0

Statistics from the literature.

(fig. 8.22), cystadenoma (fig. 6.47) and other papillary tumours metastatic to the salivary gland, especially thyroid tumours.

8.5. Basal Cell Adenocarcinoma

8.5.1. General

Basal cell adenocarcinoma is considered to be the malignant counterpart of basal cell adenoma [90] and has an incidence of about 1%. Basal cell adenocarcinoma predominantly occurs in the parotid gland and may be associated with dermal cylindroma. The recurrence rate is about 25%. A small percentage of basal cell adenocarcinomas (10%) metastasize to regional lymph nodes or distant organs, but they constitute low-grade malignancies with a relatively good prognosis.

8.5.2. Histopathology

Basal cell adenocarcinoma can be divided into four subtypes: solid, trabecular, tubular and membranous [89]. The tumour is characterized by cells arranged in islands of vari-

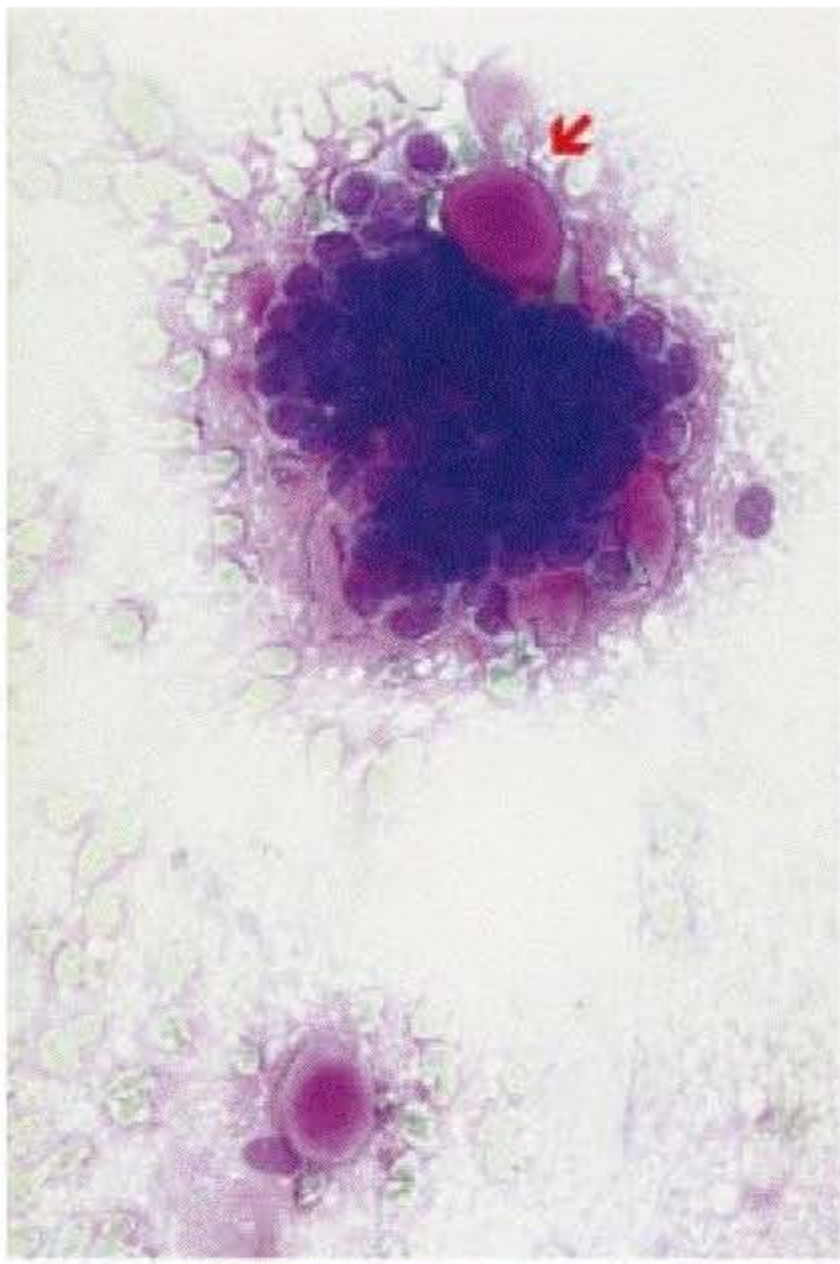

8.29

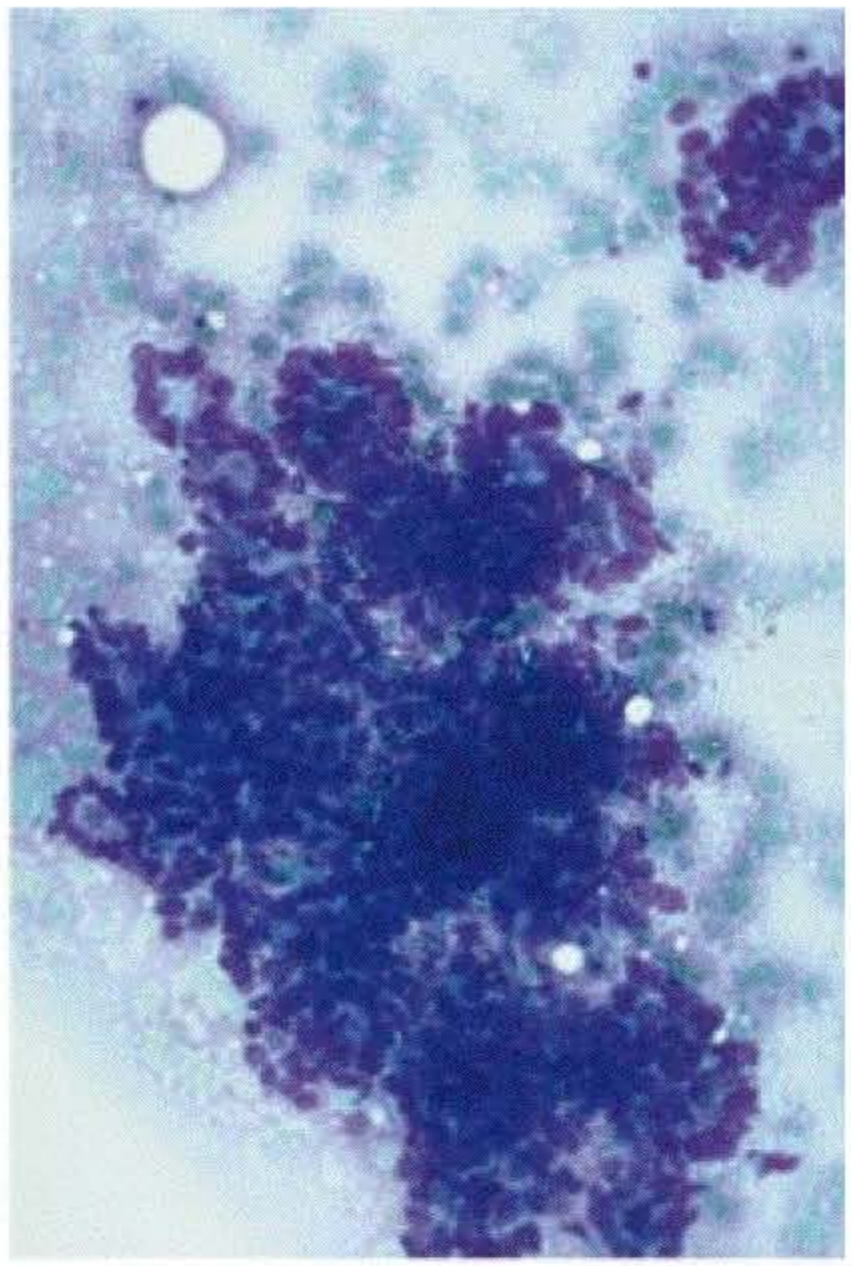

8.30

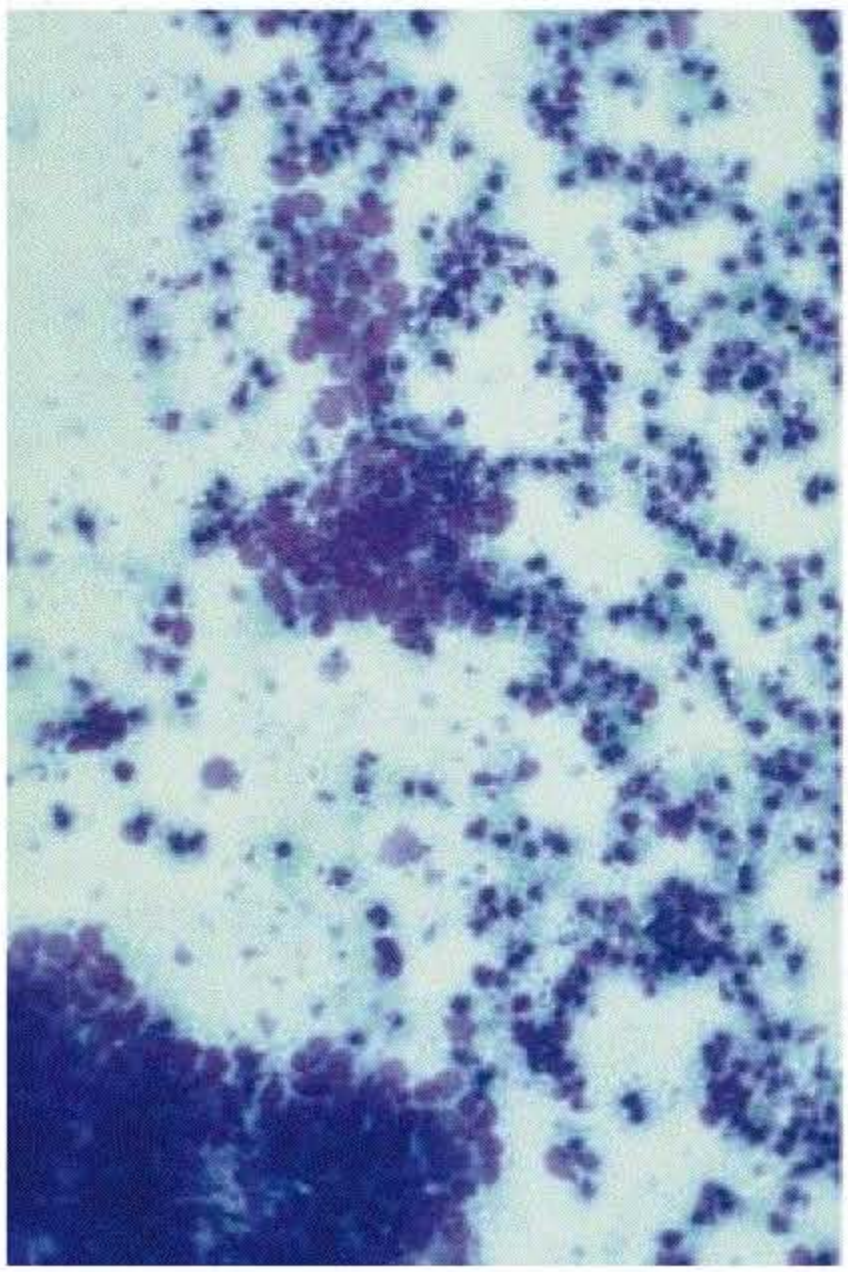

8.31

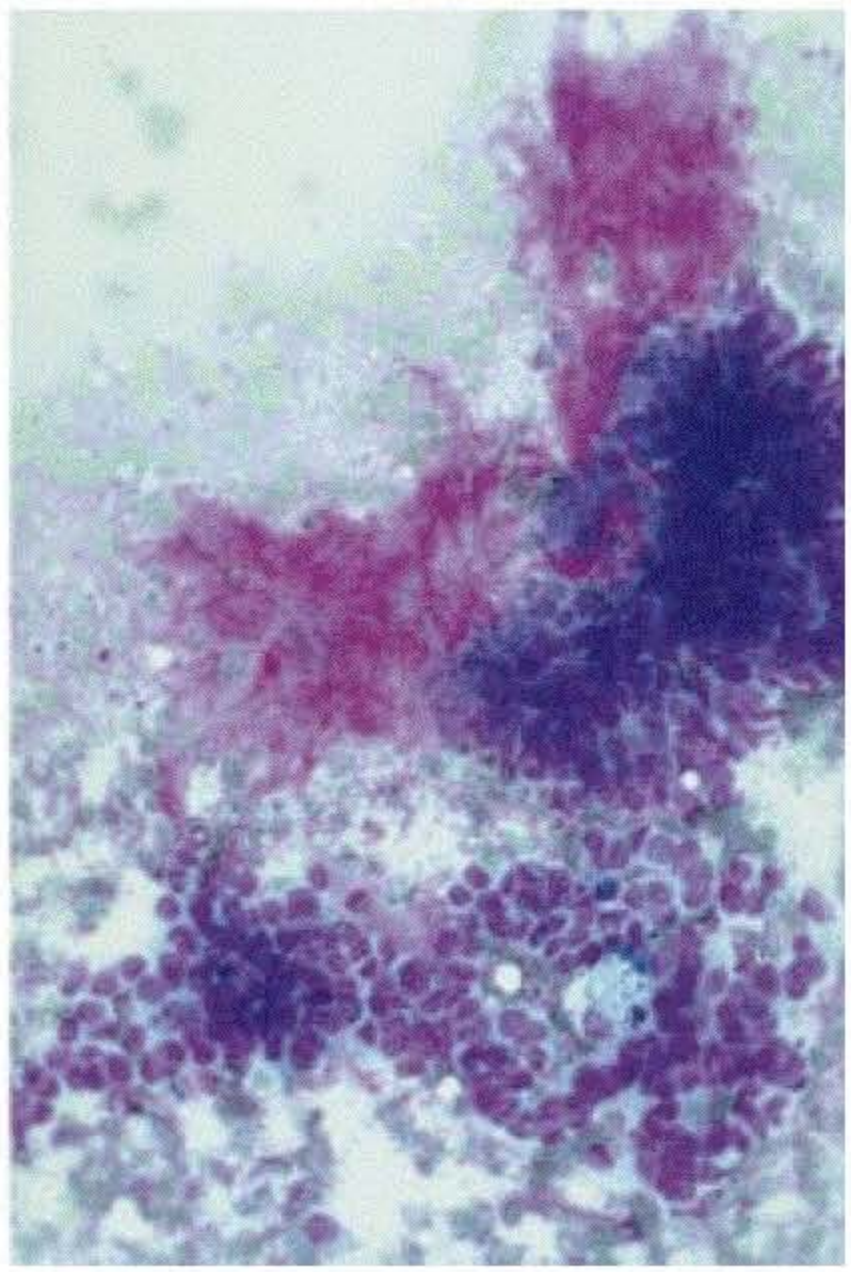

8.32

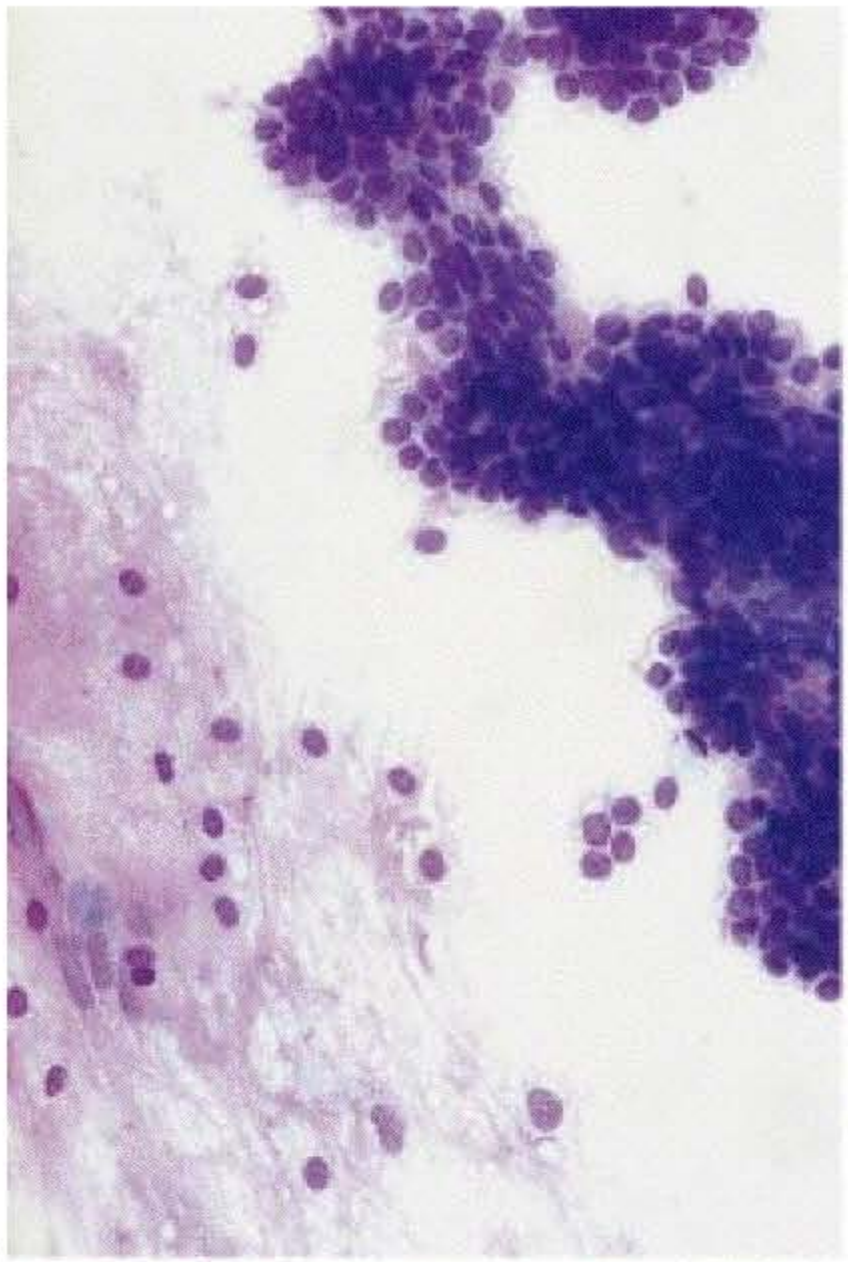

8.33

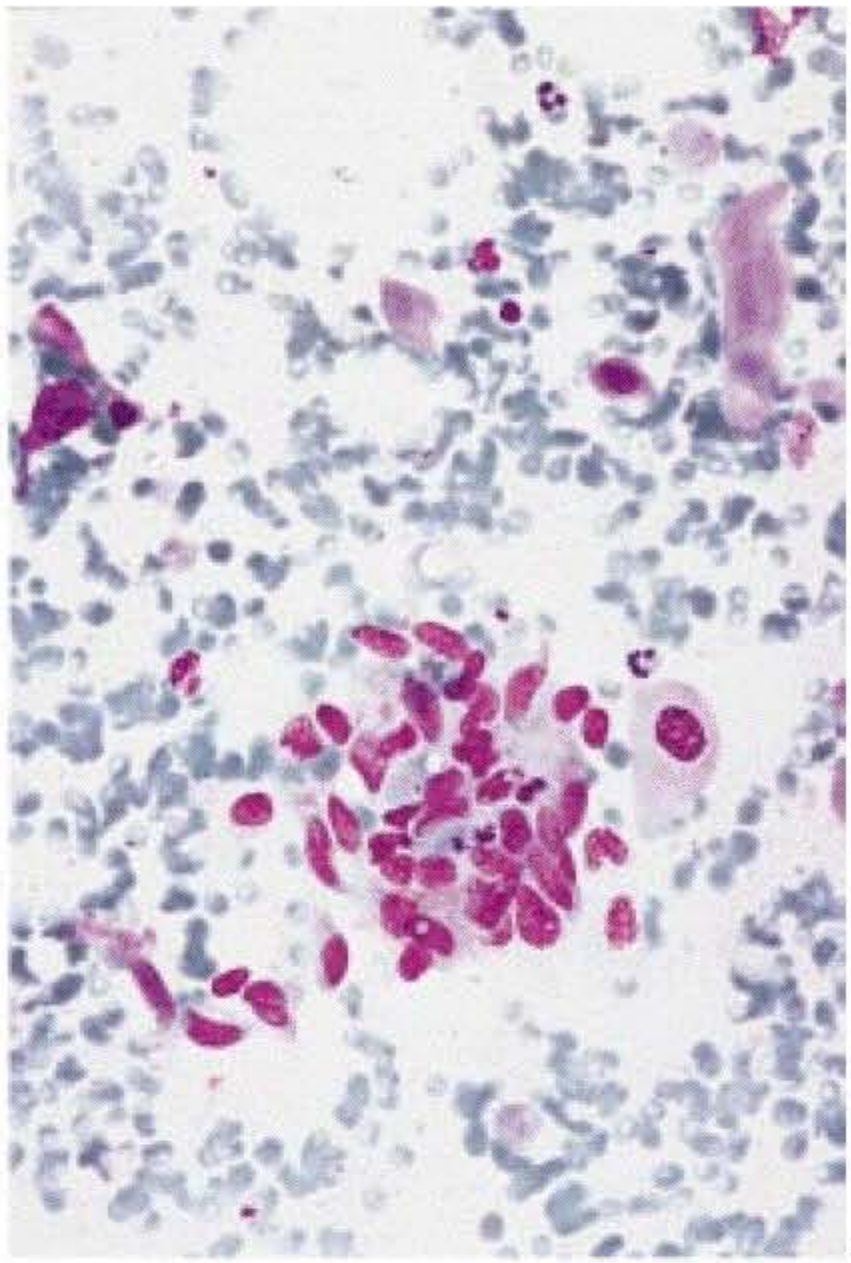

8.34

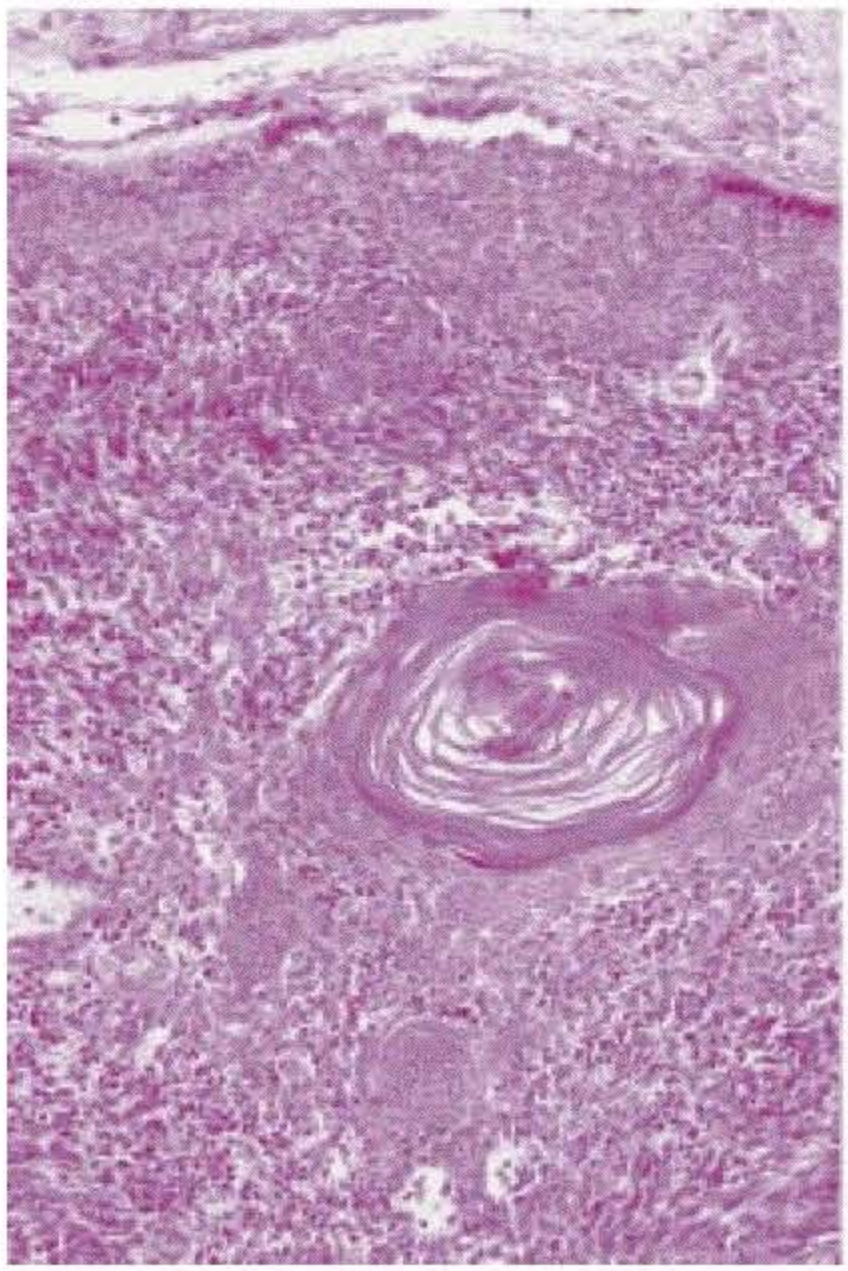

8.35

Fig. 8.29. Basal cell adenocarcinoma. Three-dimensional cluster of basaloid cells with hyaline globules (arrow) resembling adenoid cystic carcinoma. MGG. ×128.

Fig. 8.30. Basal cell adenocarcinoma. Dark clusters of malignant basaloid cells. Glandular and tubular structures are seen at the periphery. MGG. ×128.

Fig. 8.31. Basal cell adenocarcinoma. Necrosis. MGG. ×128.

Fig. 8.32. Basal cell adenocarcinoma. Cellular mild pleomorphism. MGG. ×128.

Fig. 8.33. Basal cell adenocarcinoma. Naked nuclei similar to those seen in basal cell adenoma. MGG. ×128.

Fig. 8.34. Basal cell adenocarcinoma. Focal squamous metaplasia. MGG. ×128.

Fig. 8.35. Basal cell adenocarcinoma. Histological section corresponding to figure 8.34. HES. ×32.

Table 8.7. Correlation between cytology and histology of basal cell adenocarcinomas

Author [ref.]	Number	Malignant	Suspicious	False-negative	Unsatisfactory
Lindberg, Åkerman [222]	1	1	0	0	0
Brown et al. [38]	1	1	0	0	0
Pisharodi [274]	2	2	0	0	0
Orell [263]	1	1	0	0	0
Moroz et al. [251]	1	1	0	0	0
Al-Khafaji et al. [8]	1	1	0	0	0
Klijanienko, Vielh [188]	4	4	0	0	0
Total	11	11	0	0	0

Statistics from the literature.

Table 8.8. Quantitative differential diagnosis of basal cell adenocarcinoma

	Basal cell adenocarcinoma	Basal cell adenoma	Adenoid cystic carcinoma	Cellular pleomorphic adenoma
Cells				
Plasmacytoid	–	–	–	++
Basal	++	++	+/–	–
Squamous	+/–	+	+/–	+/–
Naked nuclei	+/–	++	++	–
Peripheral palisading	+/–	+/–	–	–
Necrosis, mitoses	+/–	–	+/–	–
Stroma				
Chondromyxoid	–	–	–	+
Globules	+/–	+/–	++	+/–
Finger-like structures	–	–	++	–

++ = Common; + = rare; +/– = occasionally; – = absent.

ous size with hyaline material outside of the cell nests. Cells are small, round with scant cytoplasm and dark nuclei. The peripheral parts of the islands are lined by palisading cells in contact with the stroma. In the centre of the islands, the cells are larger, slightly eosinophilic and squamous metaplasia is occasionally seen. Necrosis may also be observed.

8.5.3. Cytopathology

Basal cell adenocarcinomas are composed of cells similar to those seen in basal cell adenoma, but present some cellular pleomorphism, mitotic figures, coarse chromatin and focal necrosis [188]. Solid, trabecular and tubular areas, as well as focal squamous metaplasia are also present (fig. 8.29–8.35).

8.5.4. Diagnostic Accuracy

Only 11 cases have been reported in the literature (table 8.7). Interestingly, despite morphological similarities to basal cell adenoma, all reported cases of basal cell adenocarcinoma were cytologically diagnosed as malignant.

8.5.5. Differential Diagnosis

Basal cell adenocarcinoma must be differentiated from basal cell adenoma, adenoid cystic carcinoma and cellular pleomorphic adenoma (table 8.8).

8.5.5.1. Basal Cell Adenocarcinoma vs. Basal Cell Adenoma

Basal cell adenoma is a major differential diagnosis. Tumours with basaloid cells exhibiting one of the following features: nuclear pleomorphism, large three-dimensional

cellular clusters with glandular structures, mitotic figures, coarse chromatin and/or evidence of necrosis, are strongly suspicious of malignancy (fig. 8.30–8.32). However, only histological confirmation can definitively exclude malignancy in a cytologically benign specimen.

8.5.5.2. Basal Cell Adenocarcinoma vs. Adenoid Cystic Carcinoma

The cytological differences between basal cell adenocarcinoma and adenoid cystic carcinoma are often subtle. Tubular or finger-like structures are suggestive of adenoid cystic carcinoma (fig. 7.23–7.25, 7.27). Hyaline globules are present in both entities, but are more numerous in adenoid cystic carcinoma (fig. 7.21, 8.29). Unlike adenoid cystic carcinoma, basal cell adenocarcinoma is composed of small, more regular, ovoid to round cells with scant cytoplasm. In the case of solid adenoid cystic carcinoma, this lesion can be readily distinguished from basal cell adenocarcinoma by the absence of mitotic figures and necrosis (fig. 7.29).

8.5.5.3. Basal Cell Adenocarcinoma vs. Cellular Pleomorphic Adenoma

Correct recognition of myoepithelial cells from pleomorphic adenoma with distinctive cytoplasmic borders is of capital importance in the differential diagnosis between these entities (fig. 6.3, 8.33).

Basal Cell Adenocarcinoma

In favour of the diagnosis

Basaloid clusters of dark cells with cytonuclear pleomorphism, mitoses, scant necrosis, naked nuclei

Difficulties

Numerous hyaline globules

Against the diagnosis

Plasmacytoid cells, absence of naked nuclei

Chapter 9

Benign and Malignant Mesenchymal Tumours and Miscellaneous Lesions

Benign and malignant mesenchymal (primary or metastatic) tumours are rare and account for less than 5% of all salivary gland tumours [90, 303]. More than 90% of mesenchymal tumours arise in the parotid gland and less than 10% involve the submandibular or sublingual glands.

9.1. Benign Mesenchymal Tumours

9.1.1. General

More than 90% of mesenchymal salivary gland tumours are benign. The commonest tumours are lipomas, lymphangiomas and haemangiomas. Nearly 90% of haemangiomas occur in children and young adults, whereas lipomas and neurogenic tumours occur in the fourth to seventh decades of life. There is a male predominance for lipomas and neurofibromas, and a female predominance for neuromas.

9.1.2. Histopathology

Vascular, lipomatous and neurogenic tumours are histologically identical to their counterparts in other sites [89].

9.1.3. Cytopathology

Haemangiomas and lymphangiomas are characterized by spindle-shaped cells with moderate cytoplasm and oval bland nuclei. Clusters of small lymphocytes may be found in lymphangiomas [145, 155].

Adipocytes or free fat intermingled with connective tissue fragments are typically seen in lipomas [217].

Schwannomas may present two cell populations: spindle cells with a whorling pattern and occasional Verocay bodies and less cohesive clusters of spindle-shaped and epithelial-like cells [143, 231].

Nodular fasciitis yields uniform or plumb spindle cells within a fibrillary stroma, and loosely aggregated epithelial-like cells [3, 323]. Nuclear chromatin is bland. They may have prominet nucleoli and mitotic figures are not uncommon. Myxoid background and some inflammatory cells are also present.

Examples of benign mesenchymal tumours are illustrated in figures 9.1–9.6.

9.1.4. Diagnostic Accuracy

Only a few cytological reports of benign mesenchymal salivary gland tumours have been published (table 9.1).

9.1.5. Differential Diagnosis

Stroma-rich pleomorphic adenoma is the main differential diagnosis. Lymphangioma may be confused with Warthin's tumour (cystic content, lymphocytes) and sialadenitis. Cytological features can be very suggestive of the correct diagnosis in cases of paraganglioma, clinically presenting as a probable salivary gland tumour.

9.2. Malignant Mesenchymal Tumours

Primary or secondary sarcomas of major salivary glands are very rare. The largest series totalling 85 cases was reported by the AFIP [90].

Fig. 9.1. Benign haemangiopericytoma. Spindle-shaped benign connective tissue cells. MGG. ×128.

Fig. 9.2. Benign haemangiopericytoma. Histological section corresponding to figure 9.1. HES. ×64.

Fig. 9.3. Parotid gland lipoma. HES. ×32.

Fig. 9.4. Granular (Abrikosoff) tumour of parotid gland. Characteristic cells with granular cytoplasm. MGG. ×128.

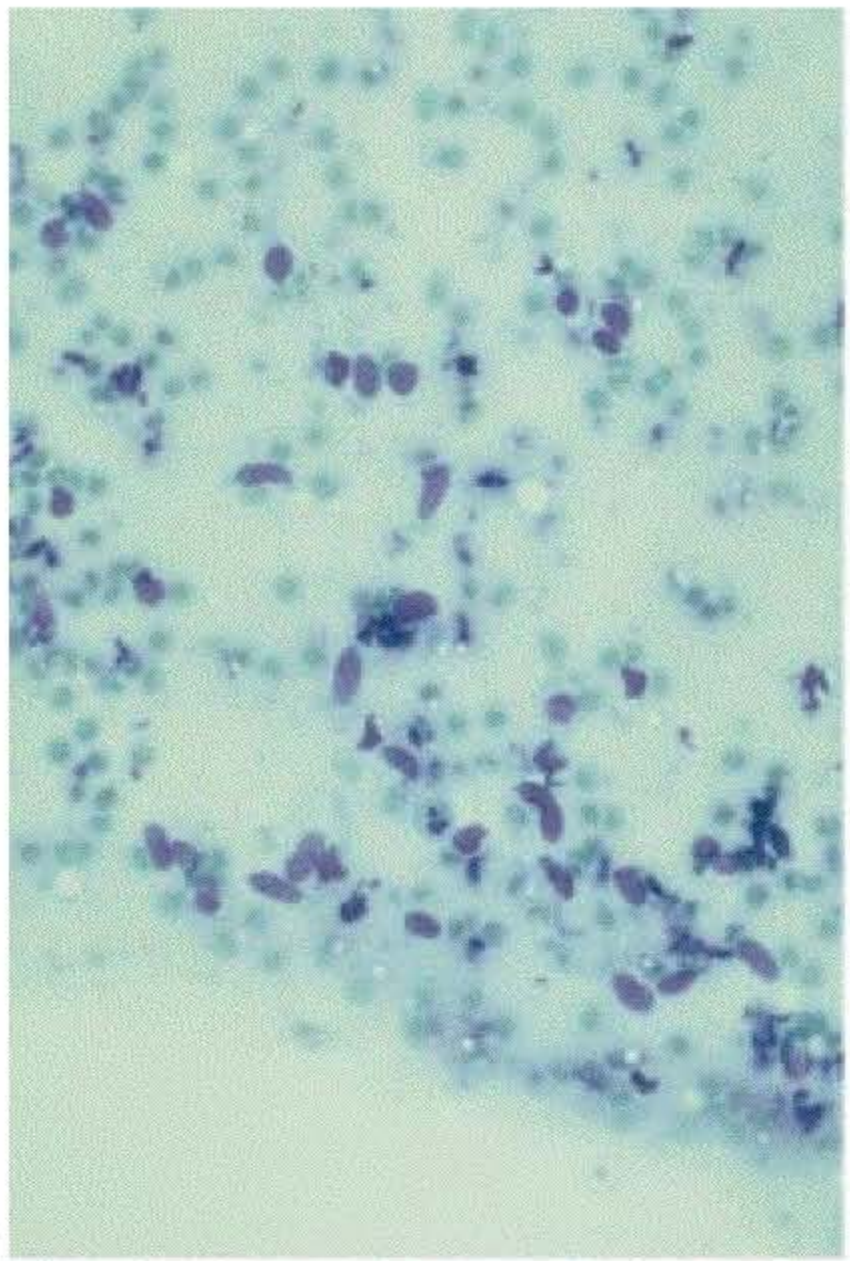

9.1

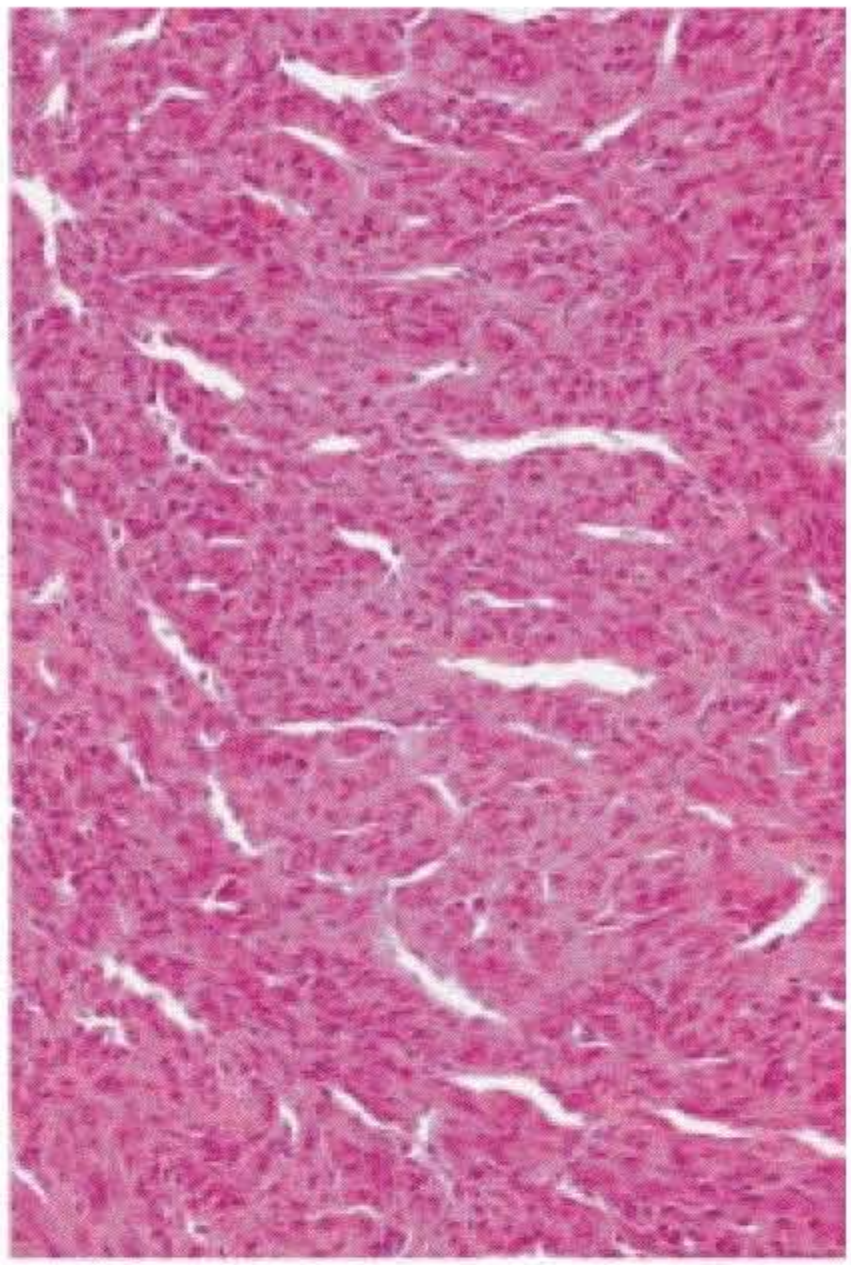

9.2

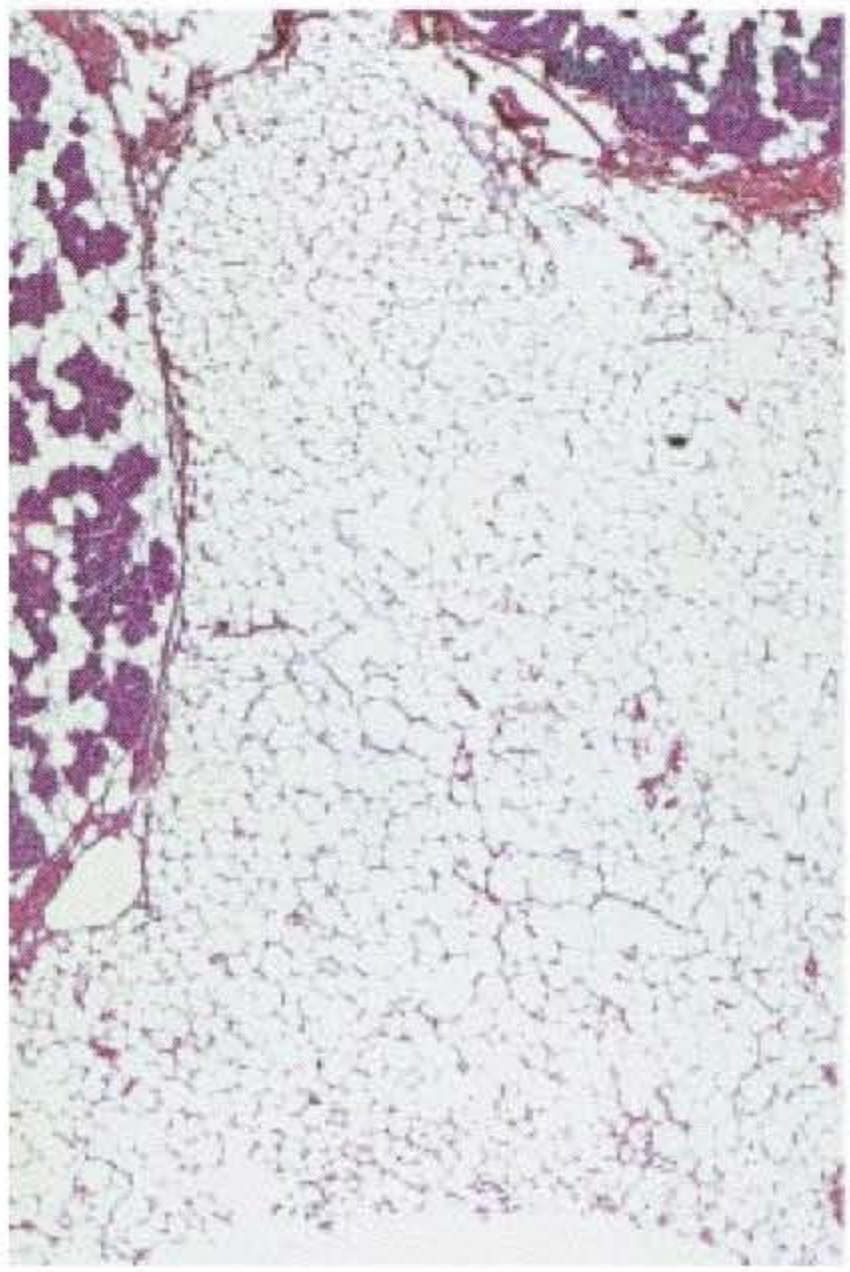

9.3

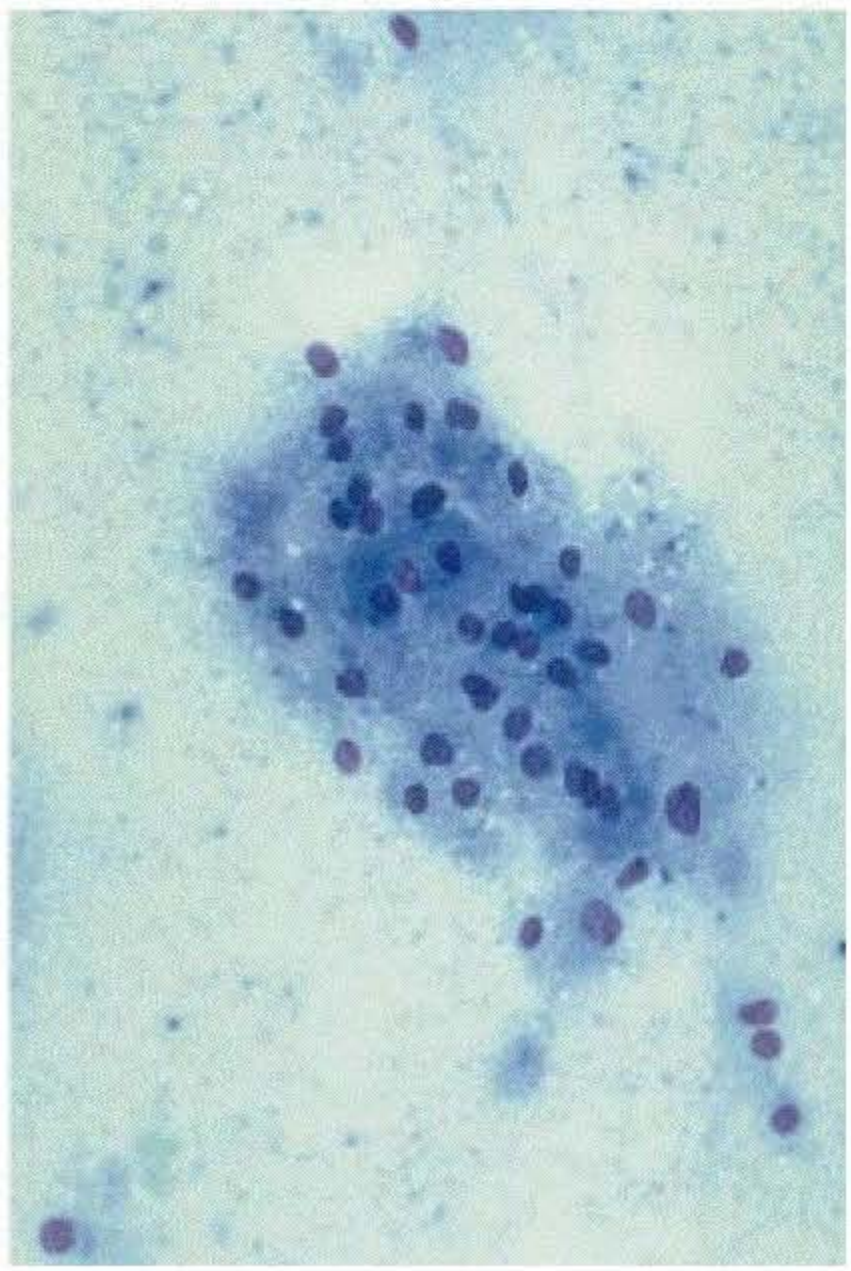

9.4

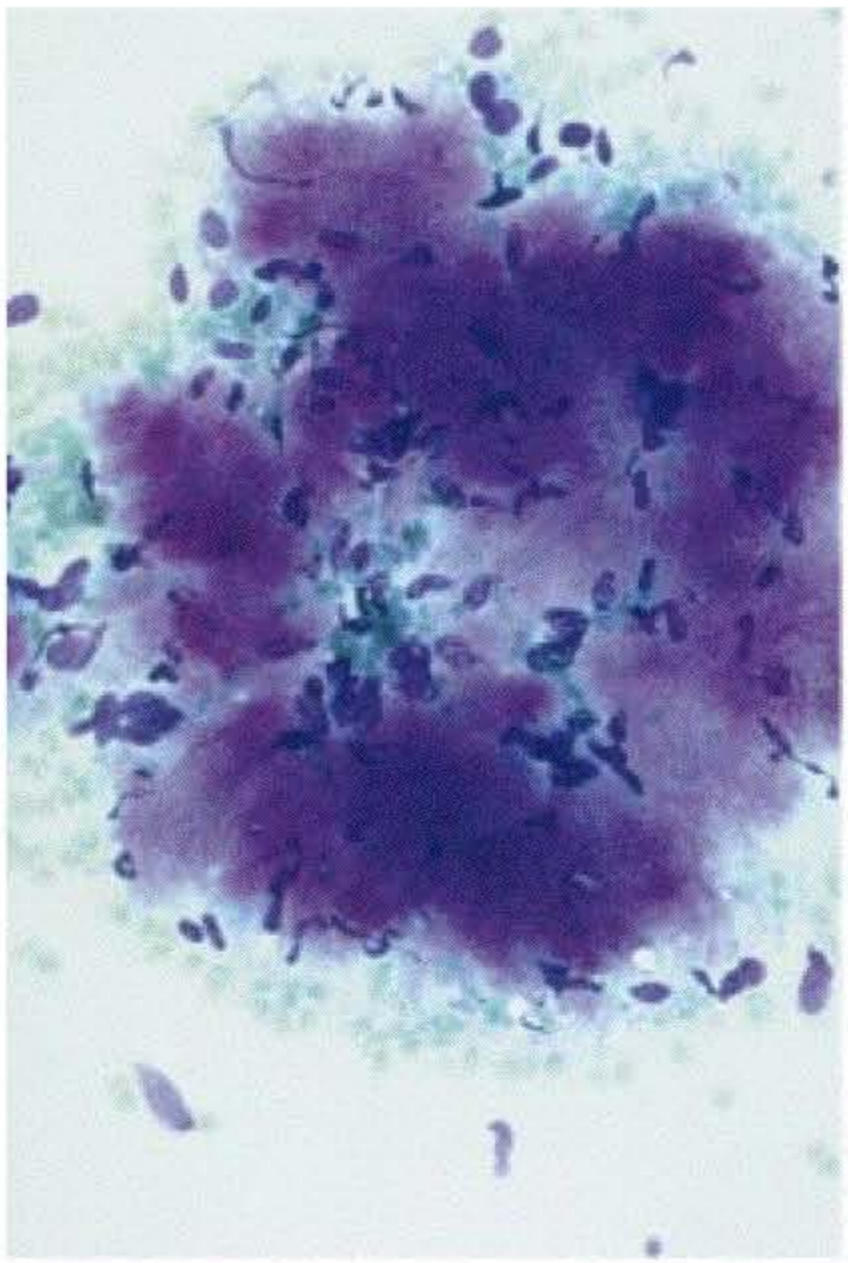

9.5

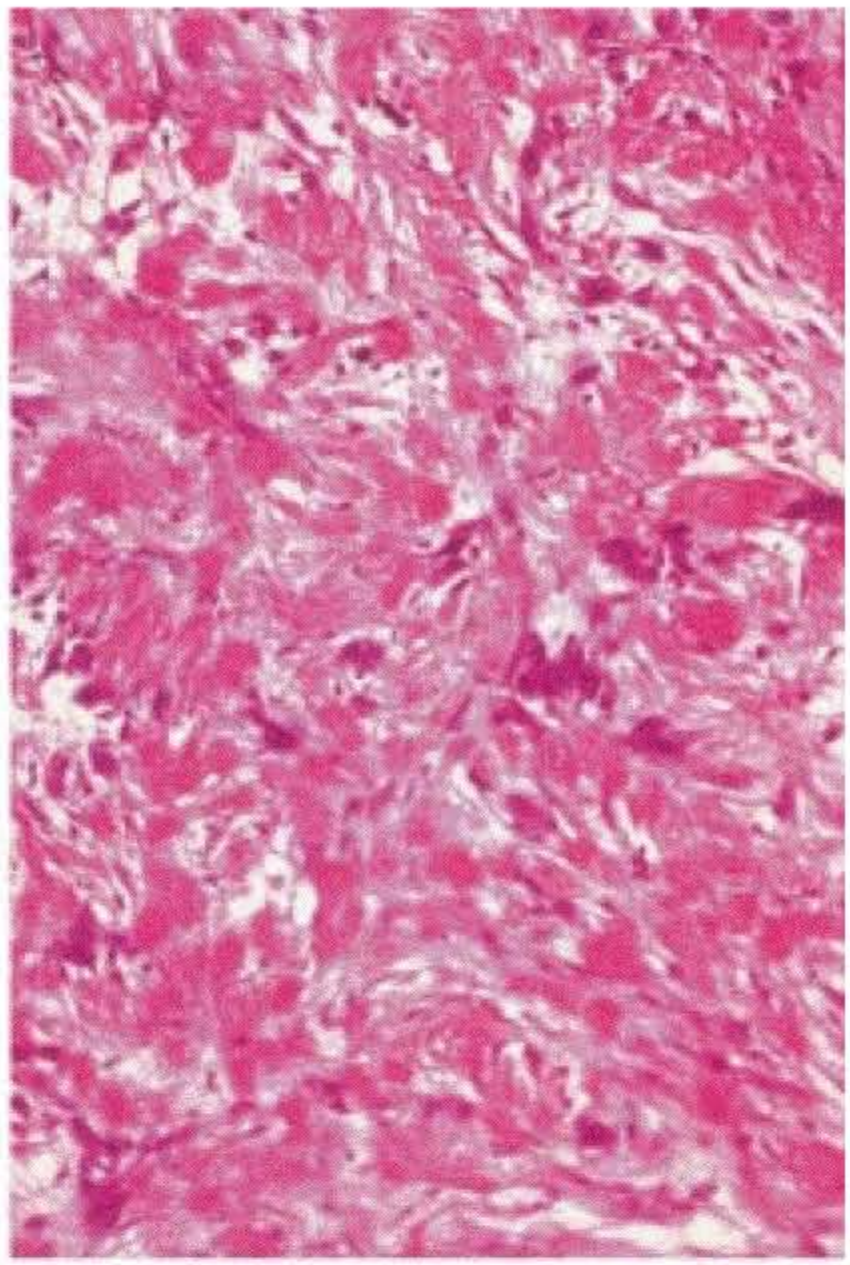

9.6

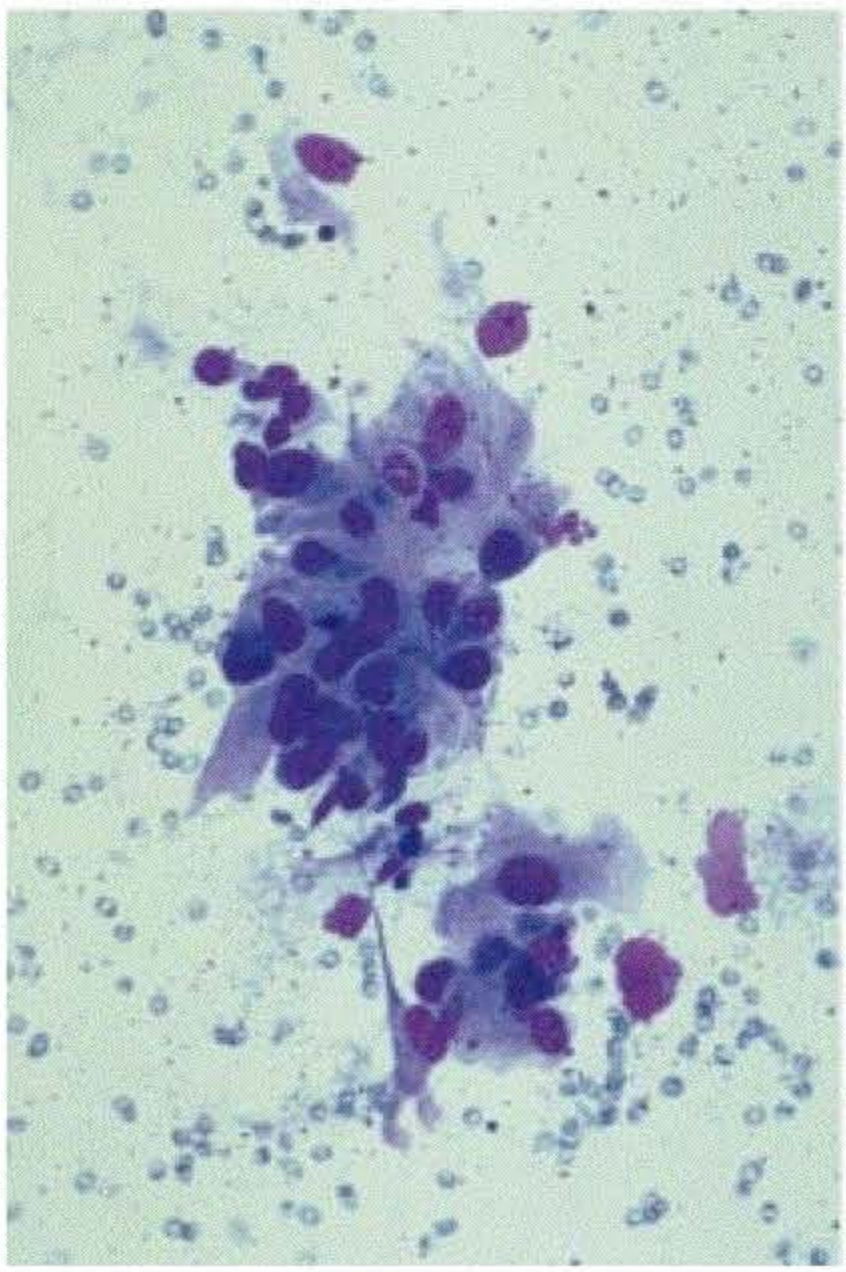

9.7

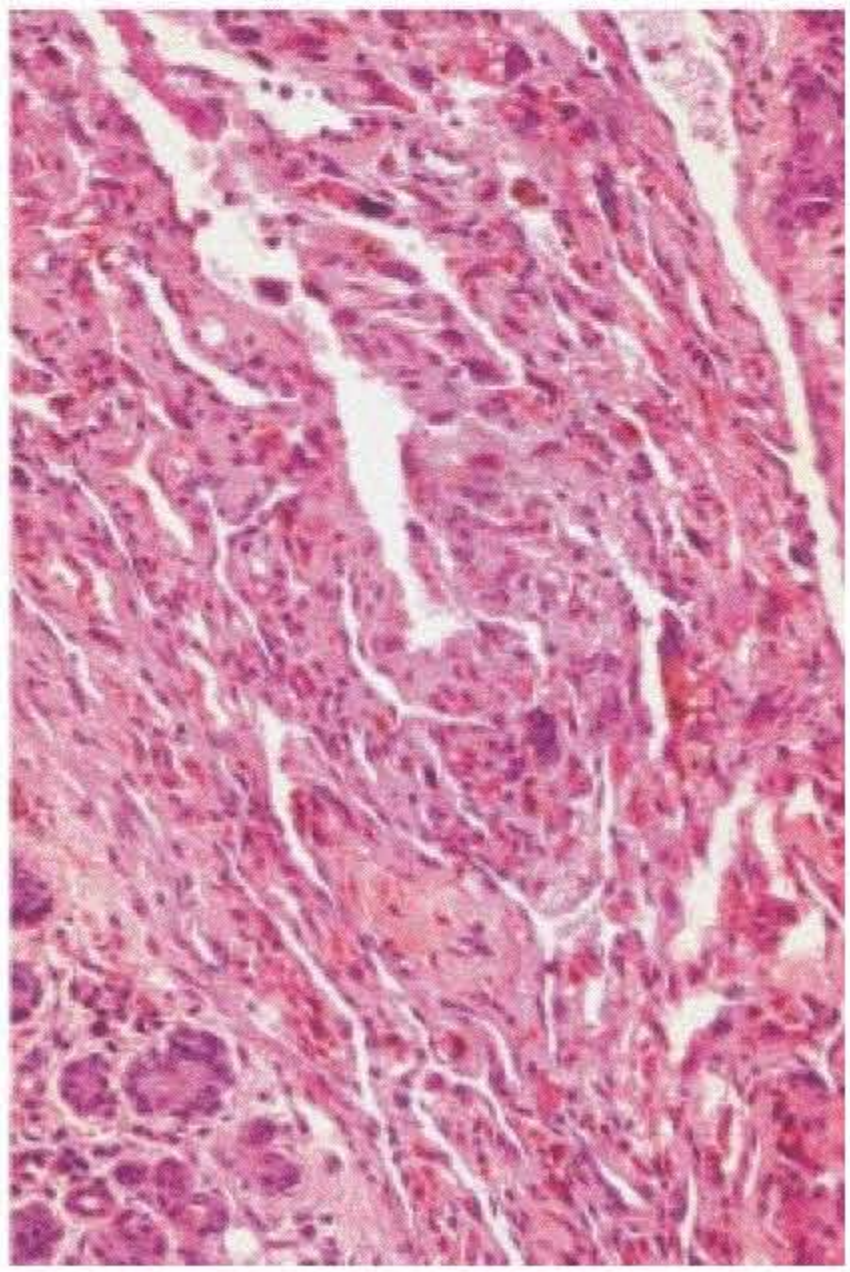

9.8

Table 9.1. Correlation between cytology and histology of soft tissue salivary tumours

Author [ref.]	Types	Number	Benign	Suspicious and False-positive	Unsatisfactory
Mavec et al. [241]	?	7	5	0	2
Eneroth et al. [96]	?	12	9	0	3
Kline et al. [201]	1	1	1	0	0
Hilborne et al. [155]	1	1	0	1	0
Mair, Leiman [231]	1	1	1	0	0
Young et al. [351]	1	1	1	0	0
Gupta, Dowle [143]	1	1	1	0	0
Smith Frable, Frable [313]	1	1	0	0	1
Layfied, Glasgow [216]	3	11	11	0	0
Layfield et al. [217]	1	6	4	0	2
Chan, McGuire [50]	1	2	0	0	0
Abad et al. [1]	1	1	1	0	0
Weinberger et al. [341]	1	1	1	0	0
MacLeod, Frable [230]	3	4	3	0	1
Gutmann [145]	1	1	1	0	0
Orell [263]	?	6	5	0	1
Abendroth, Frauenhoffer [3]	1	2	2	0	0
Cajulis et al. [41]	1	1	0	1	0
Al-Khafaji et al. [8]	1	2	2	0	0
Our series	8	25	21	0	4
Total		87	71 (81.6)	2 (2.3)	14 (16.1)

Statistics from the literature. % in parentheses.

9.2.1. General

Sarcomas represent 0.6% of all salivary gland tumours and 1.6% of all malignant tumours in the AFIP series. Tumours predominantly occur in the parotid gland, and occasionally in the submandibular gland. All ages are affected and there is no sex predominance.

9.2.2. Histopathology

Malignant haemangiopericytoma, angiosarcoma, schwannoma, fibrosarcoma, malignant fibrous histiocytoma and rhabdomyosarcoma are the commonest primary sarcomas [15, 89].

Fig. 9.5. Schwannoma. Connective tissue deposits and spindle-shaped cells. MGG. ×128.

Fig. 9.6. Schwannoma. Histological section corresponding to figure 9.5. HES. ×64.

Fig. 9.7. Angiosarcoma. Malignant cells with marked nuclear atypia. MGG. ×128.

Fig. 9.8. Angiosarcoma. Histological section corresponding to figure 9.7. HES. ×64.

9.2.3. Cytopathology

Sarcomas are relatively easily diagnosed as malignancies on cytology, but are difficult to accurately type [179]. Ancillary techniques may contribute considerably to the diagnosis.

Malignant haemangiopericytoma is composed of small, ovoid to spindle cells. Mitotic figures and necrosis are rare.

Smears of angiosarcomas are bloody and composed of isolated or clustered pleomorphic, spindle to round cells with marked atypia [252]. Nuclei are eccentric with prominent nucleoli. Binucleated cells are rarely seen. The cytoplasm is scant. Numerous siderophages are present (fig. 9.7, 9.8).

Smears of malignant schwannomas (malignant peripheral nerve sheath tumours) are usually very richly cellular and mostly consist of isolated cells. Cells are large, ovoid to spindle, with scant cytoplasm. Multinucleated cells are common (fig. 9.9).

Fibrosarcoma is paucicellular and composed of spindle cells showing nuclear pleomorphism and prominent nuclei. Cytoplasm may be abundant. Numerous connective fragments are observed in the background (fig. 9.10, 9.11).

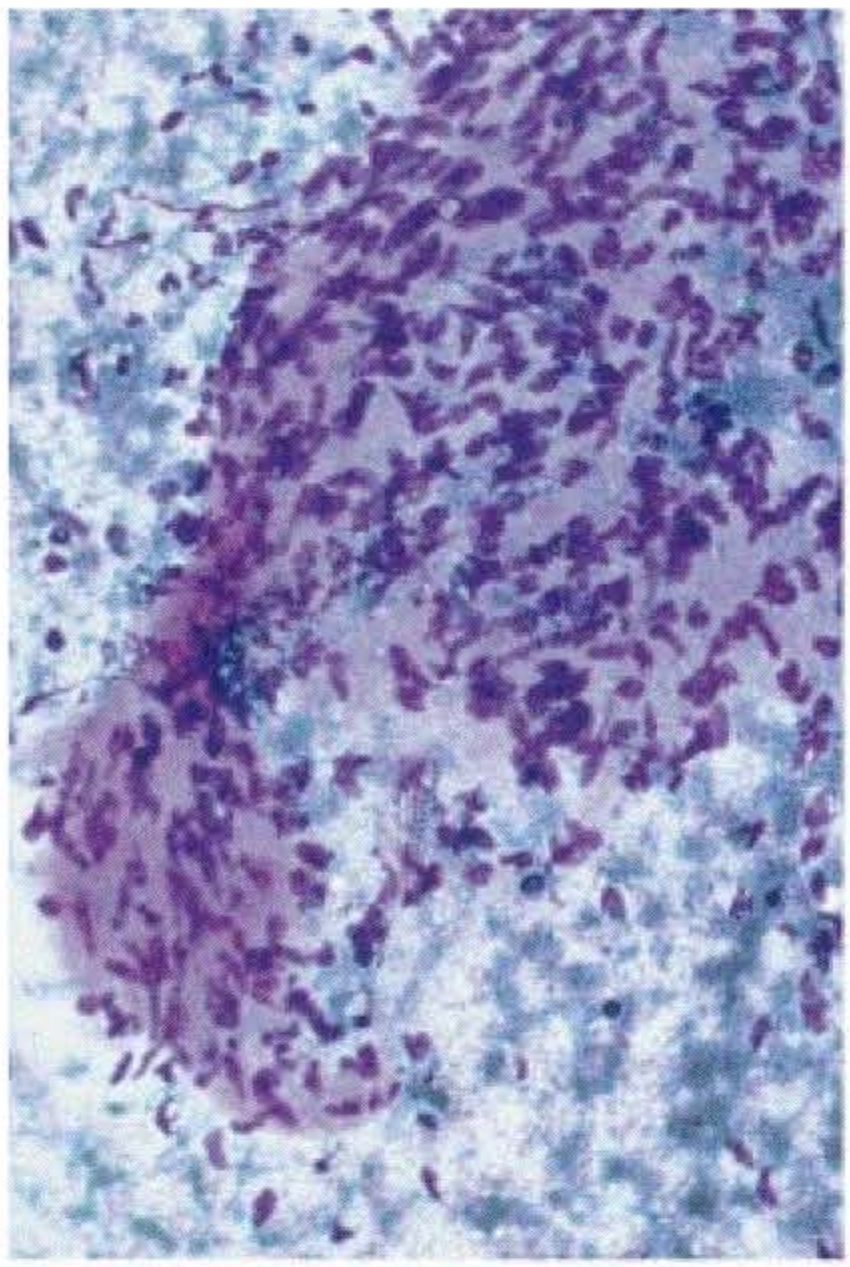

9.9

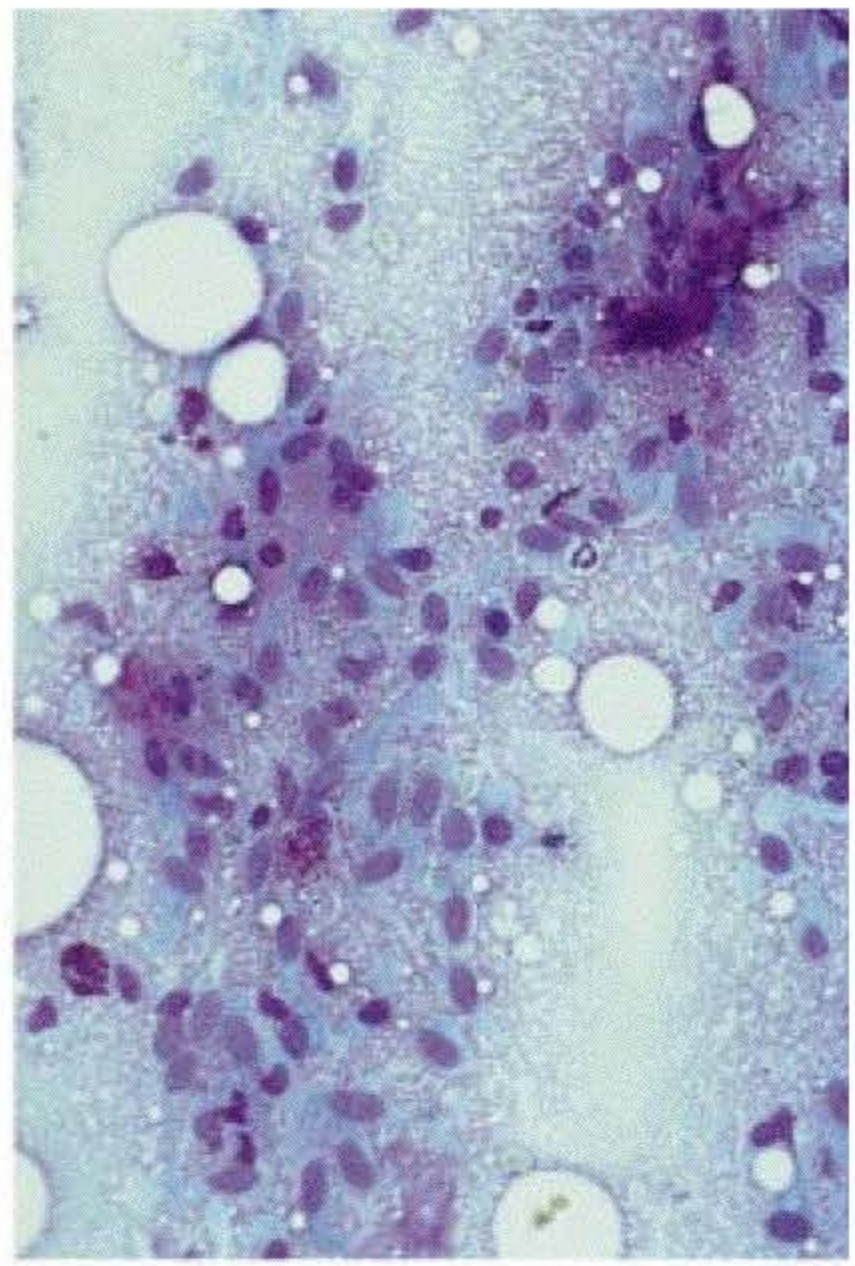

9.10

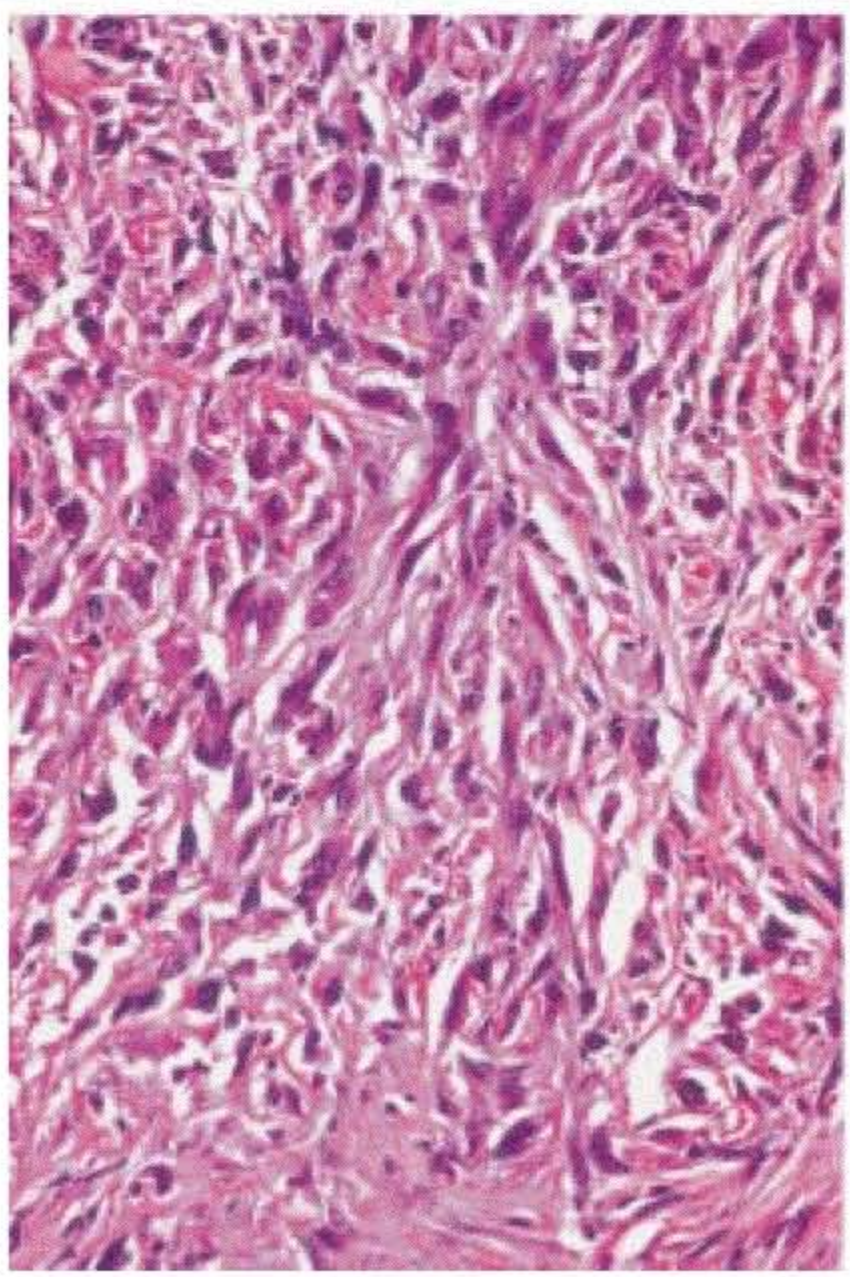

9.11

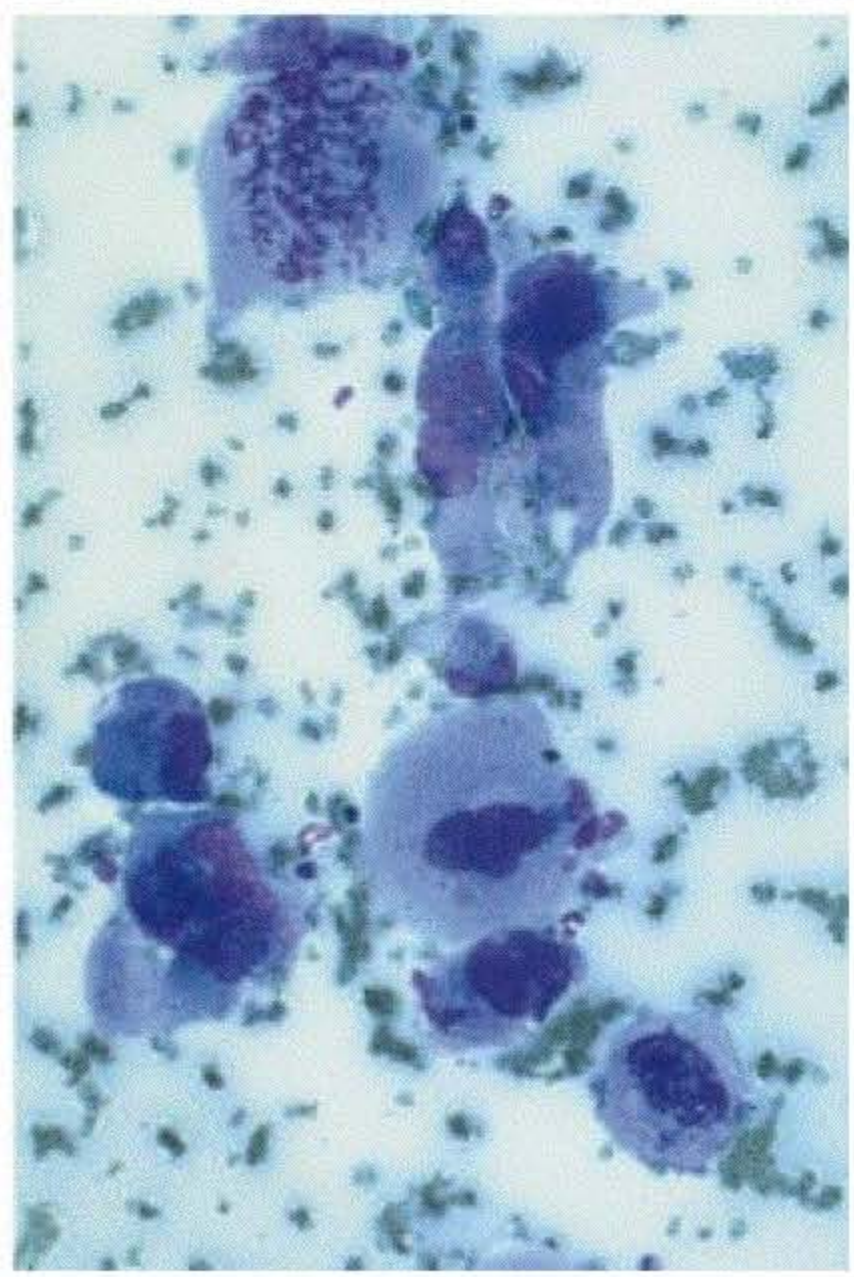

9.12

9.13

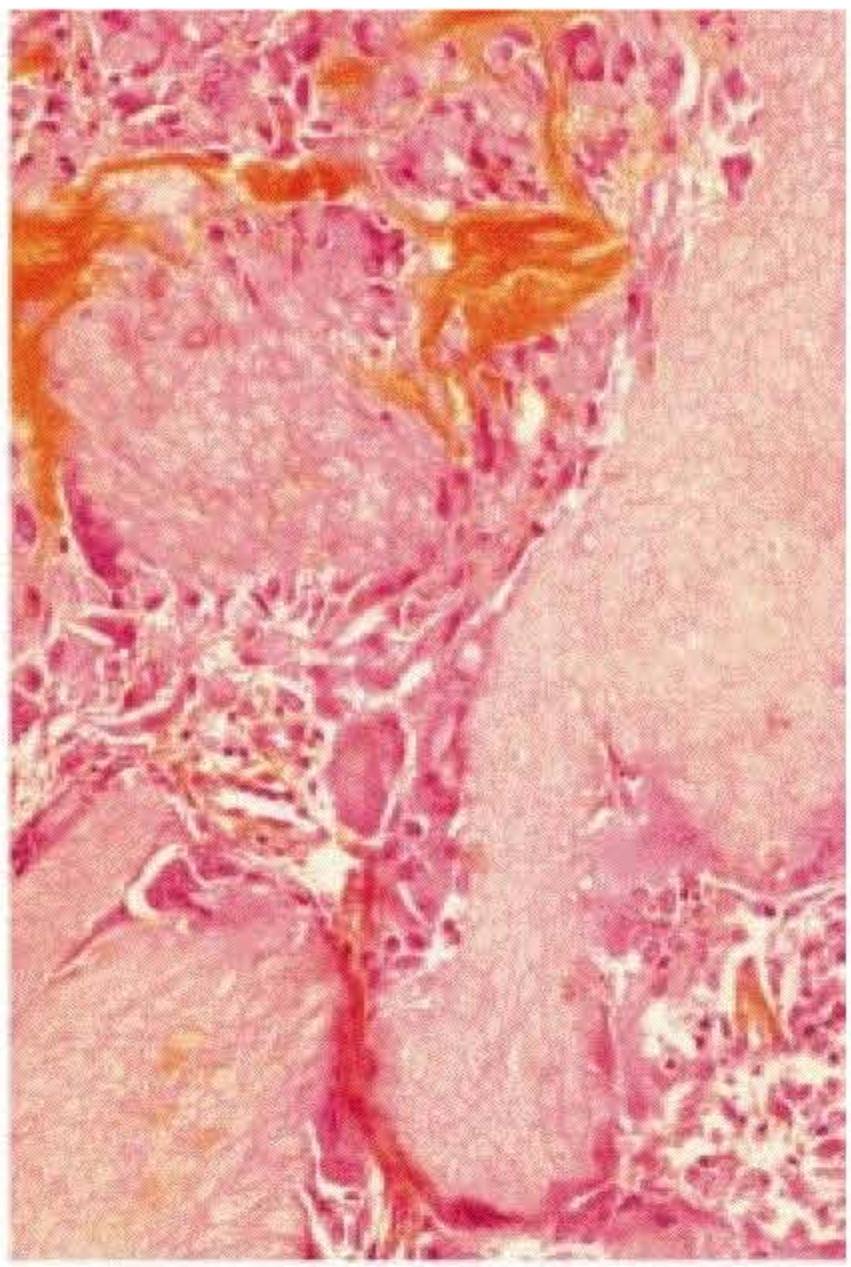

9.14

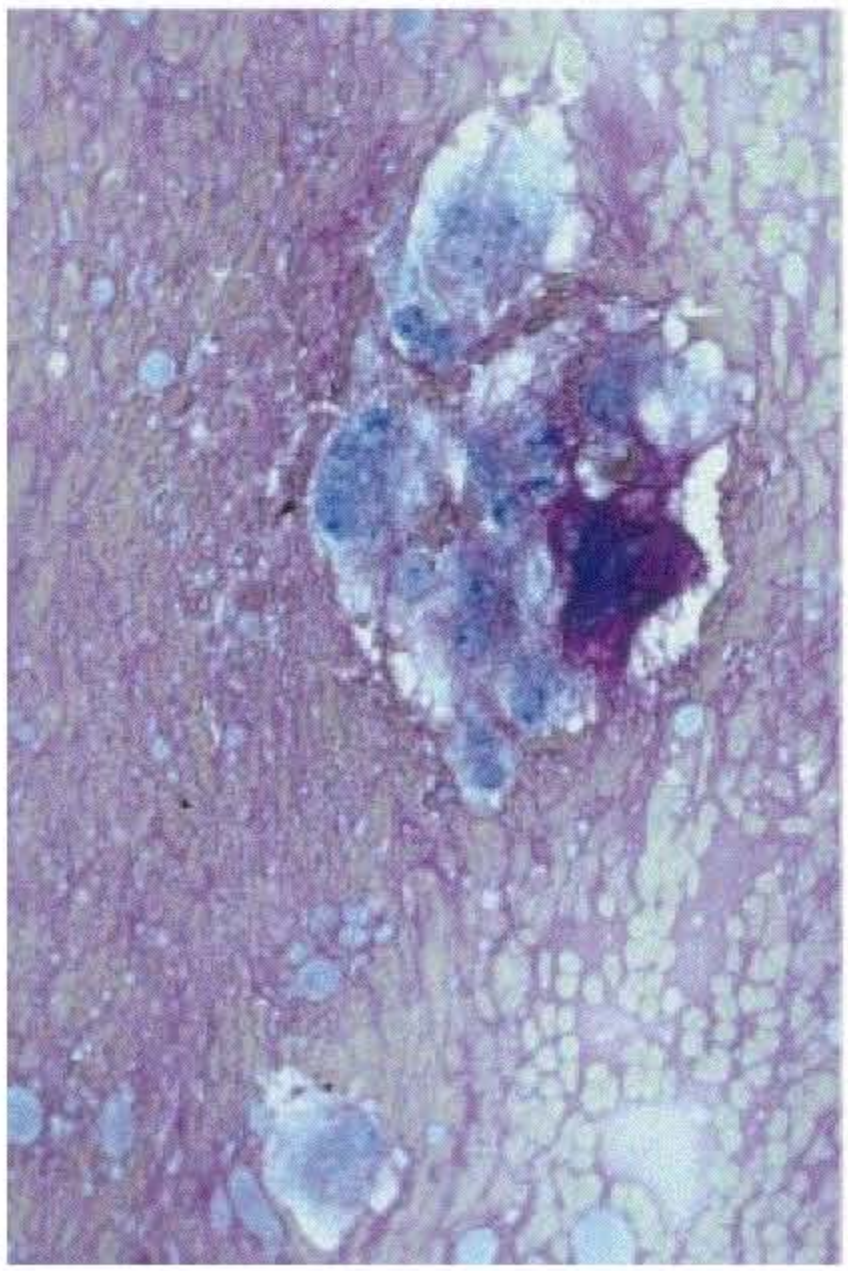

9.15

Fig. 9.9. Malignant schwannoma. Malignant spindle-shaped cells in a connective tissue background. MGG. E64.

Fig. 9.10. Fibrosarcoma, low-grade. Isolated malignant spindle-shaped cells. MGG. E64.

Fig. 9.11.. Fibrosarcoma. Histological section corresponding to figure 9.10. HES. E64.

Fig. 9.12. Rhabdomyosarcoma composed of cells with marked pleomorphism. MGG. E128.

Fig. 9.13. Pilomatrixoma. Ghost cells and calcium deposits. MGG. E128.

Fig. 9.14. Pilomatrixoma. Histological section corresponding to figure 9.13. HES. E64.

Fig. 9.15. Chordoma of the parotid gland. Large cells in a strongly eosinophilic 'mucoid' background. MGG. E64.

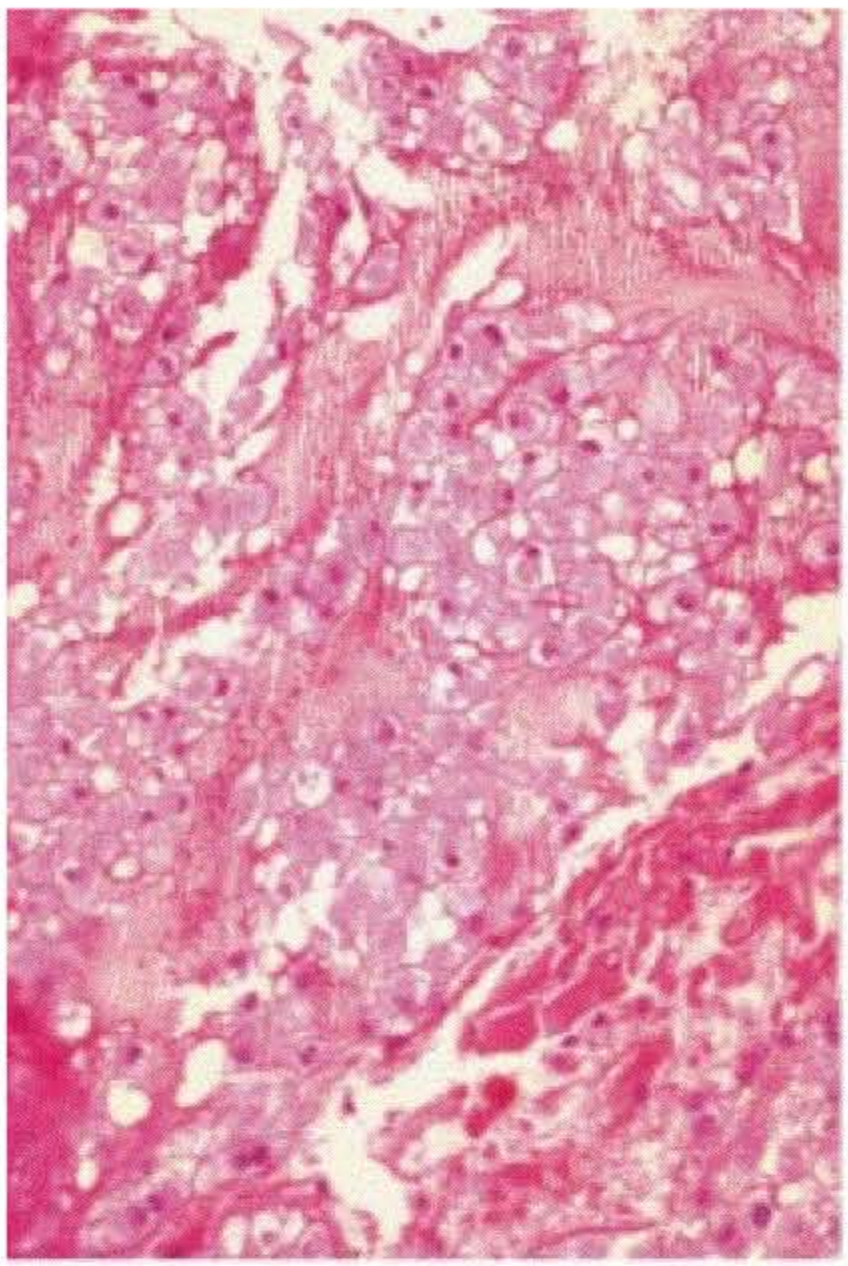

9.16

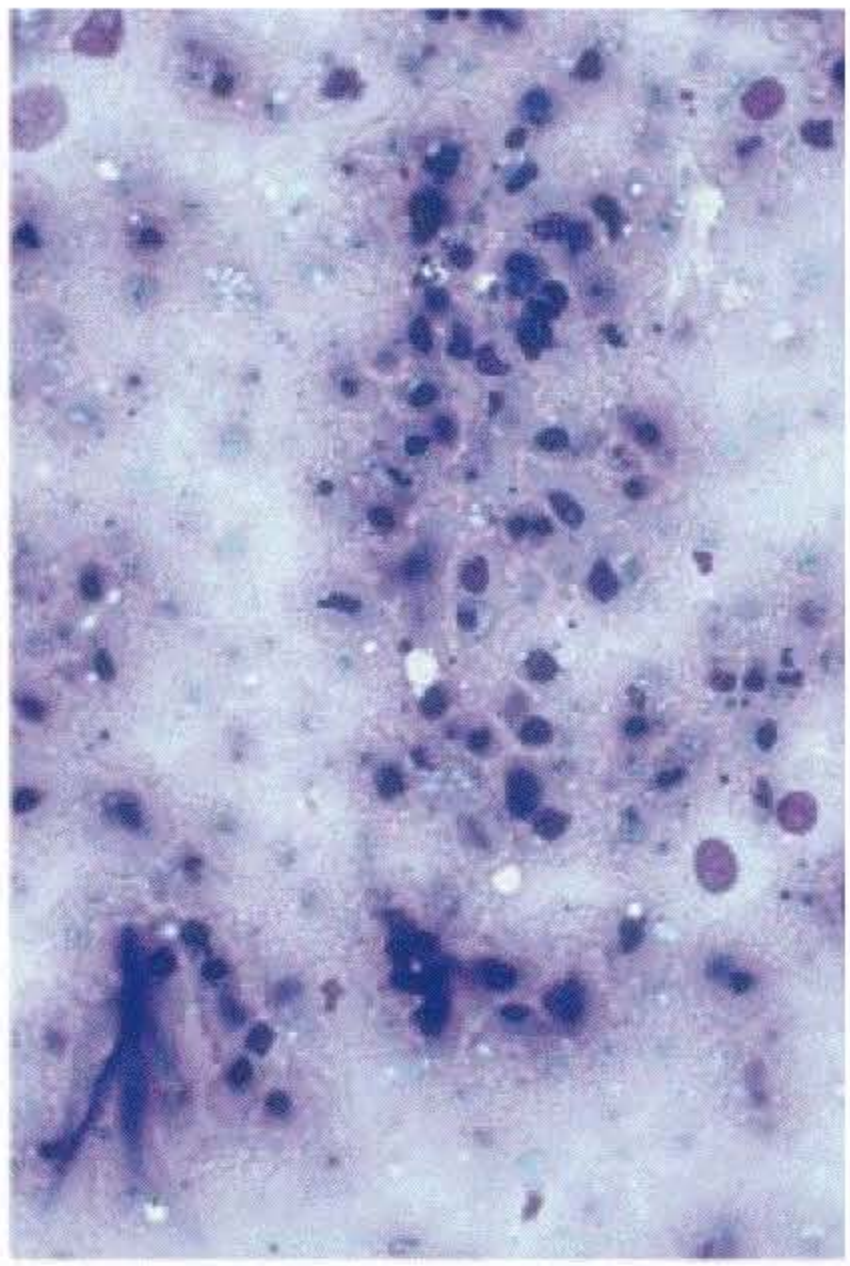

9.17

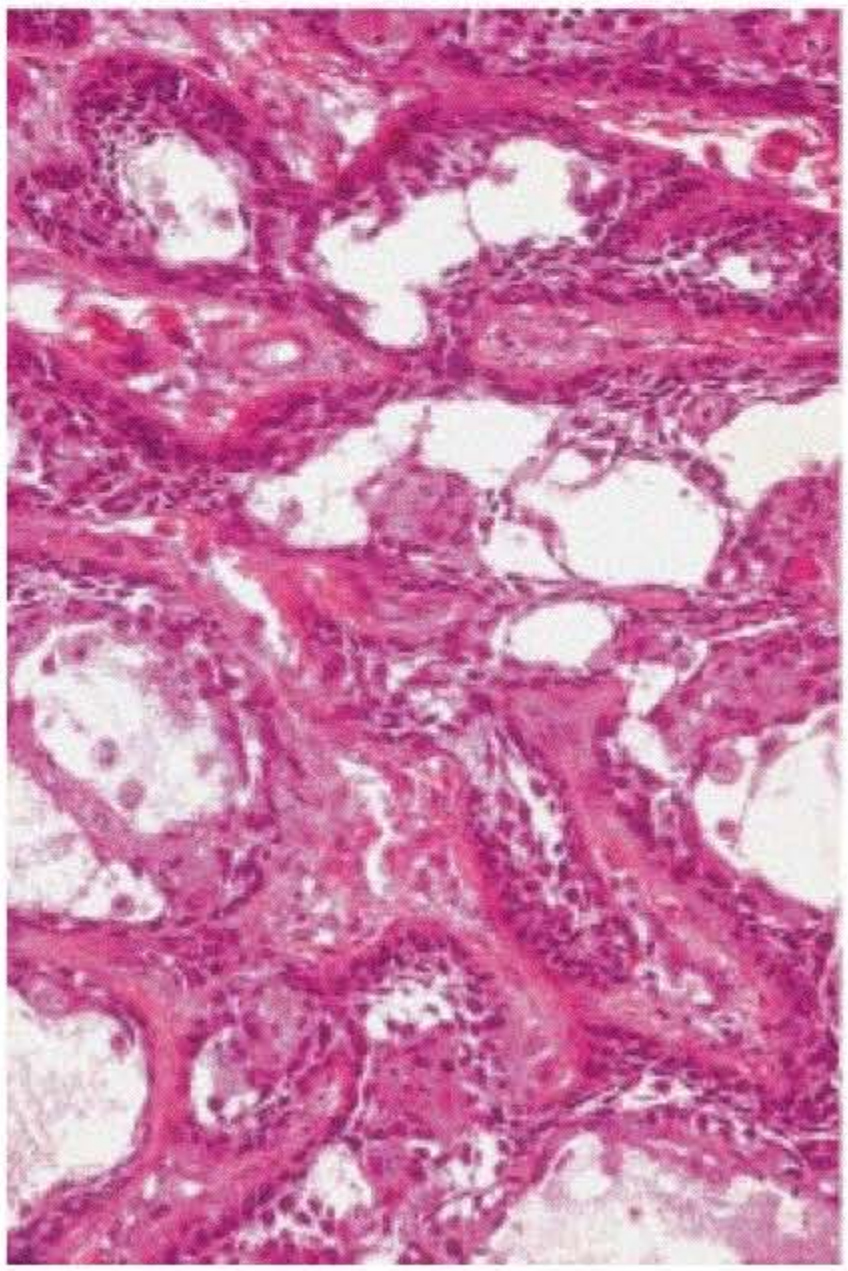

9.18

Fig. 9.16. Chordoma. Histological section corresponding to figure 9.15. HES. ×64.

Fig. 9.17. Adenosquamous carcinoma. Numerous malignant squamous cells. The differential diagnosis with squamous cell carcinoma is not possible. MGG. ×128.

Fig. 9.18. Adenosquamous carcinoma. Histological section corresponding to figure 9.17. HES. ×64.

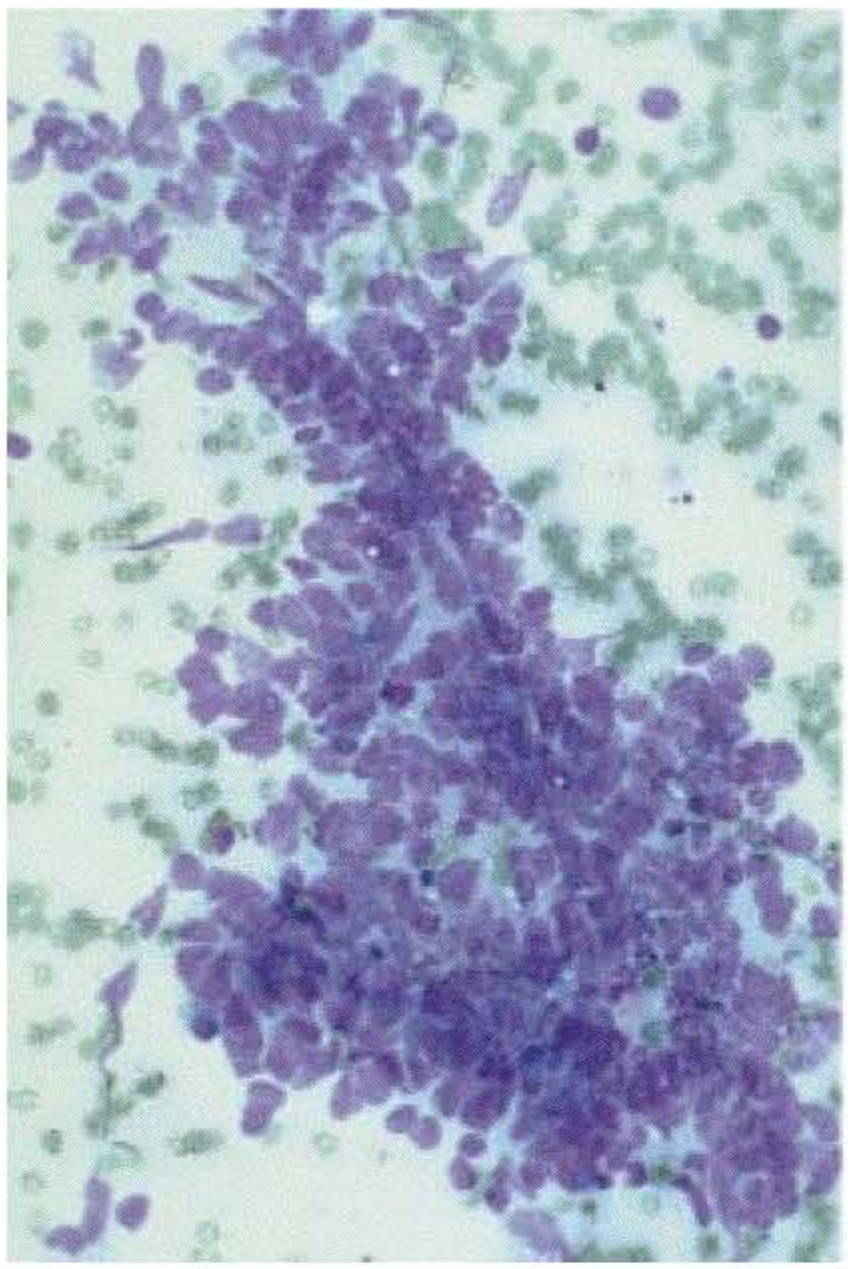

9.19

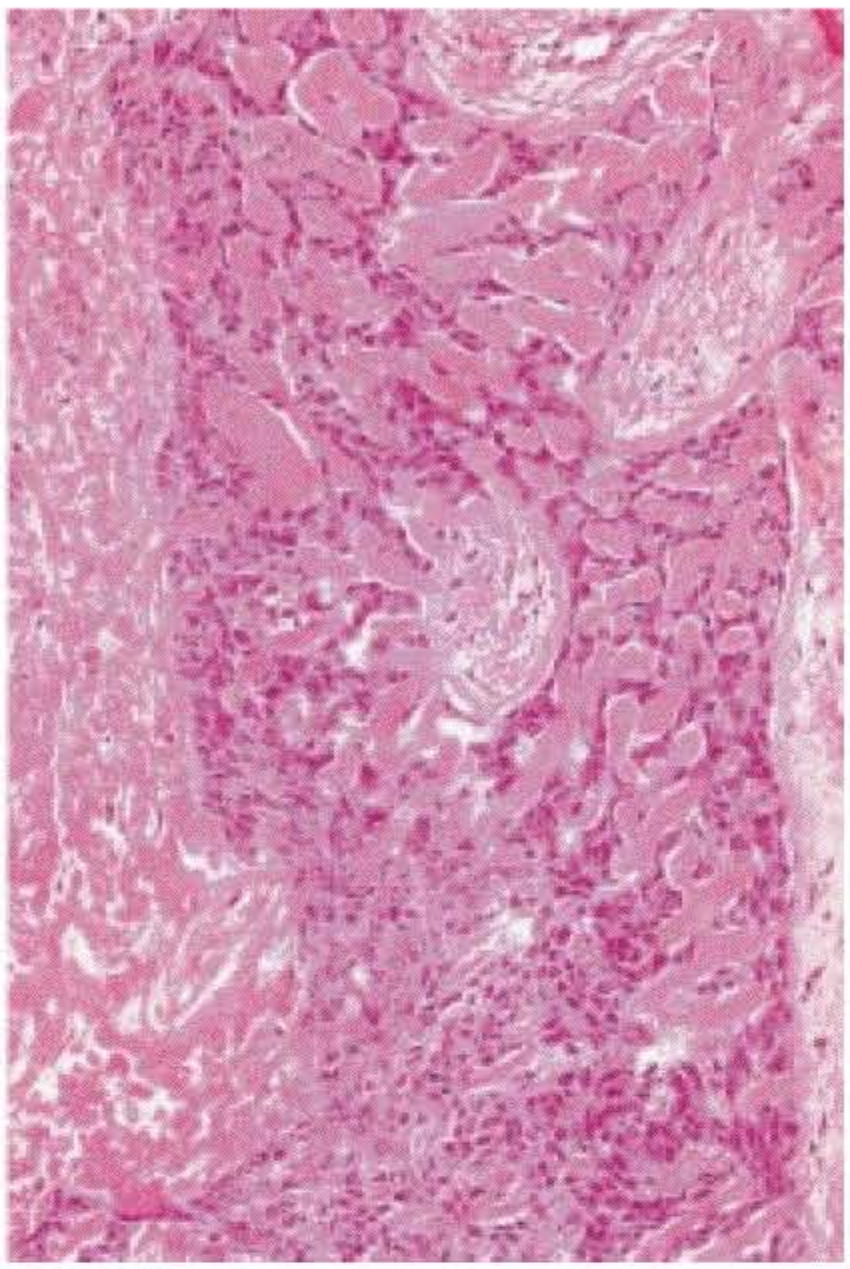

9.20

Fig. 9.19. Basaloid-squamous carcinoma deeply infiltrating parotid gland. Poorly-differentiated malignant cells. MGG. ×128.
Fig. 9.20. Basaloid-squamous carcinoma. Histological section corresponding to figure 9.19. HES. ×32.

Table 9.2. Correlation between cytology and histology of salivary sarcomas

Author [ref.]	Types	Number	Malignant	Suspicious	False-negative	Unsatisfactory
Mavec et al. [241]	?	5	5	0	0	0
Eneroth et al. [96]	?	6	6	0	0	0
Jayaram et al. [169]	1	1	1	0	0	0
Smith Frable, Frable [313]	1	1	0	0	1	0
MacLeod, Frable [230]	1	1	0	0	1	0
Mullick et al. [252]	1	1	1	0	0	0
Mathew, Ali [240]	2	2	2	0	0	0
Al-Khafaji et al. [8]	3	5	5	0	0	0
Salomão et al. [294]	1	3	3	0	0	0
Our series	5	6	4	1	1	0
Total		31	27 (87.1)	1 (3.2)	3 (9.7)	0 (0)

Statistics from the literature. % in parentheses.

Malignant fibrous histiocytoma is richly cellular and composed of a variety of isolated atypical cells. Anaplastic and giant cells are common.

Rhabdomyosarcomas are composed of intermediate-sized, spindle-shaped to round cells with large, eccentric nuclei. Cytoplasm is frequently abundant. Binucleated cells may be seen. Mitoses are frequent and necrosis is rare (fig. 9.12).

9.2.4 Diagnostic Accuracy

Few cases have been reported (table 9.2) and, interestingly, 2 of them were underdiagnosed as myoepithelioma.

9.2.5. Differential Diagnosis

When sarcoma is suggested on cytology, the patient should be referred for surgery for accurate tumour typing.

9.3. Miscellaneous Lesions

Other tumours may also arise in the parotid area, such as paraganglioma, pilomatrixoma (calcifying epithelioma of Malherbe), chordoma, adenosquamous carcinoma and basaloid-squamous carcinoma [36, 101, 111, 136, 283] (fig. 9.13–9.20).

Chapter 10

Lymphomas

Salivary gland lymphomas may reflect generalized systemic disease or may be primary tumours. The distinction between primary or secondary involvement is mainly based on clinical presentation [89].

10.1. General

As in other organs, primary lymphomas may arise from salivary glands and can be limited to intraparotid lymph nodes or diffuse, infiltrating salivary parenchyma [65, 89, 129, 148]. Lymphomas constitute 2–5% of all salivary gland tumours, and 10% are associated with either benign lymphoepithelial lesion (BLEL) (also called sialadenitis (LESA) or myoepithelial sialadenitis (MESA)) or Sjögren's syndrome [148, 290]. The average age is 60–70 years with a slight female predominance. The parotid gland is most often (70–80%) involved, followed by the submandibular (20%), sublingual and minor salivary glands (<10%). Hodgkin's lymphomas are exceptional [90].

10.2. Histopathology and Cytopathology

There are three types of salivary gland lymphomas: marginal zone B-cell, follicular and high-grade lymphomas. Extranodal marginal zone B-cell lymphomas of mucosa-associated lymphoid tissue (MALT) are low-grade lymphoid neoplastic proliferations often (15%) associated with BLEL or Sjögren's syndrome. Patients with BLEL have an increased (44×) risk of developing salivary gland or extrasalivary lymphoma, 80% of which are MALT tumours [148]. Follicular lymphomas (B-type) may arise (35%) in intrasalivary gland lymph nodes, and diffuse large B-cell lymphomas (30%) are primary or secondary to either MALT or follicular lymphomas [148].

Cytopathology combined with immunocytochemistry or immunophenotyping by flow cytometry [288, 308] may provide sufficient initial information, but biopsy is generally mandatory [89]. Examples of MALT (fig. 10.1–10.3), follicular and high-grade (fig. 10.4, 10.5) lymphomas are illustrated.

10.3. Diagnostic Accuracy

One hundred and thirty cytologically diagnosed and histology-correlated cases have been reported (table 10.1), with more than 12.4% of false-negative diagnoses.

10.4. Differential Diagnosis

The most important differential diagnosis of MALT lymphoma is BLEL. Although the presence of monocytoid B cells is highly suggestive of a diagnosis of MALT, it should be confirmed by immunocytochemistry or immunophenotyping, to determine whether the lymphocyte or plasma cell component expresses monotypic immunoglobulin, and by subsequent biopsy [148].

Follicular lymphoma is predominantly composed of centrocytes with rare centroblasts, which are typically bcl-2-positive and CD43-negative, and must be differentiated from Warthin's tumour.

High-grade lymphomas are rarely T-cell, lymphoblastic or Burkitt-like tumours and are mainly diffuse B-cell lymphomas (CD45- and CD20-positive), which should be differentiated by immunocytochemistry from other poorly-differentiated malignant tumours, especially lymphoepithelial carcinoma (keratin-positive) and melanoma (HMB-45-positive).

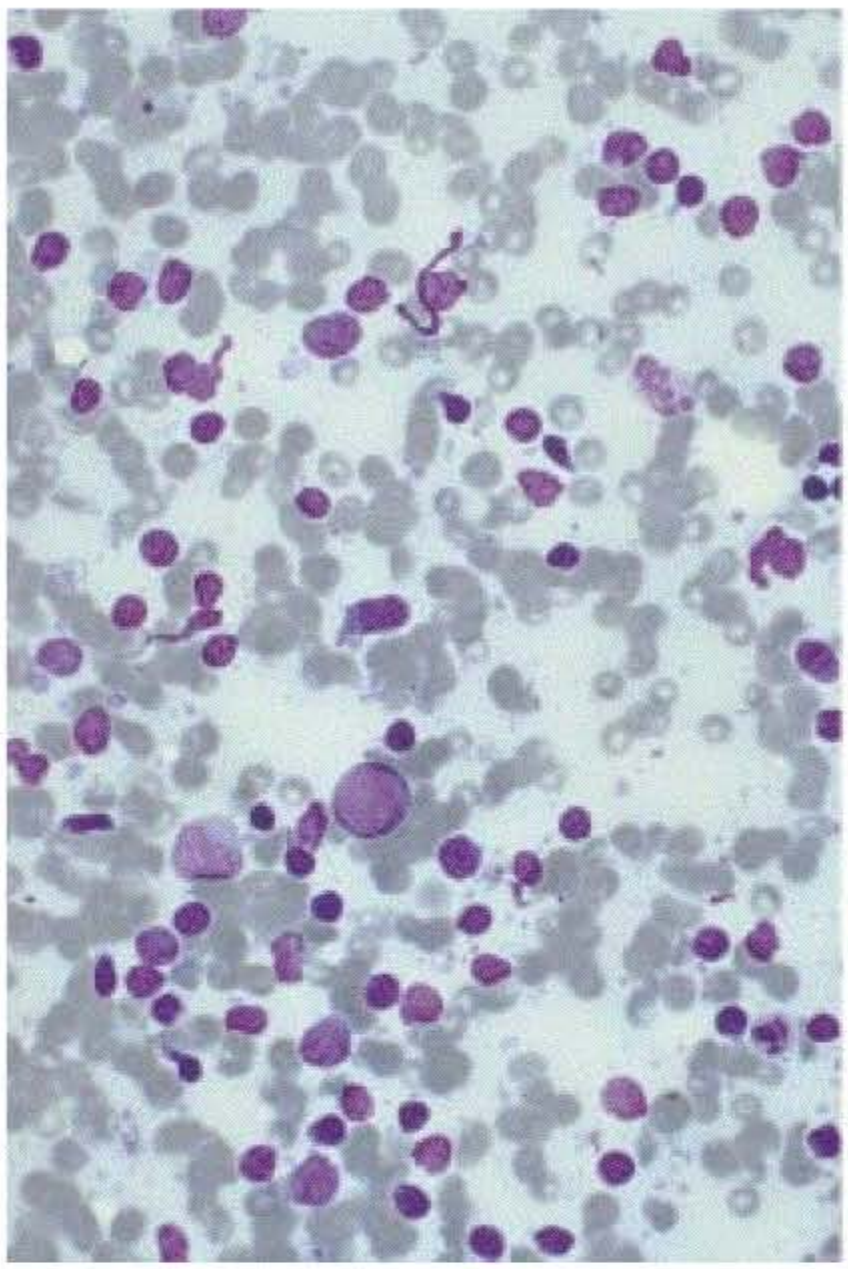

10.1

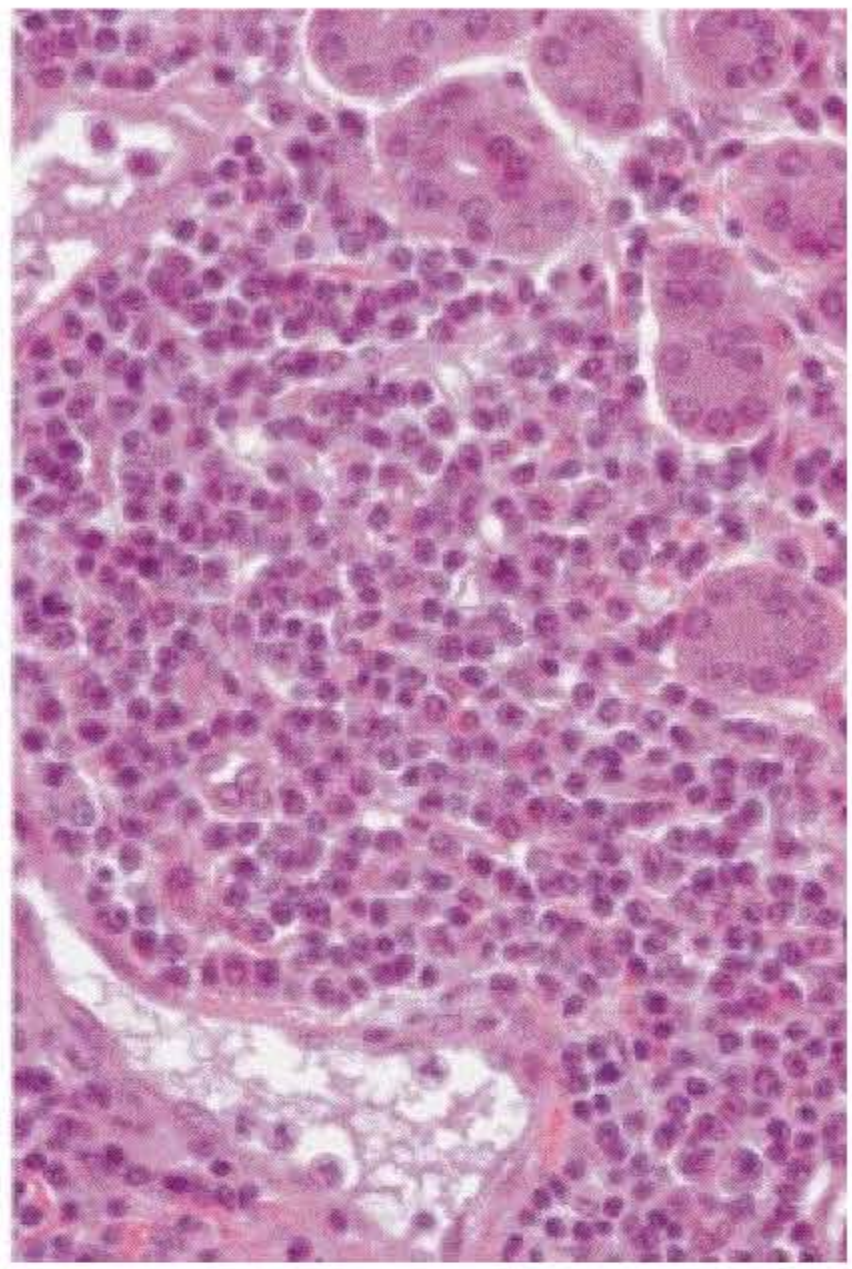

10.2

Table 10.1. Primary or secondary lymphomas including Hodgkin's lymphomas

Author [ref.]	Number	Malignant	Suspicious	False-negative	Unsatisfactory
Persson, Zettergren [270]	1	1	0	0	0
Kline et al. [201]	4	3	1	0	0
Qizilbash et al. [277]	2	0	0	2	0
O'Dwyer et al. [261]	6	3	0	3	0
Young et al. [351]	1	1	0	0	0
Kocjan et al. [204]	2	2	0	0	0
Smith Frable, Frable [313]	4	3	0	1	0
Abad et al. [1]	2	2	0	0	0
Weinberger et al. [341]	1	0	1	0	0
Zurrida et al. [350]	7	2	0	5	0
MacLeod, Frable [230]	9	8	0	1	0
Orell [263]	7	4	0	1	2
MacCallum et al. [229]	9	2	6	1	0
Cajulis et al. [41]	9	8	1	0	0
Cha et al. [47]	1	1	0	0	0
Al-Khafaji et al. [8]	10	10	0	0	0
Our series	62	58	1	3	0
Total	137	108 (78.8)	10 (7.3)	17 (12.4)	2 (1.5)

Statistics from the literature. % in parentheses.

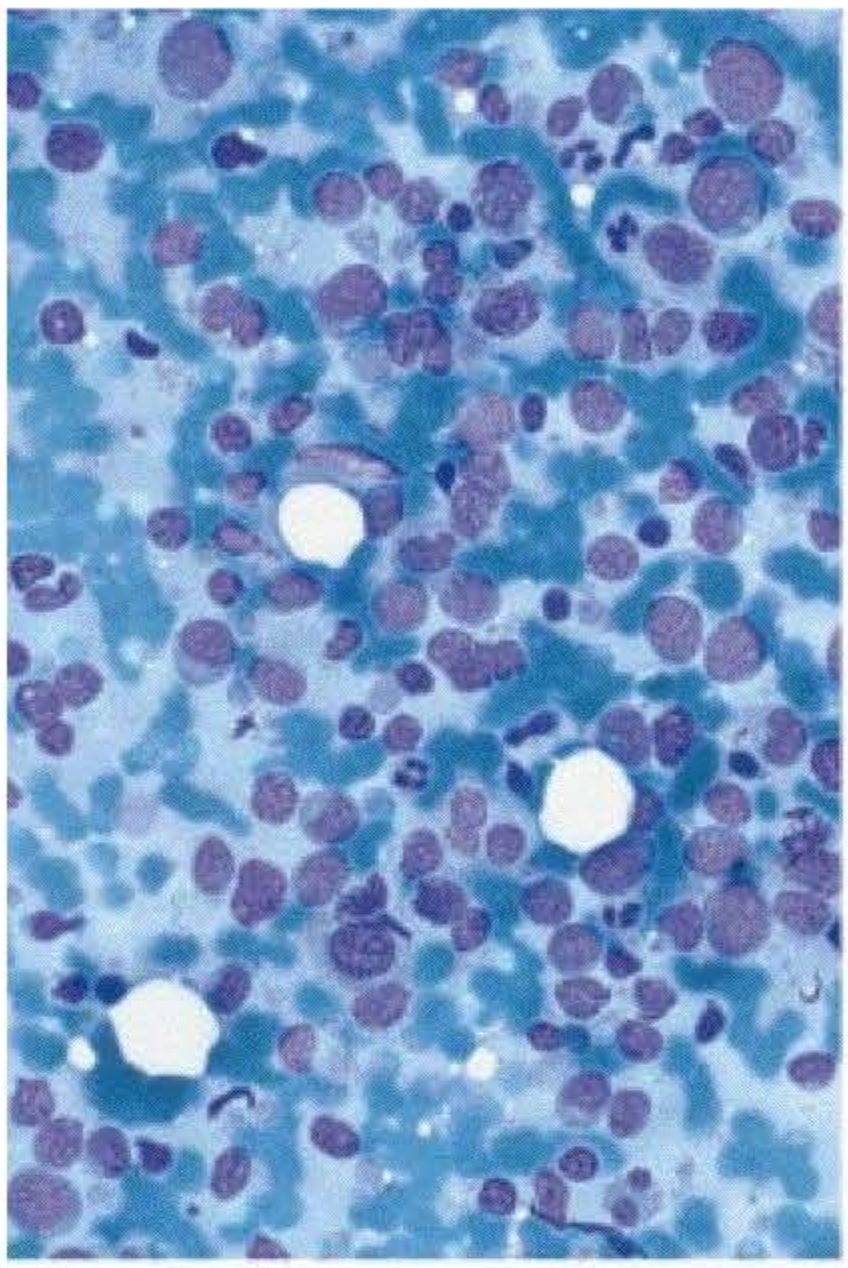

10.3

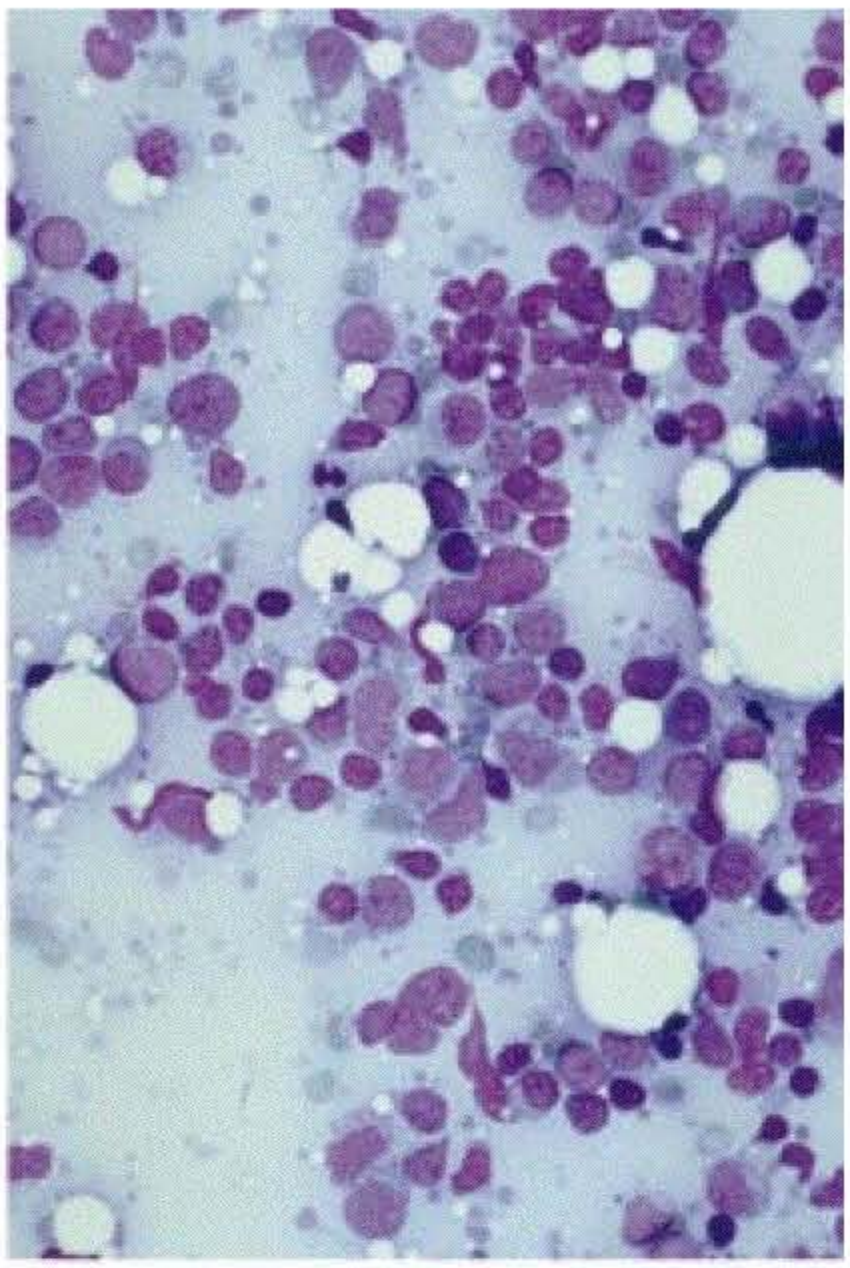

10.4

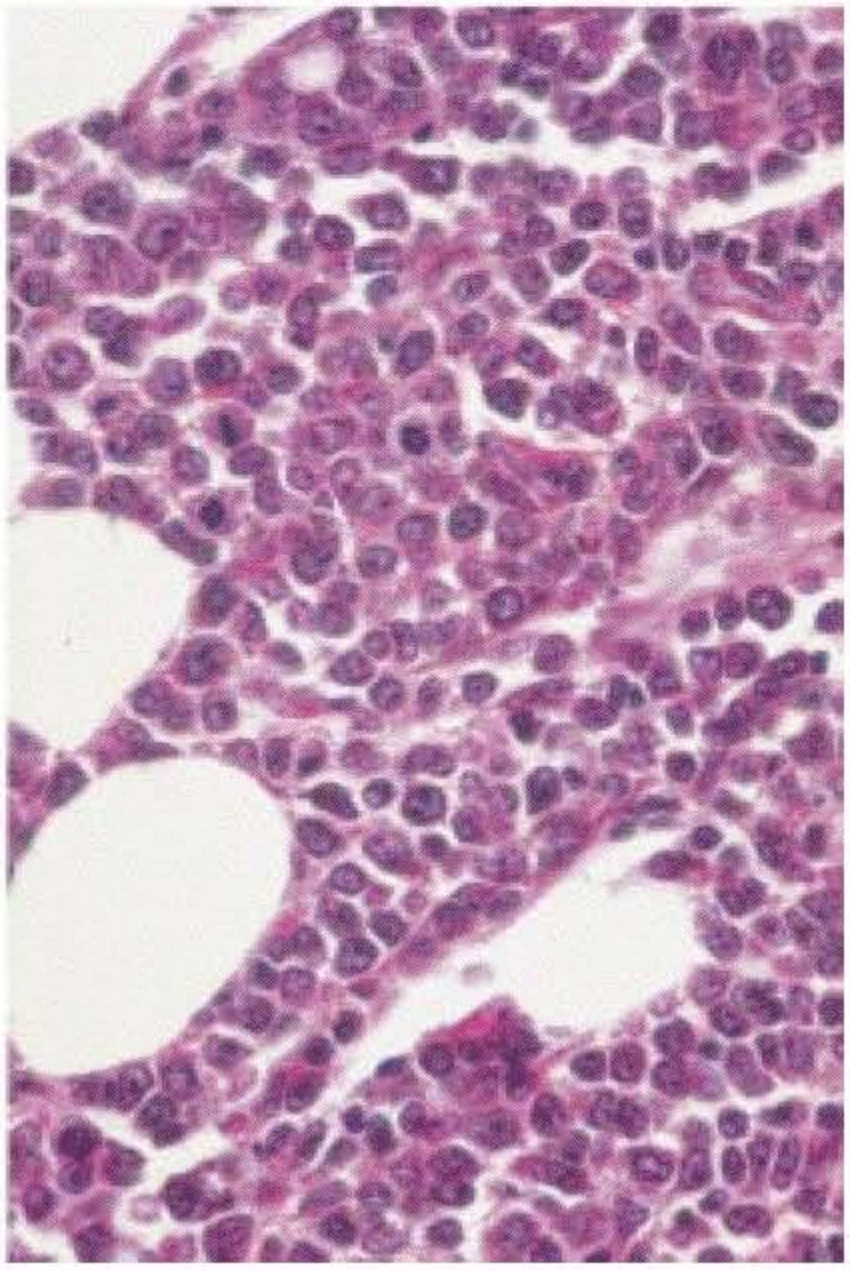

10.5

Fig. 10.1. MALT lymphoma composed of small lymphocytes. MGG. E128.
Fig. 10.2. MALT lymphoma. Histological sections corresponding to figure 10.1. HES. E128.
Fig. 10.3. Transformation of MALT lymphoma into high-grade lymphoma. Note the numerous blasts. MGG. E128.
Fig. 10.4. High-grade lymphoma. MGG. E128.
Fig. 10.5. High-grade lymphoma. Histological section corresponding to figure 10.4. HES. E128.

Secondary Tumours

The parotid gland contains lymph nodes which drain the skin of the head, posterior cheek, preauricular regions, lacrimal glands, eyelids, conjunctiva, and upper lip, etc. Similarly, the submandibular gland contains lymph nodes draining the major part of the oral cavity. Secondary tumours in major salivary glands are therefore common.

In the presence of a known primary, each salivary mass must be submitted to fine-needle sampling to confirm or exclude its secondary nature and to guide appropriate patient management [159].

11.1. General

In the AFIP series [89], secondary tumours accounted for 8.1% of all malignant salivary gland tumours, and they represent 23.4% of all malignant lesions sampled by fine-needle aspiration. Secondary tumours are more frequent between the fourth and sixth decades of life with a marked male predominance (3:1).

11.2. Histopathology and Cytopathology

Morphological types are strongly dependent on hospital patient recruitment. However, squamous cell carcinoma and melanoma seem to be the most frequent metastatic tumours, while breast carcinoma is less frequent.

Squamous cell carcinoma is easily identified cytologically, when it is composed of malignant squamous cells, keratin debris and necrosis. Similarly, pigmented, oval to round binucleated tumour cells with intranuclear inclusions are characteristic of melanoma (fig. 11.1–11.3). Metastatic breast carcinoma frequently presents as large isolated or clustered plasmacytoid cells with or without tumour necrosis (fig. 11.4, 11.5).

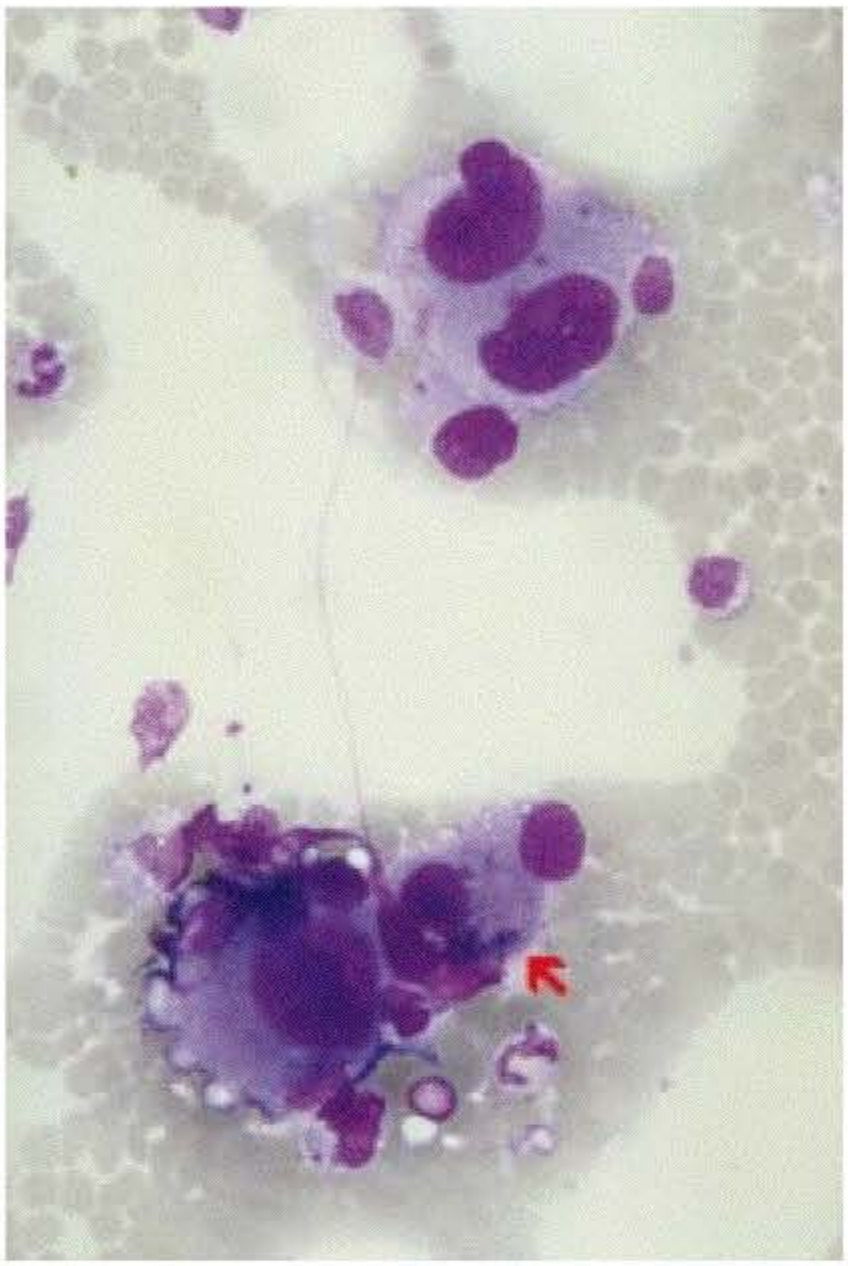

11.1

Fig. 11.1. Metastatic melanoma. A malignant cell showing intracytoplasmic pigment (arrow). MGG. ×128.

Fig. 11.2. Metastatic melanoma. Binucleated cells. Papanicolaou. ×128.

Fig. 11.3. Metastatic melanoma. Histological section corresponding to figure 11.2. HES. ×64.

Fig. 11.4. Metastatic breast carcinoma. Small clusters of adenocarcinomatous cells. Note the presence of acinar cells from the parotid gland. MGG. ×128.

Fig. 11.5. Metastatic breast carcinoma. Histological section corresponding to figure 11.4. HES. ×64.

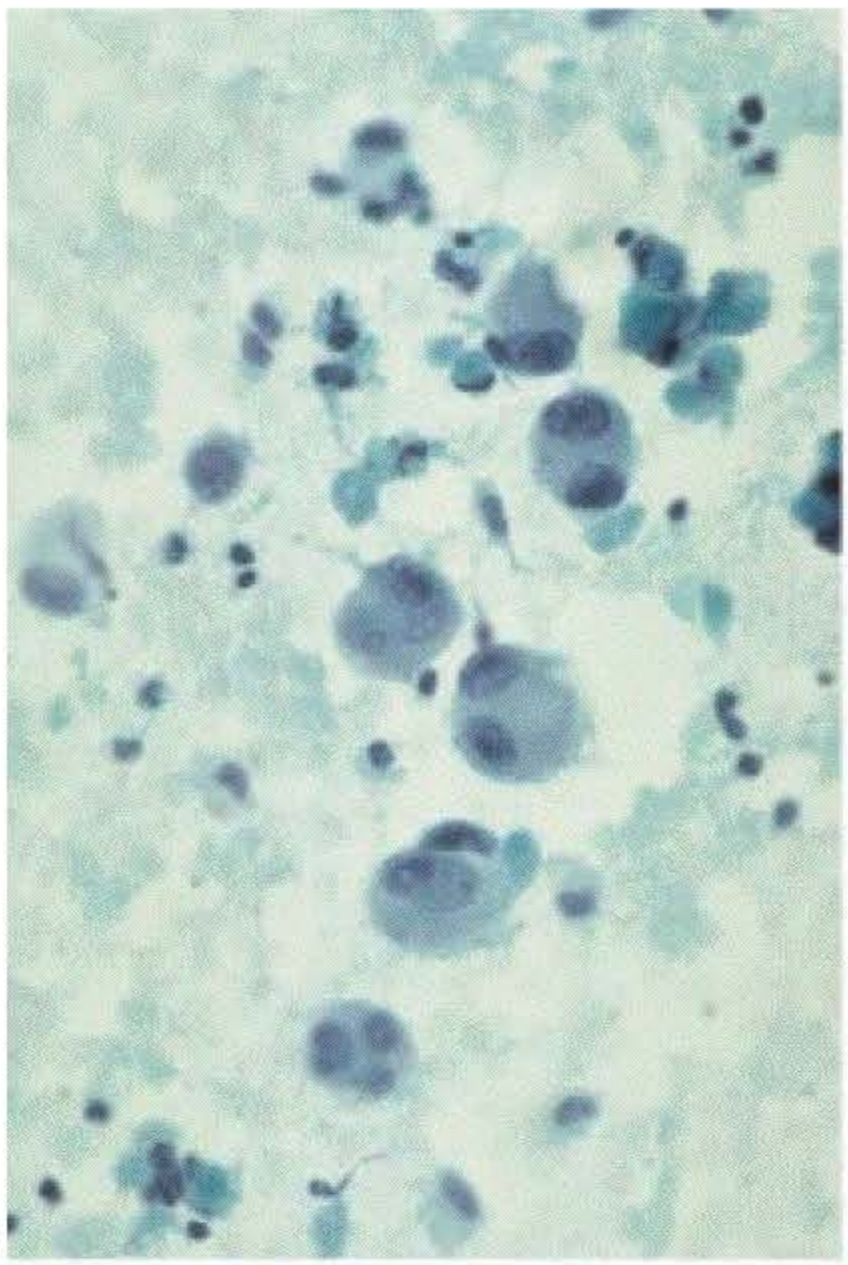

11.2

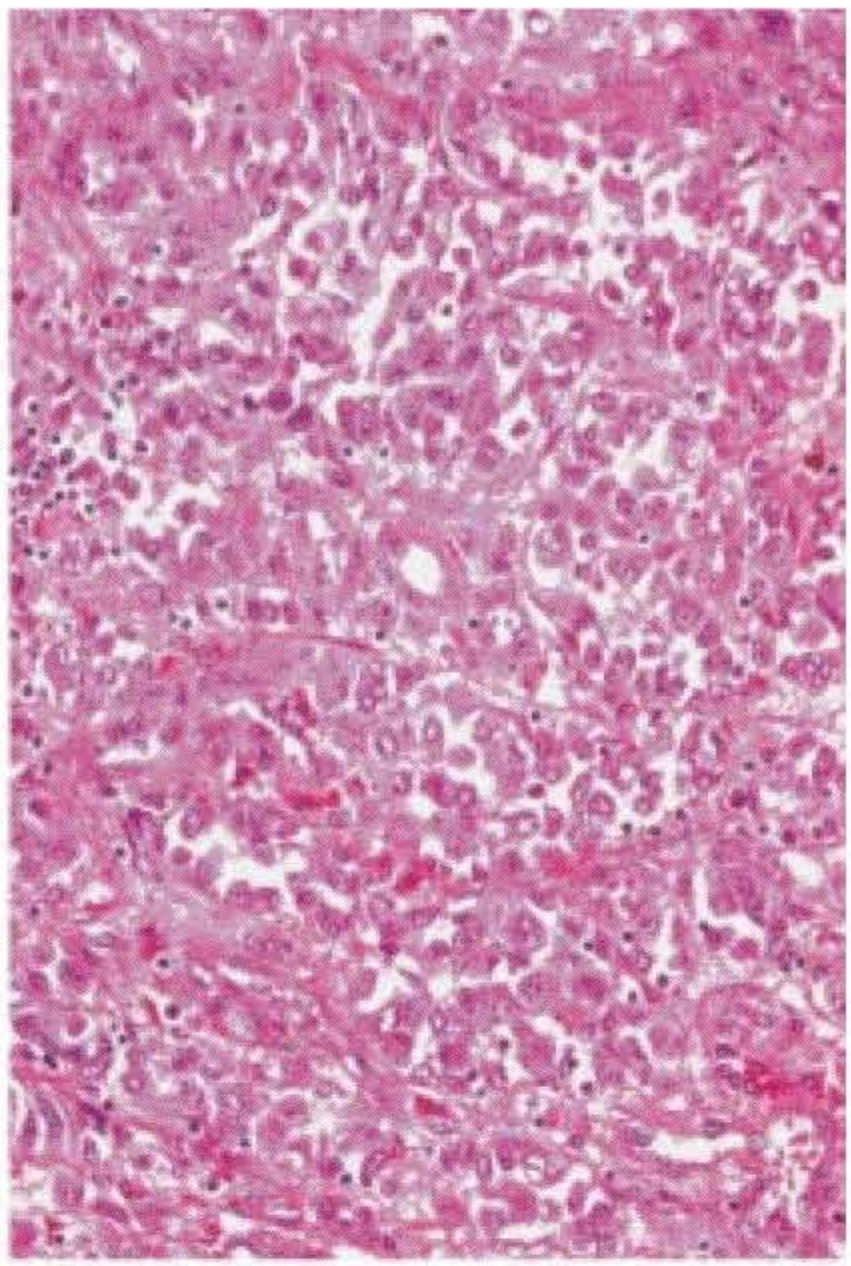

11.3

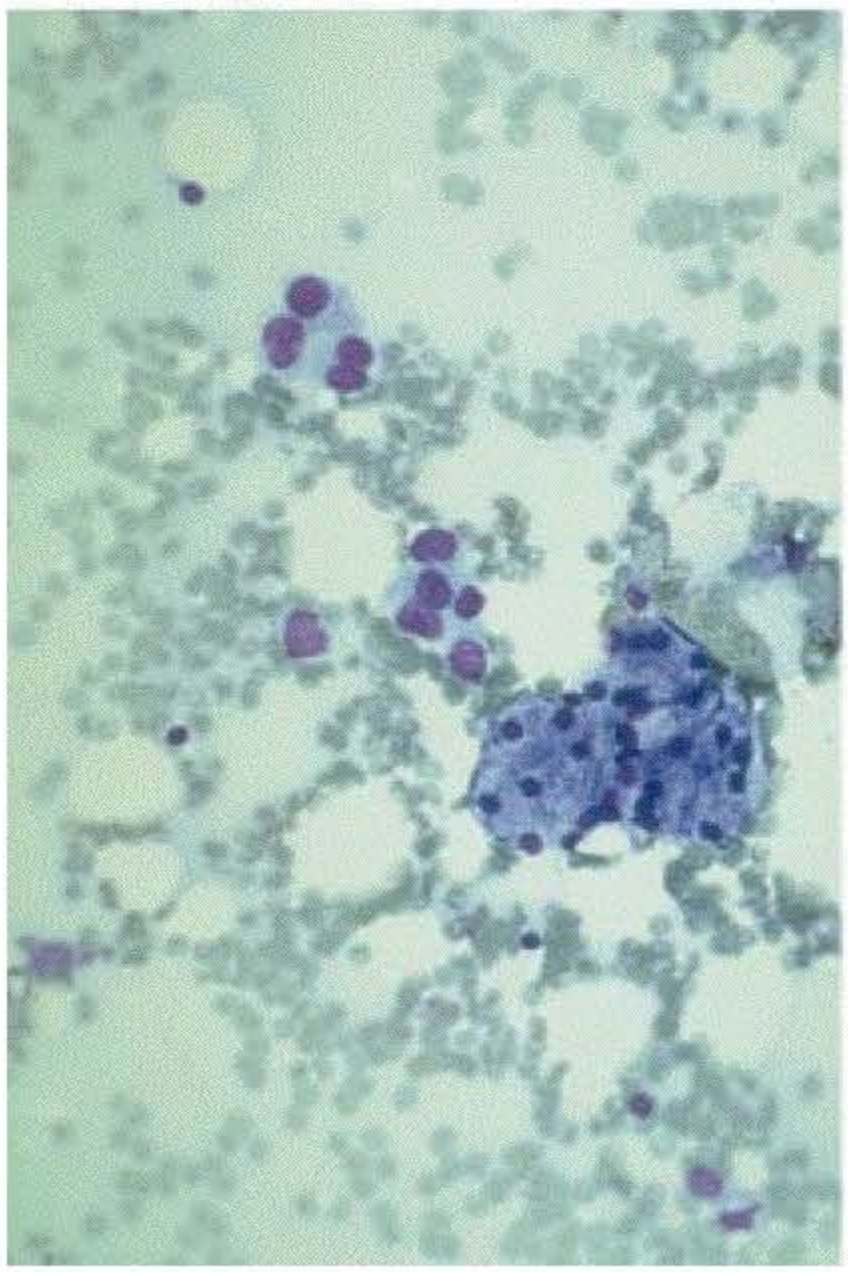

11.4

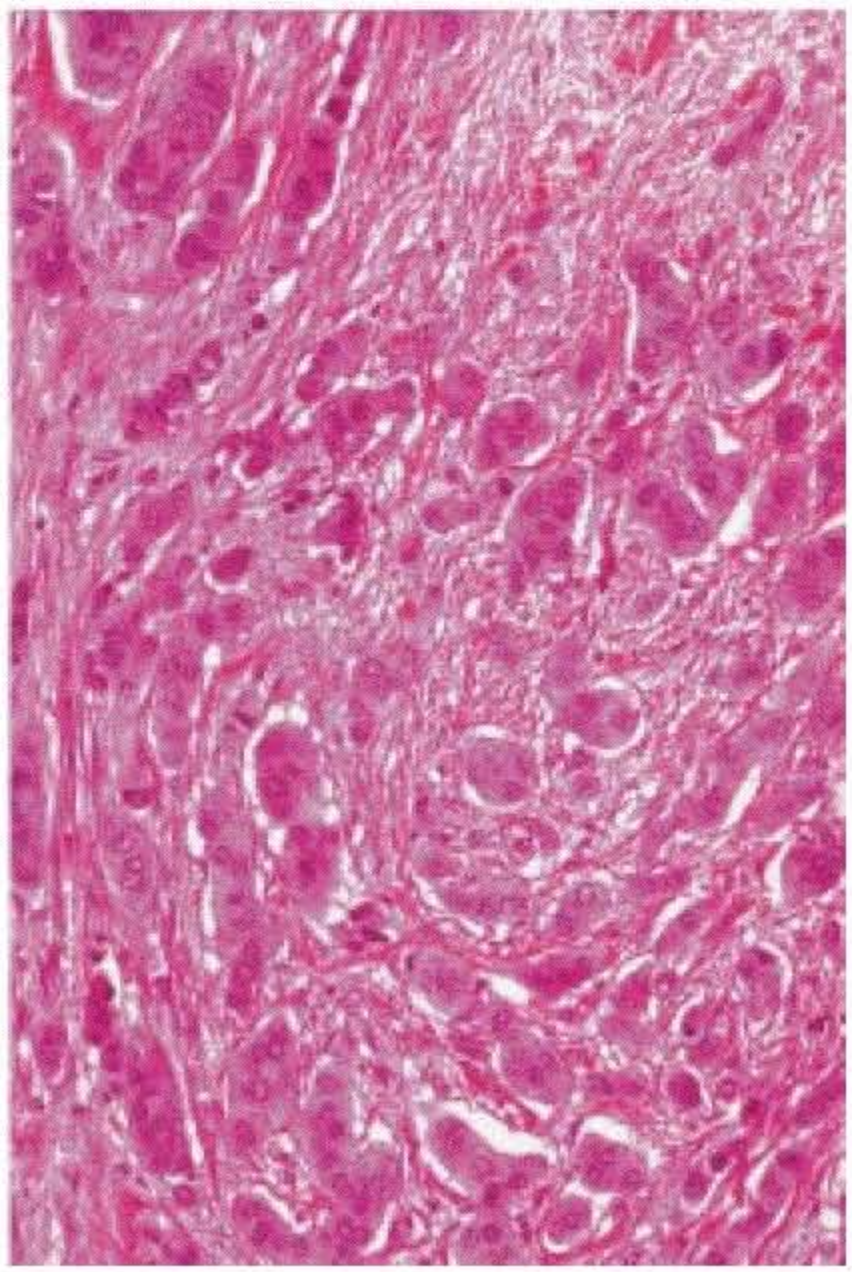

11.5

Table 11.1. Secondary tumours

Author [ref.]	Number	Malignant	Suspicious	False-negative	Unsatisfactory
Appaix et al. [10]	1	1	0	0	0
Mavec et al. [241]	13	13	0	0	0
Eneroth et al. [96]	23	23	0	0	0
Kline et al. [201]	5	4	1	0	0
Currens et al. [70]	1	1	0	0	0
Qizilbash et al. [277]	12	11	0	1	0
O'Dwyer et al. [261]	5	3	0	1	1
Gattuso et al. [122]	1	1	0	0	0
Gherardi et al. [124]	1	1	0	0	0
Kocjan et al. [204]	4	4	0	0	0
Smith Frable, Frable [313]	26	23	0	0	3
Layfield, Glasgow [216]	3	3	0	0	0
Abad et al. [1]	2	2	0	0	0
MacLeod, Frable [230]	21	18	0	0	3
Orell [263]	7	6	0	0	1
Stanley et al. [318]	9	8	1	0	0
Cajulis et al. [41]	1	1	0	0	0
Cristallini et al. [68]	3	3	0	0	0
Stanley et al. [319]	3	2	0	1	0
Mandreker et al. [235]	1	1	0	0	0
Dargent et al. [77]	1	1	0	0	0
Malata et al. [233]	11	11	0	0	0
Al-Khafaji et al. [8]	3	0	1	2	0
Horii et al. [159]	5	4	0	0	1
Sgrignoli et al. [304]	1	1	0	0	0
Our series	144	141	2	1	0
Total	307	287 (93.5)	5 (1.6)	6 (2)	9 (2.9)

Statistics from the literature. % in parentheses.

11.3. Diagnostic Accuracy

A critical review of the literature is difficult, as very few patients with secondary tumours are treated surgically. However, almost 95% of secondary tumours appeared to be diagnosed or suspected cytologically (table 11.1).

11.4. Differential Diagnosis

The diagnosis of metastatic tumours can be challenging when the primary tumour is unknown. In this setting, clinical and radiological findings [185] and immunocytochemistry using a panel of antibodies are crucial for the definitive diagnosis, as some primary salivary gland malignancies, such as salivary duct carcinoma, lymphoepithelial carcinoma, amelanotic melanoma and small-cell carcinoma, may mimic metastases from other sites.

Secondary Tumours

In favour of the diagnosis

History of cancer, unusual morphology for salivary primary, disseminated metastatic disease

Difficulties

Salivary metastasis preceding the primary in another site

Against the diagnosis

Lack of evidence of a primary in another site

Chapter 12

Tumour-Like Lesions

Cytology may rule out neoplasm and therefore allow a more conservative treatment. Unfortunately, many cases of tumour-like lesions are overdiagnosed, especially salivary cysts and Küttner's tumours.

12.1. Sialadenosis

12.1.1. General

Sialadenosis is a rare noninflammatory lesion, secondary to secretory dysfunction or metabolic factors [301]. Sialadenosis is typically associated with systemic diseases, such as diabetes mellitus, thyroid insufficiency, alcoholism, and sex hormone changes. Enlargement of the parotid glands is characteristically slow, painless, recurrent and often bilateral.

12.1.2. Histopathology

The diameter of acinar cells is larger than that of normal cells. Fat atrophy is common [89].

12.1.3. Cytopathology

Smears are richly cellular and composed of tightly packed aggregates of acini with well-preserved architecture and naked nuclei. Adipocytes are numerous. Inflammatory cells are rare [12, 144] (fig. 12.1).

12.1.4. Diagnostic Accuracy

A limited number of cases with cytology have been reported (table 12.1).

12.1.5. Differential Diagnosis

Cytology of sialadenosis is distinctive and sufficiently characteristic to allow correct diagnosis. The only differential diagnosis is well-differentiated acinic cell carcinoma. The abundance of acinic cells, the absence of adipocytes, and the presence of numerous naked nuclei and blood vessels [193] are in favour of well-differentiated acinic cell carcinoma (fig. 8.12).

Table 12.1. Correlation between cytology and histology in sialadenosis

Author [ref.]	Number	Benign	Suspicious and false-positive	Unsatisfactory
Layfield et al. [216]	1	1	0	0
Ascoli et al. [12]	4	4	0	0
Henry-Stanley al. [154]	2	2	0	0
Gupta, Sodhani [144]	4	4	0	0
Our series	19	19	0	0
Total	30	30	0	0

Statistics from the literature.

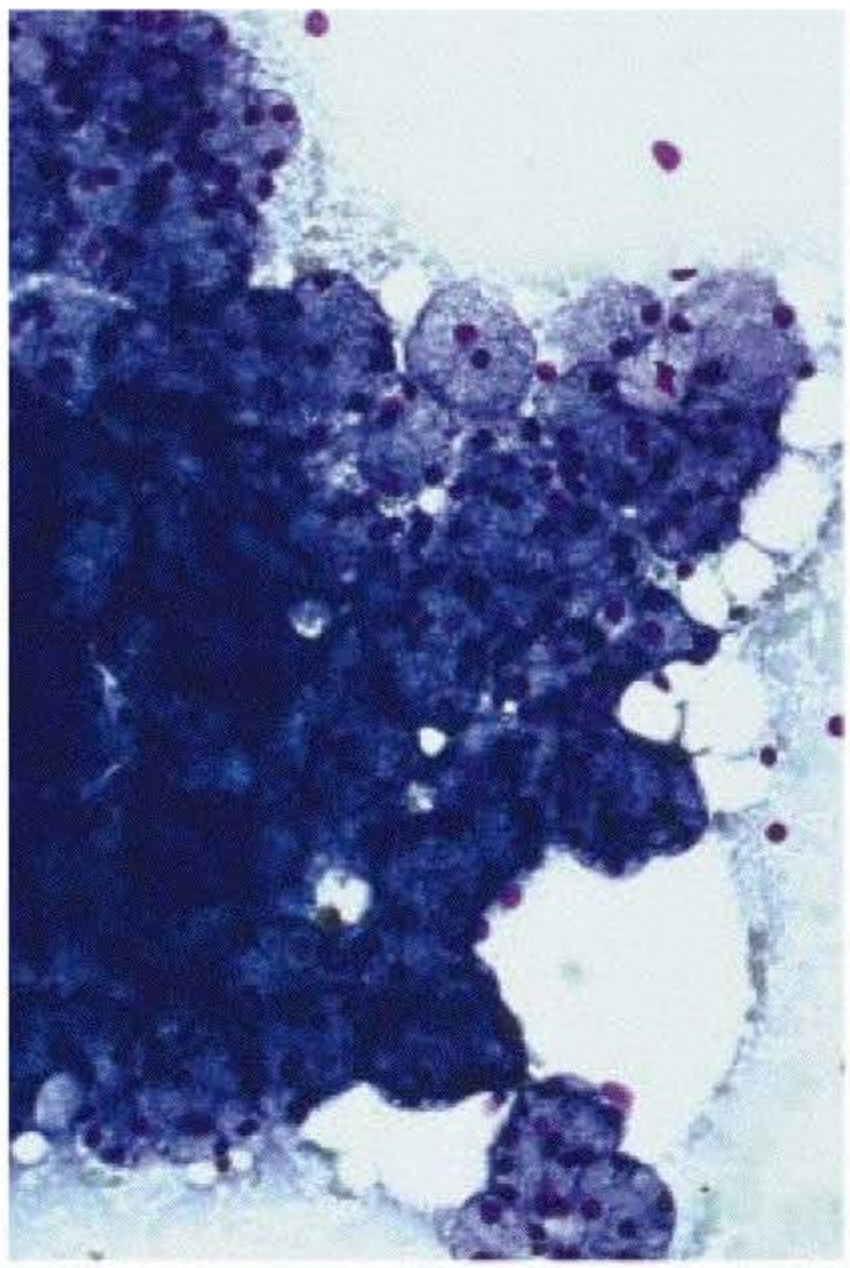

12.1

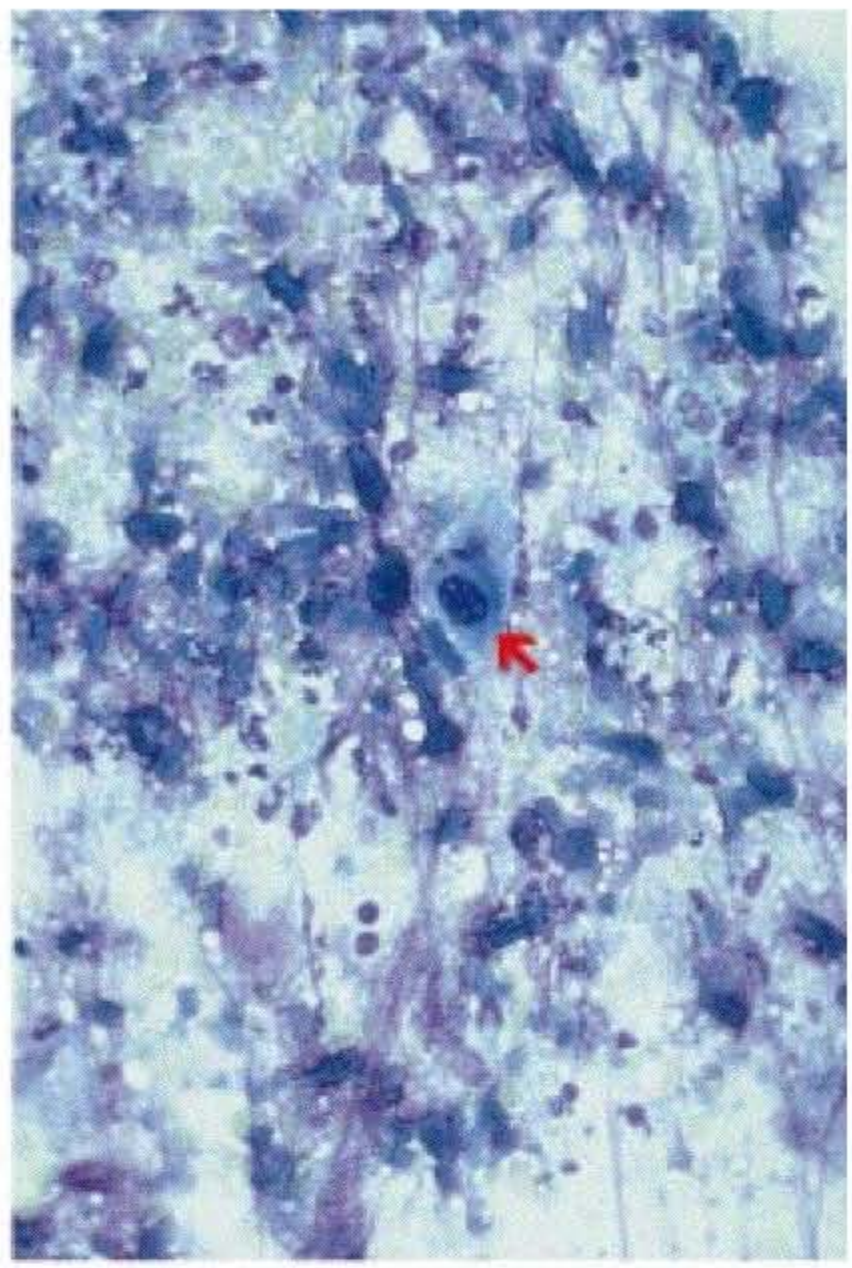

12.2

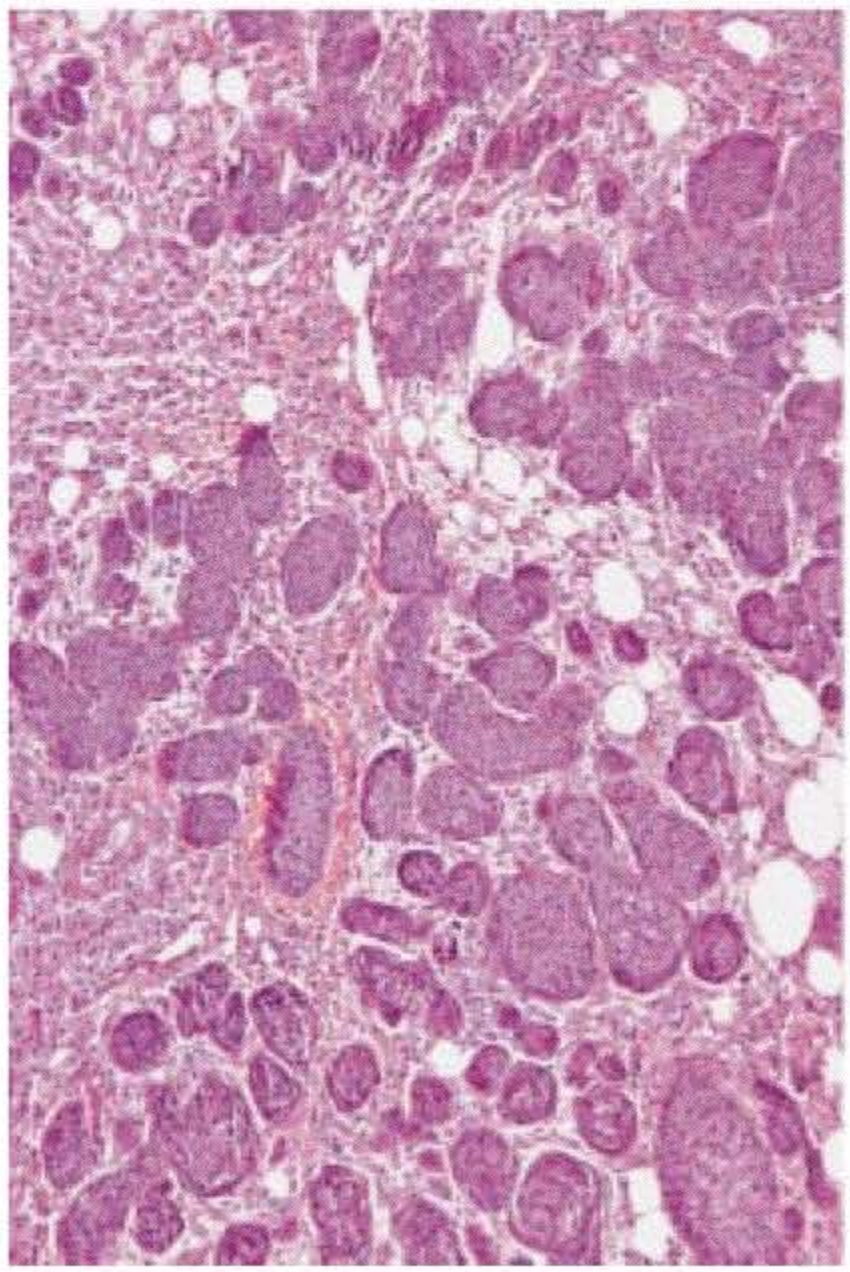

12.3

Fig. 12.1. Sialadenosis. Tightly packed aggregates of acinic cells with well-preserved microarchitecture and naked nuclei. MGG. ×128.

Fig. 12.2. Necrotizing sialometaplasia. Inflammatory necrosis and scattered squamous cells (arrow) with prominent atypia and coarse chromatin related to regeneration. MGG. ×128.

Fig. 12.3. Necrotizing sialometaplasia. Histological section corresponding to figure 12.2. HES. ×32.

Sialadenosis

In favour of the diagnosis

Cohesive acinar cells, naked nuclei, adipocytes, no inflammatory cells, systemic disease, bilateral lesions

Difficulties

Only adipocytes

Against the diagnosis

Numerous isolated cells, atypia, blood vessels

12.2. Necrotizing Sialometaplasia

Necrotizing sialometaplasia is a benign, inflammatory, necrotizing condition of salivary glands, probably related to ischaemic or traumatic aetiologies.

12.2.1. Incidence

Necrotizing sialometaplasia is predominantly located on the palate, but other head and neck mucosal and parotid gland sites have been reported [24, 37]. The majority of extrapalatal cases are related to previous trauma or radiotherapy.

12.2.2. Histopathology

Necrotizing sialometaplasia presents as an ulcerative and necrotic mass with metaplastic lobules containing squamous cells. Inflammatory cells are present [89].

12.2.3. Cytopathology

Smears of necrotizing sialometaplasia are composed of inflammatory necrosis and scattered squamous cells (fig. 12.2, 12.3). Several cells may show prominent atypia and coarse chromatin related to metaplasia and may therefore be suggestive of malignancy.

12.2.4. Diagnostic Accuracy

No cytological reports were found in the literature. We have seen 3 cases (2 involving the palate and 1 involving the parotid gland). All lesions were accurately diagnosed.

12.2.5. Differential Diagnosis

This lesion may be difficult to differentiate from squamous cell carcinoma, mucoepidermoid carcinoma and Warthin's tumour.

12.2.5.1. Necrotizing Sialometaplasia vs. Squamous Cell and Mucoepidermoid Carcinomas

The presence of squamous cells with a necrotic background in necrotizing sialometaplasia may mimic carcinomas with squamous cells (fig. 12.2). Keratin debris and marked nuclear atypia are in favour of squamous cell carcinoma (fig. 7.15, 7.16); mucus-secreting and intermediate cells are in favour of mucoepidermoid carcinoma (fig. 7.1).

12.2.5.2. Necrotizing Sialometaplasia vs. Warthin's Tumour

The presence of oncocytes, despite squamous cells and necrosis, is in favour of Warthin's tumour (fig. 6.22).

Necrotizing Sialometaplasia

In favour of the diagnosis

Necrosis, squamous cells, palatal site, traumatic aetiology

Difficulties

Extrapalatal sites, extensive necrosis, atypical squamous cells

Against the diagnosis

Keratin debris, atypia, mucus-secreting and intermediate cells, oncocytes

12.3. Lymphoepithelial Lesions

12.3.1. General

Reactive lymphoid proliferations of the salivary glands include benign lymphoepithelial lesion (BLEL) of Sjögren's syndrome, also called lymphoepithelial sialadenitis (LESA) or myoepithelial sialadenitis (MESA), and cystic lymphoid hyperplasia.

12.3.2. Histopathology

Benign lymphoepithelial lesion, described by Mikulicz in 1892, is characterized by a lymphoid infiltrate with follicular hyperplasia, surrounding and infiltrating the salivary ducts, with disorganization and proliferation of the ductal epithelial cells to form lymphoepithelial lesions [27, 148].

Cystic lymphoid hyperplasia is either unilocular or multilocular and varies in size from 0.5 to 2 cm in diameter. It is commonly seen in patients with HIV infection or AIDS [156, 291, 312, 327, 331]. Cysts are lined by squamous epithelium surrounded by dense lymphoid tissue, which may contain germinal centres with interspersed mitotic figures and foreign body multinucleated cells [89].

12.3.3. Cytopathology

Smears of lymphoepithelial lesions show numerous noncleaved and cleaved lymphocytes [46, 327]. Immunoblasts may be prominent with strongly basophilic (MGG) cytoplasm, but epithelial cells are rarely seen (fig. 12.4, 12.5).

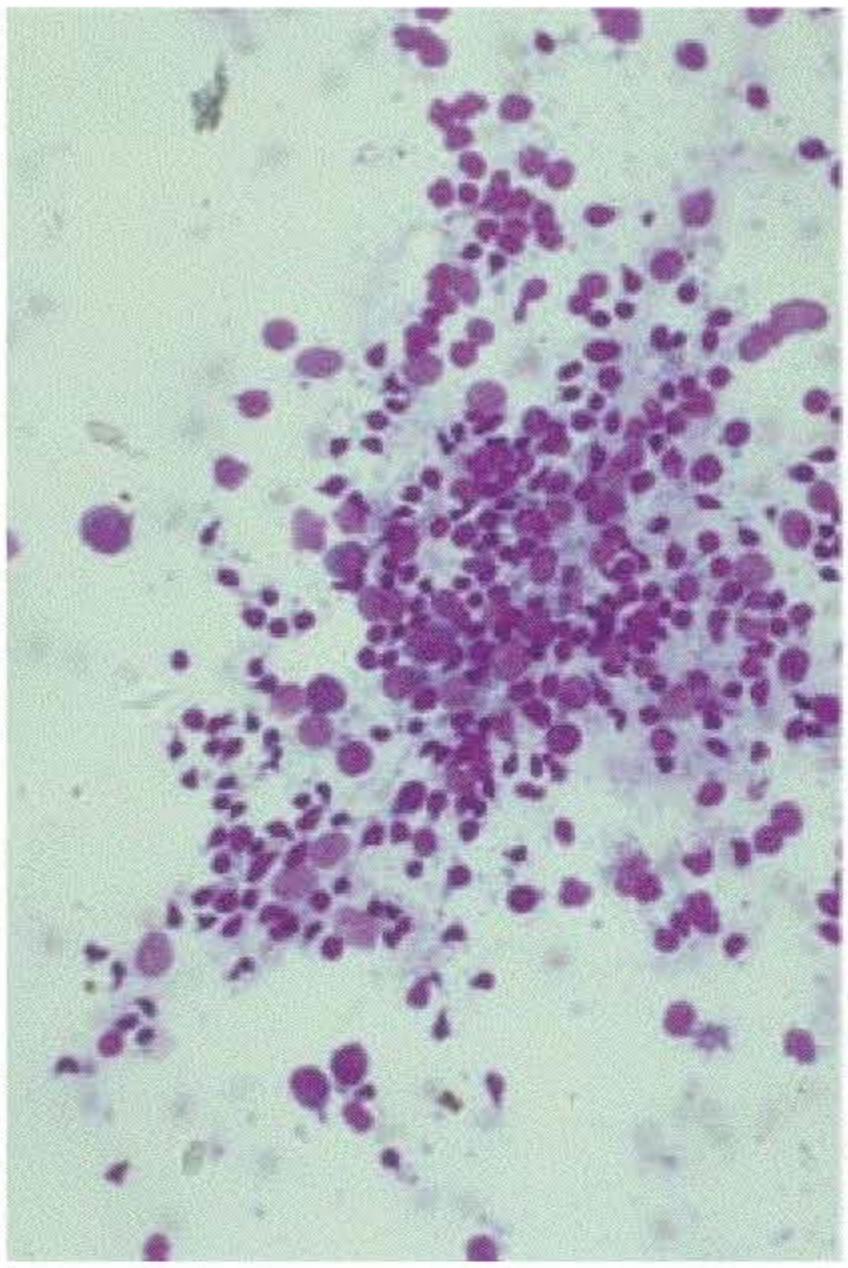

12.4

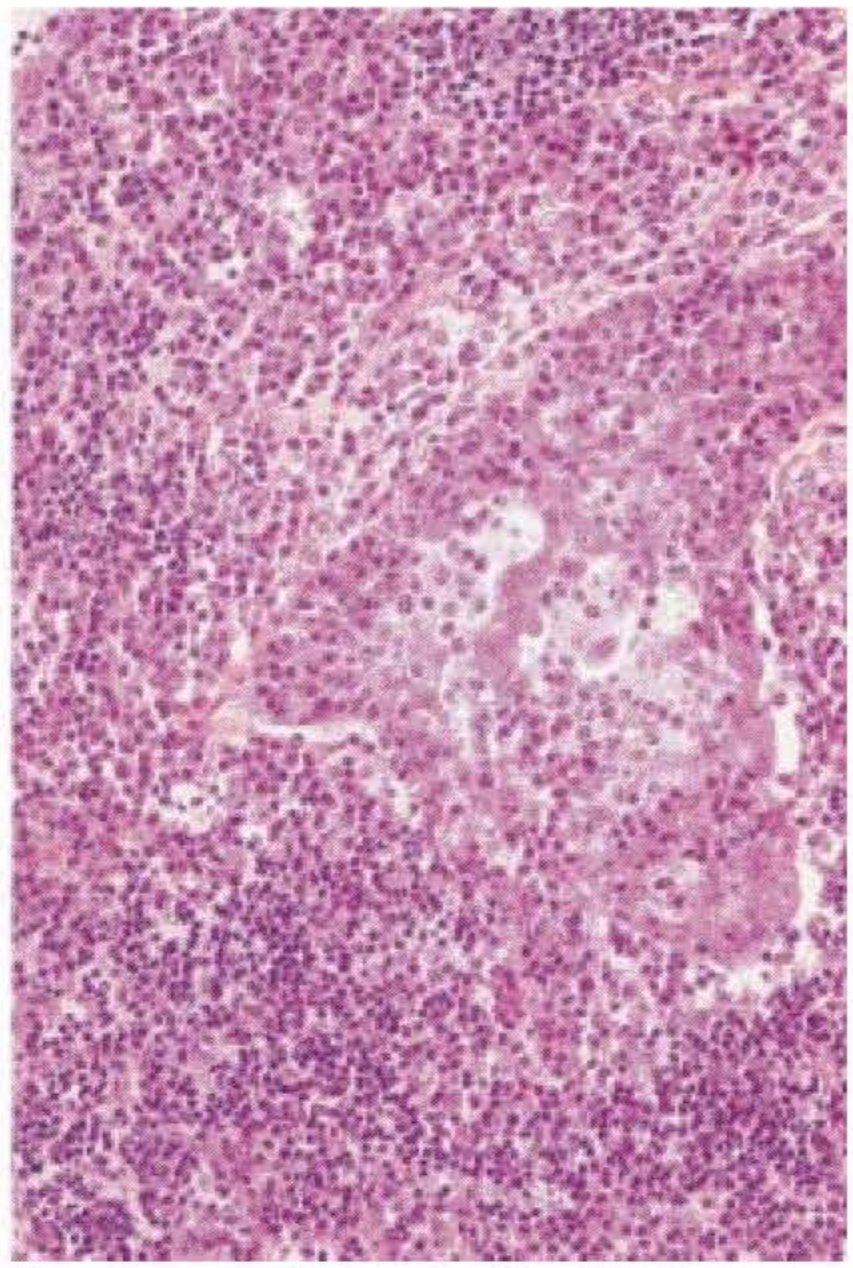

12.5

Fig. 12.4. Benign lymphoepithelial lesion. Numerous lymphocytes with poorly-preserved epithelial cells. MGG. E128.
Fig. 12.5. Benign lymphoepithelial lesion. Histological section corresponding to figure 12.4. HES. E32.

Table 12.2. Correlation between cytology and histology in lymphoepithelial lesions

Author [ref.]	Number	Benign	Suspicious and false-positive	Unsatisfactory
Persson, Zettergren [270]	4	4	0	0
Qizilbash et al. [277]	3	3	0	0
O'Dwyer et al. [261]	5	5	0	0
Finfer et al. [110]	8	7	0	1
Elliott, Oertel [88]	2	2	0	0
Casiano et al. [46]	14	14	0	0
Tao et al. [327]	2	2	0	0
Günhan et al. [141]	1	1	0	0
Weinberger et al. [341]	1	1	0	0
MacLeod, Frable [230]	1	1	0	0
Al-Khafaji et al. [8]	2	0	1	1
López-Ríos et al. [224]	2	2	0	0
Our series	6	6	0	0
Total	51	49 (96)	1 (2)	1 (2)

Statistics from the literature. % in parentheses.

Smears of cystic lymphoid hyperplasia have a clear background with an admixture of numerous small and large lymphocytes. Active macrophages, immunoblasts, anuclear squames, and cholesterol crystals may also be noted. Oncocytes are absent.

12.3.4. Diagnostic Accuracy

Cytology allows accurate diagnosis in most cases (table 12.2).

12.3.5. Differential Diagnosis

Cytologically, lymphoepithelial lesions must be differentiated from reactive lymphadenitis, in which smears are composed of lymphocytes and squamous cells are absent, and MALT lymphoma (see chapter 10.4). The differential diagnosis with branchial cleft cyst is impossible when aspirates are cystic, and squamous or columnar cells are absent.

Lymphoepithelial Lesions

In favour of the diagnosis

Polymorphous lymphocytes and squamous metaplastic cells, parotid site, cystic fluid containing lymphocytes and squamous cells, HIV seropositivity

Difficulties

Absence of squamous cells, hyperplastic lymph node, MALT lymphoma

Against the diagnosis

Atypical squamous cells, mucus-secreting cells, columnar cells, extraparotid sites

12.4. Salivary Gland Cysts

Non-neoplastic cysts are mainly mucoceles and salivary duct cysts. However, some salivary gland neoplasms, such as pleomorphic adenoma, Warthin's tumour, mucoepidermoid carcinoma, low-grade, papillary cystadenocarcinoma, and metastatic squamous cell carcinoma, may be cystic [244].

12.4.1. General

Non-neoplastic cysts are quite uncommon and represent 2–5% of all salivary gland lesions [64, 272, 286]. Mucoceles are either extravasated cysts (lip) or retention cysts in the minor salivary glands (75%), whereas salivary duct cysts mainly occur in the parotid gland and represent 10% of all salivary gland cysts [300].

Polycystic disease is very rare, and lymphoepithelial cystic lesions, sometimes related to HIV infection, are discussed in chapter 8.3.

12.4.2. Histopathology

Extravasated mucoceles (pseudocysts) contain mucus with macrophages and foreign body giant cells, whereas retention cysts present a lining epithelium with mucus and sometimes spherolites or microlites [300]. Salivary duct cysts are similar to retention cysts.

12.4.3. Cytopathology

Fine-needle sampling may lead to disappearance of the lesion. Smears are composed of a watery or mucoid fluid with occasional inflammatory and necrotic epithelial cells [35, 167, 168, 317]. Oncocytes, squamous cells, ciliated cells, crystalloids and stones may also be present (fig. 12.6, 12.7).

12.4.4. Diagnostic Accuracy

Histological correlations are rare (table 12.3). False-positive diagnoses due to mucoid substance and squamous cells have been reported [168, 270, 317]. In our series of 58 salivary cysts, in which only 18 lesions subsequently underwent surgery, all cases were accurately diagnosed cytologically.

From a practical point of view, all cystic salivary tumours should be at least followed clinically, and when possible, examined ultrasonographically [86].

12.4.5. Differential Diagnosis

The differentiation between salivary cysts and non-neoplastic lymphoid proliferation is described in paragraph 12.3.5. Salivary cysts should be differentiated from axial congenital lesions such as thyroglossal duct cyst, axial thymus, dermoid and epidermoid cysts, and branchial cleft cyst when it is located laterally. The main differential diagnostic difficulties are low-grade mucoepidermoid carcinoma, cystic squamous cell carcinoma and Warthin's tumour [80, 317] (table 12.4).

12.4.5.1. Salivary Cyst vs. Low-Grade Mucoepidermoid Carcinoma

Like salivary cysts, low-grade mucoepidermoid carcinoma may yield cystic mucoid fluid (fig. 8.3). Squamous cells and histiocytes may also mimic intermediate cells and mucus-secreting cells, respectively (fig. 8.4). This difficulty is complicated by the fact that inflammatory cells are present in both cysts and low-grade mucoepidermoid carcinoma. Inversely, crystalloids and stones (fig. 12.6) are extremely rare in mucoepidermoid carcinoma.

12.6

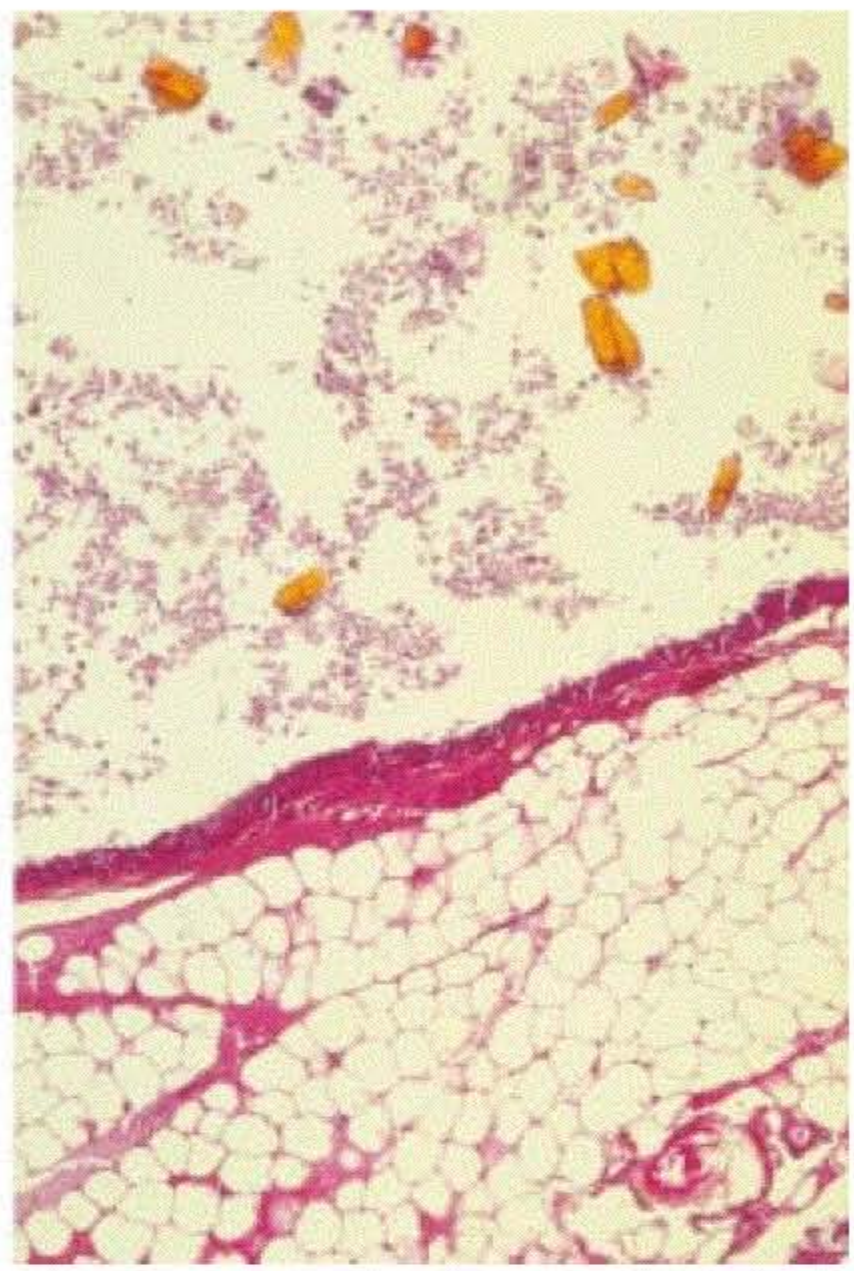

12.7

Fig. 12.6. Salivary cyst. Necrotic-like fluid containing inflammatory and dystrophic epithelial cells, and crystalloids. MGG. ×128.
Fig. 12.7. Salivary cyst. Histological section corresponding to figure 12.6. Note the presence of yellowish crystalloids. HES. ×32.

Table 12.3. Correlation between cytology and histology in salivary cysts of various aetiologies

Author [ref.]	Number	Benign	Suspicious and false-positive	Unsatisfactory
Mavec et al. [241]	7	6	0	1
Persson, Zettergren [270]	4	3	1	0
Dejmek et al. [80]	1	1	0	0
Weinberger et al. [341]	1	1	0	0
Zurrida et al. [358]	11	8	0	3
Carson et al. [45]	2	2	0	0
Stanley et al. [317]	4	2	2	0
Jayaram et al. [168]	1	0	1	0
Boudousquie, Baloch [35]	1	1	0	0
Our series	18	18	0	0
Total	50	42 (84)	4 (3)	4 (3)

Statistics from the literature. % in parentheses.

Table 12.4. Quantitative differential diagnosis of salivary cysts

Component	Salivary cyst	Mucoepidermoid carcinoma, low-grade	Squamous cell carcinoma	Warthin's tumour
Stroma				
Cystic	++	+	+	+
Mucoid	+	++		+/–
Necrotic	+	+	++	++
Inflammatory	+/–	+	++	++
Cells				
Mast cells	–	+/–	–	+
Squamous	+/–	+	++	+/–
Intermediate	–	+	–	–
Mucus-secreting	+/–	++	–	+/–
Oncocytes	+/–	+/–	–	++

++ = Common; + = rare; +/– = occasionally seen; – = absent.

We suggest that cystic tumours with no suspicious morphological features on cytology and which are totally drained by fine-needle sampling should be diagnosed as benign cysts. In contrast, when the lesion is incompletely drained, the patient should be referred for ultrasound-guided fine-needle sampling or surgery with intraoperative frozen section examination or be closely followed clinically and radiologically.

12.4.5.2. Salivary Cyst vs. Squamous Cell Carcinoma

Squamous cell carcinoma frequently yields clear or yellowish fluid. Cytologically, numerous squamous carcinoma cells and keratin debris are present, but oncocytes are absent.

12.4.5.3. Salivary Cyst vs. Warthin's Tumour

A cystic component, squamous cells, inflammatory cells and scattered oncocytes may lead to a false diagnosis of Warthin's tumour (fig. 6.24). Typical Warthin's tumour contains numerous oncocytes, often clustered, and may also contain mast cells intermixed with lymphocytes.

Salivary Cysts

In favour of the diagnosis

Cystic fluid containing lymphocytes and squamous and/or ciliated cells

Difficulties

Dense mucoid fluid, histiocytes resembling mucus-secreting cells

Against the diagnosis

Squamous atypical cells, mast cells, axial site

12.5. Küttner's Tumour (Chronic Sclerosing Sialadenitis)

12.5.1. General

Küttner's tumour is the result of a chronic inflammatory process resulting in a firm, stone-like lesion [301, 302]. The submandibular gland is the commonest site. Sialolithiasis, radiotherapy, disorders of saliva secretion and immune reactions are aetiological conditions implicated in the pathogenesis. Küttner's tumour may clinically simulate neoplasia. There is a slight predilection for males, the mean age ranges between 40 and 50 years.

12.5.2. Histopathology

Four different pathological forms may be distinguished based on the relative participation of lymphocytic infiltration, atrophy, regenerative and metaplastic changes and fibrosis [302].

12.5.3. Cytopathology

Smears are stroma-rich and characterized by a mucoid background and connective tissue fragments [13, 117, 305]. Variable amounts of inflammatory cells, necrosis and keratin debris are observed. Squamous metaplasia may appear atypical. Branching clusters of ductal cells are frequently seen. Psammoma bodies [117] have been described (fig. 12.8, 12.9).

12.5.4. Diagnostic Accuracy

Numerous studies have reported the problems of differential diagnosis (table 12.5). Küttner's tumour is relatively frequently overdiagnosed as low-grade mucoepidermoid

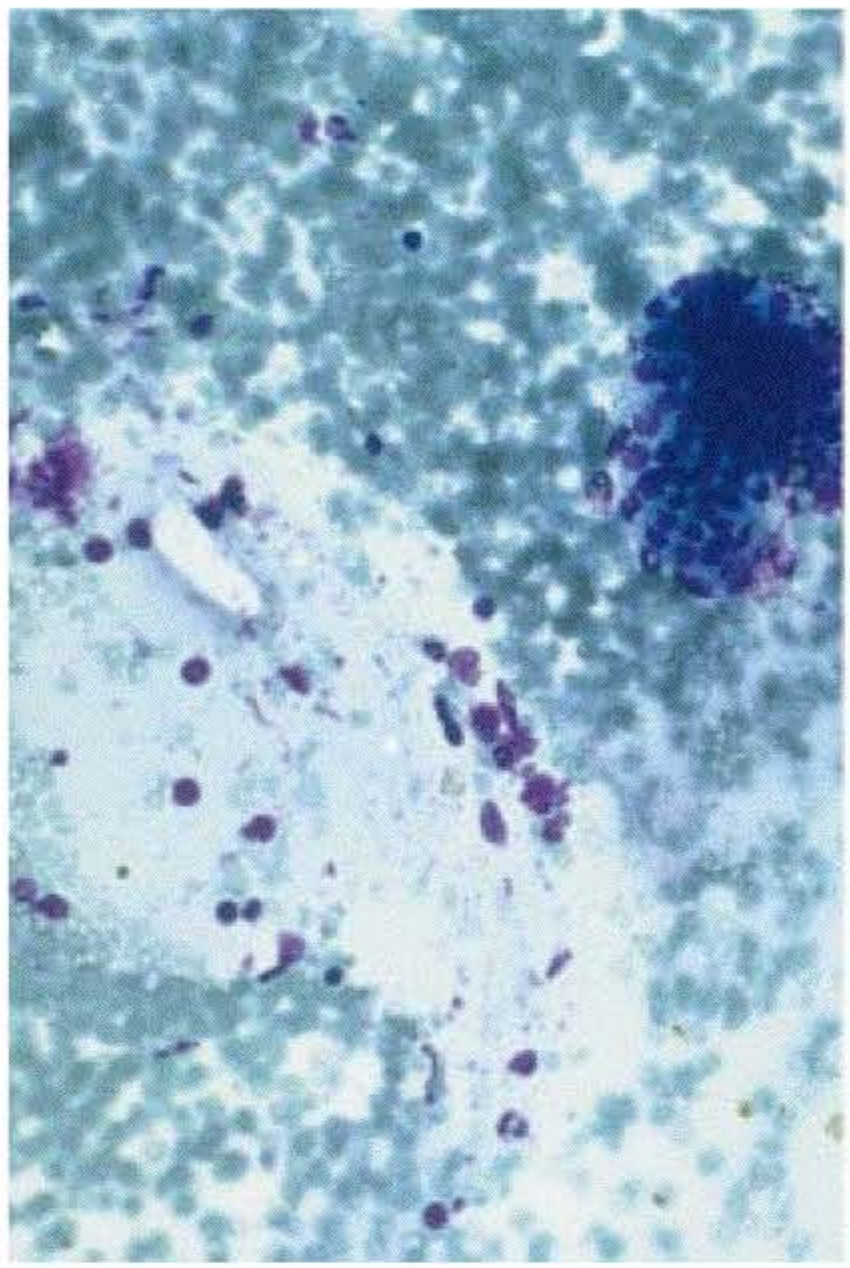

12.8

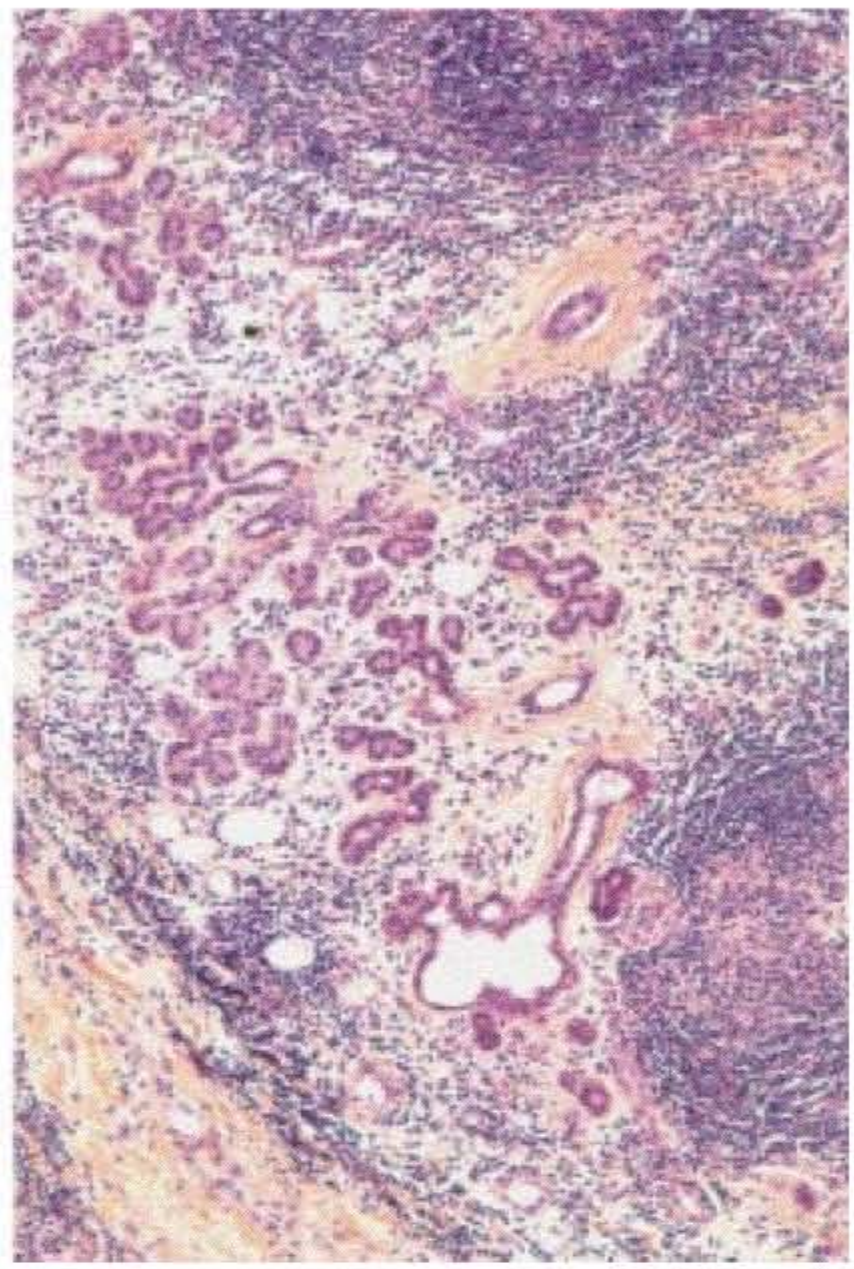

12.9

Fig. 12.8. Küttner's tumour. Mucoid background, inflammatory cells and cluster of dark ductal cells. MGG. E 128.
Fig. 12.9. Küttner's tumour. Histological section corresponding to figure 12.8. Note the presence of dystrophic ductal cells, dilatation of several ducts and inflammatory infiltrates. HES. E 32.

Table 12.5. Correlation between cytology and histology in chronic sialadenitis (Küttner's tumour)

Author [ref.]	Number	Benign	Suspicious and false-positive	Unsatisfactory
Mavec et al. [241]	16	8	1	7
Persson, Zettergren [270]	10	9	0	1
Qizilbash et al. [277]	17	17	0	0
Young et al. [351]	6	3	1	2
Frierson, Fechner [117]	1	0	1	0
Smith Frable, Frable [313]	1	1	0	0
MacLeod, Frable [230]	1	1	0	0
Abad et al. [1]	19	19	0	0
Zurrida et al. [358]	2	1	0	1
Henry-Stanley et al. [154]	3	0	0	3
Cajulis et al. [41]	2	2	0	0
Our series	11	9	2	0
Total	89	70 (78.7)	5 (5.6)	14 (15.7)

Statistics from the literature. % in parentheses.

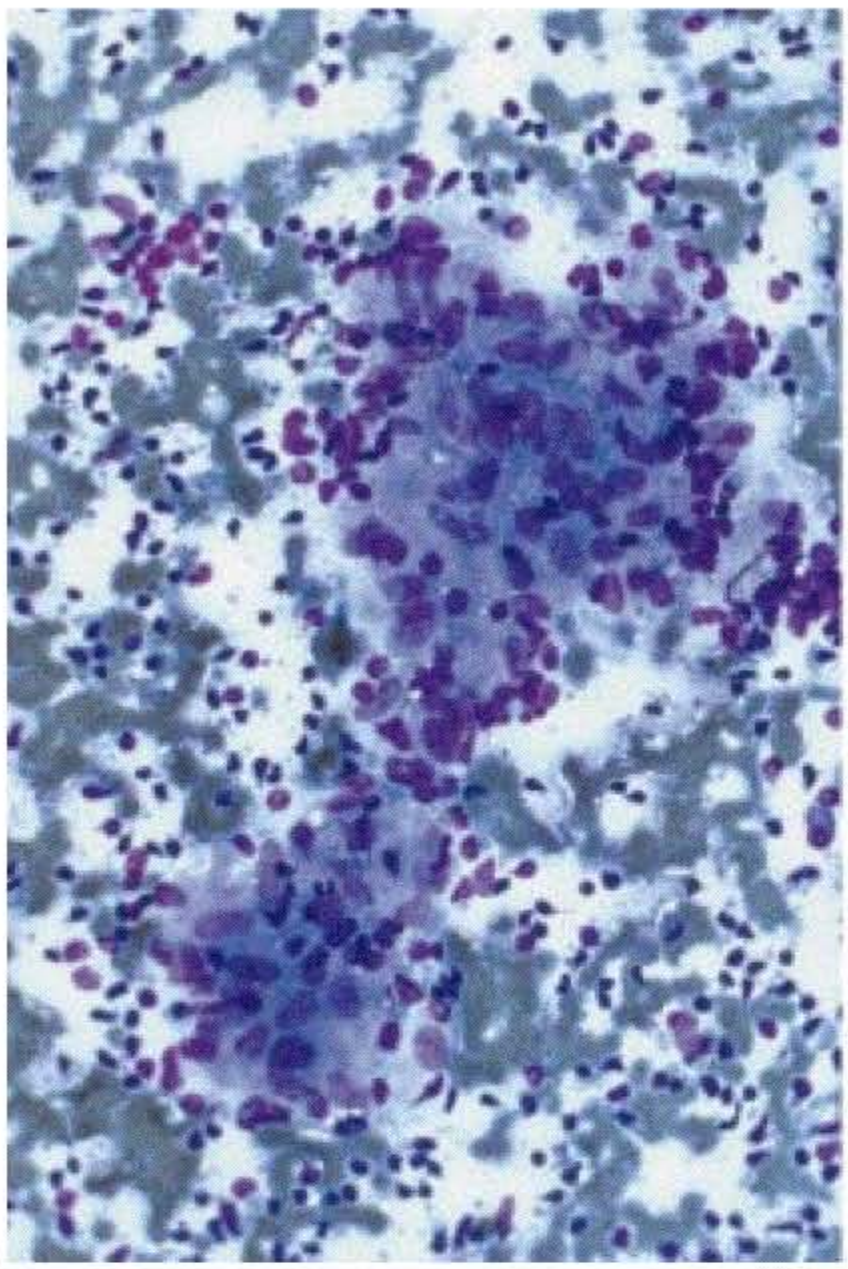

12.10

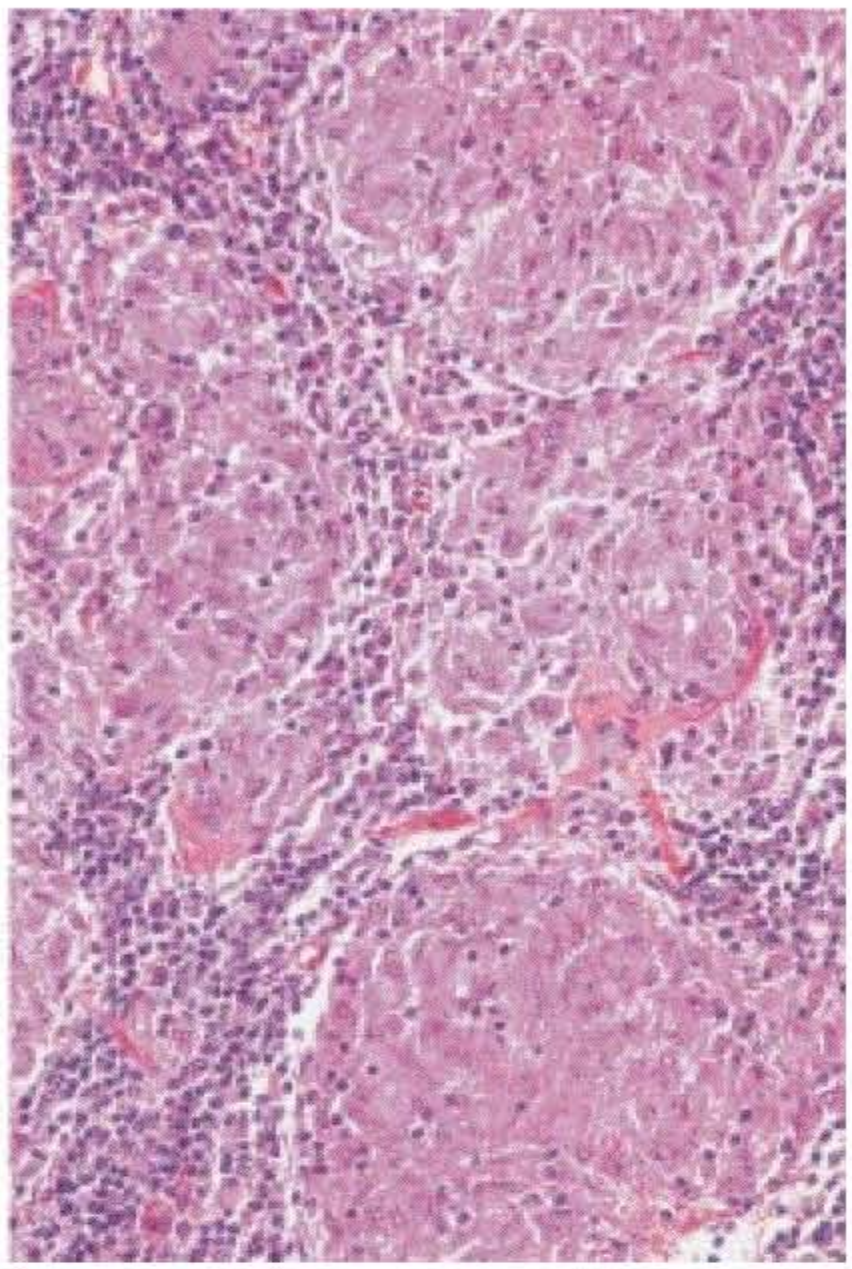

12.11

Fig. 12.10. Sarcoidosis in an intraparenchymal lymph node. Epithelioid cells and lymphocytes. MGG. ×128.
Fig. 12.11. Sarcoidosis. Histological section corresponding to figure 12.10. HES. ×64.

Table 12.6. Quantitative differential diagnosis of Küttner's tumour (chronic sialadenosis)

Component	Küttner's tumour	Low-grade muco-epidermoid carcinoma
Stroma		
Mucoid	+	++
Inflammatory	++	+
Necrotic	+	+
Cells		
Mucus-secreting	+	++
Intermediate	–	+
Mast cells	–	+/–

carcinoma. Some cases may also be misdiagnosed as pleomorphic adenoma, fibroma or basal cell adenoma.

12.5.5. Differential Diagnosis

Küttner's tumour should be differentiated from low-grade mucoepidermoid carcinoma, especially in the submandibular gland (table 12.6).

12.5.5.1. Küttner's Tumour vs. Low-Grade Mucoepidermoid Carcinoma.

Branching clusters of ductal cells may be erroneously interpreted as intermediate cells. Mucoid background with inflammatory cells may also be misinterpreted as mucoid stroma from low-grade mucoepidermoid carcinoma (fig. 7.1, 12.8). We suggest that all submandibular gland tumours should be underdiagnosed when mucoepidermoid carcinoma is suspected, with referral of the patient for surgery with intraoperative frozen section examination.

Küttner's Tumour

In favour of the diagnosis

Submandibular site, mucoid background with connective tissue fragments, inflammatory cells, necrosis, keratin debris, squamoid cells, branching clusters of ductal cells

Difficulties

Dense mucoid fluid, histiocytes resembling mucus-secreting cells, psammoma bodies

Against the diagnosis

Atypical squamous cells, intermediate, mucus-secreting and mast cells

12.6. Reactive Processes

Pseudoneoplastic enlargement of the parotid gland may be occasionally due to reactive inflammatory processes involving intraparenchymal lymph nodes [209, 259, 343]. The specific nature of these lesions and exclusion of neoplasia may be determined by cytology. Cytological examples of leishmaniasis [287], sarcoidosis [6], Kimura's or Castelman's diseases [48] and salivary gland mycoses [281] mimicking salivary neoplasia have been reported. We have seen 30 nonspecific and 23 specific (tuberculosis, sarcoidosis) cases of lymphadenitis correlated with histology (fig. 12.10, 12.11). Only one sample of nonspecific lymphadenitis was diagnosed as being suspicious for lymphoma.

References

1 Abad MM, Macias CG, Alonso MJ, Muñoz E, Paz JI, Galindo P, Herrero A, Bullon A: Statistical evaluation of the predictive power of fine needle aspiration of salivary glands. Results and cytohistological correlation. Pathol Res Pract 1992;188:340–343.

2 Abdul-Karim FW, Weaver MG: Needle aspiration cytology of an oncocytic carcinoma of the parotid gland. Diagn Cytopathol 1991;7:420–422.

3 Abendroth CS, Frauenhoffer EE: Nodular fasciitis of the parotid gland. Report of a case with presentation in an unusual location and cytologic differential diagnosis. Acta Cytol 1995;39:530–534.

4 Aberle AM, Abrams AM, Bowe R, Melrose RJ, Handlers JP: Lobular (polymorphous low-grade) carcinoma of minor salivary glands. A clinicopathologic study of twenty cases. Oral Surg Oral Med Oral Pathol 1985;60:387–395.

5 Abrams AM, Cornyn J, Scofield HH, Hansen LS: Acinic cell adenocarcinoma of the major salivary glands: A clinicopathologic study of 77 cases. Cancer 1965;18:1145–1162.

6 Aggarwal AP, Jayaram G, Mandal AK: Sarcoidosis diagnosed on fine-needle aspiration cytology of salivary glands: A report of three cases. Diagn Cytopathol 1989;5:289–292.

7 Albores-Saavedra J, Morris AW: Sebaceous adenoma of the submaxillary salivary gland: Report of case. Arch Otolaryngol 1963;77: 500–503.

8 Al-Khafaji BM, Nestok BR, Katz RL: Fine-needle aspiration of 154 parotid masses with histologic correlation. Ten-year experience at the University of Texas M.D. Anderson Cancer Center. Cancer 1998;84:153–159.

9 Anand A, Brockie ES: Cytomorphological features of salivary duct carcinoma ex pleomorphic adenoma: Diagnosis by fine-needle aspiration biopsy with histologic correlation. Diagn Cytopathol 1999;20:375–378.

10 Appaix A, Bonneau H, Sommer D: La cytologie des tumeurs des glandes salivaires. Presse Méd 1959;67:600–602.

11 Arora VK, Misra K, Bhatia A: Cytomorphologic features of the rare epithelial-myoepithelial carcinoma of the salivary glands. Acta Cytol 1990;34:239–242.

12 Ascoli V, Albedi FM, De Blasiis R, Nardi F: Sialadenosis of the parotid gland: Report of four cases diagnosed by fine-needle aspiration cytology. Diagn Cytopathol 1993;9:151–155.

13 Atula T, Grénman R, Laippala P, Klemi PJ: Fine-needle aspiration cytology of submandibular gland lesions. J Laryngol Otol 1995;109:853–858.

14 Atula T, Grénman R, Laippala P, Klemi PJ: Fine-needle aspiration biopsy in the diagnosis of parotid gland lesions: Evaluation of 438 biopsies. Diagn Cytopathol 1996;15:185–190.

15 Auclair PL, Langloss JM, Weiss SW, Corio RL: Sarcomas and sarcomatoid neoplasms of the major salivary gland regions. A clinicopathologic and immunohistochemical study of 67 cases and review of the literature. Cancer 1986;58:1305–1315.

16 Austin MB, Frierson HF, Feldman PS: Oncocytoid adenocarcinoma of the parotid gland. Cytologic, histologic and ultrastructural findings. Acta Cytol 1987;31:351–356.

17 Ballo MS, Shin HJC, Sneige N: Sources of diagnostic error in the fine-needle aspiration diagnosis of Warthin's tumor and clues to a correct diagnosis. Diagn Cytopathol 1997;17: 230–324.

18 Barnes L, Appel BN, Perez H, El-Attar AM: Myoepithelioma of the head and neck: Case report and review. J Surg Oncol 1985;28:21–28.

19 Batsakis JG: Basal cell adenoma of the parotid gland. Cancer 1972;29:226–230.

20 Batsakis JG: Clear cell tumors of salivary glands. Ann Otol Rhinol Laryngol 1980;89: 196–197.

21 Batsakis JG: Myoepithelioma Ann Otol Rhinol Laryngol 1985;94:523–524.

22 Batsakis JG, Chinn EK, Weimert TA, Work WP, Krause CJ: Acinic cell carcinoma: A clinicopathologic study of thirty-five cases. J Laryngol Otol 1979;93:325–340.

23 Batsakis JG, El-Naggar AK, Luna MA: 'Adenocarcinoma, not otherwise specified': A diminishing group of salivary carcinomas. Ann Otol Rhinol Laryngol 1992;101:102–104.

24 Batsakis JG, Manning JT: Necrotizing sialometaplasia of major salivary glands. J Laryngol Otol 1987;101:962–966.

25 Batsakis JG, Ordonez NG, Ro J, Meis JM, Bruner JM: S-100 protein and myoepithelial neoplasms. J Laryngol Otol 1986;100:687–698.

26 Batsakis JG, Regezi JA: Selected controversial lesions of salivary tissues. Otolaryngol Clin North Am 1977;10:309–328.

27 Bernier JL, Bhaskar SN: Lymphoepithelial lesions of salivary glands: Histogenesis and classification based on 186 cases. Cancer 1958;11: 1156–1179.

28 Bishop Pitman M, Thor AD, Goodman ML, Rosenberg AE: Benign metastasizing pleomorphic adenoma of salivary gland: Diagnosis of bone lesions by fine-needle aspiration biopsy. Diagn Cytopathol 1992;8:384–387.

29 Boccato P, Altavilla G, Blandamura S: Fine needle aspiration biopsy of salivary gland lesions. A reappraisal of pitfalls and problems. Acta Cytol 1998;42:888–898.

30 Bondeson L, Lindholm K, Thorstenson S: Benign dermal eccrine cylindroma: A pitfall in the cytologic diagnosis of adenoid cystic carcinoma. Acta Cytol 1983;27: 326–328.

31 Bonneau H, Sommer D: L'orientation du diagnostic des tumeurs salivaires par la ponction à l'aiguille fine. Pathol Biol 1959;7:785–791.

32 Bono A, Chiesa F, Sala L, Azzarelli A, Pilotti S, Di Pietro S: Fine-needle aspiration biopsy in parotid masses. Tumori 1983;69:417–421.

33 Bottles K, Ferrell LD, Miller TR: Tyrosine crystals in fine needle aspirates of a pleomorphic adenoma of the parotid gland. Acta Cytol 1984;28:490–492.

34 Bottles K, Löwhagen T: Psammoma bodies in the aspiration cytology smears of an acinic-cell tumor. Acta Cytol 1985;29:191–192.

35 Boudousquie AC, Baloch Z: Fine needle aspiration cytology and histopathology of crystalloids in a cystic lesion of parotid salivary gland. Acta Cytol 1998;42:1485–1487.

36 Brandrick JT, Das Gupta AR, Singh R: Jugulotympanic paraganglioma (glomus jugulare tumour) presenting as a parotid neoplasm (a case report and review of the literature). J Laryngol Otol 1988;102:741–744.

37 Brannon RB, Fowler CB, Hartman KS: Necrotizing sialometaplasia. A clinicopathologic study of sixty-nine cases and review of the literature. Oral Surg Oral Med Oral Pathol 1991; 72:317–325.
38 Brown D, Konzen B, Kashkari S: Fine needle aspiration cytology of basal cell adenocarcinoma of salivary gland. Acta Cytol 1994;38:853.
39 Bullerdiek J, Vollrath M, Wittekind C, Caselitz J, Bartnitzke S: Mucoepidermoid tumor of the parotid gland showing a translocation (3;8)(p21;q12) and a deletion (5)(q22) as sole chromosome abnormalities. Cancer Genet Cytogenet 1990;50:161–164.
40 Bullerdiek J, Wobst G, Meyer-Bolte K, Chilla R, Haubrich J, Thode B, Barnitzke S: Cytogenetic subtyping of 220 salivary gland pleomorphic adenomas: Correlation to occurrence, histological subtype, and in vitro cellular behaviour. Cancer Genet Cytogenet 1993;65: 27–31.
41 Cajulis RS, Gokaslan ST, Yu GH, Frias-Hidvegi D: Fine needle aspiration biopsy of the salivary glands. A five-year experience with emphasis on diagnostic pitfalls. Acta Cytol 1997;41:1412–1420.
42 Cameron WR, Johansson L, Tennvall J: Small cell carcinoma of the parotid. Fine needle aspiration and immunochemical findings in a case. Acta Cytol 1990;34:837–841.
43 Campbell WG, Priest RE, Weathers DR: Characterization of two types of crystalloids in pleomorphic adenomas of minor salivary glands. A light-microscopic, electron-microscopic, and histochemical study. Am J Pathol 1985;118:194–202.
44 Carrillo R, Poblet E, Rocamora A, Rodriguez-Peralto JL: Epithelial-myoepithelial carcinoma of the salivary gland: Fine needle aspiration cytologic findings. Acta Cytol 1990;34:243–247.
45. Carson HJ, Raslan WF, Castelli MJ, Gattuso P: Tyrosine crystals in benign parotid gland cysts: Report of two cases diagnosed by fine-needle aspiration biopsy with ultrastructural and histochemical evaluation. Am J Clin Pathol 1994; 102:699–702.
46 Casiano RR, Cooper JD, Gould E, Ruiz P, Uttamchandani R: Value of needle biopsy in directing management of parotid lesions in HIV-positive patients. Head Neck 1991;13:411–414.
47 Cha I, Long SR, Ljung BM, Miller TR: Low-grade lymphoma of mucosa-associated tissue in the parotid gland: A case report of fine-needle aspiration cytology diagnosis using flow cytometric immunophenotyping. Diagn Cytopathol 1997;16:345–349.
48 Chan MK, McGuire LJ, King W, Li AK, Lee JC: Cytodiagnosis of 112 salivary gland lesions. Correlation with histologic and frozen section diagnosis. Acta Cytol 1992;36:353–363.
49 Chan MK, McGuire LJ, Lee JC: Fine needle aspiration cytodiagnosis of nasopharyngeal carcinoma in cervical lymph nodes. A study of 40 cases. Acta Cytol 1989;33:344–350.
50 Chan MKM, McGuire LJ: Cytodiagnosis of lesions presenting as salivary gland swellings: A report of seven cases. Diagn Cytopathol 1992; 8:439–443.
51 Chaplin AJ, Darke P, Patel S: Tyrosine-rich crystals in pleomorphic adenomas of parotid glands. J Oral Pathol 1983;12:342–346.
52 Chaudhry AP, Cutler LS, Leifer C, Labay G, Satchidanand S, Yamane GM: Ultrastructural study of the histogenesis of salivary gland mucoepidermoid carcinoma. J Oral Pathol Med 1989;18:400–409.
53 Chaudhry AP, Cutler LS, Leifer C, Satchidanand S, Labay G, Yamane G: Histogenesis of acinic cell carcinoma of the major and minor salivary glands. An ultrastructural study. J Pathol 1986;148:307–320.
54 Chen JC, Gnepp DR, Bedrossian CW: Adenoid cystic carcinoma of the salivary glands: An immunohistochemical analysis. Oral Surg Oral Med Oral Pathol 1988;65:316–326.
55 Chen KT: Clear cell carcinoma of the salivary gland. Hum Pathol 1983;14:91–93.
56 Chen KT: Aspiration cytology of metaplastic Warthin's tumor mimicking squamous-cell carcinoma. Diagn Cytopathol 1991;7:330–331
57 Chen KT: Cytology of salivary duct carcinoma. Diagn Cytopathol 2000;22:132–134.
58 Chilla R, Droese M: Infected cystadenolymphoma. A possible reason for clinical and cytologic diagnostic error 'carcinoma'. HNO 1993; 41:446–448.
59 Chow LTC, Chow WH, Lee JCK: Monomorphic epithelioid variant of malignant myoepithelioma of the parotid gland: Cytologic features in fine needle aspiration. Cytopathology 1996;7:279–287.
60 Clarke JS, Hentz EC, Mahoney WD: Bilateral acinic cell carcinoma of the parotid gland. Ann Surg 1969;170:866–869.
61 Cleveland DB, Cosgrove MM, Martin SE: Tyrosine-rich crystalloids in a fine needle aspirate of a polymorphous low grade adenocarcinoma of a minor salivary gland. A case report. Acta Cytol 1994;38:247–251.
62 Cohen MB, Fisher PE, Holly EA, Ljung BM, Lowhagen T, Bottles K: Fine needle aspiration biopsy diagnosis of mucoepidermoid carcinoma: statistical analysis. Acta Cytol 1990;34: 43–49.
63 Cohen MB, Reznicek MJ, Miller TR: Fine-needle aspiration of the salivary glands. Pathol. Annu 1992;27:213–245.
64 Cohen MN, Rao U, Shedd DP: Benign cysts of the parotid gland. J Surg Oncol 1984;27:85–88.
65 Colby TV, Dorfman R: Malignant lymphomas involving the salivary glands. Pathol Annu 1979;14:307–342.
66 Colecchia M, Frigo B, Leopardi OM: Salivary duct carcinoma of the parotid gland. Report of a case with cytologic and immunocytochemical findings on fine needle aspiration biopsy. Acta Cytol 1997;41:593–597.
67 Corio RL, Sciubba JJ, Brannon RB, Batsakis JG: Epithelial-myoepithelial carcinoma of intercalated duct origin. A clinicopathologic and ultrastructural assessment of sixteen cases. Oral Surg 1982;53:280–287.
68 Cristallini EG, Ascani S, Farabi R, Liberati F, Macciò T, Peciarolo A, Bolis GB: Fine needle aspiration biopsy of salivary gland, 1985–1995. Acta Cytol 1997;41:1421–1425.
69 Croce A, Moretti A, Bianchedi M, D'Agostino L, Angelucci D, Dioro M: Carcinoma in ectopic Warthin's tumor: A case study and review of the literature. Acta Otorhinolaryngol Ital 1996;16:543–549.
70 Currens HS, Sajjad SM, Lukeman JM: Aspiration cytology of oat-cell carcinoma metastatic to the parotid gland. Acta Cytol 1982;26:566–567.
71 Dardick I, Daya D, Hardie J, van Nostrand A.W.P. Mucoepidermoid carcinoma: Ultrastructural and histogenetic aspects. J Oral Pathol 1984;13:342–358.
72 Dardick I, George D, Jeans MT, Wittkuhn JF, Skimming L, Rippstein P, van Nostrand AWP: Ultrastructural morphology and cellular differentiation in acinic cell carcinoma. Oral Surg Oral Med Oral Pathol 1987;63:325–334.
73 Dardick I, Kahn HJ, van Nostrand AW, Baumal R: Salivary gland monomorphic adenoma: Ultrastructural, immunoperoxidase and histogenetic aspects. Am J Pathol 1984;115:334–348.
74 Dardick I, Stratis M, Parks WR, DeNardi FG, Kahn HJ: S-100 protein antibodies do not label normal salivary gland myoepithelium. Histogenetic implications for salivary gland tumors. Am J Pathol 1991;138:619–628.
75 Dardick I, van Nostrand AWP: Morphogenesis of salivary gland tumors. A prerequisite to improving classification. Pathol Annu 1987;22: 1–53.
76 Dardick I, van Nostrand AWP: Myoepithelial cells in salivary gland tumors-revisited. Head Neck Surg 1985;7:395–408.
77 Dargent JL, Deplace J, Schneider E, Morales J, Kentos A, Willemart S, Roufosse C, Verhest A: Hepatocellular carcinoma metastatic to the parotid gland: Initial diagnosis by fine needle aspiration biopsy. Acta Cytol 1998;42:824–826.
78 De la Torre M, Larsson E: Fine-needle aspiration cytology of carcinosarcoma of the parotid gland: Cytohistological and immunohistochemical findings. Diagn Cytopathol 1995;12: 350–353.
79 Dee S, Masood S, Issacs JH, Hardy NM: Cytomorphologic features of salivary duct carcinoma on fine needle aspiration biopsy. A case report. Acta Cytol 1993;37:539–542.
80 Dejmek A, Lindholm K: Fine needle aspiration biopsy of cystic lesions of the head and neck, excluding the thyroid. Acta Cytol 1990; 34:443–448.
81 Delgado R, Klimstra D, Albores-Saavedra J: Low grade salivary duct carcinoma, a distinctive variant with a low grade histology and a predominant intraductal growth pattern. Cancer 1996;78:958–967.

82 Derias NW, Chong WH, Pambakian H: Sebaceous adenoma of parotid gland – a rare tumour diagnosed by fine needle aspiration cytology. Cytopathology 1994;5:392–395.
83 Di Palma S, Alasio L, Pilotti S: Fine needle aspiration appearances of malignant myoepithelioma of the parotid gland. Cytopathology 1996;7:357–365.
84 Dodd LG, Caraway NP, Luna MA, Byers RM: Myoepithelioma of the parotid. Report of a case initially examined by fine needle aspiration biopsy. Acta Cytol 1994;38:417–421.
85 Domson KK, Wakely PE: Aspiration and imprint cytopathology of salivary duct carcinoma. Cancer 1997;81:281–286.
86 Droese M: Cytologic diagnosis of sialadenosis, sialadenitis and parotid cysts by fine-needle aspiration biopsy. Adv Otorhinolaryngol 1981;26:49–96.
87 Dudgeon LS, Patrick CV: A new method for the rapid microscopical diagnosis of tumours: With an account of 200 cases so examined. Br J Surg 1927;15:250.
88 Elliott JN, Oertel YC: Lymphoepithelial cysts of the salivary glands. Histologic and cytologic features. Am J Clin Pathol 1990;93:39–43.
89 Ellis GL, Auclair PL: Atlas of Tumor Pathology. Tumors of the Salivary Glands. Washington, Armed Forces Institute of Pathology, 1996.
90 Ellis GL, Auclair PL, Gnepp DR: Surgical Pathology of the Salivary Glands. Philadelphia, Saunders, 1991.
91 El-Naggar AK, Batsakis JG, Luna MA, McLemore D, Byers RM: DNA flow cytometry of acinic cell carcinomas of major salivary glands. J Laryngol Otol 1990;104:410–416.
92 El-Naggar AK, Klijanienko J: Advances in clinical investigations of salivary gland tumorigenesis. Ann Pathol 1999;19:19–22.
93 Elsheikh TM, Bernacki EG: Fine needle aspiration cytology of cellular pleomorphic adenoma. Acta Cytol 1996;40:1165–1175.
94 Elsheikh TM, Bernacki EG, Pisharodi L: Fine-needle aspiration cytology of salivary duct carcinoma. Diagn Cytopathol 1994;11:47–51.
95 Eneroth CM: Oncocytoma of major salivary glands. J Laryngol Otol 1965;79:1064–1072.
96 Eneroth CM, Franzén S, Zajicek J: Cytologic diagnosis on aspirate from 1000 salivary-gland tumours. Acta Otolaryngol 1967;224:168–171.
97 Eneroth CM, Jakobsson P, Zajicek J: Aspiration biopsy of salivary gland tumors. V. Morphologic investigations on smears and histologic sections of acinic cell carcinoma. Acta Radiol Suppl 1971;310:85–931.
98 Eneroth CM, Zajicek J: Aspiration biopsy of salivary gland tumors. III. Morphologic studies on smears and histologic sections from 368 mixed tumors. Acta Cytol 1966;10:440–454.
99 Eneroth CM, Zajicek J: Aspiration biopsy of salivary gland tumors. II. Morphologic studies on smears and histologic sections from oncocytic tumors: 45 cases of papillary cystadenoma lymphomatosum and 4 cases of oncocytoma. Acta Cytol 1965;9:355–361.
100 Eneroth CM, Zajicek J: Aspiration biopsy of salivary gland tumors. IV. Morphologic studies on smears and histologic sections from 45 cases of adenoid cystic carcinoma. Acta Cytol 1969;13:59–63.
101 Engzell U, Franzén S, Zajicek J: Aspiration biopsy of tumors of the neck. II. Cytologic findings in 13 cases of carotid body tumor. Acta Cytol 1971;15:25–30.
102 Engzell V, Esposti PL, Rubio C, Sigurdson A, Zajicek J: Investigation on tumor spread in connection with aspiration biopsy. Acta Radiol 1971;10:385–389.
103 Erlandson RA, Cardon-Cardo C, Higgins PJ: Histogenesis of benign pleomorphic adenoma (mixed tumor) of the major salivary glands. An ultrastructural and immunohistochemical study. Am J Surg Pathol 1984;8:803–820.
104 Ersöz C, Çetic F, Aydin Ö, Cosar EF, Talas DÜ: Salivary duct carcinoma ex pleomorphic adenoma: Analysis of the findings in fine-needle aspiration cytology and histology. Diagn Cytopathol 1998;19:201–204.
105 Eusebi V, Martin SA, Govoni E, Rosai J: Giant cell tumor of major salivary glands: Report of three cases, one occurring in association with a malignant mixed tumor. Am J Clin Pathol 1984;81:666–675.
106 Evans HL, Batsakis JG: Polymorphous low-grade adenocarcinoma of minor salivary glands. A study of 14 cases of a distinctive neoplasm. Cancer 1984;53:935–942.
107 Fantasia JE, Neville BW: Basal cell adenomas of the minor salivary glands. A clinicopathologic study of seventeen new cases and a review of the literature. Oral Surg Oral Med Oral Pathol 1980;50:433–440.
108 Feldman PS, Kaplan MJ, Johns ME, Cantrell RW: Fine-needle aspiration in squamous cell carcinoma of the head and neck. Arch Otolaryngol 1983;109:735–742.
109 Filopoulos E, Angeli S, Daskalopoulou D, Kelessis N, Vassilopoulos P: Pre-operative evaluation of parotid tumours by fine needle biopsy. Eur J Surg Oncol 1998;24:180–183.
110 Finfer MD, Gallo L, Perchick A, Schinella RA, Burstein DE: Fine needle aspiration biopsy of cystic benign lymphoepithelial lesion of the parotid gland in patients at risk for the acquired immune deficiency syndrome. Acta Cytol 1990;34:821–826.
111 Fleming MV, Oertel YC, Rodriguez ER, Fidler WJ: Fine-needle aspiration of six carotid body paragangliomas. Diagn Cytopathol 1993;9:510–515.
112 Fonseca I, Soares J: Epithelial-myoepithelial carcinoma of the salivary glands. A study of 22 cases. Virchows Arch A 1993;422:389–396.
113 Foote FW, Frazell EL: Tumors of the major salivary glands in Foote FW, Frazell EL (eds): Atlas of Tumor Pathology, Sect IV, Fasc 11, 1st Ser Washington, Armed Forces Institute of Pathology, 1954.
114 Foss RD, Ellis GL, Auclair PL: Salivary gland cystadenocarcinomas. A clinicopathologic study of 57 cases. Am J Surg Pathol 1996;20:1440–1447.
115 Frable WJ: Fine-needle aspiration biopsy: A review. Hum Pathol 1983;14:9–28.
116 Frierson HF, Covell JL, Mills SE: Fine-needle aspiration cytology of terminal duct carcinoma of minor salivary gland. Diagn Cytopathol 1987;3:159–162.
117 Frierson HF, Fechner RE: Chronic sialadenitis with psammoma bodies mimicking neoplasia in a fine-needle aspiration specimen from the submandibular gland. Am J Clin Pathol 1991;95:884–888.
118 Fýrat P, Cramer H, Feczko JD, Kratzer S, Layfield LJ, Eisenhut CC, Glant MD: Fine needle aspiration biopsy of salivary duct carcinoma: Report of five cases. Diagn Cytopathol 1997;16:526–530.
119 Gal R, Strauss M, Zohar Y, Kessler E: Salivary duct carcinoma of the parotid gland: Cytologic and histopathologic study. Acta Cytol 1985;29:454–456.
120 Garcia-Bonafé M, Catala I, Tarragona J, Tallada N: Cytologic diagnosis of salivary duct carcinoma: A review of seven cases. Diagn Cytopathol 1998;19:120–123.
121 Garner SL, Robinson RA, Maves MD, Barnes CH: Salivary gland carcinosarcoma: True malignant mixed tumor. Ann Otol Rhinol Laryngol 1989;98:611–614.
122 Gattuso P, Castelli MJ, Shah PA, Kron T: Fine needle aspiration cytologic diagnosis of metastatic Merkel cell carcinoma in the parotid gland. Acta Cytol 1988;32:576–578.
123 Geisinger KR, Reynolds GD, Vance RP, McGuirt WF: Adenoid cystic carcinoma arising in a pleomorphic adenoma of the parotid gland. An aspiration cytology and ultrastructural study. Acta Cytol 1985;29:522–526.
124 Gherardi G, Marveggio C, Stiglich F: Parotid metastasis of Merkel cell carcinoma in a young patient with ectodermal dysplasia. Diagnosis by fine needle aspiration cytology and immunocytochemistry. Acta Cytol 1990; 34:831–836.
125 Gibbons D, Saboorian MH, Vuitch F, Gokaslan ST, Ashfaq R: Fine-needle aspiration findings in patients with polymorphous low grade adenocarcinoma of the salivary glands. Cancer 1999;87:31–36.
126 Gilcrease MZ, Guzman-Paz M: Fine-needle aspiration of basaloid squamous carcinoma: A case report with review of differential diagnostic considerations. Diagn Cytopathol 1998;19:210–215.
127 Gilcrease MZ, Guzman-Paz M, Froberg K, Pambuccian S: Salivary duct carcinoma. Is a specific diagnosis possible by fine needle aspiration cytology? Acta Cytol 1998;42:1389–1396.
128 Gillenwater A, Hurr K, Wolf P, Batsakis JG, Goepfert H, El-Naggar AK: Microsatellite alterations at chromosome 8q loci in pleomorphic adenoma. J Otolaryngol Head Neck Surg 1997;117:448–452.
129 Gleeson MJ, Bennett MH, Cawson RA: Lymphomas of salivary glands. Cancer 1986;58: 699–704.
130 Gnepp DR Malignant mixed tumors of the salivary glands: A review. Pathol Annu 1993; 28:279–329.

131 Gnepp DR: Sebaceous neoplasms of salivary gland origin: A review. Pathol Annu 1983; 18:71–102.
132 Gnepp DR, Brannon R: Sebaceous neoplasms of salivary gland origin. Report of 21 cases. Cancer 1984;53:2155–2170.
133 Gnepp DR, Chen JC, Warren C: Polymorphous low-grade adenocarcinoma of minor salivary gland: An immunohistochemical and clinicopathologic study. Am J Surg Pathol 1988;12:461–468.
134 Gnepp DR, Corio RL, Brannon RB: Small cell carcinoma of the major salivary glands. Cancer 1986;58:705–714.
135 Gnepp DR, Sporck FT: Benign lymphoepithelial parotid cyst with sebaceous differentiation – Cystic sebaceous lymphadenoma. Am J Clin Pathol 1980;74:683–687.
136 Gomez-Aracil V, Azua J, San Pedro C, Romero J: Fine needle aspiration cytologic findings in four cases of pilomatrixoma (calcifying epithelioma of Malherbe). Acta Cytol 1990;34:842–846.
137 Goode RK, Corio RL: Oncocytic adenocarcinoma of salivary glands. Oral Surg Oral Med Oral Pathol 1988;65:61–66.
138 Gould AR, Van Arsdall LR, Hinkle SJ, Harris WR: Tyrosine-rich crystalloids in adenoid cystic carcinoma: Histochemical and ultrastructural observations. J Oral Pathol 1983; 12:478–490.
139 Granger JK, Houn HY: Malignant mixed tumor (carcinosarcoma) of parotid gland diagnosed by fine-needle aspiration biopsy. Diagn Cytopathol 1991;7:427–432.
140 Günhan Ö, Celasun B, Safali M, Aksu A, Güller M, Önder T, Finci R: Fine needle aspiration cytology of malignant lymphoepithelial lesion of the salivary gland. A report of two cases. Acta Cytol 1994;38:751–754.
141 Günhan Ö, Celasun B, Dogan N, Önder T, Pabusçu Y, Finci R: Fine needle aspiration cytologic findings in a benign lymphoepithelial lesion with microcalcifications. A case report. Acta Cytol 1992;36:744–747.
142 Gupta RK: Aspiration cytodiagnosis of dermal analogue tumor, a rare subtype of salivary gland monomorphic adenoma. A case report. Acta Cytol 1996;40:331–334.
143 Gupta RK, Dowle CS: A case of neurilemoma (schwannoma) that mimicked a pleomorphic adenoma (an example of potential pitfall in aspiration cytodiagnosis). Diagn Cytopathol 1991;7:622–624.
144 Gupta S, Sodhani P: Sialadenosis of parotid gland. A cytomorphologic and morphometric study of four cases. Analyt Quant Cytol Histol 1998;20:225–228.
145 Gutmann EJ: Lymphangioma presenting as a primary parotid neoplasm in an adult. Report of a case with the diagnosis suggested by fine needle aspiration biopsy. Acta Cytol 1994;38: 747–750.
146 Hara H, Oyama T, Kimura M, Ishii E, Inoue T, Kasai H: Case of myoepithelioma originating from the palate: Collagenogenesis in myoepithelial tumor cells. Diagn Cytopathol 1996;15:415–420.
147 Harris BR, Shipkey F: Tyrosine-rich crystalloids in neoplasms and tissues of the head and neck. Arch Pathol Lab Med 1986;110:709–712.
148 Harris NL: Lymphoid proliferations of the salivary glands. Am J Clin Pathol 1999;111: S94–S103.
149 Harrison RF, Smallman LA, Young JA, Watkinson JC: Oncocytic carcinoma of the parotid gland: A problem in fine needle aspiration diagnosis. Cytopathology 1995;6:54–58.
150 Hayashi Y, Nagamine S, Yanagawa T, Yoshida H, Yura H, Azuma M, Sato M: Small cell undifferentiated carcinoma of the minor salivary gland containing exocrine, neuroendocrine, and squamous cells. Cancer 1987;60: 1583–1588.
151 Hayes MM, Cameron RD, Jones EA: Sebaceous variant of mucoepidermoid carcinoma of the salivary gland. A case report with cytohistologic correlation. Acta Cytol 1993;37: 237–241.
152 Heintz PW, Schmidt WA, Pommier RF, Vetto JT, DiTomasso JP: Submandibular gland carcinoma ex pleomorphic adenoma. Report of a case with cytologic features and diagnostic pitfalls. Acta Cytol 1998;42:1431–1436.
153 Heller KS, Attie JN, Dubner S: Accuracy of frozen section in the evaluation of salivary tumors. Am J Surg 1993;166:424–427.
154 Henry-Stanley MJ, Beneke J, Bardales RH, Stanley MW: Fine-needle aspiration of normal tissue from enlarged salivary glands: sialosis or missed target. Diagn Cytopathol 1995;13:300–303.
155 Hilborne LH, Glasgow BJ, Layfield LJ: Fine-needle aspiration cytology of juvenile hemangioma of the parotid gland: A case report. Diagn Cytopathol 1987;3:152–155.
156 Holliday RA, Cohen WA, Schinella RA, Rothstein SG, Persky MS, Jacobs JM, Som PM: Benign lymphoepithelial parotid cysts and hyperplastic cervical adenopathy in AIDS-risk patients: A new CT appearance. Radiology 1988;168:439–441.
157 Holmes GF, Eisele DW, Rosenthal D, Westra WH: PSA immunoreactivity in a parotid oncocytoma: A diagnostic pitfall in discriminating primary parotid neoplasms from metastatic prostate cancer. Diagn Cytopathol 1998;19: 221–225.
158 Hood IC, Qizilbash AH, Salama SS, Alexopoulou I: Basal cell adenoma of parotid. Difficulty of differentiation from adenoid cystic carcinoma on aspiration biopsy. Acta Cytol 1983;27:515–520.
159 Horii A, Yoshida J, Honjo Y, Mitani K, Takashima S, Kubo T: Pre-operative assessment of metastatic parotid tumors. Auris Nasus Larynx 1998;25:277–283.
160 Hoshino M, Yamamoto I: Ultrastructure of adenoid cystic carcinoma. Cancer 1970;25: 186–198.
161 Hruban RH, Erozan YS, Zinreich SJ, Kashima HK: Fine needle aspiration cytology of monomorphic adenomas. Am J Clin Pathol 1988;90:46–51.
162 Humphrey PA, Ingram P, Tucker A, Shelburne JD: Crystalloids in salivary gland pleomorphic adenomas. Arch Pathol Lab Med 1989;113:390–393.
163 Huvos AG, Paulino AGF: Salivary glands; In Sternberg SS (ed): Diagnostic Surgical Pathology. Lippincott, Williams & Wilkins, 1999, pp 853–884.
164 Ikeda KI, Katoh T, Ha-Kawa SK, Iwai H, Yamashita T, Tanaka Y: The usefulness of MR in establishing the diagnosis of parotid pleomorphic adenoma. AJNR 1996;17:555–559
165 Jacobs JC: Low grade mucoepidermoid carcinoma ex pleomorphic adenoma. A diagnostic problem in fine needle aspiration biopsy. Acta Cytol 1994;38:93–97.
166 Jahan-Parwar B, Huberman RM, Donovan DT, Schwartz MR, Ostrowski ML: Oncocytic mucoepidermoid carcinoma of salivary glands. Am J Surg Pathol 1999;23:523–529.
167 Jayaram G, Khurana N, Basu S: Crystalloids in a cystic lesion of parotid salivary gland: Diagnosis by fine-needle aspiration. Diagn Cytopathol 1993;9:70–71.
168 Jayaram G, Pathmanathan R, Khanijow V: Cystic lesion of the parotid gland with squamous metaplasia mistaken for squamous cell carcinoma. A case report. Acta Cytol 1998;42: 1468–1472.
169 Jayaram N, Ashim D, Rajwanshi A, Radhika S, Banerjee CK: The value of fine-needle aspiration biopsy in the cytodiagnosis of salivary gland lesions. Diagn. Cytopathol 1989; 5:349–354.
170 Joe VQ, Westesson PL: Tumors of the parotid gland: MR imaging characteristics of various histologic types. AJR 1994;163:433–438.
171 Johns MM, Westra WH, Califano JA, Eisele D, Koch WM, Sidransky D: Allelotype of salivary gland tumors. Cancer Res 1996;56: 1151–1154.
172 Kahn HJ, Baumal R, Marks A, Dardick I, van Nostrand AWP: Myoepithelial cells in salivary gland tumors: An immunohistochemical study. Arch Pathol Lab Med 1985;109:190–195.
173 Kate MS, Kamal MM, Bobhate SK, Kher AV: Evaluation of fine needle capillary sampling in superficial and deep-seated lesions. An analysis of 670 cases. Acta Cytol 1998;42: 679–684.
174 Katsuyama E, Kaneoka A, Higuchi K, Takasu K: Myoepithelioma of the soft palate. Acta Cytol 1997;41:1856–1858.
175 Kern SB: Necrosis of a Warthin's tumor following fine needle aspiration. Acta Cytol 1988;32:207–208.
176 Kerpel SM, Freedman PD, Lumerman H: The papillary cystadenoma of minor salivary gland origin. Oral Surg Oral Med Oral Pathol 1978;46:820–826.
177 Khurana KK, Powers CN, Bishop Pitman M, Bardales R, Korourian S, Stanley M: Aspiration cytology of salivary duct carcinoma: Morphology and diagnostic pitfalls. Acta Cytol 1996;40:1071.

178 Khurana KK, Stanley MW, Powers CN, Pitman MB: Aspiration cytology of malignant neoplasms associated with granulomas and granuloma-like features: Diagnostic dilemmas. Cancer 1998;84:84–91.
179 Kilpatrick SE, Geisinger KR: Soft tissue sarcomas. The usefulness and limitations of fine-needle aspiration biopsy. Am J Clin Pathol 1998;110:50–68.
180 Kim KH, Sung MW, Yun JB, Han MH, Baek CH, Chu KC, Kim JH, Lee KS: The significance of CT scan or MRI in the evaluation of salivary gland tumors. Auris Nasus Larynx 1998;25:297–402.
181 Kim T, Yoon GS, Kim O, Gong G: Fine needle aspiration diagnosis of malignant mixed tumor (carcinosarcoma) arising in pleomorphic adenoma of the salivary gland. A case report. Acta Cytol 1998;42:1027–1031.
182 Kleinsasser O, Hübner G, Klein HJ: Talgzellcarcinom des Parotis. Arch Klin Exp Ohren Nasen Kehlkopfheilk 1970;197:59–71.
183 Kleinsasser O, Klein HH, Hübner G: Speichelgangcarcinom: Eine den Milchgangcarcinomen der Brustdrüse analoge Gruppe von Speicheldrüsentumoren. Arch Klin Exp Ohren Nasen Kehlkopfheilkd 1968;192:100–115.
184 Klijanienko J, El-Naggar A, Vielh P: Fine-needle sampling findings in 26 carcinomas ex pleomorphic adenomas: Diagnostic pitfalls and clinical considerations. Diagn Cytopathol 1999;21:163–166.
185 Klijanienko J, El-Naggar AK, Servois V, Rodriguez J, Desjardins L, Schlienger P, Validire P, Vielh P: Histologically similar, synchronous or metachronous, lacrimal salivary-type and parotid gland tumors: A series of 11 cases. Head Neck 1999;21:512–516.
186 Klijanienko J, El-Naggar AK, Servois V, Rodriguez J, Validire P, Vielh P: Clinically aggressive metastasizing pleomorphic adenoma: Report of two cases. Head Neck 1997;19:629–633.
187 Klijanienko J, El-Naggar AK, Servois V, Rodriguez J, Validire P, Vielh P: Mucoepidermoid carcinoma ex pleomorphic adenoma. Nonspecific preoperative cytologic findings in six cases. Cancer 1998;84:231–234.
188 Klijanienko J, El-Naggar AK, Vielh P: Comparative cytologic and histologic study of fifteen salivary basal-cell tumors: Differential diagnostic considerations. Diagn Cytopathol 1999;21:30–34.
189 Klijanienko J, Micheau C, Bosq J, Nacer A, Marandas P, Carlu C: Analyse histoclinique des cylindromes des glandes salivaires accessoires. A propos de 58 cas suivis à l'Institut Gustave-Roussy. Bull Cancer 1989;76:133–145.
190 Klijanienko J, Micheau C, Schwaab G, Marandas P, Friedman S: Clear cell carcinoma in pleomorphic adenoma of the minor salivary gland. J Laryngol Otol 1989;103:789–791.
191 Klijanienko J, Servois V, Jammet P, Validire P, Pouillart P, Vielh P, El-Naggar AK, Dulmet E: Pleomorphic adenoma. Am J Surg Pathol 1998;22:772–773.
192 Klijanienko J, Vielh P: Cytologic characteristics and histomorphologic correlations of 21 salivary duct carcinomas. Diagn Cytopathol 1998;19:333–337.
193 Klijanienko J, Vielh P: Fine-needle sampling of salivary gland lesions V: Cytology of 22 cases of acinic cell carcinoma with histologic correlation. Diagn Cytopathol 1997;17:347–352.
194 Klijanienko J, Vielh P: Fine-needle sampling of salivary gland lesions. VII. Cytology and histology correlation of five cases of epithelial-myoepithelial carcinoma. Diagn Cytopathol 1998;19:405–409.
195 Klijanienko J, Vielh P: Fine-needle sampling of salivary gland lesions. III: Cytology and histology correlation of 75 cases of adenoid cystic carcinoma: Review and experience at the Institut Curie with emphasis on cytologic pitfalls. Diagn Cytopathol 1997;17:36–41.
196 Klijanienko J, Vielh P: Fine-needle sampling of salivary gland lesions. IV. Review of 50 cases of mucoepidermoid carcinoma with histologic correlation. Diagn Cytopathol 1997;17:92–98.
197 Klijanienko J, Vielh P: Fine-needle sampling of salivary gland lesions. VI. Cytological review of 44 cases of primary squamous-cell carcinoma with histologic correlation. Diagn Cytopathol 1998;18:174–178.
198 Klijanienko J, Vielh P: Fine-needle sampling of salivary gland lesions. I. Cytology and histology correlation of 412 cases of pleomorphic adenoma. Diagn Cytopathol 1996;14:195–200.
199 Klijanienko J, Vielh P: Fine-needle sampling of salivary gland lesions. II. Cytology and histology correlation of 71 cases of Warthin's tumor (adenolymphoma). Diagn Cytopathol 1997;16:221–225.
200 Klijanienko J, Vielh P: Salivary carcinomas with papillae: Cytology and histology analysis of polymorphous low-grade adenocarcinoma and papillary cystadenocarcinoma. Diagn Cytopathol 1998;19:244–249.
201 Kline TS, Merriam JM, Shapshay SM: Aspiration biopsy cytology of the salivary gland. Am J Clin Pathol 1981;76:263–269.
202 Klitz B, Bishop Pitman M: Carcinoma ex pleomorphic adenoma of the parotid gland: Pitfalls in fine needle aspiration biopsy diagnosis. Acta Cytol 1994;38:855.
203 Kocjan G, Milroy C, Fisher EW, Eveson JW: Cytological features of epithelial-myoepithelial carcinoma of salivary gland: Potential pitfalls in diagnosis. Cytopathology 1993;4:173–180.
204 Kocjan G, Nayagam M, Harris M: Fine needle aspiration cytology of salivary gland lesions: Advantages and pitfalls. Cytopathology 1990:1:269–275.
205 Kolda TF, Ardaman TDT, Schwartz MR: Eccrine spiradenoma mimicking adenoid cystic carcinoma on fine needle aspiration. A case report. Acta Cytol 1997;41:852–858.
206 Koss LC, Spiro RH, Hajdu S: Small cell (oat cell) carcinoma of minor salivary gland origin. Cancer 1972;30:737–741.
207 Kumar N, Kapila K, Verma K: Fine needle aspiration cytology of mucoepidermoid carcinoma. A diagnostic problem. Acta Cytol 1991;35:357–359.
208 Kumar N, Sharma S, Verma K: Atypical squamous cells in a fine needle aspirate from Warthin's tumor. Acta Cytol 1996;40:1115–1117.
209 Kuo T, Jung SM, Wu WJ: Kikuchi's disease of intraparotid lymph nodes presenting as a parotid gland tumour with extranodal involvement of the salivary gland. Histopathology 1996;28:185–188.
210 Kuwabara H, Kohno K, Kishida F, Uda H, Miyabe K, Nagao K, Saito K, Shibanushi T: Imprint cytology of malignant plasmacytoid myoepithelioma of the palate. Acta Cytol 1998;42:440–443
211 Laforga JB, Aranda FI: Oncocytic carcinoma of parotid gland: Fine-needle aspiration and histologic findings. Diagn Cytopathol 1994;11:376–379.
212 Latkovich P, Johnson RL: Carcinosarcoma of the parotid gland. Report of a case with cytohistologic and immunohistochemical findings. Arch Pathol Lab Med 1998;122:743–746.
213 Laucirica R, Farnum JB, Leopold SK, Kalin GB, Youngberg GA: False-positive diagnosis in fine-needle aspiration of an atypical Warthin's tumor: Histochemical differential stains for cytodiagnosis. Diagn Cytopathol 1989;5:412–415.
214 Layfield LJ: Fine needle aspiration cytology of a trabecular adenoma of the parotid gland. Acta Cytol 1985;29:999–1002.
215 Layfield LJ, Glasgow BJ: Aspiration cytology of clear-cell lesions of the parotid gland: Morphologic features and differential diagnosis. Diagn Cytopathol 1993;9:705–712.
216 Layfield LJ, Glasgow BJ: Diagnosis of salivary gland tumors by fine needle aspiration cytology: A review of clinical utility and pitfalls. Diagn Cytopathol 1991;7:267–272.
217 Layfield LJ, Glasgow BJ, Goldstein N, Lufkin R: Lipomatous lesions of the parotid gland. Potential pitfalls in fine needle aspiration biopsy diagnosis. Acta Cytol 1991;35:553–556.
218 Layfield LJ, Reznicek M, Lowe M, Bottles K: Spontaneous infarction of a parotid gland pleomorphic adenoma. Report of a case with cytologic and radiographic overlap with a primary salivary gland malignancy. Acta Cytol 1992;36:381–386.
219 Layfield LJ, Tan P, Glasgow BJ: Fine-needle aspiration of salivary gland lesions. Comparison with frozen sections and histologic findings. Arch Pathol Lab Med 1987;111:346–353.
220 Lee SS, Cho KJ, Jang JJ, Ham EK: Differential diagnosis of adenoid cystic carcinoma from pleomorphic adenoma of the salivary gland on fine needle aspiration cytology. Acta Cytol 1996;40:1246–1252.
221 Lewis JE, Olsen KD, Weinland LH: Acinic cell carcinoma. Clinicopathologic review. Cancer 1991;67:172–179.

222 Lindberg LG, Åkerman M: Aspiration cytology of salivary gland tumors: Diagnostic experience from 6 years of routine laboratory work. Laryngoscope 1976;86:584–594.
223 López JI, Ballestín C: Fine-needle aspiration cytology of a membranous basal cell adenoma arising in an intraparotid lymph node. Diagn Cytopathol 1993;9:668–672.
224 López-Ríos F, Ballestín C, Martínez-González MA, Serrano R, de Agustín PP: Lymphoepithelial cyst with crystalloid formation. Cytologic features of two cases. Acta Cytol 1999;43:277–280.
225 Luna MA, Batsakis JG, Ordoñez NG, Mackay B, Tortoledo ME: Salivary gland adenocarcinomas: A clinicopathologic analysis of three distinctive types. Semin Diagn Pathol 1987;4:117–135.
226 Luna MA, Batsakis JG, Tortoledo ME, Del Junco GW: Carcinomas ex monomorphic adenoma of salivary glands. J Laryngol Otol 1989;103:756–759.
227 Luna MA, El-Naggar A, Batsakis JG, Weber RS, Garnsey LA, Goepfert H: Flow cytometric DNA content of adenoid cystic carcinoma of submandibular gland. Correlation of histologic features and prognosis. Arch Otolaryngol Head Neck Surg 1990;116:1291–1296.
228 Luna MA, Ordonez NG, MacKay B, Batsakis JG, Guillamondegui O: Salivary epithelial-myoepithelial carcinomas of intercalated ducts: A clinical, electron microscopy, and immunocytochemical study. Oral Surg Oral Med Oral Pathol 1985;59:482–490.
229 MacCallum PL, Lampe HB, Cramer H, Matthews TW: Fine-needle aspiration cytology of lymphoid lesions of the salivary gland: A review of 35 cases. J Otolaryngol 1996;25:300–304.
230 MacLeod CB, Frable WJ Fine-needle aspiration biopsy of the salivary gland: Problem cases. Diagn Cytopathol 1993;9:216–225.
231 Mair S, Leiman G: Benign neurilemmoma (schwannoma) masquerading a pleomorphic adenoma of the submandibular salivary gland. Acta Cytol 1989;33:907–910.
232 Mair S, Phillips JI, Cohen R: Small cell undifferentiated carcinoma of the parotid. Cytologic, histologic, immunohistochemical, and ultrastructural features of a neuroendocrine variant. Acta Cytol 1989;33:164–168.
233 Malata CM, Camilleri IG, McLean NR, Piggott TA, Soames JV: Metastatic tumours of the parotid gland. Br J Oral Maxillofac Surg 1998;36:190–195.
234 Malberger E, Tillinger R, Lichtig C: Diagnosis of basal-cell carcinoma with aspiration cytology. Acta Cytol 1984;28:301–304.
235 Mandreker S, Pinto RW, Usgaonkar U: Sebaceous carcinoma of the eyelid with metastasis to the parotid region: Diagnosis by fine needle aspiration cytology. Acta Cytol 1997;41:1636–1637.
236 Mark J, Wedell B, Dahlenfors R, Stenman G: Karyotypic variability and evolutionary characteristics of a polymorphous low grade adenocarcinoma in the parotid gland. Cancer Genet Cytogenet 1991;55:19–29.
237 Marsot-Dupuch K, Meyohas MC, Ouayoun M, Brunereau L, Merite A, De Saint-Maur P, Tubiana JM: Imaging of ORL diseases in acquired immunodeficiency syndrome. Ann Otolaryngol Chir Cervicofac 1997;114:292–301.
238 Martin HE, Ellis EB: Biopsy by needle puncture and aspiration. Ann Surg 1930;92:169–181.
239 Martinez-Madrigal F, Micheau C: Histology of the major salivary glands. Am J Surg Pathol 1989;13:879–899.
240 Mathew S, Ali SZ: Parotid fine-needle aspiration: A cytologic study of pediatric lesions. Diagn Cytopathol 1997;17:8–13.
241 Mavec P, Eneroth CM, Franzén S, Moberger G, Zajicek J: Aspiration biopsy of salivary gland tumors. Acta Otolaryngol 1964;58:471–484.
242 Meza-Chavez L: Sebaceous glands in normal and neoplastic parotid glands: Possible significance of sebaceous glands in respect to the origin of tumors of the salivary gland. Am J Pathol 1949;25:627–645.
243 Micheau C: What's new in histological classification and recognition of nasopharyngeal carcinoma? Pathol Res Pract 1986;181:249–253.
244 Micheau C, Klijanienko J, Luboinski B, Richard J: So-called branchiogenic carcinoma is actually cystic metastases in the neck from a tonsillar primary. Laryngoscope 1990;100:878–883.
245 Milchgrub S, Gnepp DR, Vuitch F, Delgado R, Albores-Saavedra J: Hyalinizing clear cell carcinoma of salivary gland. Am J Surg Pathol 1994:18:74–82.
246 Mills SE, Garland TA, Allen MS: Low-grade papillary adenocarcinoma of palatal salivary gland origin. Am J Surg Pathol 1984;8:367–374.
247 Mincione GP, Nesi G, Amorosi A: Polymorphous low-grade adenocarcinoma of the soft palate: Fine needle aspiration cytology. Cytopathology 1999;10:61–65.
248 Mintz GA, Abrams AM, Melrose RJ: Monomorphic adenomas of the major and minor salivary glands: Report of twenty-one cases and review of the literature. Oral Surg Oral Med Oral Pathol 1982;53:375–386.
249 Mohamed AH, Cherrick HM: Glycogen-rich adenocarcinoma of minor salivary glands. A light and electron microscopic study. Cancer 1975;36:1057–1066.
250 Moore JG, Bocklage T: Fine needle aspiration biopsy of large-cell undifferentiated carcinoma of the salivary glands: Presentation of two cases, literature review, and differential cytodiagnosis of high-grade salivary gland malignancies. Diagn Cytopathol 1998;19:44–50.
251 Moroz K, Ferreira C, Dhurandhar N: Fine needle aspiration of basal cell adenocarcinoma of the parotid gland. Report of a case with assessment of DNA ploidy in aspirates and tissue sections by image analysis. Acta Cytol 1996;40:773–778.
252 Mullick SS, Mody DR, Schwartz MR: Angiosarcoma at unusual sites. A report of two cases with aspiration cytology and diagnostic pitfalls. Acta Cytol 1997;41:839–844.
253 Nagao K, Matsuzaki O, Saiga H, Sugano I, Shigematsu H, Kaneko T, Katoh T, Kitamura T: Histopathologic studies of undifferentiated carcinoma of the parotid gland. Cancer 1982;50:1572–1579.
254 Nagao K, Matsuzaki O, Saiga H, Sugano I, Shigematsu H, Kaneko H, Katoh T, Kitamura T: Histopathologic studies of basal cell adenoma of the parotid gland. Cancer 1982;50:736–745.
255 Nagao T, Sugano I, Ishida Y, Tajima Y, Furuya N, Kondo Y, Nagao K: Mucoepidermoid carcinoma arising in Warthin's tumour of the parotid gland: Report of two cases with histopathological, ultrastructural and immunohistochemical studies. Histopathology 1998;33:379–386.
256 Nagel H, Hotze HJ, Laskawi R, Chilla R, Droese M: Cytologic diagnosis of adenoid cystic carcinoma of salivary glands. Diagn Cytopathol 1999;20:258–366.
257 Nagel H, Laskawi R, Bütter JJ, Schröder M, Chilla R, Droese M: Cytologic diagnosis of acinic-cell carcinoma of salivary glands. Diagn Cytopathol 1997;16:402–412.
258 Nakazato Y, Ishida Y, Takahashi K, Suzuki K: Immunohistochemical distribution of S-100 protein and glial fibrillary acidic protein in normal and neoplastic salivary glands. Virchows Arch A 1985;405:299–310.
259 Nandapalan V, Jones TM, Morar P, Clark AH, Jones AS: Localized amyloidosis of the parotid gland: A case report and review of the localized amyloidosis of the head and neck. Head Neck 1998;20:73–78.
260 Nelson JF, Jacoway JR: Monomorphic adenoma (canalicular type). Report of 29 cases. Cancer 1973;31:1511–1513.
261 O'Dwyer P, Farrar WB, James AG, Finkelmeier W, McCabe DP: Needle aspiration biopsy of major salivary gland tumors: Its value. Cancer 1986;57:554–557.
262 Olsen KD, Goellner JR: False-positive cytologic findings in Warthin's tumor: A report of two cases. Ear Nose Throat J 1992;71:417–421.
263 Orell SR: Diagnostic difficulties in the interpretation of fine needle aspirates of salivary gland lesions: The problem revisited. Cytopathology 1995;6:285–300.
264 Orenstein JM, Dardick I, van Nostrand AW: Ultrastructural similarities of adenoid cystic carcinoma and pleomorphic adenoma. Histopathology 1985;9:623–638.
265 Osaki T, Hirota J, Ohno A, Tatemoto Y: Mucinous adenocarcinoma of the submandibular gland. Cancer 1990;66:1796–1801.
266 Ostrzega N, Cheng L, Layfield L: Glial fibrillary acid protein immunoreactivity in fine-needle aspiration of salivary gland lesions: A useful adjunct for the differential diagnosis of salivary gland neoplasms. Diagn Cytopathol 1989;5:145–149.

267 Palma O, Torri AM, de Cristofaro JA, Fiaccavento S: Fine needle aspiration cytology in two cases of well-differentiated acinic-cell carcinoma of the parotid gland. Discussion of diagnostic criteria. Acta Cytol 1985;29:516–521.
268 Palmer RM, Lucas RB, Knight J, Gusterson B: Immunocytochemical identification of cell types in pleomorphic adenoma, with particular reference to myoepithelial cells. J Pathol 1985;146:213–220.
269 Pérez-Guillermo M, Sola Pérez J, Espinosa Parra FJ: Asteroid bodies and calcium oxalate crystals: Two infrequent findings in fine-needle aspirates of parotid sarcoidosis. Diagn Cytopathol 1992:8:248–252.
270 Persson PS, Zettergren L: Cytologic diagnosis of salivary gland tumors by aspiration biopsy. Acta Cytol 1973;17:351–354.
271 Perzin KH, LiVolsi VA: Acinic cell carcinomas arising in salivary glands: A clinicopathologic study. Cancer 1979;44:1434–1457.
272 Pieterse AS, Seymour AE: Parotid cysts: An analysis of 16 cases and suggested classification. Pathology 1981;13:225–234.
273 Pinto RG, Couto F, Mandreker S: Infarction after fine needle aspiration. A report of four cases. Acta Cytol 1996;40:739–741.
274 Pisharodi LR: Basal cell adenocarcinoma of the salivary gland. Diagnosis by fine-needle aspiration cytology. Am J Clin Pathol 1995; 103:603–608.
275 Pisharodi LR: Low grade papillary adenocarcinoma of minor salivary gland origin. Diagnosis by fine needle aspiration cytology. Acta Cytol 1997;41:1407–1411.
276 Pitman MB: Mucoepidermoid carcinoma ex pleomorphic adenoma of the parotid gland. Acta Cytol 1995;39:604–606.
277 Qizilbash AH, Sianos J, Young JEM, Archibald SD: Fine needle aspiration biopsy cytology of major salivary glands. Acta Cytol 1985;29:503–512.
278 Qizilbash AH, Young JEM: Clear-cell carcinoma; in Kline TS (ed): Guides to Clinical Aspiration Biopsy. Head and Neck. New York, Igaku-Shoin, 1988, pp 99–100.
279 Qizilbash AH, Young JEM: Salivary glands; in Qizilbash AH, Young JEM (Eds): Guides to Clinical Aspiration Biopsy. Head and Neck. New York, Igaku-Shoin, 1988, pp 15–116.
280 Quintarelli G: Histochemical identification of salivary mucins. Ann NY Acad Sci 1963;106: 339–363.
281 Raab SS, Thomas PA, Cohen MB: Fine-needle aspiration biopsy of salivary gland mycoses. Diagn Cytopathol 1994;11:286–290.
282 Rajan PB, Wadehra V, Hemming JD, Hawkesford JE: Fine needle aspiration cytology of malignant oncocytoma of the parotid gland – A case report. Cytopathology. 1994;5: 110–113.
283 Rana RS, Dey P, Das A: Fine needle aspiration cytology of extra-adrenal paragangliomas. Cytopathology 1997;8:108–113.
284 Raubenheimer EJ, van Heerden FP, Thein T: Tyrosine-rich crystalloids in a polymorphous low-grade adenocarcinoma. Oral Surg Oral Med Oral Pathol 1990;70:480–482.
285 Regezi JA, Lloyd RV, Zarbo RJ, McClatchey KD: Minor salivary gland tumors: A histologic and immunohistochemical study. Cancer 1985;55:108–115.
286 Richardson GS, Clairmont AA, Erickson ER: Cystic lesions of the parotid gland. Plast Reconstr Surg 1978;61:364–370.
287 Rios Martín JJ, Otal Salaverri C, Gonzáles-Cámpora R: Intraparotid *Leishmania donovani* lymphadenitis: Diagnosis by fine needle aspiration. Acta Cytol 1993;37:843–845.
288 Robins DB, Katz RL, Swan F, Atkinson EN, Ordonez NG, Huh YO: Immunotyping of lymphoma by fine-needle aspiration. A comparative study of cytospin preparations and flow cytometry. Am J Clin Pathol 1994;101: 569–576.
289 Rollins CE, Yost BA, Costa MJ, Vogt PJ: Squamous differentiation in small-cell carcinoma of the parotid gland. Arch Pathol Lab Med 1995;119:183–185.
290 Royer B, Cazals-Hatem D, Sibilia J, Agbalika F, Cayuela JM, Soussi T, Maloisel F, Clauvel JP, Brouet JC, Mariette X: Lymphomas in patients with Sjögren's syndrome are marginal zone B-cell neoplasms, arise in diverse extranodal and nodal sites, and are not associated with viruses. Blood 1997;15:766–775.
291 Ryan JR, Ioachim HL, Marmer J, Loubeau JM: Acquired immune deficiency syndrome-related lymphadenopathies presenting in the salivary gland lymph nodes. Arch Otolaryngol 1985;111:554–556.
292 Safneck JR, Ravinski E, Yazdi HM, Nason RW, Dort JC, Anderson BJ: Fine needle aspiration biopsy findings in lymphoepithelial carcinoma of salivary gland. Acta Cytol 1997;41:1023–1030.
293 Sahlin P, Mark J, Stenman G: Detection of hidden structural rearrangments by FISH in pleomorphic adenomas. Genes Chromosomes Cancer 1995;12:81–86.
294 Salomão DR, Sigman JD, Greenebaum E, Cohen MB: Rhabdomyosarcoma presenting as a parotid gland mass in pediatric patients. Fine-needle aspiration biopsy findings. Cancer 1998;84:245–251.
295 Schoenmarker EFPM, Wanschura S, Mols R, Bullerdiek J, Van der Berghe H, Vand de Ven WJM: Recurrent rearrangments in the high mobility group protein gene, HMGI-C, in benign mesenchymal tumors. Nat Genet 1995; 10:436-443.
296 Schulman J, Waisman J, Morledge D: Sebaceous carcinoma of the parotid gland. Arch Otolaryngol 1973;98:417–421.
297 Sciubba JJ: Salivary epithelial-myoepithelial carcinomas of intercalated ducts: A clinical, electron microscopic, and immunocytochemical study. Oral Surg. Oral Med Oral Pathol 1985;59:482–490.
298 Seifert G: Bilateral mucoepidermoid carcinomas arising in bilateral pre-existing Warthin's tumours of the parotid gland. Oral Oncol 1997;33:284–287.
299 Seifert G: Classification and differential diagnosis of clear and basal cell tumors of the salivary glands. Seminars Diagn Pathol 1996;13: 95–103.
300 Seifert G: Histological typing of salivary gland tumours; in World Health Organization International Histological Classification of Tumours. Geneva, Springer, 1991.
301 Seifert G: Tumour-like lesions of the salivary glands. The new WHO classification. Pathol Res Pract 1992;188:836–846.
302 Seifert G, Donath K: On the pathogenesis of the Küttner tumor of the submandibular gland. Analysis of 349 cases with chronic sialadenitis of the submandibular. HNO 1977; 25:81–92.
303 Seifert G, Oehne H: Mesenchymal (non-epithelial) salivary gland tumors. Analysis of 167 tumor cases of the salivary gland register. Laryngol Rhinol Otol (Stuttg) 1986;65:485–491.
304 Sgrignoli A, Abati A, Pass H, Lebovics R, Hijazi Y: Metastatic mesothelioma presenting as a salivary gland neoplasm. Acta Cytol 1998; 42:818–820.
305 Shaha AR, Webber C, DiMaio T, Jaffe BM: Needle aspiration biopsy in salivary gland lesions. Am J Surg 1990;160:373–376.
306 Shin HJ, Caraway NP: Fine-needle aspiration biopsy of metastatic small cell carcinoma from extrapulmonary sites. Diagn Cytopathol 1998;19:177–181.
307 Simpson RH, Clarke TJ, Sarsfield PT, Babajews AV: Salivary duct adenocarcinoma. Histopathology 1991;18:229–235.
308 Simsir A, Fetsch P, Stetler-Stevenson M, Abati A: Immunophenotypic analysis of non-Hodgkin's lymphomas in cytologic specimens: A correlative study of immunocytochemical and flow cytometric techniques. Diagn Cytopathol 1999;20:278–284.
309 Sironi M, Taccagni G, Assi A: A cytologic, immunocytochemical and ultrastructural study of a malignant parotid gland myoepithelioma. Cytopathology 1997;8:53–62.
310 Sismanis A, Merriam JM, Kline TS, Davis RK, Shapshay SM, Strong MS: Diagnosis of salivary gland tumors by fine needle aspiration biopsy. Head Neck Surg 1981;3:482–489.
311 Skálová A, Michal M, Nathansky Z: Epidermoid carcinoma arising in Warthin's tumour: a case study. J Oral Pathol Med 1994;23:330–333.
312 Smith FB, Rajdeo H, Panesar N, Bhuta K, Stahl R: Benign lymphoepithelial lesion of the parotid gland in intravenous drug users. Arch Pathol Lab Med 1988;112:742–745.
313 Smith Frable MA, Frable WJ: Fine-needle aspiration biopsy of salivary glands. Laryngoscope 1991;101:245–249.
314 Sparrow SA, Frost FA: Salivary monomorphic adenomas of dermal analogue type: Report of two cases. Diagn Cytopathol 1993;9: 300–303.
315 Spiro RH: Salivary neoplasms: Overview of a 35-year experience with 2,807 patients. Head Neck Surg 1986;8:177–184.

316 Spiro RH. Strong EW, Huvos AG: Adenocarcinoma of salivary origin. Clinicopathologic study of 204 patients. Am J Surg 1982;144: 423–431.
317 Stanley MW, Bardales RH, Beneke J, Korourian S, Stern SJ: Sialolithiasis. Differential diagnostic problems in fine-needle aspiration cytology. Am J Clin Pathol 1996;106:229–233.
318 Stanley MW, Bardales RH, Farmer CE, Frierson HF, Suhrland M, Powers CN, Rollins SD: Primary and metastatic high-grade carcinomas of the salivary glands: A cytologic-histologic correlation study of twenty cases. Diagn Cytopathol 1995;13:37–43.
319 Stanley MW, Horwitz CA, Bardales RH, Stern SJ, Korourian S: Basal cell carcinoma metastatic to the salivary glands: Differential diagnosis in fine-needle aspiration cytology. Diagn Cytopathol 1997;16:247–252.
320 Stanley MW, Horwitz CA, Henry MJ, Burton LG, Lowhagen T: Basal-cell adenoma of the salivary gland: A benign adenoma that cytologically mimics adenoid cystic carcinoma. Diagn Cytopathol 1988;4:342–346.
321 Stanley MW, Horwitz CA, Rollins SD, Powers CN, Bardales RH, Korourian S, Stern SJ: Basal cell (monomorphic) and minimally pleomorphic adenomas of the salivary glands. Distinction from the solid (anaplastic) type of adenoid cystic carcinoma in fine-needle aspiration. Am J Clin Pathol 1996;106:35–41.
322 Stanley MW, Lowhägen T: Mucin production by pleomorphic adenomas of the parotid gland: A cytologic spectrum. Diagn Cytopathol 1990;6:49–52.
323 Stanley MW, Skoog L, Tani EM, Horwitz CA: Nodular fasciitis: Spontaneous resolution following diagnosis by fine-needle aspiration. Diagn Cytopathol 1993;9:322–324.
324 Stewart CJ, Hamilton S, Brown IL, MacKenzie K: Salivary epithelial-myoepithelial carcinoma: Report of a case misinterpreted as pleomorphic adenoma on fine needle aspiration. Cytopathology 1997;8:203–209.
325 Takeda Y: Crystalloid granuloma of the parotid gland: A previously undescribed salivary gland lesion. J Oral Pathol Med 1991;20: 234–236.
326 Takeda Y: Crystalloids with calcareous deposition in the parotid gland: One of the possible causes of development of salivary calculi. J Oral Pathol 1986;15:459–461.
327 Tao LC, Gullane PJ: HIV infection-associated lymphoepithelial lesions of the parotid gland: Aspiration biopsy cytology, histology, and pathogenesis. Diagn Cytopathol 1991;7:158–162.
328 Thomas K, Hutt MS: Tyrosine crystals in salivary gland tumours. J Clin Pathol 1981;34: 1003–1005.
329 Thompson MB, Nestok BR, Gluckman JL: Fine needle aspiration cytology of lymphoepithelioma-like carcinoma of the parotid gland. A case report. Acta Cytol 1994;38:782–786.
330 Torlakovic E, Ames ED, Manivel JC, Stanley MW: Benign and malignant neoplasms of myoepithelial cells: Cytologic findings. Diagn Cytopathol 1993;9:655–660.
331 Ulirsch RC, Jaffe ES: Sjögren's syndrome-like illness associated with the acquired immunodeficiency syndrome-related complex. Hum Pathol 1987;18:1063–1068.
332 Van der Wal JE, Carter RL, Klijanienko J, Micheau C, Rilke F, Seifert G, Van der Waal I: Histological re-evaluation of 101 intraoral salivary gland tumors by an EORTC study group. J Oral Pathol Med 1993;22:21–22.
333 Van Krieken JH: Prostate marker immunoreactivity in salivary gland neoplasms. A rare pitfall in immunohistochemistry. Am J Surg Pathol 1993;17:410–414.
334 Vellios F, Shafer WG: Tumors of the intraoral accessory salivary glands. Surg Gynecol Obstet 1959;198:450–456.
335 Vielh P: Guides to Clinical Aspiration Biopsy. Flow Cytometry. New York, Igaku-Shoin, 1991.
336 Viguer JM, Vicandi B, Jiménez-Heffernan JA, López-Ferrer P, Limeres MA: Fine needle aspiration cytology of pleomorphic adenoma. An analysis of 212 cases. Acta Cytol 1997; 41:786–794.
337 Von Haam E: A comparative study of the accuracy of cancer cell detection by cytologic methods. Acta Cytol 1962;6:508–518.
338 Watanabe K, Ono N, Saito K, Saito A, Suzuki T: Fine-needle aspiration cytology of polymorphous low-grade adenocarcinoma of the tongue. Diagn Cytopathol 1999;20:167–169.
339 Wax T, Layfield LJ: Epithelial-myoepithelial cell carcinoma of the parotid gland: A case report and comparison of cytologic features with other stromal, epithelial, and myoepithelial cell containing lesions of the salivary glands. Diagn Cytopathol 1996;14:298–304.
340 Webb AJ: Cytologic diagnosis of salivary gland lesions in adult and pediatric surgical patients. Acta Cytol 1973;17:51–58.
341 Weinberger MS, Rosenberg WW, Meurer WT, Robbins KT: Fine needle aspiration of parotid gland lesions. Head Neck 1992;14: 483–487.
342 Whitlatch SP: Psammoma bodies in fine-needle aspiration biopsies of acinic cell tumor. Diagn Cytopathol 1986;2:268–269.
343 Williams SB, Foss RD, Ellis GL: Inflammatory pseudotumors of the major salivary glands. Clinicopathologic and immunohistochemical analysis of six cases. Am J Surg Pathol 1992;16:896–902.
344 Woyke S, Jach K: Epithelial-myoepithelial tumor of the salivary gland. Cytologic and histologic features. Patol Pol 1991;42:71–72.
345 Woyke S, Olszewski W: Cytodiagnostyka aspiracyjna guzow slinianek. Patol Pol 1978;29: 303–312.
346 Woyke S, Olszewski W, Domagala W, Marzecki Z: Cytodiagnosis of acinic cell carcinoma. Ultrastructural study of material obtained by fine needle aspiration biopsy. Acta Cytol 1975;19:110–116.
347 Wu HHJ, Silvernagel SW: Fine-needle aspiration cytology of an oncocytic carcinoma of the submandibular gland. Diagn Cytopathol 1998;19:186–189.
348 Yamamoto Y, Virmani AK, Wistuba II, McIntire D, Vuitch F, Albores-Saavedra J, Gazdar AF: Loss of heterozygosity and microsatellite alterations in p53 and Rb genes in adenoid cystic carcinoma of the salivary glands. Hum Pathol 1996;27:1204–1210.
349 Yang GCH, Schneck MJV, Hayden RE, Gupta PK: Merkel cell tumor-like neuroendocrine carcinoma associated with the submandibular gland. Report of a case with cytologic, immunohistochemical, electron microscopic and flow cytometric studies. Acta Cytol 1994; 38:742–746.
350 Young GC, Schneck MJ, Hayden RE, Gupta PK: Merkel cell tumor-like neuroendocrine carcinoma associated with the submandibular gland. Report of a case with cytologic, immunohistochemical, electron microscopic and flow cytometric studies. Acta Cytol 1994; 38:742–746.
351 Young JA, Smallman LA, Thompson H, Proops DW, Johnson AP: Fine needle aspiration cytology of salivary gland lesions. Cytopathology 1990;1:25–33.
352 Zajdela A, de Maublanc MA, Schlienger P, Haye C: Cytologic diagnosis of orbital and periorbital palpable tumors using fine-needle sampling without aspiration. Diagn Cytopathol 1986;2:17–20.
353 Zajicek J: Salivary glands; in Monographs in Clinical Cytology. Aspiration Biopsy Cytology. Part I. Cytology of Supradiaphragmatic Organs. Basel. Karger, 1974, pp 37–38.
354 Zajicek J, Eneroth CM, Jakobson P: Aspiration biopsy of salivary gland tumors. VI. Morphologic studies on smears and histologic sections from mucoepidermoid carcinoma. Acta Cytol 1976;20:35–41.
355 Zarbo RJ, Regezi JA, Batsakis JG: S-100 protein in salivary gland tumors: An immunohistochemical study of 129 cases. Head Neck Surg 1986;8:268–275.
356 Zarbo RJ, Regezi JA, Hatfield JS, Maisel H, Trojanowski JQ, Batsakis JG, Crissman JD: Immunoreactive glial fibrillary acidic protein in normal and neoplastic salivary glands: A combined immunohistochemical and immunoblot study. Surg Pathol 1988;1:55–63.
357 Zocchi M, Nicosia G, Ramponi A, Pisani P, Boldorini R: Myoepithelial-epithelial carcinoma of the parotid: Cyto-histological description of a case. Pathologica 1995;87:534–538.
358 Zurrida S, Alasio L, Tradati N, Bartoli C, Chiesa F, Pilotti S: Fine-needle aspiration of parotid masses. Cancer 1993;72:2306–2311.

Index

Acinic cell carcinoma 91
– diagnostic accuracy 95
– differential diagnosis 95
Adenocarcinoma, not otherwise specified 77
Adenoid cystic carcinoma 59
– diagnostic accuracy 59
– differential diagnosis 59
Adenolymphoma 31
Adenosquamous carcinoma 114
AIDS, *see* Lymphoepithelial lesions
Angiosarcoma 109
Atypical, Warthin's tumour 34

Basal cell adenocarcinoma 101
– diagnostic accuracy 104
– differential diagnosis 104
Basal cell adenoma 38
– diagnostic accuracy 41
– differential diagnosis 41
Basaloid-squamous carcinoma 114
Benign lymphoepithelial lesion, *see* Lymphoepithelial lesions

Canalicular adenoma, *see* Basal cell adenoma
Carcinoma ex pleomorphic adenoma 80
– diagnostic accuracy 84
– differential diagnosis 84
Carcinoma ex Warthin's tumour 36, 72
Carcinosarcoma 85
– diagnostic accuracy 85
– differential diagnosis 85
Cellular, pleomorphic adenoma 25
Chondromyxoid, pleomorphic adenoma 25
Chordoma 114
Chronic sclerosing sialadenitis, *see* Küttner's tumour
Clear cell carcinoma, *see* Epithelial-myoepithelial carcinoma
Cystadenocarcinoma, papillary, *see* Papillary cystadenocarcinoma
Cystadenomas 46
– mucinous 46
– papillary 46
Cystic lymphoid hyperplasia, *see* Lymphoepithelial lesions
Cysts 125
– diagnostic accuracy 125
– differential diagnosis 125
Ductal papilloma 45

Epithelial-myoepithelial carcinoma 64
– diagnostic accuracy 66
– differential diagnosis 66
Epstein-Barr virus 56

Fasciitis, nodular 106
Fibrosarcoma 109

Haemangioma 106
Haemangiopericytoma, malignant 109
HIV, *see* Lymphoepithelial lesions
Hodgkin's lymphoma, *see* Lymphomas
Hyalinizing clear cell carcinoma 64

Intraductal papilloma 45
Inverted ductal papilloma 45

Küttner's tumour, 127
– diagnostic accuracy 127
– differential diagnosis 129

Large cell undifferentiated carcinoma 56
– diagnostic accuracy 56
– differential diagnosis 56
Lipoma 106
Lymphangioma 106
Lymphoepithelial lesions 123
– diagnostic accuracy 125
– differential diagnosis 127
Lymphoepithelial carcinoma 56
– diagnostic accuracy 58
– differential diagnosis 58
Lymphoepithelial sialadenitis, *see* Lymphoepithelial lesions
Lymphomas 115
– diagnostic accuracy 115
– differential diagnosis 115

Malherbe calcifying epithelioma, *see* Pilomatrixoma
Malignant fibrous histiocytoma 109
Malignant mixed tumour, *see* Carcinoma ex pleomorphic adenoma
Malignant myoepithelioma 69
– diagnostic accuracy 69
– differential diagnosis 69
Malignant oncocytoma 71
– diagnostic accuracy 71
– differential diagnosis 71
Malignant Warthin's tumour
see Carcinoma ex Warthin's tumour
MALT, *see* Lymphomas
Mesenchymal tumours, benign 106
– diagnostic accuracy 106
– differential diagnosis 106
Mesenchymal tumours, malignant 106
– diagnostic accuracy 114
– differential diagnosis 114
Metaplastic, pleomorphic adenoma 28
Metastasizing pleomorphic adenoma 29
Metastatic, *see* Secondary tumours
Mixed tumour, metastasizing, *see* Metastasizing pleomorphic adenoma
Mixed tumour, *see* Pleomorphic adenoma
Mucinous adenocarcinoma 80
Mucinous cystadenomas 46
Mucoepidermoid carcinoma, high-grade 47
– diagnostic accuracy 52
– differential diagnosis 52
Mucoepidermoid carcinoma, low-grade 86
– diagnostic accuracy 89
– differential diagnosis 90
Mucoid, in pleomorphic adenoma 28
Mucosa-associated lymphoid tissue, *see* Lymphomas
Mycoses 130
Myoepithelial adenoma 29
Myoepithelial carcinoma, *see* Malignant myoepithelioma
Myoepithelial sialadenitis, *see* Lymphoepithelial lesions
Myoepithelial, pleomorphic adenoma 25
Myoepithelioma 29
– diagnostic accuracy 29
– differential diagnosis 29

Necrotizing sialometaplasia 123
– diagnostic accuracy 123
– differential diagnosis 123
Nodular fasciitis 106
Non-Hodgkin's lymphoma, *see* Lymphomas

Oncocytic adenoma, *see* Oncocytoma
Oncocytic carcinoma, *see* Malignant oncocytoma
Oncocytoma 36
– diagnostic accuracy 36
– differential diagnosis 36
Oncocytosis, *see* Oncocytoma

Papillary cystadenocarcinoma 100
– diagnostic accuracy 100
– differential diagnosis 100
Papillary cystadenoma lymphomatosum, *see* Warthin's tumour
Papillary cystadenoma 46
Papilloma, ductal, *see* Ductal papilloma
Papilloma, inverted ductal, *see* Ductal papilloma
Paraganglioma 114
Pilomatrixoma 114
Pleomorphic adenoma 22
– chondromyxoid 25
– cellular 25
– myoepithelial 25
– metaplastic 28
– diagnostic accuracy 28
– differential diagnosis 28
– tyrosine-rich crystalloids 28
– with mucoid 28
– metastasizing 29
Polymorphous low-grade adenocarcinoma 96
– diagnostic accuracy 97
– differential diagnosis 99

Rhabdomyosarcoma 109

Salivary duct carcinoma 73
– diagnostic accuracy 75
– differential diagnosis 76
– low-grade 75
– oncocytic-like 75
Sarcoidosis 130
Sarcomas 109
Schwannoma
– benign 106
– malignant 109
Sebaceous adenoma 43
Sebaceous carcinoma 72
Sebaceous lymphadenocarcinoma, *see* Sebaceous carcinoma
Sebaceous lymphadenoma, Sebaceous adenoma
Secondary tumours 118
– diagnostic accuracy 120
– differential diagnosis 120
Sialadenosis 121
– diagnostic accuracy 121
– differential diagnosis 121
Sialadenitis, chronic sclerosing, *see* Küttner's tumour
Sialadenoma papilliferum 45
Sialometaplasia, necrotizing, *see* Necrotizing sialometaplasia
Sjögren's syndrome, *see* Lymphoepithelial lesions
Small cell carcinoma 78
– diagnostic accuracy 78
– differential diagnosis 78
Squamous cell carcinoma, primary 52
– diagnostic accuracy 53
– differential diagnosis 55
Squamous cell carcinoma, secondary, *see* Secondary tumours

Terminal duct carcinoma, *see* Polymorphous low-grade adenocarcinoma
True malignant mixed tumour, *see* Carcinosarcoma
Tuberculosis 130
Tumour-like lesions 121
Tyrosine-rich crystalloids, in pleomorphic adenoma 28

Undifferentiated carcinoma 56

Warthin's tumour 31
– diagnostic accuracy 34
– differential diagnosis 34
– atypical (squamous cells) 34
– malignant 36, 72