Basic Intraoperative TEE Exam

Department of Anesthesiology | Perioperative Echocardiography

★ = Tested on ABA Advanced Cardiac Anesthesia Exam | Views in standard acquisition sequence

Image Optimization Checklist
1. Good ECG signal
2. Patient information entered correctly
3. Focus — just distal to structure of interest
4. Gain — blood appears just black; random color just disappears
5. Nyquist — set at 50–60 cm/s for color Doppler
6. Review study to confirm images captured well

Midesophageal AV Short Axis ★

~45° | Depth ~8 cm

Goal: Rule out aortic stenosis; evaluate structural AV abnormalities

- Center the valve; advance/withdraw to visualize coaptation
- Use multiplane angle for symmetrical cusp display
- Check bi- vs. tri-leaflet morphology, excursion, and coaptation
- Assess for sclerocalcific changes
- Add ~90° to multiplane angle for next view

CFD: not routinely used in this view

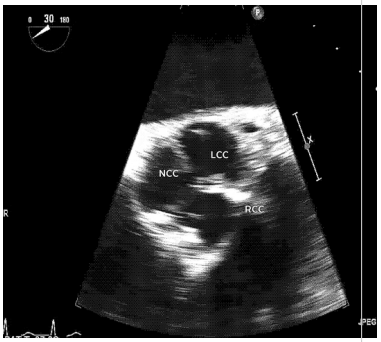

Midesophageal AV Long Axis ★

130°–140° | Depth ~8 cm

Goal: Rule out AS, AI, type A dissection, dynamic LVOT obstruction

- Keep LA-MV-LV pathway open with probe rotation
- Locate AV using multiplane adjustment
- Rotate R/L until leaflet excursion is clear and central, sinuses symmetric
- Assess coaptation, degree of calcification, and aortic root size
- Slight decrease in multiplane, slight right turn, increase depth for next view

CFD: look for AI; Y-sign suggests LVOT obstruction

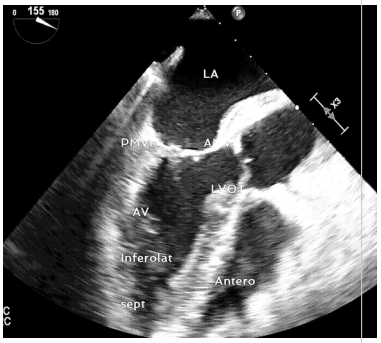

Midesophageal Bicaval ★

90°–110° with right turn | Depth ~12 cm

Goal: Evaluate for ASD, SVC collapse; monitor wire advancement

- Rotate to visualize fossa ovalis clearly
- Withdraw probe to see SVC; advance for IVC/coronary sinus
- Scan through entire septum
- Turn left and decrease multiplane for next view

CFD: fossa ovalis for ASD — do not reduce Nyquist; IVC may not be visible

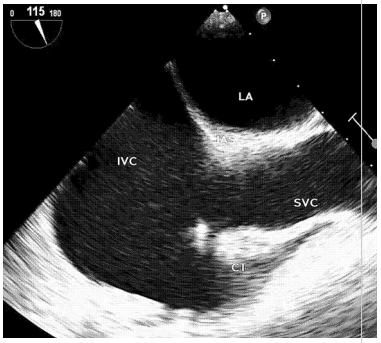

Midesophageal RV Inflow/Outflow

55°–75° | Depth ~12 cm

Goal: Evaluate RV structure/function, TV, PV; track PA catheter

- Confirm simultaneous visualization of RA/RV/PV/PA
- Decrease multiplane, advance slightly, increase depth for next view

CFD: apply to PV (not TV in this view)

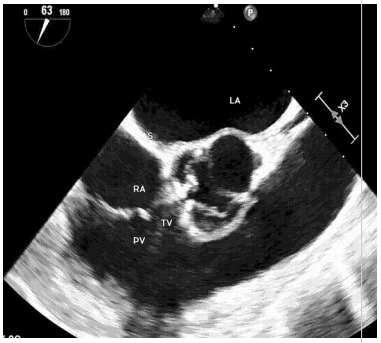

Midesophageal RV-Focused 4 Chamber

0°–20° | Depth ~16 cm (apex just visible)

Goal: Assess RV size and function, RA size, tricuspid regurgitation

- Normal TAPSE > 1.6 cm
- CFD on TV; advance and withdraw to scan valve
- Rotate left, center LV on screen for next view

Foreshortening pitfall: confirm apex is fully visible

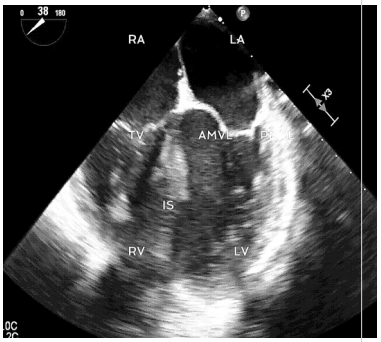

Midesophageal LV-Focused 4 Chamber ★

0°–20° | Depth ~16 cm (apex just visible)

Goal: Assess LV inferoseptal and anterolateral walls, global LV function, LV/LA size, MR

- Advance, retroflex, and increase angle to eliminate LVOT and foreshortening
- CFD on MV; advance and withdraw to scan valve
- Position LV center of screen; increase multiplane for next view

Ensure apex is not foreshortened before assessing function

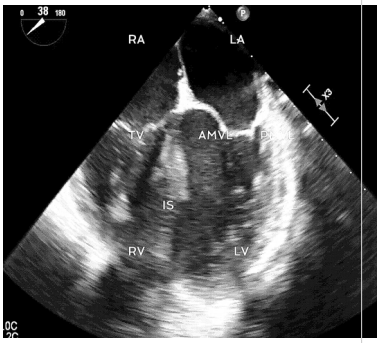

Midesophageal 2 Chamber ★

80°–90° | Depth ~16 cm

Goal: Assess anterior and inferior walls (AAA rule), apex, rule out LAA thrombus

- Identify SAX coronary sinus on left (check for cannula) and LAA on right
- LV "lengthening" or excess apical motion suggests foreshortening
- Increase multiplane for next view

LAA thrombus: assess carefully before cardioversion

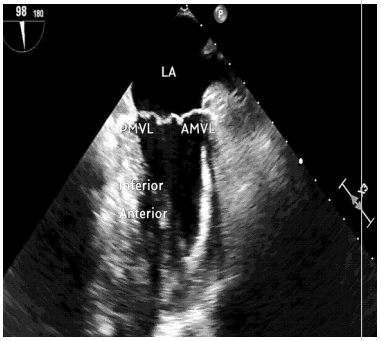

Midesophageal Long Axis ★

130°–140° | Depth ~16 cm

Goal: Assess anteroseptal and inferolateral walls

- Should visualize LVOT, MV, AV — typically no papillary muscles
- Decrease multiplane, advance into stomach, gentle anteflexion for next view

Confirm LVOT diameter here if needed for stroke volume calculation

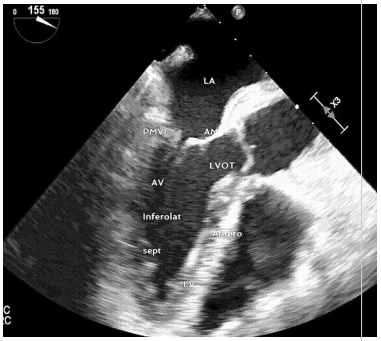

Transgastric Mid Short Axis ★

0° | Always at ~12 cm depth

Goal: Evaluate global and regional LV systolic function, preload, afterload

- Advance and anteflex gently to contact stomach wall
- Confirm both papillary muscles are visible
- Evaluate wall thickening in each segment (all coronary distributions represented)
- Center LV; increase multiplane for next view (can use x-plane)

Assess wall thickening, not just motion — motion alone may be misleading

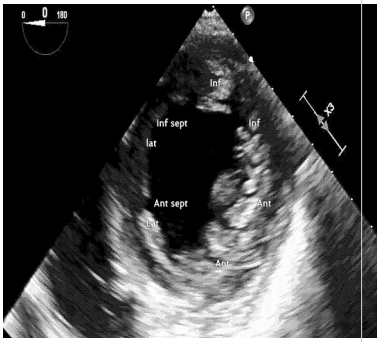

Transgastric 2 Chamber ★

90° | Depth ~10 cm

Goal: Evaluate LV size and thickness; assess anterior and inferior walls

- Rotate to ensure maximal LV diameter
- Minimize foreshortening with multiplane adjustment
- Return to 0°, rotate left, and withdraw for next view

Useful for LV wall thickness measurements

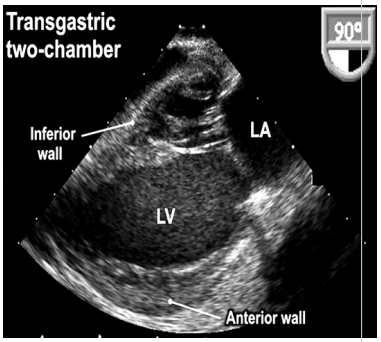

Descending Aorta Short Axis ★

0° | Decrease depth, maximize MHz

Goal: Screen for aortic plaque, dissection, pleural effusion

- Do not decrease depth so much that a left pleural effusion is missed
- Withdraw probe to aortic arch; rotate back right; advance to ME window

Severe plaque: mobile or diameter ≥ 0.5 cm

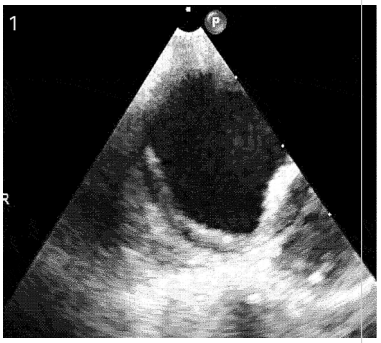

Echo images courtesy of showmethepocus.com. Probe position, depth, and multiplane angle are approximate — adjust per patient anatomy. For educational use.