Universiteit Leiden
The Netherlands

Mitral valve replacement with the 15-mm mechanical valve: a 20-year multicenter rxperience

IJsselhof, R.J.; Slieker, M.G.; Hazekamp, M.G.; Accord, R.; Wetten, H.V.; Haas, F.; Schoof, P.H.

Citation
IJsselhof, R. J., Slieker, M. G., Hazekamp, M. G., Accord, R., Wetten, H. V., Haas, F., & Schoof, P. H. (2020). Mitral valve replacement with the 15-mm mechanical valve: a 20-year multicenter rxperience. *The Annals Of Thoracic Surgery, 110*(3), 956-961. doi:10.1016/j.athoracsur.2019.11.050

Version: Publisher's Version
License: Creative Commons CC BY 4.0 license
Downloaded from: https://hdl.handle.net/1887/3184011

Note: To cite this publication please use the final published version (if applicable).

Mitral Valve Replacement With the 15-mm Mechanical Valve: A 20-Year Multicenter Experience

Rinske J. IJsselhof, MD, Martijn G. Slieker, MD, PhD, Mark G. Hazekamp, MD, PhD, Ryan Accord, MD, Herbert van Wetten, MD, Felix Haas, MD, PhD, and Paul H. Schoof, MD, PhD

Division of Pediatrics, Department of Pediatric Cardiac Surgery, University Medical Center Utrecht, Utrecht, The Netherlands; Division of Pediatrics, Department of Pediatric Cardiology, University Medical Center Utrecht, Utrecht, The Netherlands; Division Heart and Lung, Department of Cardiothoracic Surgery, Leiden University Medical Center, Leiden, The Netherlands; Division Heart and Lung, Department of Cardiothoracic Surgery, University Medical Center Groningen, Groningen, The Netherlands; and Division Heart and Lung, Department of Cardiothoracic Surgery, Radboud University Medical Center, Nijmegen, The Netherlands

Background. **The aim of this study was to evaluate early and long-term outcomes (mortality and prosthetic valve replacement) after mitral valve replacement with the 15-mm St Jude Medical prosthesis (St Jude Medical, St Paul, MN).**

Methods. **A multicenter, retrospective cohort study was performed among patients who underwent mitral valve replacement with a 15-mm St Jude Medical Masters prosthesis at 4 congenital cardiac centers in The Netherlands. Operative results were evaluated and echocardiographic data studied at 0.5, 1, 2, 3, 5, and 10 years after surgery.**

Results. **Surgery was performed in 17 infants. Ten patients (59%) were treated in the intensive care unit before surgery; 8 (47%) were on ventilator support. Median age at surgery was 3.2 months (interquartile range [IQR], 1.2-5.6), and median weight was 5.2 kg (IQR 3.9-5.7). There was 1 early cardiac death and 1 late noncardiac death. Median follow-up time was 9.6 years (IQR, 2.4-13.2), including 8 patients with a follow-up more than 10 years. The first prosthetic valve explantation (n = 11) occurred at a median of 2.9 years (IQR, 2.0-5.4). Other reinterventions were permanent pacemaker implantation (n = 3), subaortic stenosis resection (n = 2), and paravalvular leak repair (n = 1). Prosthetic valve gradients increased from a mean of 5.0 mm Hg (at discharge) to a mean of 14.3 mm Hg (at 5-year follow-up).**

Conclusions. **Mitral valve replacement with the 15-mm prosthesis can safely be performed in infants and even in neonates. Median freedom from prosthesis replacement for outgrowth is 3.5 years. Thromboembolic complications were rare.**

(Ann Thorac Surg 2020;110:956-61)
© 2020 by The Society of Thoracic Surgeons

Mitral valve replacement (MVR) may be the only bailout option in infants with irreparable atrioventricular (AV) valve stenosis or regurgitation.[1] Prosthetic valves > 17 mm have long been the only available option for MVR, but these prostheses are often too large for infants and neonates. In contrast the stented bovine jugular vein graft valve (Melody; Medtronic, Minneapolis, MN) has been shown to be a promising alternative.[2] However this valve is expensive and not designed to be surgically implanted (because it has a high profile and no sewing ring) with a risk of causing left ventricular outflow tract obstruction, leaving paravalvular leak, or creating pulmonary vein obstruction.[3,4] Fortunately a size-reduced, 15-mm bileaflet mechanical prosthesis has been introduced that is less expensive, designed for surgical use, and can be implanted with straightforward surgical techniques.[5] Conceivably this valve has a limited longevity because of increasing patient–prosthesis mismatch in the growing child and requires the use of anticoagulants.

The dime-sized, 15-mm prosthetic heart valve, the Abbott St Jude Medical (SJM) Masters HP 15-mm (SJM, St Paul, MN) (Figure 1), has been tested clinically (valve-related adverse events through 12 months after implant in 20 subjects with a mean follow-up duration of 10.4 months) and was subsequently approved by the US Food and Drug Administration.[5] Long-term follow-up data are not available. However this particular prosthesis was already clinically available for off-label use in The Netherlands since 1998. We studied our nationwide long-term experience with up to 20 years of follow-up with this particular valve in the mitral position in infants and neonates.

Material and Methods

Study Design

A multicenter, retrospective cohort study was performed among patients who underwent MVR with a 15-mm SJM

Accepted for publication Nov 25, 2019.

Presented at the Poster Session of the Fifty-sixth Annual Meeting of The Society of Thoracic Surgeons, New Orleans, LA, Jan 25-28, 2020.

Address correspondence to Dr IJsselhof, Department of Pediatric Cardiac Surgery, University Medical Center Utrecht, Lundlaan 6, 3584 EA, Utrecht, The Netherlands; email: r.j.ijsselhof@umcutrecht.nl.

© 2020 by The Society of Thoracic Surgeons
Published by Elsevier Inc.

0003-4975/$36.00
https://doi.org/10.1016/j.athoracsur.2019.11.050

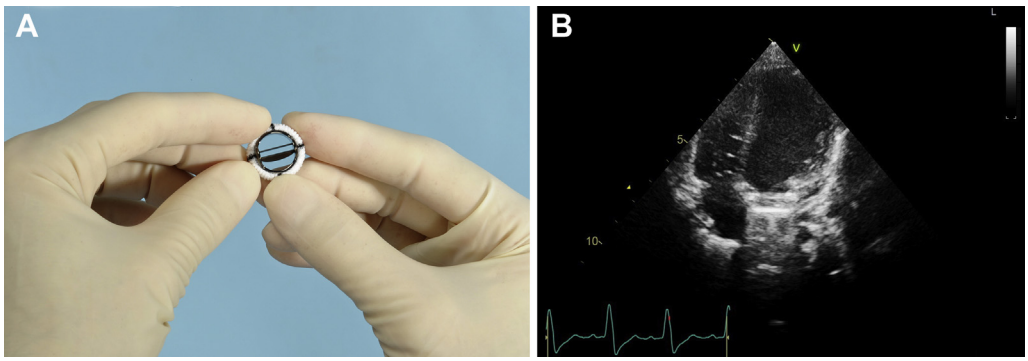

Figure 1. (A) Abbott St Jude Medical Masters HP 15-mm prosthesis. (B) A 15-mm prosthesis implanted at the supraannular level.

Masters prosthesis between January 1, 1998 and December 31, 2018. Four Dutch congenital heart centers participated, including university medical centers in Groningen, Leiden, Nijmegen, and Utrecht. Approval was obtained from the institutional review board at each center, with a waiver of informed consent obtained before data collection. Clinical and echocardiographic data were collected.

Patients

We identified 17 patients who received 18 MVRs using the 15-mm SJM Masters prosthesis. All patients were included for analysis because they met our inclusion criteria of receiving a 15-mm SJM Masters prosthesis.

Surgical Technique

Transseptal access to the left AV valve was used in most patients (n = 15). To prepare implantation all valve tissue (except the posterior leaflet in 4 patients [24%]) was excised including the top of the papillary muscles, which has shown to potentially interfere with prosthetic valve opening.

Polytetrafluoroethylene pledget–supported (3 × 3 × 1.6 mm), 5-0 braided polyester (Ethibond Excel; Ethicon, Somerville, NY) sutures with an RB-2 needle were used in 9 patients and nonpledgetted sutures in 8. Pledgets were positioned on the ventricular side of the annulus. A small valve ridge was left in the posteroinferior angle to avoid the AV conduction tissue when placing sutures. Orientation of the valve was always "antianatomic" (90 degrees orthogonal to the native orientation). The decision for level of implantation was made during surgery based on annular size. Annular implantation was possible in 14 patients and supraannular in 3. Valve mobility was confirmed before the heart was closed and deaired.

Systemic Anticoagulation

Heparin (continuous infusion, 20 units/kg/h) was started right after surgery in the intensive care unit (ICU) with a target activated partial thromboplastin time ratio of 1.8 to 2.5. Anti-Xa factor levels were measured daily from day 1 with a target range of 0.1 to 0.4. Coumarin therapy (acenocoumarol or phenprocoumon) was started 24 hours after surgery. Heparin was stopped when the target international normalized ratio (INR; 2.5-3.5) was reached.[6] Patients did not use aspirin.

Data Collection

Collected data included basic demographic information, descriptive anatomic diagnoses, associated noncardiac or genetic anomalies, preoperative factors, echocardiographic data, surgical procedures, mortality, and other clinical adverse events and reinterventions. Procedural details were obtained from operative reports.

Outcomes

The primary outcomes evaluated were mortality and prosthesis replacement. Secondary outcomes were major adverse events, thromboembolic events, resource utilization (postoperative days on ventilator, postoperative ICU length of stay, and hospital length of stay), and echocardiographic function. Major adverse events were defined according to The Society of Thoracic Surgeons congenital heart surgery database.[7,8]

Postoperative days on the ventilator were defined as the total number of days on the ventilator after the index operation and included all reintubation days. Postoperative ICU length of stay was defined as total postoperative days in the ICU, including days readmitted to the ICU during hospitalization for the index operation.

Echocardiography

All echocardiographic studies were reviewed before surgery, at discharge, and 0.5, 1, 2, 3, 5, and 10 years after MVR. Measurements of the MV annulus, gradient and degree of valvular regurgitation, tricuspid regurgitation, and left ventricular function were performed by an experienced cardiologist applying the recommendations of the American Society of Echocardiography.[9,10]

Statistical Methods

Patient and procedural characteristics were summarized as frequencies and percentages for categorical variables and medians and interquartile ranges (IQRs) for continuous variables. Time to prosthesis replacement was estimated using the Kaplan-Meier method. Statistical analysis was performed with SPSS for Windows (version 25 (IBM Corp., Armonk, NY)).

Results

Patients

All 17 patients had the 15-mm prosthesis implanted in the mitral or left AV valve position (Table 1). Ten patients (59%) were treated in the ICU before surgery and 8 (47%) were on mechanical ventilator support. Median age at implantation was 3.2 months (IQR, 1.2-5.6; range, 1 day to 18 months). Indications for valve replacement included valvular regurgitation (moderate or greater) in 5 patients, valvular stenosis (moderate or greater) in 2, and both in 10. Eight patients (47%) had previous attempts of repair. Median time from repair to replacement was 1.1 months (IQR, 0.6-5.7).

Native Echocardiographic Valve Size

Median preoperative lateral and anterior-posterior left AV valve diameters were 12.0 mm (range, 8.0-16.6) and 12.6 mm (range, 10.6-16.4).

Surgical Technique

Procedural details and outcomes are outlined in Table 2. Median pump time was 111 minutes (IQR, 88-201) and median cross-clamp time 78 minutes (IQR, 61-113). Twelve patients (71%) underwent MVR during the first bypass run and 5 patients (29%) underwent MVR as a second-run procedure (failure of initial mitral valve repair, n = 4; iatrogenic mitral valve regurgitation [prolapse of the anterior mitral valve leaflet] after initial resection of subaortic stenosis, n = 1). At discharge the median echocardiographic Doppler gradient of the SJM Masters prosthesis was 4.5 mm Hg (IQR, 3.4 -6.0; range, 1.4-11.0), and (para)valvular regurgitation was absent in all patients.

Table 1. Patient and Procedural Characteristics (N = 17)

Characteristic	Value
Age at operation, mo	3.2 (1.2-5.6)
Female sex	9 (53)
Weight at surgery, kg	5.2 (3.9-5.7)
Prematurity	2 (12)
Neonate	3 (18)
Preoperative condition	
In intensive care unit	10 (59)
On ventilator support	8 (47)
Previous valve repair	
1 repair	7 (41)
2 repairs	1 (6)
Repair–replacement interval, mo	1.1 (0.6-5.7)
Diagnosis	
Mitral regurgitation (congenital or acquired)	3 (18)
Congenital mitral stenosis	1 (6)
Congenital mitral regurgitation and stenosis	5 (29)
Hypoplastic left heart complex	4 (24)
Atrioventricular canal defect	4 (24)
Genetics	
Trisomy 21	1 (6)
Kabuki syndrome	1 (6)

Values are n (%) or median (interquartile range).

Table 2. Operative Outcome Data

Variables	Value
Second bypass run	5 (29)
Posterior leaflet spared	4 (24)
Concomitant procedure[a]	6 (35)
Prosthetic valve level implant	
Annular	14 (82)
Supraannular	3 (18)
Condition at discharge	
Gradient, mm Hg	4.5 (3.4-6.0)
Absent regurgitation	17 (100)
Atrioventricular block requiring pacemaker	3 (18)
Outcome	
Mortality	2 (12)
Early death	1 (6)
Late death	1 (6)
Second mitral valve replacement	11 (65)
First and second replacement interval, y	2.9 (2.0-5.4)
Major adverse events[b]	8 (47)
Days on ventilator	8.0 (1.5-9.0)
Intensive care unit length of stay, days	10.0 (6.5-28.5)
Hospital length of stay, days	29.0 (17.5-43.5)
Follow-up, y	9.6 (2.4-13.2)

[a]Aortic valve repair, primary closure of ventricular septal defect, right atrioventricular valve repair, resection of subaortic stenosis, implantation of permanent pacemaker, coarctectomy with end-to-end anastomosis, Ross-Kono procedure; [b]Bleeding or mediastinitis requiring reoperation, unplanned reintervention before discharge, arrhythmia requiring placement of permanent pacemaker, cardiac arrest requiring resuscitation, renal failure requiring dialysis.

Values are n (%) or median (interquartile range).

Mortality

Early cardiac death occurred in 1 patient (6%). This non–Down syndrome patient had a partial AV septal defect and severe AV valve regurgitation. The patient had heart failure and underwent left AV valve replacement after attempted emergency repair at 1 day of age. The patient died a few hours after surgery because of poor left ventricular contractility despite adequate prosthetic function. Late death occurred in 1 non–Down syndrome patient (6%) 2.5 years after surgery and was attributed to pneumonia.

Prosthetic Valve Replacement

Eleven patients (65%) underwent prosthesis replacement. In all but 3 patients the 15-mm prostheses remained in place until the prostheses were found to be obstructive. This was the main indication for replacement. The median gradient before prosthesis replacement was 17.0 mm Hg (IQR, 10.0-20.5). Other indications for replacement were thrombosis in 2 and paravalvular leak in 1 patient. The median time to prosthetic valve replacement was 2.9 years (IQR, 2.0-5.4). Similar prostheses were used for replacement, with 19 mm the most commonly used size. Other sizes used were 15 mm (n = 1), 17 mm (n = 2), 21 mm (n = 2),

and 23 mm (n = 1). Larger prostheses during redo surgery were used in all cases except 1 (prosthesis replacement after 1 month because of thrombosis). Figure 2 represents the Kaplan-Meier survival analysis curve for prosthetic valve replacement. Median freedom from prosthesis replacement was 3.5 years. Other indications for reoperation were resection of subaortic stenosis (4 in 2 patients) and aortic valve replacement (2).

Major Adverse Events

Twelve major adverse events occurred in 8 patients (47%): 3 permanent pacemaker implantations, 2 unplanned reoperations before discharge, 2 renal failures requiring dialysis, 2 cardiac arrests requiring resuscitation, 2 bleeding events requiring reoperation, and 1 mediastinitis requiring reoperation. Patients had 1 (n = 5), 2 (n = 2), or 3 (n = 1) major adverse events.

Unplanned reoperation before discharge included repair of paravalvular leak (n = 1) and prosthetic valve replacement for thrombosis (n = 1). In the latter patient prosthetic valve impingement was seen on echocardiogram 1 week after operation. Despite optimal anticoagulant therapy the patient developed a valve thrombosis that was attributed to an impeded prosthetic opening due to subvalvular tissue remnants. The stuck prosthesis was replaced 4 weeks after surgery, and the patient remained free from subsequent thrombosis over the next 3 years (Table 3, patient 1).

Neonatal Cases

Patient 1 was diagnosed with congenital mitral stenosis and regurgitation and had respiratory insufficiency. The patient was intubated and admitted to the ICU on the day of birth and received a 15-mm MV prosthesis at 4 days of age. Resection of subaortic stenosis was performed 9 months after the index surgery. The patient was maintained with a 15-mm valve for 3.0 years, at which time a 21-mm SJM prosthesis was implanted and a second resection of subaortic stenosis performed. The patient remains well with the 21-mm prosthesis at age 15 years with a mean gradient of 8 mm Hg. Left ventricular function is good, and there are no signs of pulmonary hypertension.

Patient 2 was diagnosed with congenital mitral regurgitation and heart failure. The patient was intubated and on inotropic support immediately after birth. Our decision to give the patient a 15-mm MV prosthesis at 1 day of age was due to the patient's poor cardiac condition. The patient underwent a reoperation because of retrocardiac bleed causing tamponade. The patient was discharged home for 5 months and readmitted with a paravalvular leak. The prosthesis was replaced with a 17-mm SJM prosthesis. The patient received a second prosthesis replacement (25-mm SJM) 12.6 years after implantation of the 17-mm MVR. The child remains well with the 25-mm prosthesis at age 16 years with a mean gradient of 10.8 mm Hg. Left ventricular function is good, and there are no signs of pulmonary hypertension.

Patient 3 was diagnosed with a partial AV septal defect (non–Down syndrome) and severe AV valve regurgitation. The patient was in poor condition (heart failure) when he went for emergency AV septal defect repair at 1 day of age. The attempted left AV valve repair failed, and we decided to perform an MVR during second bypass run. The patient died a few hours after surgery because of poor left ventricular contractility despite adequate prosthetic function.

Follow-up

The median follow-up time was 9.6 years (IQR, 2.4-13.2). Four patients experienced a thromboembolic/bleeding event (Table 3). The median postoperative days on a

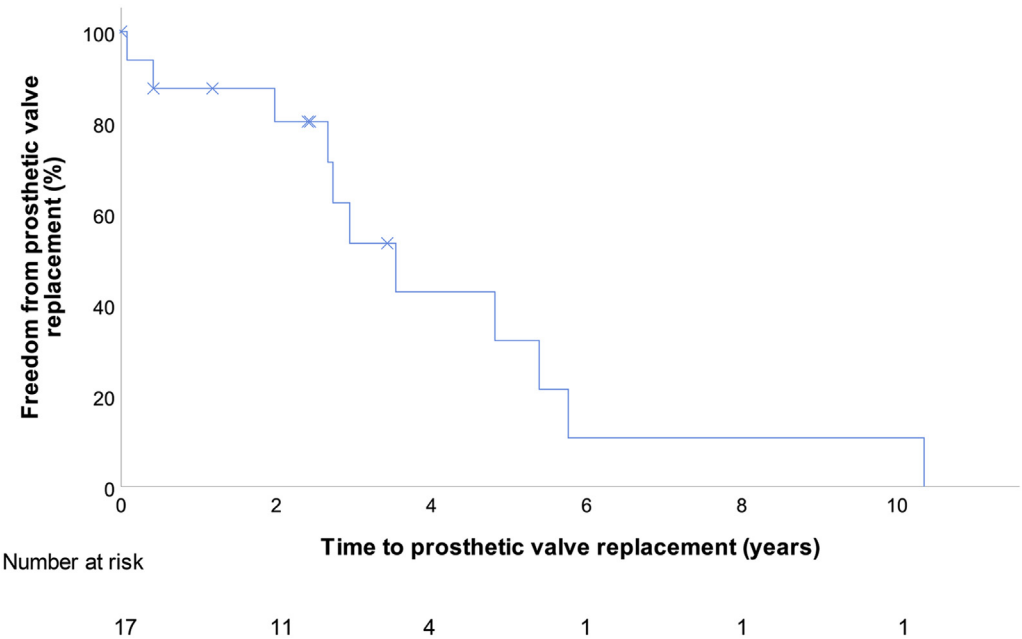

Figure 2. Kaplan-Meier estimate of time to prosthetic valve replacement. The number at risk at each time point is provided at the bottom of the figure.

Table 3. Thromboembolic and/or Bleeding Events

Patient No.	Events	Etiology	Time Since Valve Replacement (mo)	Anticoagulation	Persisting Neurologic Deficit
1	Prosthesis thrombosis	Prosthesis impingement	0.9	Fenprocoumon (INR, 3.1-4.5)	None
2	Prosthesis thrombosis	Anticoagulation (gastroenteritis)	22	Acenocoumarol (INR, 1.8-3.3)	Yes
3	Stroke[a]	Other[a]	6	Other[a]	Yes
4	Subdural hemorrhage	Anticoagulation (medication error)	3	Fenprocoumon (INR, 7)	Yes

[a]Perioperative stroke (Ross-Kono procedure with postoperative mechanical circulatory support).

INR, international normalized ratio.

ventilator was 8 (IQR, 1.5-9), and the median ICU length of stay was 10 days (IQR 6.5-28.5). All patients were in New York Heart Association functional class 1 at the last follow-up, and left ventricular function was good in 11 patients (73%), slightly below normal in 3 (20%), and severely below normal in 1 (7%). At last follow-up mild to moderate pulmonary hypertension was present in 4 patients (27%) and severe pulmonary hypertension in 1 patient.

Comment

The miniaturized 15-mm mechanical prosthesis may offer a favorable solution to critically ill infants who have no further options for valve repair. This small valve can be used in the smallest hearts, can be implanted with straightforward techniques, and lacks the drawbacks of the bovine jugular vein graft. It has been used in all involved Dutch centers with good early outcomes, with only 1 early dearth (6%), which occurred in a patient with a poor preoperative condition who died because of poor left ventricular contractility despite adequate prosthetic function. Early (6%) and late mortality (6%) in our cohort is in line with early (11%-42%)[11-14] and late mortality (0%-24%)[12,14,15] reported in studies in children undergoing mechanical MVR with a slightly larger prosthesis. Our mortality rate is not higher compared to the rate reported by Pluchinotta and colleagues,[16] who showed death rates of 12% (early) and 8% (late) in a recent multicenter study among 59 patients who underwent MVR with a Melody valve.

Reinterventions

One concern associated with prosthetic valve replacement in children is that a fixed-sized prosthesis is not accommodating for somatic growth of the patient. Our series shows that implantation of a 15-mm prosthesis helped infants and neonates to survive and be bridged a median of 3.5 years ahead until patient–prosthesis mismatch required the small prosthesis to be replaced. Prosthetic valve endocarditis was not reported. No mortality was observed during the prosthesis replacement. Several studies showed expanding of the mitral ring during growth even with a prosthesis, which allowed placement of a larger prosthesis during subsequent operations.[17-19] This is in line with our study, which shows the ability of placing larger prostheses during redo surgery in all cases except 1 (prosthesis replacement after 1 month because of thrombosis).

Another concern with MVR in small patients is the limitation posed by the small mitral annulus. In particular there is substantial concern about placement of a prosthetic valve that is larger than the annulus. Forcing too large a valve into the annulus has been associated with multiple complications, including complete heart block with the need for permanent pacemaker and compression of the circumflex coronary artery or obstruction of the left ventricular outflow tract.[10,20] In our cohort heart block requiring pacemaker (n = 3) and subaortic stenosis resection (n = 2) were expected complications, and circumflex artery compression did not occur despite the fact that most prostheses were implanted at the annular level. Prosthetic ring attachment to valve tissue in the critical area could help to prevent the need for a permanent pacemaker. In our series the mean echocardiographic valve annulus diameter before 15-mm prosthesis implantation was 12.0 mm. This is smaller than the annulus measured in the study of Eltayeb and colleagues (14.8 mm).[19] Apparently it is safe to mildly oversize the prosthetic valve in infants and neonates and implant the prosthesis at the annular level.

Pluchinotta and colleagues[16] reported the development of structural Melody prosthesis deterioration in a significant number of patients (35%), requiring prosthesis replacement at a median of 22 months after implantation. The interval to prosthesis replacement was not lower compared with our cohort. In addition to differences in clinical outcomes between the Melody prosthesis and the 15-mm mechanical prosthesis, the costs do significantly differ, with the Melody prosthesis being 4 times as expensive.

Pannus Formation and Thromboembolic Events

Inflammation or calcification has been noted in explanted SJM prostheses, primarily demonstrated as pannus formation. In our cohort pannus formation of SJM Masters prosthesis at time of explantation was reported in 4 (24%) patients. As opposed to pannus formation, prosthetic valve thrombosis occurs early after surgery, and results from both increased thrombogenicity and abnormal flow through the mechanical valve.

None of the patients in our cohort was on antiplatelet therapy. There is no consensus about adding antiplatelet therapy to the anticoagulant regimen. Support for the

addition of antiplatelet therapy to vitamin K antagonist therapy alone comes from randomized trails showing a reduced risk of mortality and thromboembolisms with combined antiplatelet and anticoagulant therapy when compared with anticoagulant therapy alone.[21,22] On the other hand these trials showed an increased risk of major hemorrhage with combined therapy when compared with anticoagulant-only therapy.

One of the 3 thromboembolic events in our cohort was prosthesis related (reduced cusp mobility 1 week after implantation). Prosthesis inspection during replacement revealed absent mobility of the posterior cusp and small thrombi on the cusp and in the hinge mechanism. The prosthesis was removed and a new 15-mm SJM Masters prosthesis implanted. The other valve thrombosis was related to a subtherapeutic INR level (infection). The bleeding event was related to an elevated INR level (high medication intake by mistake). The incidence of thromboembolic events due to prosthesis impingement was low in our cohort (1/17). Oral anticoagulant-related thromboembolic events were limited (2/17). The INR could be well targeted with the use of a good INR home monitoring system (INR self-testing and strict guidance from specialized thrombosis care) in our country. However the incidence of thromboembolic complications and difficulty of managing anticoagulation in a small child are clearly downsides of the mechanical valve when compared with the Melody prosthesis, especially in countries with limited INR monitoring options.

Study Limitations

This is a nonrandomized retrospective study. Echocardiography protocols differed among participating centers, resulting in missing data for some variables. However to avoid interobserver variability, studies were reviewed by an experienced cardiologist from the coordinating center. There was no comparison group, such as with the Melody prosthesis.

Conclusions

The miniaturized 15-mm mechanical prosthesis has been a valuable adjunct to the armamentarium of the pediatric cardiac surgeon. It has offered a chance of survival to critically ill infants and neonates. The prosthesis is relatively inexpensive and easy to implant in even the smallest infants. Late exchange for patient–prosthesis mismatch was required after a median of 3.5 years and could be carried out without the need for annular enlargement procedures. Complications of oral anticoagulant therapy were rare.

References

1. Kojori F, Chen R, Caldarone CA, et al. Outcomes of mitral valve replacement in children: a competing-risks analysis. *J Thorac Cardiovasc Surg*. 2004;128:703-709.
2. Quinonez LG, Breitbart R, Tworetsky W, et al. Stented bovine jugular vein graft (Melody valve) for surgical mitral valve replacement in infants and children. *J Thorac Cardiovasc Surg*. 2014;148:1443-1449.
3. Freud LR, Marx GR, Marshall AC, et al. Assessment of the Melody valve in the mitral position in young children by echocardiography. *J Thorac Cardiovasc Surg*. 2017;153:153-160.
4. Langer NB, Solowiejczyk D, Fahey JT, et al. Modified technique for Melody valve implantation in the mitral position. *J Thorac Cardiovasc Surg*. 2018;156:1190-1191.
5. US Food and Drug Administration. Premarket approval database: SJM Masters series mechanical heart valve, 15 mm HP. Available at: https://www.accessdata.fda.gov/scripts/cdrh/cfdocs/cfpma/pma.cfm?id#xE0CE;P810002s101. Accessed July 7, 2019.
6. Huisman MV, Bakx R, Coppens M, et al. Dutch guidelines anticoagulation therapy mechanical heart valves. Available at: https://richtlijnendatabase.nl/richtlijn/antitrombotisch_beleid/kleppen_en_antistolling/profylaxe_mechanische_hartklepprothesen.html. Accessed July 29, 2019.
7. Pasquali SK, Shahian DM, O'Brien SM, et al. Development of a congenital heart surgery composite quality metric: part 1—conceptual framework. *Ann Thorac Surg*. 2019;107:583-589.
8. Jacobs JP, Jacobs ML, Austin EH, et al. Quality measures for congenital and pediatric cardiac surgery. *World J Pediatr Cong Heart Surg*. 2012;3:32-47.
9. Lopez L, Colan SD, Frommelt PC, et al. Recommendations for quantification methods during the performance of a pediatric echocardiogram: a report from the Pediatric Measurements Writing Group of the American Society of Echocardiography Pediatric and Congenital Heart Disase Council. *J Am Soc Echocardiogr*. 2010;23:465-495.
10. Zoghbi WA, Enriquez-Sarano M, Foster E, et al. Recommendations for evaluation of the severity of native valvular regurgitation with two-dimensional and Doppler echocardiography. *J Am Soc Echocardiogr*. 2003;16:777-802.
11. Alsoufi B, Manlhiot C, McCrindle BW, et al. Results after mitral valve replacement with mechanical prostheses in young children. *J Thorac Cardiovasc Surg*. 2010;139:1189-1196.
12. Beierlein W, Becker V, Yates R, et al. Long-term follow-up after mitral valve replacement in childhood: poor event-free survival in the young child. *Eur J Cardiothorac Surg*. 2007;31:860-865.
13. Ibezim C, Sarvestani AL, Knight JH, et al. Outcomes of mechanical mitral valve replacement in children. *Ann Thorac Surg*. 2019;107:143-150.
14. Henaine R, Nloga J, Wautot F, et al. Long-term outcome after annular mechanical mitral valve replacement in children aged less than five years. *Ann Thorac Surg*. 2010;90:1570-1576.
15. Brown JW, Fiore AC, Ruzmetov M, et al. Evolution of mitral valve replacement in children: a 40-year experience. *Ann Thorac Surg*. 2012;93:626-633.
16. Pluchinotta FR, Piekarski BL, Milani V, et al. Surgical atrioventricular valve replacement with melody valve in infants and children—a multicenter study. *Circ Cardiovasc Interv*. 2018;11:e007145.
17. Nudelman I, Schachner A, Levy MJ. Repeated mitral valve replacement in the growing child with congenital mitral valve disease. *J Thorac Cardiovasc Surg*. 1980;79:765-769.
18. Raghuveer G, Caldarone CA, Hills CB, et al. Mechanical mitral valve replacement in children aged 5 years, and predictors of prosthesis survival, growth, and functional status following: multiinstitutional study. *Circulation*. 2003;108:II174-II179.
19. Eltayeb OM, Readdy WJ, Mongé MC, et al. Mitral valve replacement in infants using a 15-mm mechanical valve. *Ann Thorac Surg*. 2019;108:552-557.
20. Tierney ESS, Pigula FA, Berul CI, Lock JE, del Nido PJ, McElhinney DB. Mitral valve replacement in infants and children 5 years of age or younger: evolution in practice and outcome over three decades with a focus on supra-annular prosthesis implantation. *J Thorac Cardiovasc Surg*. 2008;136:954-961.
21. Massel DR, Little SH. Antiplatelet and anticoagulation for patients with prosthetic heart valves. *Cochrane Database Syst Rev*. 2013;(7):CD003464.
22. Whitlock RP, Sun JC, Fremes SE, Rubens FD, Teoh KH. Antithrombotic and thrombolytic therapy for valvular disease: antithrombotic therapy and prevention of thrombosis, 9th ed: American College of Chest Physicians evidence-based clinical practice guidelines. *Chest*. 2012;141(2 Suppl):e576S-e600S.