European Journal of Cardio-Thoracic Surgery 2023, 63(6), ezad199
https://doi.org/10.1093/ejcts/ezad199 Advance Access publication 31 May 2023

ORIGINAL ARTICLE

CATHETER-BASED VALVE OPERATIONS

Cite this article as: Kerbel T, Uyanik-Ünal K, Mach M, Bartunek A, Gökler J, Osorio E *et al.* Transcatheter tricuspid valve edge-to-edge repair after a heart transplant: a single-centre experience with a novel therapy†. Eur J Cardiothorac Surg 2023; doi:10.1093/ejcts/ezad199.

Transcatheter tricuspid valve edge-to-edge repair after a heart transplant: a single-centre experience with a novel therapy†

Tillmann Kerbel[a,‡], Keziban Uyanik-Ünal[a,‡]*, Markus Mach [a], Anna Bartunek[b], Johannes Gökler[a], Emilio Osorio[a], Philipp Bartko[c], Andreas Zuckermann [a] and Martin Andreas [a]

[a] Department of Cardiac Surgery, Medical University of Vienna, Austria
[b] Division of Cardiothoracic and Vascular Anesthesia, Medical University of Vienna, Austria
[c] Department of Internal Medicine II, Medical University of Vienna, Austria

* Corresponding author. Department of Cardiac Surgery, Medical University of Vienna, Waehringer Guertel 18-20, 1090 Vienna, Austria. Tel: +43 1 40400 20505; email: keziban.uyanik-uenal@meduniwien.ac.at (K. Uyanik-Ünal).

Received 22 October 2022; received in revised form 28 March 2023; accepted 16 May 2023

Key question

Is transcatheter edge-to-edge repair a treatment option in heart transplanted patients who are no surgical candidates?

Key finding(s)

Tricuspid regurgitation was significantly decreased resulting in favourable right heart remodelling.

Take-home message

Management of post-transplant tricuspid regurgitation was safe, effective and durable, even though these patients remain vulnerable.

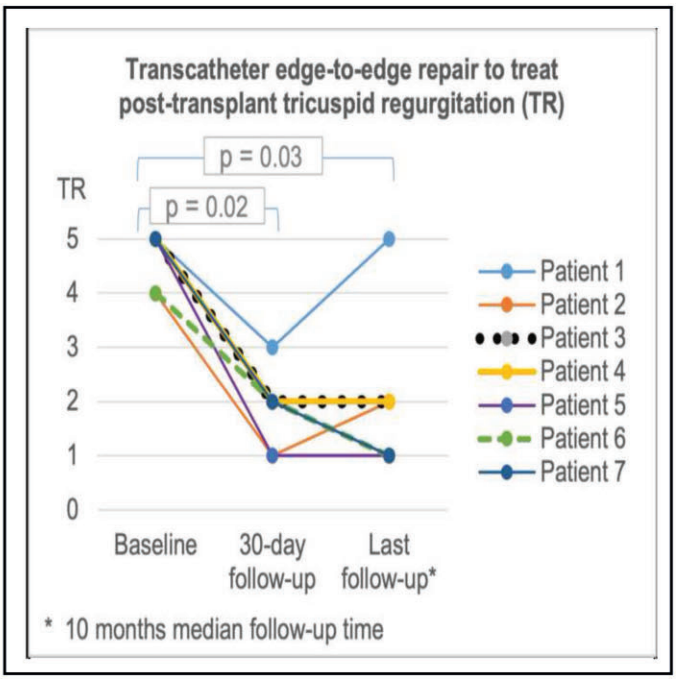

Abstract

OBJECTIVES: Tricuspid regurgitation (TR) in patients who had heart transplants is associated with poor outcome. The increased risk for surgical and postoperative complications might be reduced in these vulnerable patients by transcatheter therapies.

METHODS: All patients with a prior heart transplant (HTX) undergoing transcatheter edge-to-edge repair in the tricuspid position (T-TEER) were prospectively enrolled in an institutional registry.

RESULTS: Seven patients who had heart transplants (5/7 female) at a mean age of 53 [48; 64] and median TRI-SCORE of 14 [7; 22] underwent T-TEER to treat symptomatic TR ≥ IV in an elective (n = 6) and urgent (n = 1) setting, respectively. The median time from HTX to

†Presented at the 36th Annual Meeting of the European Association of Cardio-Thoracic Surgery, Milan, Italy, 5–8 October 2022.
‡These authors contributed equally to this work.

© The Author(s) 2023. Published by Oxford University Press on behalf of the European Association for Cardio-Thoracic Surgery.
This is an Open Access article distributed under the terms of the Creative Commons Attribution-NonCommercial License (https://creativecommons.org/licenses/by-nc/4.0/), which permits non-commercial re-use, distribution, and reproduction in any medium, provided the original work is properly cited. For commercial re-use, please contact journals.permissions@oup.com

T-TEER was 13 years. A total of 2 (n = 4) and 3 (n = 3) clips were implanted with a technical success in 6/7 (one single- device detachment). TR reduction was effective and durable within a median echocardiographic follow-up time of 10 months (TR baseline vs last follow-up: $P = 0.03$). Further, significant right ventricular remodelling (right ventricular end-diastolic diameter: 50 mm–36 mm, $P = 0.02$), decrease in the inferior vena cava diameter (24 mm–18 mm, $P = 0.04$) and in the gamma-glutamyl-transferase (255 U/l–159 U/l, $P = 0.04$) was found. Four of 7 patients were free of cardiovascular death (n = 1, 267 days after T-TEER), cardiac redo surgery (n = 1) and heart failure hospitalization (n = 2) and had no further clinical signs of right heart failure.

CONCLUSIONS: T-TEER after HTX is feasible and effective regarding TR reduction in a short-term follow-up. The initial results may pave the way for a novel approach in TR management in patients having HTX.

Keywords: transcatheter edge-to-edge repair • heart transplantation • tricuspid regurgitation • cardiac intervention • tricuspid valve

ABBREVIATIONS AND ACRONYMS

HTX–	heart transplant
iTVS–	isolated tricuspid valve surgery
NYHA–	New York Heart Association
SLDA–	single leaflet device attachment
TEER–	transcatheter edge-to-edge repair
T-TEER–	transcatheter edge-to-edge repair, tricuspid position
TR–	tricuspid regurgitation
TV–	tricuspid valve

INTRODUCTION

Significant tricuspid regurgitation (TR) is reported in up to 7% of patients after a heart transplant (HTX) [1, 2] and is associated with an increased risk for lethal right heart failure [3, 4].

The management of these patients, who are refractory to guideline-directed optimal medical therapy, is challenging because there are no guidelines and only limited experiences supporting the decision making in these vulnerable patients.

In-hospital mortality after isolated tricuspid valve surgery (iTVS), also if modern surgical techniques (e.g. beating-heart iTVS, minimally invasive thoracotomy) are applied, still exceeds the 5% burden in patients who had not received a transplant [5, 6]. In patients who have had a HTX, the mortality after iTVS might be even higher due to the increased risk for a postoperative adverse event such as infection, wound healing complications due to the immunosuppression, rejection and end-organ failure (e.g. acute kidney injury) [7–13].

The surgical risk might be avoided by an interventional approach. The technical feasibility of transcatheter techniques to treat significant TR in HTX patients has been described before. However, the experience is limited to a published sample size of 3 patients [transcatheter edge-to-edge repair (TEER): $n = 2$; direct annuloplasty: $n = 1$] [14, 15].

For further evaluation, we report our single-centre experience of 7 patients after HTX undergoing transcatheter edge-to-edge repair in the tricuspid position.

MATERIAL & METHODS

Ethical statement

The study was approved by the internal review board (# 1959/2020). Informed consent was obtained prior to the intervention.

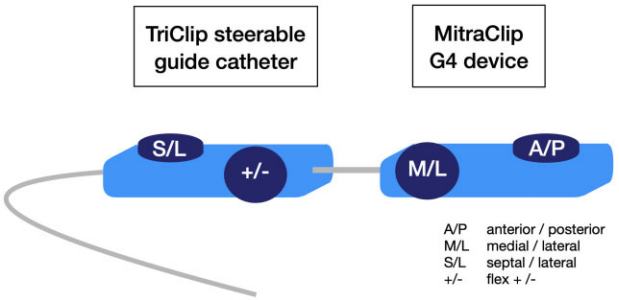

Figure 1: Off-label combination of a MitraClip with a TriClip guiding sheath. Additional knob on the MitraClip delivery sheath [MitraClip delivery sheath: medial/lateral (M/L) and anterior/posterior (A/P) versus a TriClip delivery sheath: only flex/extend (F/E) knob] allows extended steering useful in complex anatomies and angulations.

The patients and interventional technique

We performed a subanalysis of a monocentric, prospective observational study (AV—observational study) to investigate our entire, initial experience of TEER in the tricuspid position (T-TEER) in patients having HTXs. The interventions were performed at the Department of Cardiac Surgery, Medical University of Vienna, Austria, between August 2021 and April 2022.

Prior to the procedure, relevant pulmonary hypertension was excluded by right heart catheterization. All patients were reviewed by the local heart team, whose decision-making process was not influenced by this analysis.

Under continuous 2-dimensional and 3-dimensional transoesophageal echocardiography and fluoroscopic guidance, T-TEER was performed via right femoral venous access, using the MitraClip G4 device in a TriClip guiding sheath (both Abbott Vascular, Santa Clara, CA, USA). This off-label combination allows extended steering options due to an additional knob [medial/lateral (M/L) + anterior/posterior (A/P) knob instead of a single flex/extend (F/E) knob], as depicted in Fig. 1.

For beneficial leaflet visualization, particularly when grasping the leaflet, 2-dimensional intracardiac echocardiography via a 9F left femoral venous access (ICE; ViewFlex Xtra, Irvine Biomedical Inc. a St. Jude Medical Company, Irvine, CA, USA) was applied in 3 patients.

Data assessment and end-point definition

New York Heart Association (NYHA) functional class, TR, and laboratory parameters were assessed prior to admission for T-TEER (baseline), 30 days after the intervention and at the last available

Table 1: Patient characteristics and preinterventional evaluation

Patient #	Age (years)	Gender	HTX to TEER (months)	HTX—details	GV	History of rejection reaction	PM	Symptoms	Right heart catheterization, mmHg	Calculated surgical risk	Heart team's argument against iTVS
1	52	F	238	• Marfan syndrome: end-stage heart failure after aortic dissection and left main malperfusion • Biatrial HTX	Y, no PCI	N	Y	NYHA II, oedema, ascites	mPAP 24 mPCWP 19	TRI-SCORE: 5 % ES II: 4.32%	High surgical risk (Marfan syndrome)
2	43	F	363	• Dilated, non-ischaemic CMP • Biatrial HTX	N	N	N	NYHA II, oedema, ascites	mPAP 11 mPCWP 6	TRI-SCORE: 8% ES II: 4.55%	iTVS declined
3	37	F	HTX#1: 161 HTX#2: 112 HTX#3: 56	• HTX #1: dilated, non-ischaemic CMP; HTX #2: graft failure; HTX #3: acute rejection reaction after MKr + 1 x CABG • Bicaval HTX (HTX #3)	M	Y, acute	N	NYHA III, oedema, ascites	mPAP 25 mPCWP 18	TRI-SCORE: 5% ES II: 6.8%	iTVS declined & high surgical risk (immunologic)
4	60	M	45	• Dilated, ischaemic CMP • Bicaval HTX	N	Y, subacute	N	Symptomatic worsening after EMB: NYHA III, oedema, ascites	mPAP 23 mPCWP 19	TRI-SCORE: 22% ES II: 5.53%	High surgical risk
5	67	F	2	• Dilated, ischaemic CMP • Bicaval HTX	N	N	N	NYHA IV Acute RHF with transient ECMO support	N/A*	TRI-SCORE: 22% ES II: 11.37%	too frail
6	53	F	328	• Congenital CMP • Bicaval HTX	Y, PCI	N	N	NYHA III, oedema, ascites	mPAP 54 mPCWP 49	TRI-SCORE: 14% ES II: 7.96%	iTVS declined (& high surgical risk; 3x NTX prior)
7	73	M	159	• Dilated, non-ischaemic CMP • Bicaval HTX	Y, PCI	N	Y	NYHA III, oedema, ascites	mPAP 23 mPCWP 18	TRI-SCORE: 22% ES II: 9.19%	high surgical risk

*Precapillary pulmonary hypertension was excluded prior to the intervention; however, the exact values are retrospectively not assessable.

CABG: coronary artery bypass graft; CMP: cardiomyopathy; ECMO: extracorporeal membrane oxygenation; EMB: endomyocardial biopsy; ES II: EuroSCORE II; GV: graft vasculopathy; iTVS: isolated tricuspid valve surgery; HTX: heart transplant; MKr: mitral valve repair; mPAP: mean pulmonary artery pressure; mPCWP: mean pulmonary capillary wedge pressure; NTX: kidney transplant; NYHA: New York Heart Association Class; PCI: percutaneous coronary intervention; PM: pacemaker; RHF: right heart failure; TEER: transcatheter edge-to-edge repair.

Table 2: Procedural details

Patient #	Procedural time, min	Number of TEER devices	Clip 1 position	Clip 2 position	Clip 3 position	TV MPG, mmHg	Technical success
1	67	2	A/S	A/S	–	1	Y
2	56	2	A/S	A/S	–	1	Y
3	89	3	A/S	A/S	A/S	1	Y
4	78	2	A/S	A/S		0	Y
5	79	3	P/S	P/S	P/S	1	N*
6	60	2	A/S	P/S		2	Y
7	105	3	A/S	P/S	A/S	1	Y

*Single leaflet device attachment; clip stabilized with another clip.

A/S: between anterior and septal tricuspid leaflet; MPG: mean pressure gradient; P/S: between posterior and septal tricuspid leaflet; TEER: transcatheter edge-to-edge repair; TV: tricuspid valve.

clinical visit. TR grading was conducted according to Hahn *et al.* from mild (I) to "torrential" (V); therefore, quantitative assessment was performed as recommended by the current European guidelines (vena contracta, estimated regurgitant orifice area, regurgitation volume) [16]. Right ventricular systolic function was calculated by right ventricular fractional area change and tricuspid annular plane systolic excursion.

The primary end point was the TR severity at the follow-up examination after T-TEER compared to baseline (TR; 30 days vs pre, last visit vs pre). Secondary end points were the effect on the NYHA status, laboratory parameters (renal, hepatic and cardiac markers) as well as the safety end points as defined by the Mitral Valve Academic Research Consortium criteria [17]. Technical success was defined as successful access, proper grasping and attachment of the implanted clips and an absence of complications during the system retrieval.

Statistics

Normal assumption was graphically assessed by using QQ plots. Demographic data, interventional data and follow-up data were reported—depending on Gaussian distribution—as mean ± standard deviation, median [Q1; Q3] and number (percentage), respectively. A Wilcoxon signed-rank test was applied for the primary and secondary end points.

Excel 16.62 (Microsoft, Redmond, WA, USA) and SPSS 27.0 (SPSS Inc, Chicago, IL, USA) for MacIntosh were used for data analysis. A P-value of < 0.05 was considered significant.

RESULTS

A total of 7 patients who received HTXs (5/7 female, median age: 53) underwent isolated T-TEER to treat symptomatic TR $\geq$ 4. Baseline patient characteristics, HTX-related details and reasons against redo surgery are reported separately for each patient in Table 1.

Primary TR (flail, ruptured chords) was suspected in 3 of 7 patients, probably an injury after repeated endomyocardial biopsies. In a median procedural time of 78 min, a total of 2 ($n = 4$) and 3 ($n = 3$) long and wide clips (XTW G4 MitraClip, TriClip guiding catheter) were implanted. The clips were positioned between the anterior and septal (A/S) and/or posterior and septal (P/S) tricuspid valve (TV) leaflets, without hampering the diastolic right ventricle filling (postinterventional TV mean pressure gradient: 0–2 mmHg; Table 2). Technical success was achieved in 6/7 of the patients: Because of a single leaflet device attachment (SLDA) in patient #5, the detached leaflet was stabilized by another clip.

T-TEER significantly mitigated TR at the 30-day follow-up (TR; 30 days vs pre: $P = 0.016$). The repair effect was durable in an intermediate-term echocardiographic follow-up ranging from 4 to 13 months (TR; last visit vs pre: $P = 0.026$; visual abstract), resulting in a significant decrease of the inferior vena cava diameter (30 days vs pre: $P = 0.027$ and last visit vs pre: $P = 0.042$). Six of 7 patients had a TR $\leq$ II at the last visit. Patient #1 presented with TR $\geq$ III, despite an immediate TR reduction to level II, after the 30-day follow-up. Further echocardiographic details are summarized in Table 3.

Clinical outcome

Patients treated in an elective setting (6/7) had no in-hospital adverse events and were discharged without an intensive care unit stay on median postoperative day 2.5. In contrast, the urgently treated patient #5, with prior right heart failure requiring extracorporeal membrane oxygenation support within 1 month following the HTX, had a prolonged in-hospital stay due to frailty, had a kidney biopsy-related bleeding complication (Bleeding Academic Research Consortium 3 b) with coiling of the affected vessels and multiple skin lesions (bedsore) requiring surgical flap plastic.

In a median follow-up time of 373 days, the overall mortality was 1/7: patient #4 had perforated diverticulitis with a burst abdomen after a laparotomy and a postoperative suspected acute rejection reaction with consecutive right heart failure and died 267 days after the T-TEER despite an almost optimal TR reduction.

NYHA functional class status improved in 5 of the 6 remaining patients (Fig. 2) within the follow-up period: Patient #1 had progressive right heart failure requiring hospitalization for heart failure 491 days after the T-TEER. High-risk cardiac redo surgery was performed 534 days after the T-TEER with the interesting finding of a pacemaker lead perforation of the papillary muscle of the TV, which was undetected prior to the operation. Patient #3 initially improved from NYHA III to NYHA I; however, SARS-CoV II infection caused worsening of the dyspnoea and temporary increase of the TR, so that hospitalization for heart failure was indicated 429 days after T-TEER (Table 4). Clinical right heart failure signs were alleviated in the other patients.

Table 3: Echocardiography

#	Last Echo- TEER, days	TR mechanism		VC, mm			EROA, mm^2			TR volume, ml			TAPSE, mm		RV FAC, %		RVEDD, mm		VCI, mm		
		Aetiology	Description	Baseline	30 days	Last visit	Baseline	30 days	Last visit	Baseline	30 days	Last visit	Baseline	Last visit	Baseline	Last visit	Baseline	Last visit	Baseline	30 days	Last visit
1	402	Mixed	Ring dilatation, iatrogenic*	15.2	13.5	15.7	147	55	96	95	39	103	15	N/a	35	37	50	46	50	44	52
2	288	Mixed	Ring dilatation, flail ATL	10	2.0	3.7	68	19	22	38	10	17	14	18	48	45	44	34	24	16	15
3	380	Primary	Flail ATL	21	5.0	6.8	n/a	22	38	n/a	18	31	13	n/a	49	49	52	38	19	18	18
4	267	Primary	Flail ATL + STL	21.1	5.7	5.4	93	n/a	12	32	n/a	4	10	5	57	30	52	37	33	26	28
5	319	Secondary	Ring dilatation	22	2.9	0.6	156	14	0	41	13	0	n/a	19	39	56	42	25	23	n/a	14
6	135	Secondary	Ring dilatation	16.9	6.6	2.7	74	32	12	63	20	11	11	n/a	48	n/a	42	38	20	14	15
7	148	Secondary	Ring dilatation	20	6.5	3	108	33	10	49	18	5	n/a	15	46	40	57	47	40	39	37
∑	288 [108; 350]	4/7 Organic components			*P* = 0.018	*P* = 0.028		*P* = 0.043	*P* = 0.028		*P* = 0.042	*P* = 0.046		*P* = 0.655		*P* = 0.500		*P* = 0.018		*P* = 0.027	*P* = 0.042

A Wilcoxon signed-rank test was applied for 30 days versus baseline and last visit versus baseline, respectively.

*Intraoperative finding: pacemaker lead perforation of the papillary muscle.

ATL: anterior tricuspid leaflet; ECHO: echocardiography; EROA: effective regurgitant orifice area; RVEDD: right ventricular end-diastolic diameter; RV FAC: right ventricular fractional area change; STL: septal tricuspid leaflet; TAPSE: tricuspid annular plane systolic excursion; TEER: transcatheter edge-to-edge repair; TR: tricuspid regurgitation; VC: vena contracta; VCI: inferior vena cava.

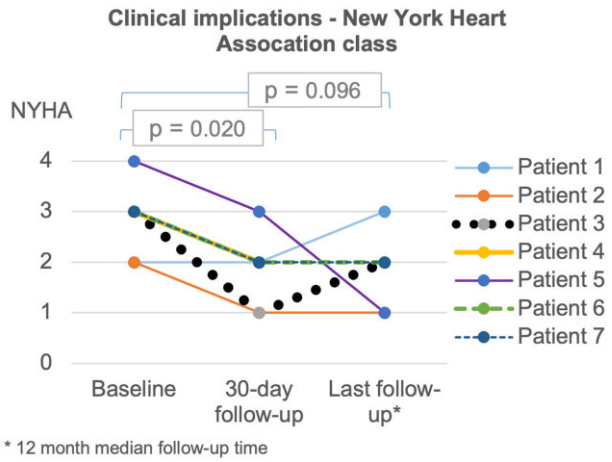

Figure 2: NYHA throughout the follow-up period demonstrating a significant symptomatic improvement at the 30-day follow-up. Though a non-significant difference in NYHA class at a mean follow-up time of 12 months compared to baseline, 5 of the remaining 6 patients [(1 death (patient 4) prior to 1-year follow-up] showed an improvement of ≥ 1 NYHA class in this time range.

Laboratory parameters are summarized in Table 5. Most interestingly, gamma-glutamyl transferase levels significantly decreased ($P = 0.043$), whereas there was no significant change in other hepatic, renal and cardiac markers, respectively, during the follow-up period.

Right ventricular remodelling

Intermediate-term follow-up demonstrated significant right ventricular remodelling (right ventricular end-diastolic diameter; last visit vs pre: $P = 0.018$). However, the right ventricular systolic function did not improve significantly (Table 3).

DISCUSSION

We report the short- to intermediate-term outcomes of the largest cohort of patients so far undergoing HTXs ($n = 7$) who had interventional treatment for isolated severe TR. The key findings were that T-TEER is feasible and safe despite 1 SLDA. Imaging guidance and device handling were challenging partially due to the rotated heart axis and heavy angulations on the device. Electively treated patients (6/7) were discharged between postoperative day 2 and 4 without any in-hospital adverse events. Repair with T-TEER was effective and durable: 6/7 patients were in TR ≤ II within an echocardiographic median follow-up time of 10 months; 4 of these vulnerable patients were free of cardiovascular death ($n = 1$), redo surgery ($n = 1$) and rehospitalization ($n = 2$), and improved by at least 1 NYHA class compared to baseline. In the follow-up period, significant right ventricular remodelling, without improvement in the right ventricular systolic function, and a significant decrease in the diameter of the inferior vena cava were found. Gamma-glutamyl transferase levels significantly declined, reflecting hepatic decongestion after T-TEER [18].

Survival after a median clinical follow-up period of almost 13 months was 6/7: 1 patient died—unrelated to the procedure—after a tremendous course 9 months after T-TEER; he was stable in TR I and had no cardiac symptoms up to a perforated diverticulitis. The patient did not recover from a complicated postoperative course after sigma resection (wound dehiscence), had a suspected rejection reaction that was not responsive to high-dose steroid treatment and died of right heart failure, probably related to rejection (tricuspid annular plane systolic excursion 5 mm). Four patients, including the patient who died during the 1-year follow-up, were not surgical candidates due to the high surgical risk; thus T-TEER was the remaining option. Several factors like the immunologic status influence the surgical risk in patients who receive transplants; these factors are not reflected in standard risk scores; thus these risk scores underestimate the surgical risk in patients with HTXs.

Though TR is a volume-dependent, dynamic disease and 91% of the severe TR that is manifest in the early postoperative phase resolves within the first year after an HTX [19], patient #5 underwent T-TEER after temporary extracorporeal membrane oxygenation support in an urgent setting 59 days after an HTX. Recovery and subsequent transfer to the normal ward were not expected with medical therapy only, but high-dose diuretics enabled us to refer the patient in a compensated condition to T-TEER (TR V–III). This patient did not meet the criteria of a technical success because of the SLDA. However, the SLDA did not impair the TR reduction (TR I at the 11-month follow-up), because another stabilizing clip was implanted. The SLDA rate was—even if it was not clinically relevant in our patients—higher than in the TRILUMINATE study [20]. This result might be related to our small sample size and/or the rotated heart axis and the subsequent partially challenging device handling and echocardiographic guiding, respectively. Direct valve inspection is not possible during TEER; being able to grasp the leaflet appropriately depends heavily on the quality of the imaging and thus on advanced imaging technologies; for example, 3-dimensional ICE catheters (VeriSight Pro, Philips, Andover, MA, USA), whose application is thus far restricted to the United States [21], are awaiting CE mark approval to further improve the fundamental steps (grasping) during TEER in patients with and without transplants.

A fundamental understanding of the underlying mechanism causing TR is essential for a good repair result with TEER. As seen in previous intraoperative findings during iTVS in the recipients of donated hearts [8], chordal rupture, which might be related to repeated endomyocardial biopsies [22], was the predominant TR mechanism in our cohort ($n = 3$). Ischaemic functional TR due to graft vasculopathy was manifested in 2 patients [3]. The biatrial anastomosis technique, which is associated with an increased risk for atrioventricular incompetence [23], was applied in 2 of our patients, but was not the driving factor of TR (#1: iatrogenic TR, #2: flail).

One patient underwent iTVS > 1 year for residual, symptomatic (generalized congestion) TR after T-TEER that was not manageable with advanced heart failure medication. Because the patient's anatomy was not suitable for bail-out interventional options (transcatheter tricuspid valve replacement, caval valve implant), she was referred for high-risk re-re-re-redo surgery [tricuspid valve replacement (bioprosthesis) and mitral valve repair]. Intraoperative findings revealed a previously undetected pacemaker lead perforating the papillary muscle, which was undetected before; thus the lesson to be learned was to perform multimodal imaging with 4-dimensional, full heart cycle cardiac computed tomography, for procedural planning in patients with a right ventricular pacemaker lead and limited imaging quality in the future.

Surgical treatment of TR in donor heart recipients is rarely performed (0.2 to 2%) [10–12]; therefore, the evidence of iTVS in donor-heart recipients is limited to experiences from relatively

Table 4: Clinical follow-up

Patient #	Last FU: TEER, days	Cardiovascular death			All-cause death			Cardiac redo surgery			HFH			Major bleeding*		
		In-hospital	30d	Last visit	In-hospital	30d	Last visit	In-hospital	30d	Last visit	In-hospital	30 days	Last visit	In-hospital	30 days	Last visit
1	535	-	-	-	-	-	-	-	-	Y[#]	-	-	Y	-	-	-
2	477	-	-	-	-	-	-	-	-	-	-	-	-	-	-	-
3	429	-	-	-	-	-	-	-	-	-	-	-	Y	-	-	-
4	267	-	-	Y	-	-	Y	-	-	-	-	-	-	-	-	-
5	373	-	-	-	-	-	-	-	-	-	-	-	-	Y	-	Y
6	282	-	-	-	-	-	-	-	-	-	-	-	-	-	-	-
7	256	-	-	-	-	-	-	-	-	-	-	-	-	-	-	-
∑	373 [275; 453]		0/7			1/7			1/7			2/7			1/7	

Patient #	Last FU: TEER, days	Access complication			Myocardial infarction			Thrombo-embolic event			Stroke			AKI II/III			Acute liver failure			SLDA		
		In-hospital	30 days	Last visit	In-hospital	30 days	Last visit	In-hospital	30 days	Last visit	In-hospital	30 days	Last visit	In-hospital	30 days	Last visit	In-hospital	30 days	Last visit	In-hospital	30 days	Last visit
1	535	-	-	-	-	-	-	-	-	-	-	-	-	-	-	Y	-	-	-	-	-	-
2	477	-	-	-	-	-	-	-	-	-	-	-	-	-	-	-	-	-	-	-	-	-
3	429	-	-	-	-	-	-	-	-	-	-	-	-	-	-	-	-	-	-	-	-	-
4	267	-	-	-	-	-	-	-	-	-	-	-	-	-	-	Y	-	-	-	-	-	-
5	373	-	-	-	-	-	-	-	-	-	-	-	-	-	-	-	-	-	-	Y	Y	Y
6	282	-	-	-	-	-	-	-	-	-	-	-	-	-	-	-	-	-	-	-	-	-
7	256	-	-	-	-	-	-	-	-	-	-	-	-	-	-	-	-	-	-	-	-	-
∑	373 [275; 453]		0/7			0/7			0/7			0/7			2/7			0/7			1/7	

*> Bleeding Academic Research Consortium 3a.

[#]Cardiac redo surgery due to residual severe tricuspid regurgitation (and mitral regurgitation III+).

AKI: acute kidney injury; FU: follow-up; HFH: heart failure hospitalization; SLDA: single leaflet device attachment; TEER: transcatheter edge-to-edge repair; TR: tricuspid regurgitation.

Table 5: Laboratory values

Patient #	Last FU: TEER, days	NT-proBNP, ng/dL			Creatinine, mg/dL			AST, U/l			ALT, U/l			yGT, U/l			Bilirubin, mg/dL		
		Baseline	30 days	Last visit	Baseline	30 Days	Last visit	Baseline	30 days	Last visit	Baseline	30 days	Last visit	Baseline	30 Days	Last visit	Baseline	30 days	Last visit
1	535	3808	2843	6903	1.5	1.4	2.6	30	30	28	19	17	18	56	44	50	0.9	0.6	0.4
2	477	1157	555	560	1.2	1.0	0.8	33	35	35	32	37	41	255	158	198	1.5	0.9	2.6
3	429	n/a	2188	5265	1.8	1.4	2.5	26	40	13	16	38	14	437	493	286	0.9	0.8	0.6
4	267	3991	3231	29833	1.6	1.1	1.0	25	16	46	23	10	19	123	69	88	1.9	1.5	2.2
5	373	25077	n/a	1373	0.6*	1.9	1.6	27	19	42	19	9	40	114	55	38	0.3	0.4	0.5
6	282	11270	5404	9974	2.7	2.8	2.9	29	29	30	25	22	21	411	399	159	0.6	0.6	1.0
7	256	2315	4414	3918	2.6	2.7	2.4	23	26	35	10	22	32	659	671	687	1.0	0.9	1.0
$\sum$	373 [275; 453]		$P = 0.17$	$P = 0.60$		$P = 0.61$	$P = 0.35$		$P = 0.89$	$P = 0.27$		$P = 0.87$	$P = 0.50$		$P = 0.23$	$P = 0.043$		$P = 0.07$	$P = 0.53$

A Wilcoxon signed-rank test was applied for the 30-day follow-up versus baseline and the last follow-up versus baseline, respectively.

*Assessed during haemofiltration.

ALT: alanine aminotransferase; AST: aspartate aminotransferase; FU: follow-up; ε-GT: gamma glutamyl transferase. NT-proBNP: N-terminal pro brain natriuretic peptide; TEER: transcatheter edge-to-edge repair.

small sample sizes conducted in selected centres [8–13]. The in-hospital mortality after iTVS was comparable with that of patients who did not receive HTXs. Nevertheless, the risk for (in-hospital-acquired) infections, wound healing disorders, renal adverse events and immunologic reactions up to an acute rejection reaction was determined in these vulnerable patients [10–12], all of which might be mitigated by an interventional treatment approach. Whereas surgical TV repair was associated with a high repair failure rate in relation to the need for redo surgery [9], isolated TV replacement with a bioprosthesis showed stable mid- and long-term results [8, 10, 11] and might be the preferred surgical plan. Due to the low risk of T-TEER and stable outcomes after isolated biological TV replacement, we propose a more widespread interventional treatment of isolated significant TR, also in patients with lower surgical risk who have HTXs. We do this because—next to the excellent TR reduction reported herein and previously by Roth *et al.* and Wösten *et al.* [14, 15]—clips in situ do not block the way for surgical TV replacement—an analogue to the technique applied after failed TEER in the mitral position [24].

These interesting data from our single-centre experience open a new scenario for the treatment of significant TR in patients with heart transplants and might instigate a matched paired multicentre analysis between iTVS and T-TEER to identify additional ways to manage significant TR in these vulnerable patients.

LIMITATIONS

This is a single-centre experience with a sample size restricted to 7 patients. The procedures were conducted by the same surgeon, who had performed about 100 T-TEER cases. This experience might be necessary in complex anatomical findings such as a rotated heart axis after an HTX. Baseline TR was graded at the time of referral to the heart team. Thus, because of the pharmacologically optimized patient volume status prior the procedure, the given values could diverge from the pre-interventional TR in the hybrid operating room. (Semi)-quantification of the TR was applied, even though the applied methods are limited in complex jets and multiple jet origins. We herein report only the short-term outcomes after T-TEER in patients receiving HTXs; we cannot therefore draw conclusions about the long-term outcome in these patients.

CONCLUSION

T-TEER is a safe and effective technique to use for TR reduction and thus expands the therapeutic options in patients with transplanted hearts suffering from symptomatic TR refractory to optimal medical heart failure therapy.

Funding

This study received no specific grant from any funding agency in the public, commercial or not-for-profit sectors.

Conflict of interest: Martin Andreas is Proctor/Consultant/Speaker (Edwards, Abbott, Medtronic, Boston, Zoll, AbbVie) and has received Institutional Research Grants (Edwards, Abbott, Medtronic, LSI). Markus Mach has received institutional grants, research support, speaker honoraria and travel compensation from Edwards Lifesciences, Symetis SA, Jena Valve, Boston Scientific, Medtronic, Abbott and Novartis.

DATA AVAILABILITY

The data will be made available on reasonable request.

Author contributions

Tillmann Kerbel: Conceptualization; Methodology; Formal analysis; Writing—original draft preparation; Visualization. **Keziban Uyanik-Ünal:** Conceptualization; Methodology; Writing—original draft preparation. **Markus Mach:** Conceptualization; Methodology; Writing—review and editing. **Anna Bartunek:** Writing—review and editing. **Johannes Gökler:** Writing—review and editing. **Emilio Osorio:** Writing—review and editing. **Philipp Bartko:** Writing—review and editing. **Andreas Zuckermann:** Writing—review and editing. **Martin Andreas:** Conceptualization; Methodology; Formal analysis; writing—original draft preparation.

References

[1] Chan MC, Giannetti N, Kato T, Kornbluth M, Oyer P, Valantine HA *et al.* Severe tricuspid regurgitation after heart transplantation. J Heart Lung Transplant 2001;20:709–17.
[2] Kim HR, Kim HJ, Lee SE, Jung SH, Yun TJ, Kim JJ *et al.* Prevalence and Risk Factors of Post-heart Transplant Tricuspid Regurgitation. Transplantation 2022;106:e297–e303.
[3] Lopez-Vilella R, Paniagua-Martin MJ, Gonzalez-Vilchez F, Donoso Trenado V, Barge-Caballero E, Sanchez-Lazaro I *et al.* Epidemiological Study of Tricuspid Regurgitation After Cardiac Transplantation. Does It Influence Survival? Transpl Int 2022;35:10197.
[4] Wartig M, Tesan S, Gabel J, Jeppsson A, Selimovic N, Holmberg E *et al.* Tricuspid regurgitation influences outcome after heart transplantation. J Heart Lung Transplant 2014;33:829–35.
[5] Russo M, Di Mauro M, Saitto G, Lio A, Berretta P, Taramasso M *et al.* Beating Versus Arrested Heart Isolated Tricuspid Valve Surgery: Long-term Outcomes. Ann Thorac Surg 2022;113:585–92.
[6] Russo M, Di Mauro M, Saitto G, Lio A, Berretta P, Taramasso M *et al.* Outcome of patients undergoing isolated tricuspid repair or replacement surgery. Eur J Cardiothorac Surg 2022;63:ezac230.
[7] Zuckermann A, Barten MJ. Surgical wound complications after heart transplantation. Transpl Int 2011;24:627–36.
[8] Alharethi R, Bader F, Kfoury AG, Hammond ME, Karwande SV, Gilbert EM *et al.* Tricuspid valve replacement after cardiac transplantation. J Heart Lung Transplant 2006;25:48–52.
[9] Filsoufi F, Salzberg SP, Anderson CA, Couper GS, Cohn LH, Adams DH. Optimal surgical management of severe tricuspid regurgitation in cardiac transplant patients. J Heart Lung Transplant 2006;25:289–93.
[10] Goekler J, Zuckermann A, Osorio E, Brkic FF, Uyanik-Uenal K, Laufer G *et al.* Cardiac Surgery After Heart Transplantation: elective Operation or Last Exit Strategy? Transplant Direct 2017;3:e209.
[11] Goerler H, Simon A, Warnecke G, Meyer AL, Kuehn C, Haverich A *et al.* Cardiac surgery late after heart transplantation: a safe and effective treatment option. J Thorac Cardiovasc Surg 2010;140:433–9.
[12] Holmes TR, Jansz PC, Spratt P, Macdonald PS, Dhital K, Hayward C *et al.* Cardiac surgery is successful in heart transplant recipients. Heart Lung Circ 2014;23:703–10.
[13] Gokler J, Aliabadi-Zuckermann AZ, Kaider A, Ambardekar AV, Antretter H, Artemiou P *et al.* Indications, Complications, and Outcomes of Cardiac Surgery After Heart Transplantation: results From the Cash Study. Front Cardiovasc Med 2022;10:879612.
[14] Roth E, Noll G, Gamperli O, Wenaweser P, Wyss C, Grunenfelder J *et al.* Percutaneous Tricuspid Valve Repair: a Promising Treatment for Heart Transplant Patients With Severe Tricuspid Regurgitation. JACC Case Rep 2021;3:1269–74.
[15] Wosten M, Baldus S, Pfister R. Case report: transcatheter valve repair with Cardioband: a new treatment option for secondary tricuspid regurgitation in cardiac transplant patients. Eur Heart J Case Rep 2020;4:1–4.

[16] Vahanian A, Beyersdorf F, Praz F, Milojevic M, Baldus S, Bauersachs J, ESC/EACTS Scientific Document Group *et al.* 2021 ESC/EACTS Guidelines for the management of valvular heart disease. Eur J Cardiothorac Surg 2021;60:727–800.

[17] Stone GW, Adams DH, Abraham WT, Kappetein AP, Genereux P, Vranckx P, Mitral Valve Academic Research Consortium (MVARC) *et al.* Clinical trial design principles and endpoint definitions for transcatheter mitral valve repair and replacement: part 2: endpoint definitions: a consensus document from the Mitral Valve Academic Research Consortium. Eur Heart J 2015;36:1878–91.

[18] Lau GT, Tan HC, Kritharides L. Type of liver dysfunction in heart failure and its relation to the severity of tricuspid regurgitation. Am J Cardiol 2002;90:1405–9.

[19] Bishawi M, Zanotti G, Shaw L, MacKenzie M, Castleberry A, Bartels K et al Tricuspid Valve Regurgitation Immediately After Heart Transplant and Long-Term Outcomes. Ann Thorac Surg 2019;107:1348–55.

[20] Lurz P, Stephan von Bardeleben R, Weber M, Sitges M, Sorajja P, Hausleiter J, TRILUMINATE Investigators *et al.* Transcatheter Edge-to-Edge Repair for Treatment of Tricuspid Regurgitation. J Am Coll Cardiol 2021;77:229–39.

[21] Alkhouli M, Simard T, El Shaer A, Bird J, Nkomo VT, Freidman PA *et al.* First Experience With a Novel Live 3D ICE Catheter to Guide Transcatheter Structural Heart Interventions. JACC Cardiovasc Imaging 2021;15:1502–9

[22] Nguyen V, Cantarovich M, Cecere R, Giannetti N. Tricuspid regurgitation after cardiac transplantation: how many biopsies are too many? J Heart Lung Transplant 2005;24:S227–31.

[23] Koch A, Remppis A, Dengler TJ, Schnabel PA, Hagl S, Sack FU. Influence of different implantation techniques on AV valve competence after orthotopic heart transplantation. Eur J Cardiothorac Surg 2005;28: 717–23.

[24] Kaneko T, Hirji S, Zaid S, Lange R, Kempfert J, Conradi L, CUTTING-EDGE Investigators *et al.* Mitral Valve Surgery After Transcatheter Edge-to-Edge Repair: mid-Term Outcomes From the CUTTING-EDGE International Registry. JACC Cardiovasc Interv 2021;14:2010–21.