European Journal of Cardio-Thoracic Surgery 55 (2019) 191–200
doi:10.1093/ejcts/ezy391 Advance Access publication 11 December 2018

REPORT

Cite this article as: Bidar E, Folliguet T, Kluin J, Muneretto C, Parolari A, Barili F *et al*. Postimplant biological aortic prosthesis degeneration: challenges in transcatheter valve implants. Eur J Cardiothorac Surg 2019;55:191–200.

Postimplant biological aortic prosthesis degeneration: challenges in transcatheter valve implants

Elham Bidar[a], Thierry Folliguet[b], Jolanda Kluin[c], Claudio Muneretto[d], Alessandro Parolari[e], Fabio Barili[f], Piotr Suwalski[g], Nikolaos Bonaros[h], Prakash Punjabi[i], Rafa Sadaba[j], Michele De Bonis[k], Nawwar Al-Attar[l], Jean Francois Obadia[m], Martin Czerny[n], Malakh Shrestha[o], Rachid Zegdi[p], Ehsan Natour[a] and Roberto Lorusso[a,*]

[a] Department of Cardio-Thoracic Surgery, Maastricht University Medical Centre, Maastricht, Netherlands
[b] Centre Hospitalo-Universitaire Brabois ILCV, Hôpital Henri Mondor, Division of Cardio Thoracic Surgery and Transplantation, Université Paris 12 UPEC, France
[c] Department of Cardio-Thoracic Surgery, Academic Medical Center, Amsterdam, Netherlands
[d] Cardiac Surgery Unit, University of Brescia Medical School, Brescia, Italy
[e] Cardiac Surgery and Translational Research Units, IRCCS, Policlinico S. Donato, University of Milan, Milan, Italy
[f] Department of Cardiac Surgery, S. Croce Hospital, Cuneo, Italy
[g] Department of Cardiac Surgery, Central Clinical Hospital of the Ministry of Interior and Administration, Centre of Postgraduate Medical Education, Warsaw, Poland
[h] Department of Cardiac Surgery, Innsbruck Medical University, Innsbruck, Austria
[i] Department of Cardio-Thoracic Surgery, Imperial College Healthcare NHS Trust, Imperial College School of Medicine, London, UK
[j] Department of Cardiac Surgery, Hospital de Navarra, Pamplona, Spain
[k] Department of Cardiac Surgery, S. Raffaele University Hospital, Milan, Italy
[l] Department of Cardiac Surgery, Golden Jubilee National Hospital, Glasgow, UK
[m] Department of Cardio-Thoracic Surgery, Hôpital Cardiothoracique Louis Pradel, Lyon, France
[n] Department of Cardio-Vascular Surgery, University Hospital Freiburg, Freiburg, Germany
[o] Department of Cardio-Thoracic, Transplantation and Vascular Surgery, Hannover Medical School, Hannover, Germany
[p] Hôpital Européen Georges Pompidou, Paris, France

* Corresponding author. Department of Cardio-Thoracic Surgery, Heart & Vascular Centre, Maastricht University Medical Centre, P. Debeyelaan 25, 6229 HX Maastricht, Netherlands. Tel: +31-43-3876032; e-mail: roberto.lorussobs@gmail.com (R. Lorusso).

Received 28 August 2018; received in revised form 8 October 2018; accepted 15 October 2018

Abstract

Surgical aortic valve replacement (SAVR) is highly effective and can be achieved with relatively low risk in patients with severe aortic stenosis. Bioprostheses have been used most frequently during the past 60 years. However, the function of biological valves usually declines after 10–15 years from implant when structural valve degeneration occurs often mandating a reoperation once valve dysfunction becomes haemodynamically significant. Known for many years by surgeons and cardiologists taking care of patients with SAVR, the issue of postimplant structural valve degeneration has been recently highlighted also in patients with transcatheter aortic valve implant (TAVI). There is growing concern that TAVI valves exhibit structural valve degeneration due to inherent challenges of the deployment mode. The impact on postimplant degeneration of TAVI valves compared to SAVR has still to be understood and defined. Based on the ongoing process of expanding TAVI indications, several potential shortcomings and caveats, learned during the last 60 years of SAVR experience, should be taken into consideration to refine this technique.

Keywords: Transcatheter aortic valve implant • Aortic valve replacement • Structural valve degeneration • Transcatheter aortic valve degeneration

INTRODUCTION

Aortic valve stenosis (AVS) is the most prevalent valvular heart disease with a mortality rate of 15–50% in symptomatic patients if left untreated [1]. For over 60 years, surgical aortic valve replacement (SAVR) using artificial valves has provided improved life expectancy and enhanced quality of life for patients operated on [1]. Mechanical and biological prostheses have been variably used in SAVR, but tissue valves have gradually become the valve of choice [2], particularly in patients older than 60 years of age, mainly due to the lack of need for anticoagulation and the absence of valve-related noise. Despite excellent results with tissue valves in patients with SAVR, structural valve degeneration (SVD), which characterizes xenografts and is known to be multifactorial in aetiology, undermines the long-term performance and durability. In line with these surgical experiences, the explosion of the use of transcatheter aortic valve implant (TAVI) and the initial events and reports about early or medium-term SVD have

© The Author(s) 2018. Published by Oxford University Press on behalf of the European Association for Cardio-Thoracic Surgery. All rights reserved.

REPORT
https://academic.oup.com/ejcts/article/55/2/191/5238839 by Universiteit van Amsterdam user on 15 October 2025

recently alerted the scientific community to these issues. Furthermore, specific transcatheter prosthesis-related characteristics may contribute to further jeopardize their durability and should be taken into account for long-term prediction and in therapeutic decision-making.

Based on these premises, we discuss the inherent limitations of and outcomes with biological valves. Particularly in relation to SAVR, we provide a comprehensive overview about postimplant SVD, which most likely affects the longevity and performance of the new TAVI-based bioprostheses as well.

Xenografts: from surgical aortic valve replacement to transcatheter aortic valve implant

In the 1960s, dysfunctional aortic valves were successfully replaced by allografts. Ever since Dwight Harken implanted the first aortic valve in a human, biological and mechanical valves have been used for SAVR, with more than 70 types of valve prostheses implanted over time. Today biological xenografts are the most frequently used artificial valves, with valve tissue being either porcine (restructured from cusps or the aortic root of porcine aortic valves) or bovine (constructed from bovine pericardium). Progress in the field of valve engineering and the inherent anatomical features of the tissue valves have led to the development and clinical application of TAVI procedures. The first implantation of porcine valves built into endovascular stents in an animal model was carried out in 1992 [3], and the first transluminal aortic valve implant in a human took place in 2002 by Cribier [4]. Subsequently, this field has evolved with balloon-expandable and self-expandable tissue valves positioned through a guidewire in the aortic root where the native calcified valve is pushed aside towards the aortic wall. Nowadays, in Europe, there is a remarkable increase in TAVI procedures compared to a steady decline in SAVR [5]. The demonstration of the non-inferiority of TAVI results compared to SAVR results in high-risk patients [6] has paved the way for treatment of lower-risk patients and has concomitantly become an appealing option for reoperations due to tissue valve SVDs [7].

The self-expandable CoreValve, later the Evolut R (Medtronic, Inc., Minneapolis, MN, USA), is a porcine pericardial tissue valve placed into a nitinol frame that gives the stent the required flexibility to crimp in colder temperatures and the stability with shape memory to expand at warm (body core) temperatures. The Edwards Sapien 3 (Edwards Life Sciences, Inc., Irvine, CA, USA) is a balloon-expandable bovine pericardial tissue valve. Both systems are delivered through 14–16 French vascular sheaths. These 2 TAVI prostheses represent the majority of TAVI valves currently implanted. Today, a total of 8 systems are commercially available in Europe, and more types are expected to become available for clinical use in the future.

Native valve degeneration is an active process after the 'first hit'

The native cusps consist of an outer layer, valvular endothelial cells (VEC), and an inner layer, valvular interstitial cells. Carrying the burden at the centre of a highly dynamic region, the aortic valve facilitates blood transport 100 000 times a day, with different haemodynamics on the ventricular side than on the arterial (fibrosa) side [8]. Therefore, the VEC in their natural environment are exposed to severe mechanical stress consisting of systolic and diastolic pressure differences and velocity gradients. Notably, the shear stress levels on both the aortic and ventricular sides differ continuously from those in the adjacent environment [9]. Consequently, the cellular characteristics of the VEC on the fibrosa side differ from those on the ventricularis side [10]. The fibrosa layer is more susceptible to calcification than the ventricularis layer, partly because of its anatomical exposure to oscillatory flow [11, 12]. Therefore, the early stages of degeneration are the result of a disruption of the VEC as a consequence of mechanical forces, which may be seen as a 'first hit' in the degeneration cascade. After the first hit, accumulating active procalcific steps follow, including activation of inflammatory cells, resulting in fibrosis and osteogenic protein activity. Inflammatory cells precede the calcification process by degrading the extracellular matrix proteins [11]. In the native valve, the receptor activator of the nuclear factor kappa B ligand activates bone morphogenetic protein-2 and binds the receptor activator of the nuclear factor kappa. This process then leads to the differentiation of valvular interstitial cells into osteoblastic cells [13], which leads to active ossification of the aortic valve by these myofibroblasts [14]. The process is further linked to chronic inflammation combined with oxidized low-density lipoproteins (LDL) and angiotensin converting enzyme and its profibrotic AT1 receptor [15, 16]. Although angiotensin converting enzyme may be produced by local macrophages, it may also be transported into the valve by plasma LDL, signifying the importance of the role of LDL in the calcification of the native valve [16]. The levels of plasma resistin, a hormone that regulates LDL accumulation in the arterial wall, have been associated with higher calcification levels in the aortic valve [17]. Notably, despite the central role of LDL in the development of AVS and the shared risk factors of atherosclerosis and AVS [8, 18, 19], 3-hydroxy-3-methylglutaryl coenzyme A reductase inhibitors (statins) were ineffective in inhibiting AVS progression in the absence of hypercholesterolaemia [20], emphasizing the multifactorial aetiology of this disease. Hence, AVS is a systemic, multifactorial disease. Implanted tissue valves therefore are vulnerable to the environment they are exposed to as discussed below.

Xenograft degeneration is a passive process after the 'first hit'

In xenografts, the first damage to the outer layer, i.e. the first hit, occurs in a similar fashion and has to do with wear. From a histological point of view, fatigue-induced loss of hardness, collagen disruption and rearrangement of the fibre network start in the early months to years in the functioning process of surgical xenografts [21, 22], whereas late valve failure has been associated with degeneration as a result of calcification [23]. Deterioration of the biological prosthesis has to do, paradoxically, with the side effects of the protective stabilizing chemical glutaraldehyde. Ever since Carpentier introduced the chemical treatment of xenografts in 1969, glutaraldehyde (1,5 pentane dialdehyde) has been used to treat the surface of the biological cusps. It is used to reduce immunogenicity in xenograft valves because of its favourable characteristics including solubility in water and reaction at a physiological pH. Its pretreatment stabilizes the biomaterial, which prevents antigenicity and host collagenase activity from digesting the tissue [24, 25]. However, limitations of glutaraldehyde pretreatment itself have important effects and are mainly related to the toxicity of glutaraldehyde activity inside the host

Downloaded from https://academic.oup.com/ejcts/article/55/2/191/5238839 by Universiteit van Amsterdam user on 15 October 2025

environment [24]. Some authors have suggested and clinically confirmed the primary immunological effects of IgM/IgG antibodies leading to collagen breakdown through macrophage deposition on the glutaraldehyde pretreated tissue valve surface [26–29]. In fact glutaraldehyde does not entirely protect against the antigen galactose-α1,3-galactose, which stimulates human anti-Gal antibodies to mediate an immune response to tissue valve leaflets [30, 31]. Furthermore, mechanical dysfunction as a result of stiffening of the valve after glutaraldehyde pretreatment is an important issue [25]. The stiffness restricts the ability of the cusp free-edge to bulge in diastole; thus, by increasing the stress of the diastolic forces, it damages the attachment sites at the commissural level and may cause the cusp to tear [24]. However, contrary to the active calcification process occurring in the native valve after the 'first hit', further calcification of the artificial tissue valve is a passive progressive process. The damage to the biological valve, as described previously, paves the way for a passive calcium influx inside the vulnerable non-viable connective tissue aggravated by systemic diseases such as hypercholesterolaemia [32], metabolic syndrome [33], type II diabetes mellitus [34] and atherosclerosis [35]. Recently, Salaun *et al*. [36] demonstrated that degeneration of the bioprosthesis, as defined by an echocardiographically measured increase in the mean prosthesis gradient >10 mmHg or transprosthesis regurgitation, was seen in >40% of patients within 5 years and in 80% within 10 years after implant. Interestingly, independent predictors of early haemodynamic valve deterioration included diabetes mellitus, active smoking, renal insufficiency and patient-prosthesis mismatch [36].

Additionally, the accumulation of calcium has been hypothesized to occur due to a lack of an intracellular calcium-removing system in the xenograft tissue [25, 37]. This is partly evident by the success of additional antimineralization pretreatment alongside glutaraldehyde [38], which removes the phospholipid substrate in the non-viable prosthesis, enhancing its performance compared to that of non-pretreated valves [39]. Thus, mechanical stress and its related surface injury represent the important first hit in the cascade of SVD.

Potential pitfalls and challenges in transcatheter aortic valve implant

Transcatheter valves, which are also treated with glutaraldehyde, share the previously mentioned failure modes of the SAVR [40]. Therefore, several pitfalls in TAVI inherent mostly in the deployment mode may contribute to an early 'first hit' [41].

First, the leaflets of transcatheter valves are thinner than those of SAVR biological tissue valves, which allows valve crimping and mounting on the catheter-related stent and deployment device [42]. However, these factors make transcatheter valves less robust and therefore more prone to mechanical stress-related damage and fatigue-induced SVD compared to surgical valves [43]. During crimping of the valve, cracks in the glutaraldehyde layer may occur, thereby increasing the chances of damage to the valve [44]. Indeed, microscopic analysis of crimped transcatheter valves showed collagen fibre fragmentation in areas where the entire thickness of the valve was involved (Fig. 1) [45]. Second, by effectively squeezing the calcified native leaflets against the aortic wall, some parts of the calcification may protrude inside the stent and get in contact with the thin TAVI leaflets, inducing tears on its surface (Fig. 2A) or the formation of pannus (Fig. 2B).

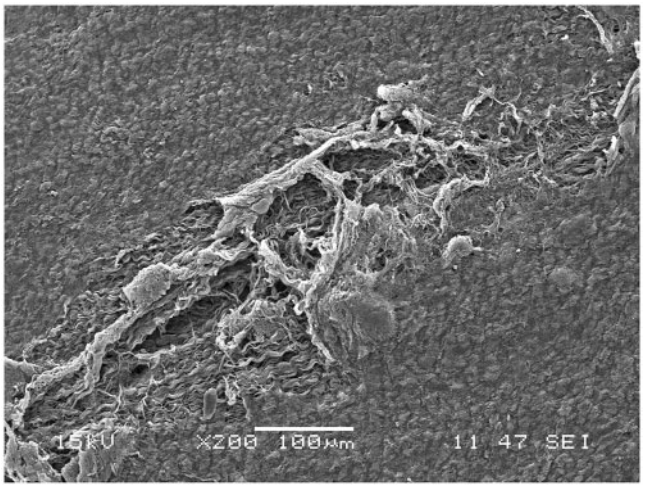

Figure 1: A 29-mm Sapien XT prosthesis (after *ex vivo* deployment) studied by scanning electronic microscopy. At ×200 magnification, an area of leaflet tearing/abrasion is shown.

Another important pitfall during the TAVI procedure is the undersizing or malposition of the valve, which has been related to volume and shape of the calcification landscape of the native valve [46, 47]. Consequently, suboptimal deployment or malpositioning in TAVI has been shown to increase leaflet stress with higher levels of fatigue damage [48, 49], compromising tissue durability. In addition, paravalvular leaks, which are known to be more common after TAVI procedures than after SAVR, are also related to this phenomenon [50, 51]. Notably, paravalvular leaks have been shown to cause heart failure and lead to increased hospitalization at 1 year [52] and to independently predict late mortality [53]. Thus the structural qualities alongside the deployment method, although heavily reducing the surgical burden, increase the stress on the tissue valve itself and should be addressed in the future development of these valves.

Prosthesis-patient mismatch

There are structural differences between porcine and pericardial biological valves. The porcine right coronary cusp has a muscle ridge at its base, which may make the valve prone to early degeneration and higher gradients in smaller sizes. Therefore, the new generation porcine valves are 'composite valves' in which the cusp is replaced by a different cusp. The bovine pericardial valve may have some haemodynamic advantages such as a larger orifice during systole [24, 54] and presumably higher collagen content than the porcine valve [55], which may contribute to longer durability. Indeed, in an animal model, porcine valves showed higher calcification rates compared to pericardial valves [38]. On the other hand, early haemodynamic valve deterioration occurred more often in pericardial compared to porcine valves [36].

In line with this observation, prosthesis-patient mismatch is certainly a relevant mechanism. Stented biological valves naturally reduce the annulus of the outflow tract due to calcification and fibrosis of the native annulus, combined with the rigid structure as well as the encumbrance of the prosthesis itself [56]. This effect is most notable when stented valves are compared to stentless valves, which emphasizes the importance of the transvalvular gradient and the gained effective orifice area after SAVR

REPORT

tps://academic.oup.com/ejcts/article/55/2/191/5238839 by Universiteit van Amsterdam user on 15 October 2025

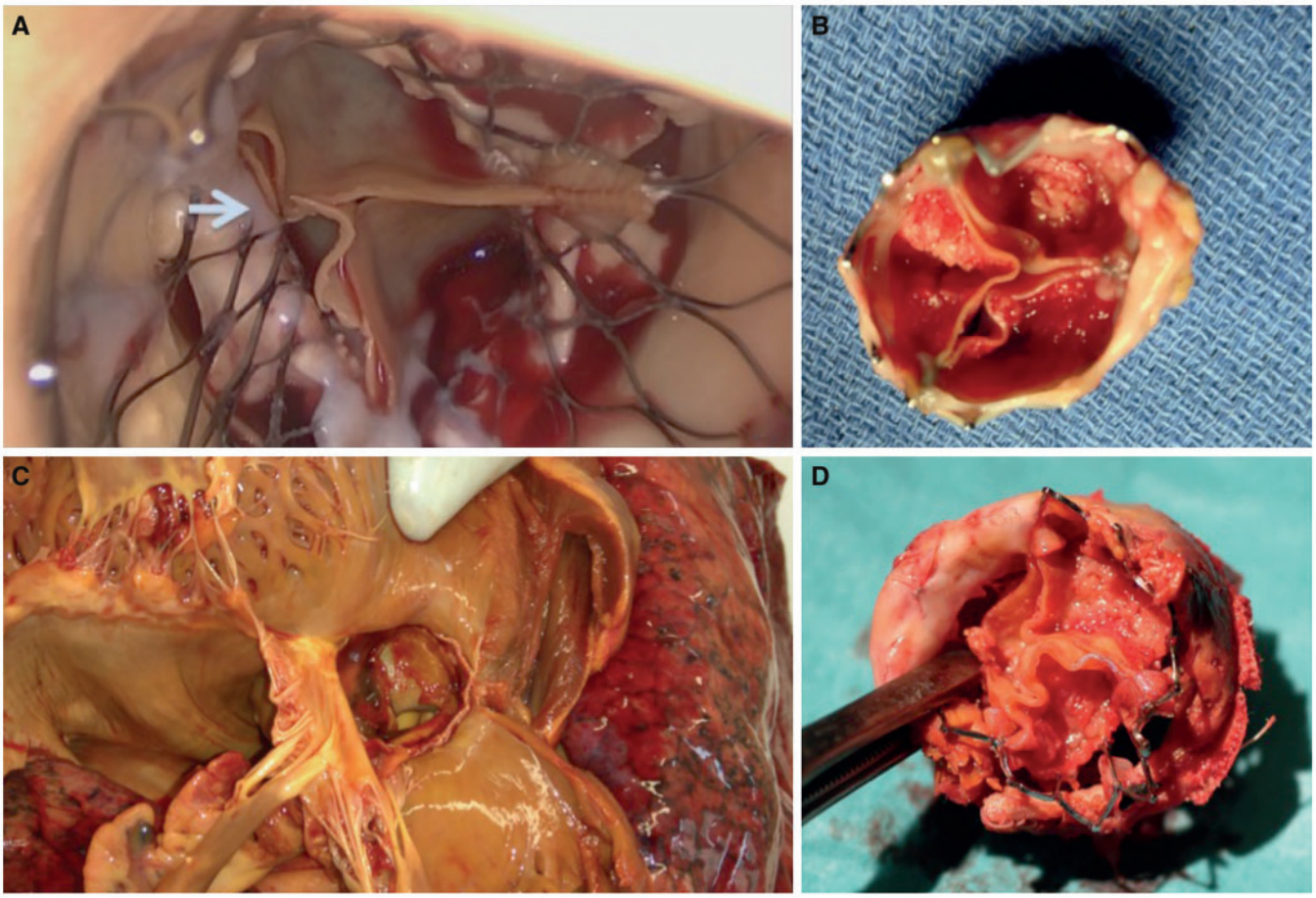

Figure 2: (**A**) Evidence of a CoreValve (Medtronic Inc., Minneapolis, MN, USA) transcatheter valve with a cusp tear occurring 1 year from implant and resulting in severe aortic insufficiency and the need for reoperation. (**B**) Example of a transcatheter valve (Edwards XT 23 mm, Edwards Lifesciences, Irvine, CA, USA) with calcification and thrombosis already being organized and exclusively affecting the aortic and not the ventricular side in an 82-year-old woman, 2.5 years after a transcatheter procedure that resulted clinically in the typical symptoms of aortic valve restenosis and that required reoperation. (**C**) Subvalvular thrombosis of a Sapien 3 (Edwards Lifesciences, Irvine, CA, USA), 26 mm, occurred 3 days after transcatheter valve implantation in a 78-year-old male patient with low-flow, low-gradient aortic stenosis who died of acute heart failure. (**D**) Explanted Edwards Sapien (Lifesciences, Irvine, CA, USA) transcatheter aortic valve positioned in a Mitroflow (Sorin Group, Milan, Italy) bioprosthesis (outer stent layer). Interestingly, also here, most calcification was seen on the aortic side, which is the side where leaflet damage would be expected during implantation due to pressure of the leaflets against the stent.

[36, 57, 58]. Early prosthesis-patient mismatch (i.e. higher gradient in seemingly normally functioning valves) leads to early valve calcification and stenosis compared to valves with a normal gradient [36, 57].

In TAVI, the calcified native valve is not removed, which potentially reduces the effective orifice area [41]. Nevertheless, compared to SAVR, TAVI shows a significantly larger increase in the aortic valve area [59]. Consequently, although SAVR shows a greater rate of left ventricular mass regression, TAVI shows significantly fewer patient-prosthesis mismatches [50, 51]. In addition, TAVI reduces the aortic gradient, increases the left ventricular ejection fraction and decreases the left ventricular mass index compared to medical therapy alone [60].

Another advantage of the transcatheter valve implant is the option of using the valve-in-valve technique [61, 62], which is often considered and relied on as an attractive solution for a dysfunctional, previously implanted SAVR bioprosthesis or after the potential early degeneration of a TAVI valve [1]. The valve-in-valve technique recently was reported to have a 93% success rate in 202 patients, with a 30-day mortality rate of 8.4% [63]. Although a TAVI valve is usually placed on top of a relatively flexible calcified native annulus, in the valve-in-valve procedure, it is placed on top of a rigid bioprosthetic stent or on top of an earlier TAVI with no margins [64] (Fig. 2D). As a result, a valve-in-valve reduces the effective orifice area, which may lead to a higher transvalvular gradient [61, 63] and a higher mortality rate [65]. As expected, this effect is more prominent when the TAVI is placed inside a stented bioprosthesis compared to TAVI in a native valve [64] or a stentless valve [63]. Nevertheless, the valve-in-valve procedure is a safe, minimally invasive technique and an important alternative for high-risk patients requiring a reoperation [65]. Notably, due to their effectiveness, these techniques are evolving fast, finding solutions such as 'cracking' the previously implanted stent to achieve a larger orifice area [66, 67].

Subvalvular thrombosis

A new emerging complication of biological valves is valve thrombosis (Fig. 2C) [68–70]. This condition is poorly visualized on transthoracic echocardiography (TTE) and is associated with higher gradients on TTE with valve thickening [71]. Indeed, this field could be underestimated because of the limitations of TTE due to beam-hardening artefacts of the stented valves [72, 73].

Downloaded from https://academic.oup.com/ejcts/article/55/2/191/5238839 by Universiteit van Amsterdam user on 15 October 2025

Table 1: Recent trials with assessment of long-term outcomes of biological aortic valves

First author, year (ref)	Number of patients	Mean age (years)	Type of valve	Mean follow-up (years)	SVD requiring reintervention	Freedom from SVD (%)	Authors' conclusions
Bourguignon *et al.*, 2015 [81]	2659	70.7 ± 10.4	Carpentier-Edwards Perimount	6.7 ± 4.8	157 (5.9%), 123 were reoperated on	10 years: 94.2 ± 0.8 20 years: 48.5 ± 4.6	With a low rate of valve-related events at 20 years, this valve remains a reliable choice, especially for patients older than 60 years.
Johnston *et al.*, 2015 [82]	12 569	71 ± 11	Carpentier-Edwards Perimount	6	423 (3.3%), 155 were reoperated on	Not reported	Durability of this valve is excellent; explant for SVD is related to gradient at implantation, especially in younger patients.
ISTHMUS Investigators, 2011 [83]	1591	75.3 ± 6.8	Mitroflow	5.1	78 (4.9%), 59 were reoperated on	18 years: 65.5 ± 2.2	This valve provides favourable long-term postoperative results in terms of valve durability and valve-related events.
Yankah *et al.*, 2008 [84]	1513	73.2 ± 0.22	Mitroflow	4 ± 0.12	64 (4.2%)	20 years: 62.3 ± 5.0	Mitroflow exhibits very low pressure gradients combined with easy implantability and low rate of valve-related events.
Christ *et al.*, 2015 [85]	50	54.5 ± 6.3	St. Jude Medical Toronto	14 ± 6	24 (48%)	10 years: 76.0 ± 6.7 15 years: 44.1 ± 8.9	In younger patients, this bioprosthesis provided reliable long-term survival despite limited durability.
David *et al.*, 2008 [86]	357	65 ± 10	St. Jude Medical Toronto	8 ± 3	49 (13.7%), 45 were reoperated on	10 years: 86 ± 3 12 years: 69 ± 4	Optimal patient survival, haemodynamic features and symptomatic improvement but suboptimal valve durability, particularly in patients <65 years.
Goldman *et al.*, 2017 [87]	710	72.4 ± 9.3	St. Jude Medical Trifecta	5	15 (2.1%), 11 were reoperated on	6 years: 95.7	Trifecta has excellent haemodynamic performance, particularly in the smaller valve sizes and exhibits excellent durability over 6 years of follow-up.
Repossini *et al.*, 2016 [88]	565	74.6 ± 8.3	Freedom Solo	7 ± 4	23 (4%)	10 years: 90.8	Given the low rate of SVD and a simple implantability, this valve proved to be a valid alternative to stented bioprostheses.
David *et al.*, 2010 [89]	1134	67 ± 11	Hancock II	12	87 (7.6%), 74 were reoperated on	10 years: 97.6 ± 0.6 15 years: 86.6 ± 1.8 20 years: 63.4 ± 4.2	Very durable valve in patients 60 years and older and is probably the gold standard of bioprosthetic valve durability in this patient population.
Une *et al.*, 2014 [90]	304	49.2 ± 9.0	Hancock II	14.2	85 (27.9%), 78 were reoperated on	10 years: 90.9 ± 2.1 15 years: 61.6 ± 4.3 20 years: 25.2 ± 5.0	Hancock II for AVR in patients <60 years is associated with excellent durability during the first decade; however, SVD increases dramatically during the second decade.
Bach and Kon, 2014 [91]	725	71.7 ± 7.9	Freestyle	8	34 (4.6%)	10 years: 96.4 ± 1.4 15 years: 85.1 ± 4.9	This valve offered good clinical outcomes in terms of freedom from structural valve deterioration; it is a viable option for the anticipated desire for long-term durability.
Guenzinger *et al.*, 2015 [92]	455	72.5 ± 9	St. Jude Medical Biocor	8 ± 6	37 (8.1%), 24 were reoperated on	10 years: 92.1 ± 1.7 15 years: 84.8 ± 3.0 20 years: 67.0 ± 7.3	Biocor prosthesis shows excellent durability with low incidence of SVD and reoperation; the incidence of SVD is higher among patients <65 years.

Continued

REPORT
https://academic.oup.com/ejcts/article/55/2/191/5238839 by Universiteit van Amsterdam user on 15 October 2025

Table 1: Continued

First author, year (ref)	Number of patients	Mean age (years)	Type of valve	Mean follow-up (years)	SVD requiring reintervention	Freedom from SVD (%)	Authors' conclusions
Barbanti *et al.*, 2015 [93]	353	81.5 ± 6.3	CoreValve	5	5 (1.4%), 2 reinterventions	Not reported	With a low rate (1.4%) of significant prosthetic valve failure, this procedure appears to be an adequate and lasting solution to treat aortic stenosis in selected high-risk patients.
Toggweiler *et al.*, 2013 [94]	88	83 ± 7	Cribier-Edwards (49) + Sapien (39)	5	0	Not reported	Favourable outcomes 5 years after successful TAVI; no patient developed severe valvular regurgitation or stenosis.
Sawaya *et al.*, 2016 [95]	114	82.3 ± 5.6	Sapien	5	0	Not reported	Long-term echocardiographic outcomes suggest stable haemodynamic function of first generation balloon-expandable Sapien at 5 years.
Gleason *et al.*, 2018 [96]	390	82.3	CoreValve	4.2	3 (0.7)	5 years: 99.2	The 5-year outcomes show a similar safety profile and freedom from severe SVD for both TAVR and SAVR.
Holy *et al.*, 2018 [97]	152		CoreValve	6.3 ± 1.0	0	Not reported	Among patients surviving beyond 5 years, none showed evidence of structural valve deterioration; long-term follow-up documents showed favourable performance of CoreValve.
Bouleti *et al.*, 2015 [98]	123	82 ± 8	CoreVavle (12) + Sapien (112)	3.6	0	Not reported	No patient required reintervention for valve failure; all prosthetic dysfunction occurred with the Sapien device.
Douglas *et al.*, 2017 [99]	2482	84.5 ± 7.2	Sapien	3.1	11 (0.4%), 5 reinterventions	Not reported	This large study of transcatheter heart valves revealed excellent durability of the valves.
Tarantini *et al.*, 2017 [100]	171	81	CoreValve (87) + Sapien (84)	4.4	3 (1.8%), 1 reintervention	Not reported	Favourable outcome at long-term follow-up after successful TAVI, independent of valve type; haemodynamic performance of prostheses was encouraging and sustained.
Deutsch *et al.*, 2018 [101]	300	81.43 ± 6.55	CoreValve (214) + Sapien (86)	7.14	11 (3.6%), 4 reinterventions	Not reported	With a cumulative incidence of 14.9% at 7 years, there is some suggestion that SVD after TAVI may become increasingly relevant during longer-term follow-up.
Eltchaninoff *et al.*, 2018 [102]	378	83.3 ± 6.8	Various (balloon-expandable)	3.1	2 (0.5%)	8 years: 87.2	Even though limited by the poor survival of the very high-risk/compassionate early population, our data do not demonstrate any risk concerning transcatheter aortic valve durability.

AVR: aortic valve replacement; SAVR: surgical aortic valve replacement; SVD: structural valve deterioration; TAVI: transaortic valve implantation; TAVR: transcatheter aortic valve replacement.

Downloaded from https://academic.oup.com/ejcts/article/55/2/191/5238839 by Universiteit van Amsterdam user on 15 October 2025

One study reported valve thrombosis in 5 (4%) patients with a normal TTE scan after using multidetector computed tomography (CT) [73]. Using CT and transoesophageal echocardiography [72], Makkar *et al.* [72] recently found reduced leaflet motion in up to 40% of patients who had a TAVI. This phenomenon of insinuating subvalvular thrombosis was resolved with the use of oral anticoagulation. In line with this finding, Del Trigo *et al.* [74] found a lack of oral anticoagulation to be a predictor of valvular haemodynamic deterioration in a TAVI cohort of more than 1500 patients. Importantly, this study only used TTE and therefore may have underestimated the incidence of 'asymptomatic' valve thrombosis. Latib *et al.* [75] found a reported incidence of 0.61% cases of TAVI valve thrombosis in a large population of 4266 patients. They also found that oral anticoagulation decreased the gradient in most of these patients [75]. Ongoing studies with advanced imaging in SAVR and TAVI settings will likely provide more conclusive information about the actual incidence and relevance of this complication.

The impact of age

For yet unknown reasons, the rate of SVD and reoperation in the first 10 years after biological valve replacement in adults is much higher in patients who are 60 years old compared with those who are >65 years old [76, 77]. Indeed, age <65 years was recently shown to be an independent predictor of clinically relevant biological degeneration of SAVR at 10 years [78]. This phenomenon is more pronounced in young and paediatric patients [37, 79]. In very young patients (average age 12 years), life-threatening calcifications of the leaflets and early dysfunction within 3 years that rapidly aggravates in 6 months have been shown [80]. One explanation for this aggressive deterioration may be an extreme immune reaction to the xenograft, which has been shown in a young rat model in which glutaraldehyde-treated xenografts unleashed an immune reaction including macrophages, eosinophils and T-cell lymphocytes leading to higher calcification rates compared to untreated grafts [29]. Interestingly, inflammation was closely correlated with calcification of the xenografts and, as expected, steroids inhibited this process [29].

Difference in durability between surgical aortic valve replacement and transcatheter aortic valve implant

Studies providing information on tissue valve durability are summarized in Table 1. Survival after SAVR is comparable with both types of valves and shows a steep decline after 10 years with freedom from SVD of 94% at 10 years, which declined by up to 50% at 20 years [103]. These findings are consistent for the pericardial (Perimount, Edward Lifesciences) [76, 82] as well as for the porcine valves (Medtronic Hancock II®) [77]. A comparison of porcine Mosaic valves with bovine Perimount valves showed a slightly increased number of early redo operations for SVD with porcine valves (2.2 vs 0.9%, $P = 0.002$, in <10 years) [104]. Notably, recent data from a large cohort of >600 patients undergoing biological SAVR revealed that, whereas freedom from clinically relevant SVD after 10 years was >96%, almost 30% showed subclinical SVD (increased gradient >10 mmHg or regurgitation) quantified by ultrasound [78]. More importantly, in this trial, freedom from all-cause mortality at 10 years was only 47.7%; most deaths were related to age and co-morbidities [78]. Although these findings show excellent results with SAVR, they underline the diseased environment in which the xenografts are applied, potentially contributing to the degenerating process and masking the survival data during the follow-up period.

TAVI has been shown to be superior to SAVR in terms of mortality and major stroke at 1 year in high-risk patients [105, 106]; to be at least comparable in terms of valve calcification [107, 108]; and not to degenerate until 6 years as shown by the results of the PARTNER (Placement of AoRTic TraNscathetER Valve) trials [6, 109]. The registries of the UK and Canada both showed 60% and 40% survival in high-risk patients at 3 and 5 years, respectively [94, 110]. Recently, the 2-year follow-up data from the PARTNER trials also confirmed the non-inferiority of TAVI compared to surgery in terms of mortality and major stroke in the intermediate-risk group [108]. It is clear that the follow-up periods available so far are not long enough to provide conclusive information about TAVI valve durability or comparison with well-known SAVR valve performance. This is especially true when considering the advanced age of the TAVI population, which leads to incomplete follow-up in most reports. Longer postoperative evaluation is needed to provide such data.

CONCLUSION

In the new era of TAVI, the tissue characteristics of the xenograft, especially the factors contributing to SVD, are still unresolved. Although improvements in the implantation system and techniques have overcome the trauma of the surgery, the vulnerability of the valve itself remains a challenge. Calcification of the tissue valve is a passive progressive disease that emerges after a 'first hit', i.e. damage to the outer layer of the valve due to, for example, an immune reaction or a haemodynamic change such as damage due to oscillatory flow on the aortic side of the valve. In TAVI, this 'first hit' may already have occurred during the implantation from balloon expansion or crimping-induced leaflet tissue damage. Furthermore, peculiar TAVI tissue valve features, like reduced leaflet thickness, compared to SAVR valves, may play an additional role in this predisposing environment for postimplant SVD, rendering the TAVI valve at higher risk of more rapid degeneration than the SAVR valve. This process may also be aggravated by a subvalvular thrombus, and the consequent need of oral anticoagulation may have much further reaching consequences than have yet been discovered. Future research should therefore not be confined to the clinical outcomes of the different valves but should invest more effort in imaging and histological diagnosis to discover the extent and pathophysiological mechanisms of tissue valve degeneration, particularly in light of the expanding indications of TAVI procedures.

ACKNOWLEDGEMENTS

The following authors were also instrumental in the final production of this manuscript thanks to their contributions to the topic under discussion: Jos G. Maessen, Suzanne Kats, Leo Veenstra, Holger Schroefel, Sebastian C.A.M. Bekkers and Bas Kietselaer.

Conflict of interest: Roberto Lorusso is Principal Investigator of PERSIST-AVR Trial sponsored by LIVANOVA. Thierry Folliguet, Past

REPORT

https://academic.oup.com/ejcts/article/55/2/191/5238839 by Universiteit van Amsterdam user on 15 October 2025

Chairman cardiovascular nucleus working group European Society of Cardiology; President European Society of Cardiac and Vascular and Endovascular Surgery. Thierry Folliguet and Malakh Shresta are part of the Steering Committee of the PERSIST-AVR Trial sponsored by LIVANOVA. Fabio Barilli reports personal fees from Abbott, outside the submitted work. The other authors have nothing to disclose.

REFERENCES

[1] Vahanian A, Alfieri O, Andreotti F, Antunes MJ, Baron-Esquivias G, Baumgartner H *et al*. Guidelines on the management of valvular heart disease (version 2012): the Joint Task Force on the Management of Valvular Heart Disease of the European Society of Cardiology (ESC) and the European Association for Cardio-Thoracic Surgery (EACTS). Eur J Cardiothorac Surg 2012;42:S1–44.
[2] Brown JM, O'Brien SM, Wu C, Sikora JA, Griffith BP, Gammie JS. Isolated aortic valve replacement in North America comprising 108,687 patients in 10 years: changes in risks, valve types, and outcomes in the Society of Thoracic Surgeons National Database. J Thorac Cardiovasc Surg 2009; 137:82–90.
[3] Andersen HR, Knudsen LL, Hasenkam JM. Transluminal implantation of artificial heart valves. Description of a new expandable aortic valve and initial results with implantation by catheter technique in closed chest pigs. Eur Heart J 1992;13:704–8.
[4] Cribier AG. The Odyssey of TAVR from concept to clinical reality. Tex Heart Inst J 2014;41:125–30.
[5] Eggebrecht H, Mehta RH. Transcatheter aortic valve implantation (TAVI) in Germany 2008-2014: on its way to standard therapy for aortic valve stenosis in the elderly? EuroIntervention 2016;11:1029–33.
[6] Mack MJ, Leon MB, Smith CR, Miller DC, Moses JW, Tuzcu EM *et al*. 5-year outcomes of transcatheter aortic valve replacement or surgical aortic valve replacement for high surgical risk patients with aortic stenosis (PARTNER 1): a randomised controlled trial. Lancet 2015;385:2477–84.
[7] Reinohl J, Kaier K, Reinecke H, Frankenstein L, Zirlik A, Zehender M *et al*. Transcatheter aortic valve replacement: the new standard in patients with previous coronary bypass grafting? JACC Cardiovasc Interv 2016;9: 2137–43.
[8] Schoen FJ, Gotlieb AI. Heart valve health, disease, replacement, and repair: a 25-year cardiovascular pathology perspective. Cardiovasc Pathol 2016;25:341–52.
[9] Butcher JT, Nerem RM. Valvular endothelial cells and the mechanoregulation of valvular pathology. Philos Trans R Soc Lond B Biol Sci 2007;362: 1445–57.
[10] Kadner A, Chen RH, Mitchell RN, Adams DH. Homograft crossmatching is unnecessary due to the absence of blood group antigens. Ann Thorac Surg 2001;71:S349–52.
[11] Hutcheson JD, Aikawa E, Merryman WD. Potential drug targets for calcific aortic valve disease. Nat Rev Cardiol 2014;11:218–31.
[12] Ankeny RF, Thourani VH, Weiss D, Vega JD, Taylor WR, Nerem RM *et al*. Preferential activation of SMAD1/5/8 on the fibrosa endothelium in calcified human aortic valves–association with low BMP antagonists and SMAD6. PLoS One 2011;6:e20969.
[13] Pawade TA, Newby DE, Dweck MR. Calcification in aortic stenosis: the skeleton key. J Am Coll Cardiol 2015;66:561–77.
[14] Rajamannan NM, Subramaniam M, Rickard D, Stock SR, Donovan J, Springett M *et al*. Human aortic valve calcification is associated with an osteoblast phenotype. Circulation 2003;107:2181–4.
[15] Mazzone A, Epistolato MC, Gianetti J, Castagnini M, Sassi C, Ceravolo R *et al*. Biological features (inflammation and neoangiogenesis) and atherosclerotic risk factors in carotid plaques and calcified aortic valve stenosis: two different sites of the same disease? Am J Clin Pathol 2006;126:494–502.
[16] O'Brien KD, Shavelle DM, Caulfield MT, McDonald TO, Olin-Lewis K, Otto CM *et al*. Association of angiotensin-converting enzyme with low-density lipoprotein in aortic valvular lesions and in human plasma. Circulation 2002;106:2224–30.
[17] Mohty D, Pibarot P, Despres JP, Cartier A, Arsenault B, Picard F *et al*. Age-related differences in the pathogenesis of calcific aortic stenosis: the potential role of resistin. Int J Cardiol 2010;142:126–32.
[18] Stewart BF, Siscovick D, Lind BK, Gardin JM, Gottdiener JS, Smith VE *et al*. Clinical factors associated with calcific aortic valve disease. Cardiovascular Health Study. J Am Coll Cardiol 1997;29:630–4.
[19] Agmon Y, Khandheria BK, Meissner I, Sicks JR, O'Fallon WM, Wiebers DO *et al*. Aortic valve sclerosis and aortic atherosclerosis: different manifestations of the same disease? Insights from a population-based study. J Am Coll Cardiol 2001;38:827–34.
[20] Chan KL, Teo K, Dumesnil JG, Ni A, Tam J; ASTRONOMER Investigators. Effect of Lipid lowering with rosuvastatin on progression of aortic stenosis: results of the aortic stenosis progression observation: measuring effects of rosuvastatin (ASTRONOMER) trial. Circulation 2010;121: 306–14.
[21] Tobaruela A, Rojo FJ, Garcia Paez JM, Bourges JY, Herrero EJ, Millan I *et al*. Indentation hardness: a simple test that correlates with the dissipated-energy predictor for fatigue-life in bovine pericardium membranes for bioprosthetic heart valves. J Mech Behav Biomed Mater 2016; 61:55–61.
[22] Broom ND. The stress/strain and fatigue behaviour of glutaraldehyde preserved heart-valve tissue. J Biomech 1977;10:707–24.
[23] Schoen FJ, Hobson CE. Anatomic analysis of removed prosthetic heart valves: causes of failure of 33 mechanical valves and 58 bioprostheses, 1980 to 1983. Hum Pathol 1985;16:549–59.
[24] Vesely I. The evolution of bioprosthetic heart valve design and its impact on durability. Cardiovasc Pathol 2003;12:277–86.
[25] Golomb G, Schoen FJ, Smith MS, Linden J, Dixon M, Levy RJ. The role of glutaraldehyde-induced cross-links in calcification of bovine pericardium used in cardiac valve bioprostheses. Am J Pathol 1987;127:122–30.
[26] Siddiqui RF, Abraham JR, Butany J. Bioprosthetic heart valves: modes of failure. Histopathology 2009;55:135–44.
[27] Butany J, Zhou T, Leong SW, Cunningham KS, Thangaroopan M, Jeggatheeswaran A *et al*. Inflammation and infection in nine surgically explanted Medtronic Freestyle stentless aortic valves. Cardiovasc Pathol 2007;16:258–67.
[28] Konakci KZ, Bohle B, Blumer R, Hoetzenecker W, Roth G, Moser B *et al*. Alpha-Gal on bioprostheses: xenograft immune response in cardiac surgery. Eur J Clin Invest 2005;35:17–23.
[29] Manji RA, Zhu LF, Nijjar NK, Rayner DC, Korbutt GS, Churchill TA *et al*. Glutaraldehyde-fixed bioprosthetic heart valve conduits calcify and fail from xenograft rejection. Circulation 2006;114:318–27.
[30] Manji RA, Lee W, Cooper DKC. Xenograft bioprosthetic heart valves: past, present and future. Int J Surg 2015;23:280–4.
[31] Naso F, Gandaglia A, Bottio T, Tarzia V, Nottle MB, d'Apice AJ *et al*. First quantification of alpha-Gal epitope in current glutaraldehyde-fixed heart valve bioprostheses. Xenotransplantation 2013;20:252–61.
[32] Farivar RS, Cohn LH. Hypercholesterolemia is a risk factor for bioprosthetic valve calcification and explantation. J Thorac Cardiovasc Surg 2003;126:969–75.
[33] Briand M, Pibarot P, Despres JP, Voisine P, Dumesnil JG, Dagenais F *et al*. Metabolic syndrome is associated with faster degeneration of bioprosthetic valves. Circulation 2006;114:I512–7.
[34] Lorusso R, Gelsomino S, Luca F, De Cicco G, Bille G, Carella R *et al*. Type 2 diabetes mellitus is associated with faster degeneration of bioprosthetic valve: results from a propensity score-matched Italian multicenter study. Circulation 2012;125:604–14.
[35] Nollert G, Miksch J, Kreuzer E, Reichart B. Risk factors for atherosclerosis and the degeneration of pericardial valves after aortic valve replacement. J Thorac Cardiovasc Surg 2003;126:965–8.
[36] Salaun E, Mahjoub H, Dahou A, Mathieu P, Larose E, Despres JP *et al*. Hemodynamic deterioration of surgically implanted bioprosthetic aortic valves. J Am Coll Cardiol 2018;72:241–51.
[37] Schoen FJ, Levy RJ. Calcification of tissue heart valve substitutes: progress toward understanding and prevention. Ann Thorac Surg 2005;79: 1072–80.
[38] Flameng W, Meuris B, Yperman J, De Visscher G, Herijgers P, Verbeken E. Factors influencing calcification of cardiac bioprostheses in adolescent sheep. J Thorac Cardiovasc Surg 2006;132:89–98.
[39] Flameng W, Rega F, Vercalsteren M, Herijgers P, Meuris B. Antimineralization treatment and patient-prosthesis mismatch are major determinants of the onset and incidence of structural valve degeneration in bioprosthetic heart valves. J Thorac Cardiovasc Surg 2014;147:1219–24.
[40] Mylotte D, Andalib A, Theriault-Lauzier P, Dorfmeister M, Girgis M, Alharbi W *et al*. Transcatheter heart valve failure: a systematic review. Eur Heart J 2015;36:1306–27.
[41] Dasi LP, Hatoum H, Kheradvar A, Zareian R, Alavi SH, Sun W *et al*. On the mechanics of transcatheter aortic valve replacement. Ann Biomed Eng 2017;45:310–31.
[42] Tseng EE, Wisneski A, Azadani AN, Ge L. Engineering perspective on transcatheter aortic valve implantation. Intervent Cardiol 2013;5:53–70.

Downloaded from https://academic.oup.com/ejcts/article/55/2/191/5238839 by Universiteit van Amsterdam user on 15 October 2025

[43] Martin C, Sun W. Comparison of transcatheter aortic valve and surgical bioprosthetic valve durability: a fatigue simulation study. J Biomech 2015;48:3026–34.
[44] Bourget JM, Zegdi R, Lin J, Wawryko P, Merhi Y, Convelbo C. Correlation between structural changes and acute thrombogenicity in transcatheter pericardium valves after crimping and balloon deployment. Morphologie 2017;101:19–32.
[45] Zegdi R, Bruneval P, Blanchard D, Fabiani JN. Evidence of leaflet injury during percutaneous aortic valve deployment. Eur J Cardiothorac Surg 2011;40:257–9.
[46] Sturla F, Ronzoni M, Vitali M, Dimasi A, Vismara R, Preston-Maher G *et al*. Impact of different aortic valve calcification patterns on the outcome of transcatheter aortic valve implantation: a finite element study. J Biomech 2016;49:2520–30.
[47] Fonseca P, Figueiredo B, Almeida C, Almeida J, Bettencourt N, Sampaio F *et al*. Aortic valve calcium volume predicts paravalvular regurgitation and the need for balloon post-dilatation after transcatheter aortic valve implantation. J Interv Cardiol 2016;29:117–23.
[48] Martin C, Sun W. Transcatheter valve underexpansion limits leaflet durability: implications for valve-in-valve procedures. Ann Biomed Eng 2017;45:394–404.
[49] Abbasi M, Azadani AN. Leaflet stress and strain distributions following incomplete transcatheter aortic valve expansion. J Biomech 2015;48: 3663–71.
[50] Kim SJ, Samad Z, Bloomfield GS, Douglas PS. A critical review of hemodynamic changes and left ventricular remodeling after surgical aortic valve replacement and percutaneous aortic valve replacement. Am Heart J 2014;168:150–9.e1–7.
[51] Ngo A, Hassager C, Thyregod HGH, Sondergaard L, Olsen PS, Steinbruchel D *et al*. Differences in left ventricular remodelling in patients with aortic stenosis treated with transcatheter aortic valve replacement with corevalve prostheses compared to surgery with porcine or bovine biological prostheses. Eur Heart J Cardiovasc Imaging 2018;19:39–46.
[52] Kodali S, Pibarot P, Douglas PS, Williams M, Xu K, Thourani V *et al*. Paravalvular regurgitation after transcatheter aortic valve replacement with the Edwards sapien valve in the PARTNER trial: characterizing patients and impact on outcomes. Eur Heart J 2015;36:449–56.
[53] Gilard M, Eltchaninoff H, Donzeau-Gouge P, Chevreul K, Fajadet J, Leprince P *et al*. Late outcomes of transcatheter aortic valve replacement in high-risk patients: the FRANCE-2 registry. J Am Coll Cardiol 2016;68: 1637–47.
[54] Gao G, Wu Y, Grunkemeier GL, Furnary AP, Starr A. Durability of pericardial versus porcine aortic valves. J Am Coll Cardiol 2004;44:384–8.
[55] Liao K, Seifter E, Hoffman D, Yellin EL, Frater RW. Bovine pericardium versus porcine aortic valve: comparison of tissue biological properties as prosthetic valves. Artif Organs 1992;16:361–5.
[56] Pibarot P, Dumesnil JG. Hemodynamic and clinical impact of prosthesis-patient mismatch in the aortic valve position and its prevention. J Am Coll Cardiol 2000;36:1131–41.
[57] Flameng W, Herregods MC, Vercalsteren M, Herijgers P, Bogaerts K, Meuris B. Prosthesis-patient mismatch predicts structural valve degeneration in bioprosthetic heart valves. Circulation 2010;121:2123–9.
[58] Yun KL, Sintek CF, Fletcher AD, Pfeffer TA, Kochamba GS, Hyde MR *et al*. Aortic valve replacement with the freestyle stentless bioprosthesis: five-year experience. Circulation 1999;100:II17–23.
[59] Ngo A, Hassager C, Thyregod HGH, Sondergaard L, Olsen PS, Steinbruchel D *et al*. Differences in left ventricular remodelling in patients with aortic stenosis treated with transcatheter aortic valve replacement with corevalve prostheses compared to surgery with porcine or bovine biological prostheses. Eur Heart J Cardiovasc Imaging 2018;19: 39–46.
[60] Douglas PS, Hahn RT, Pibarot P, Weissman NJ, Stewart WJ, Xu K *et al*. Hemodynamic outcomes of transcatheter aortic valve replacement and medical management in severe, inoperable aortic stenosis: a longitudinal echocardiographic study of cohort B of the PARTNER trial. J Am Soc Echocardiogr 2015;28:210–7.e1–9.
[61] Silva D, Stripling JH, Hansen L, Riess FC. Aortic valve replacement after transapical valve-in-valve implantation. Ann Thorac Surg 2011;91:e5–7.
[62] Webb JG, Mack MJ, White JM, Dvir D, Blanke P, Herrmann HC *et al*. Transcatheter aortic valve implantation within degenerated aortic surgical bioprostheses: PARTNER 2 valve-in-valve registry. J Am Coll Cardiol 2017;69:2253–62.
[63] Dvir D, Webb J, Brecker S, Bleiziffer S, Hildick-Smith D, Colombo A *et al*. Transcatheter aortic valve replacement for degenerative bioprosthetic surgical valves: results from the global valve-in-valve registry. Circulation 2012;126:2335–44.
[64] Tuzcu EM, Kapadia SR, Vemulapalli S, Carroll JD, Holmes DR Jr, Mack MJ *et al*. Transcatheter aortic valve replacement of failed surgically implanted bioprostheses: the STS/ACC registry. J Am Coll Cardiol 2018; 72:370–82.
[65] Paradis JM, Del Trigo M, Puri R, Rodes-Cabau J. Transcatheter valve-in-valve and valve-in-ring for treating aortic and mitral surgical prosthetic dysfunction. J Am Coll Cardiol 2015;66:2019–37.
[66] Loyalka P, Montgomery KB, Nguyen TC, Smalling RW, Howe M, Rajagopal K. Valve-in-valve transcatheter aortic valve implantation: a novel approach to treat paravalvular leak. Ann Thorac Surg 2017;104:e325–27.
[67] Tanase D, Grohmann J, Schubert S, Uhlemann F, Eicken A, Ewert P. Cracking the ring of Edwards Perimount bioprosthesis with ultrahigh pressure balloons prior to transcatheter valve in valve implantation. Int J Cardiol 2014;176:1048–9.
[68] Heras M, Chesebro JH, Fuster V, Penny WJ, Grill DE, Bailey KR *et al*. High risk of thromboemboli early after bioprosthetic cardiac valve replacement. J Am Coll Cardiol 1995;25:1111–19.
[69] Brown ML, Park SJ, Sundt TM, Schaff HV. Early thrombosis risk in patients with biologic valves in the aortic position. J Thorac Cardiovasc Surg 2012;144:108–11.
[70] Poels TT, Veenstra L, van Ommen V, Kietselaer BL, Das M, Maessen JG *et al*. Severely Thrombosed transcatheter aortic valve 9 months after implantation. Ann Thorac Surg 2015;100:1441.
[71] Cordoba-Soriano JG, Puri R, Amat-Santos I, Ribeiro HB, Abdul-Jawad Altisent O, del Trigo M *et al*. Valve thrombosis following transcatheter aortic valve implantation: a systematic review. Rev Esp Cardiol (Engl Ed) 2015;68:198–204.
[72] Makkar RR, Fontana G, Jilaihawi H, Chakravarty T, Kofoed KF, de Backer O *et al*. Possible subclinical leaflet thrombosis in bioprosthetic aortic valves. N Engl J Med 2015;373:2015–24.
[73] Leetmaa T, Hansson NC, Leipsic J, Jensen K, Poulsen SH, Andersen HR *et al*. Early aortic transcatheter heart valve thrombosis: diagnostic value of contrast-enhanced multidetector computed tomography. Circ Cardiovasc Interv 2015;8. pii: e001596.
[74] Del Trigo M, Munoz-Garcia AJ, Wijeysundera HC, Nombela-Franco L, Cheema AN, Gutierrez E *et al*. Incidence, timing, and predictors of valve hemodynamic deterioration after transcatheter aortic valve replacement: multicenter registry. J Am Coll Cardiol 2016;67:644–55.
[75] Latib A, Naganuma T, Abdel-Wahab M, Danenberg H, Cota L, Barbanti M *et al*. Treatment and clinical outcomes of transcatheter heart valve thrombosis. Circ Cardiovasc Interv 2015;8. pii: e001779.
[76] Bourguignon T, Bouquiaux-Stablo AL, Candolfi P, Mirza A, Loardi C, May MA *et al*. Very long-term outcomes of the Carpentier-Edwards Perimount valve in aortic position. Ann Thorac Surg 2015;99:831–7.
[77] Borger MA, Ivanov J, Armstrong S, Christie-Hrybinsky D, Feindel CM, David TE. Twenty-year results of the Hancock II bioprosthesis. J Heart Valve Dis 2006;15:49–55; discussion 55–6.
[78] Rodriguez-Gabella T, Voisine P, Dagenais F, Mohammadi S, Perron J, Dumont E *et al*. Long-term outcomes following surgical aortic bioprosthesis implantation. J Am Coll Cardiol 2018;71:1401–12.
[79] Karamlou T, Jang K, Williams WG, Caldarone CA, Van Arsdell G, Coles JG *et al*. Outcomes and associated risk factors for aortic valve replacement in 160 children: a competing-risks analysis. Circulation 2005;112:3462–9.
[80] Saleeb SF, Newburger JW, Geva T, Baird CW, Gauvreau K, Padera RF *et al*. Accelerated degeneration of a bovine pericardial bioprosthetic aortic valve in children and young adults. Circulation 2014;130:51–60.
[81] Bourguignon T, El Khoury R, Candolfi P, Loardi C, Mirza A, Boulanger-Lothion J *et al*. Very long-term outcomes of the Carpentier-Edwards Perimount aortic valve in patients aged 60 or younger. Ann Thorac Surg 2015;100:853–9.
[82] Johnston DR, Soltesz EG, Vakil N, Rajeswaran J, Roselli EE, Sabik JF 3rd *et al*. Long-term durability of bioprosthetic aortic valves: implications from 12,569 implants. Ann Thorac Surg 2015;99:1239–47.
[83] ISTHMUS Investigators. The Italian study on the Mitroflow postoperative results (ISTHMUS): a 20-year, multicentre evaluation of Mitroflow pericardial bioprosthesis. Eur J Cardiothorac Surg 2011;39:18–26; discussion 26.
[84] Yankah CA, Pasic M, Musci M, Stein J, Detschades C, Siniawski H *et al*. Aortic valve replacement with the Mitroflow pericardial bioprosthesis: durability results up to 21 years. J Thorac Cardiovasc Surg 2008;136: 688–96.
[85] Christ T, Claus B, Borck R, Konertz W, Grubitzsch H. The St. Jude Toronto stentless bioprosthesis: up to 20 years follow-up in younger patients. Heart Surg Forum 2015;18:129–33.

REPORT

tps://academic.oup.com/ejcts/article/55/2/191/5238839 by Universiteit van Amsterdam user on 15 October 2025

[86] David TE, Feindel CM, Bos J, Ivanov J, Armstrong S. Aortic valve replacement with Toronto SPV bioprosthesis: optimal patient survival but suboptimal valve durability. J Thorac Cardiovasc Surg 2008;135: 19–24.
[87] Goldman S, Cheung A, Bavaria JE, Petracek MR, Groh MA, Schaff HV. Midterm, multicenter clinical and hemodynamic results for the Trifecta aortic pericardial valve. J Thorac Cardiovasc Surg 2017;153:561–9.e2.
[88] Repossini A, Fischlein T, Santarpino G, Schafer C, Claus B, Passaretti B *et al*. Pericardial stentless valve for aortic valve replacement: long-term results. Ann Thorac Surg 2016;102:1956–65.
[89] David TE, Armstrong S, Maganti M. Hancock II bioprosthesis for aortic valve replacement: the gold standard of bioprosthetic valves durability? Ann Thorac Surg 2010;90:775–81.
[90] Une D, Ruel M, David TE. Twenty-year durability of the aortic Hancock II bioprosthesis in young patients: is it durable enough? Eur J Cardiothorac Surg 2014;46:825–30.
[91] Bach DS, Kon ND. Long-term clinical outcomes 15 years after aortic valve replacement with the Freestyle stentless aortic bioprosthesis. Ann Thorac Surg 2014;97:544–51.
[92] Guenzinger R, Fiegl K, Wottke M, Lange RS. Twenty-seven-year experience with the St. Jude Medical Biocor bioprosthesis in the aortic position. Ann Thorac Surg 2015;100:2220–6.
[93] Barbanti M, Petronio AS, Ettori F, Latib A, Bedogni F, De Marco F *et al*. 5-year outcomes after transcatheter aortic valve implantation with CoreValve prosthesis. JACC Cardiovasc Interv 2015;8:1084–91.
[94] Toggweiler S, Humphries KH, Lee M, Binder RK, Moss RR, Freeman M *et al*. 5-year outcome after transcatheter aortic valve implantation. J Am Coll Cardiol 2013;61:413–19.
[95] Sawaya F, Kappetein AP, Wisser W, Nataf P, Thomas M, Schachinger V *et al*. Five-year haemodynamic outcomes of the first-generation SAPIEN balloon-expandable transcatheter heart valve. EuroIntervention 2016;12: 775–82.
[96] Gleason TG, Reardon MJ, Popma JJ, Deeb GM, Yakubov SJ, Lee JS *et al*. Self-expanding transcatheter aortic valve replacement or surgical valve replacement in high-risk patients: 5-year outcomes. J Am Coll Cardiol 2018. pii: S0735-1097(18)38290-1.
[97] Holy EW, Kebernik J, Abdelghani M, Stampfli SF, Hellermann J, Allali A *et al*. Long-term durability and haemodynamic performance of a self-expanding transcatheter heart valve beyond five years after implantation: a prospective observational study applying the standardised definitions of structural deterioration and valve failure. EuroIntervention 2018;14:e390–6.
[98] Bouleti C, Himbert D, Iung B, Alos B, Kerneis C, Ghodbane W *et al*. Long-term outcome after transcatheter aortic valve implantation. Heart 2015;101:936–42.
[99] Douglas PS, Leon MB, Mack MJ, Svensson LG, Webb JG, Hahn RT *et al*. Longitudinal hemodynamics of transcatheter and surgical aortic valves in the PARTNER trial. JAMA Cardiol 2017;2:1197–206.
[100] Tarantini G, Purita PAM, D'Onofrio A, Fraccaro C, Frigo AC, D'Amico G *et al*. Long-term outcomes and prosthesis performance after transcatheter aortic valve replacement: results of self-expandable and balloon-expandable transcatheter heart valves. Ann Cardiothorac Surg 2017;6:473–83.
[101] Deutsch MA, Erlebach M, Burri M, Hapfelmeier A, Witt OG, Ziegelmueller JA *et al*. Beyond the five-year horizon: long-term outcome of high-risk and inoperable patients undergoing TAVR with first-generation devices. EuroIntervention 2018;14:41–9.
[102] Eltchaninoff H, Durand E, Avinee G, Tron C, Litzler PY, Bauer F *et al*. Assessment of structural valve deterioration of transcatheter aortic bioprosthetic balloon-expandable valves using the new European consensus definition. EuroIntervention 2018;14:e264–71.
[103] Foroutan F, Guyatt GH, O'Brien K, Bain E, Stein M, Bhagra S *et al*. Prognosis after surgical replacement with a bioprosthetic aortic valve in patients with severe symptomatic aortic stenosis: systematic review of observational studies. BMJ 2016;354:i5065.
[104] Webb J, Parkin D, Tondel K, Simitsis P, Roxburgh J, Chambers JB. A comparison of early redo surgery rates in Mosaic porcine and Perimount bovine pericardial valves. Eur J Cardiothorac Surg 2018;54:724–8.
[105] Reardon MJ, Adams DH, Kleiman NS, Yakubov SJ, Coselli JS, Deeb GM *et al*. 2-year outcomes in patients undergoing surgical or self-expanding transcatheter aortic valve replacement. J Am Coll Cardiol 2015;66:113–21.
[106] Thourani VH, Kodali S, Makkar RR, Herrmann HC, Williams M, Babaliaros V *et al*. Transcatheter aortic valve replacement versus surgical valve replacement in intermediate-risk patients: a propensity score analysis. Lancet 2016;387:2218–25.
[107] Sulzenko J, Tousek P, Kocka V, Bednar F, Linkova H, Petr R *et al*. Degenerative changes and immune response after transcatheter aortic valve implantation. Comparison with surgical aortic valve replacement. J Cardiol 2017;69:483–8.
[108] Leon MB, Smith CR, Mack MJ, Makkar RR, Svensson LG, Kodali SK *et al*. Transcatheter or surgical aortic-valve replacement in intermediate-risk patients. N Engl J Med 2016;374:1609–20.
[109] Kapadia SR, Leon MB, Makkar RR, Tuzcu EM, Svensson LG, Kodali S *et al*. 5-year outcomes of transcatheter aortic valve replacement compared with standard treatment for patients with inoperable aortic stenosis (PARTNER 1): a randomised controlled trial. Lancet 2015;385:2485–91.
[110] Duncan A, Ludman P, Banya W, Cunningham D, Marlee D, Davies S *et al*. Long-term outcomes after transcatheter aortic valve replacement in high-risk patients with severe aortic stenosis: the U.K. Transcatheter Aortic Valve Implantation Registry. JACC Cardiovasc Interv 2015;8: 645–53.

Downloaded from https://academic.oup.com/ejcts/article/55/2/191/5238839 by Universiteit van Amsterdam user on 15 October 2025

thoraflex™ **hybrid**

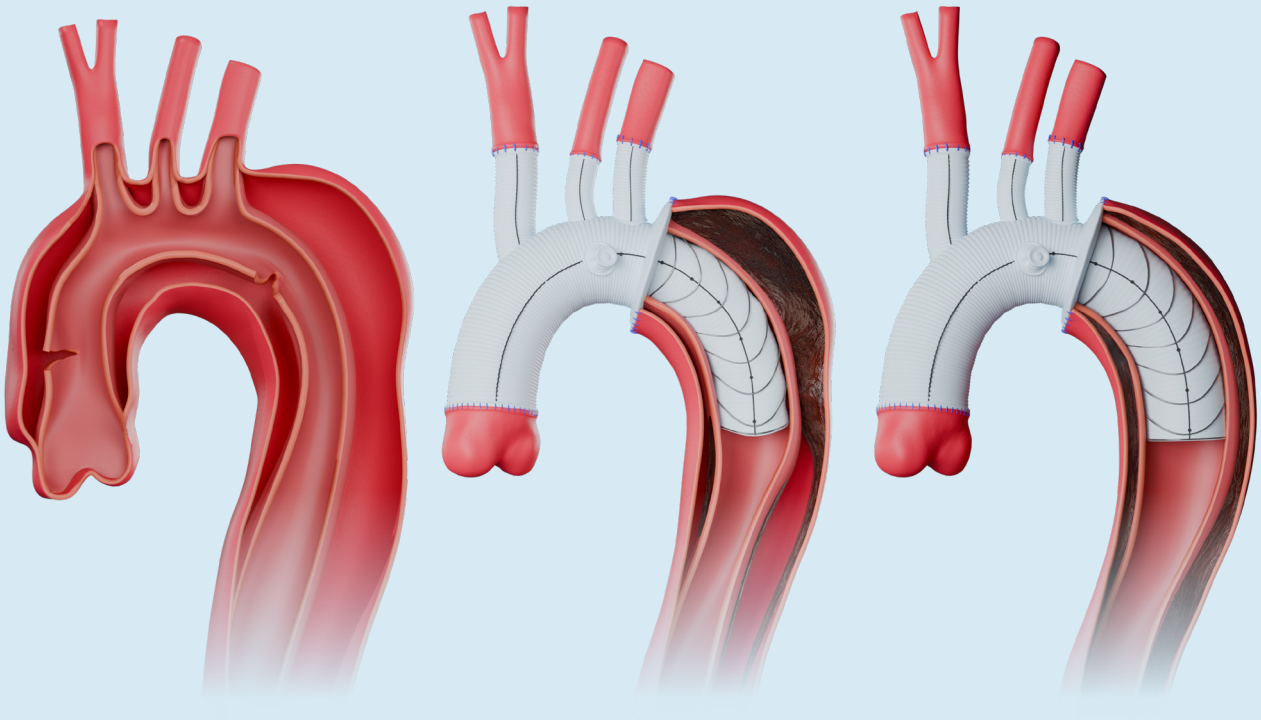

Remodelling and Aneurysmal Regression with Thoraflex™ Hybrid

Flexible. Effective. Transformative.

73%
Aneurysm Sac Regression around FET*
(29/40) [1]

100%
False Lumen Thrombosis**
(within 2 years) [2]

81%
Freedom from Unplanned Distal Intervention
(at 5 years) [3]

Discover more
terumoaortic.com/thoraflex-hybrid

LinkedIn VuMedi X

* FET = Frozen Elephant Trunk
** At the level of the stent graft

1. Chu M *et al.* (2019). Early Clinical Outcomes of Hybrid Arch Frozen Elephant Trunk Repair With the Thoraflex Hybrid Graft. *Annals of Thoracic Surgery*; 107(1), pp47-53.
2. Shrestha M *et al.* (2016). Total aortic arch replacement with a novel 4-branched frozen elephant trunk prosthesis: single-centre results of the first 100 patients. *Journal of Thoracic & Cardiovascular Surgery;* 152(1), pp148-159.
3. Shimamura J *et al.* (2023). Five-Year Outcomes of Hybrid Arch Frozen Elephant Trunk Repair With Novel Multibranched Hybrid Graft. *Annals of Thoracic Surgery Short Reports*; 1(4), pp599-603.

TERUMO AORTIC

PM-09857

View IFU at eifu.terumoaortic.com for more information on use, indications, contraindications and warnings/precautions.

Product availability subject to local regulatory approval.
For distributor information, visit terumoaortic.com/contact

Vascutek Ltd.
Newmains Avenue, Inchinnan,
Renfrewshire, PA4 9RR, United Kingdom