University of Southern Denmark

Direct Visualization of TAVR-Related Coronary Artery Management Techniques in Reanimated Beating Hearts

Sanchez, Jorge Zhingre; Burzotta, Francesco; Valenzuela, Thomas; Lassen, Jens Flensted; Iles, Tinen; Iaizzo, Paul A.

Published in:
JACC: Cardiovascular Interventions

DOI:
10.1016/j.jcin.2021.02.045

Publication date:
2021

Document version:
Final published version

Document license:
CC BY-NC-ND

Citation for pulished version (APA):
Sanchez, J. Z., Burzotta, F., Valenzuela, T., Lassen, J. F., Iles, T., & Iaizzo, P. A. (2021). Direct Visualization of TAVR-Related Coronary Artery Management Techniques in Reanimated Beating Hearts. *JACC: Cardiovascular Interventions*, *14*(9), e87-e91. https://doi.org/10.1016/j.jcin.2021.02.045

Go to publication entry in University of Southern Denmark's Research Portal

Terms of use
This work is brought to you by the University of Southern Denmark.
Unless otherwise specified it has been shared according to the terms for self-archiving.
If no other license is stated, these terms apply:

- You may download this work for personal use only.
- You may not further distribute the material or use it for any profit-making activity or commercial gain
- You may freely distribute the URL identifying this open access version

If you believe that this document breaches copyright please contact us providing details and we will investigate your claim.
Please direct all enquiries to puresupport@bib.sdu.dk

Download date: 02. Apr. 2026

JACC: CARDIOVASCULAR INTERVENTIONS VOL. 14, NO. 9, 2021
© 2021 THE AUTHORS. PUBLISHED BY ELSEVIER ON BEHALF OF THE AMERICAN COLLEGE OF CARDIOLOGY FOUNDATION. THIS IS AN OPEN ACCESS ARTICLE UNDER THE CC BY-NC-ND LICENSE (http://creativecommons.org/licenses/by-nc-nd/4.0/).

IMAGES IN INTERVENTION

Direct Visualization of TAVR-Related Coronary Artery Management Techniques in Reanimated Beating Hearts

Jorge Zhingre Sanchez, PhD,[a,b] Francesco Burzotta, MD, PhD,[c,d] Thomas Valenzuela, BS,[a] Jens Flensted Lassen, MD, PhD,[e] Tinen Iles, PhD,[a] Paul A. Iaizzo, PhD[a]

Despite improvements in transcatheter aortic valve replacement (TAVR), post-TAVR percutaneous coronary intervention and periprocedural coronary occlusion represent major issues. To assess the interactions between TAVR prostheses, coronary ostia, and percutaneous coronary intervention devices, we tested TAVR-related coronary techniques using Visible Heart methodologies (1). This study complied with the guidelines by the Institutional Animal Care and Use Committee (University of Minnesota). The selected TAVR system was Evolut self-expandable prosthesis (Medtronic, Minneapolis, Minnesota). Procedures were conducted under fluoroscopic guidance by 2 expert interventional cardiologists, while endoscopic visualization was simultaneously recorded. Coronary cannulation and percutaneous coronary intervention were performed after single Evolut self-expandable prosthesis implantation and after transcatheter aortic valve-in-transcatheter aortic valve. The collected endoscopic footages highlighted the jailed coronary artery ostia appearance and the optimal cannulation achieved in challenging scenarios (**Figures 1 and 2,** Videos 1 and 2). Furthermore, 2 stent-based techniques for intraprocedural coronary occlusion prevention/management were tested. In particular, the "classic" chimney/snorkel procedure and the novel orthotopic snorkel stenting technique (2) were directly visualized and the obtained results were assessed by microcomputed tomography (**Figures 3 and 4,** Videos 3 and 4).

FUNDING SUPPORT AND AUTHOR DISCLOSURES

The funding and CoreValve Evolut TAVR products for this work were provided through a research contract with Medtronic. Dr. Sanchez is employed by Medtronic. Dr. Burzotta received speaker fees from Abbott, Medtronic, and Abiomed. Dr. Iaizzo has a research contract with Medtronic and serves as an educational consultant. All other authors have reported that they have no relationships relevant to the contents of this paper to disclose.

ADDRESS FOR CORRESPONDENCE: Dr. Francesco Burzotta, Università Cattolica del Sacro Cuore, Fondazione Policlinico Universitario A. Gemelli IRCCS, L.go Gemelli 1, 00168 Rome, Italy. E-mail: francesco.burzotta@unicatt.it.

From the [a]Visible Heart Laboratories, Department of Surgery, University of Minnesota, Minneapolis, Minnesota, USA; [b]Medtronic Inc., Minneapolis, Minnesota, USA; [c]Università Cattolica del Sacro Cuore, Rome, Italy; [d]Dipartimento di Scienze Cardiovascolari, Fondazione Policlinico Universitario A. Gemelli IRCCS, Rome, Italy; and the [e]Department of Cardiology B, Odense University Hospital and University of Southern Denmark, Odense, Denmark.

The authors attest they are in compliance with human studies committees and animal welfare regulations of the authors' institutions and Food and Drug Administration guidelines, including patient consent where appropriate. For more information, visit the Author Center.

Manuscript received January 28, 2021; accepted February 16, 2021.

ISSN 1936-8798 https://doi.org/10.1016/j.jcin.2021.02.045

JACC: CARDIOVASCULAR INTERVENTIONS VOL. 14, NO. 9, 2021
MAY 10, 2021:e87–91

FIGURE 1 Coronary Ostia Appearance and Coronary Cannulation With Guiding Catheter After TAVR

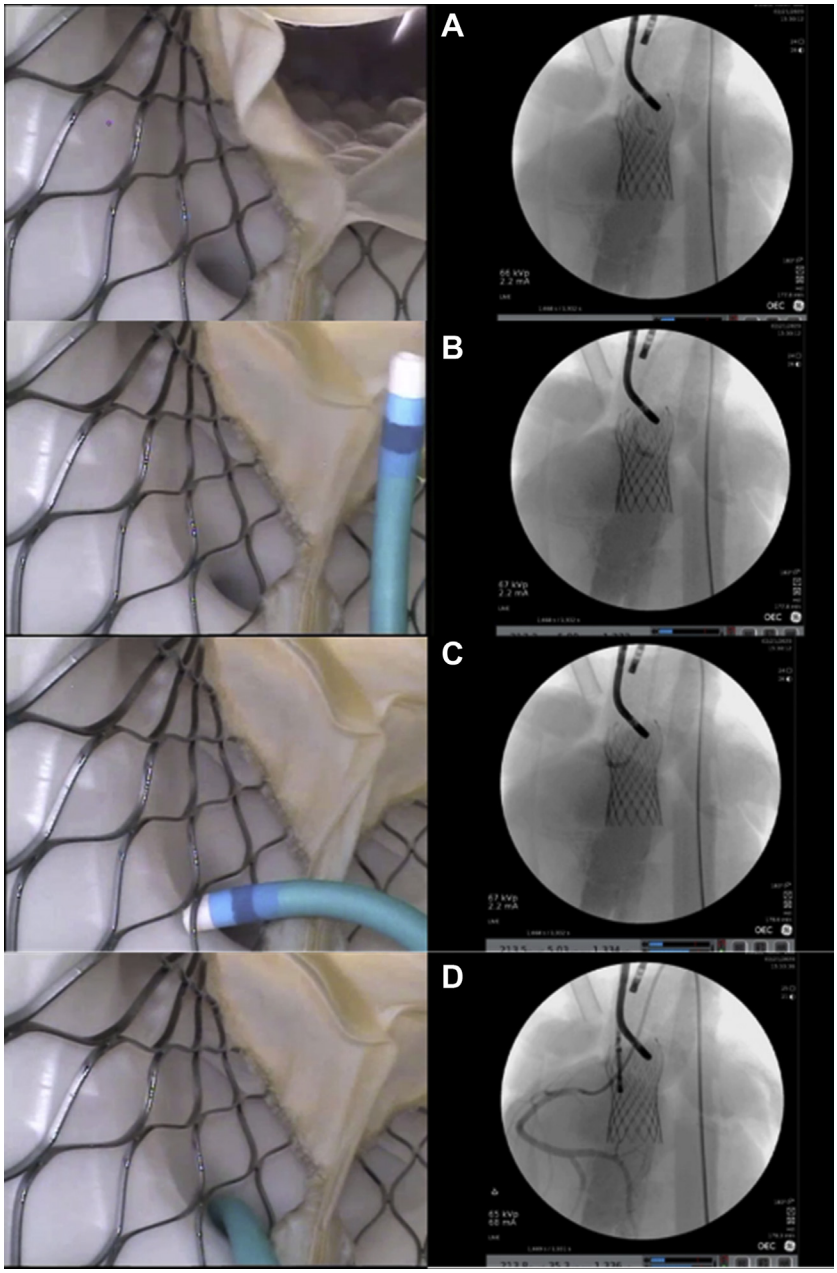

(A) Low take-off of right coronary artery and adverse alignment of ESEP commissural post are evident. **(B to D)** Selective cannulation is achieved. ESEP = Evolut self-expandable prosthesis; TAVR = transcatheter aortic valve replacement.

FIGURE 2 Coronary Ostia Appearance and Selective Coronary Cannulation With Guiding Catheter After TAV-in-TAV

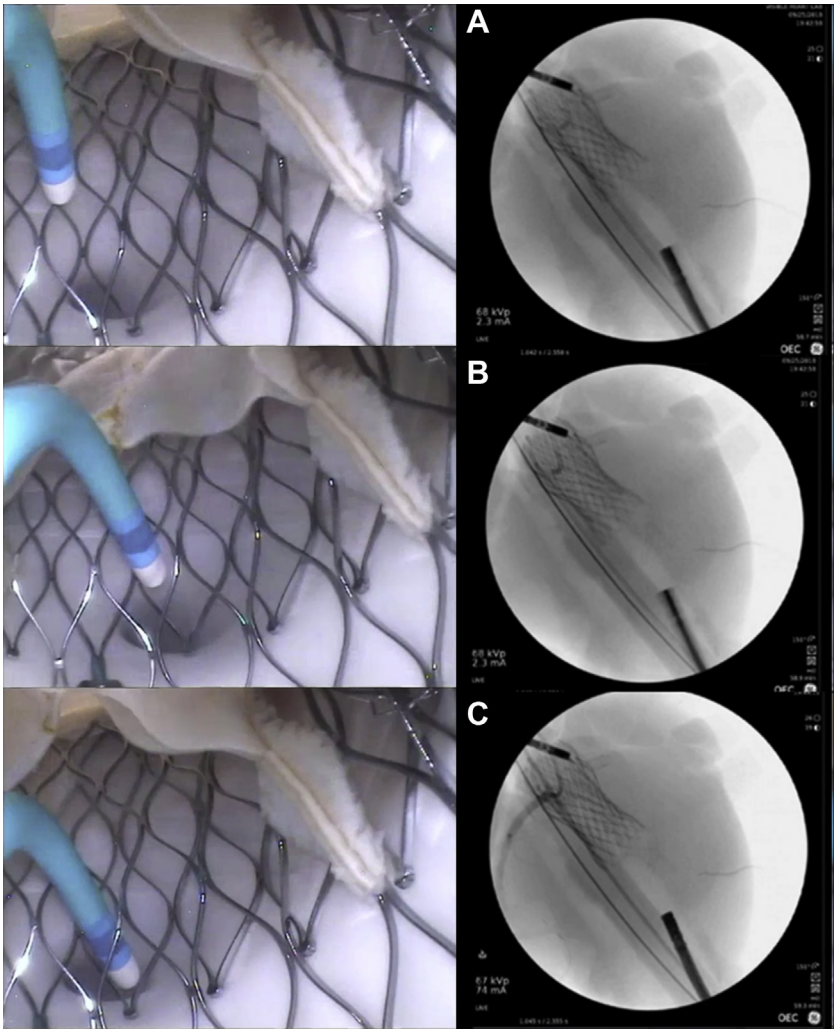

(A) The overlapping TAVR frames resulted in smaller cells jailing the right coronary ostium. **(B, C)** The cells are large enough to allow selective cannulation. TAV = transcatheter aortic valve; other abbreviation as in Figure 1.

JACC: CARDIOVASCULAR INTERVENTIONS VOL. 14, NO. 9, 2021
MAY 10, 2021:e87–91

FIGURE 3 Chimney/Snorkel Technique to Protect the Low-Take-Off Left Main

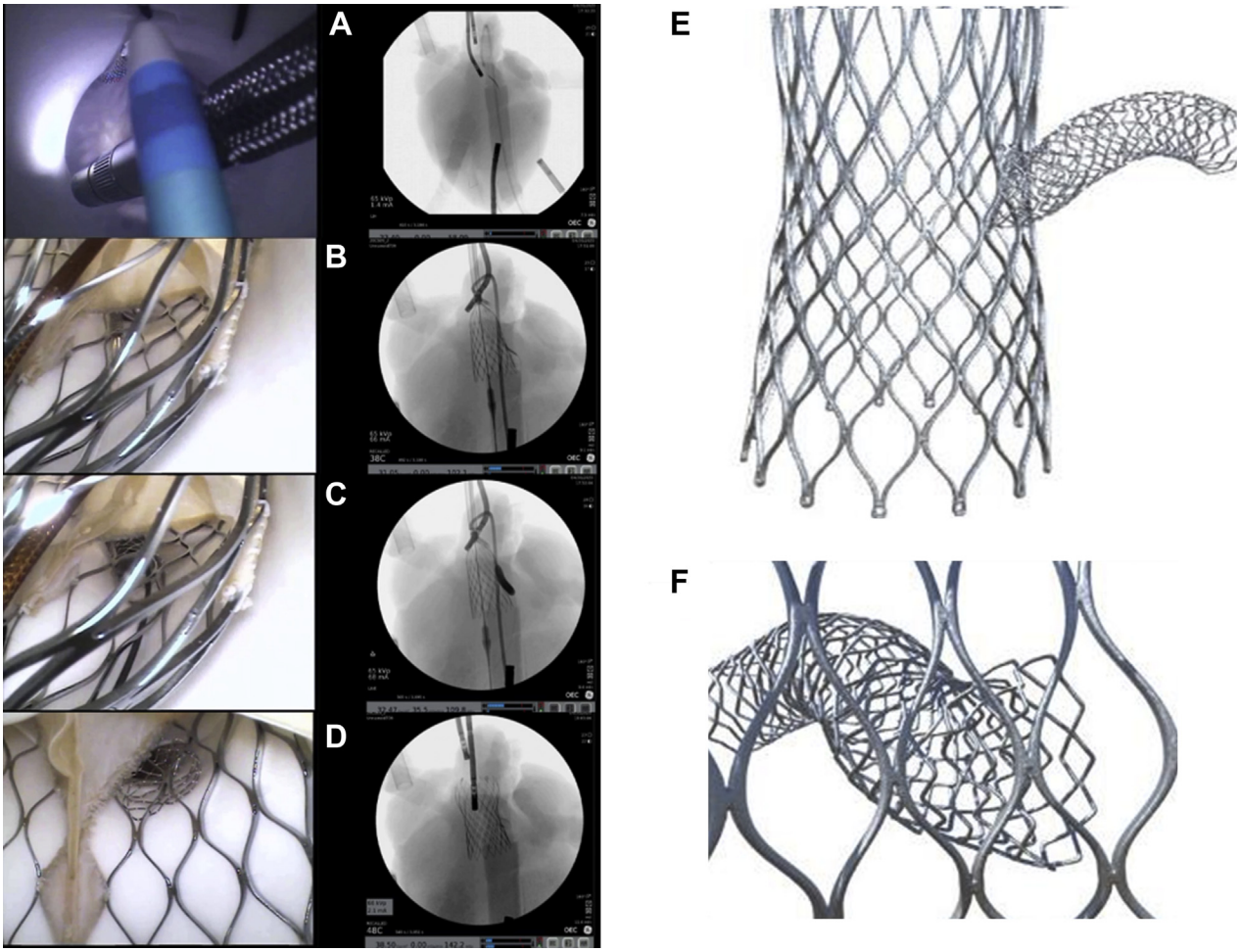

(A) The stent is implanted floating into the aorta immediately before ESEP implantation. **(B, C)** Then guiding catheter is pulled back leaving the guidewire in place. The final configuration achieved is able to maintain coronary patency despite an adverse ESEP commissural posts alignment **(D)** and can be appreciated by micro-CT **(E, F)**. CT = computed tomography; other abbreviation as in Figure 1.

FIGURE 4 Orthotopic-Snorkel-Stent Technique

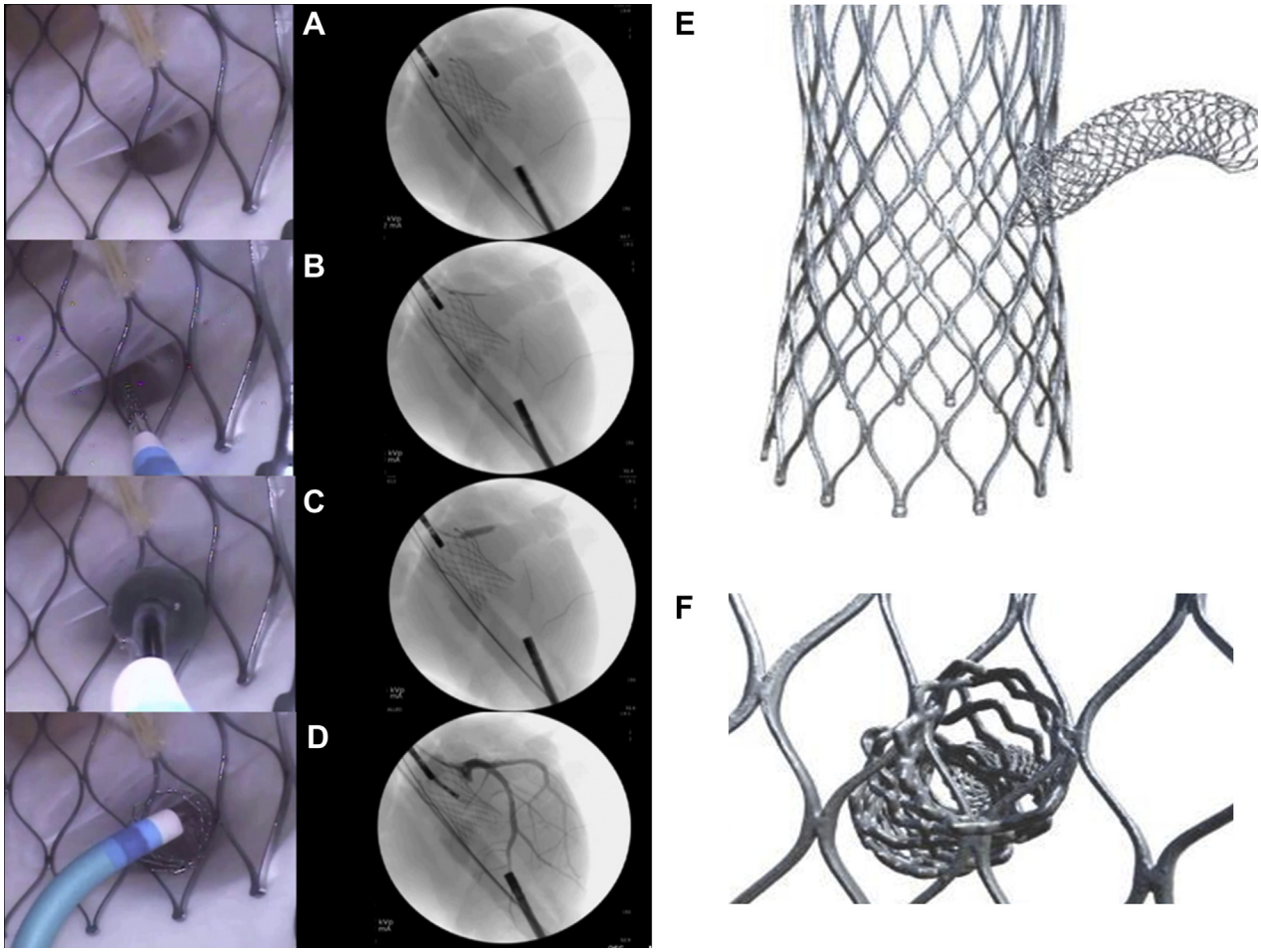

(A) After TAVR, partial left main obstruction is noticed. The coronary artery is wired and a stent (of appropriate length to reach the TAVR frame) is advanced and (after guiding catheter removal) positioned from the coronary artery to the TAVR prosthesis **(B to D)** to achieve an "anatomic" configuration appreciated by micro-CT **(E, F)**. Abbreviations as in Figures 1 and 3.

REFERENCES

1. Zhingre Sanchez JD, Bateman MG, Iaizzo PA. Multimodal imaging of a self-expanding-transcatheter-aortic valve-replacement (TAVR) procedure in a reanimated human heart and post-implant analyses. Int J Cardiovasc Imaging 2019; 35:2135–7.

2. Burzotta F, Kovacevic M, Aurigemma C, et al. An "orthotopic" snorkel-stenting technique to maintain coronary patency during transcatheter aortic valve replacement. Cardiovasc Revasc Med 2020 [E-pub ahead of print].

KEY WORDS coronary artery management, PCI, personalized medicine, TAVR

APPENDIX For supplemental videos, please see the online version of this paper.