JACC: CARDIOVASCULAR INTERVENTIONS
VOL. 15, NO. 23, 2022
© 2022 BY THE AMERICAN COLLEGE OF CARDIOLOGY FOUNDATION
PUBLISHED BY ELSEVIER

Hybrid Approach Using the Cusp-Overlap Technique for Transcatheter Aortic Valve Replacement With a Balloon-Expandable Valve

Mariama Akodad, MD, PhD,[a,b,c] Philipp Blanke, MD,[d] Thomas Nestelberger, MD,[a,b] Abdulmajeed Alosail, MD,[a,b] Andrew G. Chatfield, MB ChB,[a,b] Ming-Yu A. Chuang, MD, MMed,[a,b] Jonathon A. Leipsic, MD,[a,b,c,d] Georgios Tzimas, MD,[d] Youcef Lounes, MD,[e] David Meier, MD,[a,b,c] Janarthanan Sathananthan, MB ChB, MD,[a,b,c] David A. Wood, MD,[a,b,c] John G. Webb, MD[a,b,c]

ABSTRACT

BACKGROUND The cusp-overlap (CO) technique has recently been advocated and is being increasingly adopted for self-expandable transcatheter heart valve (THV) implantation.

OBJECTIVES The aim of this study was to evaluate the feasibility, implantation depth, and outcomes of the CO technique for the balloon-expandable SAPIEN 3 THV.

METHODS The CO technique was used in consecutive patients undergoing balloon-expandable THV implantation at one center between April 2021 and March 2022. Optimal fluoroscopic angles were determined from preprocedural computed tomography and confirmed on predeployment angiography. The THV radiolucent line was positioned 2 to 4 mm below the noncoronary cusp in the CO view, and positioning was confirmed in the 3-cusp view. Postdeployment THV implantation depth was assessed in both views. One-month outcomes were assessed using Valve Academic Research Consortium 3 criteria.

RESULTS Among 137 patients eligible for the CO technique, the CO view was not used because of unfavorable ergonomics in 27 patients (26.5%) and hemodynamic instability in 8 patients (7.8%). Among 102 patients, the mean age was 81.1 ± 6.6 years, the mean Society of Thoracic Surgeons score was 3.3% ± 2.2%, and 64.7% were men. The mean measured THV implantation depth was 3.0 ± 1.4 mm in the CO view and 2.5 ± 1.4 mm in the 3-cusp view. At 1-month follow-up, 1 patient (1.0%) had died, 1 (1.0%) had had a stroke, and 7 (6.8%) had undergone permanent pacemaker implantation.

CONCLUSIONS The CO technique is feasible and safe and may facilitate more accurate balloon-expandable THV positioning, especially when deep implantation needs to be avoided. Further studies are required to explore potential reduction in atrioventricular conduction block, pacemakers, or paravalvular regurgitation.
(J Am Coll Cardiol Intv 2022;15:2387–2395) © 2022 by the American College of Cardiology Foundation.

From the [a]Centres for Heart Valve Innovation and for Cardiovascular Innovation, St. Paul's and Vancouver General Hospitals, Vancouver, British Columbia, Canada; [b]Division of Cardiology, University of British Columbia & St. Paul's Hospital, Vancouver, British Columbia, Canada; [c]Cardiovascular Translational Laboratory, Centre for Heart Lung Innovation, University of British Columbia & St. Paul's Hospital, Vancouver, British Columbia, Canada; [d]Department of Radiology, University of British Columbia, Vancouver, British Columbia, Canada; and the [e]Acute Care Surgery and Trauma, Division of General Surgery, Department of Surgery, University of British Columbia, Vancouver, British Columbia, Canada.
The authors attest they are in compliance with human studies committees and animal welfare regulations of the authors' institutions and Food and Drug Administration guidelines, including patient consent where appropriate. For more information, visit the Author Center.

Manuscript received June 29, 2022; revised manuscript received September 23, 2022, accepted October 21, 2022.

ISSN 1936-8798/$36.00
https://doi.org/10.1016/j.jcin.2022.10.035

JACC: CARDIOVASCULAR INTERVENTIONS VOL. 15, NO. 23, 2022
DECEMBER 12, 2022:2387–2395

ABBREVIATIONS AND ACRONYMS

CO = cusp-overlap

CT = computed tomographic

LAO = left anterior oblique

LCC = left coronary cusp

LM = left main

MSCT = multislice computed tomographic

NCC = noncoronary cusp

RAO = right anterior oblique

RCC = right coronary cusp

TAVR = transcatheter aortic valve replacement

THV = transcatheter heart valve

Identifying a coplanar view of the aortic valve, usually by multislice computed tomographic (MSCT) imaging, is a key component of procedural planning in patients undergoing transcatheter aortic valve replacement (TAVR).[1] Commonly, the 3 aortic cusps are aligned with the right coronary cusp (RCC) centered between the noncoronary cusp (NCC) and the left coronary cusp (LCC), referred to as the 3-cusp view.[1-3] However, recently the cusp-overlap (CO) view, defined as a coplanar projection overlapping the RCC and the LCC, has been advocated for the deployment of self-expandable transcatheter heart valves (THVs).[4-7] This CO view may provide advantages for the implantation of self-expandable platforms by minimizing catheter parallax and reducing the distance between the NCC and LCC, ultimately leading to a better appreciation of the membranous septum and facilitating more accurate positioning and depth of implantation. As conduction disorders are determined largely by the depth of implantation, with potential for impacting the left bundle branch beneath the NCC and RCC, higher implantation appears to reduce the incidence of conduction injury and the need for a permanent pacemaker.[8-11] Furthermore, accurate positioning of the THV and a better appreciation of the true implantation depth may be useful in patients in whom future coronary access may be challenging because of low coronary height. However, the CO technique with its typically right anterior oblique (RAO) caudal orientation can be challenging to achieve in terms of ergonomics in some patients, potentially limiting the application of this technique.[2]

SEE PAGE 2396

To date, use of the CO view for performing TAVR with the balloon-expandable SAPIEN 3 or SAPIEN 3 Ultra (Edwards Lifesciences) THV has not been formally studied.

We therefore aimed to evaluate the feasibility, effective implantation depth, and clinical outcomes using a hybrid approach combining both 3-cusp and CO views with the balloon-expandable THV.

METHODS

STUDY POPULATION. We changed our practice for balloon-expandable THV implantation using the CO technique considering recent data suggesting a better appreciation of THV implantation depth using the CO technique with self-expandable THVs.[4-7] We used a hybrid approach combining both the standard 3-cusp and the CO views in patients undergoing transfemoral TAVR for native aortic stenosis with a balloon-expandable THV between April 2021 and March 2022 at our institution. Patients undergoing valve-in-valve or redo TAVR procedures or TAVR with self-expandable THVs, as well as patients with bicuspid native aortic valves or glomerular filtration rates <35 mL/min/m^2, were excluded from this analysis (**Figure 1**). Data were collected as part of a TAVR registry approved by our institutional ethics committee.

PREPROCEDURAL MSCT IMAGING. Patients underwent routine preprocedural MSCT imaging with computed tomographic (CT) data acquisition and reconstruction in accordance with current expert consensus.[1] In brief, contrast-enhanced cardiac CT data were acquired using a volume CT scanner (GE Revolution or GE CardioGraphe, GE Medical Systems) with prospective electrocardiographic gating and full cardiac cycle acquisition. Thin-sliced 0.625-mm axial image data were reconstructed in 10% intervals throughout the cardiac cycle and transferred to a dedicated postprocessing workstation (Aquarius iNtuition, TeraRecon).

After reconstruction and identification of the annular plane by orienting the multiplanar reconstruction lines at the nadir of each cusp,[1] both 3-cusp and CO coplanar views were systematically determined by aligning the CT crosshairs to either center the RCC between the NCC and LCC or to overlap the RCC and LCC, isolating the NCC, respectively, as illustrated in **Central illustration A**. Required left anterior oblique (LAO)/RAO and cranial/caudal angulations were recorded.

TAVR PROCEDURE PROTOCOL. At the beginning of the TAVR procedure, 2 aortograms in 3-cusp view and CO view orientation were obtained to assess the ergonomic feasibility of the CO angle and the aortographic quality (**Central Illustration B**). Adjustment of the fluoroscopic view was allowed only in case of unsatisfactory cusps alignment in the CO view (unsatisfactory overlap of the RCC and LCC) and/or in the 3-cusp view (unsatisfactory alignment of the 3 cusps). The adjustment was then performed within a 10° range (−5° to +5°), moving along the S-curve, in the LAO/cranial direction for the 3-cusp view (less cranial was compensated by less LAO) and the RAO/caudal direction for the CO view (less caudal was compensated by less RAO). Repeat aortography was then performed to confirm the improvement of the view(s), and the exact same view(s) were used for deployment.

If the CO view was not achievable or convenient for the operators because of patient or equipment

FIGURE 1 Study Flowchart

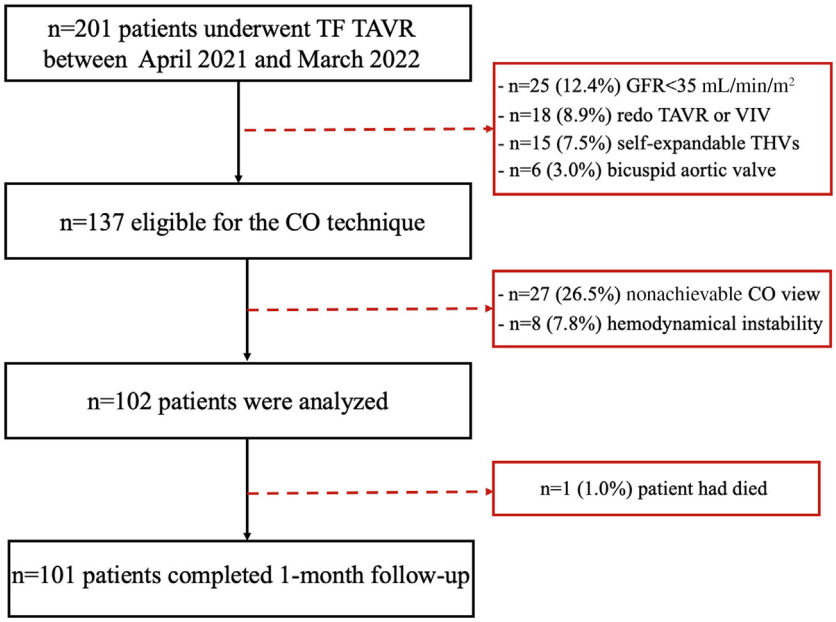

CO = cusp-overlap; GFR = glomerular filtration rate; TAVR = transcatheter aortic valve replacement; TF = transfemoral; THV = transcatheter heart valve; VIV = valve-in-valve.

interference (ergonomics issues), in lieu of determining a cutoff angle above which the CO view would be challenging to achieve in terms of ergonomics, no adjustment was allowed, and the CO view was considered "nonachievable." In this situation, only the standard 3-cusp view was used.

The native aortic valve was then crossed in either the CO or 3-cusp view. The THV was positioned in the CO view. An aortogram was obtained in the CO view to confirm satisfactory THV positioning on the basis of the balloon central marker and the THV radiolucent line, aimed to be positioned routinely 2 to 4 mm below the aortic annulus (**Central Illustration C**). Positioning was left to the operator's discretion regarding patient anatomy and clinical features, including the risk for conduction disorder where high implantation was targeted and the risk for impaired coronary access where the THV positioning might be intentionally lower. To allow a better appreciation of the relation between the left main (LM) and the THV frame and to allow comparison of the positioning between the 2 views, a second aortogram was obtained in the 3-cusp view, and the THV was deployed under rapid pacing (160-180 beats/min). After THV deployment, a final angiogram was obtained in both the 3-cusp and CO views after correction of the THV parallax toward the LAO plane for the 3-cusp view and toward the RAO plane for the CO view if achievable, to allow comparison of the measured implantation depth between the 2 views.

PARALLAX AND IMPLANTATION DEPTH. THV parallax was assessed (as present or absent) before THV deployment in both the 3-cusp and CO views (**Central Illustration C**). The radiolucent line depth according to the aortic annular plane was assessed in both the 3-cusp and CO views prior THV deployment.

As previously described, the postdeployment implantation depth was measured on fluoroscopy from the THV inflow frame to the aortic annulus at the LCC and NCC in the 3-cusp view and from the THV inflow frame to the aortic annulus at the NCC and overlapping cusps in the CO view using syngo Dynamics software (Siemens Healthineers)[12] (**Central Illustration D**).

NCC implantation depth, LCC implantation depth, and mean implantation depth ([NCC implantation depth + LCC implantation depth]/2 for the 3-cusp view and [NCC implantation depth + overlapping LCC/RCC implantation depth]/2 for the CO view) were

JACC: CARDIOVASCULAR INTERVENTIONS VOL. 15, NO. 23, 2022
DECEMBER 12, 2022:2387–2395

CENTRAL ILLUSTRATION Hybrid Approach Using the Cusp-Overlap Technique for Balloon-Expandable THV Implantation: Procedural Planning, THV Positioning, Implantation Depth, and Outcomes (N = 102)

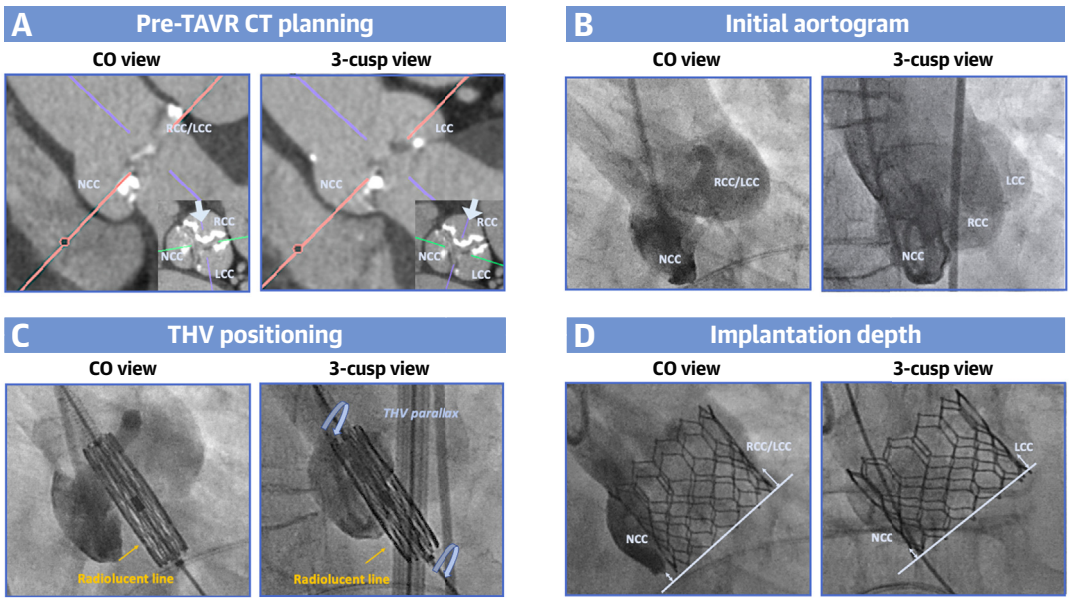

Mean THV implantation depth: 3.0 ± 1.4mm (CO view) and 2.5 ± 1.4mm (3-cusp view)
1-month permanent pacemaker implantation: n = 7 (6.8%)

Akodad M, et al. J Am Coll Cardiol Intv. 2022;15(23):2387–2395.

(A) Pre-transcatheter aortic valve replacement (TAVR) evaluation of the cusp-overlap (CO) view and the 3-cusp view; **blue arrow** represents x-ray direction. In the CO view, the interventricular septum appears with less foreshortening. **(B)** Initial aortogram during the TAVR procedure showing typical aspects in both the CO and 3-cusp views. **(C)** Initial transcatheter heart valve (THV) positioning using the radiolucent line in the CO view, with optimal THV alignment without THV parallax. THV in the 3-cusp view showing THV parallax. **(D)** Measurement of THV implantation depth at the noncoronary cusp (NCC) and at the overlapping right coronary cusp (RCC) and left coronary cusp (LCC) in the CO view and at the NCC and at the LCC in the 3-cusp view. CT = computed tomographic.

assessed for all patients and compared between both views. Measurements were performed independently by 2 different experienced operators. Position of the THV outflow frame relative to the LM ostium and the sinotubular junction at the level of the LM was assessed visually.

CLINICAL OUTCOMES. Procedural complications and outcomes were defined according to the Valve Academic Research Consortium 3 criteria classification.[13] Outcomes assessed included all-cause mortality, cardiovascular death, stroke, myocardial infarction, new pacemaker implantation, and heart failure at 1-month follow-up.

STATISTICAL ANALYSIS. Patients' characteristics are presented with proportions for categorical variables and as mean ± SD or median (IQR) for quantitative variables. Normality of data distribution was assessed graphically and using the Shapiro-Wilk test. Comparisons between the CO and 3-cusp views regarding THV parallax were performed using the chi-square test for categorical variables. Pearson analysis was performed to assess interobserver variability for implantation depth measurement on fluoroscopy. Statistical significance was set at $P < 0.05$. Statistical analyses were performed using SAS version 9.1 (SAS Institute), and the statistical significance threshold was set at 5%.

RESULTS

STUDY POPULATION AND BASELINE CHARACTERISTICS. Of 201 consecutive patients who underwent TAVR within the study period, 137 were eligible for the CO

TABLE 1 Baseline Characteristics (N = 102)

Age, y	81.1 ± 6.6
Male	66 (64.7)
Body mass index >25 kg/m^2	64 (62.7)
STS score, %	3.3 ± 2.2
EuroSCORE II, %	3.3 ± 2.7
Dyslipidemia	53 (52.0)
Hypertension	68 (66.7)
Diabetes	21 (20.6)
Coronary artery disease	40 (39.2)
Previous CABG	11 (10.8)
COPD	14 (13.7)
Chronic kidney disease	27 (26.5)
Previous stroke	11 (10.8)
Peripheral artery disease	4 (3.9)
Permanent pacemaker	12 (11.8)
Previous right bundle branch block	10 (9.8)
Atrial fibrillation	37 (36.3)
eGFR, mL/min/m^2	66.5 ± 17.1
Hemoglobin, g/dL	12.6 ± 18.2
LVEF, %	55.4 ± 12.3
Mean aortic gradient, mm Hg	41.8 ± 11.9
Aortic valve area, cm^2	0.8 ± 0.2

Values are mean ± SD or n (%).

CABG = coronary artery bypass grafting; COPD = chronic obstructive pulmonary disease; eGFR = estimated glomerular filtration rate; EuroSCORE = European System for Cardiac Operative Risk Evaluation; LVEF = left ventricular ejection fraction; STS = Society of Thoracic Surgeons.

TABLE 2 Pretranscatheter Aortic Valve Replacement Multislice Computed Tomographic Characteristics (N = 102)

Aortic valve annulus	
Perimeter, mm	79.5 ± 10.8
Area, mm^2	488.1 ± 90.9
Mean diameter (area derived), mm	24.9 ± 2.3
Maximum diameter (area derived), mm	27.8 ± 2.7
Minimum diameter (area derived), mm	22.7 ± 2.4
Sinus of Valsalva mean diameter, mm	32.9 ± 4.0
Sinotubular junction	
Height, mm	20.3 ± 3.3
Mean diameter, mm	29.9 ± 3.9
LM height, mm	15.3 ± 2.9
RCA height, mm	17.3 ± 3.7
3-cusp view	
LAO, °	7.7 ± 7.8
Caudal, °	4.7 ± 10.3
CO view	
RAO, °	15.3 ± 10.2
Caudal, °	25.6 ± 11.5

Values are mean ± SD.

CO = cusp-overlap; LAO = left anterior oblique; LM = left main; RAO = right anterior oblique; RCA = right coronary artery.

technique. Among them, the CO view was ultimately not used because of unfavorable ergonomics in 27 patients (26.5%). In these patients, the mean view was RAO 18.4° ± 13.2°, caudal 38.9° ± 8.2°. The CO technique was abandoned during the procedure in 8 patients (7.8%) because of hemodynamic instability before or during THV positioning. The CO technique was therefore used in 102 patients, included in the analysis, with a mean age of 81.1 ± 6.6 years and a mean Society of Thoracic Surgeons score of 3.3% ± 2.2%; 64.7% were men (Figure 1). Baseline and pre-TAVR MSCT characteristics are summarized in Tables 1 and 2.

PROCEDURAL CHARACTERISTICS AND THV IMPLANTATION DEPTH. Procedural success was achieved in 102 patients (100.0%). Procedural characteristics are presented in Table 3. The mean total amount of contrast was 97.6 ± 44.5 mL. Prior to THV deployment, THV parallax was noted in 46 patients (45.1%) in the CO view and 74 patients (72.5%) in the 3-cusp view ($P < 0.01$). On the basis of the analysis of the 3-cusp view, valve position was adjusted in the CO view in 6 patients (5.8%), and aortography was repeated. Prior to THV deployment, the mean radiolucent line depth was 3.1 ± 1.7 and 2.9 ± 1.6 mm in the CO and 3-cusp views, respectively. We assessed interobserver variability in a random sample of 20 patients for implantation depth measurement on fluoroscopy, with excellent correlation ($\rho = 0.94$ for the 3-cusp implantation depth measurement and $\rho = 0.96$ for the CO implantation depth measurement) (Figures 2A and 2B). Following THV deployment, the mean THV implantation depth was 3.0 ± 1.4 and 2.5 ± 1.4 mm in the CO and 3-cusp views, respectively (Central Illustration D). After THV deployment, THV parallax needed to be corrected in 36 patients (35.3%) in the CO view and in 63 patients (61.8%) in the 3-cusp view ($P < 0.01$).

RELATION BETWEEN THV OUTFLOW, LM, AND SINOTUBULAR JUNCTION. After THV deployment, the THV outflow frame was above the LM ostium in 61 patients (59.8%), at the level of the LM ostium in 21 patients (20.6%), and below the LM ostium in 20 patients (19.6%) (Figure 3). The THV outflow frame was below the sinotubular junction in 41 patients (40.2%), at the level of the sinotubular junction in 48 patients (47.1%), and above the sinotubular

JACC: CARDIOVASCULAR INTERVENTIONS VOL. 15, NO. 23, 2022
DECEMBER 12, 2022:2387–2395

TABLE 3 Procedural Characteristics (N = 102)

THV type	
SAPIEN 3	43 (42.2)
SAPIEN 3 Ultra	59 (57.8)
THV size	
20 mm	6 (5.9)
23 mm	22 (21.6)
26 mm	50 (49.0)
29 mm	24 (23.5)
Overfilling	18 (17.6)
Underfilling	23 (22.5)
Predilatation	6 (5.9)
Postdilatation	12 (11.8)
3-cusp view	
LAO, °	5.9 ± 8.9
Caudal, °	3.9 ± 10.4
CO view	
RAO, °	15.2 ± 10.1
Caudal, °	25.2 ± 9.6
Radiolucent line depth, mm	
3-cusp view	
NCC	2.2 ± 1.5
LCC	3.5 ± 2.0
Mean	2.9 ± 1.6
CO view	
NCC	2.3 ± 1.7
LCC/RCC	3.8 ± 2.0
Mean	3.1 ± 1.7
THV implantation depth, mm	
3-cusp view	
NCC	2.8 ± 1.5
LCC	2.2 ± 1.6
Mean	2.5 ± 1.4
CO view	
NCC	2.9 ± 1.6
LCC-RCC overlapping	3.1 ± 1.6
Mean	3.0 ± 1.4
THV implantation depth, %	
3-cusp view	
NCC	13.5 ± 7.2
LCC	11.0 ± 8.3
Mean	12.3 ± 6.8
CO view	
NCC	14.1 ± 7.6
LCC-RCC overlapping	15.7 ± 7.9
Mean	14.9 ± 7.0
Parallax correction, angle difference, °	
3-cusp view	
LAO	5.6 ± 8.2
Cranial	0.4 ± 5.1
CO view	
RAO	−2.2 ± 6.1
Caudal	1.0 ± 4.9
Amount of contrast, mL	97.6 ± 44.5

Values are n (%) or mean ± SD.

LCC = left coronary cusp; NCC = noncoronary cusp; RCC = right coronary cusp; THV = transcatheter heart valve; other abbreviations as in Table 2.

junction in 13 patients (12.7%). The relation between THV outflow and right coronary artery ostium was not reliably assessable.

1-MONTH OUTCOMES. The median length of hospital stay was 1 day (IQR: 1-1 days).

None of the patients had unknown clinical status at 1-month follow-up. At 1-month follow-up, 1 patient (1.0%) had died, 1 patient (1.0%) had had a stroke, and no patients had been hospitalized for heart failure. New pacemaker implantation was necessary in 7 patients (6.8% of the total population and 7.7% of the population at risk excluding 12 patients with previous permanent pacemakers), and 14 patients (13.7%) developed new left bundle branch block (Table 4). At 1-month follow-up, the mean aortic valve gradient was 12.2 ± 5.3 mm Hg, and 2 patients (1.9%) had moderate paravalvular leaks.

DISCUSSION

We aimed to assess the routine feasibility of the CO technique in patients undergoing TAVR using balloon-expandable THVs. The CO technique has been shown to be reliable and reproducible with self-expandable THVs,[3-7] facilitating a better appreciation of the true implantation depth below the NCC.

CO VIEW FEASIBILITY. In our study, the CO view was determined by MSCT analysis, allowing better procedural planning. About one-quarter of patients were not eligible for the CO technique because of ergonomics, mainly because of an inconvenient C-arm caudal (>35°) angulation. However, the RAO caudal angle may be adjusted using the coplanar S-curve to be approximated in practice, as previously shown with self-expandable THVs.[2,3] Although the NCC would still be isolated using this adjusted view, the LCC and RCC would not be perfectly overlapping. In a recent study, the investigators showed high implantation depth with the balloon-expandable THV using the RAO caudal view, defined during the TAVR index procedure as a view eliminating THV parallax.[14] This approach could provide the advantages of the CO view with regard to THV parallax elimination; however, the native aortic valve may not be coplanar, as the RAO view used was not determined by pre-TAVR CT imaging. Therefore, predicting the feasibility of the CO technique on the basis of the angles obtained on pre-TAVR CT imaging may make it possible to

FIGURE 2 Interobserver Variability for Implantation Depth Measurement on Fluoroscopy

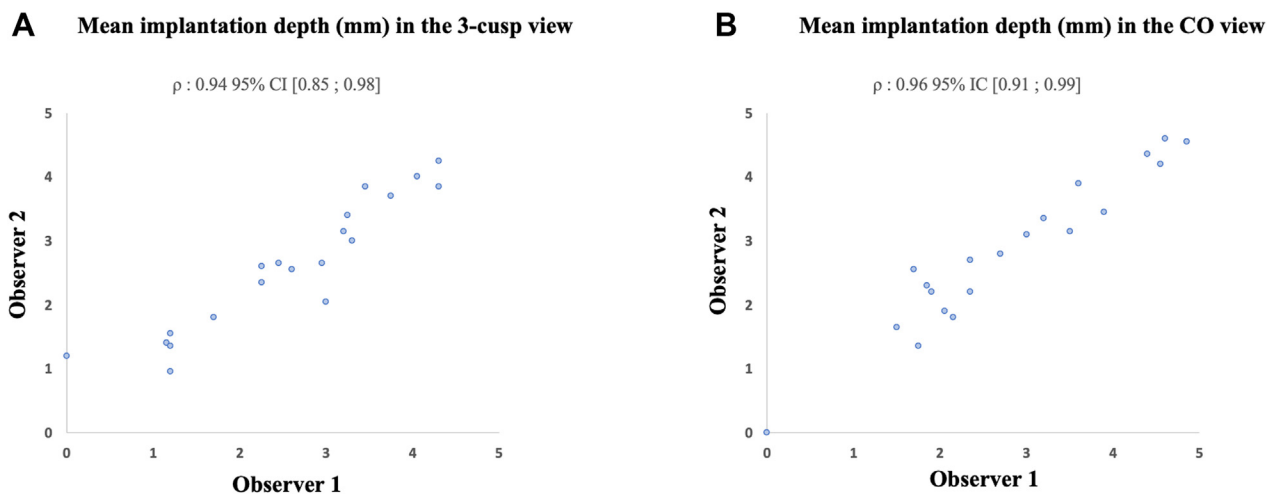

Interobserver variability for mean implantation depth measurement in the 3-cusp view **(A)** and the cusp-overlap (CO) view **(B)**.

determine an "adjusted" CO coplanar view offering a compromise between the CO view and ergonomic issue (patient or equipment interference).

CO VIEW ADVANTAGES. The CO view, provided by pre-TAVR MSCT analysis, is usually an RAO caudal view, providing several advantages. First, isolation of the NCC provides a maximum elongation of the left ventricle outflow tract, allowing better assessment of the true implantation depth and better appreciation of the relation between the conduction pathways and the THV.[2-5] Second, the delivery catheter and the THV appeared more coaxial, with substantially less parallax in the CO view compared with the 3-cusp view, allowing more accurate THV positioning. Altogether, limiting left ventricular outflow tract and delivery catheter foreshortening allows a better appreciation of the true implantation depth.[2-5] This

FIGURE 3 Position of the THV Outflow Frame Relative to the LM

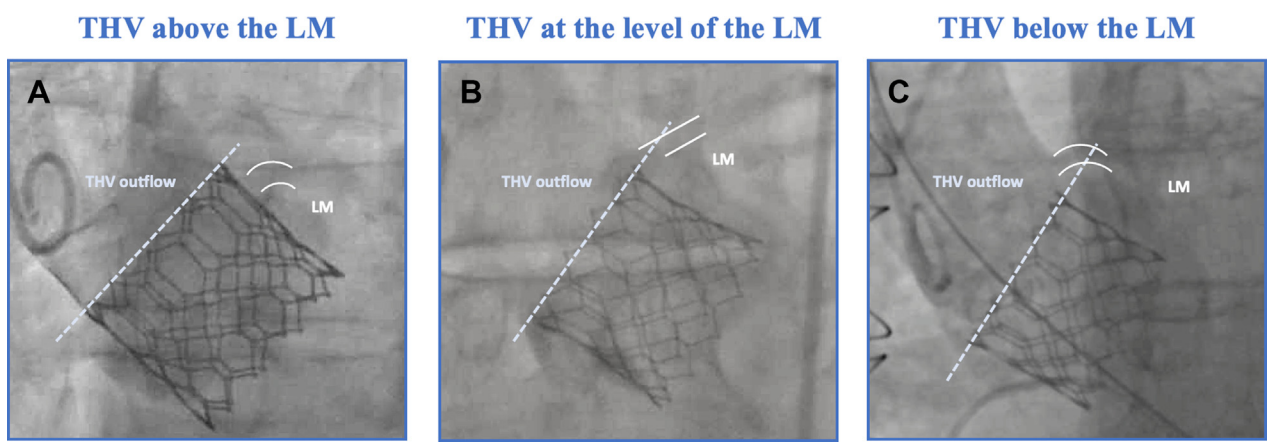

Transcatheter heart valve (THV) outflow frame **(A)** above, **(B)** at the level of, and **(C)** below the left main (LM) ostium.

TABLE 4 1-Month Outcomes (N = 102)

Death	1 (1.0)
Stroke	1 (1.0)
Major vascular complication	0 (0.0)
Major bleeding	0 (0.0)
Myocardial infarction	0 (0.0)
Acute kidney injury	0 (0.0)
New pacemaker implantation	7 (6.8)
New pacemaker implantation[a]	7 (7.7)
Rehospitalization for heart failure	0 (0.0)

Values are n (%). [a]Patients at risk excluding patients with previous permanent pacemakers (7 of 90).

better appreciation may allow higher THV positioning or, when required by a low coronary height, relatively deeper implantation depth. In our study, THV positioning was adapted to each case scenario, aiming for reasonably high implantation to decrease the risk for conduction disorder but also slightly deeper implantation in patients in whom durability and THV implantation repeatability might be concerns. Finally, the CO view, reflecting the short axis of the aortic valve, may allow a better appreciation of THV expansion than the 3-cusp view.[2]

THV IMPLANTATION DEPTH. In our study, the implantation depth was relatively high and consistent between both views, although the mean implantation depth appeared shallower in the 3-cusp view, mainly because of the greater parallax between the native annulus and the THV. Thus, the 3-cusp view may lead to deeper implantation than expected. Indeed, implantation depth might be better assessed showing sufficient implantation depth in the CO view by reducing parallax. Additionally, using the radiolucent line as a complementary marker for THV positioning may be of interest to allow high THV implantation depth, as recently demonstrated.[15] In contrast, classical markers for THV positioning, including the balloon central marker, can be influenced by balloon alignment, which may not always be central. The radiolucent line, visible on the THV itself, is a reliable marker and may be used for THV positioning but may be difficult to assess in the presence of THV parallax. Although the CO view may allow less THV parallax and thus a better appreciation of the radiolucent line, the CO view may be used in association with classical markers for THV positioning. Using both views for THV positioning may allow a more accurate assessment of the implantation depth at the level of the NCC with the CO view and a better appreciation of the relationship between the THV and the LM using the 3-cusp view. However, if achievable, the CO view might be sufficient by itself, especially if high implantation is desirable with no concerns regarding coronary height. In contrast, the 3-cusp view might not be optimal to assess the relationship between the THV and the LM, and a dedicated view isolating the LM along the S-curve (overlapping of the RCC and the NCC) may be of interest in selected patients.

CLINICAL OUTCOMES. Using both the CO and the 3-cusp views may be associated with an increase in contrast use. However, none of the patients developed acute kidney injury or increases in creatinine level up to 1-month follow-up. We excluded patients with predicted estimated glomerular filtration rates <35 mL/min/m^2, as these patients may not be suitable for this approach because of the increased amount of contrast with this technique. Moreover, the rate of pacemaker placement was relatively low in our study (<10%), which may be related to more accurate THV positioning resulting in higher implantation depth when this was required. Our findings are consistent with those of Sammour et al,[14] demonstrating that high implantation (1.5-mm implantation depth) of a balloon-expandable THV using an RAO view was associated with a low rate of pacemaker implantation (5.5%).

STUDY LIMITATIONS. First, the single-center and nonrandomized study design and the relatively small sample size with a small number of events may not allow a full appreciation of the impact of the CO technique on outcomes, including pacemaker implantation. Second, the rate of nonachievable CO view angles might have been overestimated because of the learning curve within the first months of our experience and as no adjustment of the CO view angles was allowed in case of nonachievable angle in our protocol.

Finally, implantation depth was assessed primarily on angiography and might not have been optimal in cases of parallax removal. However, angle correction after parallax removal was minimal (between 0.5° and 5°), which appears acceptable. Moreover, CT implantation depth could not be determined, as postimplantation MSCT imaging is not routinely performed in our practice.

CONCLUSIONS

The CO technique is reliable and may facilitate more accurate THV positioning with balloon-expandable THVs, especially when deep implantation needs to be avoided. Further studies are required to explore potential reduction in atrioventricular conduction block, pacemakers, or paravalvular regurgitation.

FUNDING SUPPORT AND AUTHOR DISCLOSURES

Dr Akodad has received research funding from Medtronic, Biotronik, Villa M, and Federation Française de Cardiologie. Dr Blanke is a consultant to Edwards Lifesciences; and provides computed tomography core laboratory services for Edwards Lifesciences, Medtronic, Neovasc, Boston Scientific, and Abbott, for which no direct compensation is received. Dr Nestelberger has received research support from the Swiss National Science Foundation (grant P400PM_191037/1), the Swiss Heart Foundation (grant FF20079), the Prof Dr Max Cloëtta Foundation, Margarete und Walter Lichtenstein-Stiftung (grant 3MS1038), University Basel, and University Hospital Basel; and has received speaker honoraria and consulting honoraria from Siemens, Beckman Coulter, Bayer, Ortho Clinical Diagnostics and Orion Pharma, all outside the submitted work. Dr Chatfield is funded by the New Zealand Heart Foundation and John Ormiston Scholarship. Dr Chuang is funded by the Royal Australian College of Physicians Vincent Fairfax Research Entry Scholarship. Dr Leipsic holds institutional research core laboratory agreements with Medtronic, Edwards Lifesciences, Abbott, Boston Scientific, and Pi CARDIA. Dr Meier is supported by the Swiss National Science Foundation (grant P2LAP3_199561). Dr Tzimas is supported by Fondation Vaudoise de Cardiologie and the SICPA Foundation. Dr Sathananthan has received speaker fees from Edwards Lifesciences and NVT Medical; and is a consultant for Edwards Lifesciences, Boston Scientific, and Medtronic. Dr Wood is a consultant for and receives unrestricted grant support from Medtronic, Edwards Lifesciences, and Abbott Vascular. Dr Webb is a consultant for Edwards Lifesciences. All other authors have reported that they have no relationships relevant to the contents of this paper to disclose.

ADDRESS FOR CORRESPONDENCE: Dr John Graydon Webb, St. Paul's Hospital, 614-1033 Davie Street, Vancouver, British Columbia V6E 1M7, Canada. E-mail: johngraydonwebb@gmail.com.

PERSPECTIVES

WHAT IS KNOWN? The CO positioning technique is widely used to facilitate optimal implantation depth in the setting of implantation of self-expandable transcatheter aortic valves. Experience suggests a reduction in depth of implantation and the need for new pacemakers.

WHAT IS NEW? The CO view may also facilitate optimal implantation depth in the setting of implantation of balloon-expandable transcatheter aortic valves.

WHAT IS NEXT? Future studies are needed to assess the impact of the CO technique on the accuracy and depth implantation, paravalvular regurgitation, new conduction disorders, and the need for new pacemakers.

REFERENCES

1. Blanke P, Weir-McCall JR, Achenbach S, et al. Computed tomography imaging in the context of transcatheter aortic valve implantation (TAVI) / transcatheter aortic valve replacement (TAVR): an expert consensus document of the Society of Cardiovascular Computed Tomography. *J Cardiovasc Comput Tomogr*. 2019;13:1–20.

2. Ben-Shoshan J, Alosaimi H, Lauzier PT, et al. Double S-curve versus cusp-overlap technique: defining the optimal fluoroscopic projection for TAVR with a self-expanding device. *J Am Coll Cardiol Intv*. 2021;14(2):185–194.

3. Tchétché D, Siddiqui S. Optimizing fluoroscopic projections for TAVR: any difference between the double S-curve and the cusp-overlap technique? *J Am Coll Cardiol Intv*. 2021;14(2):195–197.

4. Tang GHL, Zaid S, Michev I, et al. Cusp-overlap" view simplifies fluoroscopy-guided implantation of self-expanding valve in transcatheter aortic valve replacement. *J Am Coll Cardiol Intv*. 2018;11(16):1663–1665.

5. Sacha J, Krawczyk K, Gwóźdź W, Bugajski J, Darmetko M, Gierlotka M. Cusp overlap technique for transcatheter self-expanding aortic valve implantation. *Postepy Kardiol Interwencyjnej*. 2021;17(2):230–231.

6. Pascual I, Almendárez M, Avanzas P, et al. Cusp-overlapping TAVI technique with a self-expanding device optimizes implantation depth and reduces permanent pacemaker requirement. *Rev Esp Cardiol (Engl Ed)*. 2022;75(5):412–420.

7. Wong I, Bieliauskas G, De Backer O, Søndergaard L. Technical considerations for transcatheter aortic valve replacement with ACURATE neo2. *J Am Coll Cardiol Intv*. 2021;14(2):224–226.

8. Kim W-K, Möllmann H, Walther T, Hamm CW. Predictors of permanent pacemaker implantation after ACURATE neo transcatheter heart valve implantation. *Pacing Clin Electrophysiol*. 2021;44(2):410–415.

9. Rodés-Cabau J. Optimizing valve implantation depth to win the battle against conduction disturbances post-TAVR. *J Am Coll Cardiol Intv*. 2019;12(18):1808–1810.

10. Wang T, Ou A, Xia P, Tian J, Wang H, Cheng Z. Predictors for the risk of permanent pacemaker implantation after transcatheter aortic valve replacement: a systematic review and meta-analysis. *J Card Surg*. 2022;37(2):377–405.

11. Jilaihawi H, Zhao Z, Du R, et al. Minimizing permanent pacemaker following repositionable self-expanding transcatheter aortic valve replacement. *J Am Coll Cardiol Intv*. 2019;12(18):1796–1807.

12. Nijhoff F, Agostoni P, Samim M, et al. Optimisation of transcatheter aortic balloon-expandable valve deployment: the two-step inflation technique. *EuroIntervention*. 2013;9(5):555–563.

13. VARC-3 Writing Committee, Généreux P, Piazza N, et al. Valve Academic Research Consortium 3: updated endpoint definitions for aortic valve clinical research. *J Am Coll Cardiol*. 2021;77(21):2717–2746.

14. Sammour Y, Banerjee K, Kumar A, et al. Systematic approach to high implantation of SAPIEN-3 valve achieves a lower rate of conduction abnormalities including pacemaker implantation. *Circ Cardiovasc Interv*. 2021;14(1):e009407.

15. Ishizu K, Shirai S, Kawaguchi T, et al. Effect of radiolucent line-guided balloon-expandable transcatheter aortic valve implantation on subsequent pacemaker rate. *Am J Cardiol*. 2022;165:72–80.

KEY WORDS balloon-expandable THV, cusp overlap, implantation depth, transcatheter aortic valve replacement