Check for updates

Original research article

JVA The Journal of Vascular Access

The Journal of Vascular Access
2025, Vol. 26(5) 1476–1481
© The Author(s) 2024
Article reuse guidelines:
sagepub.com/journals-permissions
DOI: 10.1177/11297298241282369
journals.sagepub.com/home/jva
Sage

Comparison of peripheral cannula outcomes, ultrasound-guided placement of deep veins versus blind insertion of superficial veins in children aged 0–18 years: A retrospective study

Michela Refosco[1], Alessandro Mazza[1], Antuan Divisic[2], Diana Binotto[1], Sara Zamberlan[1], Barbara Schiavon[2] and Beatrice Prodomini[1]

Abstract

Background: The clinical use of ultrasound has increased the chances of successful insertion of all venous access devices, including short peripheral cannulas (SPC) and long peripheral catheters (LPC). The aim of the study was to compare the clinical performance of peripheral cannulas inserted using the traditional "blind" technique versus those inserted with ultrasound guidance (US).

Methods: In this retrospective study we compared 135 peripheral intravenous cannulations (PIVCs) with ultrasound guidance and 135 PIVCs with blind technique, inserted in children (0–18 years) in the emergency department. All devices were inserted using the catheter-over-needle technique. With the blind technique, superficial arm veins were cannulated using SPCs (1.9 cm, 24G; 2.5 cm, 22G; 3.2 cm, 20G), while with US, deeper non-palpable veins were accessed using SPCs of 3.2 cm, 24G; and LPCs of 6.4 cm, 22G; 6.4 cm, 20G.

Results: The accesses were removed electively in 66% of US-PIVCs, with an average duration of the device of 5.3 ± 4.0 days, but only in 30% of Blind-PIVCs, which presented an average duration of 2.5 ± 1.8 days. The longest dwelling time (8.7 ± 5.1 days) was observed in 20G LPCs inserted with US into the basilic vein of the arm; among Blind-PIVCs, the longest duration (3.0 ± 2.1 days) was observed in 22G SPCs inserted into the cephalic vein at the forearm. The most commonly encountered complication in both groups was accidental dislodgment.

Conclusions: PIVCs with ultrasound guidance were apparently more effective than the blind ones, reducing the number of successive cannulations. Additionally, LPCs, with their greater length compared to SPCs, have proven to be more durable and may be recommended as emergency venous access in children requiring peripheral access for 4–15 days. Dislodgement should be reduced by improving the securement of the device.

Keywords

Ultrasound-guided, blind insertion, ultrasound, short peripheral cannulas, long peripheral catheters, SPC, LPC, pediatric emergencies, over-needle technique, over needle

Date received: 21 March 2024; accepted: 26 August 2024

Introduction

In the pediatric population, venous access devices (VADs) are of paramount importance for intravenous delivery of infusions and drugs, as well as for blood sampling.

The most common VADs in pediatric emergencies are short peripheral cannulas (SPCs) placed with the traditional blind over-needle technique, though their insertion

[1]Pediatric Emergency Department, Padua University Hospital, Padua, Italy
[2]Pediatric Hospice, Padua University Hospital, Padua, Italy

Corresponding author:
Michela Refosco, Pediatric Emergency Department, Padua University Hospital, via giustiniani 2, Padua, Veneto 35128, Italy.
Email: michy.ref@gmail.com

may be difficult because of the anatomical features of pediatric vasculature and by concomitant pathological conditions.[1,2] At times, multiple attempts at cannulation are needed, causing pain to the child and delaying the start of the intravenous treatment.[3] Additionally, Blind-SPCs have a limited lifespan, reported in the literature as between 48 and 72 h, as different complications rapidly occur before the completion of treatment. The need to rapidly establish stable venous access in pediatric patients is a common challenge.[4,5]

The clinical introduction of ultrasound guidance (US) has increased the chances of successful insertion of all venous access devices, including short peripheral cannulas (SPC) and long peripheral catheters (LPC), especially in patients with difficult venous access (DIVA).

Longer than SPCs, LPCs are peripheral VADs classified within the "mini-midline" group, with a length ranging from 6 to 15 cm.[6] They have the potential to reach deeper vessels and allow for a longer intravascular device tract compared to short cannulas of the same gage.[7,8] The current literature-based indications for choosing the placement of LPC include the need for intravenous therapy lasting 4–15 days.[5]

There is a wide range of available peripheral cannulas, each differing in design, clinical performance, and cost. SPCs can be classified as "simple," characterized by minimal or absent wings, no preassembled component, and an open system connection, or as "integrated," featuring large wings, preassembled extension and needle-free connector, thus representing a closed system.[6] Regarding LPCs, some are similar to simple SPCs and are placed using the over-needle technique, which may reduce procedural time compared to other advanced LPCs, inserted using the catheter-over-guidewire technique (direct Seldinger), that may require 8–16.8 min for placement, according to a recent review by Qin[9]; others LPCs are presented as a coaxial device.[6]

The aim of this study was to compare the clinical outcomes of PIVCs inserted in superficial veins using blind technique versus those placed with US guidance in deep veins.

Methods

In this retrospective study, we considered the peripheral VADs placed within a year, from March 2022 to February 2023, in the Pediatric Emergency Unit of a large University Hospital in Padua, Italy.

In the span of 1 year, 135 US-PIVCs were inserted, they were compared with 135 blind-PIVC of SPCs randomly selected within the same time frame. The age of the patients ranged from 0 to 18 years. The use of eco-guided technique was decided based on the status of the patient's veins, the planned therapeutic program, and the availability of personnel specifically trained in ultrasound-guided venous cannulation.

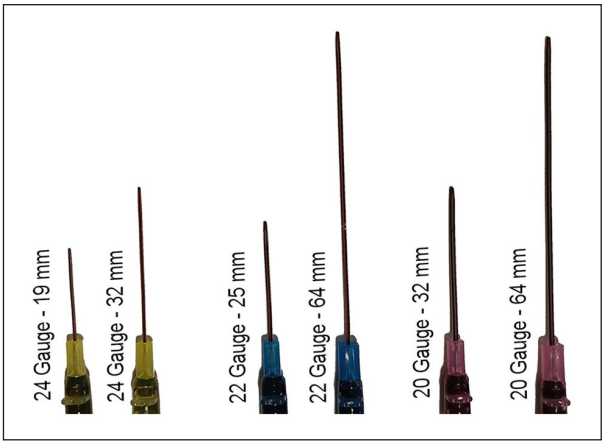

Figure 1. PIVCs used: SPC and LPC, length and size. PUR cannulas without "wings."

The peripheral VADs in our clinical setting, to be chosen according to the vein's morphology and depth, were: SPCs of 1.9 cm, 24G; 2.5 cm, 22G; 3.2 cm, 20G for Blind-PIVCs, while SPCs of 3.2 cm, 24G; and LPCs of 6.4 cm, 22G; and 6.4 cm, 20G, for US-PIVCs, as displayed in Figure 1.

All devices, LPCs and SPCs, were "simple" cannulas, without securing wings, in polyurethane, and covered with transparent semipermeable membranes.

Two different types of 24G SPCs were used based on their length. The 3.2 cm 24G cannulas were primarily used in infants with ultrasound-guided cannulations to reach their deep arm veins. They are longer than the 1.9 cm 24G SPC cannulas, which were instead used to access superficial veins. Currently, there is limited literature regarding the use of LPCs in infants; nonetheless, our 3.2 cm device still allowed us to access the deep veins of smaller patients.

The data on venous catheters were obtained from the vascular access database of the department and analyzed retrospectively. Statistical analysis was performed using IBM SPSS Statistics for Windows v.27.0 (IBM Corporation, Armonk, NY, USA). Continuous data were reported as mean and standard deviation (SD), and categorical data as frequencies and percentages. Statistical significance was assessed using the Chi-square test for categorical data and analysis of variance (ANOVA) with Tukey's post hoc comparisons for continuous data. A p-value <0.05 was regarded as significant.

All cannulas, whenever possible, were inserted 1 h after the application of a topical local anesthetic cream containing 2.5% lidocaine + 2.5% prilocaine. The maneuver was performed in a dedicated procedure room, with the child lying supine on a bed. Two operators performed the procedure on one side of the child, while the caregiver comforted the baby on the other side. Non-pharmacological analgo-sedation techniques were used to calm the child before cannula insertion. According to the protocols of our unit, the procedure was performed adopting appropriate

hand hygiene, non-sterile gloves and skin antisepsis with 2% chlorhexidine.

All devices were inserted into the veins of the upper limbs using the catheter-over-needle technique. Through the blind technique, we placed SPCs into superficial, palpable, or visible veins, with a check for tip placement based on the presence of blood during aspiration and concurrent ability for infusion without pain or signs of extravasation. Four insertion sites were accessed: basilic vein of the forearm, cephalic vein of the arm, median antebrachial vein, and veins of the hand (in this case, due to the need for immediate infusion therapies and a lack of other accessible veins). Using the ultrasound-guided technique, SPCs/LPCs were positioned to access the deep veins of the arm, after ultrasound pre-procedural evaluation of the veins according to the RaPeVA protocol (Rapid Peripheral Vein Assessment)[10]; and finally, ultrasound was utilized to verify tip placement inside the vein. When using the US technique, the insertion site was in three locations: cephalic vein of the forearm, basilic vein at the arm, and brachial vein of the arm.

The majority of VADs were inserted without the need of additional sedation, while in some cases (2 SPCs with Blind-technique, 5 SPCs with US and 16 LPCs with US technique), mild sedation with intranasal midazolam was administered to increase the possibility of cannulation at the first attempt in children with non-compliance and excessive movement.

In some children aged 1–10 years, without additional sedation, the procedural pain score was evaluated using the CHEOPS scale (Children's Hospital Eastern Ontario Pain Scale). The score could range from a minimum of 4 (no pain) to a maximum of 13 (severe pain).[11]

Results

The overall average duration of device was 5.3 ± 4.0 days for US-PIVCs and 2.5 ± 1.8 days for Blind-PIVCs.

24 G-sized cannulas were used in approximately 50% of children in both groups, who were less than 1 year old, while the other 50% of children, who were older, received 22–20G cannulas. Considering their age, we grouped the children into four categories: from 0 to 12 months, from 1 to <4 years, from 4 to <8 years, and 8 years and older. The duration of US-PIVCs increased with the child's age (except for a slight decrease in patients > 8 years), while for Blind-PIVCs, there was no significant difference among the groups. The dwell time of US-PIVCs exceeded that of Blind-PIVCs in age groups, as shown in Figure 2.

The Long Peripheral Cannulas (20–22G; 64 mm, inserted using the US technique) had a mean dwell time of 6.9 ± 4.6 days, significantly more durable compared to the total SPCs, where it resulted 2.85 ± 2 days (with 3.6 ± 2.5 days for 24G US-SPCs and 2.5 ± 1.8 days for Blind-SPCs). The comparison between Blind cannulas

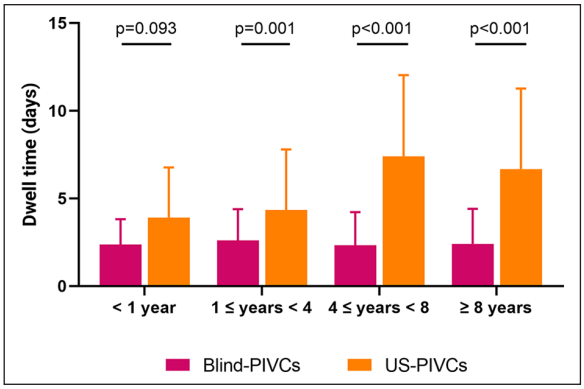

Figure 2. Dwell time of blind-PIVCs and US-PIVCs by age groups.

themselves was not significant ($p = 0.9$). Table 1 shows the different durations of the devices based on their size.

As regards the insertion site, the cannulas in the basilic vein at the arm for the US-PIVCs and the cannulas in the cephalic vein at the arm for the Blind-PIVCs were found to be more stable. The longest duration of US-PIVC (8.7 ± 5.1 days) was reported for 20G LPCs inserted in the basilic vein of the arm. On the other hand, the longest duration of Blind-PIVC (3.1 ± 2.1 days) was reported for 22G SPCs inserted in the cephalic vein at the arm.

The cannulas electively removed, upon reaching the end of the treatment or for the decision to replace them with another vascular device, were 66% in the US-PIVC group and 30% in the Blind-PIVC group. A significant difference in the incidence of device removals due to complications was observed, occurring in 34% of US-PIVCs and 70% of Blind-PIVCs, while there isn't a significant variation in the distribution of the type of complication between the two groups, as shown in Table 2. Dislodgment was the most frequent complication in both groups; this included total or partial removal of the device from the insertion site, typically caused by inappropriate patient movements or accidental actions by caregivers and staff. No complications occurred during or immediately after the insertion maneuver.

Some catheters (about the 24% of the total), awaiting replacement with midline or central device, were used sparingly for the delivery of infusions commonly considered irritating with the peripheral route (which needed to be initiated as soon as possible), including ciprofloxacin, gentamicin, meropenem, and vancomycin. The duration of these devices did not vary compared to those in which the treatment was not administered, the most common complication reported for devices used for a few times for irritating infusions was accidental dislodgment, while the incidence of phlebitis was low (approximately 5%).

In some children aged 1–10 years, procedural pain was assessed and the CHEOPS scale score was 8.4 ± 1.4 for LPCs insert with US-guidance and 6.1 ± 1.8 for SPCs with

Table 1. Trend of devices based on their size.

	US-PIVC			Blind-PIVC			*p*-Value
	n = 135			*n* = 135			
Type of cannulas	20G, 64 mm	22G, 64 mm	24G, 32 mm	20G, 32 mm	22G, 25 mm	24G, 19 mm	-
Number (%)	11 (4)	57 (21)	67 (25)	8 (3)	59 (22)	68 (25)	-
Duration	8.5 ± 4.9	6.6 ± 4.5	3.6 ± 2.5	1.5 ± 1	2.8 ± 1.9	2.3 ± 1.7	<0.001
Elective removal	6 (55)	41 (72)	44 (66)	2 (25)	18 (31)	20 (29)	<0.001
Complications	5 (45)	16 (28)	23 (34)	6 (75)	41 (69)	48 (71)	<0.001

Values expressed as *N* (%) or mean ± SD.
US: UltraSound-guided; PIVC: Peripheral IntraVenous Cannulation.

Table 2. Insertion site of the cannulas, duration and complications.

Insertion site—vein	US PIVC			Blind PIVC				*p*-Value
	Arm basilic	Forearm cephalic	Arm brachial	Median antebrachial	Veins of the hand	Arm cephalic	Forearm basilic	
Number (%)	84 (31)	38 (14)	13 (5)	56 (21)	41 (15)	29 (11)	9 (3)	-
Duration	5.9 ± 4.2	4.5 ± 3.9	4.0 ± 2.9	2.4 ± 1.7	2.4 ± 1.7	2.7 ± 1.8	2.6 ± 1.9	<0.001
Complication	28 (33)	14 (37)	4 (31)	41 (73)	30 (73)	19 (66)	5 (56)	<0.001
Dislocation	24/84	12/38	3/13	36/56	25/41	16/29	5/9	0.904
Phlebitis	2/84	0	1/13	1/56	4/41	2/29	0	0.280
Infiltration	1/84	2/38	0	4/56	1/41	1/29	0	0.715
Occlusion	1/84	0	0	0	0	0	0	0.496

Values expressed as *N* (%) or mean ± SD.
US: UltraSound-guided; PIVC: Peripheral IntraVenous Cannulation.

blind technique. Literature suggests that a score equal to or higher than 7 provides grounds for the administration of analgesics.[11]

Discussion

Our results highlight that the US-PIVCs were apparently more effective than Blind-PIVCs, allowing successful completion of intravenous therapy in approximately two-thirds of children and reducing the frequency of venipunctures, consequently minimizing traumatic events for pediatric patients.

The differences between the two groups are probably related not only to the insertion techniques (US vs blind) but also to the different devices used. In fact, focusing on the length of the devices, LPCs showed better dwell time compared to SPCs, almost twice as long (6.9 ± 4.6 vs 2.85 ± 2 days), as the longer intravascular segment of the cannula provided greater stability.

The majority of US-PIVCs and LPCs, in our study, were removed electively at the completion of treatment; though, it is possible that they might have remained in place even longer, thereby increasing the average dwelling time.

The US-PIVCs had a significantly lower rate of complications compared to the Blind-PIVCs. The ability to visualize the vein with ultrasound allows for obtaining an adequate intra-vascular device tract and enables the selection of an appropriately sized vein for the cannula.

Interestingly, there is a lack of literature data regarding the dwell times of over-needle LPC devices, as studies tend to focus on LPCs inserted using the Seldinger technique, with an average dwell time ranging from 5 to 14 days in the pediatric population,[12] or in a 2021 study on infants, the average dwell time was 4.17 days (ranging from 1 to 12).[13]

In adults, several studies have investigated the performance of US-PIVCs with encouraging results. A recent investigation about 1156 LPCs inserted using the Seldinger technique in elderly patients has shown an average dwell time of the device of 10 days (1–30).[14] In another study, Bahl et al.[15] found that in the adult population LPCs are more cost-effective than SPCs, because of the longer dwelling time and less requirement for repeated cannulations.

Insertion sites distant from joint movements are associated with longer dwell times of the device. In this study, for both US-PIVCs and Blind-PIVCs, the most stable insertion site was the arm compared to the forearm; ultrasound-guided cannulas exhibited lower complication rates than blind cannulas for every insertion site analyzed.

The main complication observed was dislocation. The stabilization issue can be improved by adopting devices with wings and using cyanoacrylate glue, as suggested by

Bahl's findings.[16] Additionally, for the PIVCs under investigation, it is recommended to use effective Engineered Stabilization Devices (ESD) such as statlock IV, or to incorporate advanced dressings like Sorbaview Shield. In a pilot study that analyzed LPCs in children over 10 years of age, Paladini reported that catheters secured with sutureless devices lasted 9.2 ± 6 days.[3]

In the US-PIVCs group, there we observed an increase in the dwelling time of the cannula in relation to the patients' age, which is attributable to the fact that, aside from receiving, on average, larger vascular accesses, older children presumably had better tolerance to the VAD and engaged in fewer attempts at self-removal of the device.

Cannulation was apparently more painful for US-PIVCs than for Blind-PIVCs, maybe because the device passes through deeper layers of the skin and subcutaneous tissues, which are not covered by superficial cutaneous anesthesia. Thus, proper pain management during deep vein cannulation may require not only topical analgesia but also for mild sedation. Effective analgesia and reduction of anxiety can be achieved combining topical anesthesia and nitrous oxide,[17] or by administration of oralketamine.[18]

Our study has many limitations:

(a) The adoption of glue is recommended by international guidelines as necessary to stabilize LPCs.
(b) The use of simple VADs, without wings, in association with transparent semi-permeable membranes causes a greater risk of dislocation, it is recommended to use dressings with integrated reinforcement or appropriate sutureless devices.
(c) Being a retrospective analysis, many relevant parameters are missing (such as DIVA score, time of the procedure, and the number of attempts), since they were not recorded in the database.
(d) Given the retrospective nature of the study, some results might be biased by factors such as the varying expertise of different healthcare providers and the different baseline DIVA scores of the patients.

It is believed that proposing randomized control trials for future studies, comparing Seldinger versus non-Seldinger techniques, comparing LPC with integrated peripheral cannula, conducting prospective comparative studies with three arms: Blind-SPC/US-SPC/US-LPC, could be useful. In the case of further investigations, it is hoped that recommended safety and stability systems for the devices will be adopted.

Conclusion

On the basis of our data, we suggest that LPCs should be preferred in children requiring intravenous infusions for >3 days, while the 2021 Standards of the Infusion Nursing Society suggest a cut-off at 4 days.[5] Ultrasound-guided placement of long peripheral cannulas is a technique that requires adequate training: in each unit, this maneuver must be performed by healthcare professionals (both physicians and nurses) specifically and appropriately trained, so to avoid insertion-related complications.[19]

Acknowledgements

We would like to thank the Pediatric Emergency Department's staff in Padua for their invaluable work in the positioning of vascular access, SB for her assistance in statistical considerations, and MM for her help with the English translation.

Declaration of conflicting interests

The author(s) declared no potential conflicts of interest with respect to the research, authorship, and/or publication of this article.

Funding

The author(s) received no financial support for the research, authorship, and/or publication of this article.

Ethical approval

The Territorial Ethics Committee central-eastern Veneto area, Italy, provided approval (28/09/2023), protocol number 0057943.

ORCID iD

Michela Refosco https://orcid.org/0009-0001-8409-431X

References

1. Privitera D, Bassi E, Airoldi C, et al. Effectiveness of short peripheral intravenous catheter educational programmes to improve clinical outcomes protocol for a systematic review. *MethodsX* 2023; 11: 102352.
2. Berlanga-Macías C, Díez-Fernández A, Martínez-Hortelano JA, et al. Ultrasound-guided versus traditional method for peripheral venous access: an umbrella review. *BMC Nurs* 2022; 21(1): 307.
3. Paladini A, Chiaretti A, Sellasie KW, et al. Ultrasound-guided placement of long peripheral cannulas in children over the age of 10 years admitted to the emergency department: a pilot study. *BMJ Paediatr Open* 2018; 2(1): e000244.
4. DeVries M and Scott N. Keeping patients safer: reviewing predictors of success and failure of short peripheral intravenous catheters. *J Infus Nurs* 2022; 45(4): 210–219.
5. Gorski LA, Hadaway L, Hagle ME, et al. Infusion therapy standards of practice, 8th edition. *J Infus Nurs* 2021; 44(1S Suppl 1): S1–S224.
6. Pittiruti M, Van Boxtel T, Scoppettuolo G, et al. European recommendations on the proper indication and use of peripheral venous access devices (the ERPIUP consensus): a WoCoVA project. *J Vasc Access* 2023; 24(1): 165–182.
7. Qin KR, Pittiruti M, Nataraja RM, et al. Long peripheral catheters and midline catheters: insights from a survey of vascular access specialists. *J Vasc Access* 2021; 22(6): 905–910.

8. Qin KR, Nataraja RM and Pacilli M. Long peripheral catheters: is it time to address the confusion? *J Vasc Access* 2019; 20(5): 457–460.
9. Qin KR, Ensor N, Barnes R, et al. Long peripheral catheters for intravenous access in adults and children: a systematic review of the literature. *J Vasc Access* 2021; 22(5): 767–777.
10. Brescia F, Pittiruti M, Spencer TR, et al. The SIP protocol update: eight strategies, incorporating rapid peripheral vein assessment (RaPeVA), to minimize complications associated with peripherally inserted central catheter insertion. *J Vasc Access* 2024; 25(1): 5–13.
11. Zieliński J, Morawska-Kochman M and Zatoński T. Pain assessment and management in children in the postoperative period: a review of the most commonly used postoperative pain assessment tools, new diagnostic methods and the latest guidelines for postoperative pain therapy in children. *Adv Clin Exp Med* 2020; 29(3): 365–374.
12. Burek AG, Liljestrom T, Dundon M, et al. Long peripheral catheters in children: a scoping review. *J Hosp Med* 2022; 17(12): 1000–1009.
13. Romitti MG, Perez CR, Pezzotti E, et al. Long peripheral catheters in neonates: filling the gap between short peripheral catheters and epicutaneous-caval catheters? *J Vasc Access* 2021; 24(5): 920–925.
14. Lisova K, Pavelkova K, Šimkova P, et al. The selection of the suitable long peripheral catheter in DIVA patients: the significance of ultrasonography. *J Vasc Access* 2023: 11297298231187028..
15. Bahl A, Johnson S, Hijazi M, et al. Cost effectiveness of ultrasound-guided long peripheral catheters in difficult vascular access patients. *J Vasc Access* 2024; 25(4): 1211.
16. Bahl A, Gibson SM, Jankowski D, et al. Short peripheral intravenous catheter securement with cyanoacrylate glue compared to conventional dressing: a randomized controlled trial. *J Vasc Access* 2023; 24(1): 52–63.
17. Hee HI, Goy RW and Ng AS. Effective reduction of anxiety and pain during venous cannulation in children: a comparison of analgesic efficacy conferred by nitrous oxide, EMLA and combination. *Paediatr Anaesth* 2003; 13(3): 210–216.
18. Bagheri M, Soltani AE, Qorbani M, et al. Efficacy and safety of low dose oral ketamine for controlling pain and distress during intravenous cannulation in children: a double-blind, randomized, placebo-controlled trial. *Korean J Pain* 2022; 35(3): 311–318.
19. Lamperti M, Bodenham AR, Pittiruti M, et al. International evidence-based recommendations on ultrasound-guided vascular access. *Intensive Care Med* 2012; 38(7): 1105–1117.