Experiences scanning small children without sedation in a clinical setting - the MoCo project at Rigshospitalet

Melanie Ganz-Benjaminsen

Associate Professor, PhD
Neurobiology Research Unit, Rigshospitalet &
Department of Computer Science, University of Copenhagen, Denmark

KØBENHAVNS UNIVERSITET

Introduction

MRI artefacts and their consequences

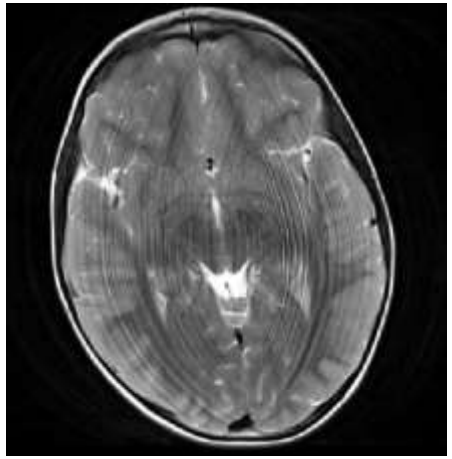

- patient head motion due to long acquisition times
  [Afacan et al. Pediatr Radiol. 2016]
- artefacts manifest as ghosting, blurring or signal variations, overall image quality and resulting in unsuccessful diagnoses
  [Godenschweger et al. PhysMed Biol. 2016]

- 20% percentage of at least partly repeated MRI examinations, estimated increased cost of 115,000 US dollars/scanner/year in the US due to motion
  [Andre et al. J Am Coll Radiol. 2015]

Introduction
Clinical MRI of children

- tend to move more in the MR scanner than adults *[De Bie et al. Eur J Pediatr. 2010]*
  - more active, lie less still
  - intimitated by scanner size
  - exposure to loud noises

- Diagnostic MRI of newborns, infants, and toddlers is typically conducted using sedation or GA *[Artunduaga et al. Pediatr. Radiol. 2021]*
  - 61–100% for children between 4 and 6 years *[Runge et al. Eur J Radiol. (2018)]*
  - 80% for children aged 1-6 years *[Jaimes et al. Am J Roentgenol. 2021]*
  - 40% for children aged 7–12 years *[Jaimes et al. Am J Roentgenol. 2021]*

Introduction
Consequences of anesthesia

- risk of sedation-related adverse events *[Cravero et al. Anesthesia & Analgesia 2009]*
- neurotoxic effects, particularly when administered to young children *[Stratmann et al. Anesthesia & Analgesia 2011]*
- FDA label changes for common general anesthetics and sedative agents in young children in 2017 *[Andropoulos et al. N Engl J Med 2017]*

- increases the patient's waiting times as well as the costs of the scan
  - additional cost for using GA in MRI estimated to 319,000 US dollars/scanner/year in Denmark *[Slipsager et al. J Magnet Reson. Imaging. (2020)]*

MoCo project

Neuroimaging of children without sedation can become reality

- PI: Melanie Ganz-Benjaminsen
- Located at: NRU, Rigshospitalet
- Dates: 1. April 2019 – end of 2023
- Budget: ca. 3.9 mio DKK
- Funded by Elsass Fonden

Introduction

Purpose

- Our aim is that the majority of children referred to MR examination at Copenhagen University Hospital should be able to be scanned without sedation / GA

- We would like to achieve this aim in two ways:
  - by preparing the child with a mobile phone app and a practice session in a practice scanner (mock scanner)

  - by correcting the images using an external motion tracking device and applying prospective motion correction during image acquisition

Methods

Study Setup

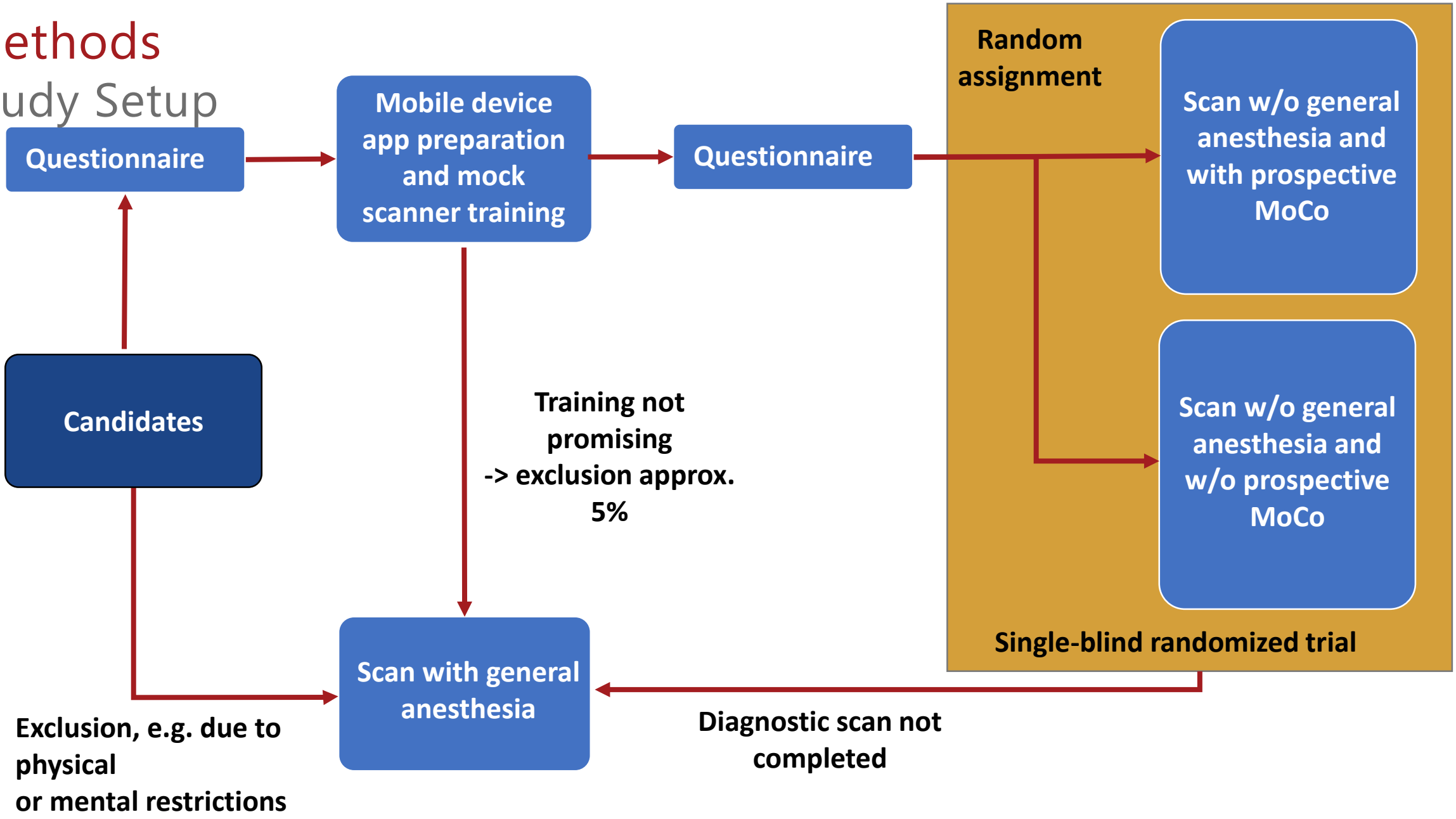

Methods

In-/Exclusion criteria

- Inclusion:
  - Age 4 -10 years
  - referred for an elective scheduled clinical cerebral MRI scan in general anesthesia

- Exclusion:
  - unstable medical condition interfering with safety of MRI scan
  - non-fluent in Danish or pronounced visual or auditory impairments
  - no major physical or developmental challenges that interfere with participation in the experimental protocol
  - contraindications for MRI (metal implants, etc.).

Methods

3-stage rocket

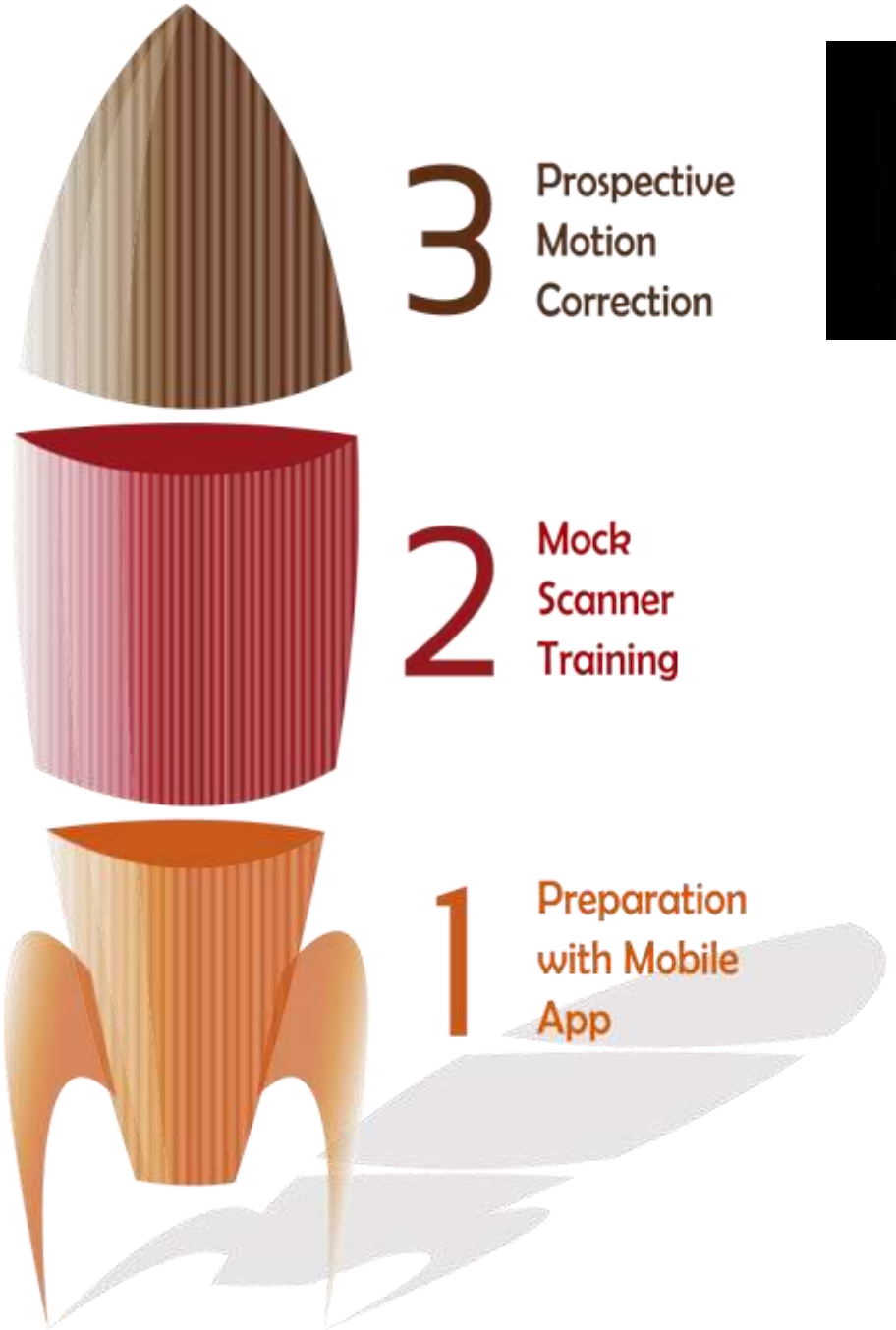

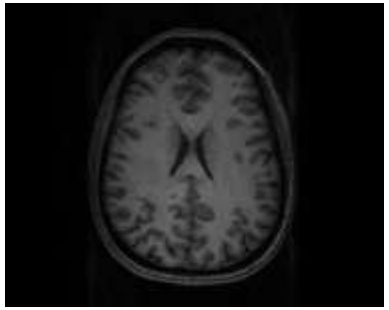

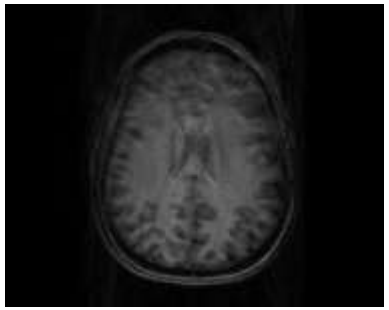

Methods

Mobile phone application

Modular design:

- Own the IP/Code
- “White label” design
  - Avatar
  - Background images
  - Videos

- Re-used in Bergen

https://github.com/melanieganz/MoCoProject

Methods

NRU mock scanner

Details:

- Siemens Magnetom Prisma shell
- 64- channel head coil
- Noise simulation
- Head motion tracking

Methods

NRU mock scanner

Operator room setup:

- PCs
- “fake” scan
- Sound control
- Intercom
- Movie interface

Methods NRU mock scanner in action

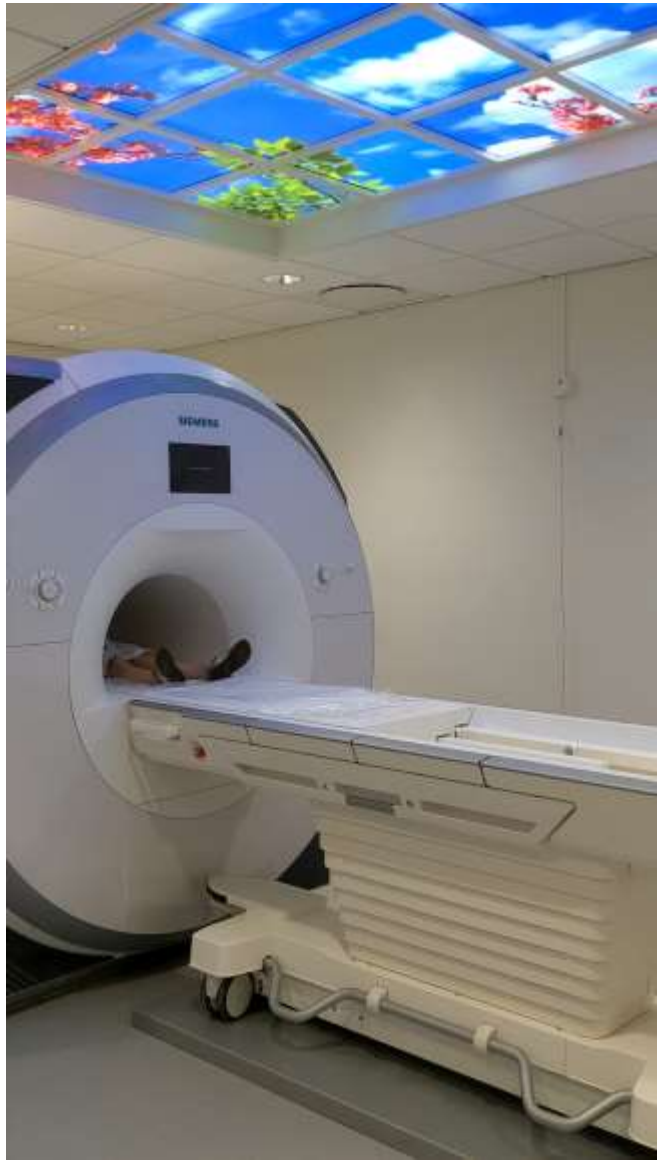

Methods

Motion monitoring/correction with Tracoline (both scanners)

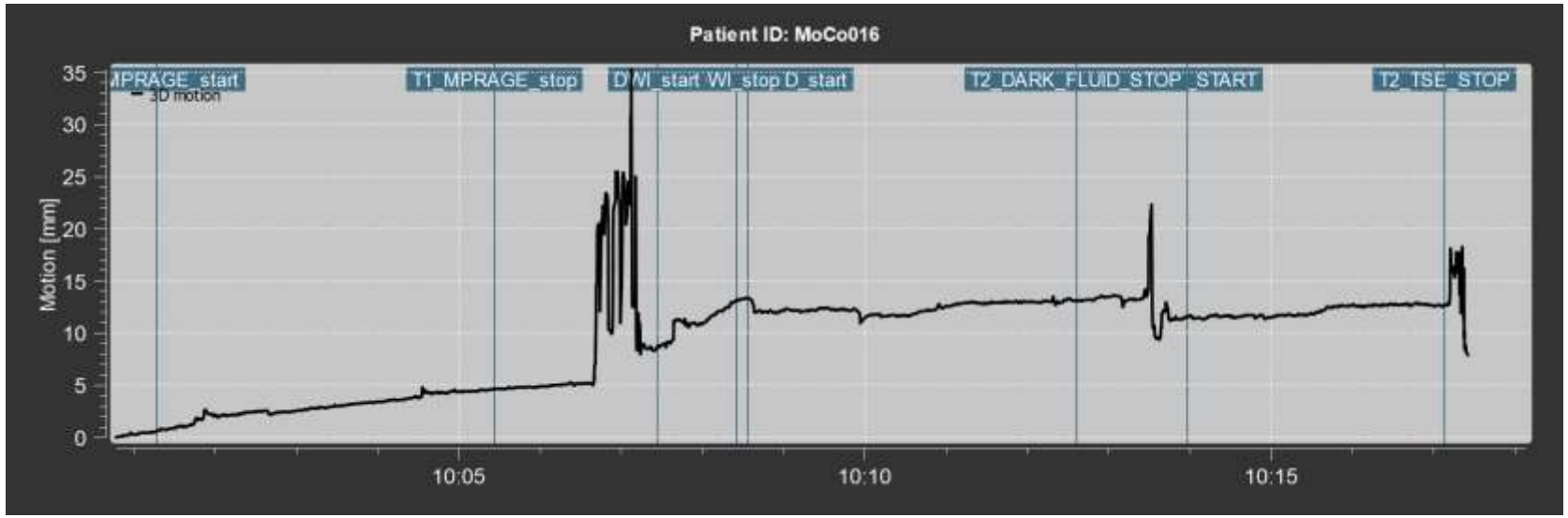

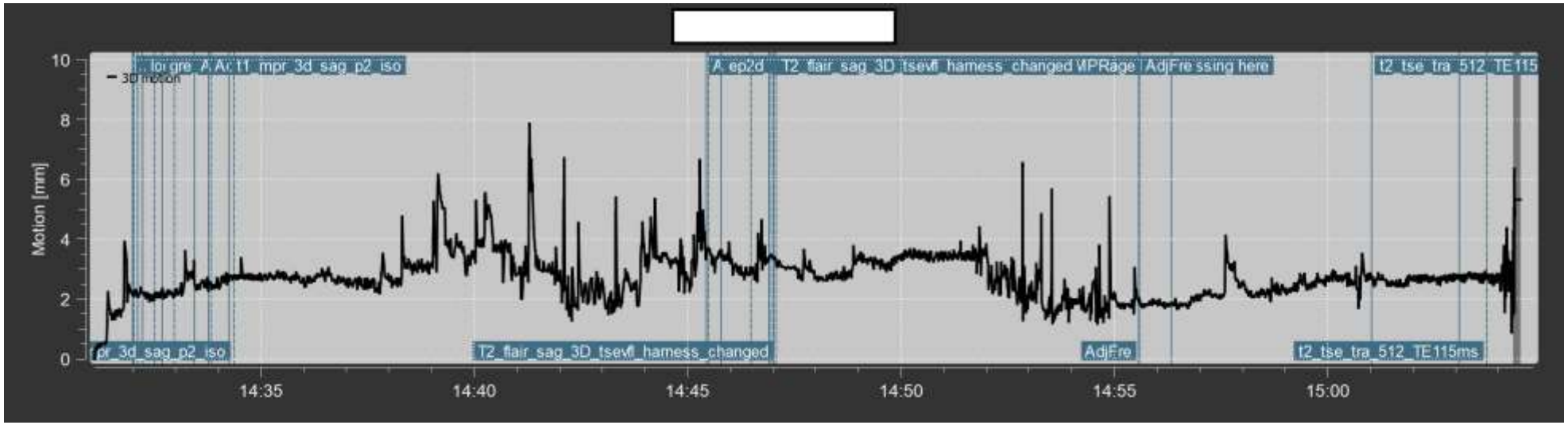

Results

Included patient population in the prospective clinical trial

	N	%
Total	50	100
Sex		
Female	25	50
Male	25	50
Age [years]		
Mean (SD)	7,24 (-1.87)	
Range (min,max)	[4, 11]	
Protocol		
cerebrum	49	98
cerebrum + neuroakse	1	2
Disease		
Hearing loss	9	18
Epilepsi	7	14
Adrenoleukodystrophy	4	8
Neurofibromathosis	4	8
Headache	7	14
Tumor Cerebri	6	12
Development delay	5	10
Other	5	10

Results

Included patient population in the prospective clinical trial

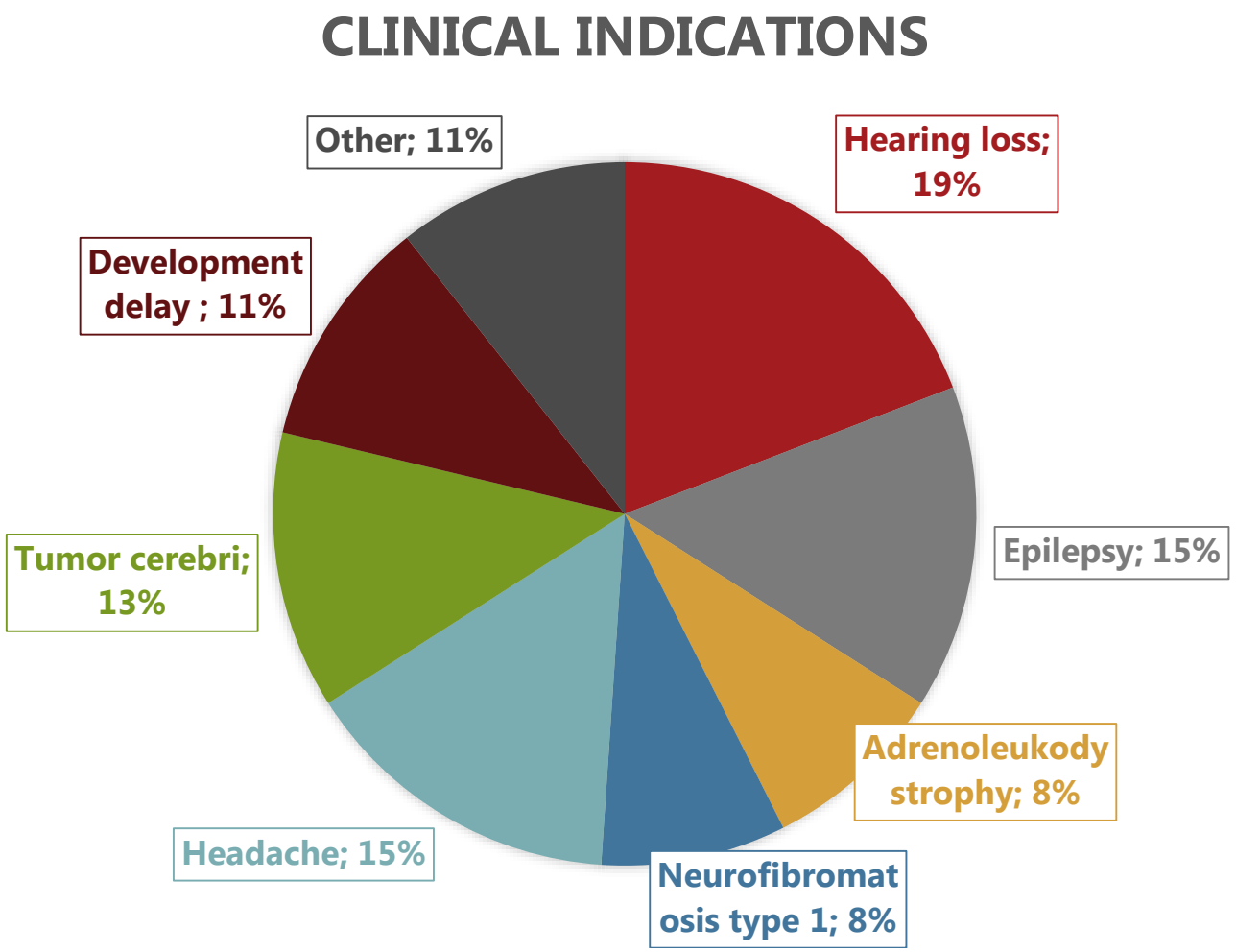

Results

Primary outcome of the prospective clinical trial

- 50 children have completed the full program
- 47 had a fully diagnostic scan wo anesthesia
- **94% success rate**

Results

Primary outcome of the prospective clinical trial

- 3 children moved to GA scan
  - 1 participant had non-verbal autism, also follow-up scans recommended in GA
  - 1 participant did not succeed the first time, for re-scan offered same treatment and then successful
  - 1 participant had traumatic experience during ear operation, could not tolerate ear plugs or noise, had successful mock scanner training (2h!), but could not cooperate during actual scan

- No issues with entering the scanner, residual motion is very low
  - training the situation (mobile phone app) and personal interaction even more important than technical solutions?

Results

Secondary outcomes - Evaluation of anxiety scanner

- STAI-C questionnaire at 5 time points, N=40
- Linear mixed model
  - Covariates: age, gender, STAI-C at home
- STAIC < 30 indicates a low level of anxiety

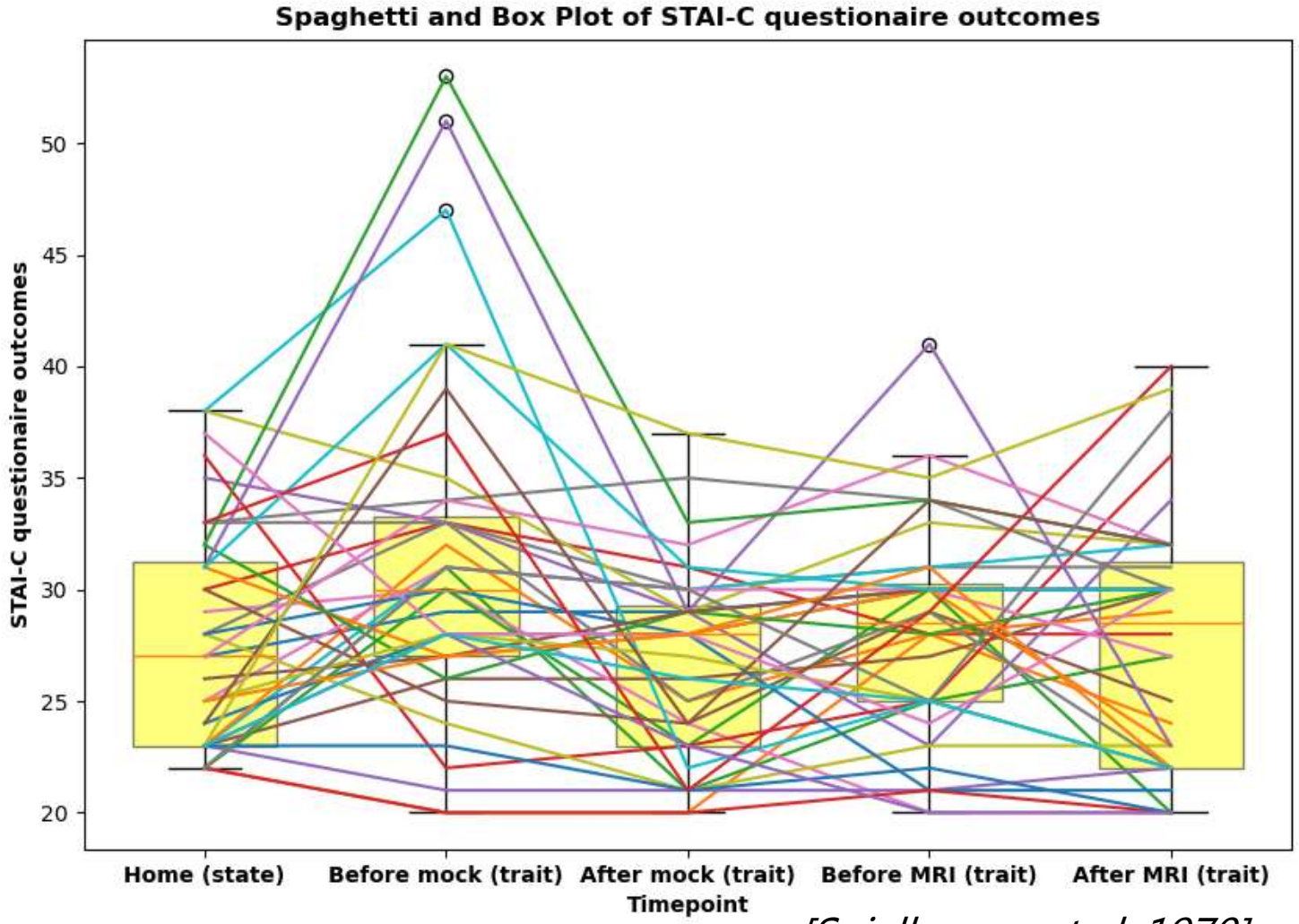

[Spielberger et al. 1970]

Results

Secondary outcomes - Motion correction status

- Randomization not fully successful

- PMC ON failed
  - Technical issues
  - Bad quality -> ethical decision to turn off PMC

NUMBER OF PMC ON/OFF SCANS

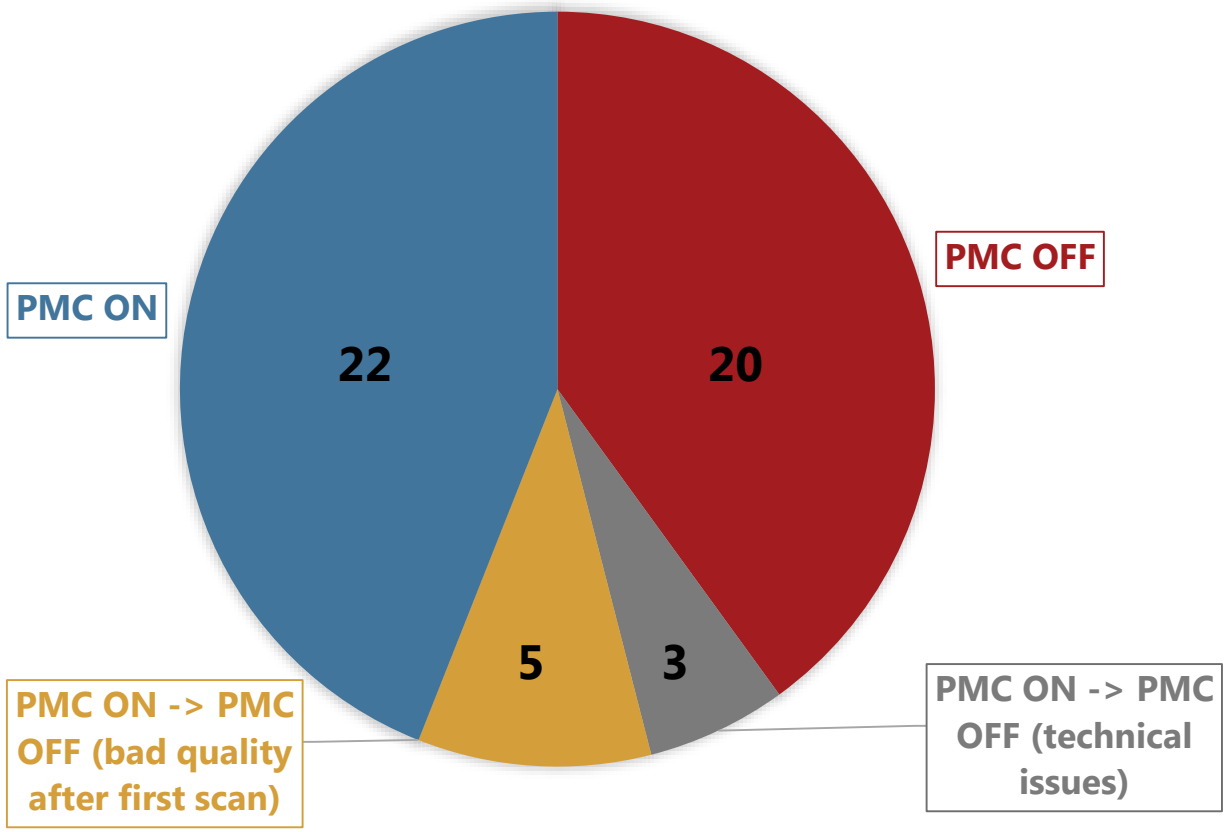

Results

Secondary outcomes - Evaluation of value of motion correction

- MPRage N=45
  - PMC ON (N = 24) and PMC OFF (N = 21)
- Image quality
  - Average Edge strength
  - Likert Scale evaluation by radiographer (TBA)
- No significant differences, maybe tendency for better image quality with PMC ON

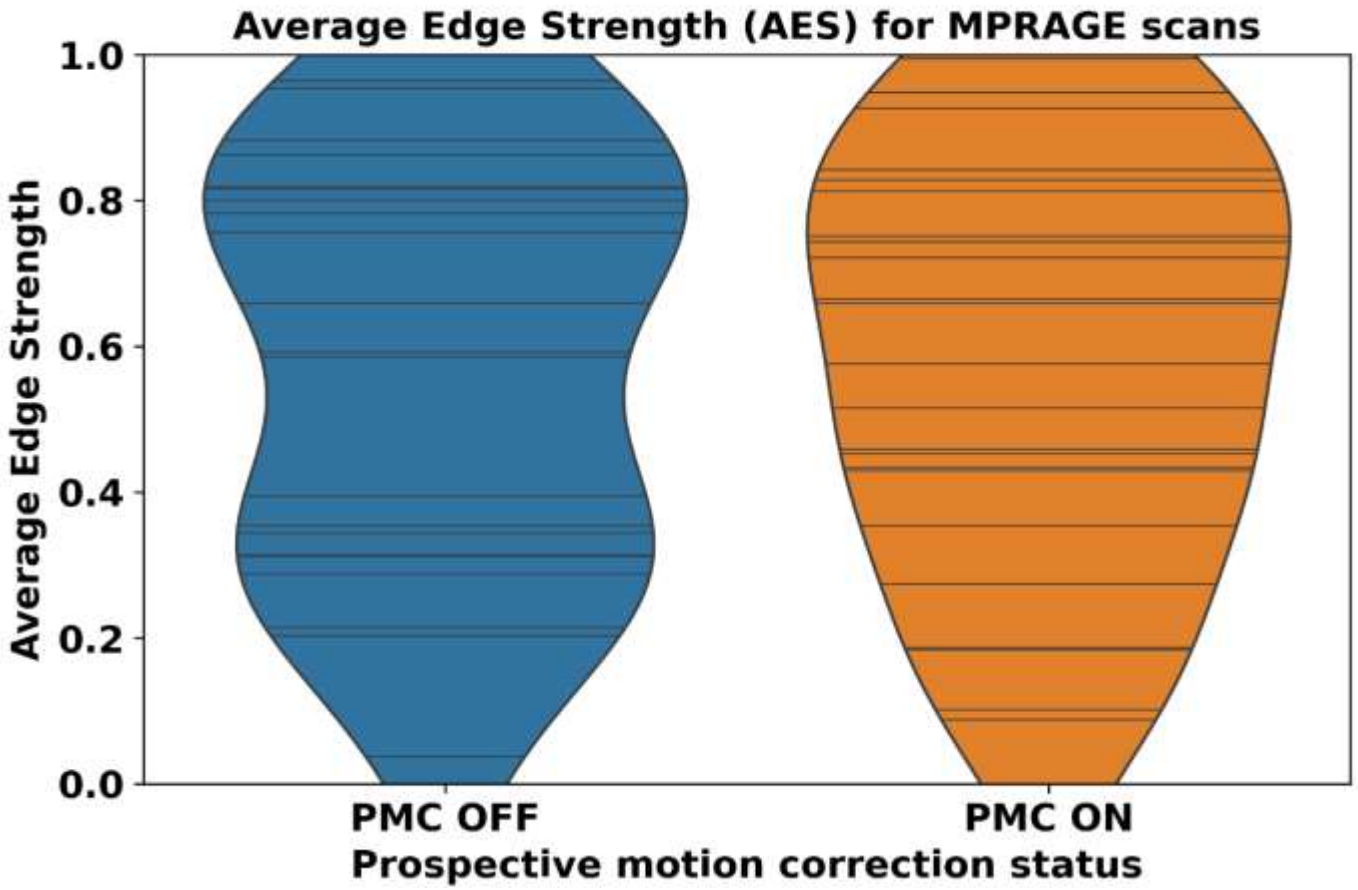

[Eichhorn et al. ISMRM 2022, Marchetto et al. ISMRM 2024]

Discussion

- focus on the complete clinical workflow, not only on the sequences
  [Harrington et al. Ped. Rad. 2022]

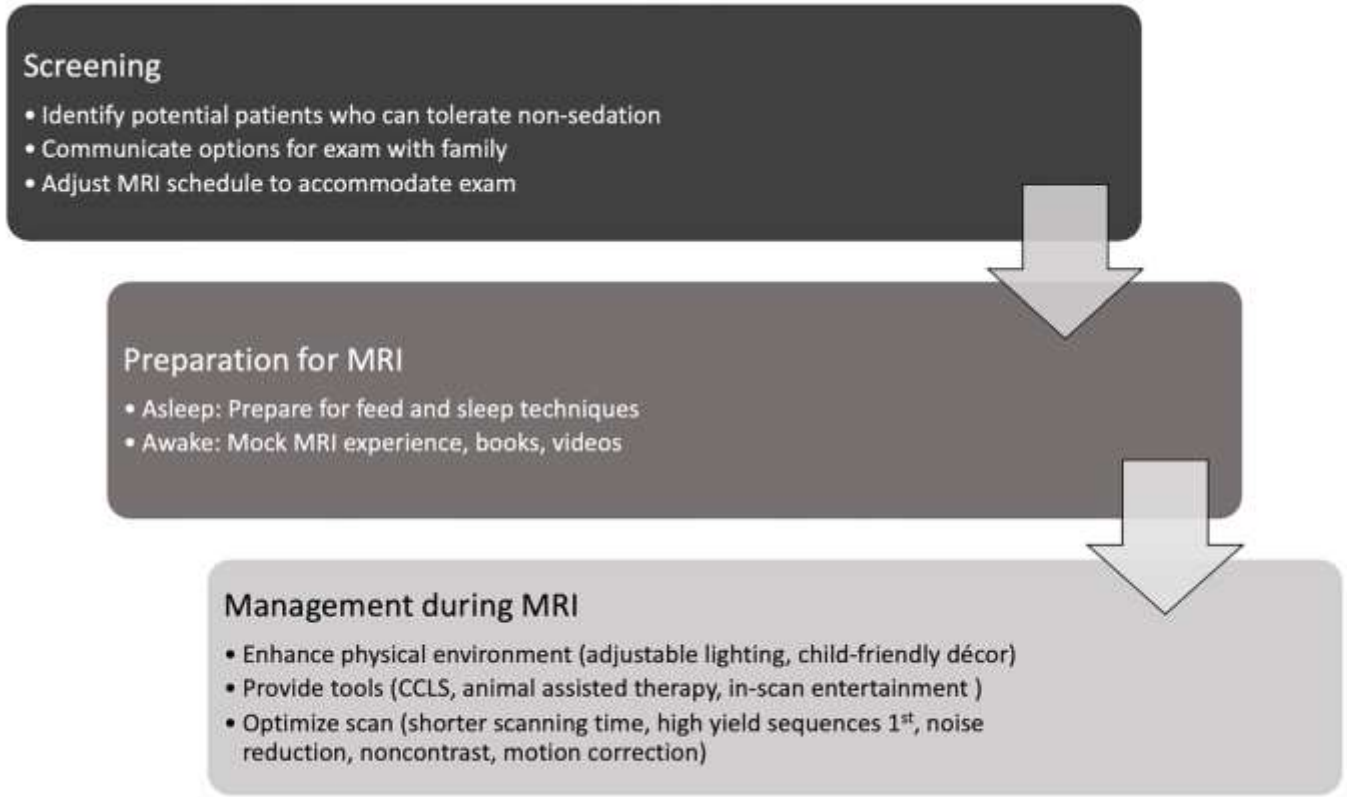

Discussion

Future endeavours

- moving on to imaging infants between 0 and 2 years -> NIBS-CP
- examine the effectiveness of training vs. prospective/retrospective motion correction –>Mini-MoCo
- Pushing the sequences to their limit wrt speed with deep learning reconstruction -> Siemens

NIBS-CP – NeuroImaging of Babies during natural Sleep to assess typical development and Cerebral Palsy

- Longitudinal cerebral MRI of 200 infants at 3 time points in natural sleep
- ~50-60 children referred to clinical cerebral MRI scans via CP-EDIT study
  - Clinical focus on structural acquisitions as well as diffusion, no fMRI, no spectroscopy
- Paving the way for clinical infant imaging in natural sleep
  - Practical setup – limited time, train personell, medvac, baby ear muffs, infant coil
- Conducted at Hvidovre Hospital -> transfer knowledge to Mary Elizabeth Hospital/BørneRiget

Mini-MoCo

- Shorter version of MoCo study in the hands of the Department of Radiology at Rigshospitalet and lead by radiographers
  - No mock scanner training and no motion correction
  - Preparation from home via mobile phone app/online videos
  - Siemens Innovision
  - More time for the radiographers to interact with the children (45 min vs. 30 min scan slots)

- 20 patients – started in september 2023 and ongoing
  - 18 recruited, 16 scanned – 15 successful -> **93% success rate**

MoCo project team & Funding

Plus:
Vibeke, Kevin, Amanda, Mette, Radiology booking

We gratefully acknowledge funding by

Elsass Fonden (18-3-0147)

Rigshospitalet
Et højt specialiseret hospital

DET NATUR- OG BIOVIDENSKABELIGE FAKULTET
KØBENHAVNS UNIVERSITET

MGH/HST Athinoula A. Martinos Center for Biomedical Imaging

METROPOLITAN UNIVERSITY COLLEGE

For good collaboration we'd like to thank

Siemens Healthineers, Denmark
TracInnovations A/S

https://github.com/melanieganz/MoCoProject

Thank you for listening!

Questions?

MoCo project team & Funding

Plus:
Vibeke, Kevin, Amanda, Mette, Radiology booking

We gratefully acknowledge funding by

Elsass Fonden (18-3-0147)

Rigshospitalet
Et højt specialiseret hospital

DET NATUR- OG BIOVIDENSKABELIGE FAKULTET
KØBENHAVNS UNIVERSITET

MGH/HST Athinoula A. Martinos Center for Biomedical Imaging

METROPOLITAN UNIVERSITY COLLEGE

For good collaboration we'd like to thank

Siemens Healthineers, Denmark
TracInnovations A/S

https://github.com/melanieganz/MoCoProject