Hypermobile Ehlers-Danlos Syndrome (hEDS)

A Patient Guide for Neurologists

WHAT IS hEDS? hEDS is a heritable disorder of connective tissue, the structural 'glue' of the body, causing joint instability, skin fragility, and systemic effects. Severity varies widely, from mild laxity and intermittent bracing to wheelchair use and complex multisystem involvement.

~1 in 500 people affected	Avg. 10+ years to diagnosis	3:1 to 4:1 diagnosed are female	No cure: management-focused

HOW HEDS AFFECTS THE BODY — SYSTEMIC INVOLVEMENT:

Patient has checked applicable symptoms

Neurological

- ☐ Migraines & headaches
- ☐ Brain fog/cognitive fatigue
- ☐ Small fiber neuropathy
- ☐ Proprioception deficits
- ☐ Anxiety/depression (often neurological in origin)

Gastrointestinal

- ☐ IBS
- ☐ Gastroparesis/ delayed emptying
- ☐ GERD & acid reflux
- ☐ Food intolerances

Immune / MCAS

- ☐ MCAS — mast cell overactivation
- ☐ Flushing, hives, itching
- ☐ GI distress & food reactions
- ☐ Chemical/environmental sensitivity

Musculoskeletal

- ☐ Joint hypermobility & instability
- ☐ Subluxations & dislocations
- ☐ Chronic widespread pain
- ☐ Muscle fatigue & weakness
- ☐ Cervical instability (can cause neurological issues)

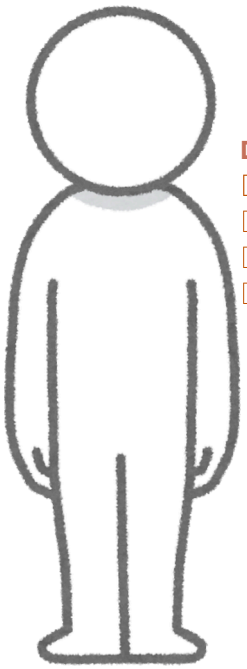

Cardiovascular

- ☐ POTS — heart rate spikes on standing
- ☐ Blood pooling & dizziness
- ☐ Palpitations

Dermatological

- ☐ Soft, velvety, hyperextensible skin
- ☐ Stretch marks without weight change
- ☐ Easy bruising
- ☐ Poor wound healing

Fatigue & Sleep

- ☐ Profound fatigue
- ☐ Non-restorative sleep
- ☐ Post-exertional malaise
- ☐ Chronic widespread pain at rest

Genitourinary

- ☐ Pelvic floor dysfunction
- ☐ Bladder urgency/frequency
- ☐ Chronic pelvic pain
- ☐ Menstrual irregularities

DO

- Recognize neurological symptoms as legitimate hEDS manifestations
- Screen for small fiber neuropathy via skin punch biopsy
- Evaluate for dysautonomia and POTS
- Consider cervical instability as a source of neurological symptoms
- Coordinate with cardiology, rheumatology, and pain management
- Validate symptom burden even when standard imaging is normal
- Recognize that brain fog in hEDS is frequently driven by POTS or MCAS, not primary cognitive disease

DON'T

- Diagnose functional neurological disorder without first ruling out hEDS; if FND is suspected, hEDS should be excluded first
- Attribute cognitive symptoms (brain fog) solely to anxiety or depression
- Assume normal MRI rules out significant neurological involvement
- Overlook proprioception deficits as a source of falls and instability
- Interpret pain complaints as drug-seeking behavior before ruling out undertreated hEDS pain

ORDER / REFER

- Skin punch biopsy (small fiber neuropathy)
- Tilt table test (POTS/dysautonomia screen)
- Cervical spine imaging if instability suspected
- Neuropsychological evaluation for cognitive symptoms if indicated
- PT specializing in hypermobility and proprioception
- Pain management for central sensitization
- Autonomic function testing (QSART or thermoregulatory sweat test) if small fiber neuropathy is confirmed or suspected

© 2026 Informed Patient Project. Free for personal use only. Not for resale.

The hEDS Trifecta: Frequently Co-Occurring Conditions

hEDS	+	POTS	+	MCAS
Joint instability Structurally abnormal connective tissue Systemic symptoms		Heart rate spikes on standing Dizziness & fatigue Brain fog & cognitive dysfunction Exercise intolerance		Mast cell overactivation Flushing, hives, itching GI distress & food reactions Chemical/environmental sensitivity

Why Neurology Matters for hEDS: Neurological symptoms in hEDS (migraines, brain fog, small fiber neuropathy, proprioception deficits, and dysautonomia) are frequently labeled psychosomatic or functional before hEDS is considered. Standard imaging is often normal, which does not mean nothing is wrong. Neurologists are frequently the first to identify dysautonomia and small fiber neuropathy as physical, measurable manifestations of connective tissue disease, and that recognition can be life-changing for patients who have been dismissed for years.

Associated Conditions to Consider: Chiari malformation type 1 and intracranial hypertension occur at higher rates in hEDS patients than in the general population. Both can produce headache, visual changes, tinnitus, and cognitive symptoms that overlap with other hEDS neurological manifestations. If a patient presents with positional headache, pulsatile tinnitus, or visual obscurations, these diagnoses should be included in the differential before attributing symptoms to hEDS alone. Tethered cord syndrome should also be considered in hEDS patients presenting with lower extremity neurological symptoms, bladder dysfunction, or progressive back pain, as connective tissue laxity may predispose to cord tethering.

COMMON MISDIAGNOSES IN hEDS PATIENTS PRESENTING TO NEUROLOGY

Often Diagnosed As	Consider instead/Also	Key Differentiator
Functional neurological disorder (FND)	hEDS with neurological manifestations	Clinical hEDS diagnosis; symptoms are consistent, not variable in the pattern typical of FND; connective tissue features present
Migraine disorder (isolated)	hEDS-driven migraine with intracranial or cervicogenic contribution	Cervical instability and intracranial hypertension are both associated with hEDS and can drive refractory migraine
Primary anxiety or depression	hEDS with autonomic dysfunction and MCAS	Autonomic instability and mast cell mediator release produce symptoms that mimic and are frequently mislabeled as primary psychiatric disease
Multiple sclerosis (early workup)	hEDS with small fiber neuropathy and dysautonomia	Normal MRI; skin punch biopsy may confirm small fiber neuropathy; no demyelinating lesions
Chronic fatigue syndrome or ME/CFS	hEDS with POTS and post-exertional malaise	Orthostatic assessment; POTS frequently drives fatigue and post-exertional malaise in hEDS patients
Psychosomatic/ functional	hEDS with normal standard workup	Clinical diagnosis; normal imaging and labs are expected and do not exclude hEDS

Cervical Instability in hEDS: Connective tissue laxity can affect the craniocervical junction and upper cervical spine, producing neurological symptoms including headache, dizziness, visual disturbances, tinnitus, and upper limb weakness. These presentations may be mistaken for primary neurological conditions. Avoid aggressive cervical manipulation. If craniocervical instability is suspected, consider upright MRI or referral to a neurosurgeon with connective tissue disorder experience before initiating manual therapy.

MCAS and Neurological Symptoms: Mast cell mediator release can produce or exacerbate headache, brain fog, anxiety-like symptoms, and cognitive dysfunction. If neurological symptoms are episodic and triggered by foods, scents, or environmental exposures, or accompanied by flushing, GI distress, or hives, include MCAS in the differential and consider Allergy/Immunology referral.

Sources: Malfait et al. 2017 (AJMG) | Tinkle et al. 2017 (AJMG) | Genetics in Medicine Open 2023 | ehlers-danlos.com | PMC11390471 | PMC11348541

This document was created to provide a concise neurological reference for providers less familiar with hEDS.
Neurological involvement is among the most frequently dismissed aspects of this condition. This reference is intended to support thorough evaluation.

© 2026 Informed Patient Project. Free for personal use only. Not for resale.

MY CURRENT MEDICATIONS & SUPPLEMENTS	WHAT HELPS:
	WHAT MAKES IT WORSE:
PRIOR DIAGNOSES RECEIVED:	
SPECIALISTS PREVIOUSLY SEEN:	

WHAT I NEED FROM TODAY'S APPOINTMENT
My primary concern today:
Questions I have:
Medication changes:
Referrals needed:
Other:
Additional notes:

CURRENT SYMPTOM SEVERITY: 0-10 Refer to Mankoski Pain Scale (pg 4)
Joint Pain and Instability Severity:
Fatigue Severity:
GI Symptoms Type and Frequency:
Heart Rate and Dizziness Triggers and Frequency:
Additional Symptoms:

Sources: Malfait et al. 2017 (AJMG) | Tinkle et al. 2017 (AJMG) | Genetics in Medicine Open 2023 | ehlers-danlos.com | PMC11390471 | PMC11348541

This document was created to provide a concise neurological reference for providers less familiar with hEDS.
Neurological involvement is among the most frequently dismissed aspects of this condition. This reference is intended to support thorough evaluation.

© 2026 Informed Patient Project. Free for personal use only. Not for resale.

MANKOSKI PAIN SCALE

Use this scale when rating your pain severity in CURRENT SYMPTOM SEVERITY

#	What the pain is like	Typical treatment	In my own words
0	No pain.	*No medication needed.*	*"I feel completely normal."*
1	Very minor annoyance — occasional minor twinges.	*No medication needed.*	*"Hardly notice it."*
2	Minor annoyance — occasional strong twinges.	*No medication needed.*	*"Annoying but manageable."*
3	Annoying enough to be distracting.	*Mild OTC painkillers may help.*	*"Hard to ignore; affects my focus."*
4	Can be ignored if very focused, but still distracting.	*Mild OTC painkillers relieve pain for 3-4 hours.*	*"Getting in the way of tasks."*
5	Can't be ignored for more than 30 minutes.	*Mild OTC painkillers reduce pain for 3-4 hours.*	*"Stops me mid-task."*
6	Can't be ignored. Can still go to work and participate in social activities.	*Stronger prescription pain relief needed; works 3-4 hours.*	*"Present all the time. I push through."*
7	Difficult to concentrate; interferes with sleep. Can still function with effort.	*Stronger painkillers only partially effective.*	*"Hard to function. Sleep is disrupted."*
8	Physical activity severely limited. Can read/converse with effort. Nausea possible.	*Strongest painkillers minimally effective.*	*"Mostly bed-bound. May feel nauseated."*
9	Unable to speak. Crying out or moaning uncontrollably. Near delirium.	*Strongest painkillers only partially effective.*	*"Cannot communicate. Losing control."*
10	Unconscious. Pain causes passing out.	*Strongest painkillers only partially effective.*	*"Passed out or on the verge of it."*

Mankoski Pain Scale developed by Andrea Mankoski, 1995. Adapted for patient communication. Not a clinical diagnostic tool.

IMPORTANT NOTE FOR HEDS PATIENTS & PROVIDERS:

People with hEDS often have an altered pain baseline due to central sensitization — a process in which the nervous system becomes increasingly sensitized to pain signals over time.

A '3' for this patient may be what others feel as a '6.'
Please do not compare severity numbers to those of patients without chronic illness.

This scale helps us communicate:
it is not a measure of tolerance, willpower, or how 'bad' things really are.

© 2026 Informed Patient Project. Free for personal use only. Not for resale.