Hypermobile Ehlers-Danlos Syndrome (hEDS)

A Patient Guide for Gastroenterologists

WHAT IS hEDS? hEDS is a heritable disorder of connective tissue, the structural 'glue' of the body, causing joint instability, skin fragility, and systemic effects. Severity varies widely, from mild laxity and intermittent bracing to wheelchair use and complex multisystem involvement.

~1 in 500 people affected	Avg. 10+ years to diagnosis	3:1 to 4:1 diagnosed are female	No cure: management-focused

HOW HEDS AFFECTS THE BODY — SYSTEMIC INVOLVEMENT:

Patient has checked applicable symptoms

Neurological

- ☐ Migraines & headaches
- ☐ Brain fog/cognitive fatigue
- ☐ Small fiber neuropathy
- ☐ Proprioception deficits
- ☐ Anxiety/depression (often neurological in origin)

Gastrointestinal

- ☐ IBS
- ☐ Gastroparesis/ delayed emptying
- ☐ GERD & acid reflux
- ☐ Food intolerances

Cardiovascular

- ☐ POTS — heart rate spikes on standing
- ☐ Blood pooling & dizziness
- ☐ Palpitations

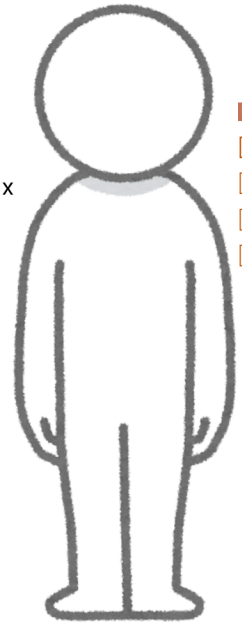

Dermatological

- ☐ Soft, velvety, hyperextensible skin
- ☐ Stretch marks without weight change
- ☐ Easy bruising
- ☐ Poor wound healing

Immune / MCAS

- ☐ MCAS — mast cell overactivation
- ☐ Flushing, hives, itching
- ☐ GI distress & food reactions
- ☐ Chemical/environmental sensitivity

Genitourinary

- ☐ Pelvic floor dysfunction
- ☐ Bladder urgency/frequency
- ☐ Chronic pelvic pain
- ☐ Menstrual irregularities

Fatigue & Sleep

- ☐ Profound fatigue
- ☐ Non-restorative sleep
- ☐ Post-exertional malaise
- ☐ Chronic widespread pain at rest

Musculoskeletal

- ☐ Joint hypermobility & instability
- ☐ Subluxations & dislocations
- ☐ Chronic widespread pain
- ☐ Muscle fatigue & weakness
- ☐ Cervical instability (may contribute to headache, cranial nerve symptoms, or myelopathy)

DO

- Recognize GI dysmotility as a direct manifestation of hEDS; not a coincidental finding
- Investigate beyond IBS: motility studies, gastric emptying scans, and MCAS workup are frequently indicated
- Coordinate with immunology, pain management, and rheumatology
- Consider dietary modification as a first-line intervention alongside pharmacological management
- Validate symptom severity even when endoscopy and colonoscopy are normal
- Monitor for medication sensitivities: MCAS patients react to fillers, dyes, and formulations as well as active ingredients

DON'T

- Diagnose IBS and close the case without investigating motility or structural causes
- Treat GI symptoms in isolation without considering hEDS as the underlying condition
- Assume normal endoscopy rules out significant GI involvement
- Dismiss food reactions as psychosomatic without screening for MCAS and histamine intolerance
- Recommend high-fiber diets without assessing motility: fiber can worsen gastroparesis significantly
- Overlook the role of autonomic dysfunction in GI motility: POTS and gastroparesis frequently coexist
- Attribute GI symptoms to anxiety without ruling out dysmotility and mast cell involvement

CONSIDER / REFER

- Gastric emptying study for suspected gastroparesis
- Antroduodenal manometry or small bowel motility evaluation for complex motility disorders (availability varies; refer to tertiary motility center if indicated)
- Low histamine diet trial for suspected MCAS-driven GI symptoms
- H1/H2 antihistamines and mast cell stabilizers if MCAS is contributing
- Prokinetic agents for gastroparesis: metoclopramide, domperidone, erythromycin
- Dietary referral for low-FODMAP, low-histamine, or gastroparesis-specific diet planning
- Enteral nutrition evaluation if oral intake is insufficient to maintain weight
- Allergy/Immunology referral for formal MCAS workup
- Neurology or cardiology if autonomic dysfunction has not been evaluated
- Pain management for central sensitization driving visceral hypersensitivity

© 2026 Informed Patient Project. Free for personal use only. Not for resale.

GI MANIFESTATIONS IN hEDS — WHY THEY OCCUR

Structural Mechanisms

- Gut wall laxity: Abnormal collagen weakens smooth muscle support, causing dysmotility throughout the GI tract
- Connective tissue fragility: Mesenteric laxity and redundant bowel loops contribute to pain and transit issues
- Enteric nervous system: Autonomic dysfunction (often co occurring POTS) disrupts gastric emptying and motility
- Hiatal laxity: Weakened ligamentous support at the gastroesophageal junction increases reflux
- Pelvic floor dysfunction: Lax pelvic connective tissue causes anorectal and evacuation disorders

Common GI Diagnoses / Presentations

- Gastroparesis/delayed gastric emptying
- GERD and refractory reflux
- IBS-C, IBS-D, or mixed IBS
- Chronic constipation/pelvic outlet dysfunction
- Functional dyspepsia
- Intestinal dysmotility
- Hiatal hernia (often recurrent post-repair)
- Internal rectal intussusception/prolapse
- Post-surgical complications (poor tissue healing)
- SIBO

MAST CELL ACTIVATION SYNDROME (MCAS) & HISTAMINE INTOLERANCE

MCAS is estimated in up to 17-20% of hEDS patients and is a major driver of GI symptoms that may appear functional. Mast cells line the entire GI tract; their inappropriate activation causes direct mucosal inflammation, dysmotility, and hypersensitivity, often with normal standard labs and endoscopic findings.

GI Symptoms of MCAS

- Nausea, vomiting
- Abdominal cramping and pain
- Diarrhea (often sudden onset)
- Bloating and distension
- GI food reactions (not IgE allergy)
- Esophageal spasm
- Oral allergy-like symptoms
- Anaphylaxis-like reactions to foods

Histamine Intolerance

Separate from MCAS but overlapping. Caused by impaired histamine breakdown (DAO enzyme deficiency):

- Worsening after high-histamine foods (aged cheese, wine, fermented food, leftovers)
- GI symptoms 30-60 min after eating
- Headache + GI + flushing together
- Improving on low-histamine diet or antihistamines
- Worsening with DAO inhibitors (alcohol, NSAIDs)

Non-GI Clues for Your Chart

Systemic MCAS signs to note during GI visit:

- Skin flushing, hives, or dermatographia
- Sudden BP drops or near syncope
- Chemical/fragrance sensitivity
- Reactions to temperature changes
- Multiple drug or dye sensitivities
- Worsening pre-menstrually
- Symptom flares without clear cause

MCAS Workup Considerations: Serum tryptase (ideally during reaction), 24h urine prostaglandin D2 and histamine metabolites, and plasma histamine.

Note: standard labs often normal. MCAS is a clinical diagnosis supported by symptom response to H1/H2 antihistamines and mast cell stabilizers (cromolyn sodium, quercetin, ketotifen (compounded in the US). Refer to Allergy/Immunology familiar with MCAS.

COMMON MISDIAGNOSES IN hEDS PATIENTS PRESENTING TO GI

Often Diagnosed As	Consider instead/Also	Key Differentiator
Functional dyspepsia	Gastroparesis + MCAS	Gastric emptying study; antihistamine trial
IBS	hEDS dysmotility + MCAS	Joint hypermobility history; food-reaction pattern
Eating disorder	MCAS/gastroparesis/sensory	GI physiology testing; full hEDS workup
Anxiety/somatization	Autonomic dysfunction (POTS)	Tilt table test; HR on standing
Food allergy (IgE)	Histamine intolerance/MCAS	Normal IgE panel; responds to antihistamines
Rectal prolapse (isolated)	Pelvic connective tissue laxity (hEDS)	Full connective tissue eval; anorectal manometry

© 2026 Informed Patient Project. Free for personal use only. Not for resale.

Beyond IBS: GI Dysmotility and MCAS in hEDS: IBS is a symptom cluster, not a mechanism. In hEDS, GI symptoms have identifiable structural and physiological drivers: abnormal connective tissue affects gut motility directly, autonomic dysfunction slows or disrupts peristalsis, and mast cell overactivation produces inflammation, cramping, and food reactions that mimic and overlap with motility disorders. Diagnosing IBS and closing the case in a patient with hEDS bypasses all of these mechanisms. A gastric emptying study, motility evaluation, and MCAS screening are the appropriate next steps when a patient with hEDS presents with chronic GI symptoms; not a functional label and a high-fiber diet recommendation.

When GI Involvement Becomes a Nutritional Emergency: GI involvement in hEDS exists on a spectrum. At its most severe, gastroparesis and pan-dysmotility can render adequate oral nutrition impossible. Patients at this end of the spectrum face significant malnutrition risk, weight loss, and deteriorating systemic health; all of which amplify every other hEDS symptom including pain, fatigue, and autonomic dysfunction. Enteral feeding via nasogastric or gastrostomy tube is an established intervention for severe gastroparesis and should be considered before the patient reaches a nutritional crisis. Early dietitian involvement, prokinetic trials, and motility-focused dietary planning can delay or prevent the need for enteral support in moderate cases.

MY CURRENT MEDICATIONS & SUPPLEMENTS	WHAT HELPS:
	WHAT MAKES IT WORSE:

WHAT I NEED FROM TODAY'S APPOINTMENT
Referrals needed:
Questions I have:
Medication changes to discuss:
My primary concern today:
Other:

CURRENT SYMPTOM SEVERITY: Complete this section using the Mankoski Pain Scale (pg. 4)
Nausea frequency and severity:
Bowel pattern type (loose, hard, mixed) and frequency:
Food reaction frequency/symptoms:
Abdominal pain severity:
Additional symptoms:

Sources: Malfait et al. 2017 (AJMG) | Tinkle et al. 2017 (AJMG) | Castori et al. 2017 (AJMG) | Afrin et al. 2017 (Immunol Allergy Clin) | ehlers-danlos.com | PMC11390471 | PMC11348541

This document was created to provide a GI-focused clinical reference for providers less familiar with hEDS.
GI involvement in this condition has identifiable physiological drivers that this reference is designed to make quickly accessible.

© 2026 Informed Patient Project. Free for personal use only. Not for resale.

MANKOSKI PAIN SCALE

Use this scale when rating your pain severity in CURRENT SYMPTOM SEVERITY

#	What the pain is like	Typical treatment	In my own words
0	No pain.	*No medication needed.*	*"I feel completely normal."*
1	Very minor annoyance — occasional minor twinges.	*No medication needed.*	*"Hardly notice it."*
2	Minor annoyance — occasional strong twinges.	*No medication needed.*	*"Annoying but manageable."*
3	Annoying enough to be distracting.	*Mild OTC painkillers may help.*	*"Hard to ignore; affects my focus."*
4	Can be ignored if very focused, but still distracting.	*Mild OTC painkillers relieve pain for 3-4 hours.*	*"Getting in the way of tasks."*
5	Can't be ignored for more than 30 minutes.	*Mild OTC painkillers reduce pain for 3-4 hours.*	*"Stops me mid-task."*
6	Can't be ignored. Can still go to work and participate in social activities.	*Stronger prescription pain relief needed; works 3-4 hours.*	*"Present all the time. I push through."*
7	Difficult to concentrate; interferes with sleep. Can still function with effort.	*Stronger painkillers only partially effective.*	*"Hard to function. Sleep is disrupted."*
8	Physical activity severely limited. Can read/converse with effort. Nausea possible.	*Strongest painkillers minimally effective.*	*"Mostly bed-bound. May feel nauseated."*
9	Unable to speak. Crying out or moaning uncontrollably. Near delirium.	*Strongest painkillers only partially effective.*	*"Cannot communicate. Losing control."*
10	Unconscious. Pain causes passing out.	*Strongest painkillers only partially effective.*	*"Passed out or on the verge of it."*

Mankoski Pain Scale developed by Andrea Mankoski, 1995. Adapted for patient communication. Not a clinical diagnostic tool.

IMPORTANT NOTE FOR HEDS PATIENTS & PROVIDERS:

People with hEDS often have an altered pain baseline due to central sensitization — a process in which the nervous system becomes increasingly sensitized to pain signals over time.

A '3' for this patient may be what others feel as a '6.'
Please do not compare severity numbers to those of patients without chronic illness.

This scale helps us communicate:
it is not a measure of tolerance, willpower, or how 'bad' things really are.

© 2026 Informed Patient Project. Free for personal use only. Not for resale.