Rickets

13

Definition

Rickets is a generalized metabolic bone disorder, characterized by a failure of, or delay in mineralization of growing bones, occurring in children before fusion of the epiphysis. The disease results typically from an inadequate supply of calcium (calcipenic rickets) or phosphate (phosphopenic rickets) to the zone of provisional calcification at the growth plate, and at the newly formed osteoid surface **(Table 1)**. Nutritional deficiency, due to deficiency of vitamin D and/or calcium is the most common cause of rickets.

Classification

TABLE 1: Classification of rickets.

Calcipenic	***Phosphopenic***
Nutritional calcipenic rickets: ☑ Vitamin D deficiency – Maternal and or nutritional vitamin D deficiency – Reduced skin synthesis of vitamin D—sunlight deprivation, sunscreen use, and increased skin pigmentation – Malabsorption—celiac disease, hepatobiliary disease, and inflammatory bowel disease – Drugs—anticonvulsants and glucocorticoids – Obesity ☑ Calcium deficiency – Nutritional deficiency *Non-nutritional calcipenic rickets:* ☑ Inborn errors of vitamin D metabolism—deficiency of 1-α hydroxylase [vitamin D-dependent ricket (VDDR) type 1] and loss of function mutation of vitamin D receptor (VDDR type 2) ☑ Distal renal tubular acidosis (RTA)	*Renal tubular disorders:* ☑ Increased renal phosphate wasting (FGF-23 dependent) – Hereditary hypophosphatemic rickets (HHR): XLD, AD, and AR – *Acquired:* McCune-Albright syndrome, tumor-induced osteomalacia, and linear nevus sebaceous syndrome ☑ Primary defect in renal phosphate absorption (FGF-23 independent) – Proximal tubular dysfunction: Fanconi syndrome, cystinosis, tyrosinemia, and galactosemia – Hereditary hypophosphatemic rickets with hypercalciuria (HHRH) *Dietary phosphate deficiency:* ☑ Prematurity ☑ Antacids (aluminum containing)

Clinical Features

Clinical features of rickets vary with the severity of the disease and the child's age (**Table 2**). Neonates and young infants usually present with hypocalcemic seizures while skeletal signs are seen in latter half of infancy and toddlers. Muscle cramps and tetany occur more frequently in adolescent age group. Short stature and deformities of lower limbs and pelvis may develop in long-standing cases. Children with hypophosphatemic rickets usually present with vague symptoms of weakness, fatigue, bone pain, and lower limb deformities.

TABLE 2: Clinical features of rickets.

Symptoms	***Signs***	
Infants <6 months—hypocalcemic seizures	Skull	Craniotabes (early sign), frontal bossing, caput quadratum, and delayed closure of anterior fontanelle
Older children—delay in achieving gross motor milestone and skeletal deformities	Teeth	Delayed eruption and enamel hypoplasia
	Thorax	Rachitic rosary, pigeon chest/pectus carinatum, and Harrison groove
Adolescents—lower limb pains, carpopedal spasms, and knock knees	Extremities	Arms—wrist widening Leg—genu varum, genu valgum, saber shin deformity, green stick fractures, and wind-swept deformity Ankle—double malleolus
	Ligaments and muscles	Laxity and decreased tone and myopathy
	Spine	Kyphoscoliosis (>2 years vertebral softening)

Approach

- ☑ Specific features in history and examination that provide clues towards the etiology of rickets are given on the next page. Investigations should begin with basic biochemistry (calcium, phosphate, albumin, alkaline phosphatase, and creatinine).
- ☑ Nutritional rickets is diagnosed on the basis of history, examination, and supportive biochemistry, and is confirmed by radiographs.
- ☑ Serum parathyroid hormone (PTH), 25(OH)D, and 1,25 di$(OH)_2$D are not needed in a usual case of nutritional rickets. The expected changes in blood and urine biochemistry in different etiology of rickets is given in **Table 3**.

Approach to a Child with Rickets

History and Examination

History	Examination
☑ Dietary intake, especially milk and dairy products, and sun exposure	☑ Anthropometry (weight and height)
☑ Anticonvulsants/drugs	☑ Signs of vitamin deficiency and rachitic deformities
☑ Hepatic/renal disease/malabsorption	☑ Hair/teeth
☑ Prematurity	☑ Trousseau sign (carpopedal spasm)
☑ Antenatal history of poly or oligohydramnios, history of polyuria, polydipsia, and failure to thrive with muscular weakness—RTA	☑ Milia, epidermal cysts, and alopecia—VDDR type 2
☑ Parental consanguinity and similar involvement in siblings—inherited disorders	☑ Anemia, hypertension, and short stature—chronic renal disease
☑ Enquire into previous administration of calcium/vitamin D	☑ Jaundice, edema, and hepatosplenomegaly—chronic liver disease
	☑ Systemic examination including muscle power

Biochemical Investigations

First line:

- ☑ Serum calcium (no tourniquet), phosphorus, alkaline phosphatase, creatinine, and albumin—all fasting samples
- ☑ Liver and kidney functions (if clinically indicated)

In non-nutritional cases:

- ☑ Venous blood gas
- ☑ Serum PTH, 25(OH)D, and 1,25$(OH)_2$D
- ☑ Urinary calcium/creatinine ratio (spot or 24 hours urine sample)
- ☑ Tubular reabsorption of phosphate (morning spot urinary sample and simultaneous fasting serum sample)

$FE(PO_4^-) = [\text{Urine } PO_4^- \times \text{Serum creatinine}/\text{Serum } PO_4^- \times \text{Urine creatinine}] \times 100$

Tubular reabsorption of phosphate (TRP) = 100 – $FE(PO_4^-)$ [normal 85–95%]

Radiology

- ☑ X-ray wrist and or knee—widening of the growth plate, generalized osteopenia, and metaphysis show cupping, splaying, and fraying
- ☑ Renal USG—nephrocalcinosis

(RTA: renal tubular acidosis; USG: ultrasonography; VDDR: vitamin D-dependent ricket)

Approach to a Child with Rickets

TABLE 3: Summary of the biochemical features in different forms of rickets.

Disorder	*Ca*	*Pi*	*ALP*	*PTH*	*25-OHD*	*1,25-(OH)$_2$D*	*Urine Ca*	*Urine Pi*
Vitamin D deficiency	N, ↓	↓	↑	↑	↓	↓, N, ↑	↓	↑
Dietary Ca deficiency	N, ↓	↓	↑	↑	N, ↓	↑	↓	↑
VDDR, type 1	N, ↓	↓	↑	↑	N	↓	↓	↑
VDDR, type 2	N, ↓	↓	↑	↑	N	↑↑	↓	↑
Chronic renal failure	N, ↓	↑	↑	↑	N	↓	N, ↓	↓
XLH and ADHR	N	↓	↑	N	N	↓, N	↓	↑
HHRH	N	↓	↑	N	N	N, ↑	↑	↑
Fanconi syndrome	N	↓	↑	N	N	N, ↑	↓ or ↑	↑

(ADHR: autosomal dominant hypophosphatemic rickets; ALP: alkaline phosphatase; Ca: calcium; HHRH: hereditary hypophosphatemic rickets with hypercalciuria; Pi: phosphorus; PTH: parathyroid hormone; VDDR: vitamin D-dependent rickets; XLH: X-linked hypophosphatemic rickets; 25-OHD: 25-hydroxyvitamin D; 1,25-(OH)2D: 1,25-dihydroxyvitamin D; N: normal; ↓: decreased; ↑: increased)

Management of Nutritional Rickets

Flowchart 1: Management of nutritional rickets.

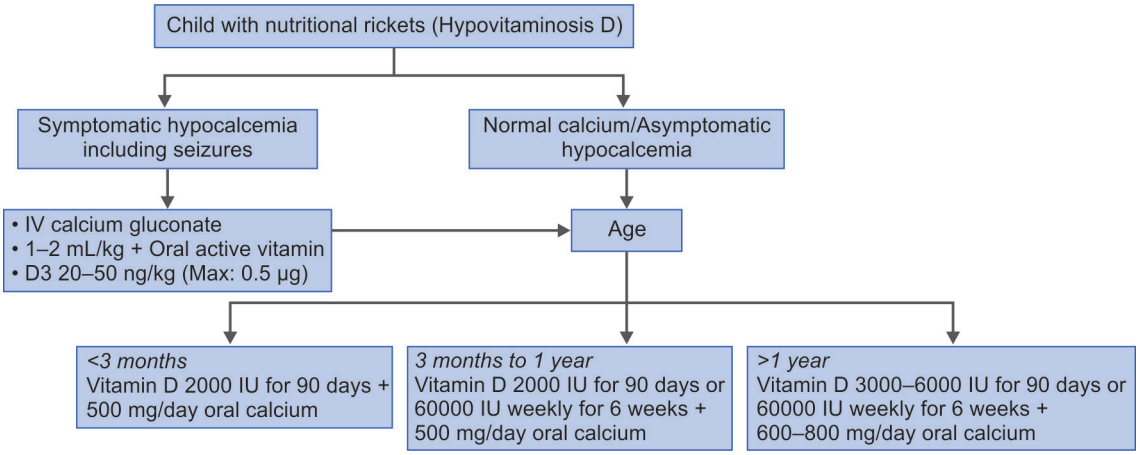

Management of Nutritional Rickets

TABLE 5: Management of non-nutritional rickets.

Condition	***Management***
Hypophosphatemic rickets	Oral phosphorous 35–75 mg/kg/day and oral calcitriol 20–40 ng/kg/day
Vitamin D-dependent rickets type 1 (VDDR 1)	Calcitriol 150–200 ng/kg/day and oral calcium (30–75 mg/kg/day)
Vitamin D-dependent rickets type 2 (VDDR 2)	Very high doses of calcitriol (1–6 µg per day) and intravenous calcium or high dose calcium (150–200 mg/kg/day)

Practical Aspects to Note

- ☑ Vitamin D replacement refers to 25-hydroxycholecalciferol. 1,25-dihydroxycholecalciferol is indicated in non-nutritional rickets, chronic kidney disease, and hypoparathyroidism and in a case of nutritional rickets in a symptomatic child with severe hypocalcemic convulsions/ cardiomyopathy.
- ☑ Mega oral or parenteral vitamin D replacement using the stoss regimen is best avoided to prevent hypercalcemia and hypercalciuria, especially under the age of 3 months.
- ☑ Vitamin D replacement is unrelated to the meal timings.
- ☑ Check the dose and strength of the preparation to avoid toxicity.
- ☑ Vitamin D replacement should be followed by maintenance doses of vitamin D.
- ☑ Calcium supplementation is mandatory along with vitamin D replacement.
- ☑ Consider non-nutritional rickets if there is no clinical, biochemical, or radiological improvement after 3 months of vitamin D replacement and malabsorption has been ruled out.
- ☑ Calcium carbonate has maximum bioavailability (40%). Calcium citrate can be taken without food and calcium carbonate should be taken with food.

Vitamin D Intoxication

- ☑ Polydipsia, polyuria, hypotonia, abdominal pain, poor feeding, nausea, vomiting, and lethargy suggest vitamin D toxicity. 25 hydroxy vitamin D levels > 100 ng/mL in a symptomatic child suggest vitamin D intoxication.
- ☑ Biochemical testing may reveal suppressed parathormone levels, elevated serum calcium (serum calcium above 10.5 mg/dL), hypercalciuria, and nephrocalcinosis.
- ☑ Management includes stoppage of vitamin D preparation, hydration of the child and diuretic therapy, steroids, and rarely bisphosphonates.

Prevention

Pediatricians should ensure that infants and children and high-risk individuals receive adequate supplementation to prevent the occurrence of rickets **(Table 6)**.

TABLE 6: Daily preventive supplementation for rickets.

	Age group	*Daily preventive supplementation*
1	Preterm baby	400 IU of vitamin D[b] along with oral calcium 150–200 mg/kg/day and oral phosphorous at 75–140 mg/kg/day
2	Neonates (0–30 days)	400 IU of vitamin D[b]
3	Breastfed infants	400 IU of vitamin D[b]
4	Formula fed infants	400 IU of vitamin D[b]
5	1–18 years	600 IU of vitamin D[b]
6	High-risk groups[a]	400–1,000 IU of vitamin D[b]
7	Pregnant and lactating mothers	600 IU of vitamin D[b]

[a]Children with obesity, liver disease, renal disease, antiepileptic medication, malignancy, hypogonadism, osteoporosis, and Cushing's disease

[b]Vitamin D refers to 25-hydroxycholecalciferol

Sunlight Exposure

There are no universally acceptable guidelines on sunlight exposure in children. There is sufficient Indian data to support the utility of casual midday sunlight exposure (10 AM to 3 PM) resulting in appropriate UVB exposure to produce adequate vitamin D production, reduced hypovitaminosis D, and rickets without vitamin D toxicity. The ideal duration of exposure should be individualized based on age, clothing, and skin pigmentation. All the recommendations made in the **Table 6** are based on minimum sunshine exposure.

Further Reading

- ☑ Balasubramanian S, Dhanalakshmi K, Amperayani S. Vitamin D deficiency in childhood—a review of current guidelines on diagnosis and management. Indian Pediatr. 2013;50(7):669-75.
- ☑ Ekbote VH, Khadilkar AV, Mughal MZ, Hanumante N, Sanwalka N, Khadilkar VV, et al Sunlight exposure and development of rickets in Indian toddlers Indian J Pediatr. 2010;77:61-5.
- ☑ Khadilkar A, Khadilkar V, Chinnappa J, Rathi N, Khadgawat R, Balasubramanian S, et al. Prevention and Treatment of Vitamin D and Calcium Deficiency in Children and Adolescents: Indian Academy of Pediatrics (IAP) Guidelines. Indian Pediatr. 2017;54:567-73.
- ☑ Munns CF, Shaw N, Kiely M, Specker BL, Thacher TD, Ozono K, et al. Global Consensus Recommendations on Prevention and Management of Nutritional Rickets. J Clin Endocrinol Metab. 2016;101(2):394-415.
- ☑ Patwardhan VG, Mughal ZM, Chiplonkar SA, Webb AR, Kift R, Khadilkar VV, et al. Duration of casual sunlight exposure necessary for adequate vitamin D status in Indian Men. Indian J Endocrinol Metab. 2018;22:249-55.
- ☑ Specker BL, Valanis B, Hertzberg V, Edwards N, Tsang RC. Sunshine exposure and serum 25-hydroxy vitamin D concentrations in exclusively breastfed infants. J Pediatr. 1985;107:372-6.

Indian Academy of Pediatrics (IAP)

STANDARD TREATMENT GUIDELINES 2022

Allergic Rhinitis

Lead Author
H Paramesh

Co-Authors
Narayan Modi, Nayan Moni Deka

Under the Auspices of the IAP Action Plan 2022

Remesh Kumar R
IAP President 2022

Upendra Kinjawadekar
IAP President-Elect 2022

Piyush Gupta
IAP President 2021

Vineet Saxena
IAP HSG 2022–2023

INDIAN ACADEMY OF PEDIATRICS

© Indian Academy of Pediatrics

IAP Standard Treatment Guidelines Committee

Chairperson

Remesh Kumar R

IAP Coordinator

Vineet Saxena

National Coordinators

SS Kamath, Vinod H Ratageri

Member Secretaries

Krishna Mohan R, Vishnu Mohan PT

Members

Santanu Deb, Surender Singh Bisht, Prashant Kariya, Narmada Ashok, Pawan Kalyan