26

Acute Rheumatic Fever

Introduction and Definition

- ☑ Acute rheumatic fever (ARhF), once a common acquired cardiac disease, is rarely seen these days.
- ☑ Considerable evidence supports the link between antecedent group A *Streptococcus* (GAS) pharyngitis and ARhF and rheumatic heart disease.
- ☑ Concept of rheumatogenicity has evolved meaning certain strains which include M types 1, 3, 5, 6, 14, 18, 19, 24, 27, and 29, and certain populations with increased genetic susceptibility such as polymorphisms of interferon-γ (IFN-γ), angiotensin-converting enzyme (ACE), FCN, FcγRIIA, toll-like receptor 2 (TLR-2), and human leukocyte antigen (HLA) can explain why rheumatic fever occurs specifically in certain individuals.
- ☑ Immune-mediated pathogenesis has been suggested.
- ☑ It is characterized by presence of modified Jones criteria proposed by the American Heart Association (AHA).

Clinical Features

Five major and four minor criteria which are representative of evidence of recent GAS infection are proposed as clinical manifestations **(Table 1)**. A detailed description of the qualifying features of the major criteria is described in **Table 2**.

TABLE 1: Modified Jones criteria, American Heart Association (AHA), 2015.

Major manifestation	***Minor manifestation***	***Supporting evidence of antecedent group streptococcal infection***
☑ Carditis ☑ Polyarthritis ☑ Erythema marginatum ☑ Subcutaneous nodule ☑ Chorea	*Clinical features* ☑ Arthralgia ☑ Fever *Laboratory features* ☑ Elevated acute phase reactants ☑ Erythrocyte sedimentation arte ☑ C-reactive protein ☑ Prolonged P-R interval	☑ Positive throat culture or rapid antigen test ☑ Elevated or increasing streptococcal antibody titer

TABLE 2: Description of the major criteria.

Arthritis	☑ Migratory ☑ Involves large joints (involvement of the spine, small joints of the hand, feet, and hip is uncommon) ☑ Extremely tender ☑ Dramatic response to salicylate ☑ Never deforming ☑ Inverse relationship between the severity of carditis and arthritis
Carditis	☑ Subclinical carditis where only echocardiographic evidence is present ☑ Clinical carditis (valvulitis—murmur) ☑ Pancarditis ☑ Cardiac involvement is variable from mild to severe ☑ Endocardial involvement is a must ☑ Mitral and aortic valve involvement is common ☑ Right-side valve involvement in isolation is rare
Chorea	☑ Movement disorder ☑ Associated with emotional liability and poor coordination ☑ Poor school performance ☑ Long latent period from onset of the disease ☑ Antibody may not be positive due to long latent period
Erythema marginatum	☑ Rare to see ☑ Characteristic rash of rheumatic fever (RF) ☑ Erythematous, serpiginous, and macular lesions with pale centers ☑ Nonpruritic ☑ Involves trunk and extremities, spares the face
Subcutaneous nodules	☑ Rare ☑ Firm nodules along the extensor surfaces of tendons near bony prominence ☑ Correlated with cardiac involvement

Diagnosis

There is no specific diagnostic test for rheumatic fever. The clinical diagnosis of the condition is done based on features in low-risk and high-risk population (AHA, 2015) **(Table 3)**.

TABLE 3: Diagnosis of rheumatic fever based on revised Jones criteria updated in 2015.

	Low-risk populations (incidence of ARhF ≤ 2/100,000 school-aged children or prevalence of RHD ≤1/1,000 population per year)	**Moderate- and high-risk populations** (incidence of ARhF > 2/100,000 school-aged children or prevalence of RHD >1/1,000 population per year)
A. Major clinical manifestations	*Carditis:* Clinical and/or subclinical (echocardiographic valvulitis)	*Carditis:* Clinical and/or subclinical (echocardiographic valvulitis)
	Arthritis: Polyarthritis only	*Arthritis:* Monoarthritis or polyarthritis or polyarthralgia
	Chorea	Chorea
	Erythema marginatum	Erythema marginatum
	Subcutaneous nodules	Subcutaneous nodules
B. Minor clinical manifestations	Polyarthralgia	Monoarthralgia
	Fever (≥38.5°C)	Fever (≥38°C)
	Raised ESR (≥ 60 mm in the first hour) and/or CRP (≥3 mg/dL)	Raised ESR (≥ 30 mm in the first hour) and/or CRP (≥3 mg/dL)
	Prolonged PR interval	Prolonged PR interval
C. Supportive evidence of antecedent GAS infection	Positive throat culture or rapid streptococcal antigen test or elevated streptococcal antibody titer	
Diagnosis of initial attack of ARhF	Two major manifestations or one major plus two minor manifestations plus supportive evidence of antecedent GAS infection	
Diagnosis of recurrent attack of ARhF	Two major manifestations or one major plus two minor manifestations or three minor manifestations plus supportive evidence of antecedent GAS infection	

(ARhF: acute rheumatic fever; CRP: C-reactive protein; ESR: erythrocyte sedimentation rate; GAS: group A *Streptococcus*; RHD: rheumatic heart disease)

Diagnosis

Conditions where Jones criteria cannot be strictly applied: Indolent carditis, when chorea is the only major manifestation and in some cases with recurrent attack of rheumatic fever.

Echocardiography is an important tool to confirm cardiac involvement in ARhF.

The following are the echocardiographic criteria developed by the AHA in 2012:

☑ *Doppler criteria:*

- Pathological mitral regurgitation—four criteria (all must be met):
  - Visible at least in two projections
  - Regurgitation jet length ≥ 2 cm at least in one projection
  - Regurgitation peak velocity > 3 m/s.
  - Regurgitation pansystolic
- Pathological aortic regurgitation—four criteria (all must be met):
  - Visible at least in two projections
  - Regurgitation jet length ≥ 1 cm at least in one projection
  - Regurgitation peak velocity > 3 m/s.
  - Regurgitation pandiastolic

☑ *Morphological criteria:*

- In acute mitral valve involvement:
  - Dilatation of mitral annulus
  - Elongation of chordae tendineae
  - Rupture of chorda tendineae with acute mitral regurgitation
  - Prolapse of anterior (less often posterior) leaflet
  - Nodular lesions on leaflets
- In chronic mitral valve involvement (invisible in acute involvement):
  - Thickening of leaflets
  - Thickening of chordae tendineae with their fusion
  - Limited mobility of leaflets
  - Calcifications
- Lesions in acute and chronic aortic valve involvement:
  - Symmetrical or focal thickening of leaflets
  - Disturbed leaflet coaptation (leaflet closing during systole)
  - Limited mobility of leaflets
  - Prolapse of leaflets.

Treatment of Rheumatic Fever

The treatment has not changed in the last few decades and consists of mainly antistreptococcal and anti-inflammatory therapy. **Flowchart 1** shows the main management principles.

Flowchart 1: Treatment algorithm.

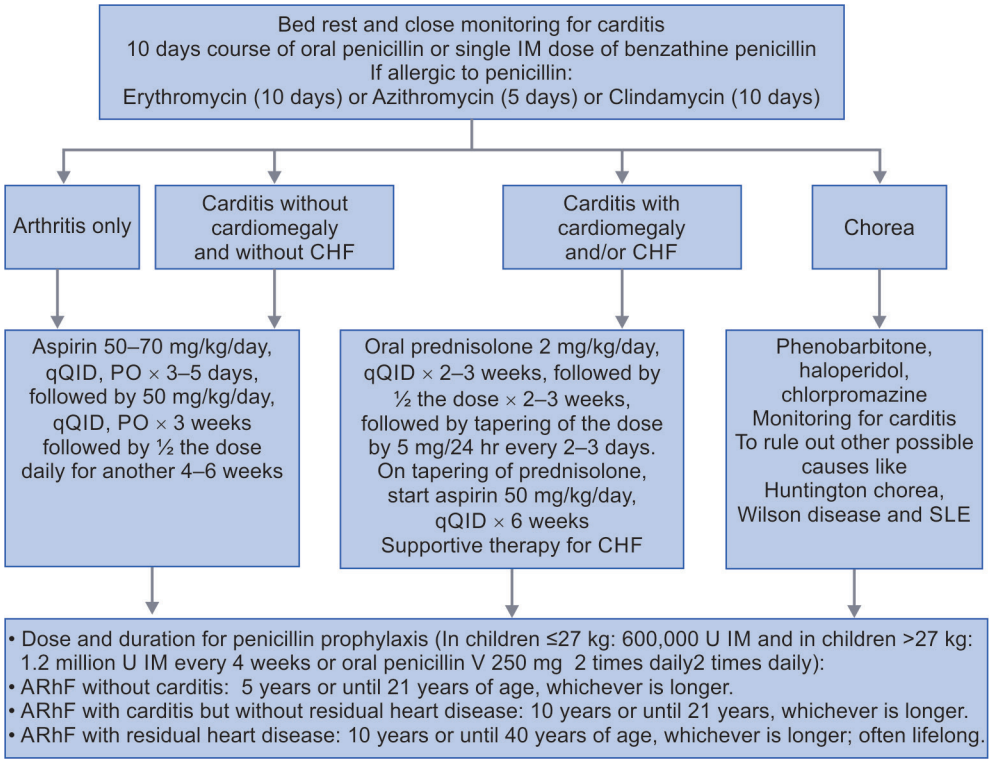

(ARhF: acute rheumatic fever; CHF: congestive heart failure; SLE: systemic lupus erythematosus; PO: per oral; IM: intramuscular)

Further Reading

- ☑ Baker MG, Gurney J, Oliver J, Moreland NJ, Williamson DA, Pierse N, et al. Risk factors for acute rheumatic fever: literature review and protocol for a case-control study in New Zealand. Int J Environres Public Health. 2019;16(22):4515.
- ☑ Gewitz MH, Baltimore RS, LY Tani, Sable CA, Shulman ST, Carapetis J, et al. Revision of the Jones criteria for the diagnosis of acute rheumatic fever in the era of Doppler echocardiography. Circulation. 2015;131:1806-18.
- ☑ Shulman ST, Reuter CH. Rheumatic fever. In: Kliegman RM, Geme III JWS, Blum NJ, Shah SS, Taskar RC, Wilson KM (Eds). Nelson's Textbook of Pediatrics. Philadelphia: Elsevier Saunders Company, Philadelphia; 2020. pp. 1445-50.
- ☑ Szczygielska I, Hernik E, Kolodziejczyk B, Gazda A, Maślińska M, Gietka P. Rheumatic fever: new diagnostic criteria. Reumatologia. 2018:56(1):37-41.

Indian Academy of Pediatrics (IAP)

STANDARD TREATMENT GUIDELINES 2022

Childhood Obesity

Lead Author

Anurag Bajpai

Co-Authors

Mohan T Shenoy, Prachi Karia-Shah

Under the Auspices of the IAP Action Plan 2022

Remesh Kumar R
IAP President 2022

Upendra Kinjawadekar
IAP President-Elect 2022

Piyush Gupta
IAP President 2021

Vineet Saxena
IAP HSG 2022–2023

© Indian Academy of Pediatrics

IAP Standard Treatment Guidelines Committee

Chairperson

Remesh Kumar R

IAP Coordinator

Vineet Saxena

National Coordinators

SS Kamath, Vinod H Ratageri

Member Secretaries

Krishna Mohan R, Vishnu Mohan PT

Members

Santanu Deb, Surender Singh Bisht, Prashant Kariya, Narmada Ashok, Pawan Kalyan