Clinical Manifestations

Skin

The typical cutaneous rash of HSP is of palpable purpura distributed predominantly over the extensor and dependent parts of the lower extremity and buttocks with usual sparing of the trunk.

Gastrointestinal (GI) vasculitis

GIT involvement can occur in 50% to 70% of cases in the form of gastritis, duodenitis, purpura, GI bleeding (manifesting as overt bleeding or stool positive for occult blood), and intussusception (detected by ultrasound abdomen).

Joint involvement

Arthralgia or arthritis occurs in up to 82% of children with HSP, primarily affecting large joints of lower limbs.

IgAV Nephritis

The incidence of nephritis is 20–80%. The majority (97–100%) manifest in the first 6 months, and the overall prognosis is good. The most common clinical presentation is hematuria with or without proteinuria. Acute nephritic syndrome, nephrotic syndrome, or both are other renal manifestations.

Risk factors for the development of IgAV nephritis: (a) Age at onset more than 7 years, (b) rash for more than 4 weeks, (c) severe GI symptoms, and (d) low factor XIII activity.

TABLE 2: Definitions of severity of IgAV nephritis.

Severity of IgAV nephritis	***Definition***
Mild	Normal GFR and mild or moderate proteinuria
Moderate	<50% crescents on renal biopsy and impaired GFR or severe persistent proteinuria
Severe	>50% crescents on renal biopsy and impaired GFR or severe persistent proteinuria
Persistent proteinuria	☑ UP/UC ratio >250 mg/mmol for 4 weeks ☑ UP/UC ratio >100 mg/mmol for 3 months ☑ UP/UC ratio >50 mg/mmol for 6 months

(GFR: glomerular filtration rate; UP/UC: spot urine protein to creatinine ratio)

A kidney biopsy may not be required for mild nephritis. But, a Pediatric Nephrologist should be involved in cases with moderate/severe/persistent proteinuria and/or deranged eGFR.

Atypical IgA Vasculitis

- ☑ It is characterized by atypical skin lesions such as hemorrhagic bullae and vesicles. Management is akin to classical HSP and does not bear a worse prognosis.
- ☑ Neurological involvement (headache, mild encephalopathy) and pulmonary features such as diffuse alveolar hemorrhage are rare.

Diagnosis

It is a clinical diagnosis **(Table 1)**. Skin biopsy is usually not required in typical HSP, but is recommended in atypical skin lesions, extensive lesions up to the trunk and upper limbs, and exclude other types of vasculitis such as ANCA-associated vasculitis. In addition, all children with IgAV should be evaluated for kidney involvement **(Flowchart 1)**. Therefore, it is vital to measure the child's blood pressure at the time of presentation of HSP and later into the follow-up for early pick up of renal hypertension. Though hypertension usually manifests along with renal involvement, occasionally, it may be an isolated finding. In such situations, if it doesn't settle as HSP resolves, further investigations are warranted.

Flowchart 1: Clinical evaluation of IgAV for nephritis.

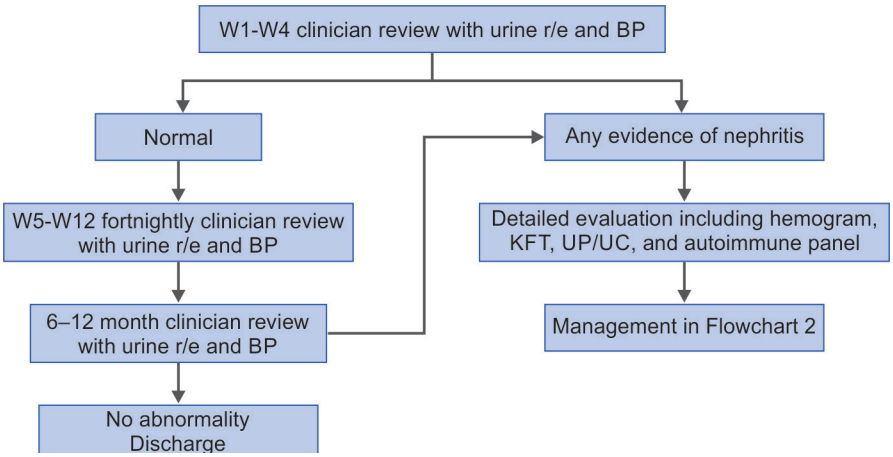

(W1-W4: week 1 to week 4; KFT: kidney function test)

Source: Modified from Tizard EJ, Hamilton-Ayres MJ. Henoch-Schönlein purpura. Arch Dis Child Educ Pract Ed. 2008;93(1):1-8.

Treatment

Clinical presentation	***Treatment***
Typical IgAV	
1. Purpura + arthritis	Supportive treatment, NSAIDs can be given with normal KFT
2. GI vasculitis/nephritis/orchitis/cerebral vasculitis/pulmonary hemorrhage a. Mild-to-moderate cases b. Severe cases (cerebral/pulmonary/GI) c. Organ/life-threatening involvement	Steroids Oral steroids @1 mg/kg/day with gradual tapering IV pulse MP @10 to 30 mg/kg/d f/day oral steroids @ 1 mg/kg/day with gradual tapering* Addition of cytotoxic DMARDs or plasma exchange*
Atypical IgAV	
a. Hemorrhagic bullae	Supportive, adequate analgesia, oral steroids effective

*Expert opinion from Pediatric Rheumatologist
(NSAIDs: nonsteroidal anti-inflammatory drugs; DMARDs: disease-modifying anti-rheumatic drugs)

Flowchart 2: Recommendations for the treatment of IgAV nephritis.

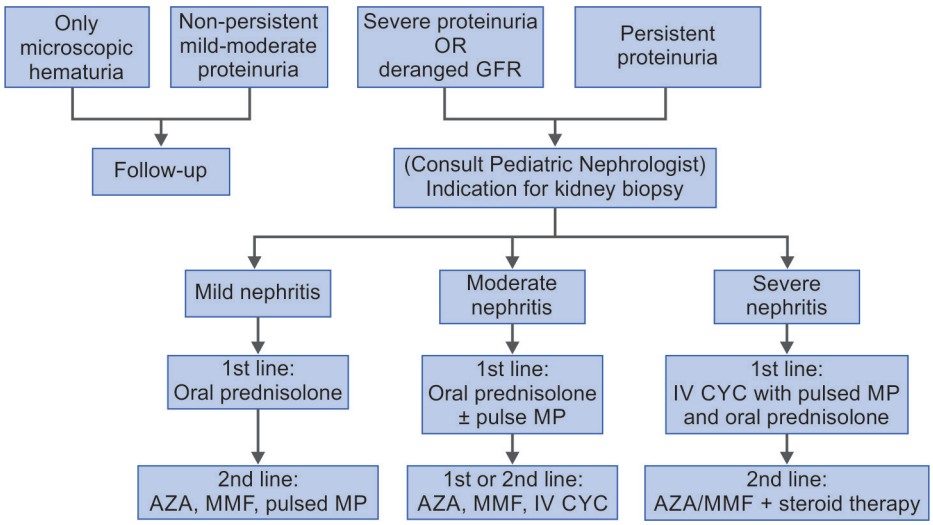

(IV: intravenous; MP: methylprednisolone; CYC: cyclophosphamide; AZA: azathioprine; MMF: mycophenolate mofetil; ACE: angiotensin-converting enzyme)

Prognosis

Though HSP is a self-limiting disease, long-term morbidity is primarily related to renal involvement. Clinical presentation such as nephrotic syndrome, renal impairment, hypertension, and decreased factor XIII at presentation are correlated with a poor prognosis. In addition, recurrence of HSP is known to occur in approximately one-third of affected children.

Further Reading

- ☑ de la Hoz JA, Antequera CE, Manso BF, Otones LL, de Inocencio Arocena J. Hemorrhagic bullous IgA vasculitis (Schönlein-Henoch purpura), does it have a worse prognosis? Reumatología Clínica (English Edition); 2021.
- ☑ Ozen S, Marks SD, Brogan P, Groot N, de Graeff N, Avcin T, Bader-Meunier B, Dolezalova P, Feldman BM, Kone-Paut I, Lahdenne P. European consensus-based recommendations for diagnosis and treatment of immunoglobulin A vasculitis—the SHARE initiative. Rheumatology. 2019;58(9): 1607-16.
- ☑ Ting TV. Diagnosis and management of cutaneous vasculitis in children. Pediatr Clin. 2014;61(2): 321-46.
- ☑ Tizard EJ, Hamilton-Ayres MJ. Henoch–Schönlein purpura. Arch Dis Child Educ Pract Ed. 2008; 93(1):1-8.

Indian Academy of Pediatrics (IAP)

STANDARD TREATMENT GUIDELINES 2022

Growing Pains

Lead Author
Rakesh Mondal

Co-Authors
Anand P Rao, Suma Balan

Under the Auspices of the IAP Action Plan 2022

Remesh Kumar R
IAP President 2022

Upendra Kinjawadekar
IAP President-Elect 2022

Piyush Gupta
IAP President 2021

Vineet Saxena
IAP HSG 2022–2023

© Indian Academy of Pediatrics

IAP Standard Treatment Guidelines Committee

Chairperson

Remesh Kumar R

IAP Coordinator

Vineet Saxena

National Coordinators

SS Kamath, Vinod H Ratageri

Member Secretaries

Krishna Mohan R, Vishnu Mohan PT

Members

Santanu Deb, Surender Singh Bisht, Prashant Kariya, Narmada Ashok, Pawan Kalyan