Varicella

50

Introduction

- ☑ Varicella-zoster virus (VZV) is a double-stranded deoxyribonucleic acid (DNA) virus that belongs to the *Herpesviridae* family of eight herpes viruses.
- ☑ Primary infection with VZV causes varicella (chickenpox).
- ☑ After primary infection, the VZV resides in sensory nerve ganglia as latent infection.
- ☑ Reactivation of latent infection results in herpes-zoster (shingles).
- ☑ Enveloped virus contains double-stranded DNA encoding 71 proteins, which are targets for host cellular and humoral immunity.

Epidemiological Factors

Young infants <1 year, adults, and immunocompromised are more susceptible to varicella complications.

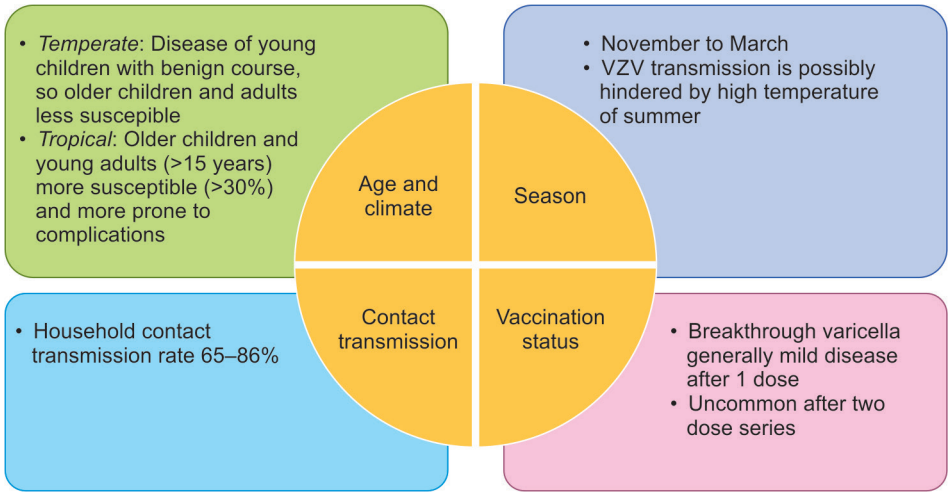

Pathogenesis

Inoculation into mucosa of upper respiratory tract and conjunctiva → Replication in local lymphoid tissue spreading through T lymphocytes causing viremia (incubation period 10–21 days) → **Onset of illness**
Young children: Mild or no prodrome precedes onset of rash
Older children and adults: Fever (38–39°C), malaise, anorexia, headache, occasionally mild abdominal pain precede rash by 1–2 days

Clinical Features

- Rashes first appear on scalp, face, and trunk then spreads to extremities (centripetal to centrifugal spread)
- Extensive rash may occur in adults and children with skin disorders (eczema)
- Initially macule (1–4 mm) and rapid progression to papule then to vesicle and finally crusting
- Healthy children have 250–500 lesions in 2–4 successive crops
- Vesicles with clear fluid on erythematous base
- Pruritic, pleomorphic rash simultaneous presence of lesion in various stages of evolution
- Skin lesions may also appear in oral mucosa, pharynx, conjunctiva, cornea, and genitalia

Fever subsides → Innate immunity overcomes skin infection → Adaptive host immunity (cellular) limit viral replication and recovery → Latent infection → VZV transported in retrograde manner through sensory axons to the dorsal root ganglion of spinal cord and cranial nerves → Reactivation at older age to herpes zoster

Other Forms of Varicella

- ☑ **Breakthrough varicella** causes atypical, predominantly maculopapular rashes, and milder form of illness, it may occur after complete vaccination but more commonly after one dose (successful immunization program in Western world have widely reduced infections of wild type VZV).
- ☑ **Immunocompromised individuals** develop progressive varicella with extensive vesicular/hemorrhagic rash, high fever, disseminated disease in 36% and complications such as pneumonia and encephalitis.
- ☑ **Congenital varicella** maternal varicella infection in first 20 weeks of gestation occasionally results in hypoplasia of an extremity, skin scarring, localized muscular atrophy, cortical atrophy, chorioretinitis, microcephaly, and low birth weight. The risk of congenital abnormality is very low (<2%).
- ☑ **Congenital varicella syndrome**:

Period of gestation	*% of infection*
<13 weeks	0.4%
13–20 weeks	2%
>20 weeks	Rare

- ☑ **Neonatal varicella:** Primary maternal varicella infection 5 days prior to delivery and 2 days afterward, results in transplacental transmission of maternal viremia to fetus (maternal antibody response is yet to be developed), high risk of fatal disseminated disease, rash appears first to second week of life.

Complications

- ☑ **Mild thrombocytopenia (1–2%):** Rarely complicated with hemorrhage and gastrointestinal (GI) bleeding
- ☑ **Secondary bacterial infections:** Mainly by group A *Streptococcus* and *Staphylococcus aureus*
- ☑ **Encephalitis:** (Infrequent complication) 1 in 50,000 cases of varicella in unvaccinated children
- ☑ **Cerebellar ataxia:** [Most common central nervous system (CNS) manifestation] 1 in 4,000 cases of varicella in unvaccinated children
- ☑ **Pneumonia:** Primary varicella pneumonia in adults, secondary bacterial pneumonia in children
- ☑ **Progressive varicella:** Seen in severely immunocompromised (absolute lymphocyte count <500) involving visceral organ
- ☑ **Herpes zoster:** Occurs mostly in adults and elderly complicated by postherpetic neuralgia.

Others: Nephritis, nephrotic syndrome, aseptic meningitis, Guillain–Barré syndrome, transverse myelitis, arthritis, myocarditis, pericarditis, pancreatitis, orchitis, and hepatitis.

Diagnosis

Primary diagnosis is by clinical appearance and epidemiological linkage to similar case and usually no tests needed.

- ☑ **Complete blood count:** Leukopenia followed by relative and absolute lymphocytosis
- ☑ **Liver function test:** Elevated liver enzymes
- ☑ **Cerebrospinal fluid (CSF) study:** Lymphocytic pleocytosis, elevated protein, and normal sugar
- ☑ **Confirmatory diagnosis:** Real-time polymerase chain reaction (PCR) (vesicular fluids and crusts) most sensitive and specific.

Antibody titer [immunoglobulin G (IgG)] four-fold rise confirms acute infection, IgM lacks sensitivity and specificity.

Treatment

Uncomplicated varicella and herpes-zoster needs no routine antiviral management except:

- ☑ Nonpregnant >12 years of age
- ☑ >12 months of age with chronic cutaneous and pulmonary disorders
- ☑ Children receiving corticosteroid and salicylate (Reye syndrome)
- ☑ Secondary cases among household contacts

Oral acyclovir (20 mg/kg/dose) four doses for 5 days preferably within 24 hours of exanthem (keep patient well hydrated)
Other drugs recommended for 2–18 years—famciclovir and valacyclovir
Monitoring of patient on acyclovir—renal function and neutrophil count

- ☑ Immunocompromised individual needs intravenous (IV) antiviral (even if 72 hours of exanthema have crossed) for 7–10 days or till no new lesions for 48 hours
- ☑ Acyclovir-resistant varicella [primarily in children infected with human immunodeficiency virus (HIV)] may be treated with foscarnet or cidofovir.

Treatment/Prevention

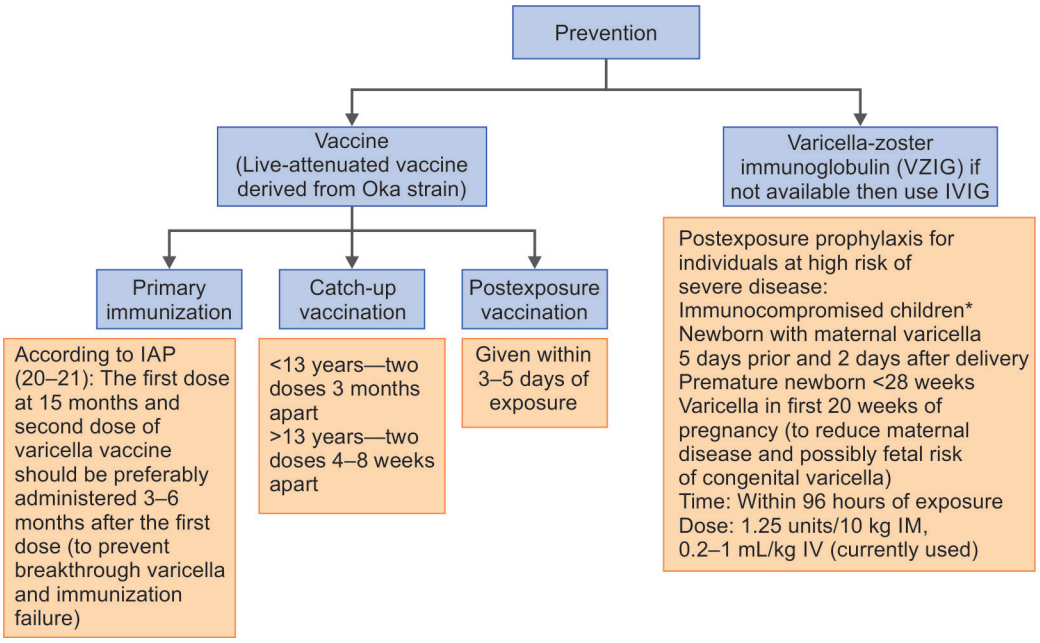

* If VZIG or intravenous immunoglobulin (IVIG) not affordable in immunocompromised children exposed to varicella, recently antivirals have found to be effective.

- ☑ **Children < 2 years:** Acyclovir in dose of 10 mg/kg (maximum 800 mg) four times daily for 7 days beginning 7–10 days after exposure.
- ☑ **Children 2 to <18 years:** Oral acyclovir in dose of 10 mg/kg (maximum 800 mg) four times daily or valacyclovir in dose of 20 mg/kg (maximum 1,000 mg) three times daily for 7 days.

Further Reading

- ☑ Centers for Disease Control and Prevention. (2021). Chickenpox (Varicella). [online] Available from: www.cdc.gov/chickenpox/. [Last accessed April 2022].
- ☑ Kasi SG, Shivananda S, Marathe S, Chatterjee K, Agarwalla S, Dhir SK, et al. Indian Academy of Pediatrics (IAP) Advisory Committee on Vaccines and Immunization Practices (ACVIP): Recommended Immunization Schedule (2020-21) and Update on Immunization for Children Aged 0 through 18 Years. Indian Pediatr. 2021;58: 44-53.
- ☑ Kliegman RM, St. Geme J. Nelson's Textbook of Pediatrics, 21st edition. Amsterdam, Netherlands: Elsevier; 2020.
- ☑ Lopez AS, Zhang J, Marin M. Epidemiology of varicella during the 2-dose varicella vaccination program—United States, 2005-2014. MMWR Morb Mortal Wkly Rep. 2016;65:902-5.
- ☑ Marin M, Marti M, Kambhampati A, Jeram SM, Seward JF. Varicella vaccine effectiveness worldwide: a systematic review and meta-analysis. Pediatrics. 2016;137(3):1-10.
- ☑ Parthasarathy A, Menon PSN, Nair MKC. IAP Textbook of Pediatrics, 7th edition. New Delhi: Jaypee Brothers Medical Publishers (P) Ltd.; 2019.
- ☑ Yewale V, Choudhury P, Thacker N. Varicella vaccine. IAP Guidebook on Immunization; IAP Committee on Immunization 2009-2011. Indian Academy of Pediatrics; 2011. pp. 111-15.

Indian Academy of Pediatrics (IAP)

STANDARD TREATMENT GUIDELINES 2022

Juvenile Idiopathic Arthritis

Lead Author

Sathish Kumar

Co-Authors

Narendra Bagri, Chandrika Bhat

Under the Auspices of the IAP Action Plan 2022

Remesh Kumar R
IAP President 2022

Upendra Kinjawadekar
IAP President-Elect 2022

Piyush Gupta
IAP President 2021

Vineet Saxena
IAP HSG 2022–2023

© Indian Academy of Pediatrics

IAP Standard Treatment Guidelines Committee

Chairperson

Remesh Kumar R

IAP Coordinator

Vineet Saxena

National Coordinators

SS Kamath, Vinod H Ratageri

Member Secretaries

Krishna Mohan R, Vishnu Mohan PT

Members

Santanu Deb, Surender Singh Bisht, Prashant Kariya, Narmada Ashok, Pawan Kalyan