Pneumothorax in Children

52

Definition

- ☑ Pneumothorax (PTX) refers to the presence of air in the pleural cavity between parietal and visceral pleura
- ☑ 4/100,000 in boys and 1/100,000 in girls.

Contributory Factors

- ☑ Bullae and blebs apical lobes
- ☑ *Pleural porosity*: Inherent areas of disturbed mesothelial cells
- ☑ Folliculin gene mutations
- ☑ Tobacco smoking.

Types

- ☑ *Spontaneous PTX (develops without obvious trauma)*:
  - Primary spontaneous pneumothorax (PSP):
    - No underlying lung disease
    - Occurs in otherwise tall thin adolescent boys
    - Smoking is an risk factor
    - Apical blebs historically been cited as risk factor (even though controversial)
  - Secondary spontaneous pneumothorax (SSP):
    - With underlying lung disease
    - Cystic fibrosis (CF) and non-CF bronchiectasis
    - Asthma and foreign body
    - Thoracic endometriosis
    - Lung malformations such as congenital pulmonary airway malformation (CPAM) and congenital lobar emphysema (CLE)
    - Tumors such as Langerhans cell histiocytosis (LCH) and pleuropulmonary blastoma
    - Marfan and Ehlers–Danlos syndrome
    - End-stage interstitial lung disease
- ☑ *Traumatic pneumothorax (TRP)*:
  - Following chest wall trauma
  - Air typically leaks from the lung (visceral pleural rupture often iatrogenic) or from the environment (in parietal pleural penetrating injury often traumatic)
- ☑ *Neonatal PTX*:
  - Secondary to respiratory distress syndrome (RDS), meconium aspiration, and mechanical ventilation
  - Oligohydramnios secondary to renal agenesis or obstructive uropathy can lead to lung hypoplasia that can be associated with spontaneous air leak. So, screen for obstructive uropathy in all cases of unexplained PTX.

Symptoms

- ☑ Depends on size of PTX, rapidity, degree of respiratory compromise, and presence of underlying lung disease
- ☑ Symptoms may be minimal or absent
- ☑ Sharp chest pain often pleuritic and worse on inspiration with or without cough and breathlessness.

Signs

- ☑ May be subtle tachypnea
- ☑ On the affected side
  - Decreased chest expansion
  - Hyper-resonance on percussion
  - Diminished breath sounds
- ☑ In case of bilateral PTX above findings are difficult to interpret.

Tension Pneumothorax

- ☑ Collection of air in pleura under pressure (more than atmospheric pressure) causing cardiorespiratory compromise by pressure effects on lungs and decrease in venous return leading to cyanosis, sweating, severe tachypnea, tachycardia, and shock
- ☑ More common in SSP and TRP
- ☑ Uncommon in PSP.

Investigations

Chest X-ray

- ☑ Upright chest X-ray (CXR) is the first line of investigation.
- ☑ In supine films, air often collected anteriorly and difficult to spot.
- ☑ *Findings*:
  - Black rim of air radiolucent shadow between visceral pleural line and chest wall and absence of bronchovascular markings.
  - *Large PTX*: Presence of visible rim of air >2 cm between lung margin and chest wall at the level of hilum.
- ☑ *Tension pneumothorax*:
  - Mediastinal shift to the contralateral side
  - Collapse of the ipsilateral lung
  - When suspected, proceed for needle aspiration rather than confirmation with CXR.

Investigations

Ultrasound of Chest

- ☑ Increasingly being utilized and replacing CXR as a point of care or bedside tool in pediatric intensive care unit (PICU) to diagnose PTX.
- ☑ Multiple rib spaces should be scanned at multiple places throughout lungs.
- ☑ In case of morbid obesity, heavy musculature and subcutaneous emphysema visualization of the pleural line is difficult and ultrasonography (USG) of chest may miss PTX.
- ☑ Can be used to evaluate lung expansion after chest tube placement and before removal.

Signs of Pneumothorax in Ultrasonography of Chest

- ☑ Presence of lung sliding, lung pulse, and B lines excludes PTX
- ☑ Absence of lung slides suggests the possibility
- ☑ Presence of lung point confirms PTX
- ☑ Barcode or stratosphere sign in mode
  - *B lines*: Vertical comet artifacts due to fluid in alveoli/interstitium.
  - *Lung slide*: Pleural line that moves in synchrony with respiratory cycle.
  - *Lung pulse*: Pleural line that moves in synchrony with cardiac pulsations.
  - *Lung point*: The point where visceral pleura (lung) begins to separate from parietal pleura (chest wall) at the margin of PTX.

Computed Tomography of Chest

- ☑ Not routinely recommended for diagnosis of PTX
- ☑ Only to identify the underlying disease (apical blebs)
- ☑ To scan the normal other lung in case of recurrences are suspected
- ☑ No universally accepted specific pediatric guidelines for its indications in PTX.

Flowchart 1: Approach to pneumothorax in children.

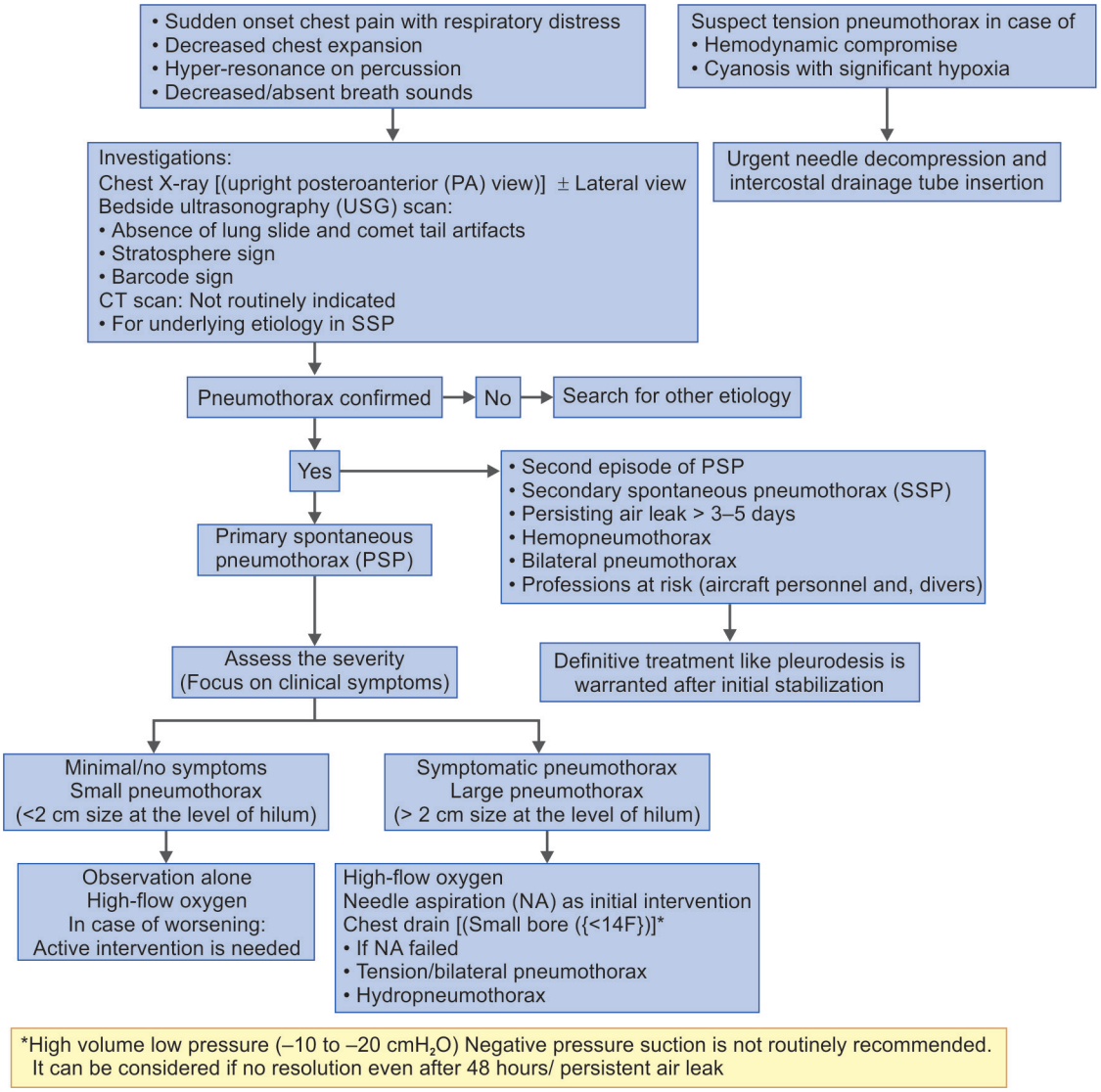

☑ *Depends on*:

- Size of PTX
- Cause of PTX
- Presence of respiratory distress
- Presence of underlying lung disease

Management

☑ *Goal*:

- Remove air from pleural space
- Prevention of recurrence

☑ *Treatment options*:

- Observation →→ Oxygen supplementation →→ Simple needle aspiration →→ Chest tube insertion →→ Pleurodesis.

Observation

☑ Small PTX (<2 cm from lung margin to chest wall at the level of hilum)

☑ No respiratory distress

☑ Not to be done in very young children and in cases of traumatic PTX.

High-flow Oxygen

☑ High-flow oxygen (10%) works by decreasing partial pressure of nitrogen and allowing it to diffuse from pleural space and hasten the reexpansion of lung

☑ 100% oxygen through nonbreathing face mask (unpleasant)

☑ Once drain is inserted high-flow oxygen adds little to the management.

Needle Aspiration

☑ *Indications*:

- Large PTX (>2 cm at the level of hilum)
- Presence of respiratory distress
- Tension PTX.

☑ Simple aspiration should be done with large bore intravenous catheter with a 3-way stopcock.

☑ If no further air is aspirated, stopcock can be closed and catheter is secured to chest wall.

☑ CXR after 4 hours of observation, if normal, catheter can removed.

☑ In case of persistent air leaks, tube thoracostomy should be performed.

Thoracostomy Tube

- ☑ Simple aspiration fails to inflate the lung
- ☑ If PTX recurs within 7 days
- ☑ For all patients with an underlying lung disease (unless small and asymptomatic).

Procedure

- ☑ *Site*:
  - Midclavicular line, second intercostal space, with one end positioned into the apex of lung and the other end in underwater seal.
  - In case of persistent leaks, larger chest drains 14–20 F may be needed.
- ☑ *Size*:
  - 10 F pigtail catheter cause less pain and will not leave any scar.
- ☑ *Suction*:
  - Required only when lung fails to inflate after 24 hours at –20 cmH_2O.
- ☑ *When to remove*:
  - Lung fully reinflated for 24 hours
  - No bubbling
- ☑ *To clamp or not*:
  - In case of uncertainty of air leak, it can be clamped for *4 hours* and then released while closely observing the underwater seal.
- ☑ *Reexpansion pulmonary edema*:
  - Suspect the above condition when child develops new onset cough, breathlessness, and chest tightness after insertion of chest drain.
  - Often they resolve spontaneously, if not, positive end-expiratory pressure (PEEP) may be required.

Pleurodesis

Obliterate the pleural space by sticking parietal and visceral pleura together.

- ☑ *Indications*:
  - First occurrence of a secondary spontaneous PTX
  - Second recurrence of a primary spontaneous PTX
  - Bilateral spontaneous pneumothoraces
  - Persistent air leak for > 5–7 days of failure to expand the lung

Management

Pleurodesis

- ☑ *Options*:
  - Surgical pleurodesis
  - Chemical pleurodesis
- ☑ *Surgical pleurodesis is preferred*:
  - Abrasion of pleural surfaces to create inflammatory process causing two pleural membranes to adhere
  - Open thoracotomy pleurodesis with mechanical abrasion appears to be effective in preventing recurrences when compared to video-assisted thoracoscopic surgery
- ☑ *Chemical pleurodesis*:
  - Preferred in children who are not suitable for surgery
  - Can be done by injecting talc/doxycycline/povidone iodine/autologous blood patch
  - The procedure is painful with recurrence rate 25%.

Flying and Diving

- ☑ No consensus regarding travel post-PTX in children
- ☑ Adult guidelines recommends delayed flying anywhere between *7 days and 6 weeks postresolution*
- ☑ Risk of recurrence of ipsilateral and contralateral PTX should be explained
- ☑ Recurrence is more with secondary PTX
- ☑ Children who had PTX should never do scuba diving.

Further Reading

- ☑ MacDuff A, Arnold A, Harvey J; BTS Pleural Disease Guideline Group. Management of spontaneous pneumothorax: British Thoracic Society Pleural Disease Guideline 2010. Thorax. 2010;65:ii18-31.
- ☑ O'Lone E, Elphick HE, Robinson PJ. Spontaneous pneumothorax in children: when is invasive treatment indicated? Pediatr Pulmonol. 2008;43:41-6.
- ☑ Qureshi FG, Sandulache VC, Richardson W, Ergun O, Ford HR, Hackam DJ. Primary vs delayed surgery for spontaneous pneumothorax in children: which is better? J Pediatr Surg. 2005;40:166-9.
- ☑ Robinson PD, Blackburn C, Babl FE, Gamage L, Schutz J, Nogajski R, et al. Management of pediatric spontaneous pneumothorax: a multicentre retrospective case series. Arch Dis Child. 2015;100: 918-23.
- ☑ Seguier-Lipszyc E, Elizur A, Klin B, Vaiman M, Lotan G. Management of primary spontaneous pneumothorax in children. Clin Pediatr (Phila). 2011;50:797-802.

Indian Academy of Pediatrics (IAP)

STANDARD TREATMENT GUIDELINES 2022

Infectious Mononucleosis

Lead Author
Abhay K Shah

Co-Authors
Mrutunjay Dash, Manu Chaudhary

Under the Auspices of the IAP Action Plan 2022

Remesh Kumar R
IAP President 2022

Upendra Kinjawadekar
IAP President-Elect 2022

Piyush Gupta
IAP President 2021

Vineet Saxena
IAP HSG 2022–2023

© Indian Academy of Pediatrics

IAP Standard Treatment Guidelines Committee

Chairperson

Remesh Kumar R

IAP Coordinator

Vineet Saxena

National Coordinators

SS Kamath, Vinod H Ratageri

Member Secretaries

Krishna Mohan R, Vishnu Mohan PT

Members

Santanu Deb, Surender Singh Bisht, Prashant Kariya, Narmada Ashok, Pawan Kalyan