Infectious Mononucleosis

54

Introduction

Infectious mononucleosis (IM) is a common viral illness characterized primarily by fever, sore throat, generalized lymphadenopathy, fatigue, and malaise **(Fig. 1)**. By and large it is a self-limiting benign illness but at times, it can have a serious course, especially in adolescent and older children. It may result into benign and malignant lymphoproliferative disorders.

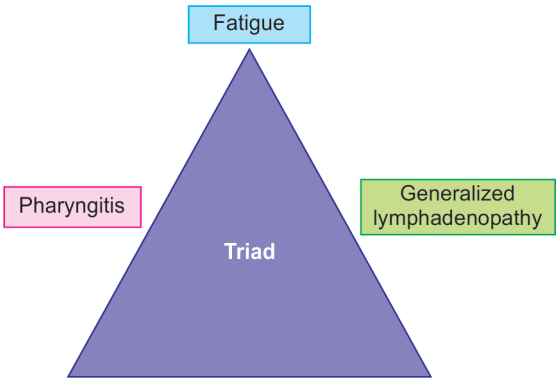

Fig. 1: Classic triad of infectious mononucleosis (IM).

Epidemiology

It is caused by Epstein–Barr virus (EBV) (human herpes virus type IV) type 1 and 2 and is transmitted through body fluids, especially saliva. Intense personal contact with shedders and poor hygiene are also contributors. Fomites do not transmit EBV virus. In children sharing toys, utensils, etc., on which they have drooled are important sources. Most people get infected with it at some point in their life. EBV1 more prevalent worldwide, EBV2 is more common in Africa.

Pathology

In primary infection, EBV mainly infects both oral epithelial cells and tonsillar B lymphocytes causing viral replication and dissemination of infected B lymphocytes in peripheral blood and lymphoreticular system. Under some circumstances EBV may infect T cells, natural killer (NK) cells, and smooth muscle cells. In some individuals, because of poor presentation by specific human leukocyte antigens or the genetic background infected T/NK cells evade host immunity and survive. Like other herpes viruses, latent infection is also common in EBV, but the reactivation is unlikely to be severe.

Incubation Period

About 30–50 days, may be shorter in children <6 weeks.

Clinical Features

Various clinical features are described in **Figure 2**.

- Fever
- Headache
- Malaise
- Periorbital edema

Moderate-to-severe pharyngitis with marked tonsillar enlargement and exudates petechiae on soft palate

Maculopapular rashes over the trunk 3–15%
Rash becomes more prominent after use of amoxicillin/ampicillin**

Splenomegaly	50%
Hepatomegaly	10%
Tender, generalized lymphadenopathy	90%

High white blood cell, over 20% atypical reactive lymphocytes also known as Downey cells

Fig. 2: Clinical features of infectious mononucleosis (IM).

*Anterior, posterior cervical lymph node (LN) and submandibular LN are most common. Epitrochlear lymphadenopathy highly suggestive of IM.

**Ampicillin rash, which is morbilliform vasculitis rash, immune mediated, resolves without specific treatment.

Differential Diagnosis

Heterophile antibody negative IM like syndrome is seen in many conditions such as:

- ☑ Cytomegalovirus (CMV) infection
- ☑ *Toxoplasma gondii*
- ☑ Human immunodeficiency virus (HIV)
- ☑ Adenoviral illness
- ☑ Group A streptococcal pharyngitis
- ☑ Herpes simplex virus (HSV)
- ☑ Human herpes virus-6 (HHV-6)
- ☑ Atopic dermatitis, especially Gianotti–Crosti syndrome in which symmetrical cheek rash with multiple erythematous papules that coalesce into plaques.

Investigations

Epstein–Barr Virus Diagnosis

- ☑ *CBC*: Absolute lymphocyte count >4,500/µL or a differential count >50%.
- ☑ *Peripheral blood smear*: Significant atypical lymphocytosis, defined as >10% of lymphocytes. *Please remember that atypical reactive lymphocytes are also seen in other conditions such as CMV, varicella, hepatitis A, and even gondii. Hence, they all are considered causes of IM and are not specific for EBV infection.*
- ☑ *Heterophile antibody (Paul Bunnell test)*: It was used as screening test until now. It detects heterophile antibodies in immune response to EBV.
- ☑ *Serology* ***(Table 1)***: Viral capsid antigen (VCA), early antigen (EA), and EBV nuclear antigen (EBNA).
  Immunoglobulin M (IgM) response to VCA is diagnostic of acute infection but can be detected up to 4 weeks and very rarely till 3 months. Antibodies to EA emerge transiently during convalescence and attain high titers in cases with EBV-related Burkitt lymphoma. Anti-EBNA antibodies are last to develop and may persist in low titers lifetime.
- ☑ *Detection of EBV virus*: Usually used in immunocompromised patients or unrevealing serology testing. Qualitative and quantitative both tests available.

TABLE 1: Serology and types of Epstein–Barr virus (EBV) infection.

Infection type	*VCA IgG*	*VCA IgM*	*EA*	*EBNA*
Acute	+	+	+/–	–
Recent infection	+	+/–	+/–	–
Past infection	+	–	+/–	+

(EA: early antigen; EBNA: EBV nuclear antigen; IgG: immunoglobulin G; IgM: immunoglobulin M; VCA: viral capsid antigen)

Acute Complications

- ☑ *Rash*: Morbilliform rash, may happen post ampicillin and, to a lesser extent, penicillin or other antibiotics
- ☑ *Airway obstruction*:
  - Due to massive lymphoid hyperplasia and mucosal edema
  - Steroids may be indicated in impending obstruction
  - Severe obstruction may need tracheostomy or endotracheal intubation
- ☑ *Splenic rupture*: One to two cases per thousand cases of IM
- ☑ *Lemierre's disease*: Some case series report coinfection with *Fusobacterium*.

Delayed Complications

- ☑ *Chronic active EBV infection*:
  - Life-threatening lymphoproliferative disorder that may involve B or T lymphocytes or NK cells
  - Persistent IM like syndrome and EBV viremia
  - Swelling of lymph nodes and hepatosplenomegaly along with liver function test abnormalities and cytopenias
  - If untreated lead to T cell infiltration of tissues, curative option being hematopoietic stem cell transplantation (HSCT).
- ☑ *Oral hairy leukoplakia*:
  - Corrugated painless plaques on lingual tissue that, unlike *Candida*, cannot be scraped from the surface to which they adhere
  - Mostly in immunocompromised hosts.
- ☑ *Lymphoproliferative disorders*:
  - *Hemophagocytic lymphohistiocytosis (HLH)*: Present with fever, generalized lymphadenopathy, hepatosplenomegaly, hepatitis, pancytopenia, and coagulopathy. One of the most common causes of infectious triggers of HLH.
  - *Lymphomatoid granulomatosis*: Angiodestructive disorder of the lymphoid system
  - *X-linked lymphoproliferative disease*: Selective immunodeficiency to EBV, manifested by severe or fatal IM and acquired immunodeficiency
  - *Post-transplant lymphoproliferative disease*:
    - Benign polyclonal B cell proliferation to malignant B cell lymphoma
    - Related to the degree and type of immunosuppression
    - Most common in EBV-negative recipients who develop primary EBV infection, usually from a graft from an EBV-positive donor.

Malignancy

- ☑ EBV is a transforming virus and has been causally linked to a variety of malignancies, including lymphomas in transplant recipients.
- ☑ Malignancies include Burkitt lymphoma, tumors in patients with HIV, Hodgkin lymphoma, nasopharyngeal and other head and neck carcinomas, gastric carcinoma, and T cell lymphoma.

In majority of cases, IM is a self-limiting disease. Symptomatic treatment, adequate rest, maintaining proper hydration and providing required nutrition are the cornerstones of the management. There is no currently accepted specific antiviral therapy. Despite their potency in vitro, antiviral drugs have limited use in vivo for treatment of acute primary EBV infection as well as EBV-associated malignancies due to toxicity and nonspecific antiviral activities. This is because most of the symptoms and signs of acute EBV are due to immunopathic responses to EBV-infected cells. There is debatable role of steroids, and they may impair clearance of the viral load.

Table 2 describes various modalities of treatment.

TABLE 2: Modalities of treatment.

Modality	***Action***	***Remarks***
General management	Paracetamol 15–20 mg/kg/dose 6 hourly as and when needed for fever, headache, and myalgia	No added advantage of potent NSAIDs Adequate rest, maintaining proper hydration, and providing required nutrition are the cornerstones of the management
Specific antiviral therapy	No currently accepted specific antiviral therapy	Mainly used in immunocompressive states, ganciclovir and valganciclovir have been used to treat EBV infections in immunocompromised hosts but there are no controlled trials demonstrating clinical efficacy
Steroids	Debatable role and they may impair clearance of the viral load Not to be used in uncomplicated cases	Corticosteroids are often prescribed to treat inflammatory complications such as airway obstruction or autoimmune phenomena such as autoimmune hemolytic anemia and thrombocytopenia with hemorrhage and meningitis Dose prednisolone 1 mg/kg/day with a maximum dose of 60 mg/day or its equivalent for 7 days and to be tapered for next 7 days
Others	Hematopoietic stem cell transplantation	Only option for chronic active EBV with complications

(EBV: Epstein–Barr virus; NSAIDs: nonsteroidal anti-inflammatory drugs)

Prognosis

- ☑ The prognosis for EBV infection is good. *Almost all people infected with EBV recover completely in about 1–3 months*. Fever and lymphadenopathy usually resolve within 2 weeks after onset but can persist for a month, or in rare cases even longer. Neurological changes usually completely resolve, although a few cases may have some deficits. Although most infections become latent, most remain asymptomatic.
- ☑ Rare patients who become infected with EBV, or reactivate EBV, develop disease that does not resolve. Some of these patients develop fulminant IM and die within days or weeks of primary infection.
- ☑ Others develop chronic active Epstein–Barr virus (CAEBV) disease which is a rare disorder in which persons are unable to control infection with the virus. Over time, these patients develop progressive immunodeficiency and if not treated, succumb to opportunistic infections, hemophagocytosis, multiorgan failure, or EBV-positive lymphomas.
- ☑ CAEBV is refractory to antiviral therapy, interferon, intravenous immunoglobulin, and conventional chemotherapy and thus has a poor prognosis. The survival of patients with T cell-type CAEBV is significantly lower, compared with that of patients with NK cell-type CAEBV. The only proven effective treatment for the disease is HSCT.

Prevention

There is no vaccine for EBV and prevention is difficult. Risk can be reduced by not contacting body fluids like saliva from infected individuals and practicing good handwashing techniques. There are ongoing efforts to develop a vaccine against EBV—both vaccines to prevent primary infection or disease and therapeutic vaccines to treat EBV malignancies—but these have not been successful to date. Contact sports should be avoided to prevent splenic rupture. Child must be update as per the immunization schedule for various vaccine preventable diseases.

Further Reading

- ☑ American Academy of Pediatrics. Committee on Infectious Diseases. Red Book: Report of the Committee on Infectious Diseases. Elk Grove Village, IL: American Academy of Pediatrics; 1994.
- ☑ Balasubramanian S, Ganesh R, Kumar JR. Profile of EBV-associated infectious mononucleosis. Indian Pediatr. 2012;49:837-8.
- ☑ Katherine L, Sullivan JL. Infectious mononucleosis. N Engl J Med. 2010;362:1993-2000.
- ☑ Okano M, Kawa K, Kimura H, Yachie A, Wakiguchi H, Maeda A, et al. Proposed guidelines for diagnosing chronic active Epstein-Barr virus infection. Am J Hematol. 2005;80(1):64-9.
- ☑ Sonke GS, Ludwig I, van Oosten H, Baars JW, Meijer E, Kater AP, et al. Poor outcomes of chronic active Epstein-Barr virus infection and hemophagocytic lymphohistiocytosis in non-Japanese adult patients. Clin Infect Dis. 2008;47:105-8.

Indian Academy of Pediatrics (IAP)

STANDARD TREATMENT GUIDELINES 2022

CPR/BLS in Office Practice

Lead Author

LN Taneja

Co-Authors

Samarendra Mahapatro, Pranam Gowdar

Under the Auspices of the IAP Action Plan 2022

Remesh Kumar R
IAP President 2022

Upendra Kinjawadekar
IAP President-Elect 2022

Piyush Gupta
IAP President 2021

Vineet Saxena
IAP HSG 2022–2023

© Indian Academy of Pediatrics

IAP Standard Treatment Guidelines Committee

Chairperson

Remesh Kumar R

IAP Coordinator

Vineet Saxena

National Coordinators

SS Kamath, Vinod H Ratageri

Member Secretaries

Krishna Mohan R, Vishnu Mohan PT

Members

Santanu Deb, Surender Singh Bisht, Prashant Kariya, Narmada Ashok, Pawan Kalyan